

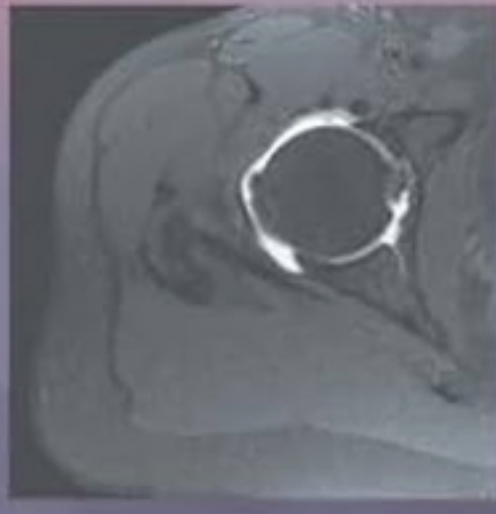
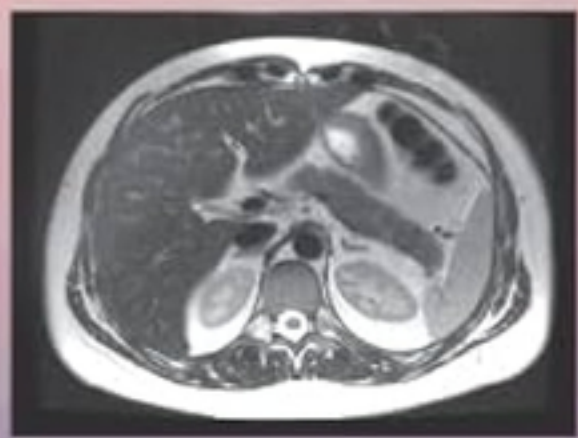
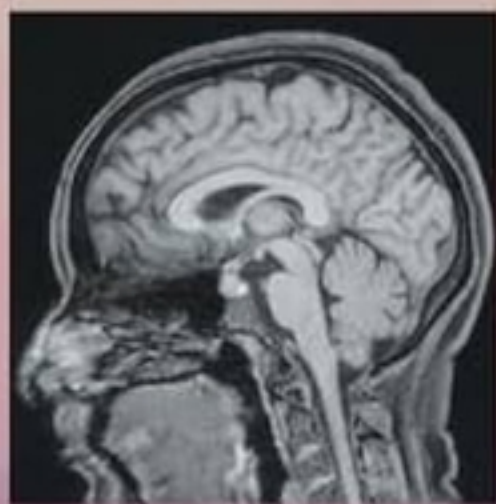
5th Edition



Enhanced  
**DIGITAL  
VERSION**  
Included

# SECTIONAL ANATOMY

*by MRI and CT*



MARK W. ANDERSON  
MICHAEL G. FOX  
NICHOLAS C. NACEY

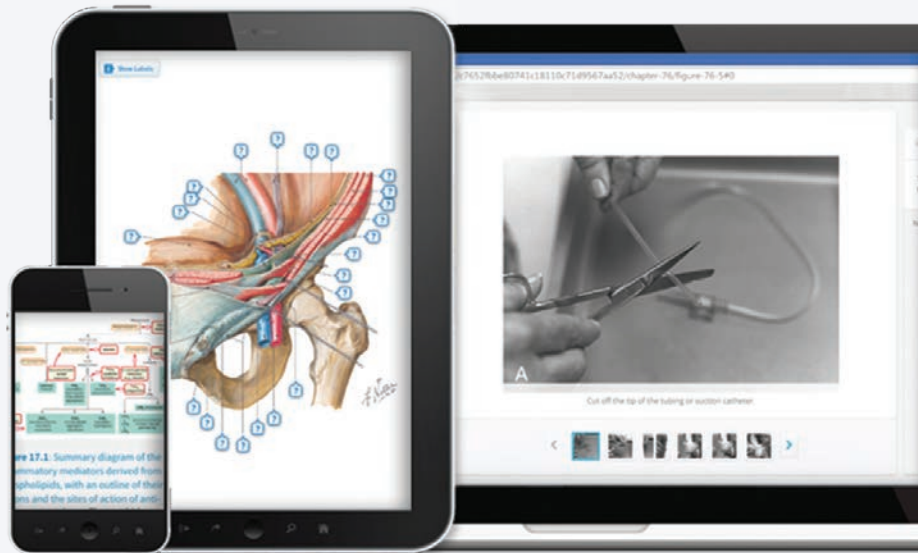


eBooks+

ELSEVIER

# Any screen. Any time. Anywhere.

Activate the eBook version  
of this title at no additional charge.



Elsevier eBooks+ gives you the power to browse, search, and customize your content, make notes and highlights, and have content read aloud.

## Unlock your eBook today.

1. Visit <http://ebooks.health.elsevier.com/>
2. Log in or Sign up
3. Scratch box below to reveal your code
4. Type your access code into the “Redeem Access Code” box
5. Click “Redeem”

It's that easy!

For technical assistance:  
email [textbookscom.support@elsevier.com](mailto:textbookscom.support@elsevier.com)  
call 1-800-545-2522 (inside the US)  
call +44 1 865 844 640 (outside the US)

Place Peel Off  
Sticker Here

Use of the current edition of the electronic version of this book (eBook) is subject to the terms of the nontransferable, limited license granted on <http://ebooks.health.elsevier.com/>. Access to the eBook is limited to the first individual who redeems the PIN, located on the inside cover of this book, at <http://ebooks.health.elsevier.com/> and may not be transferred to another party by resale, lending, or other means.



# SECTIONAL ANATOMY

*by MRI and CT*

*5th Edition*

# SECTIONAL ANATOMY

*by MRI and CT*

## MARK W. ANDERSON, MD

Harrison Distinguished Teaching Professor of Radiology  
Chief of the Division of Musculoskeletal Radiology  
Department of Radiology  
University of Virginia Health Sciences Center  
Charlottesville, Virginia

## MICHAEL G. FOX, MD

Musculoskeletal Division Chair  
Associate Professor of Radiology  
Department of Radiology  
Mayo Clinic College of Medicine  
Phoenix, Arizona

## NICHOLAS C. NACEY, MD

Associate Professor  
Department of Radiology and Medical Imaging  
University of Virginia Health Science Center  
Charlottesville, Virginia



Elsevier  
1600 John F. Kennedy Blvd.  
Ste 1800  
Philadelphia, PA 19103-2899

SECTIONAL ANATOMY BY MRI AND CT, FIFTH EDITION

ISBN: 978-0-323-93448-0

**Copyright © 2025 by Elsevier Inc. All rights are reserved, including those for text and data mining, AI training, and similar technologies.**

No part of this publication may be reproduced or transmitted in any form or by any means, electronic or mechanical, including photocopying, recording, or any information storage and retrieval system, without permission in writing from the publisher. Details on how to seek permission, further information about the Publisher's permissions policies and our arrangements with organizations such as the Copyright Clearance Center and the Copyright Licensing Agency, can be found at our website: [www.elsevier.com/permissions](http://www.elsevier.com/permissions).

This book and the individual contributions contained in it are protected under copyright by the Publisher (other than as may be noted herein).

**Notice**

Practitioners and researchers must always rely on their own experience and knowledge in evaluating and using any information, methods, compounds or experiments described herein. Because of rapid advances in the medical sciences, in particular, independent verification of diagnoses and drug dosages should be made. To the fullest extent of the law, no responsibility is assumed by Elsevier, authors, editors or contributors for any injury and/or damage to persons or property as a matter of products liability, negligence or otherwise, or from any use or operation of any methods, products, instructions, or ideas contained in the material herein.

Previous editions copyrighted 2017, 2007, 1995 and 1990.

*Senior Content Strategist:* Melanie Tucker  
*Senior Content Development Specialist:* Rishabh Gupta  
*Content Development Manager:* Ranjana Sharma  
*Publishing Services Manager:* Shereen Jameel  
*Project Manager:* Haritha Dharmarajan  
*Design Direction:* Brian Salisbury  
*Third World Compiler:* Sigfrido Ernesto Garcia

Printed in India

Last digit is the print number: 9 8 7 6 5 4 3 2 1



Working together  
to grow libraries in  
developing countries

[www.elsevier.com](http://www.elsevier.com) • [www.bookaid.org](http://www.bookaid.org)



# Preface

**W**ith the explosion of cross-sectional imaging, the accessibility of a high-quality anatomic atlas has become essential, and it is with great pleasure that we introduce the fifth edition of this classic atlas.

Since it was first published in 1990, it has become a standard anatomic reference source. The first three editions were masterfully edited by Drs. Georges El-Khoury, Ronald Bergman, and William Montgomery, and we are honored to be able to continue the tradition of excellence that they established.

This new fifth edition includes additional chapters on head CT, brain MRI, and cervical spine MRI. The corresponding online

version also allows for easy access anytime/anywhere and provides scroll and zoom functions that should further enhance the user's experience.

We hope that you will find this new edition to be an integral and valuable addition to your practice.

**Mark W. Anderson, MD**  
**Michael G. Fox, MD**  
**Nicholas C. Nacey, MD**

# Acknowledgments

**W**e are indebted to Drs. Georges El-Khoury and Ronald Bergman for their prior efforts in producing and improving this text and for allowing us to continue along the path of excellence they established. We also would like to thank Rishabh Gupta and Melanie Tucker from Elsevier for helping to bring this project to fruition. Thanks as well to our fellow Matthew Schmidt for his assistance. Dr. Anderson would like to thank all the residents and fellows who have made him a better radiologist, and his wife Amy whose sacrifice and support have made it all possible. Dr. Nacey would like to thank his wife

Mary as well as his children Ollie, Annie, Emmie, and Zach for all their support. Dr. Fox would like to thank his family (Katherine, Marie, Elizabeth, Michael Jr., and Jonathan) for their love and encouragement. Without their invaluable assistance, it would not have happened!

**Mark W. Anderson, MD**  
**Michael G. Fox, MD**  
**Nicholas C. Nacey, MD**

# Contents

Preface, v

Acknowledgments, vi

## **SECTION I** BRAIN, 1

**Chapter 1** CT of the Brain, 3

**Chapter 2** MRI of the Brain, 18

## **SECTION II** THORAX, 33

**Chapter 3** CT of the Thorax, 35

**Chapter 4** MRI of the Heart, 53

## **SECTION III** UPPER EXTREMITY, 65

**Chapter 5** MRI of the Pectoral Girdle and Chest Wall, 67

**Chapter 6** MRI of the Shoulder, 98

**Chapter 7** MR Arthrography of the Shoulder, 130

**Chapter 8** MRI of the Arm, 154

**Chapter 9** MRI of the Elbow, 178

**Chapter 10** MRI of the Forearm, 208

**Chapter 11** MRI of the Wrist, 235

**Chapter 12** MRI of the Hand, 261

## **SECTION IV** SPINE AND BACK, 285

**Chapter 13** MRI of the Cervical Spine, 287

**Chapter 14** MRI of the Thoracic Spine, 296

**Chapter 15** MRI of the Lumbar Spine, 309

## **SECTION V** ABDOMEN, 323

**Chapter 16** CT of the Abdomen, 325

**Chapter 17** MRI of the Abdomen, 345

## **SECTION VI** LOWER EXTREMITY, 371

**Chapter 18** MRI of the Hip, 373

**Chapter 19** MR Arthrography of the Hip, 402

**Chapter 20** MRI of the Thigh, 419

**Chapter 21** MRI of the Knee, 446

**Chapter 22** MRI of the Leg, 473

**Chapter 23** MRI of the Ankle, 500

**Chapter 24** MRI of the foot, 534

## **SECTION VII** PELVIS, 561

**Chapter 25** CT of the Male Pelvis, 563

**Chapter 26** CT of the Female Pelvis, 579

**Chapter 27** MRI of the Male Pelvis, 594

**Chapter 28** MRI of the Female Pelvis, 613

Index, 627



*Chapter*  
**1**

# **CT of the Brain**

# AXIAL

Figure 1.1.1

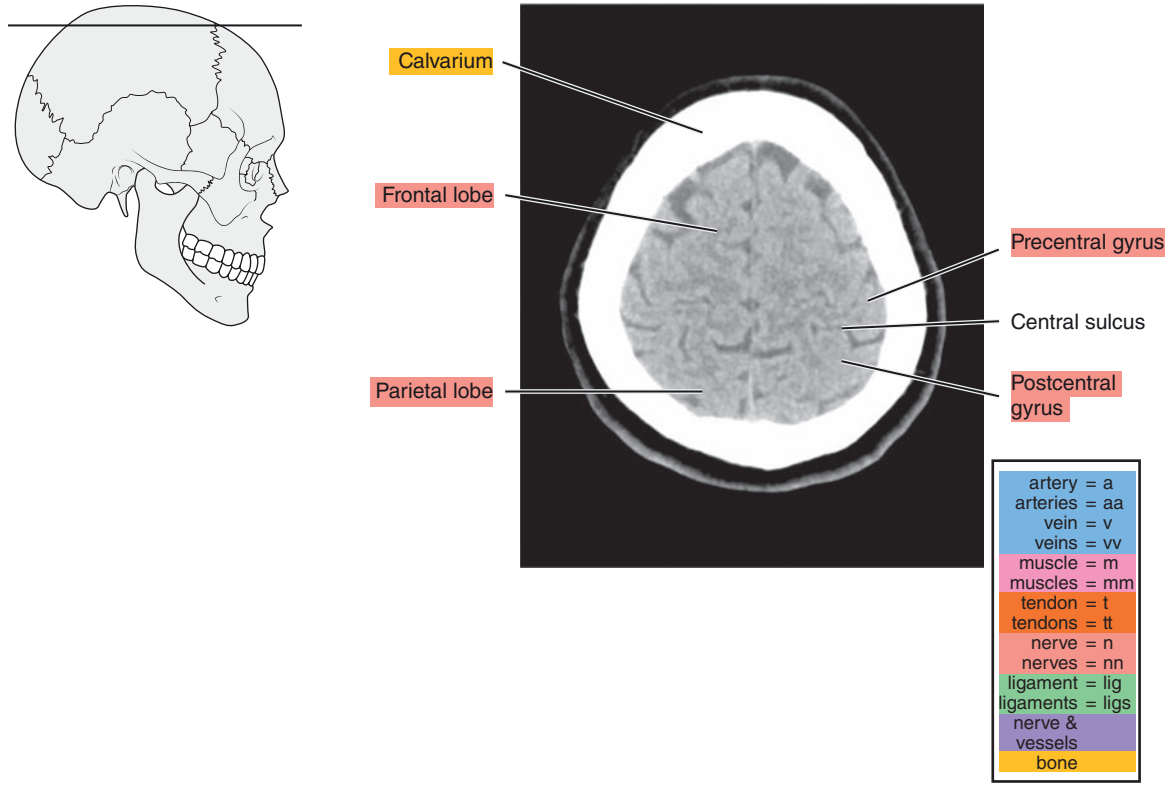


Figure 1.1.2

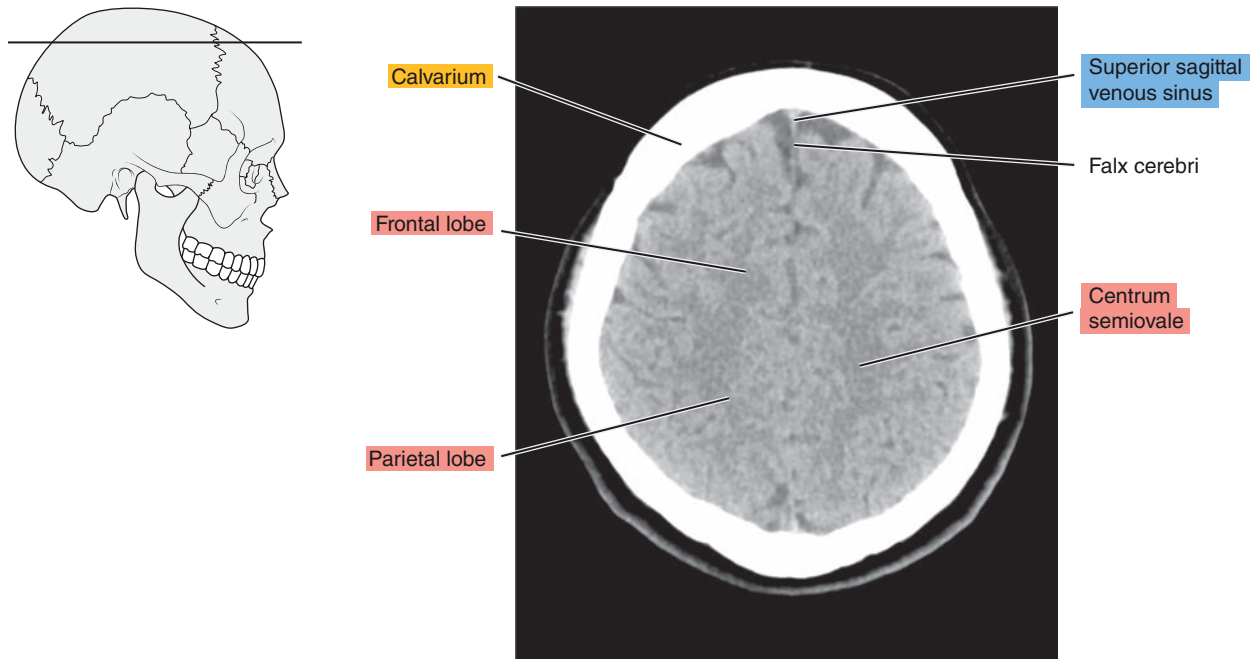


Figure 1.1.3

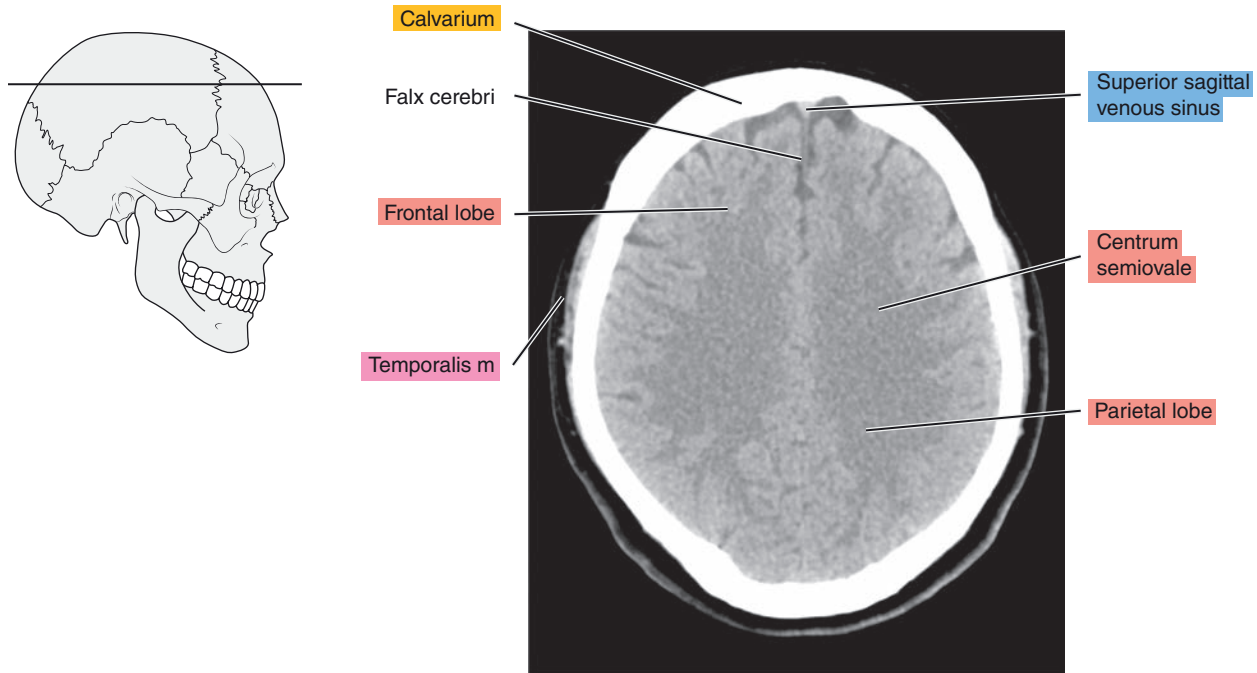


Figure 1.1.4

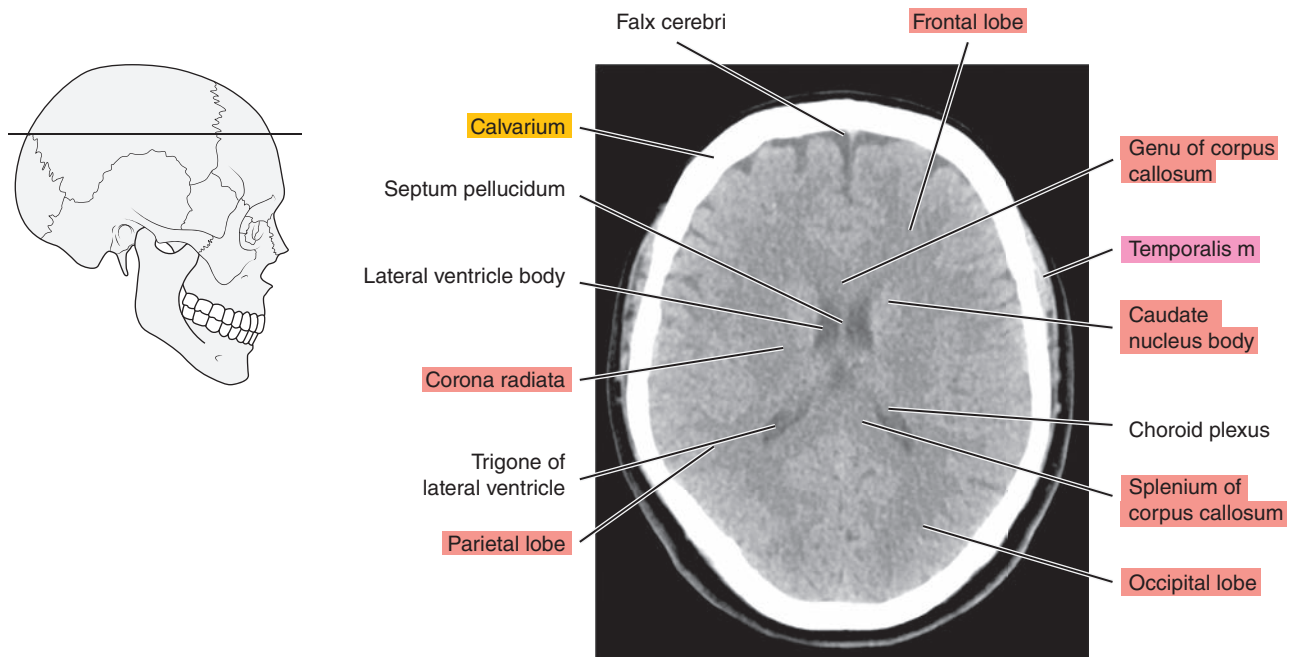




Figure 1.1.5

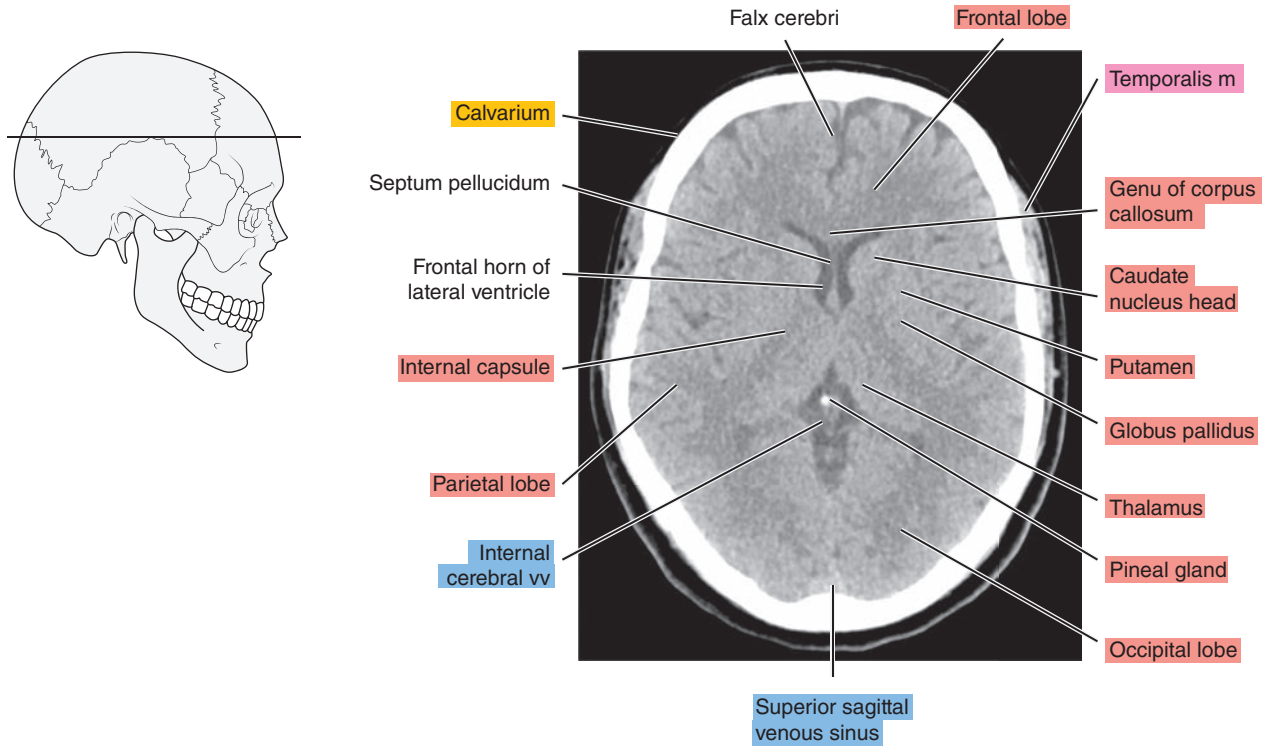


Figure 1.1.6

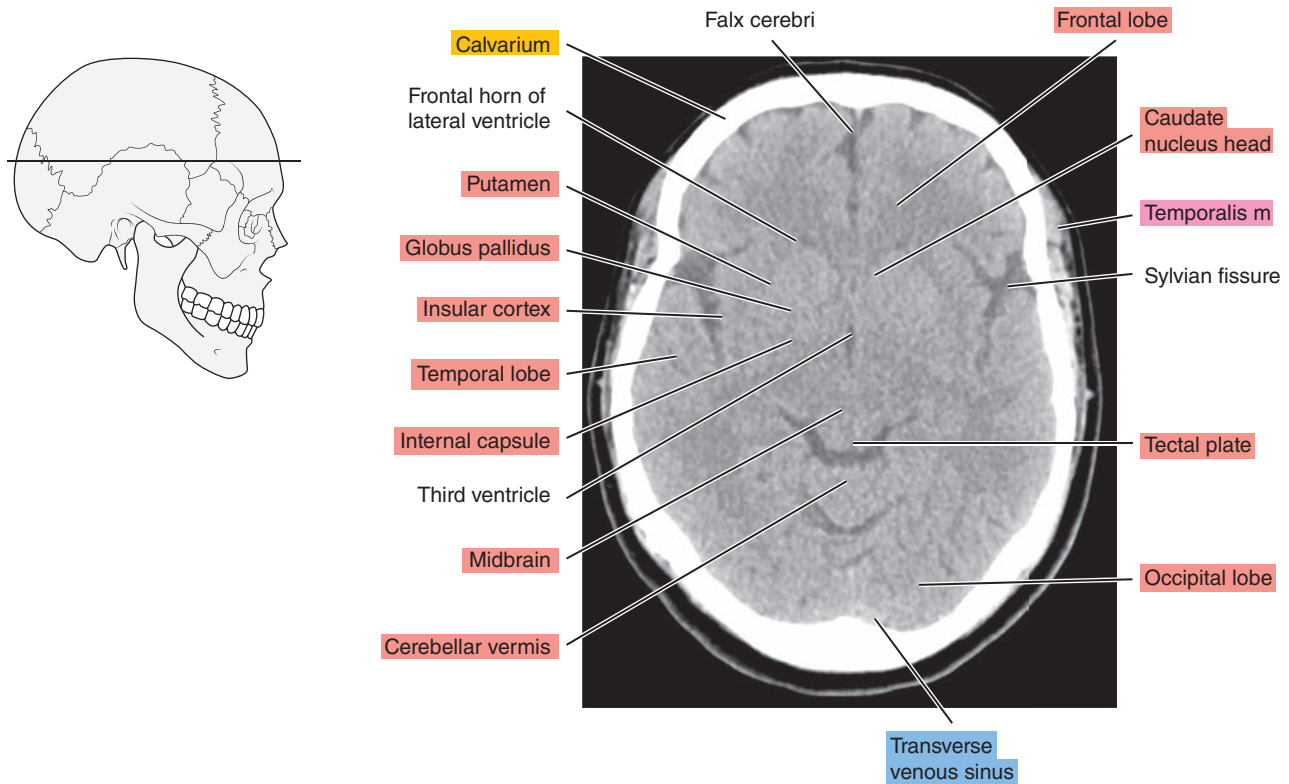


Figure 1.1.7

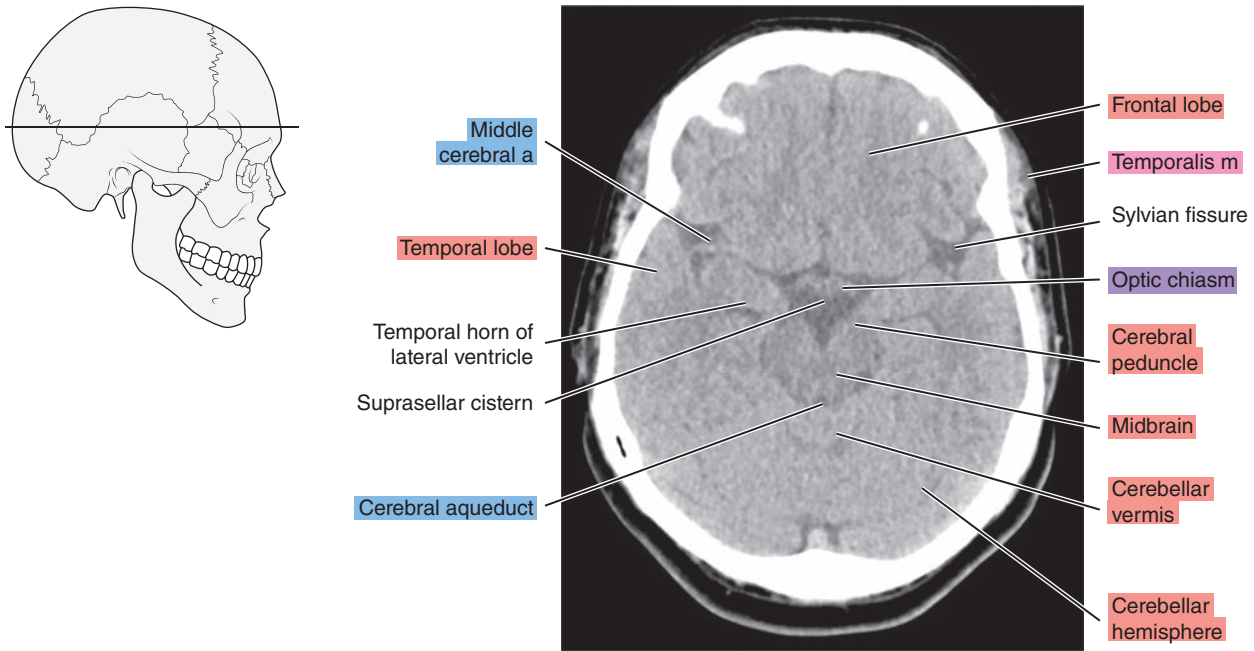


Figure 1.1.8

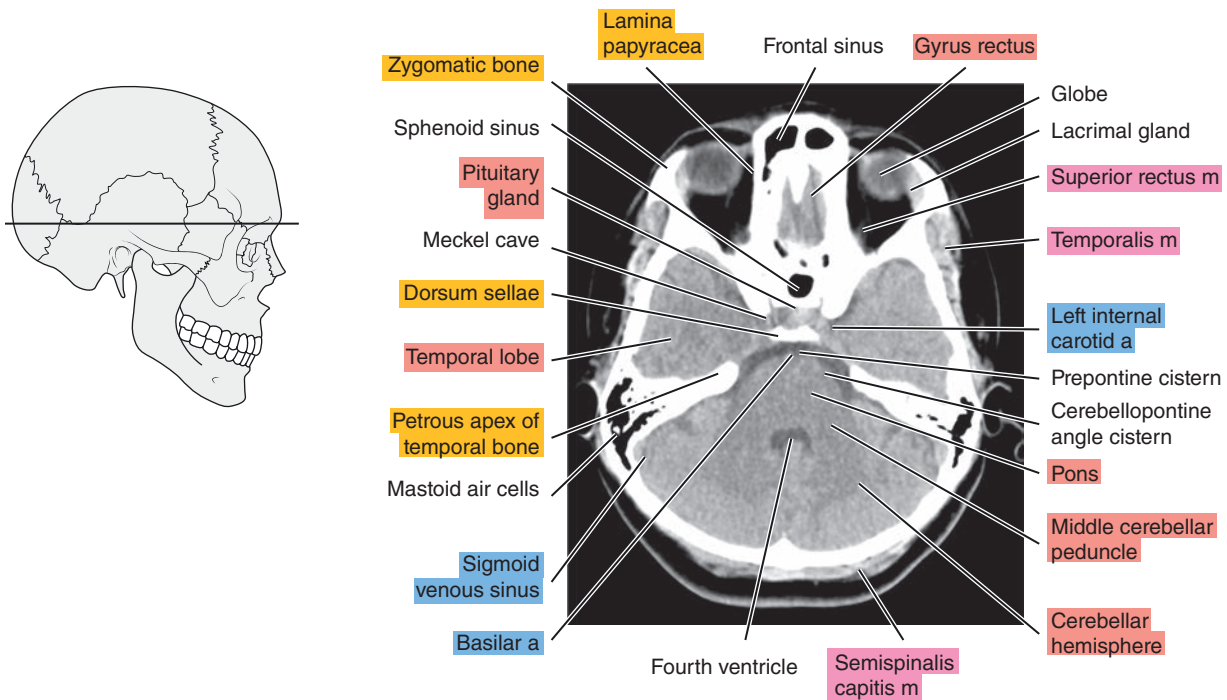


Figure 1.1.9

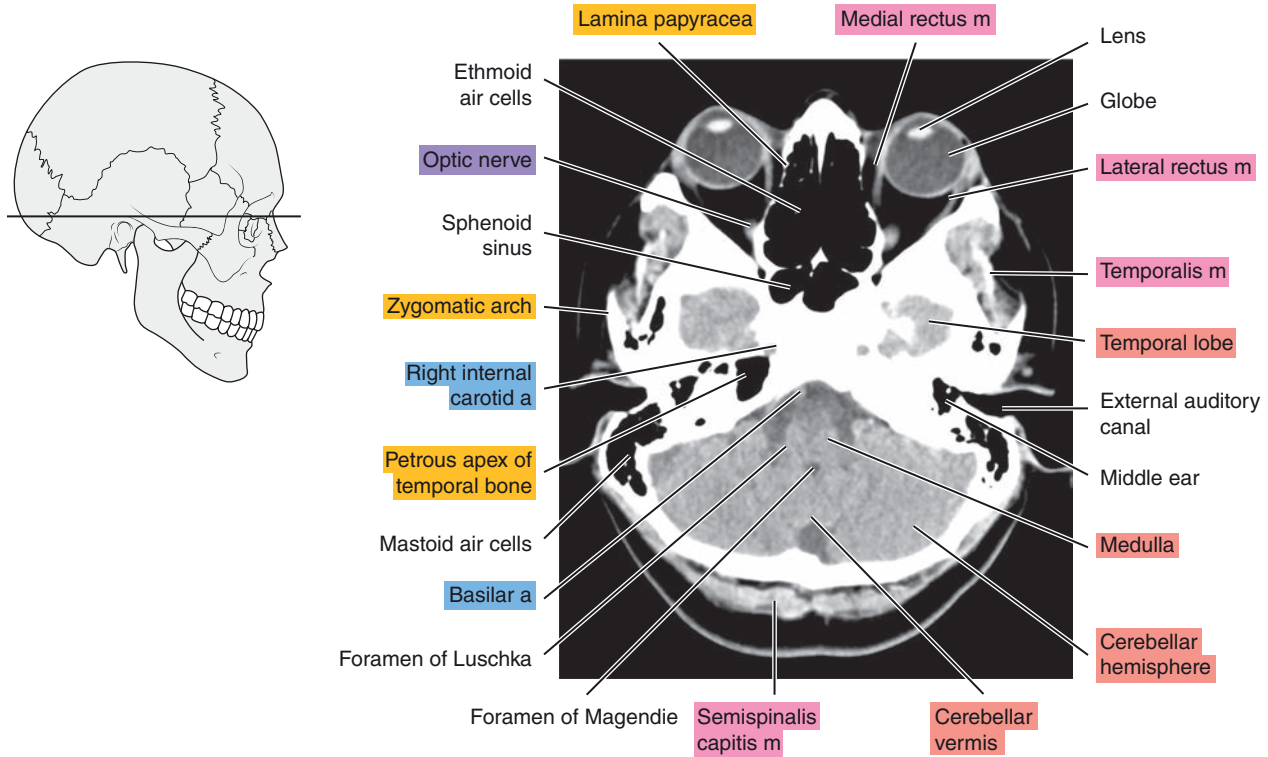


Figure 1.1.10

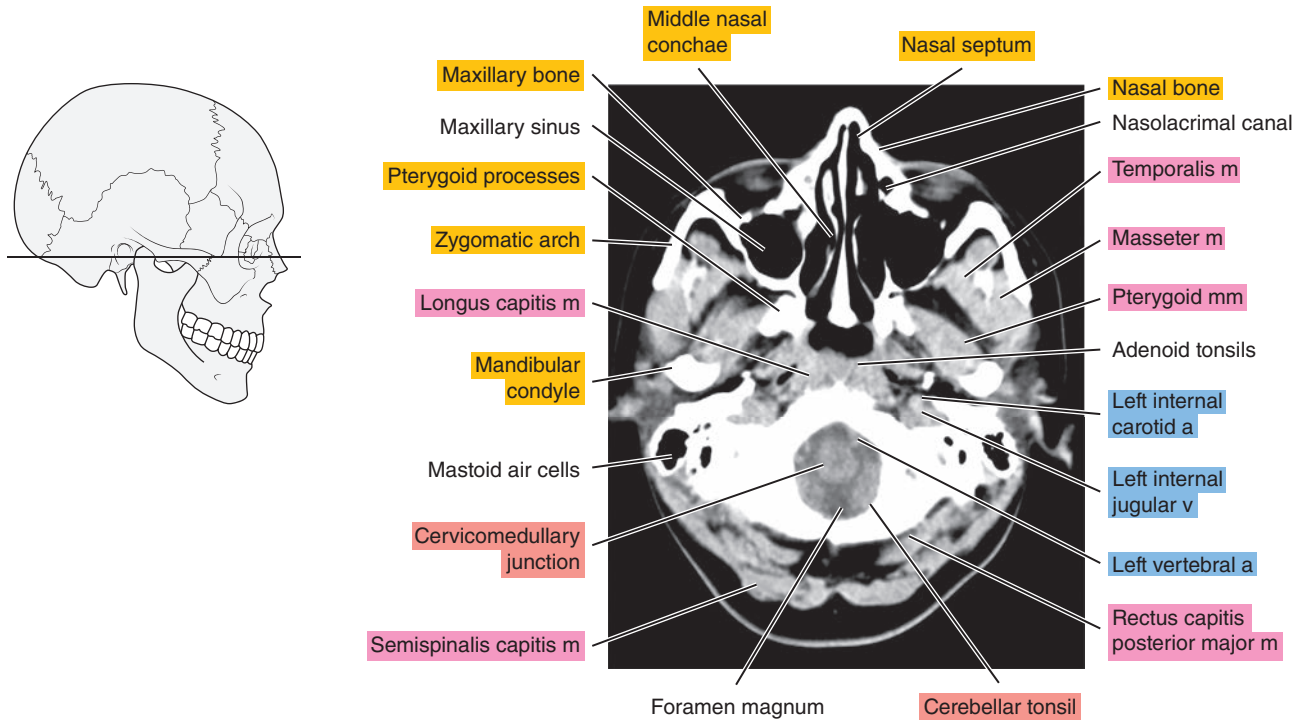
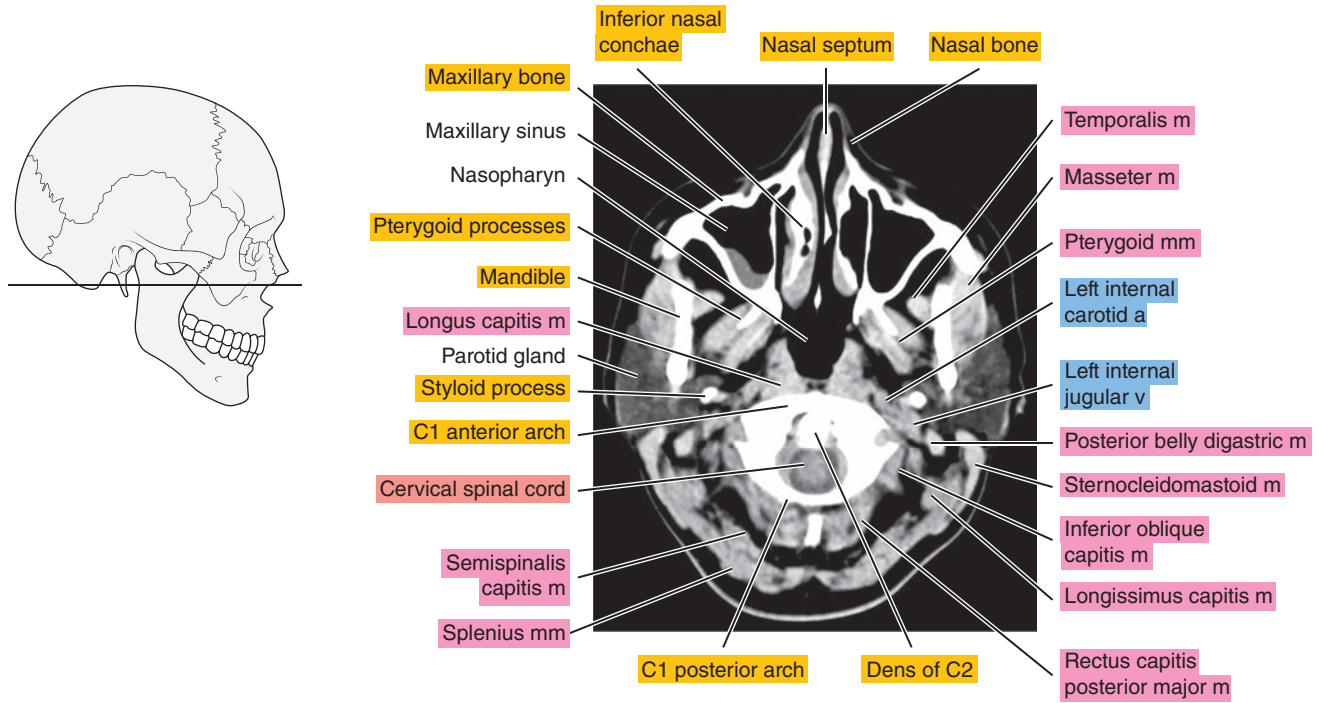




Figure 1.1.11



# SAGITTAL

Figure 1.2.1

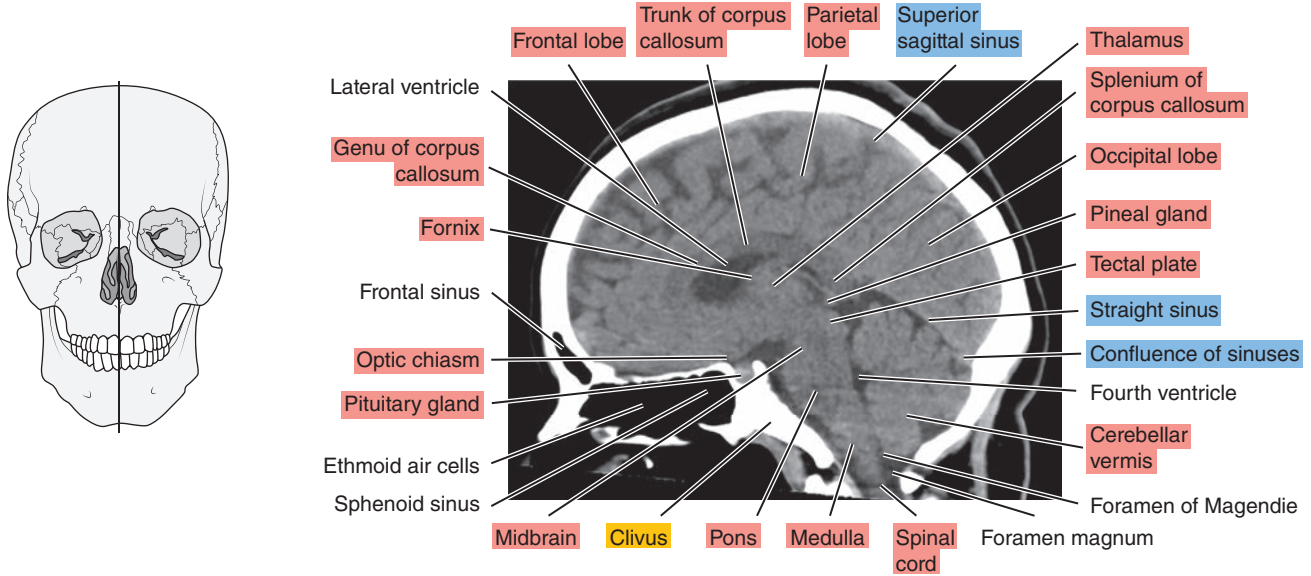


Figure 1.2.2

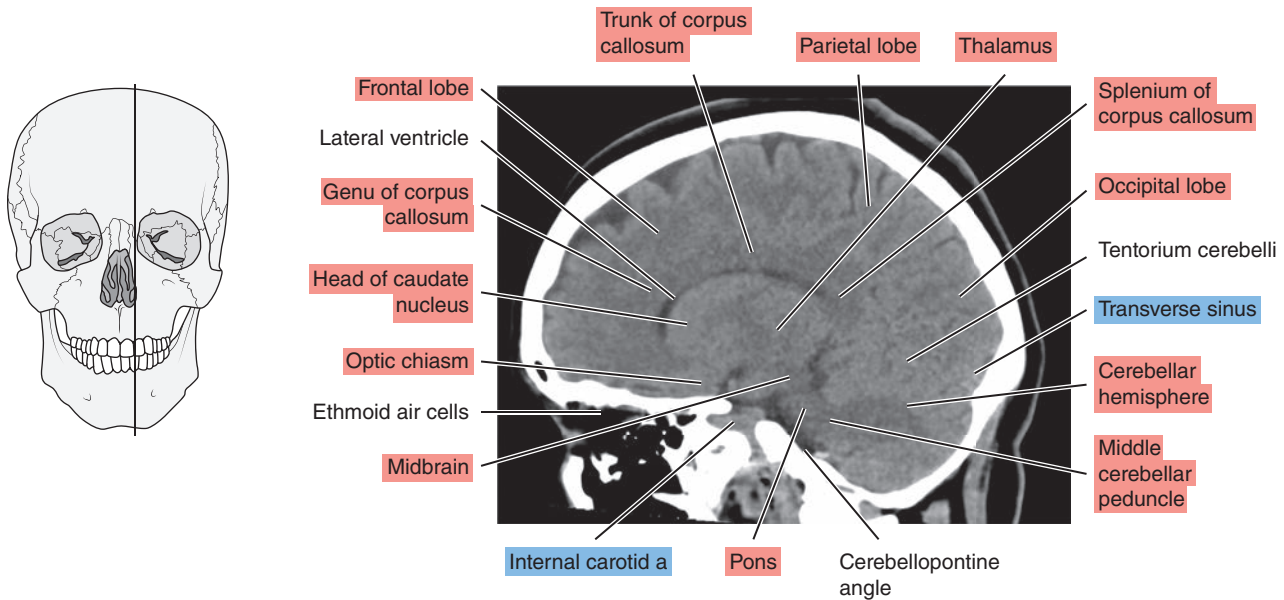


Figure 1.2.3

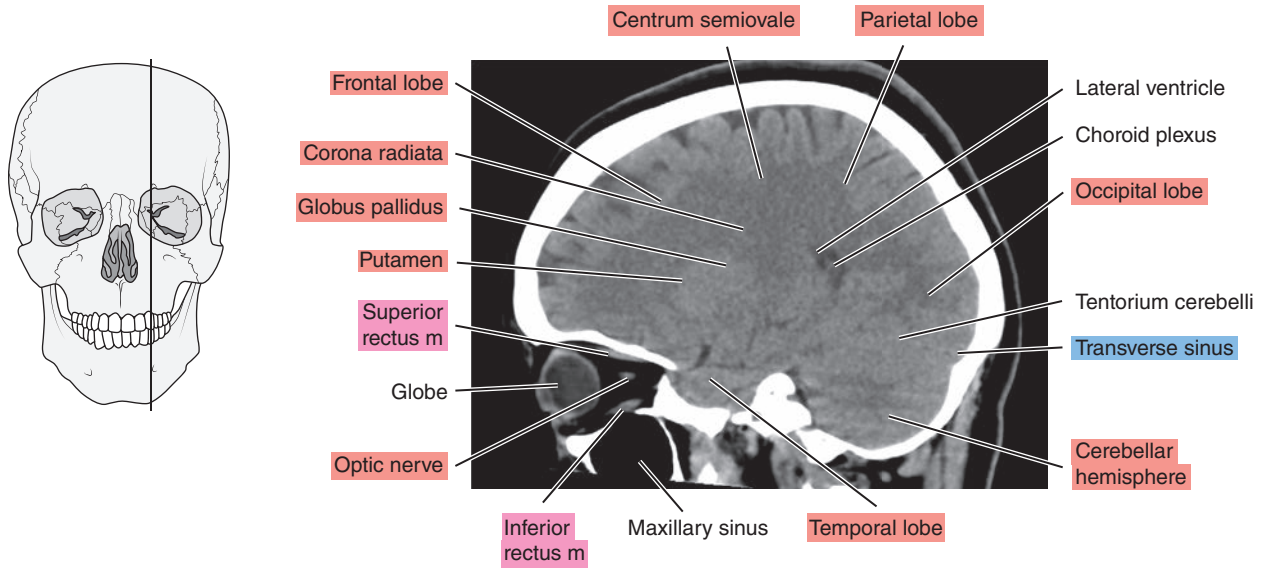


Figure 1.2.4

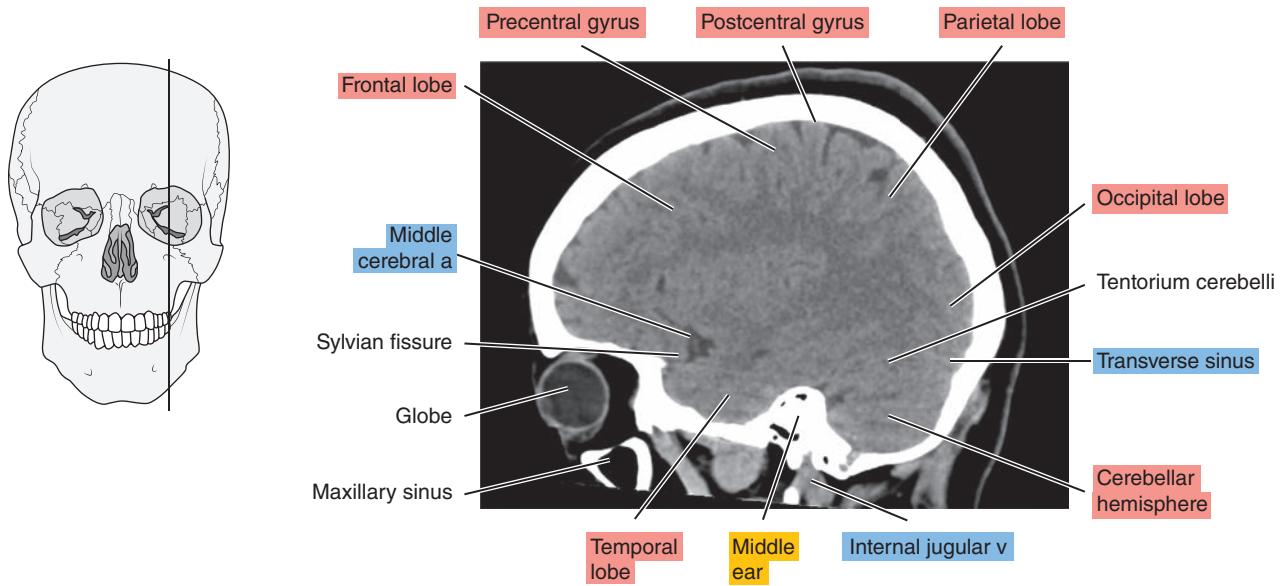


Figure 1.2.5

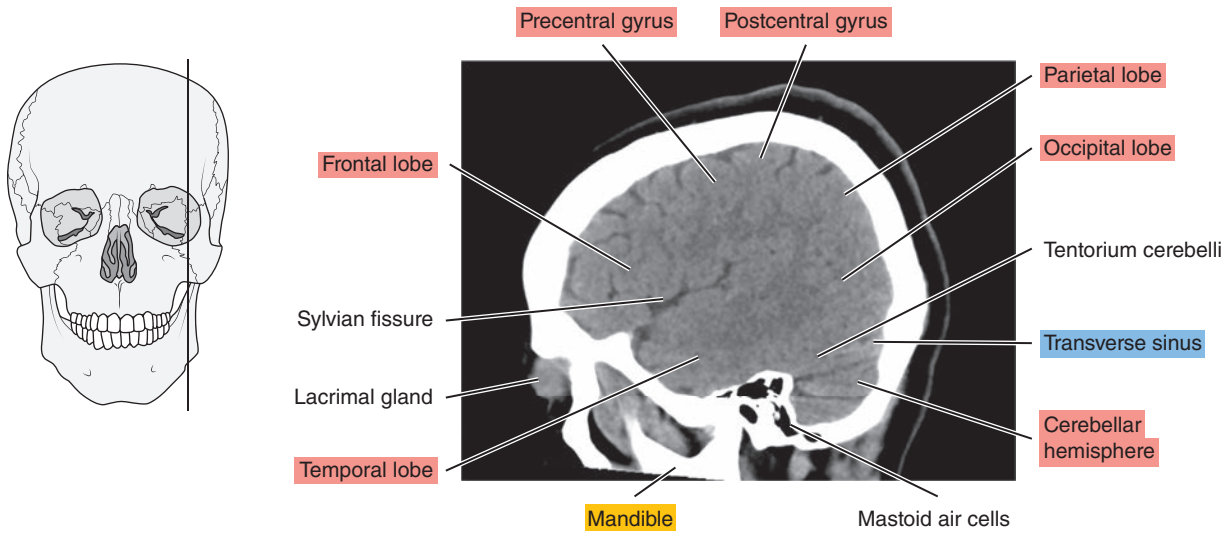
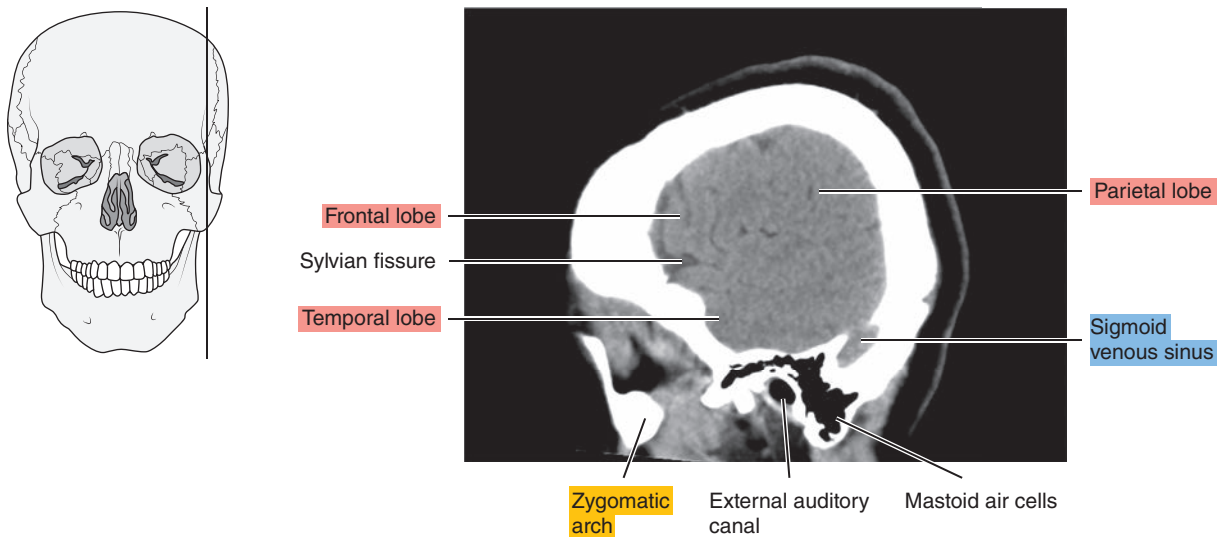


Figure 1.2.6



# CORONAL

Figure 1.3.1

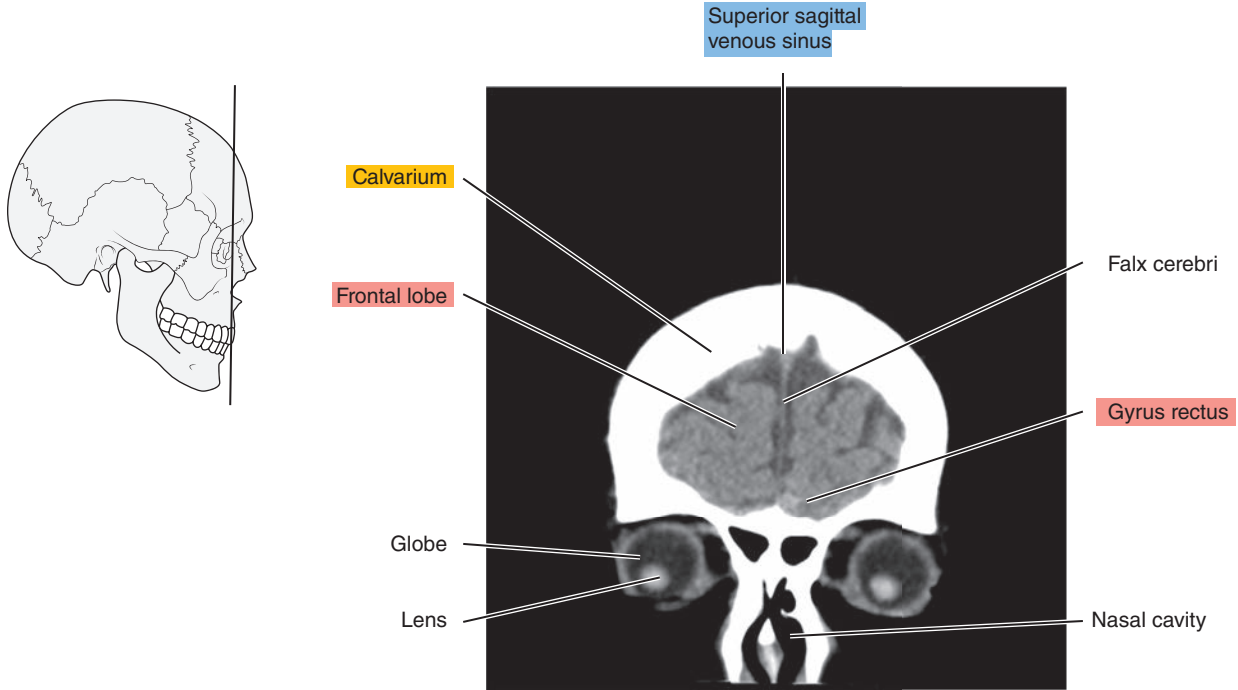


Figure 1.3.2

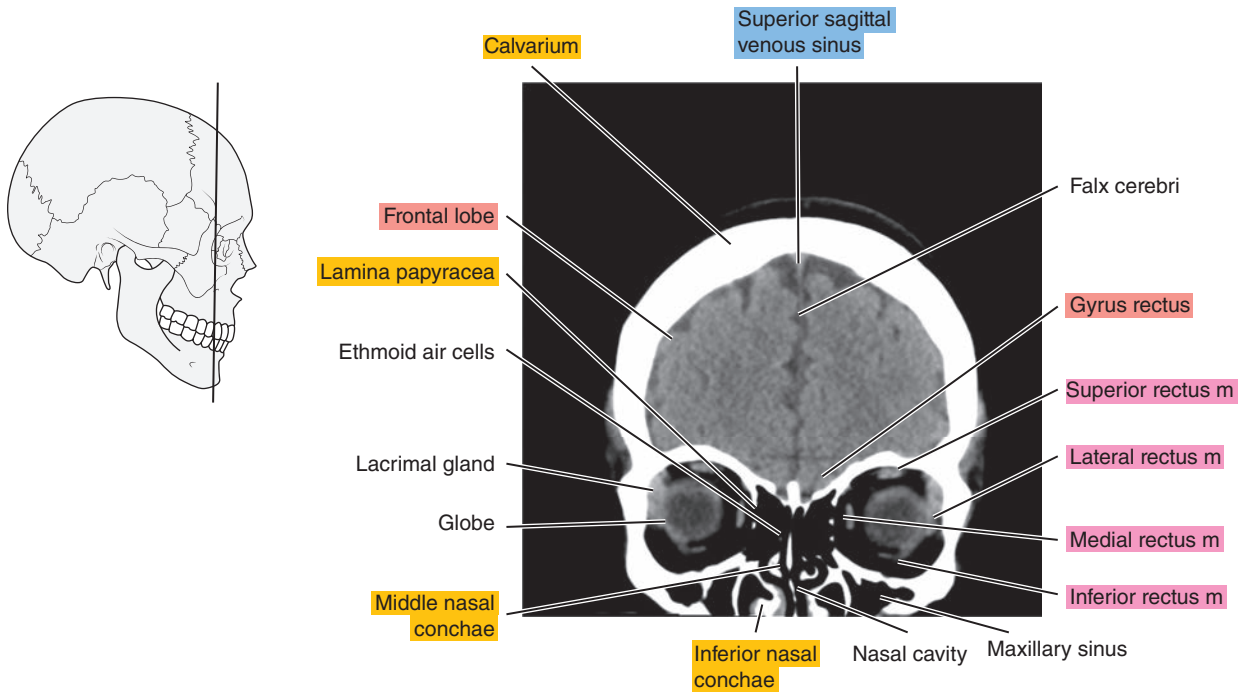


Figure 1.3.3

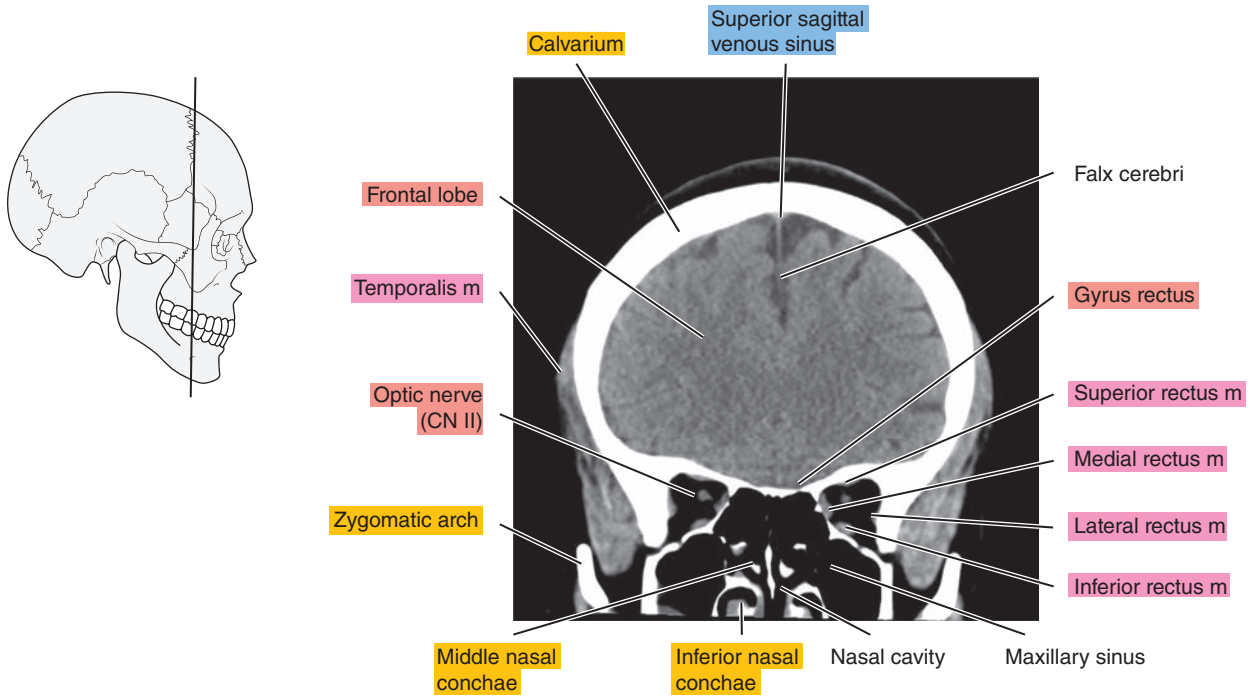


Figure 1.3.4

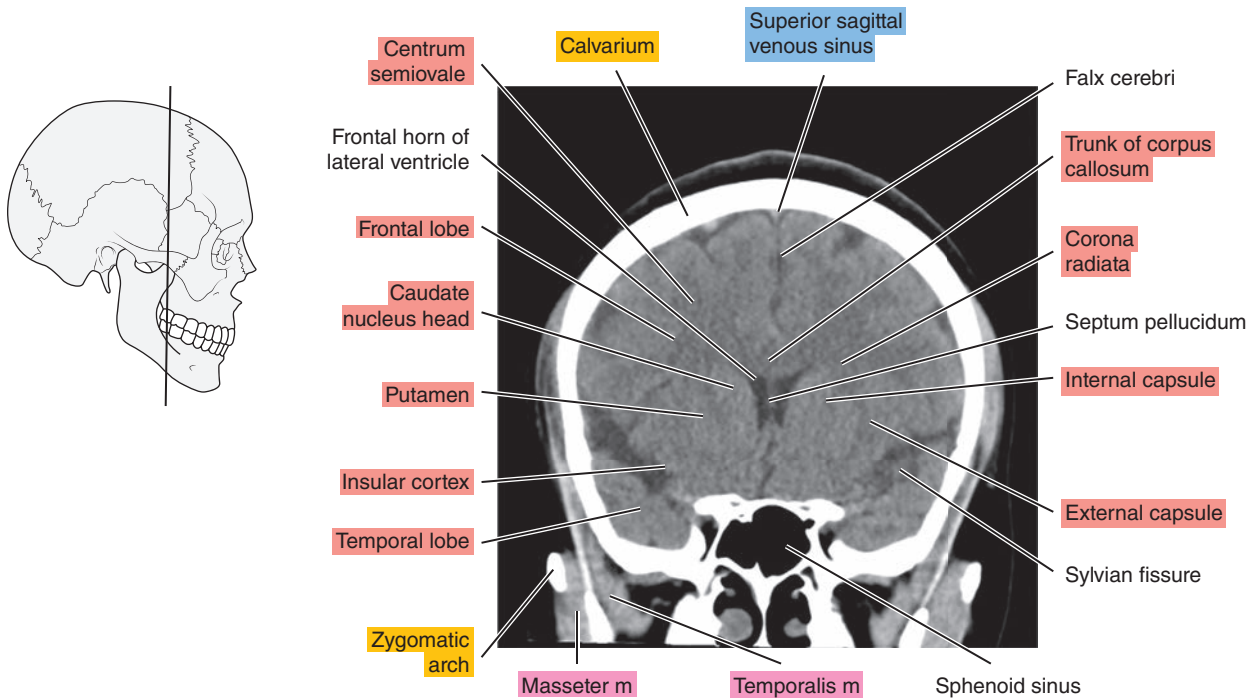




Figure 1.3.5

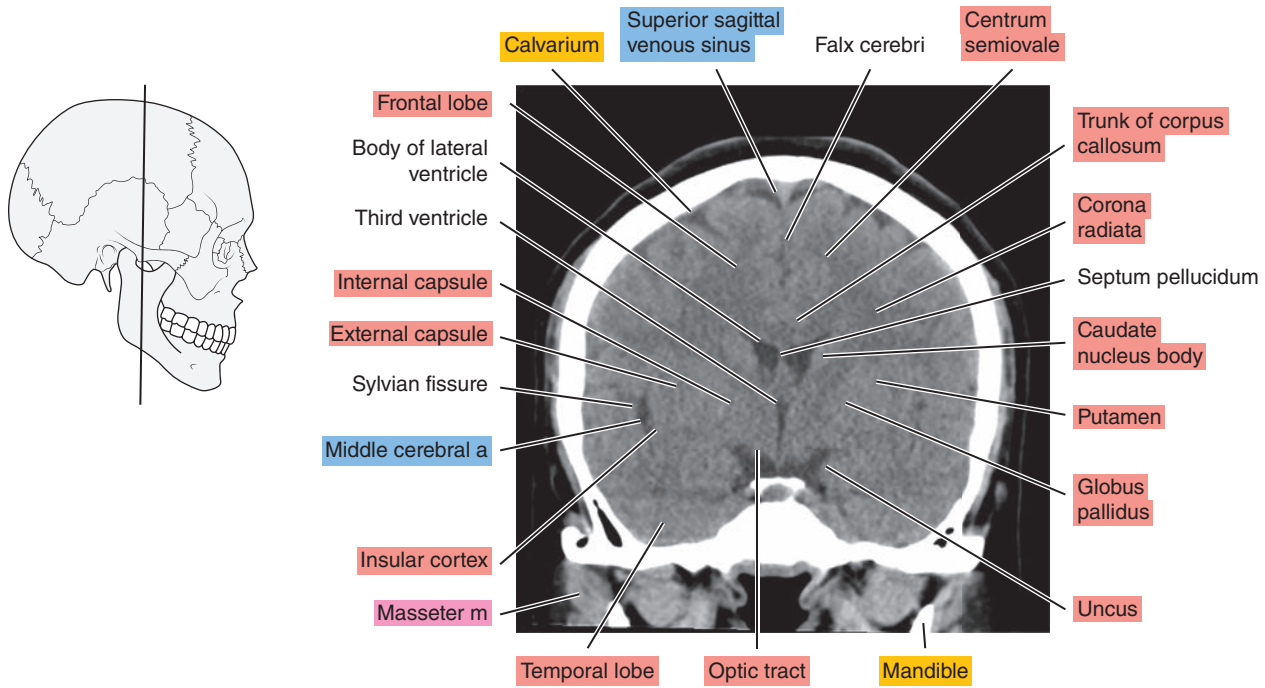


Figure 1.3.6

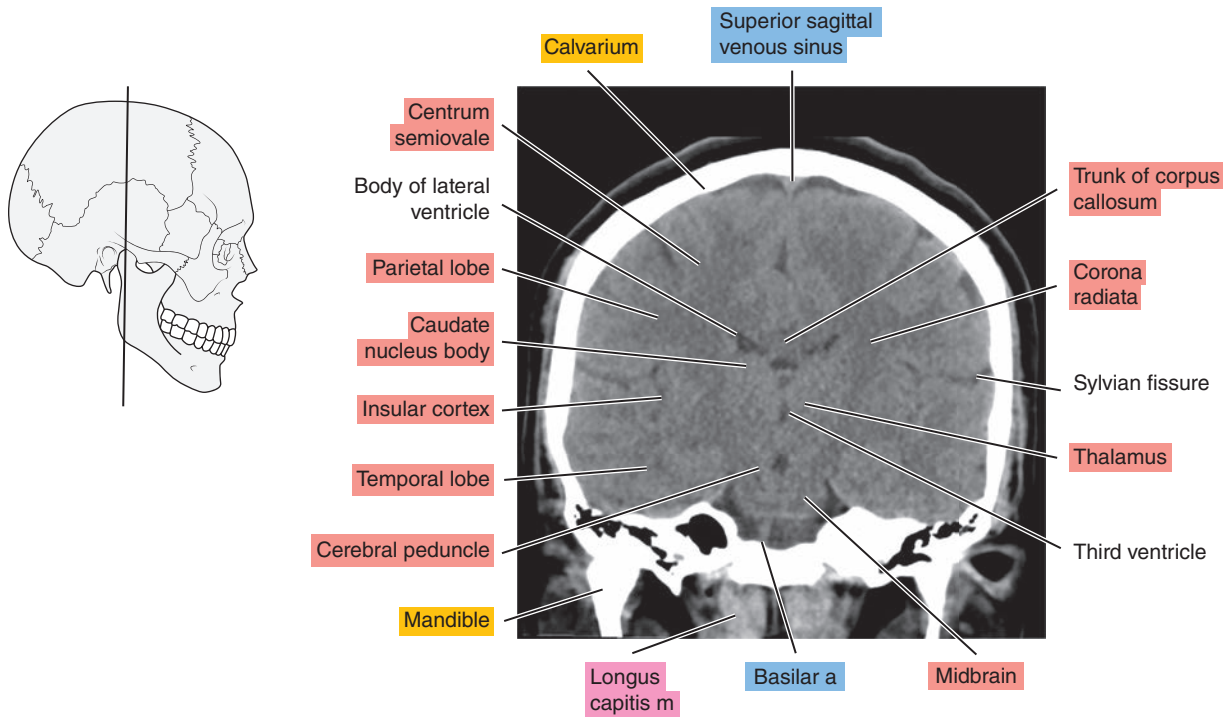


Figure 1.3.7

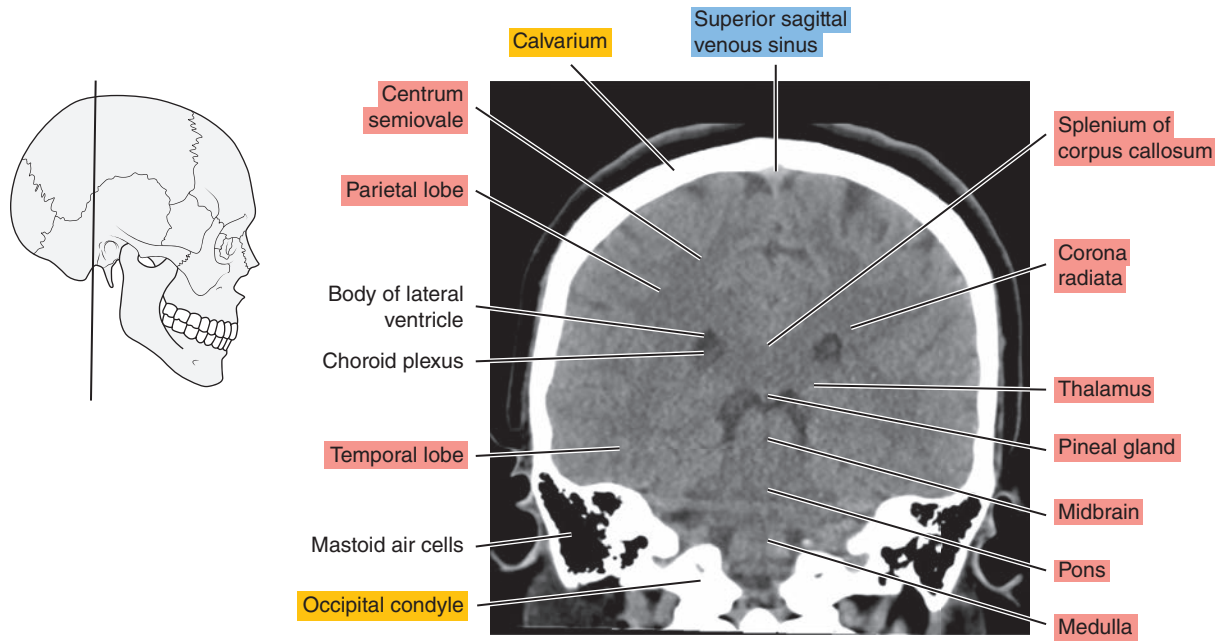


Figure 1.3.8

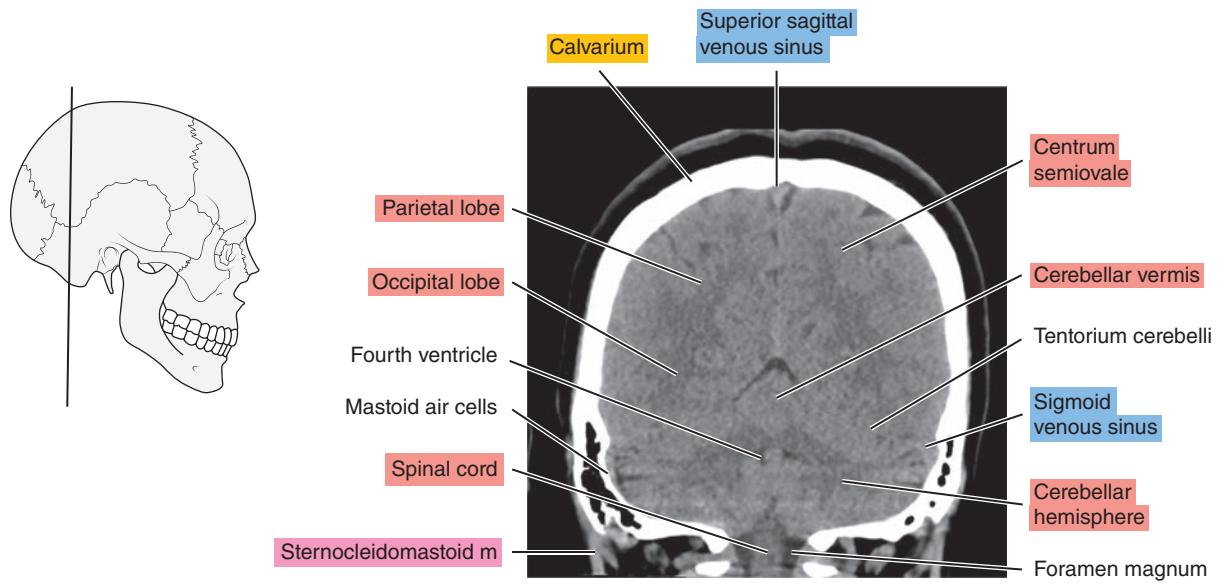


Figure 1.3.9

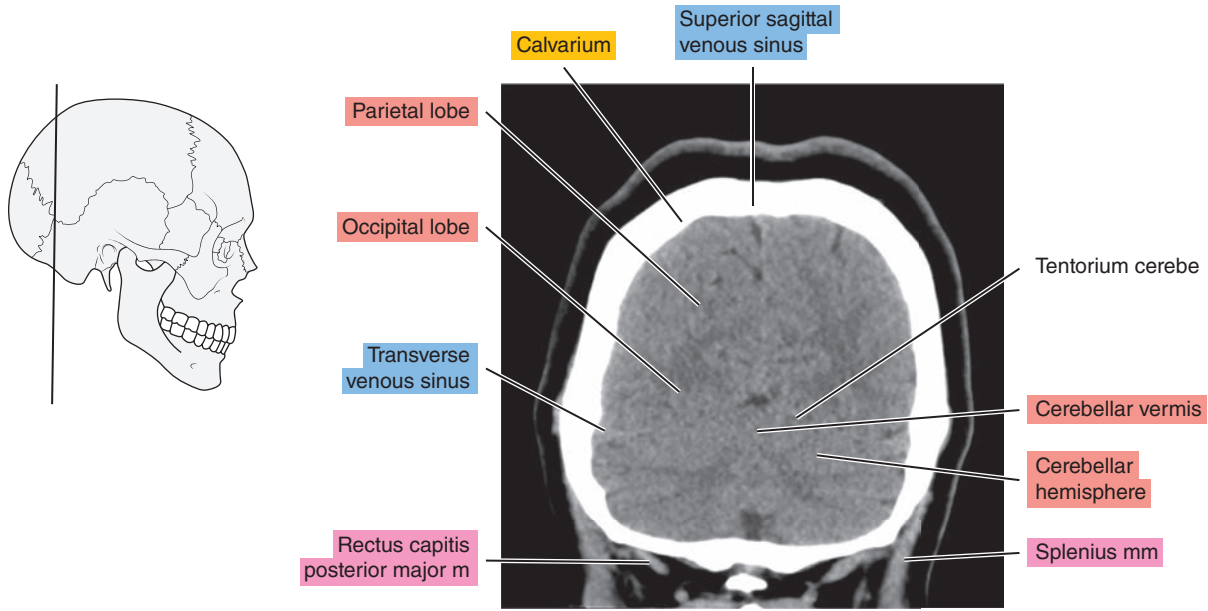
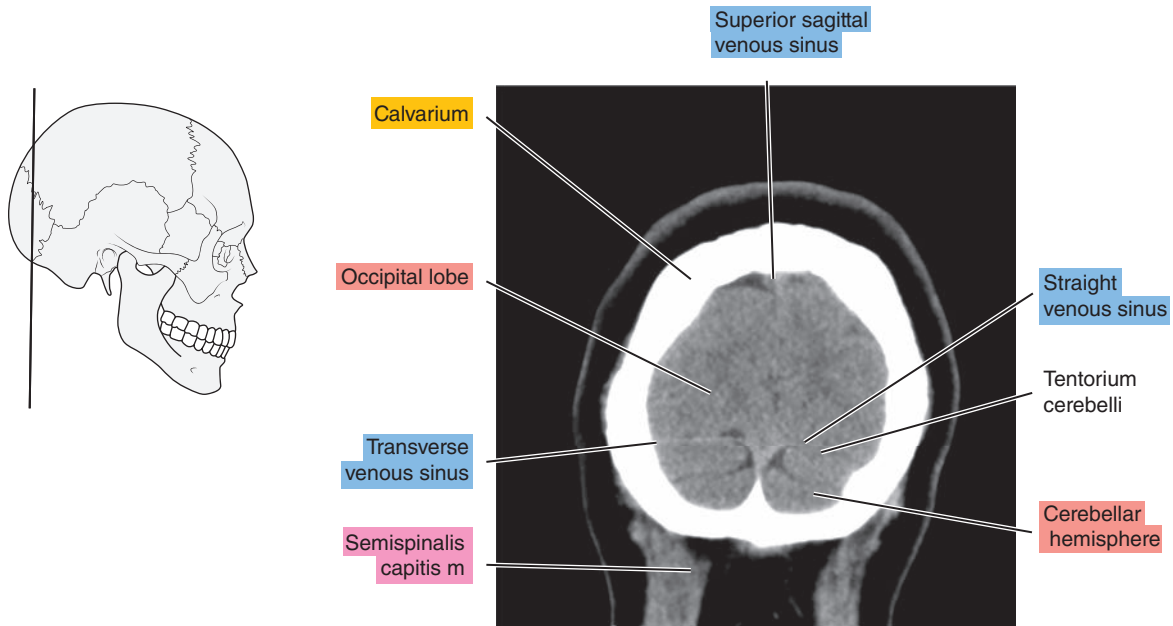


Figure 1.3.10



*Chapter*  
**2**

**MRI of the Brain**

# AXIAL

Figure 2.1.1

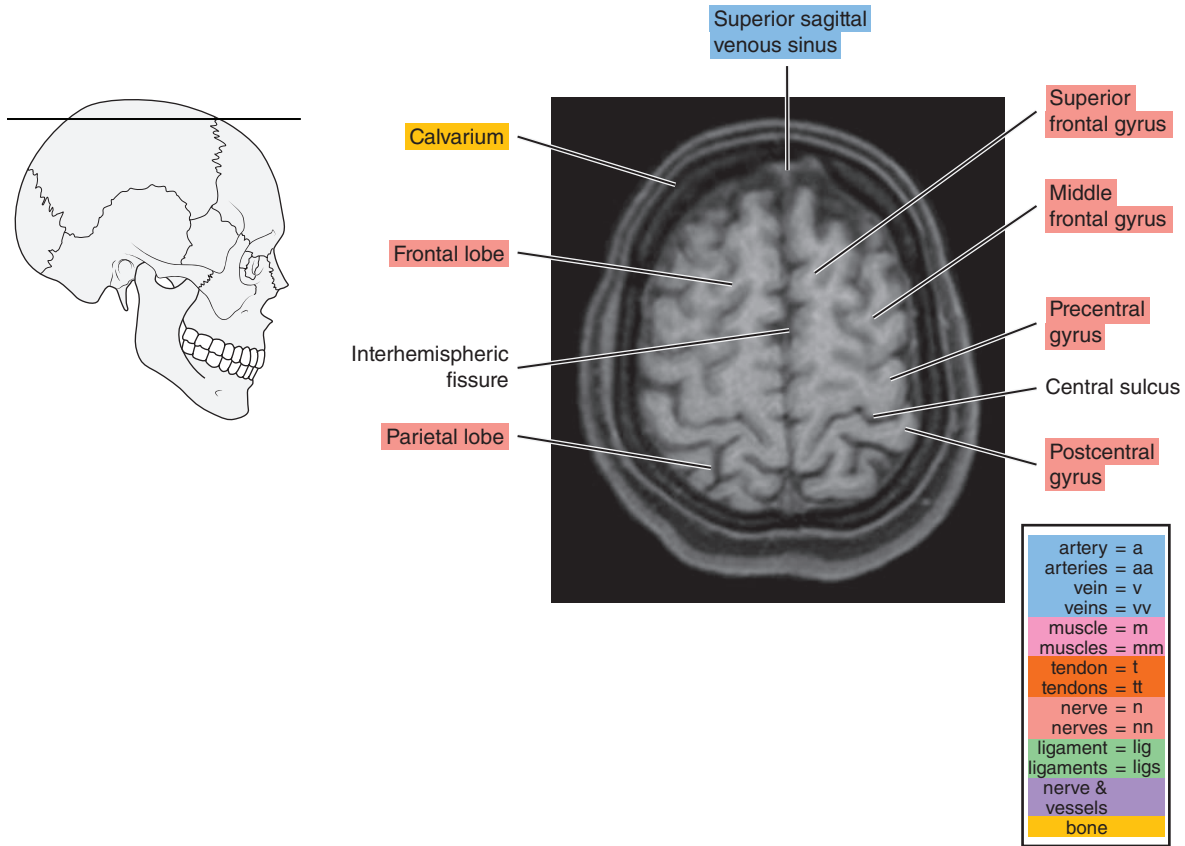


Figure 2.1.2

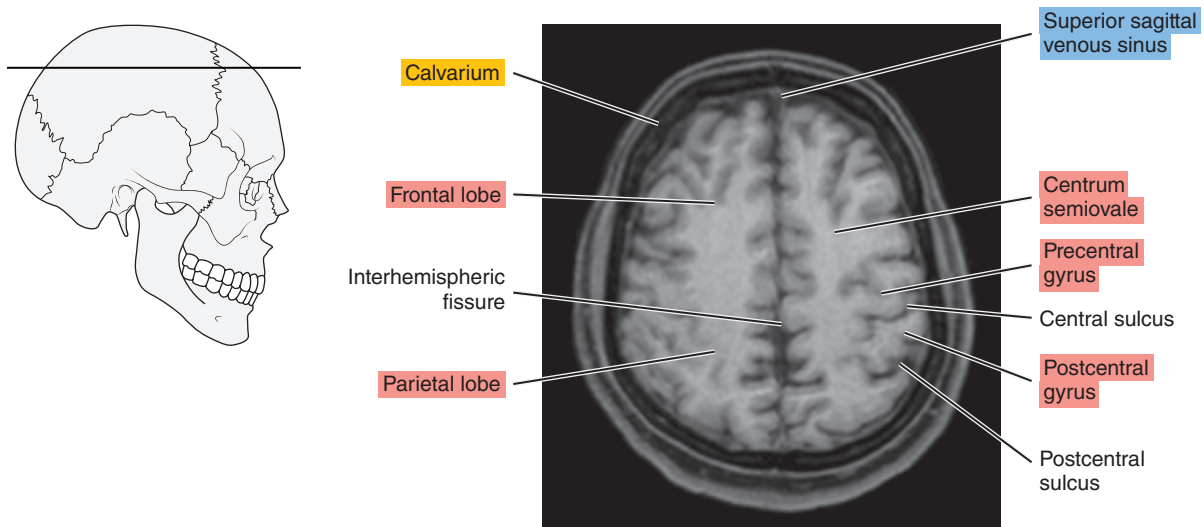


Figure 2.1.3

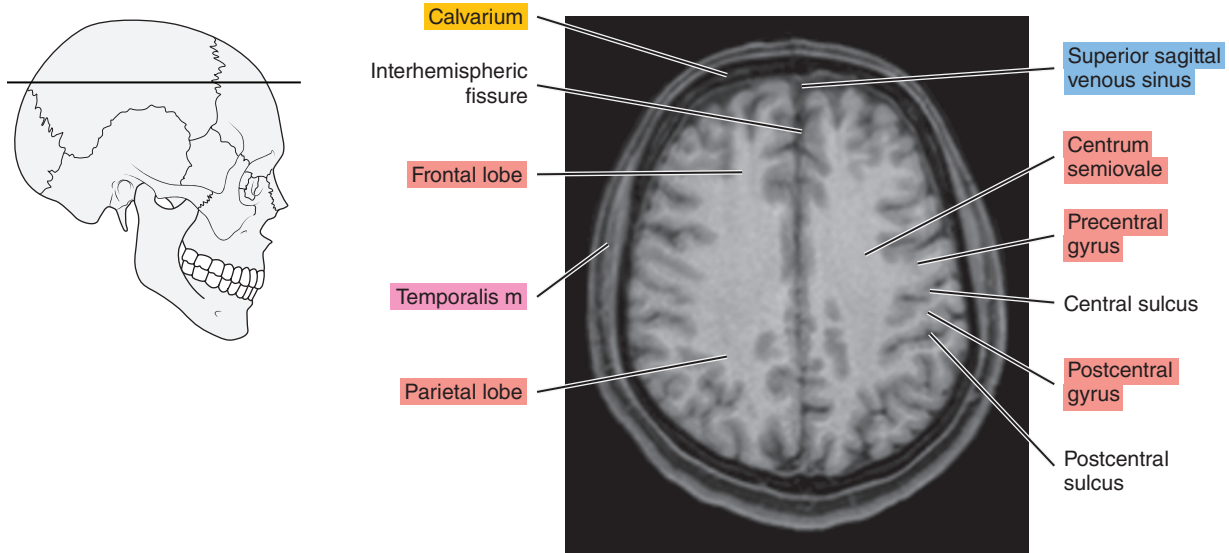


Figure 2.1.4

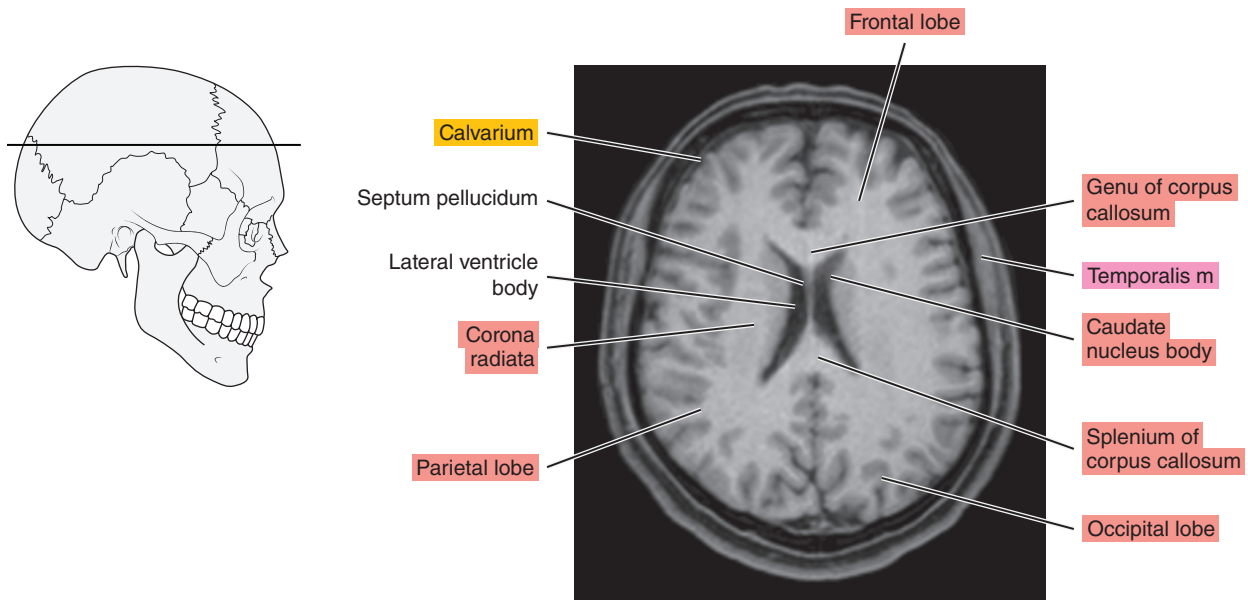




Figure 2.1.5

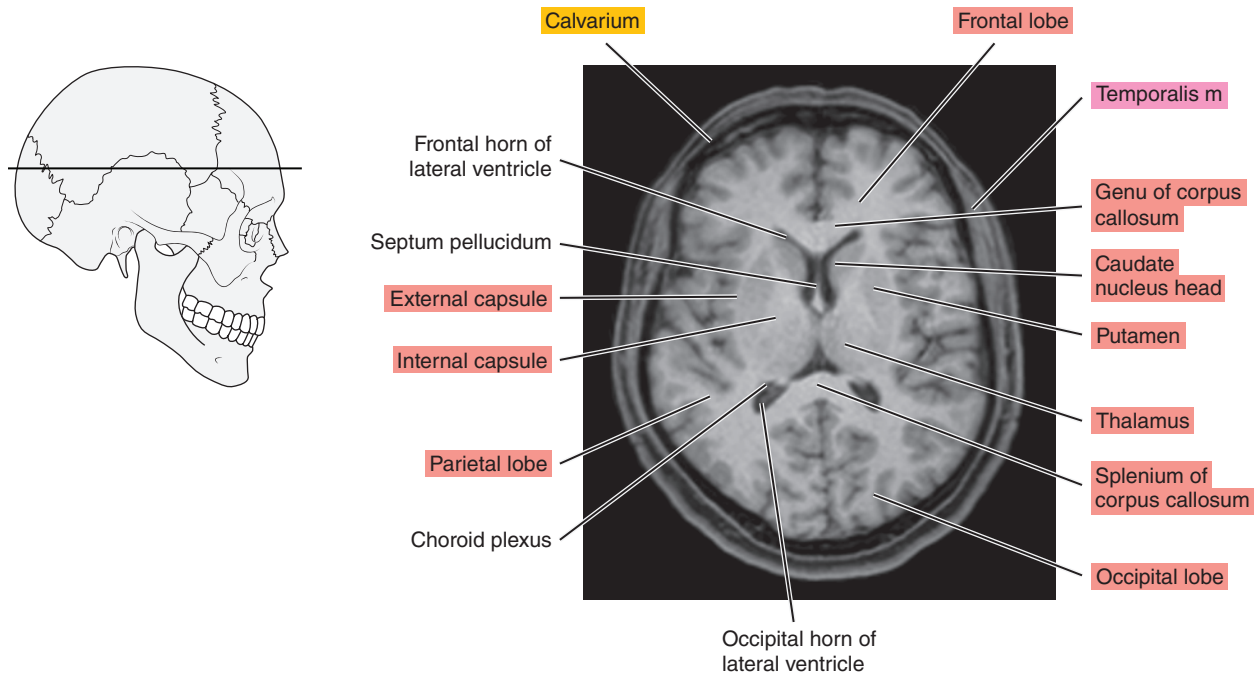


Figure 2.1.6

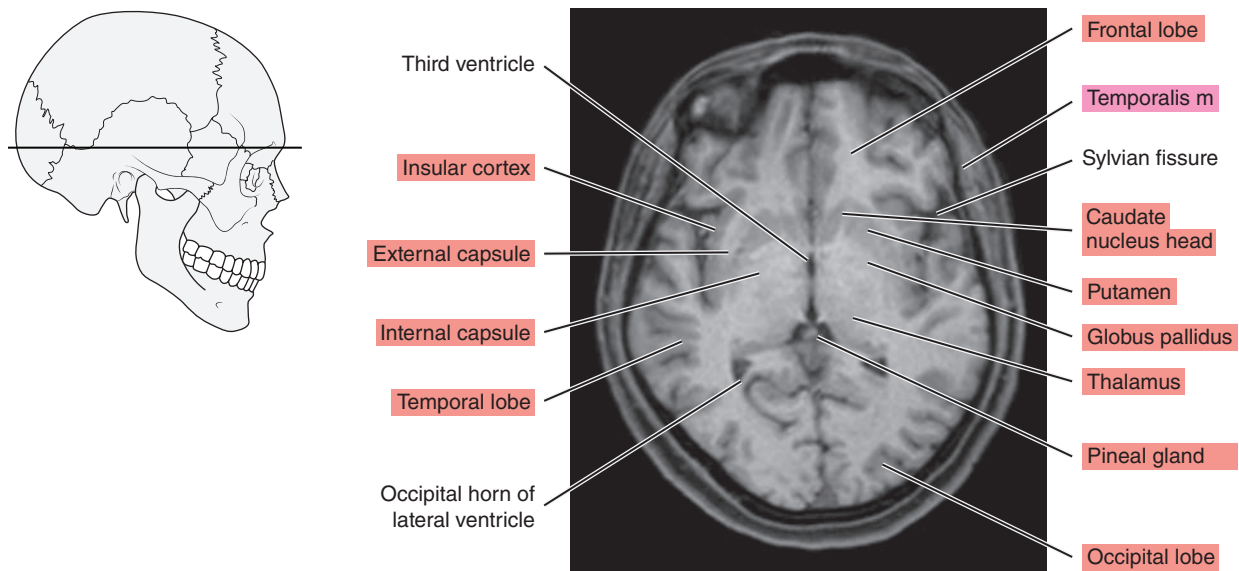


Figure 2.1.7

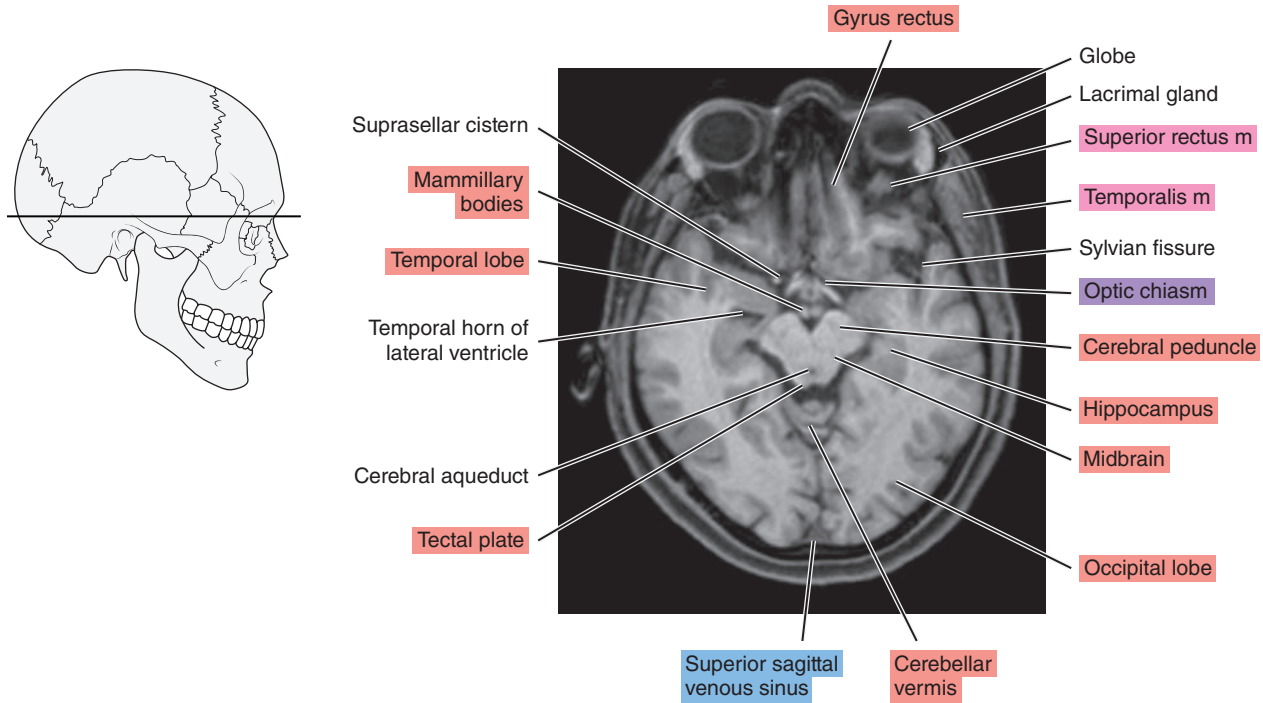


Figure 2.1.8

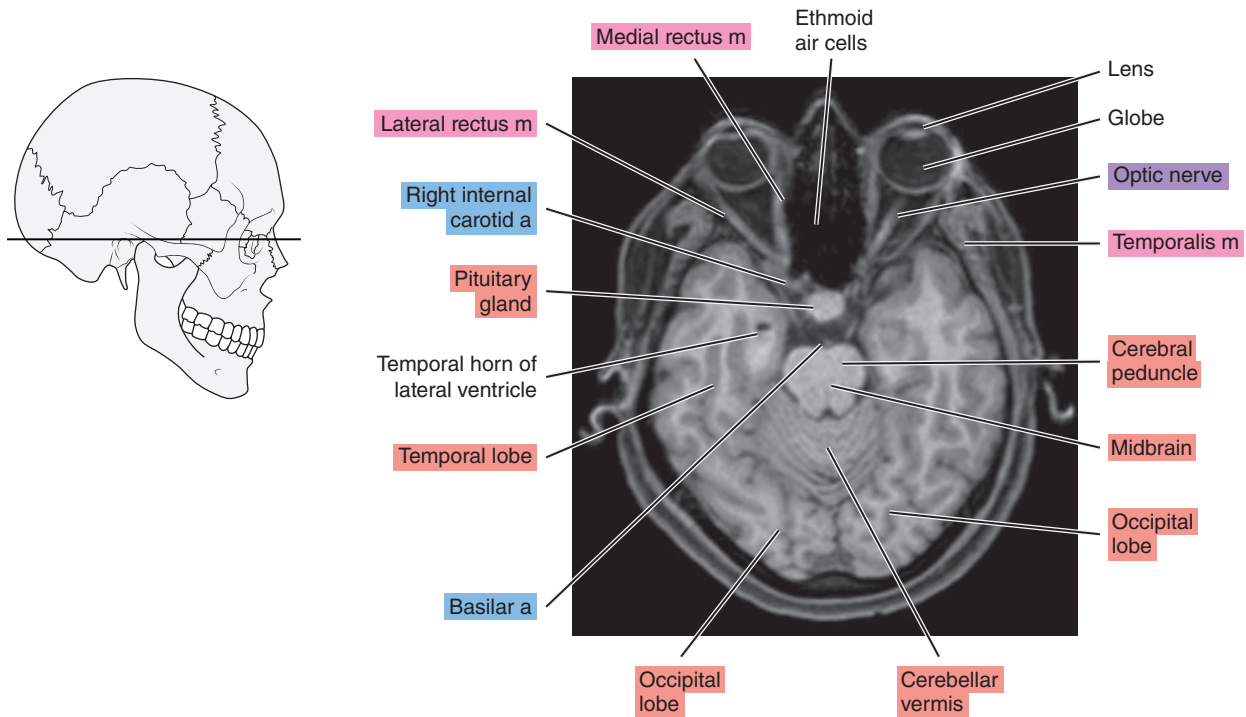


Figure 2.1.9

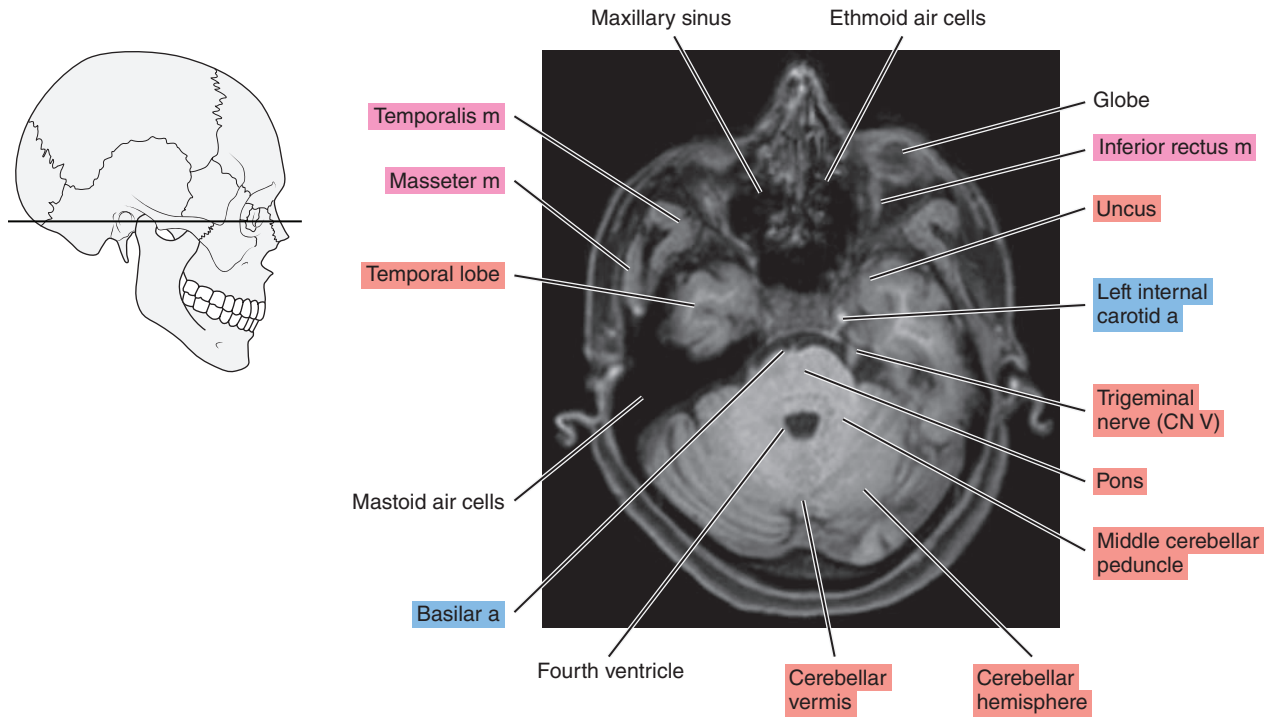


Figure 2.1.10

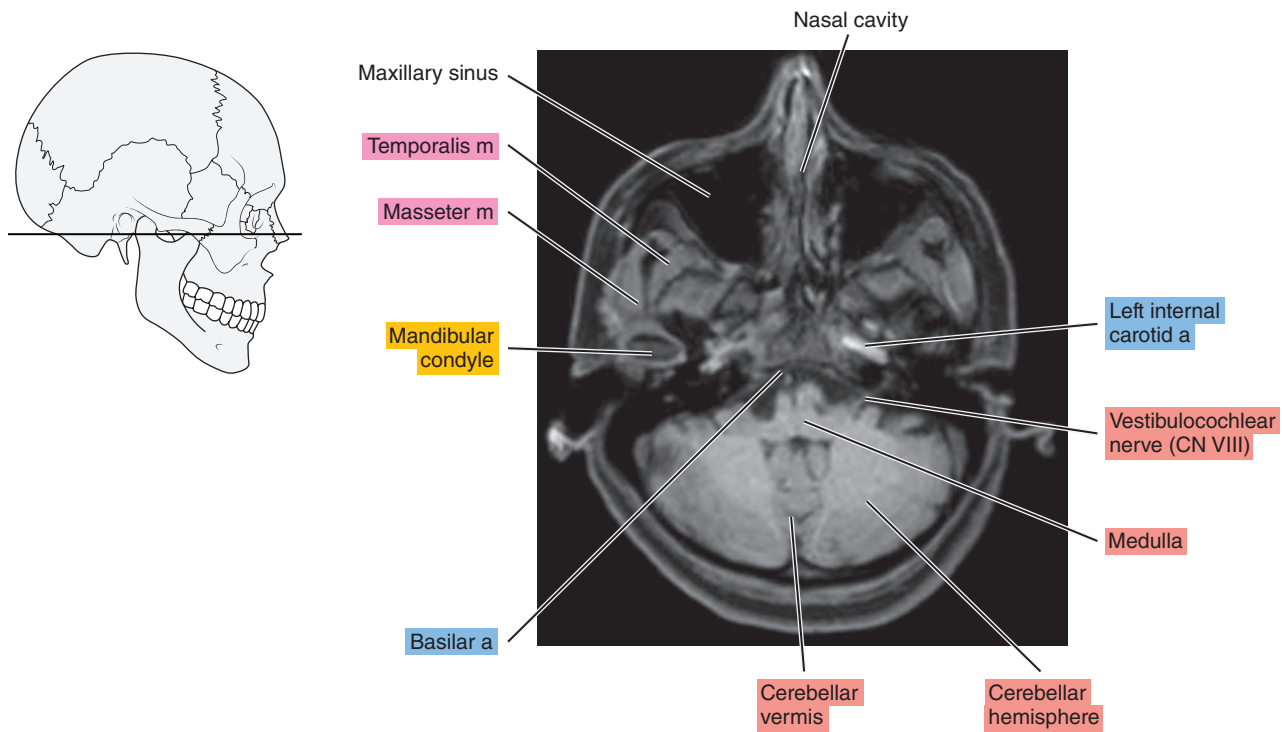


Figure 2.1.11

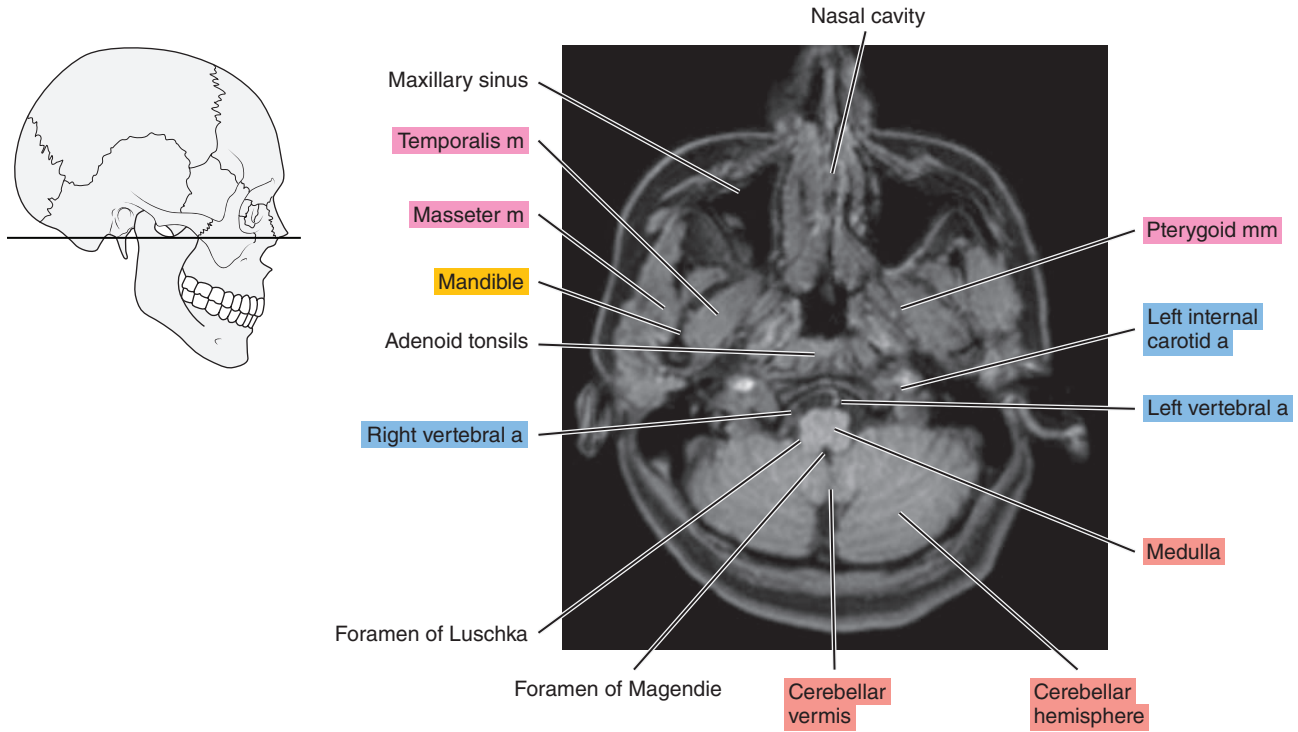
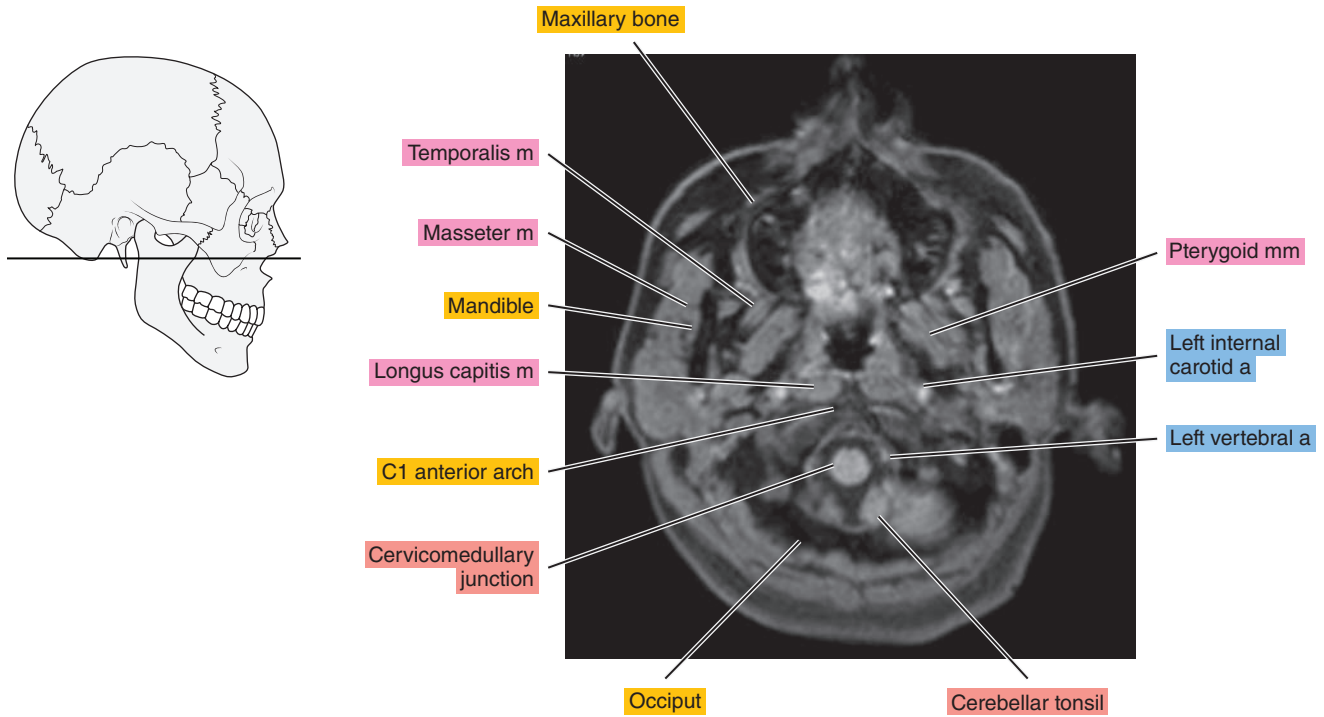


Figure 2.1.12



# SAGITTAL

Figure 2.2.1

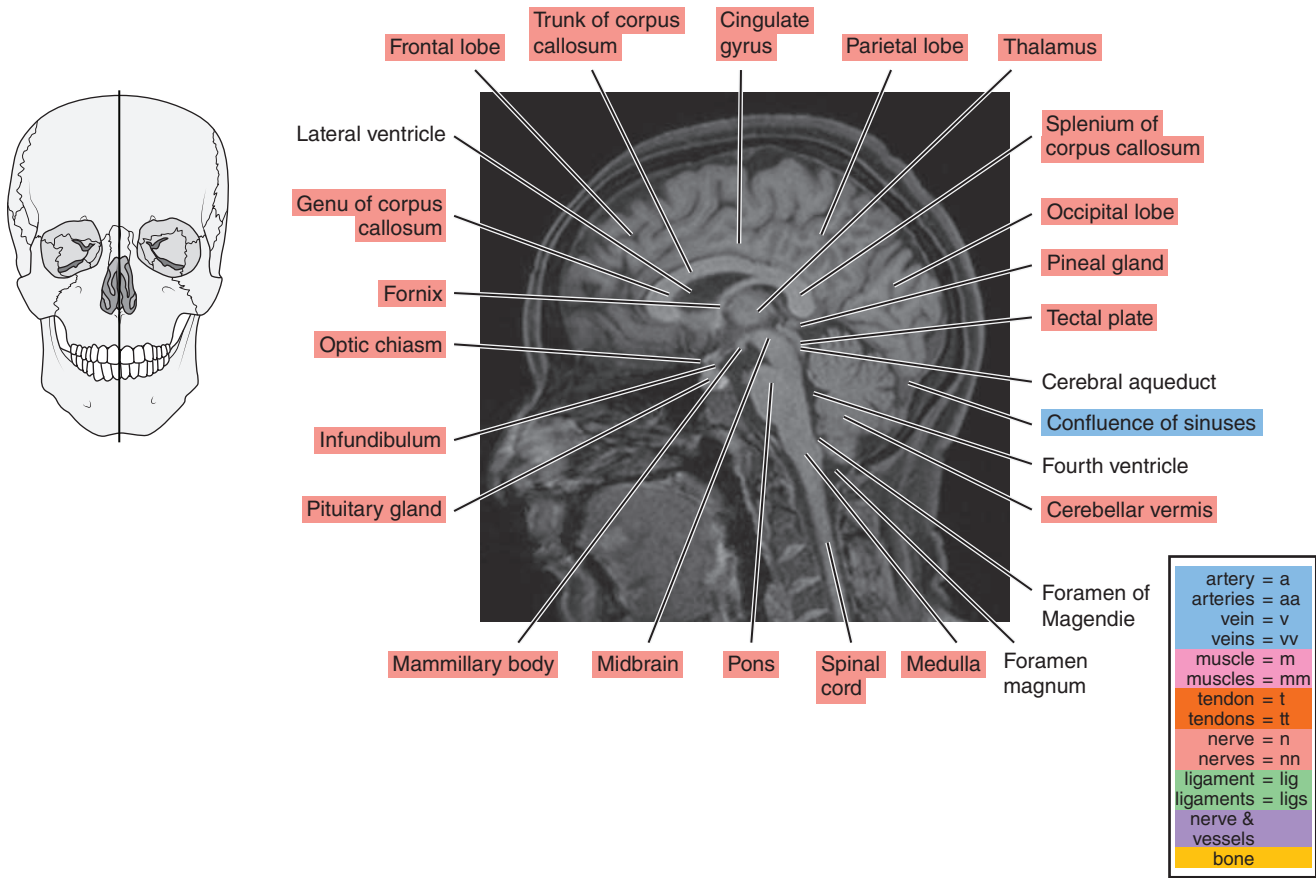


Figure 2.2.2

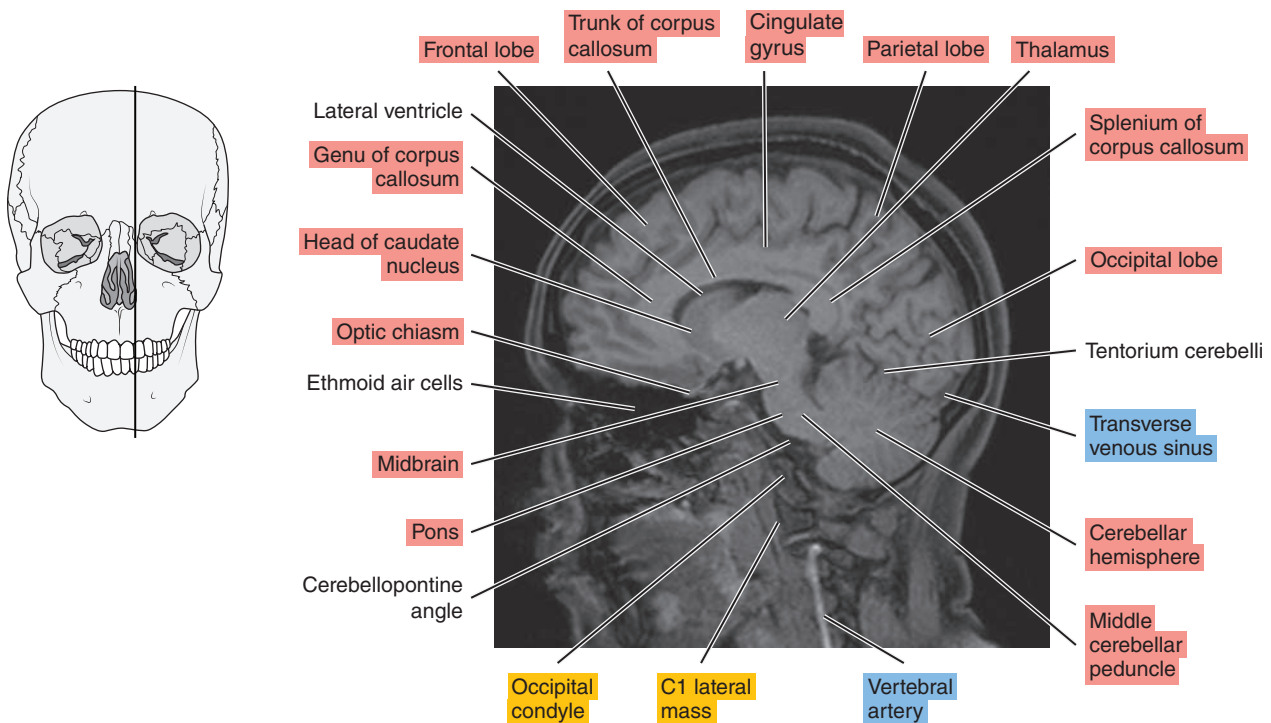




Figure 2.2.3

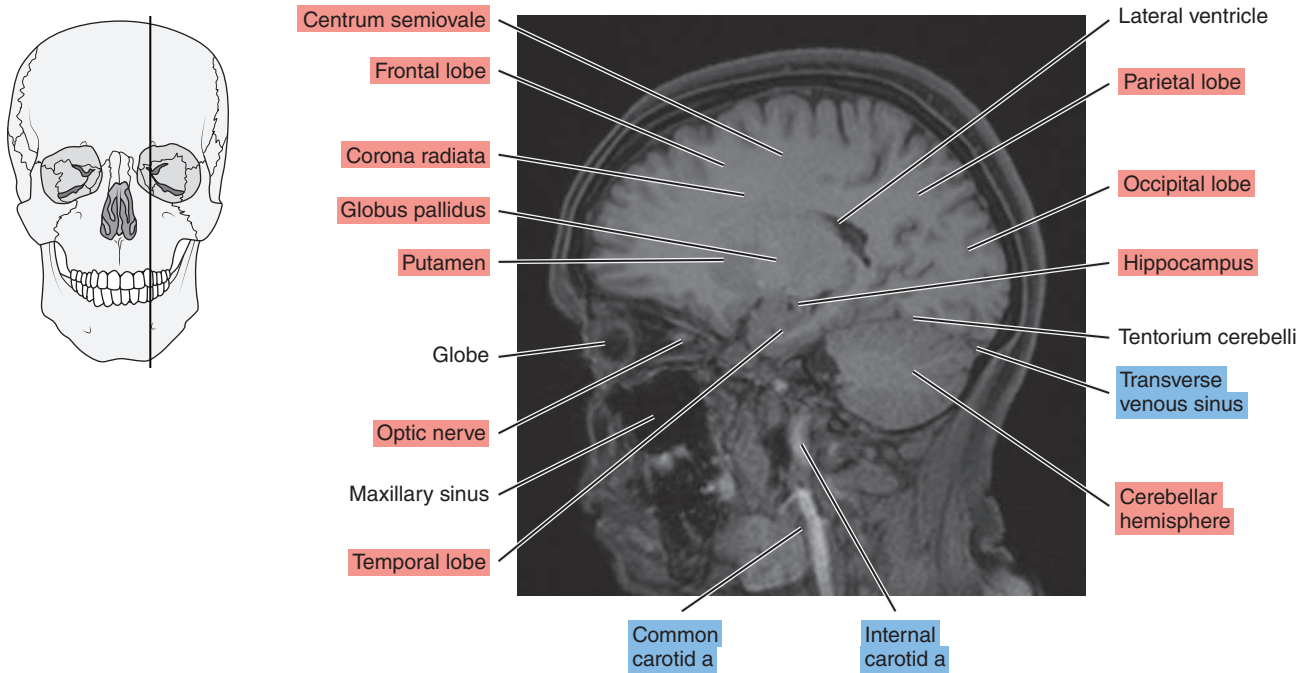


Figure 2.2.4

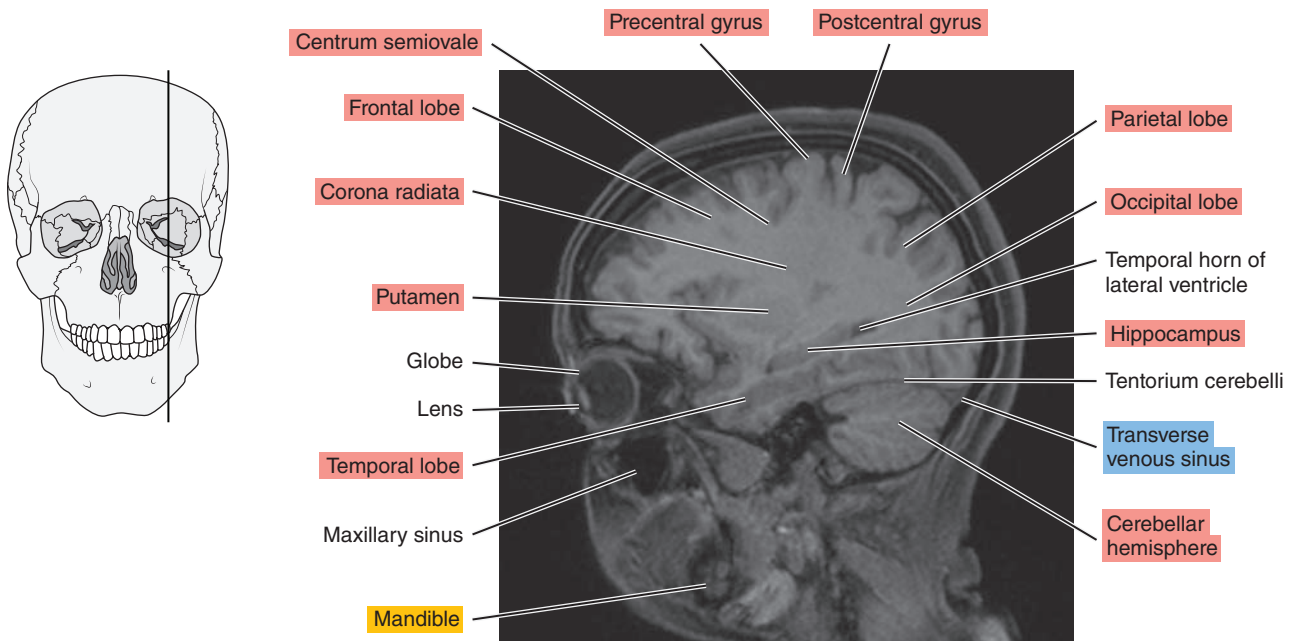




Figure 2.2.5

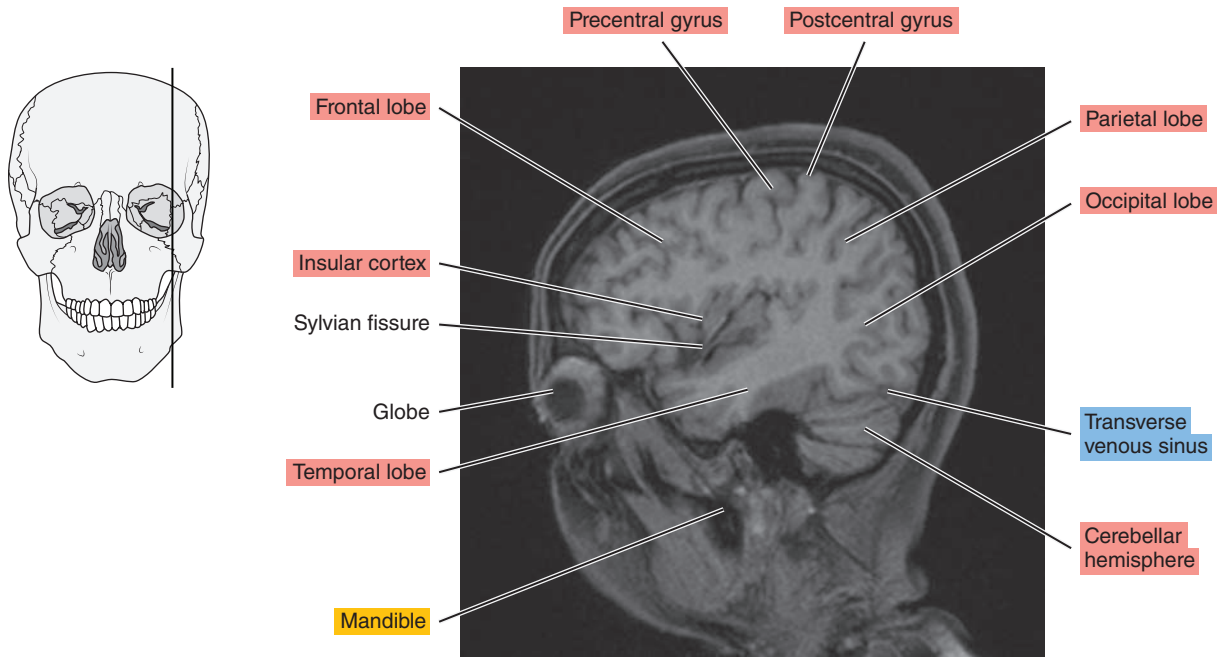
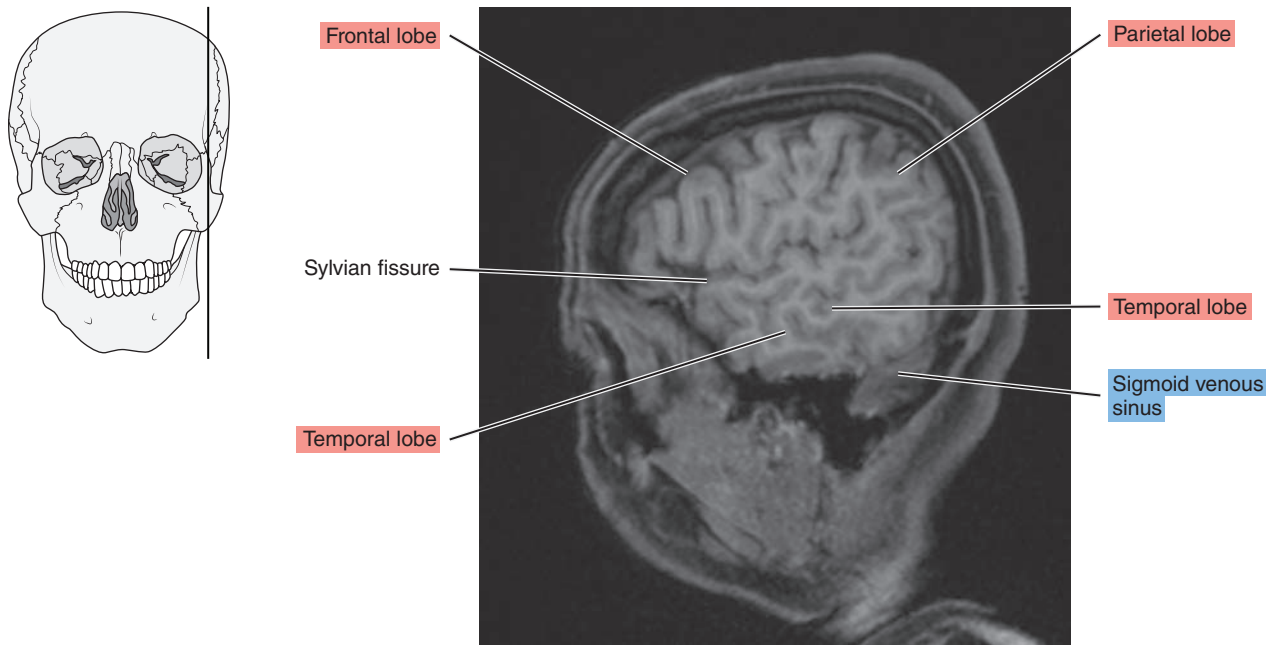


Figure 2.2.6



# SAGITTAL

Figure 2.3.1

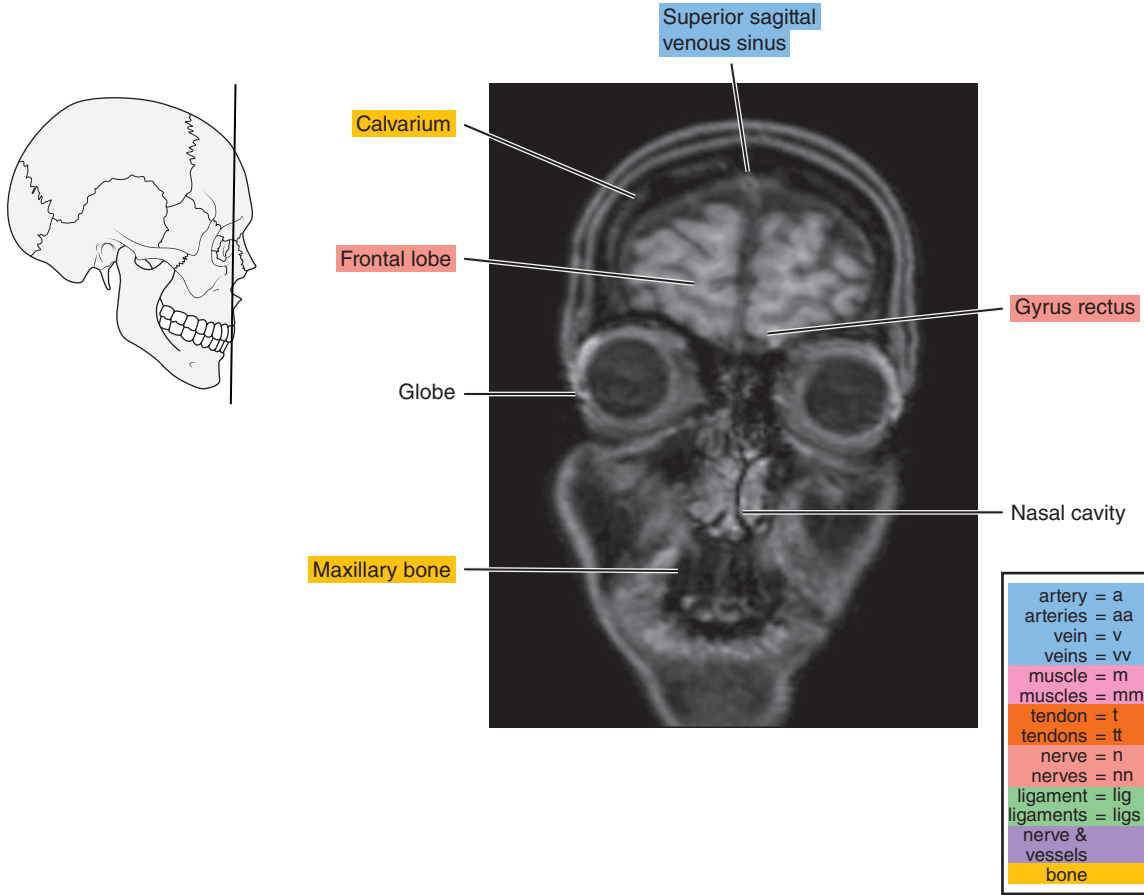


Figure 2.3.2

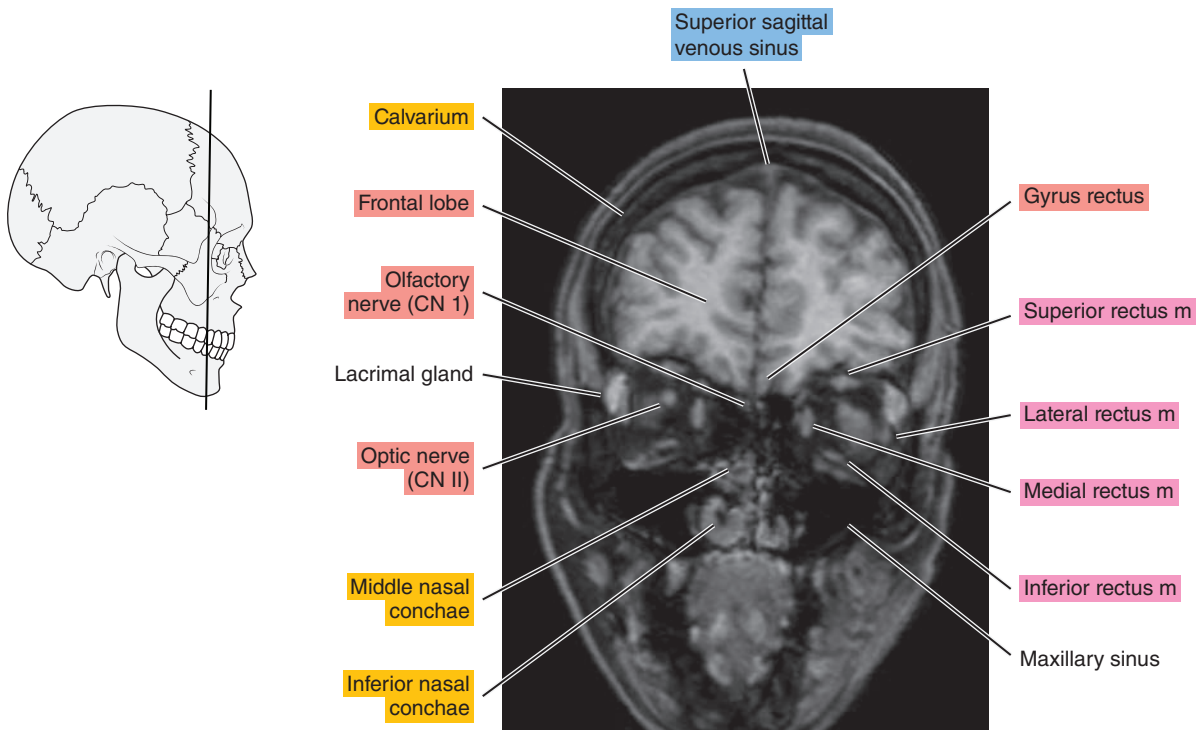


Figure 2.3.3

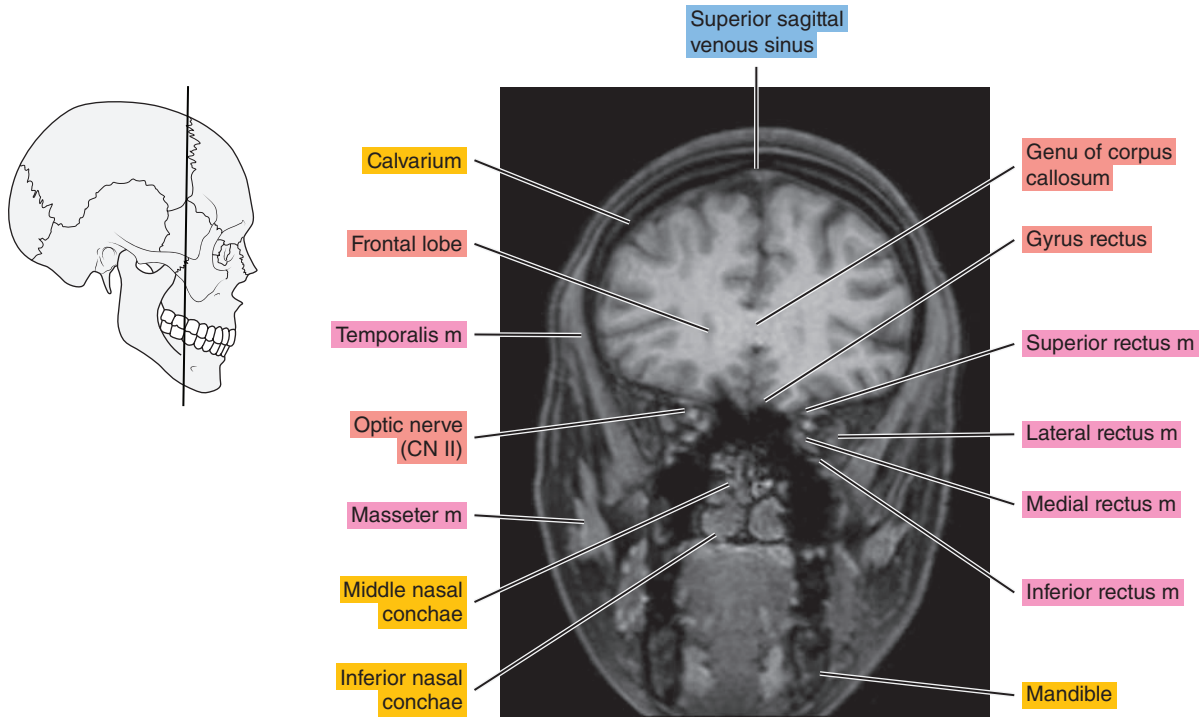


Figure 2.3.4

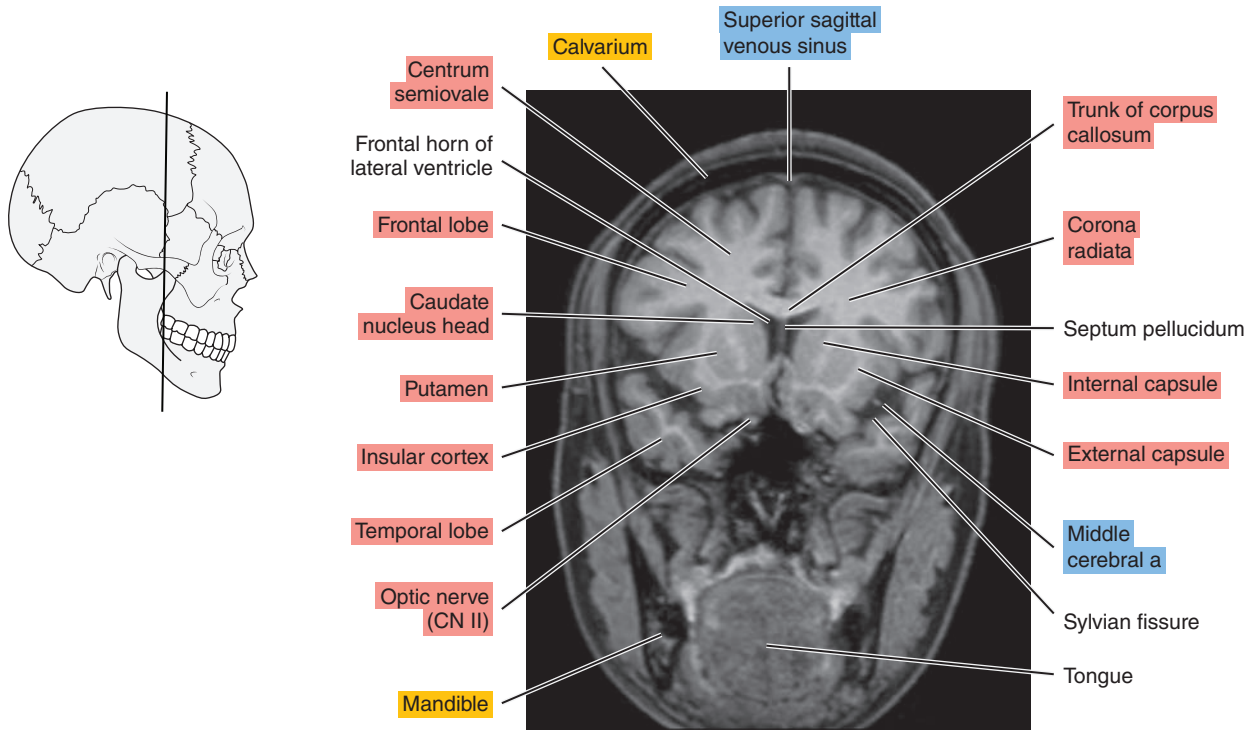


Figure 2.3.5

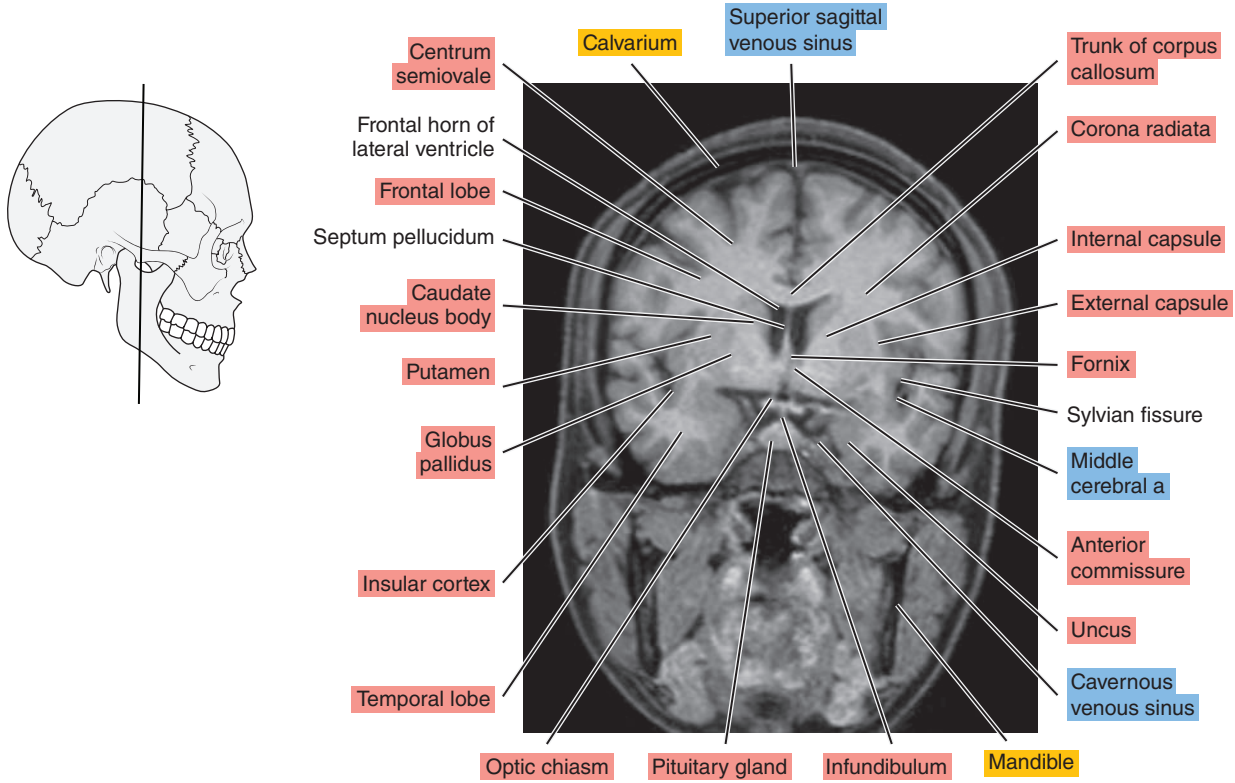


Figure 2.3.6

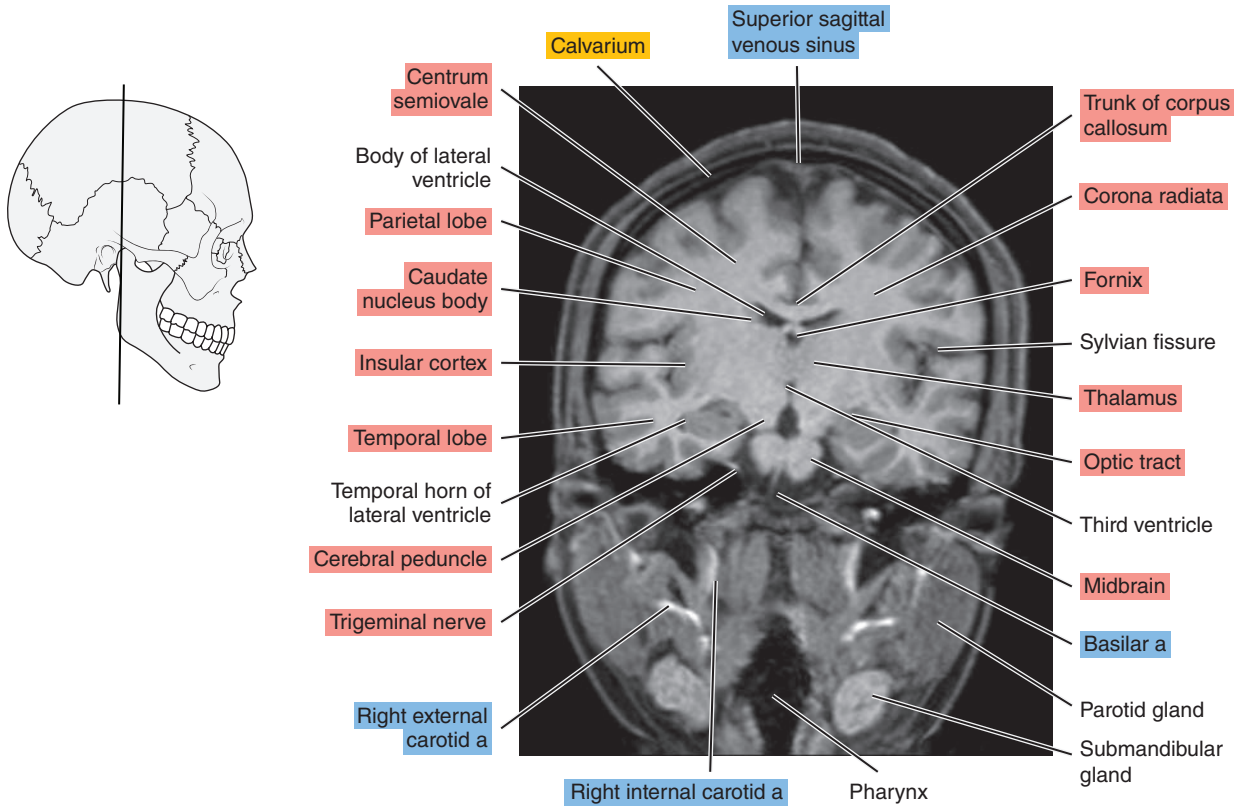


Figure 2.3.7

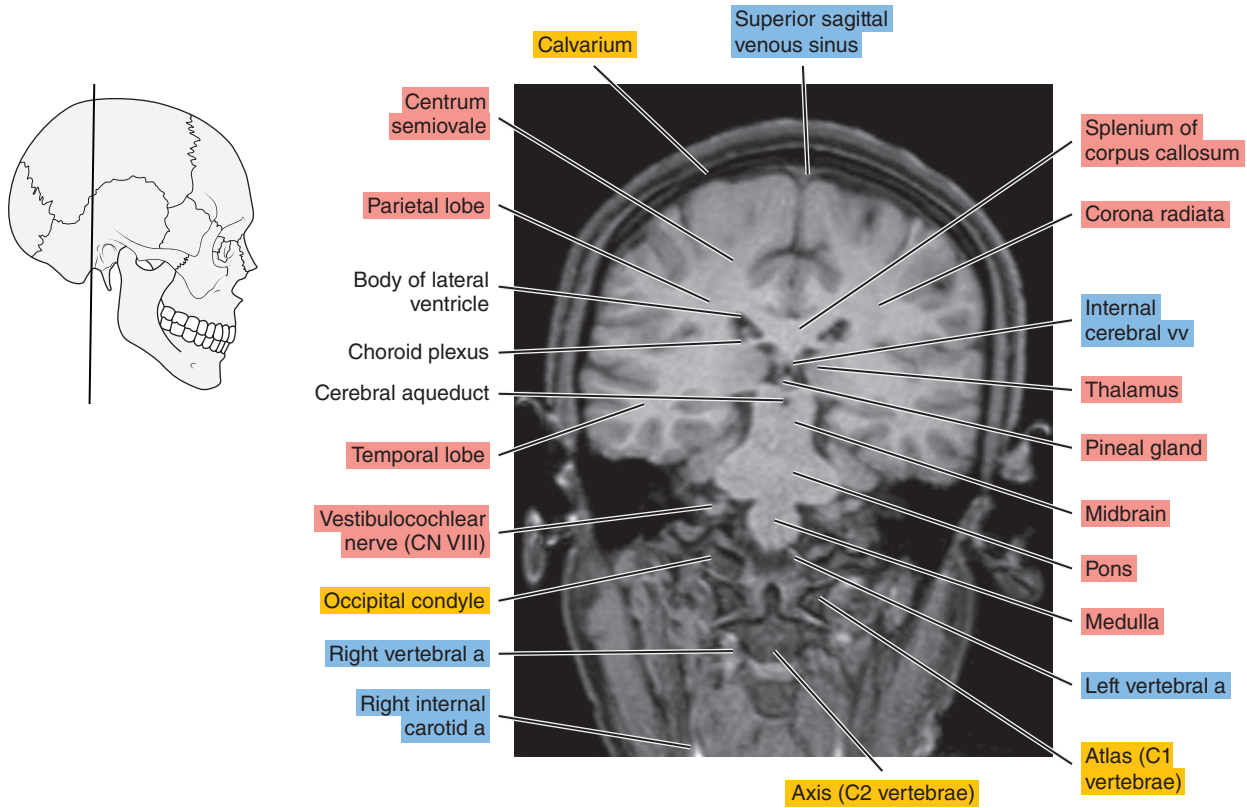


Figure 2.3.8

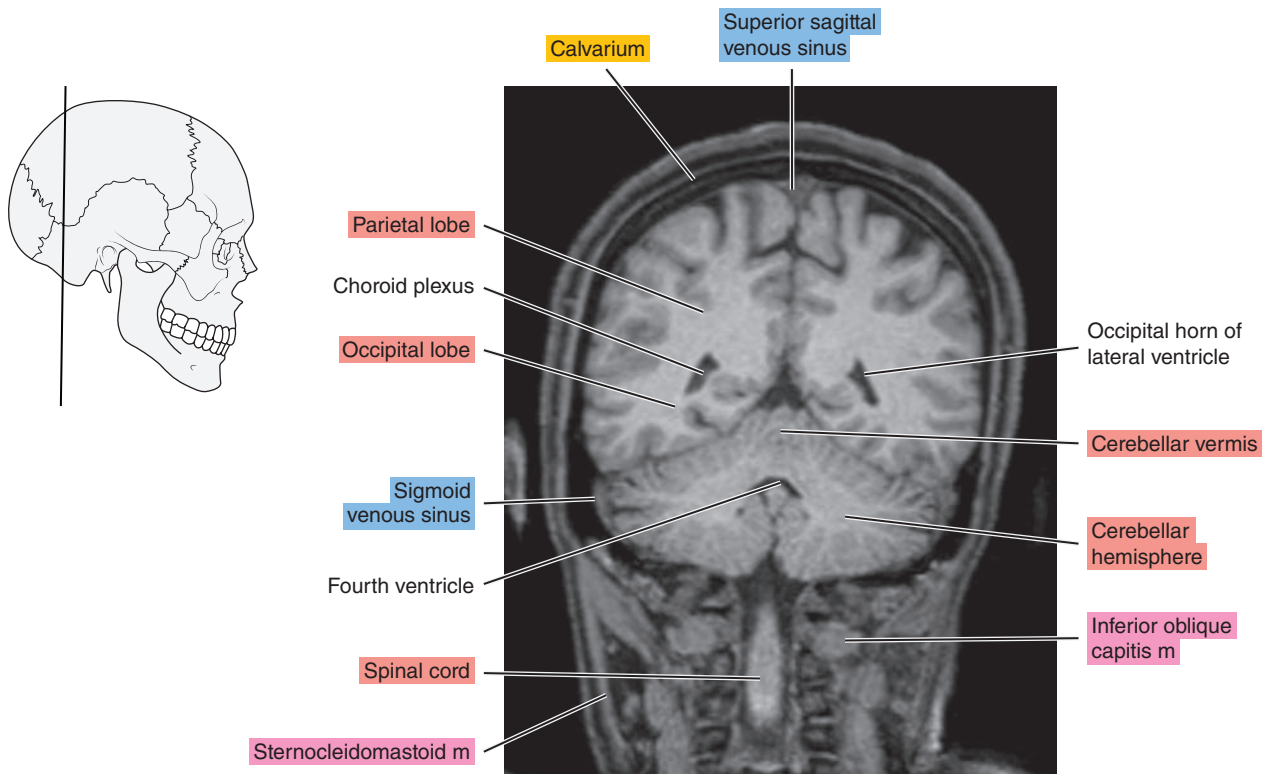




Figure 2.3.9

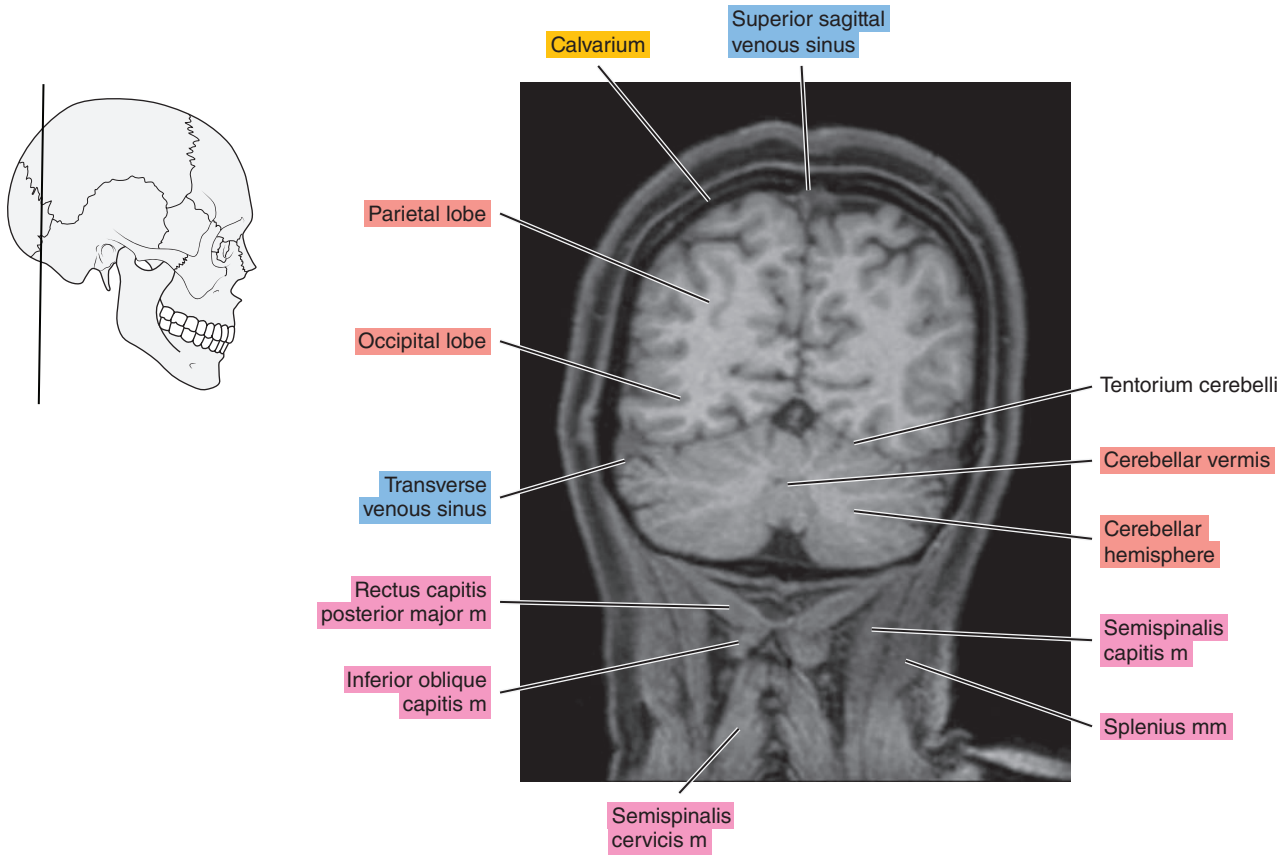
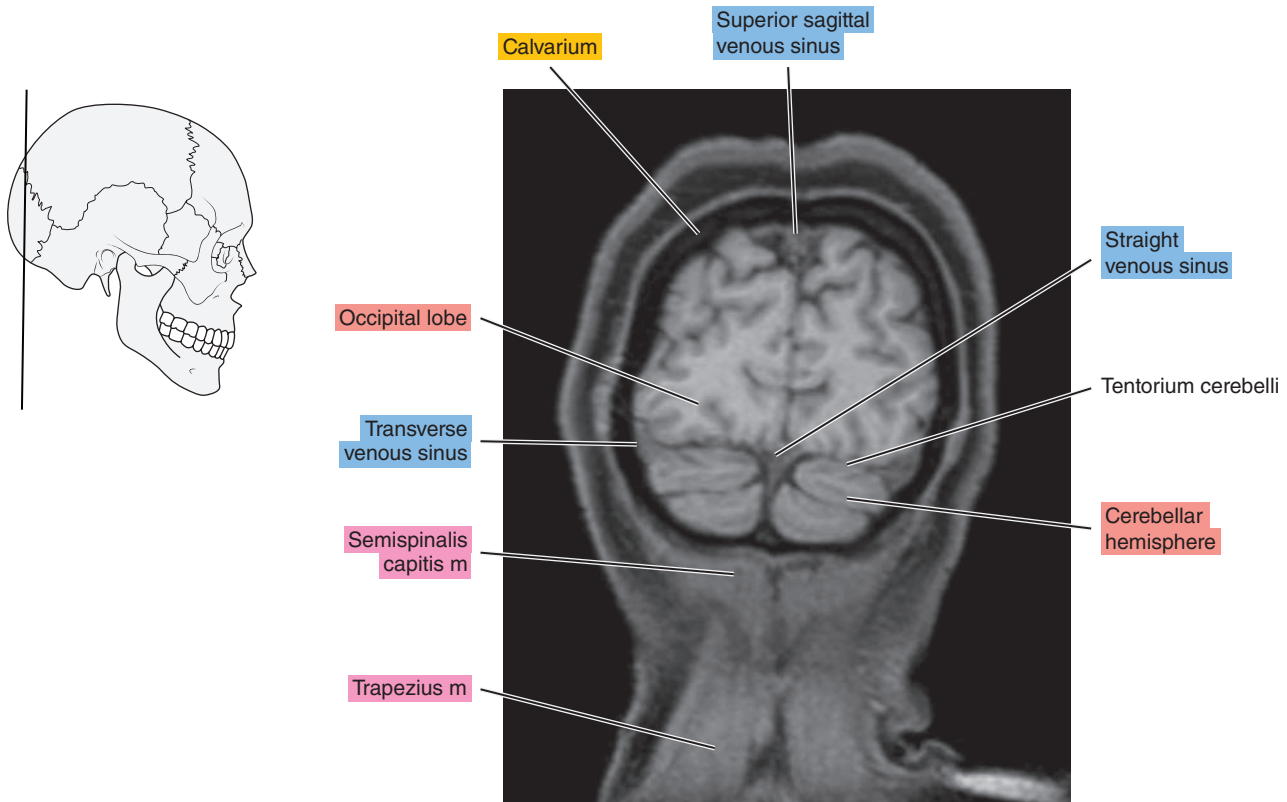


Figure 2.3.10





*Chapter*  
**3**

**CT of the Thorax**

# AXIAL

Figure 3.1.1

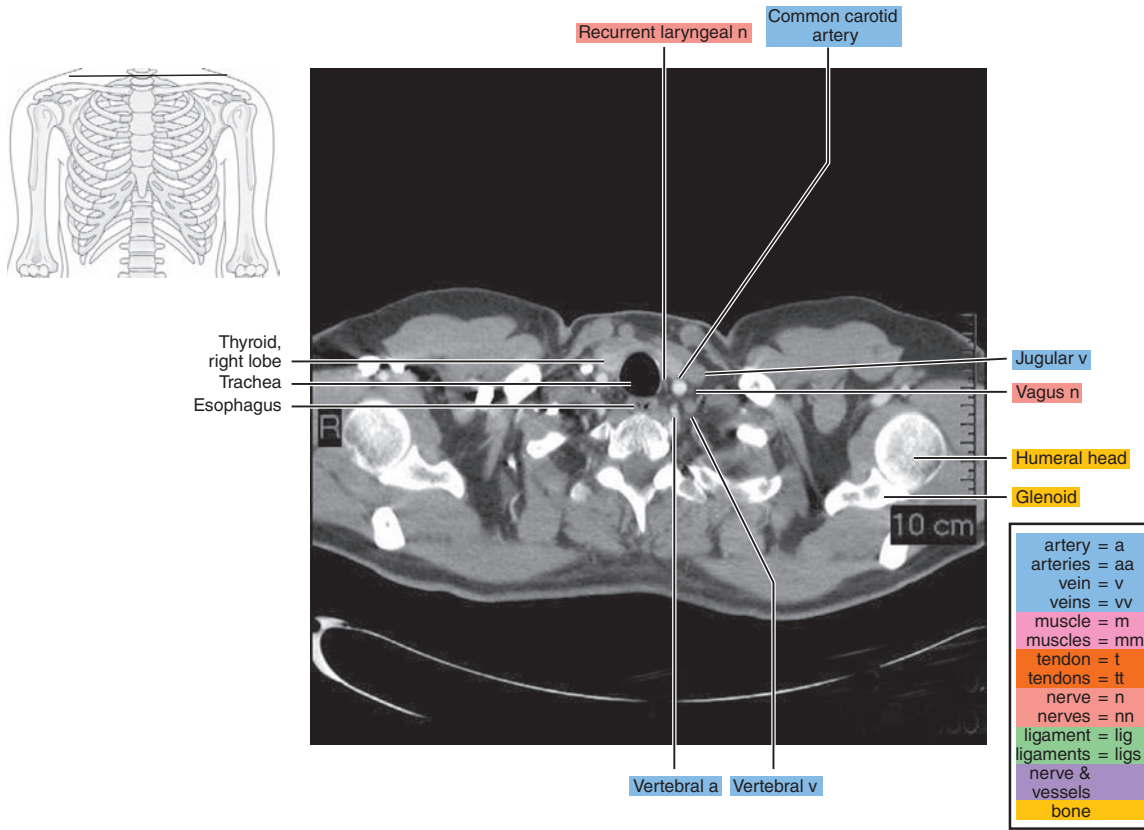


Figure 3.1.2

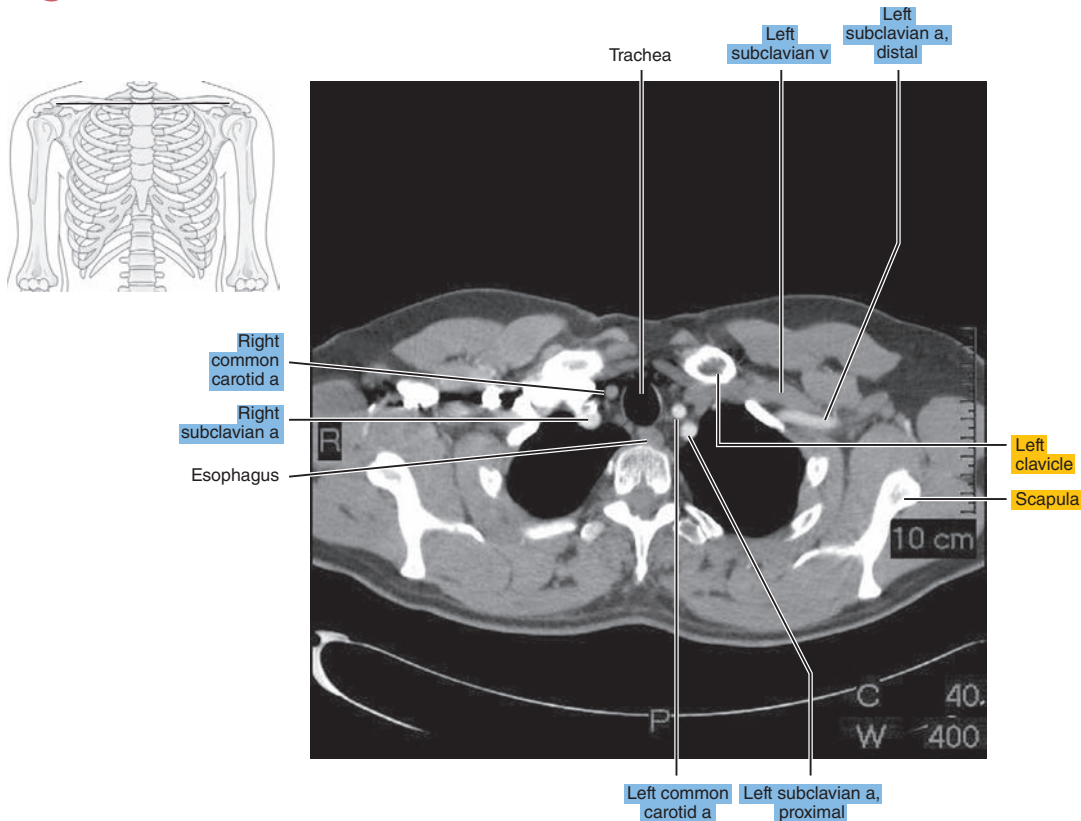


Figure 3.1.3

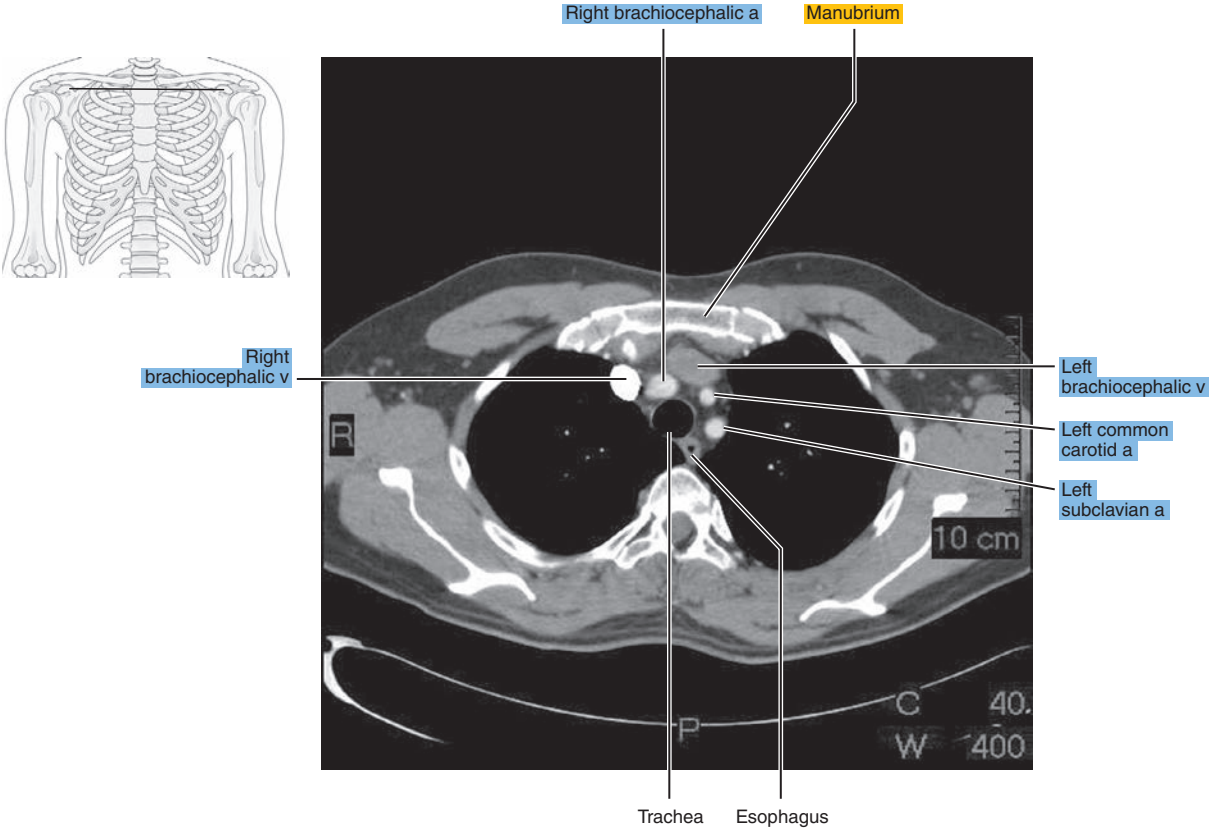


Figure 3.1.4

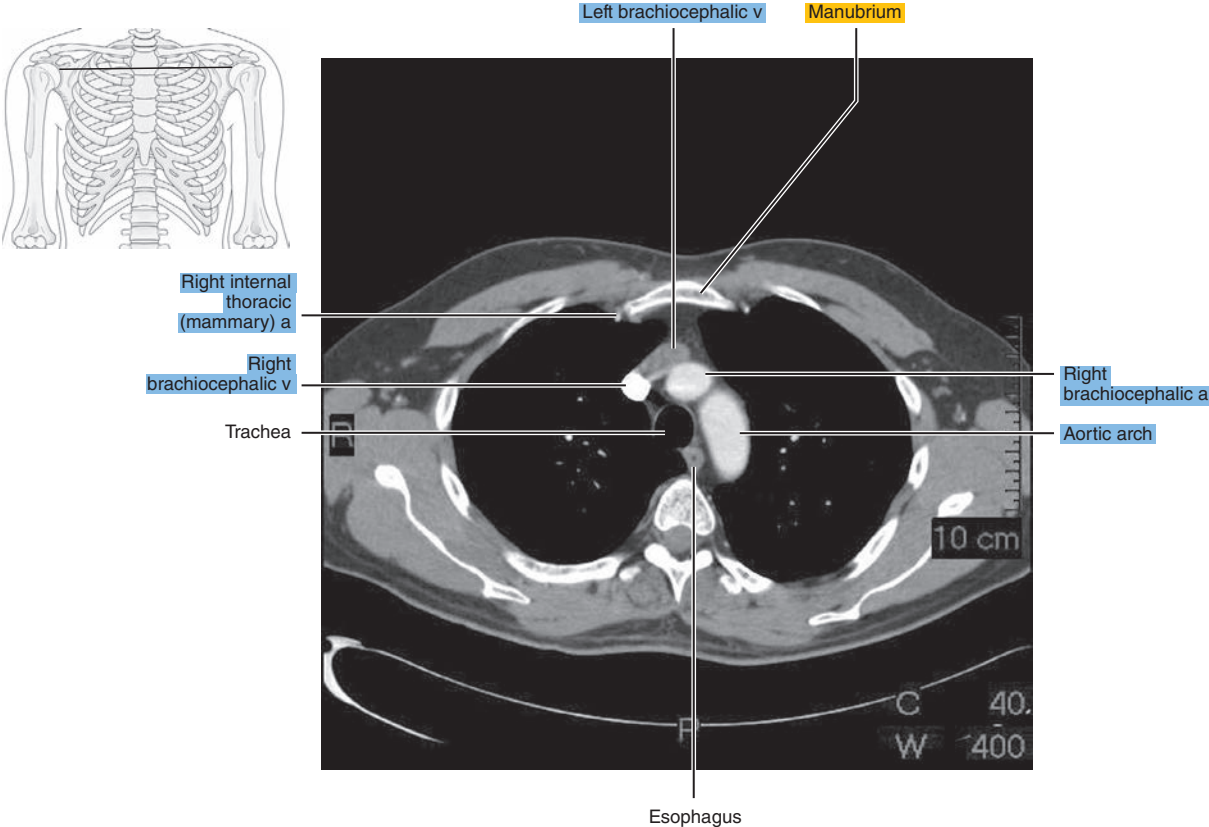


Figure 3.1.5

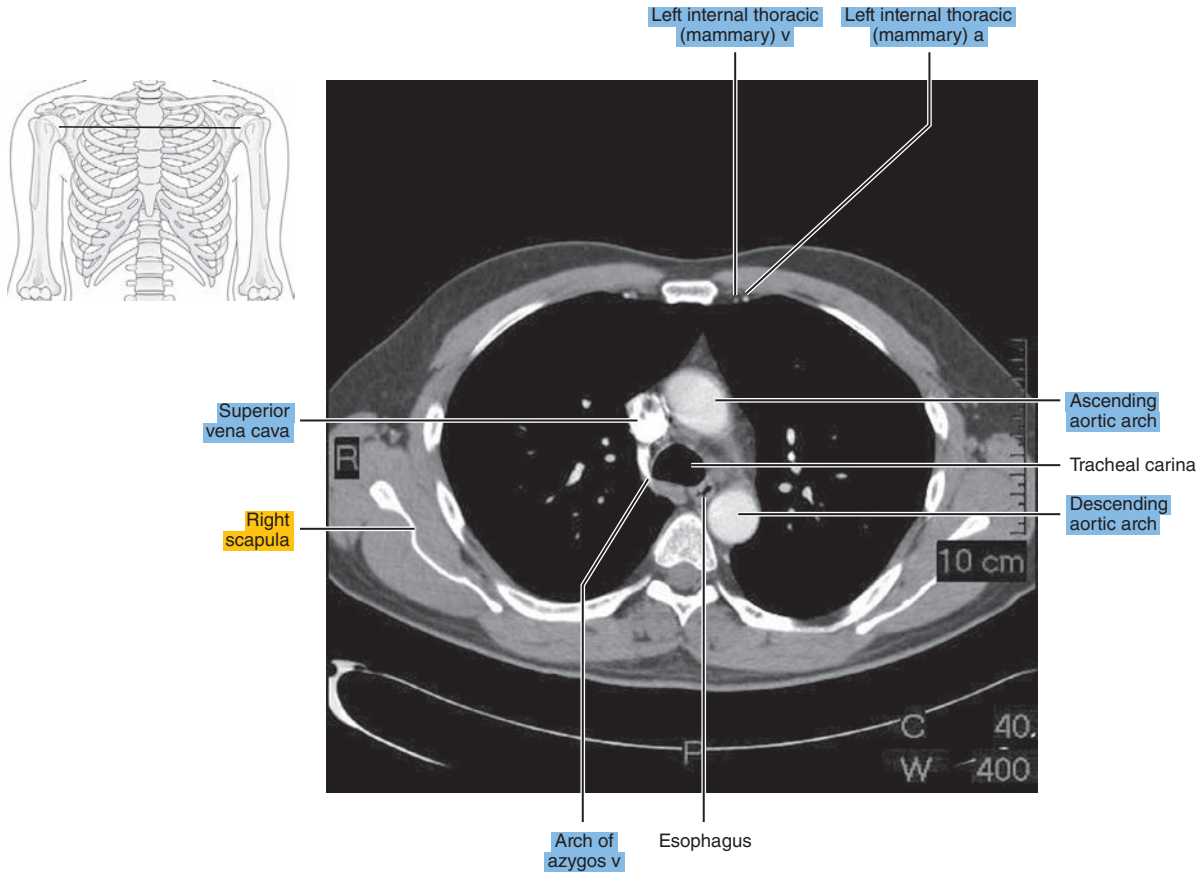


Figure 3.1.6

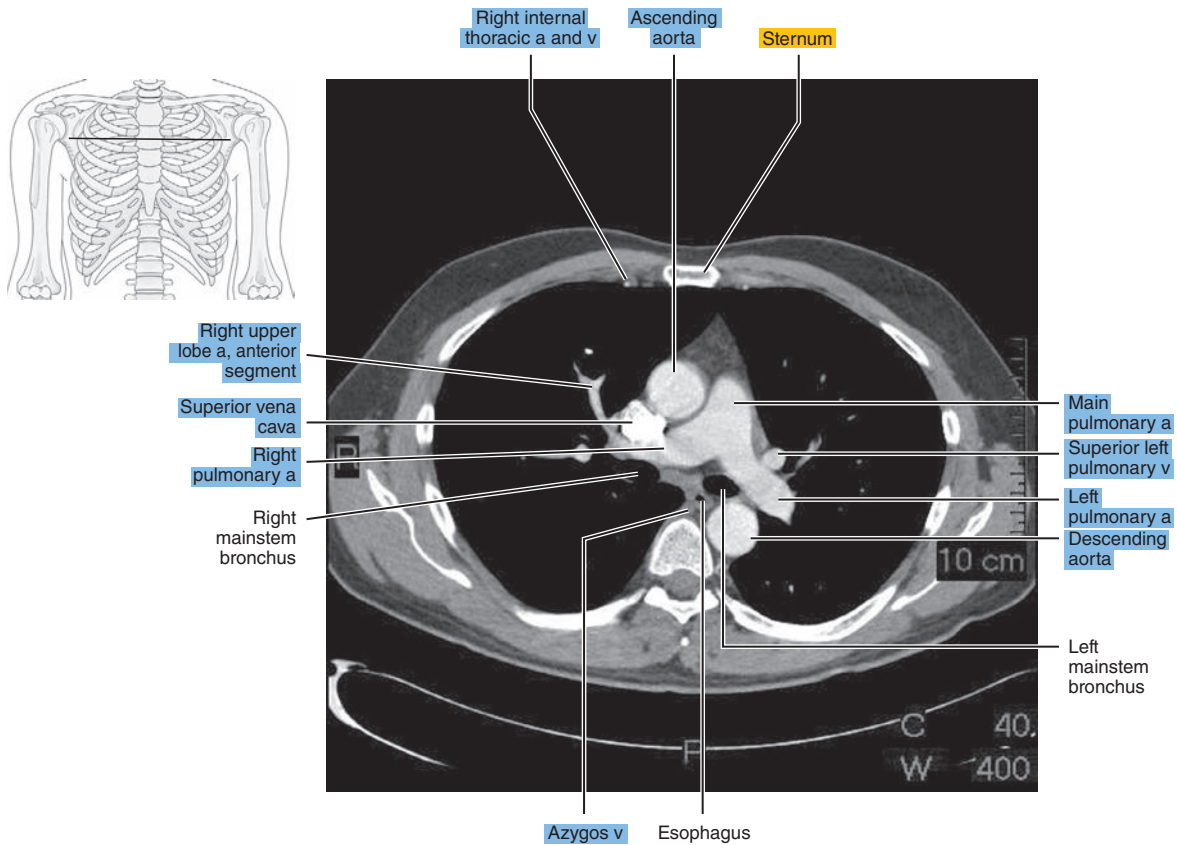




Figure 3.1.7

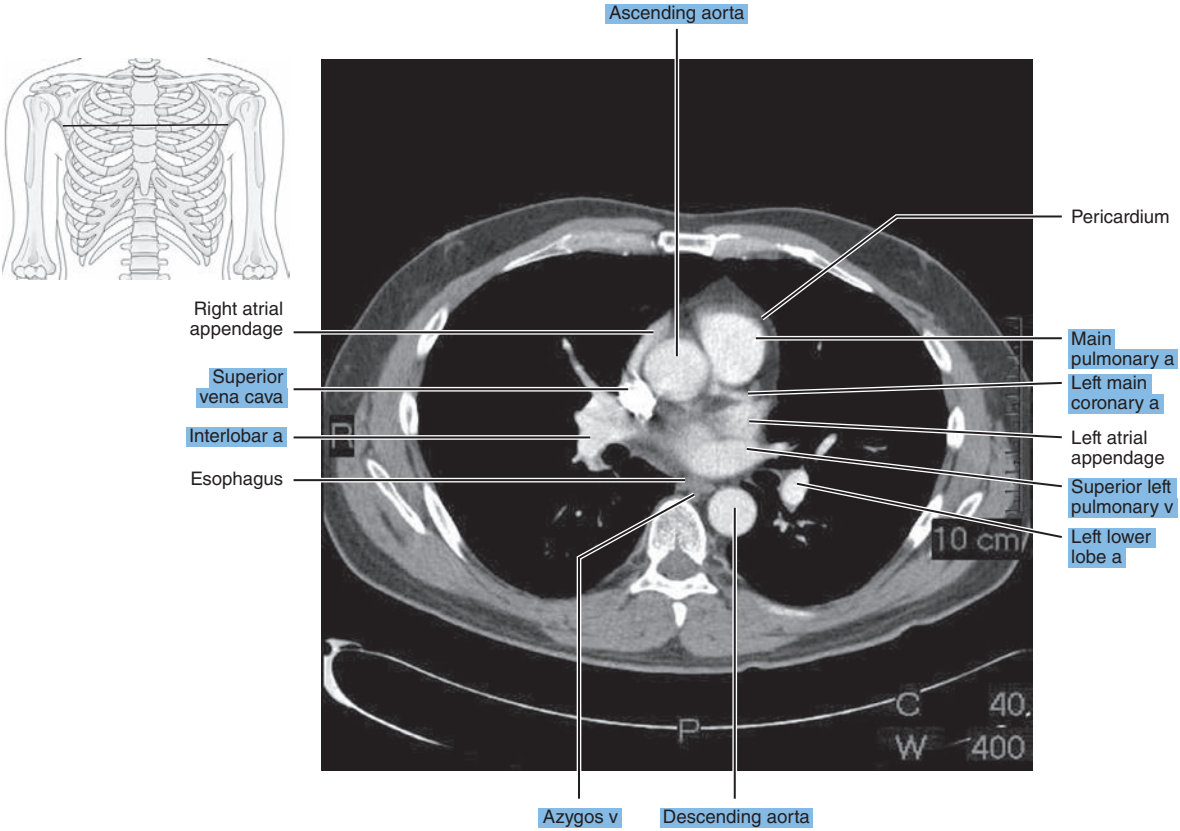


Figure 3.1.8

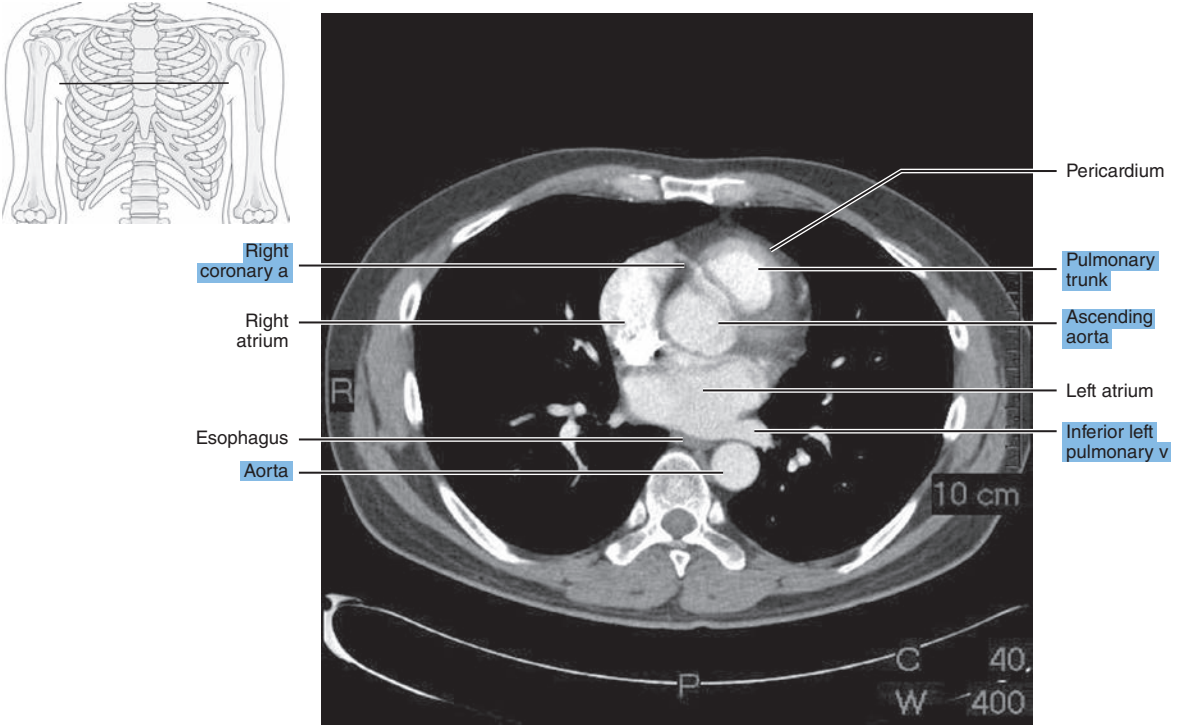


Figure 3.1.9

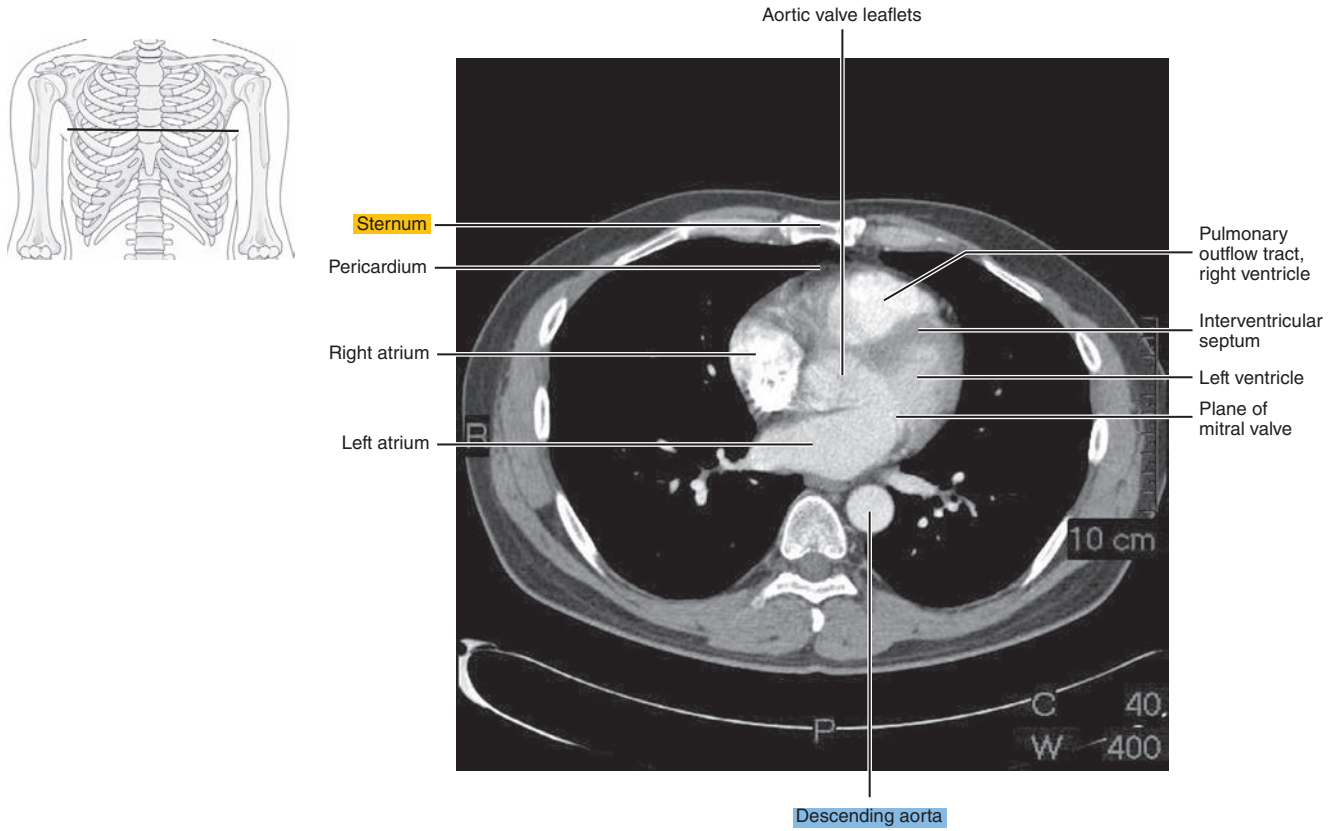


Figure 3.1.10

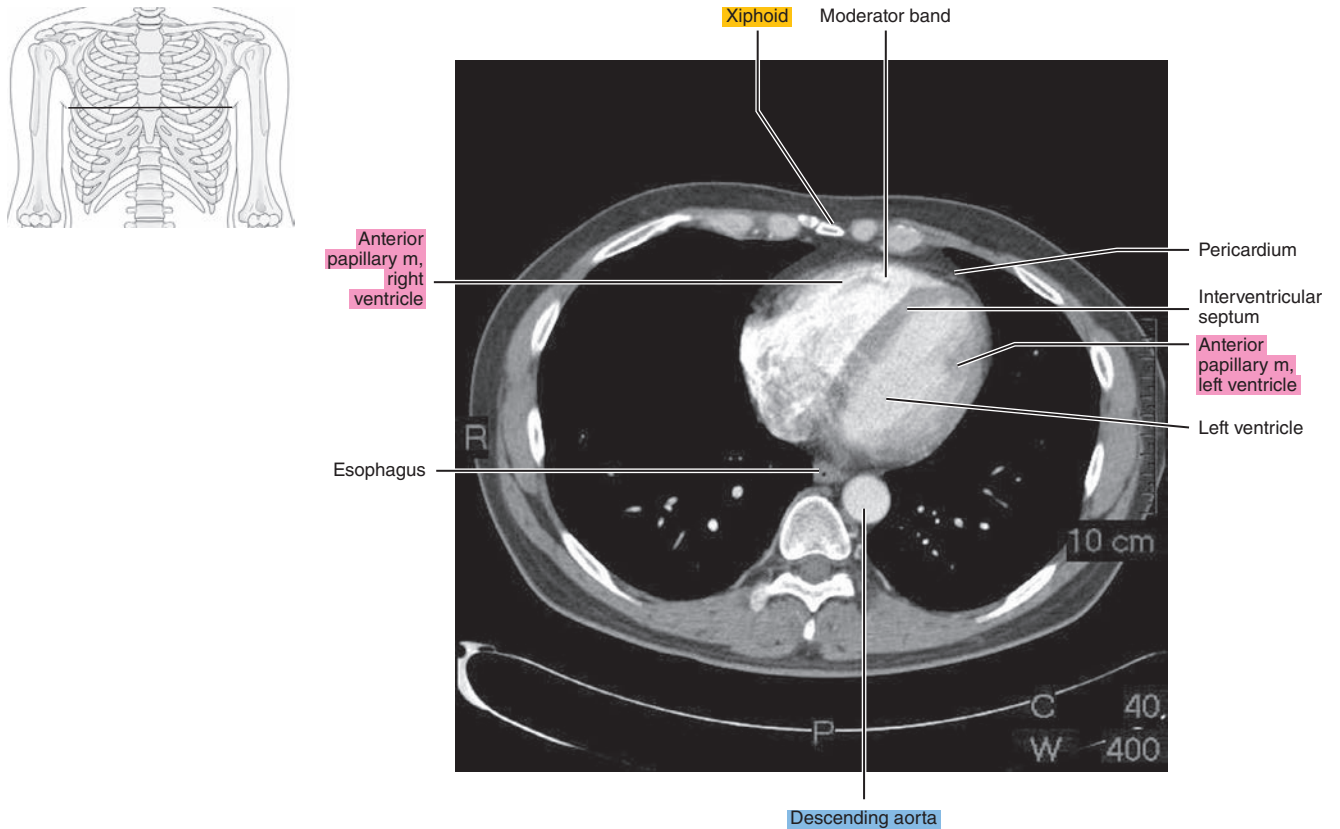




Figure 3.1.11

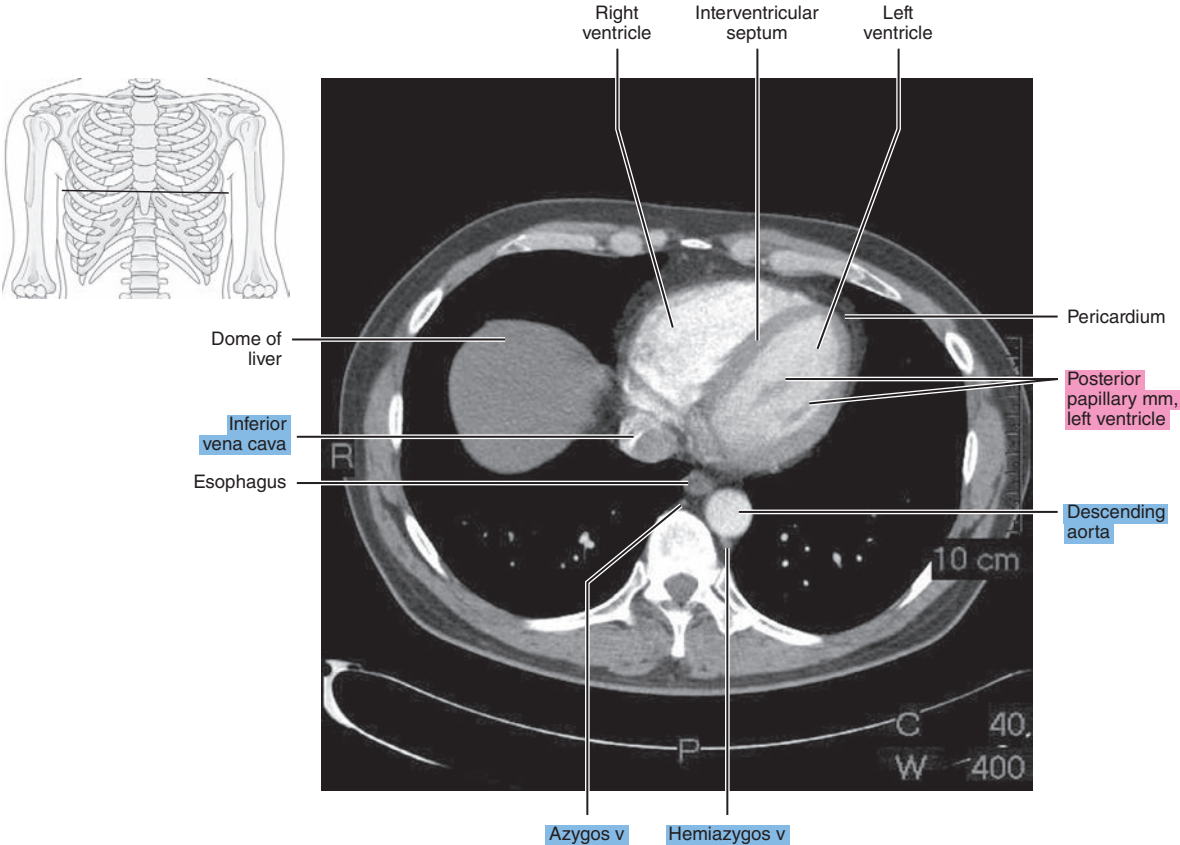


Figure 3.1.12

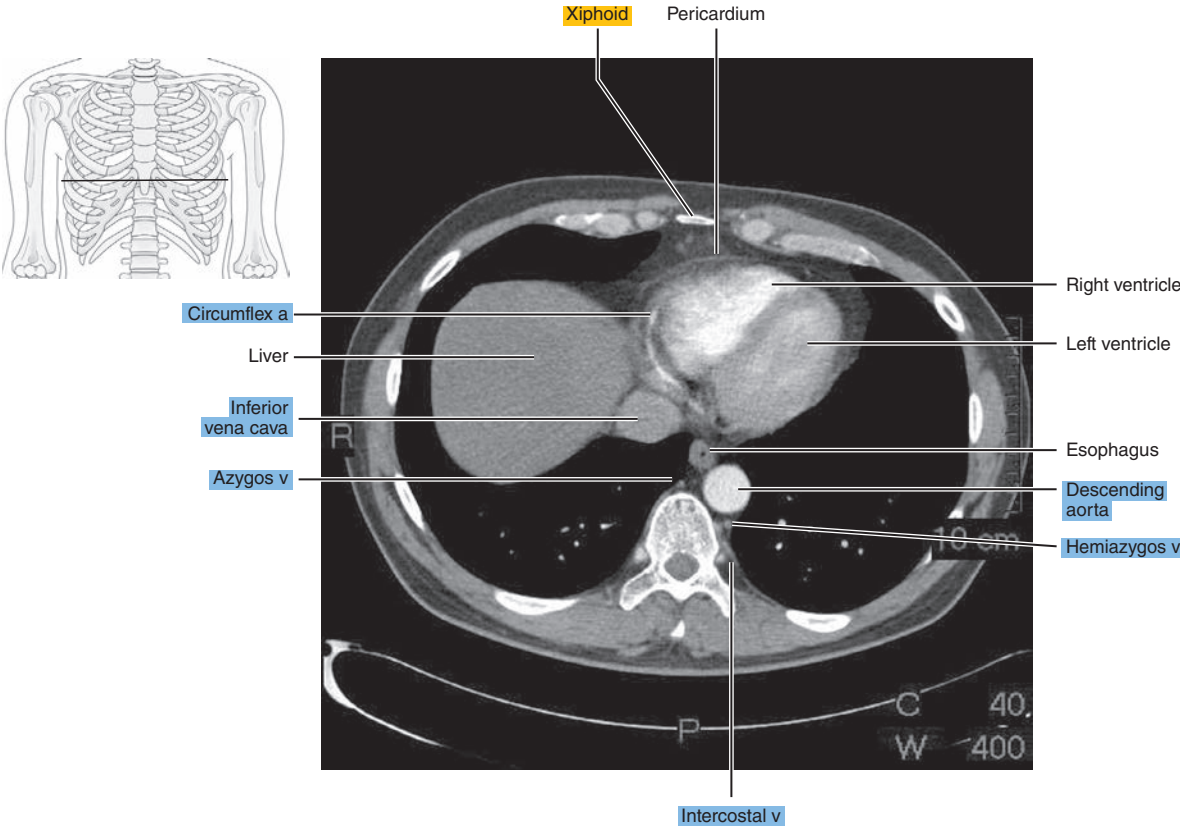
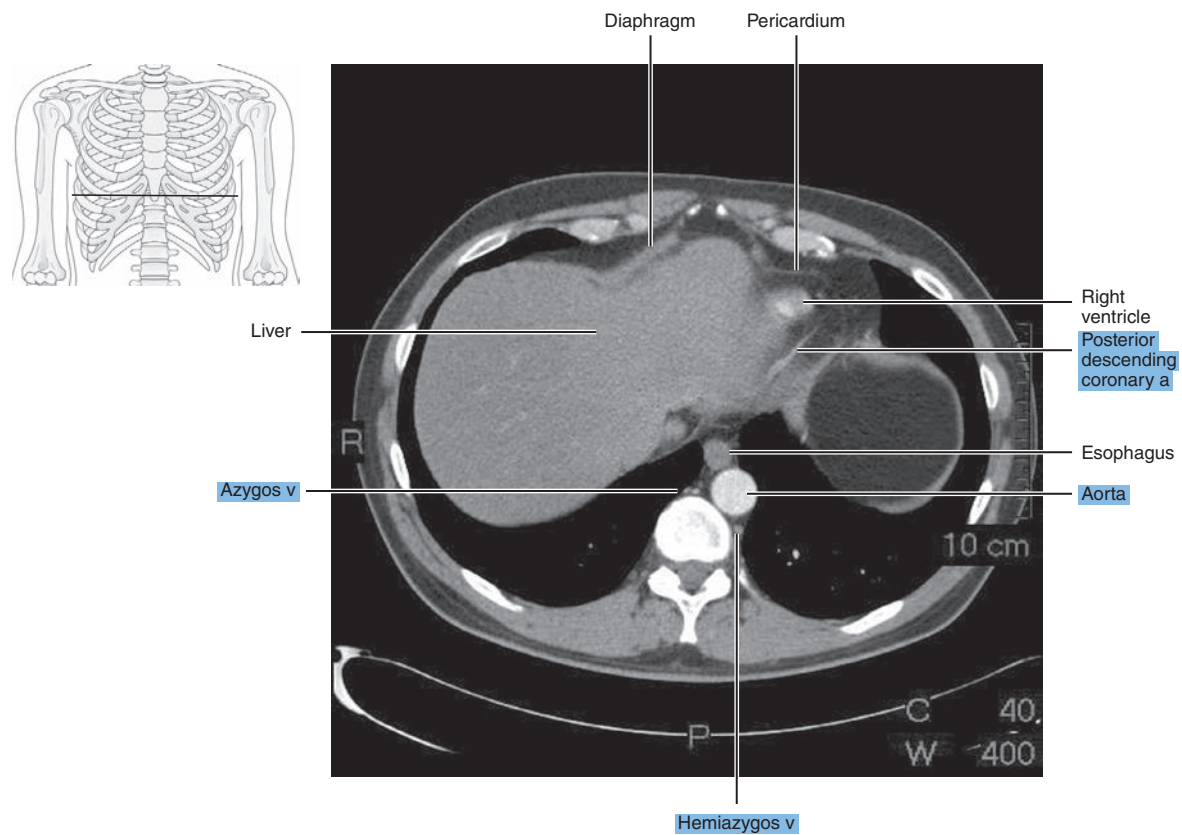
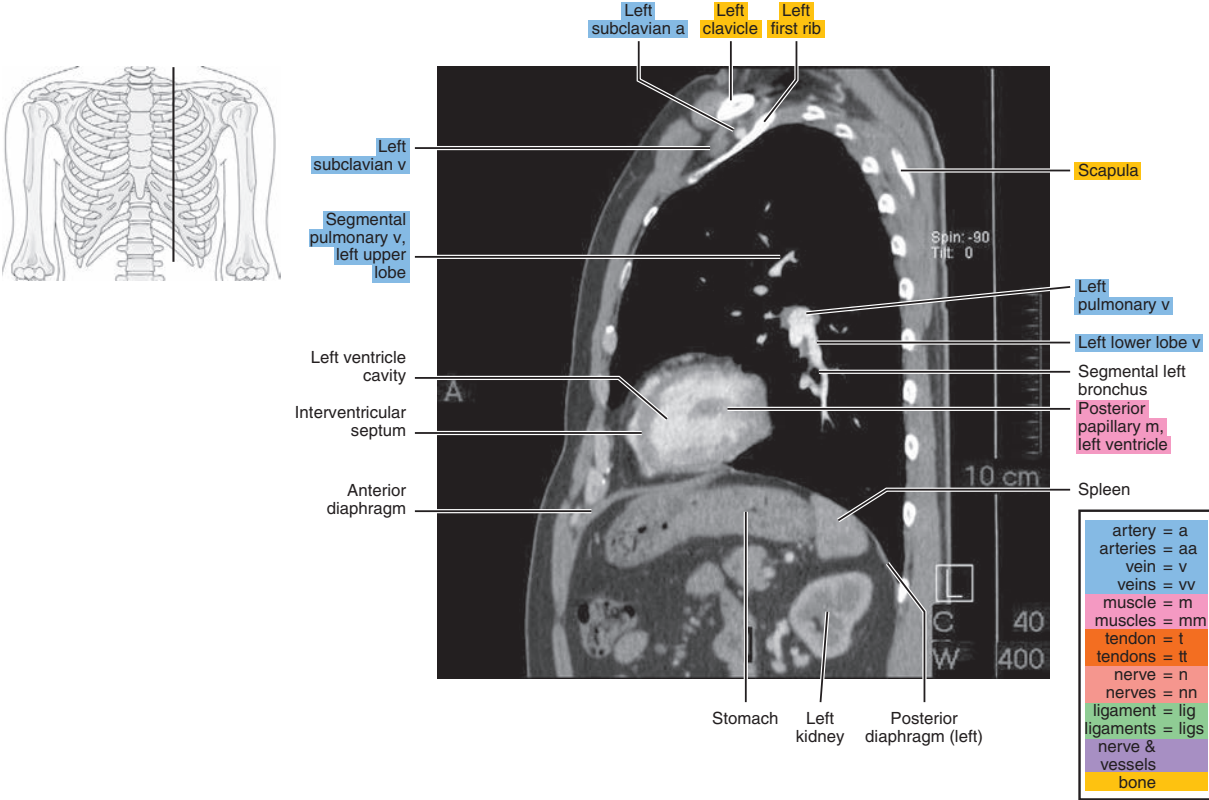


Figure 3.1.13



# SAGITTAL

## Figure 3.2.1A



## Figure 3.2.1B

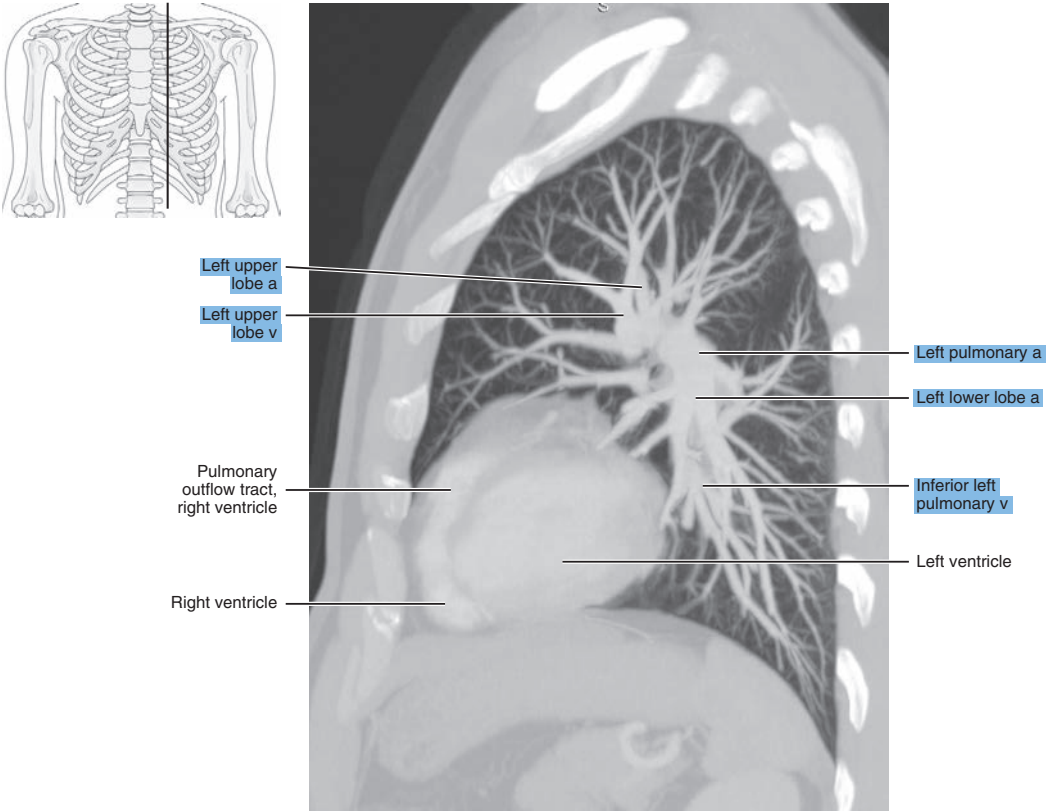


Figure 3.2.2

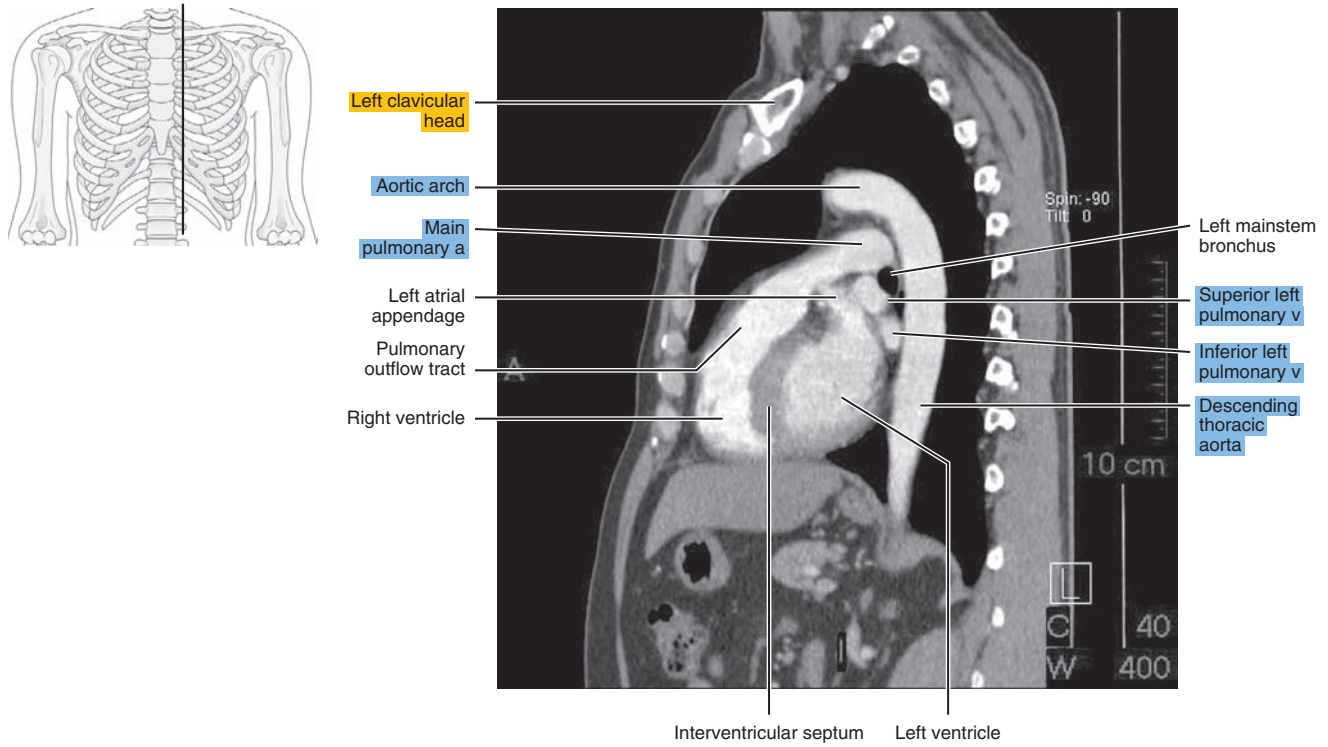


Figure 3.2.3

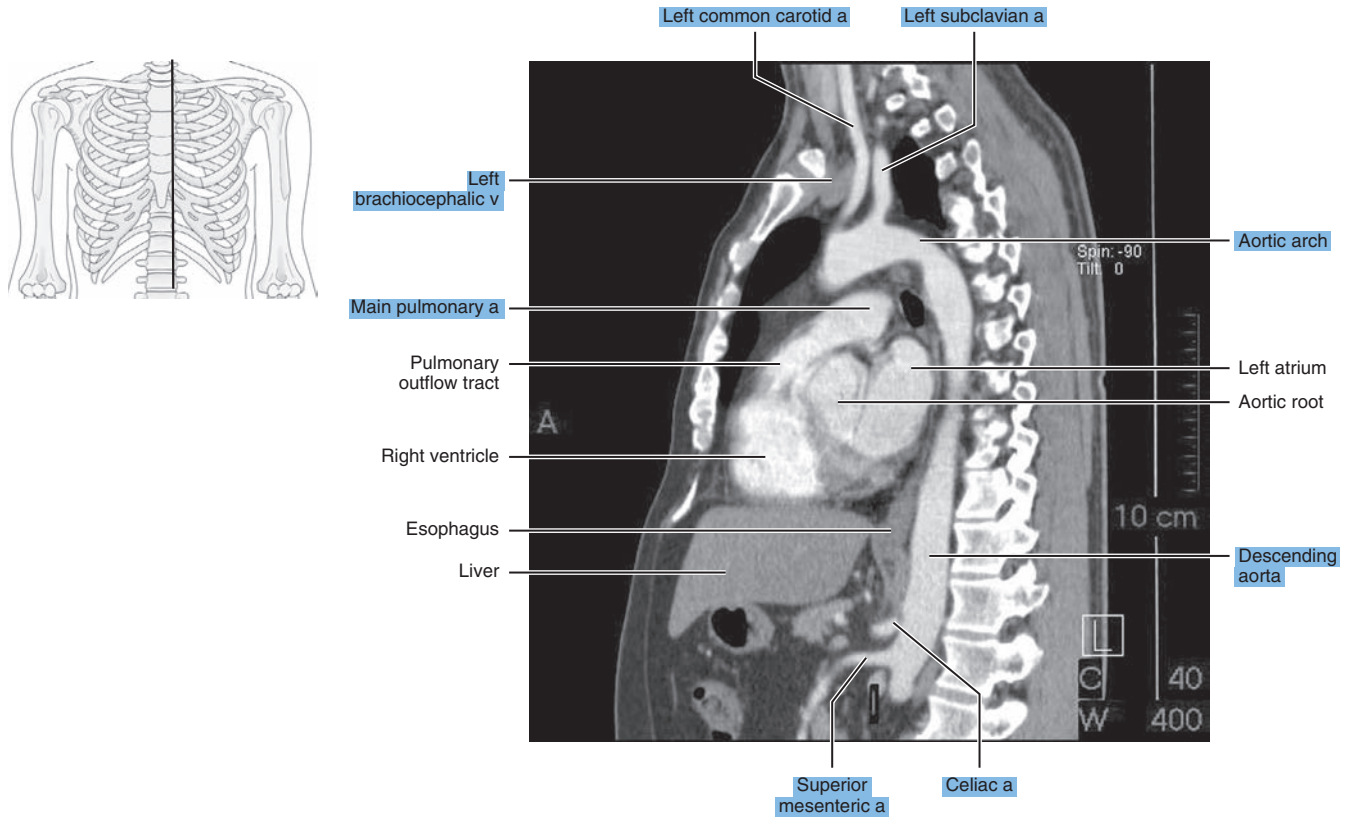




Figure 3.2.4

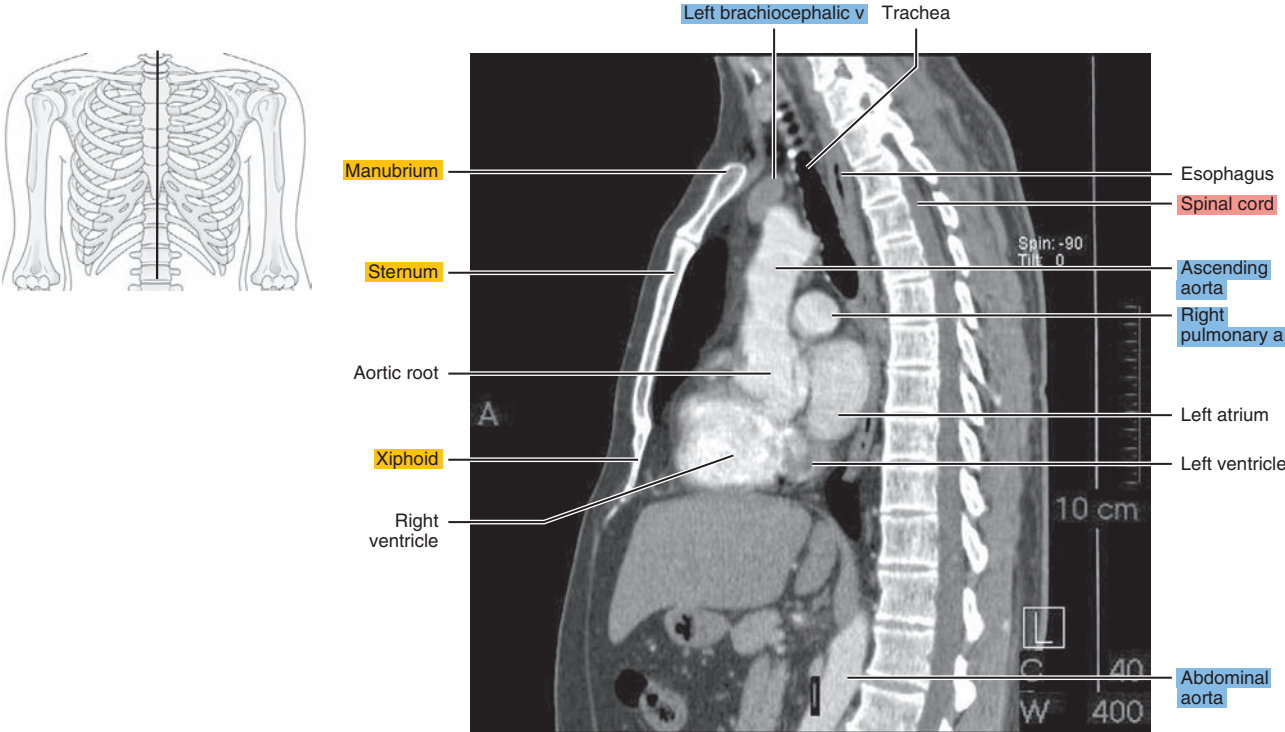


Figure 3.2.5

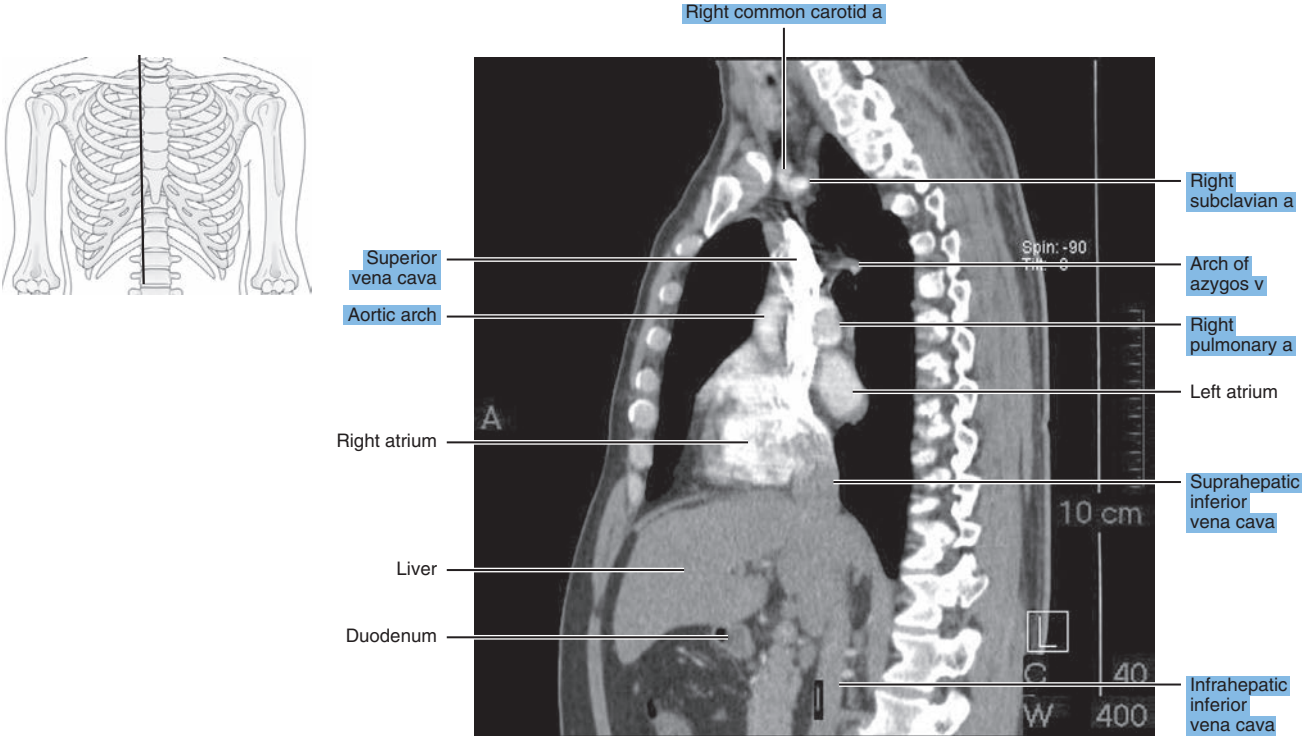
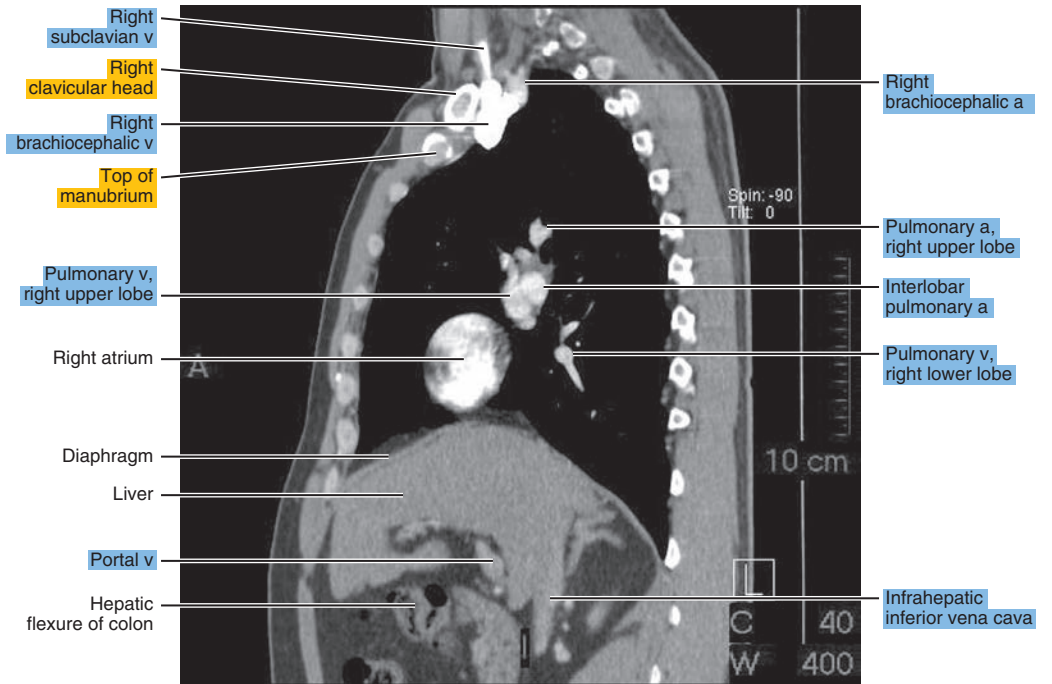
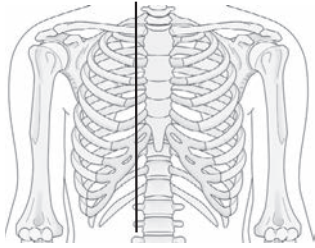


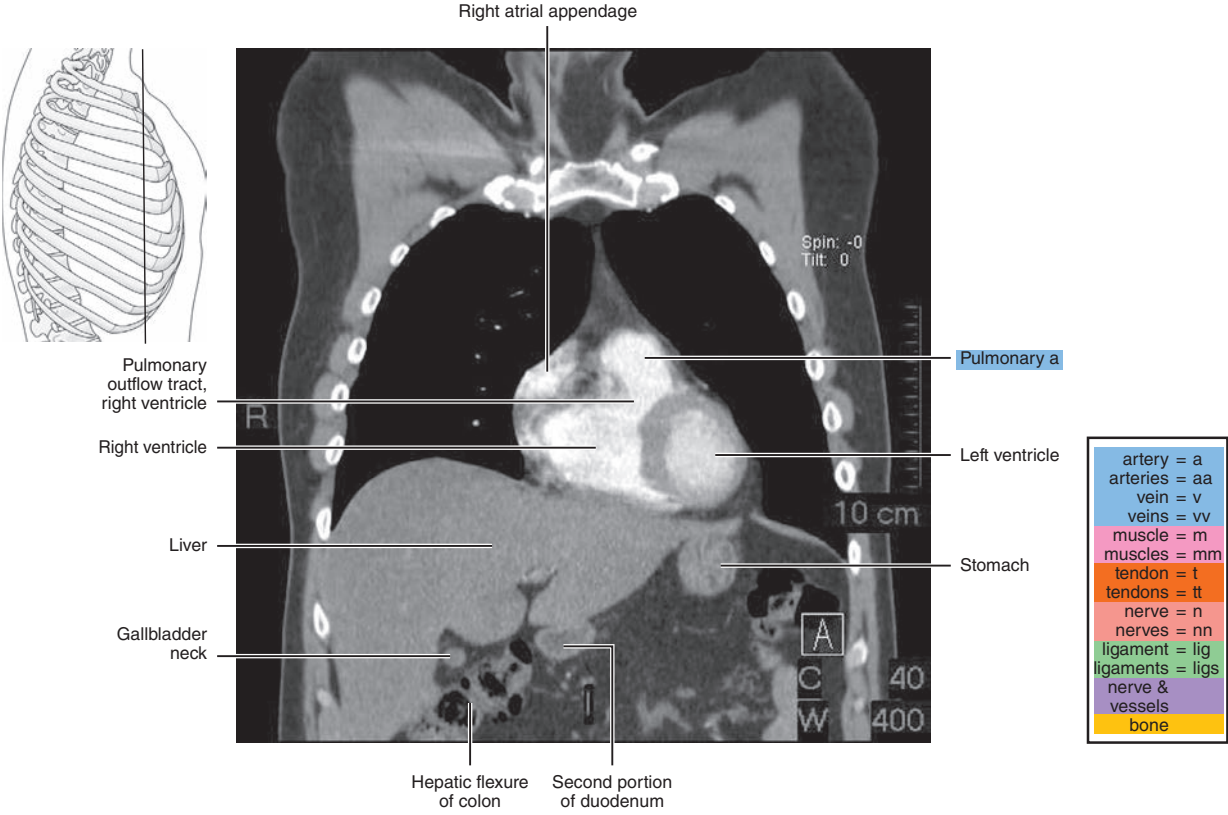
Figure 3.2.6





# CORONAL

## Figure 3.3.1



## Figure 3.3.2

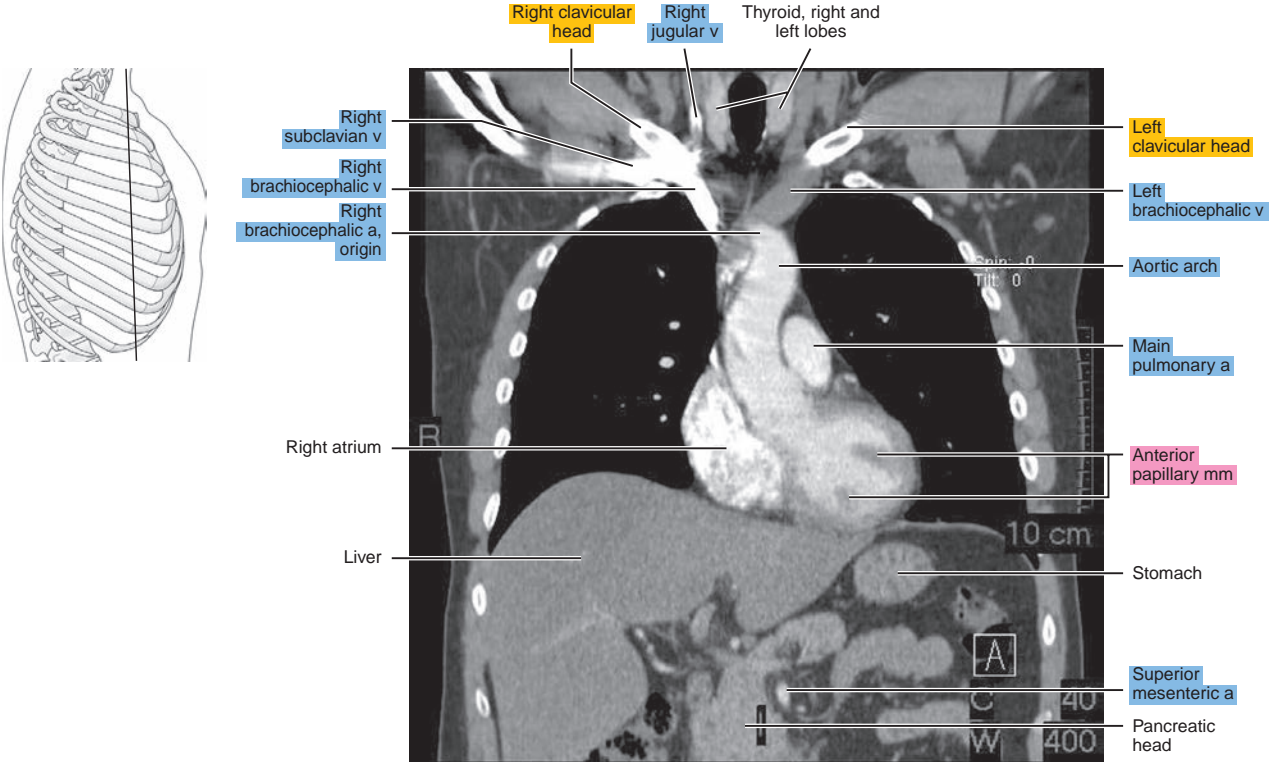


Figure 3.3.3A

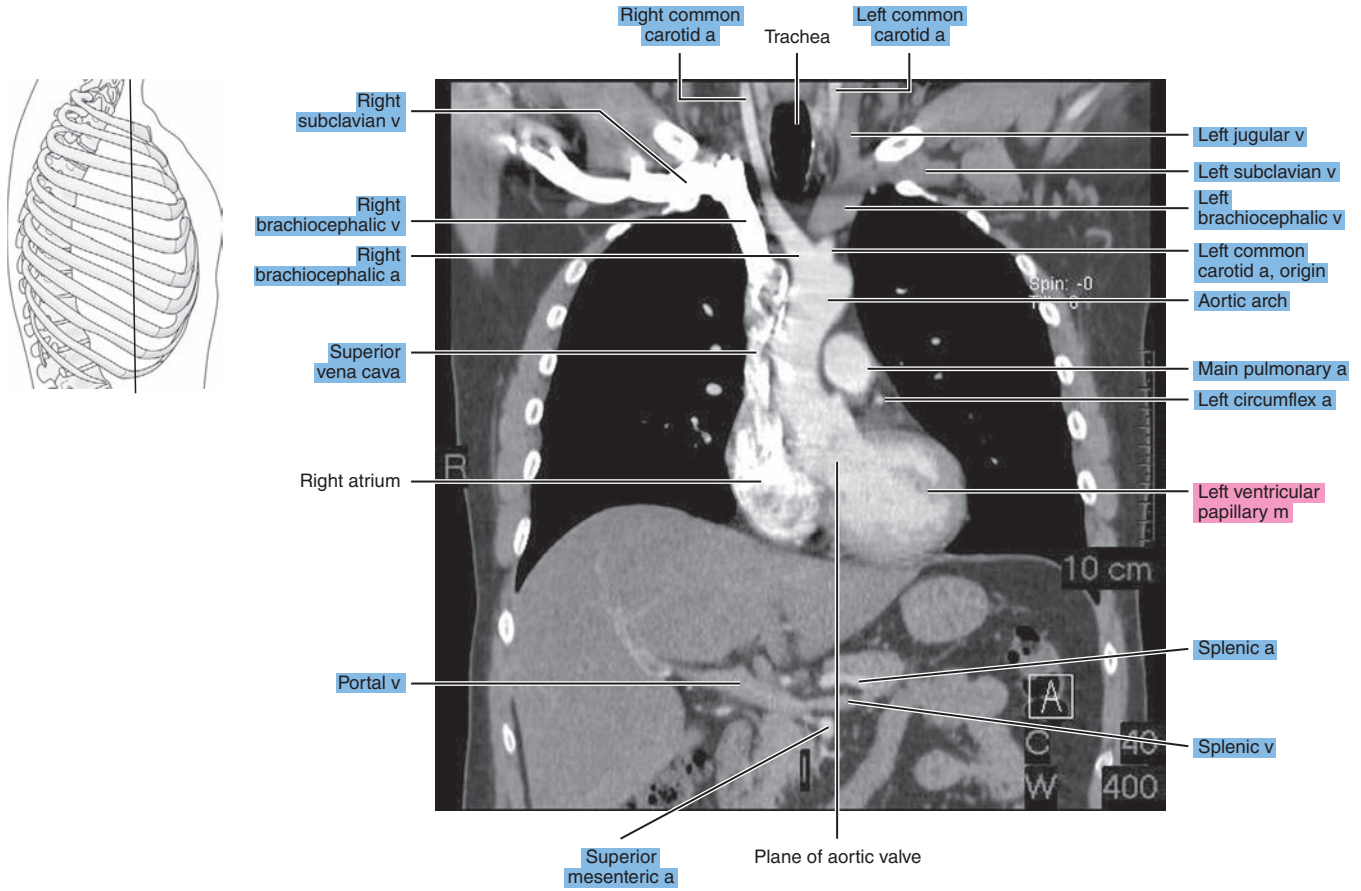


Figure 3.3.3B

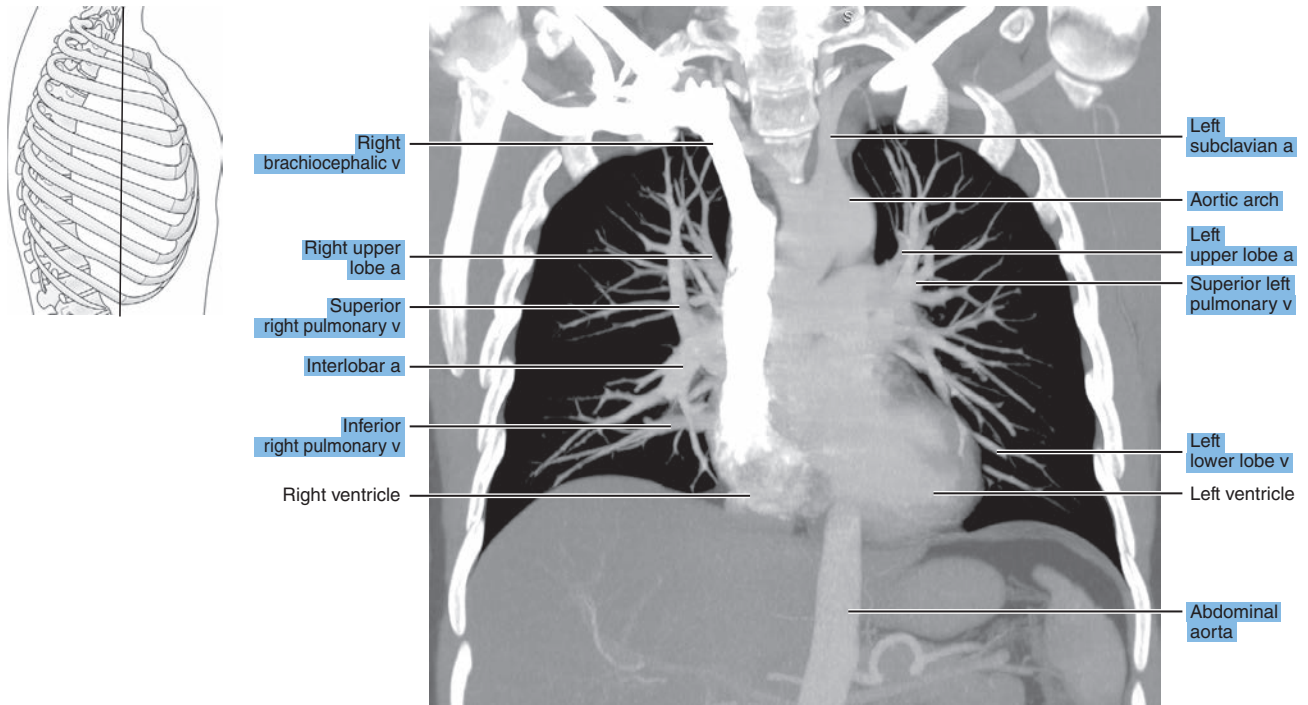


Figure 3.3.4

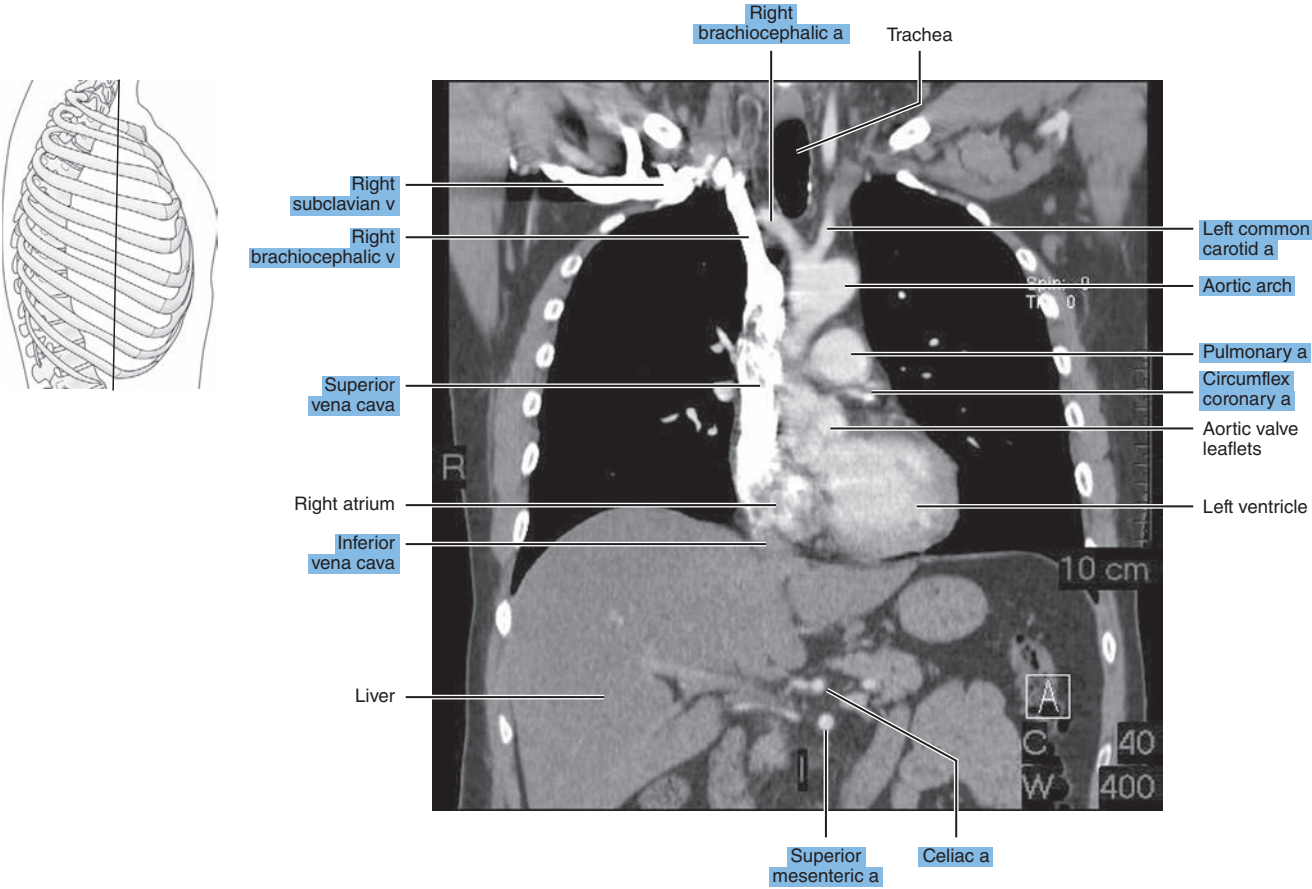


Figure 3.3.5

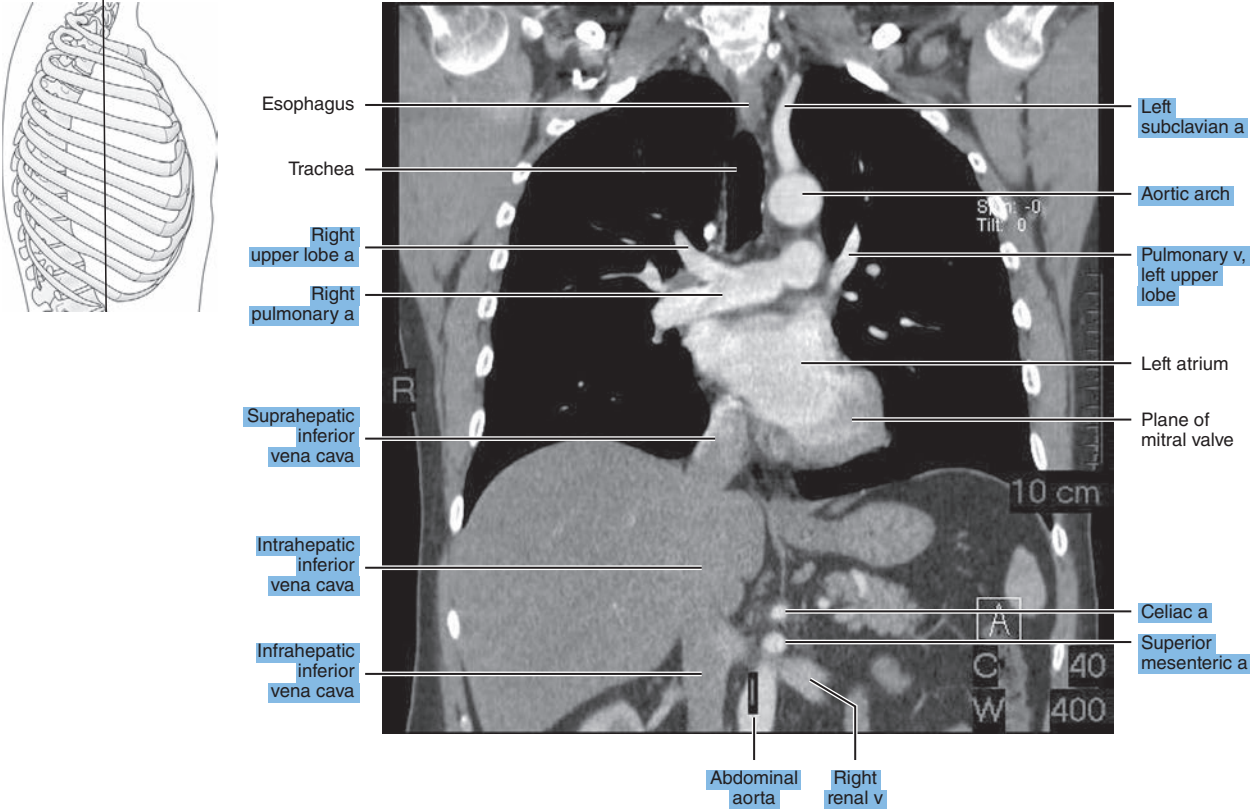




Figure 3.3.6A

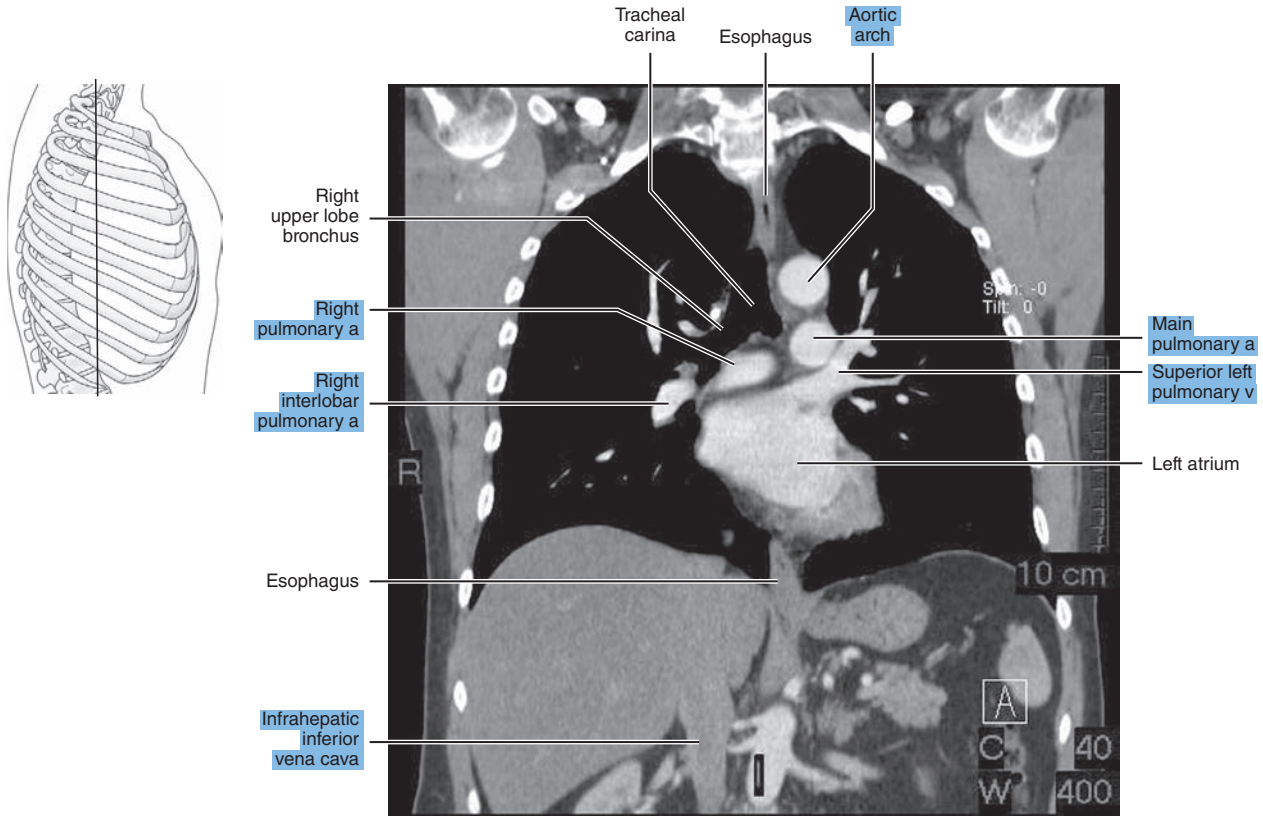


Figure 3.3.6B

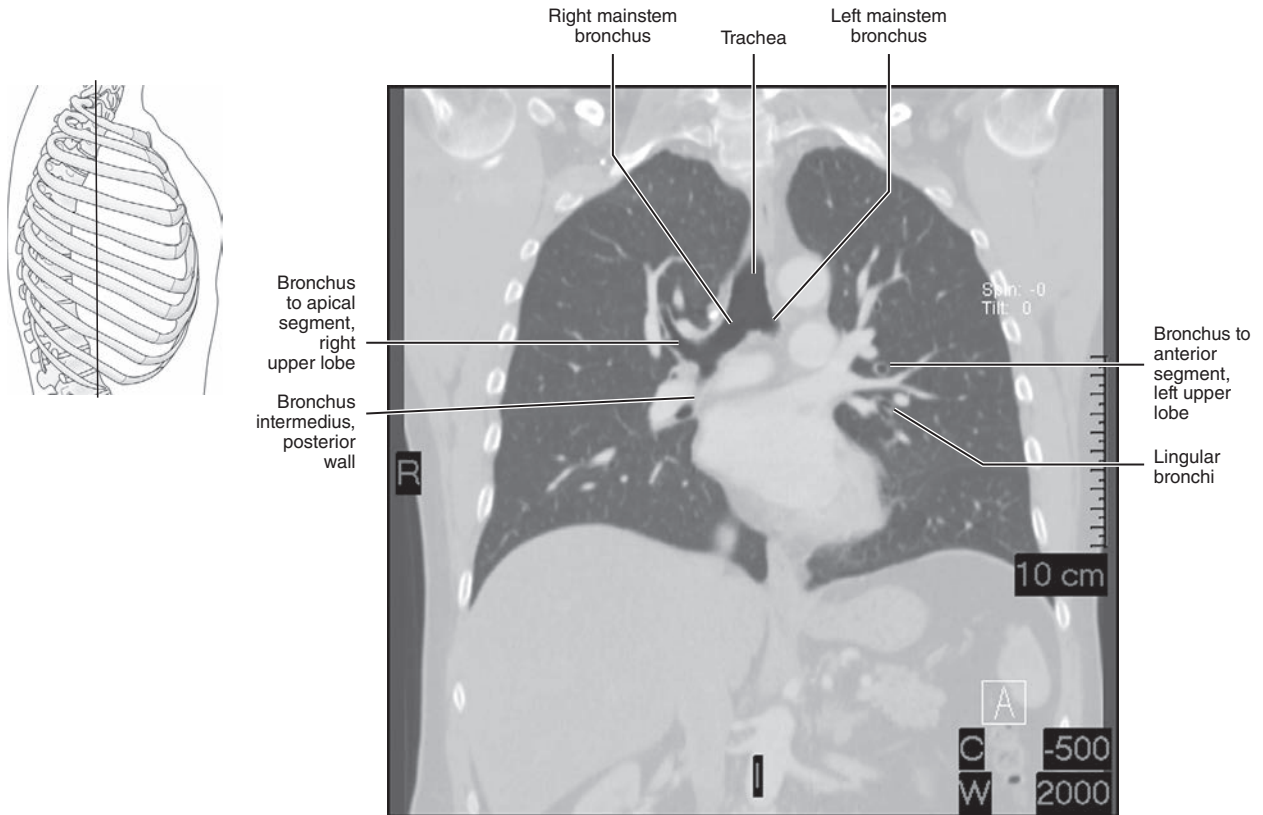


Figure 3.3.7A

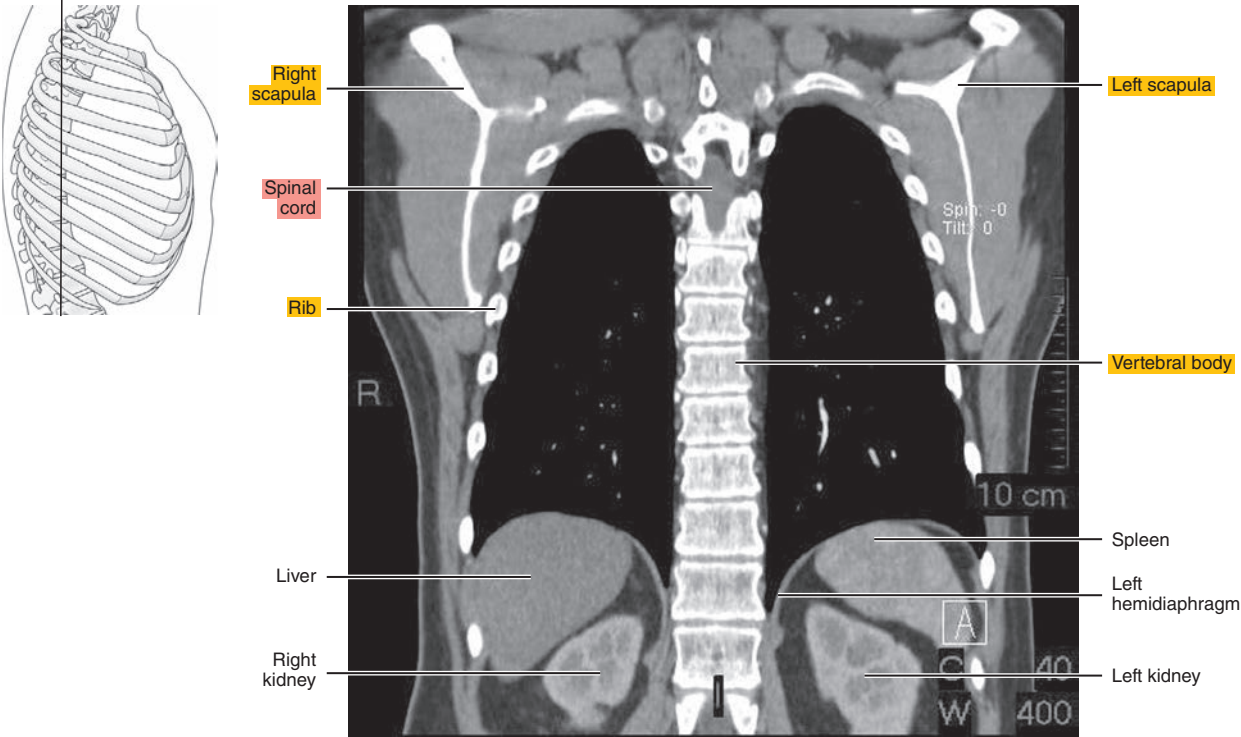


Figure 3.3.7B

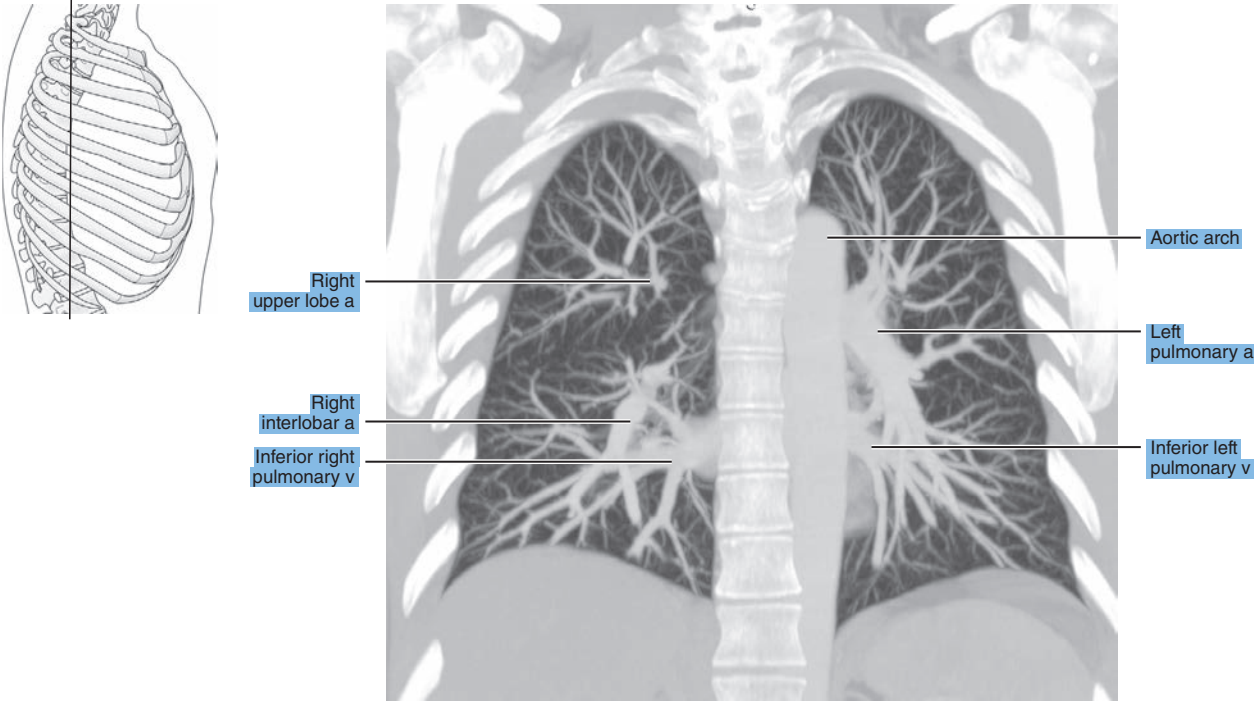
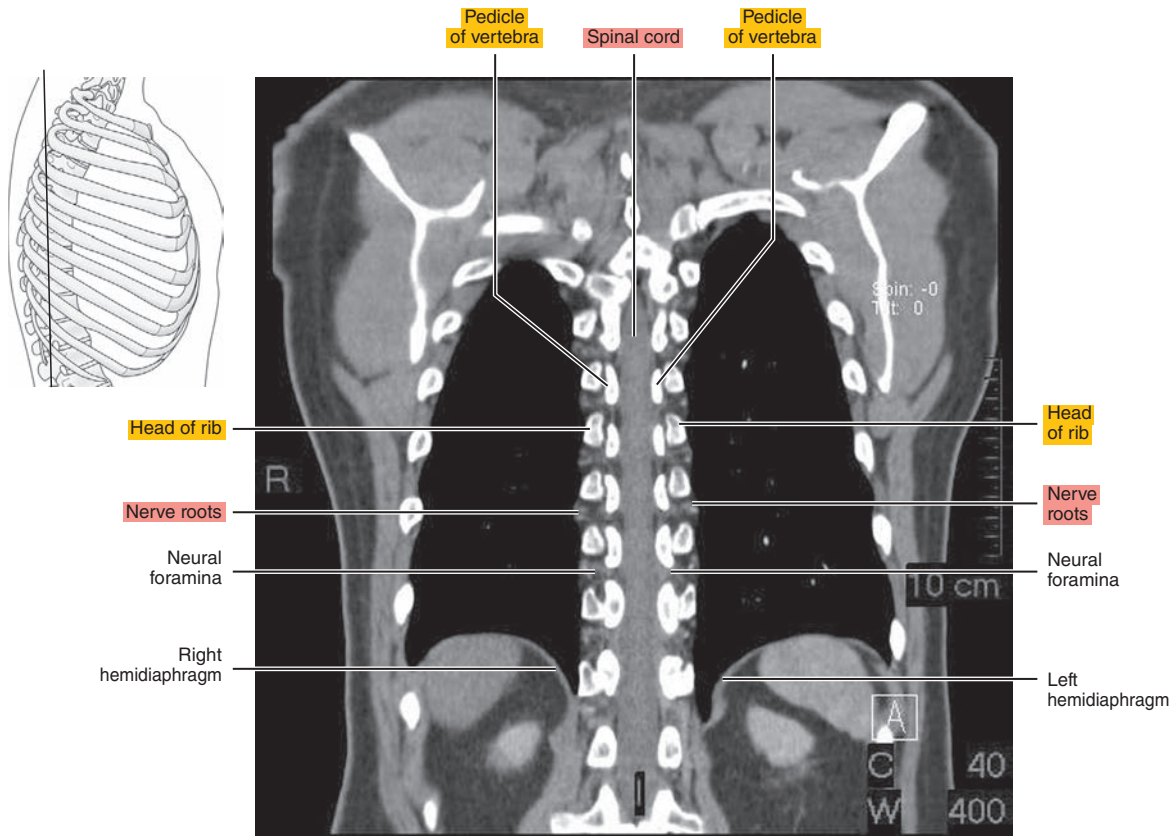


Figure 3.3.8





*Chapter*  
**4**

**MRI of the Heart**

# AXIAL

Figure 4.1.1

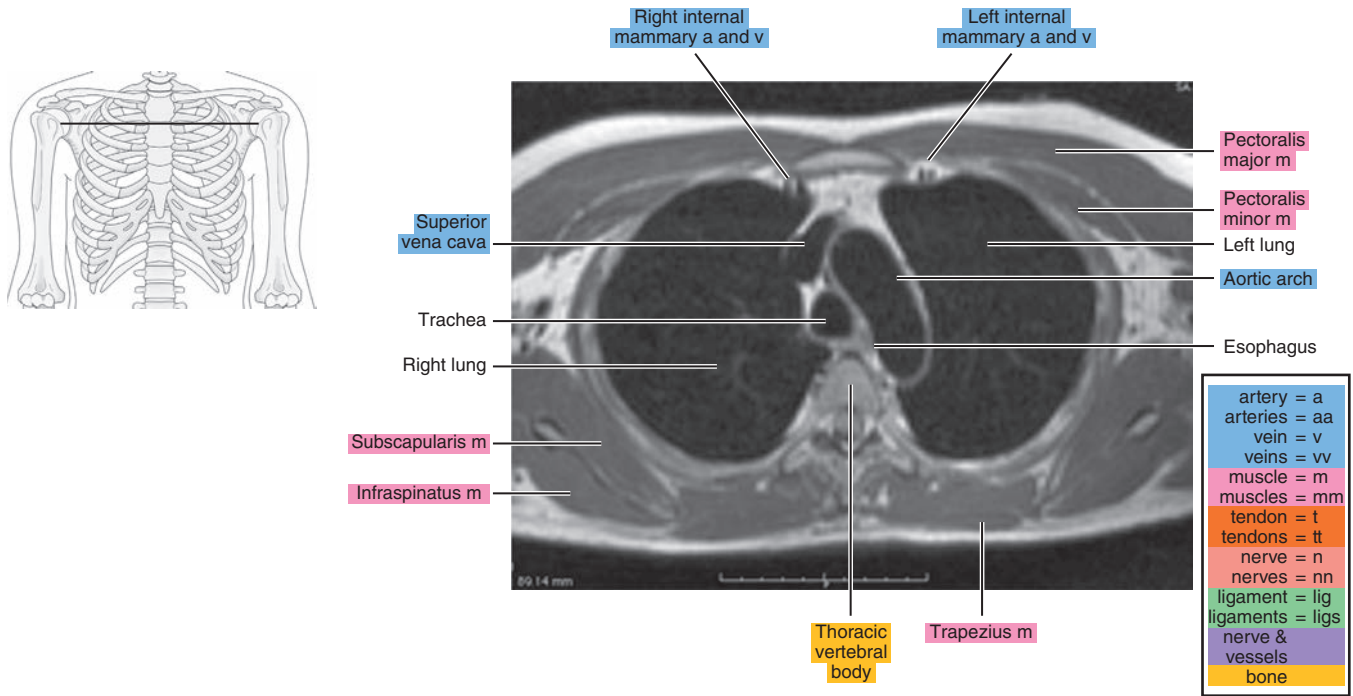


Figure 4.1.2

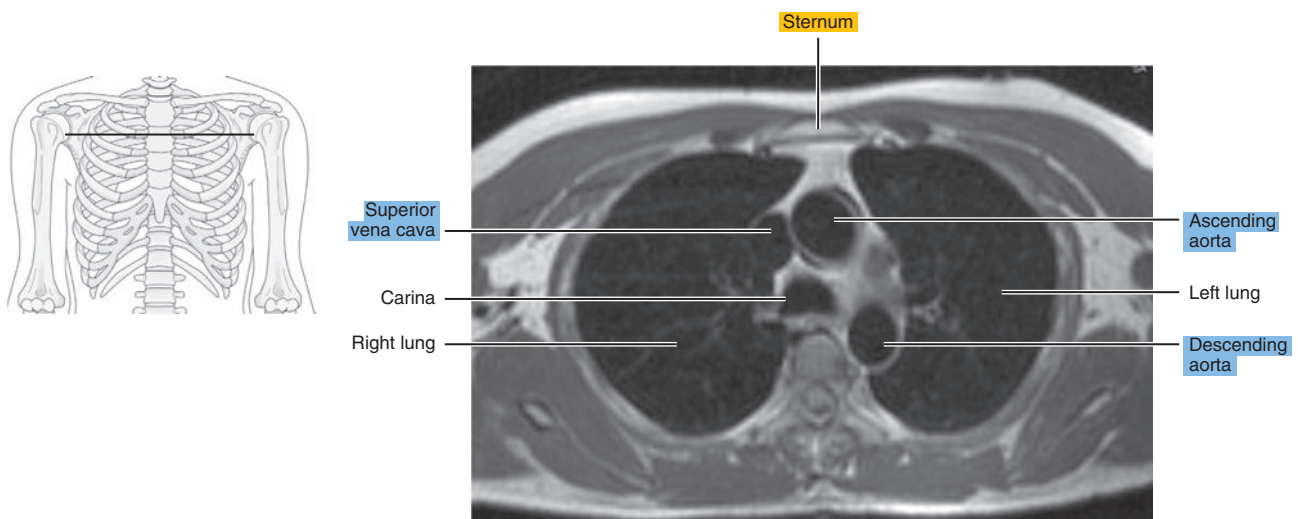


Figure 4.1.3

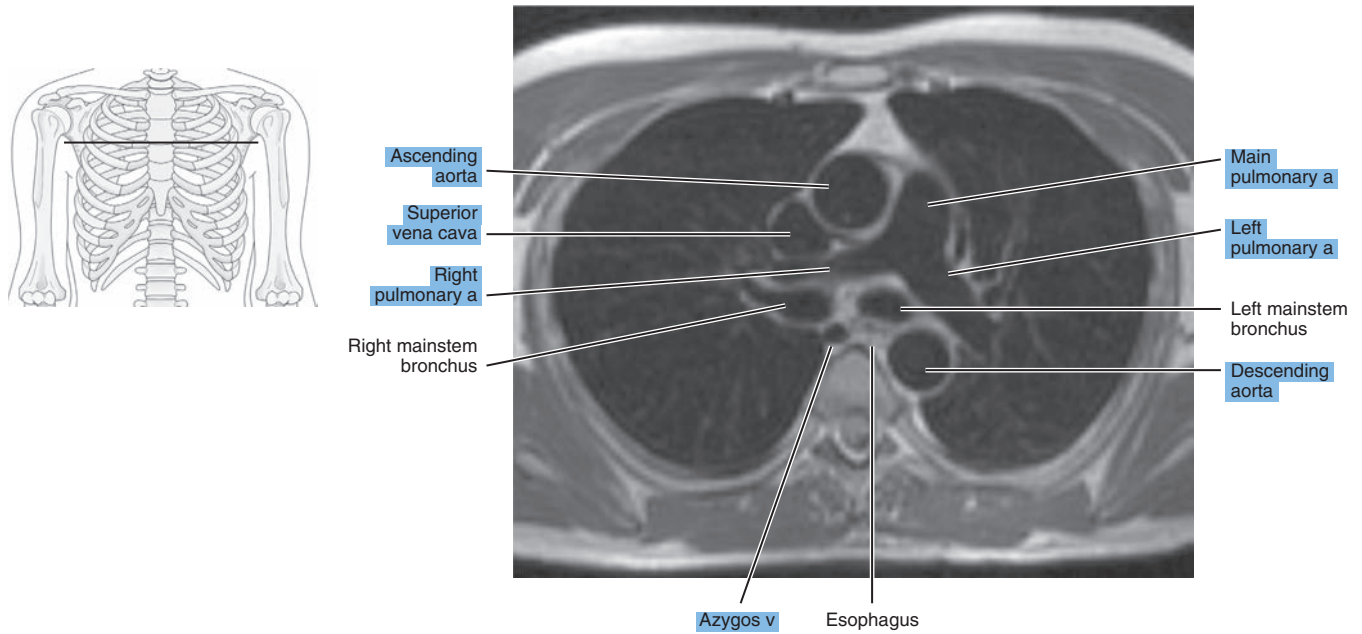


Figure 4.1.4

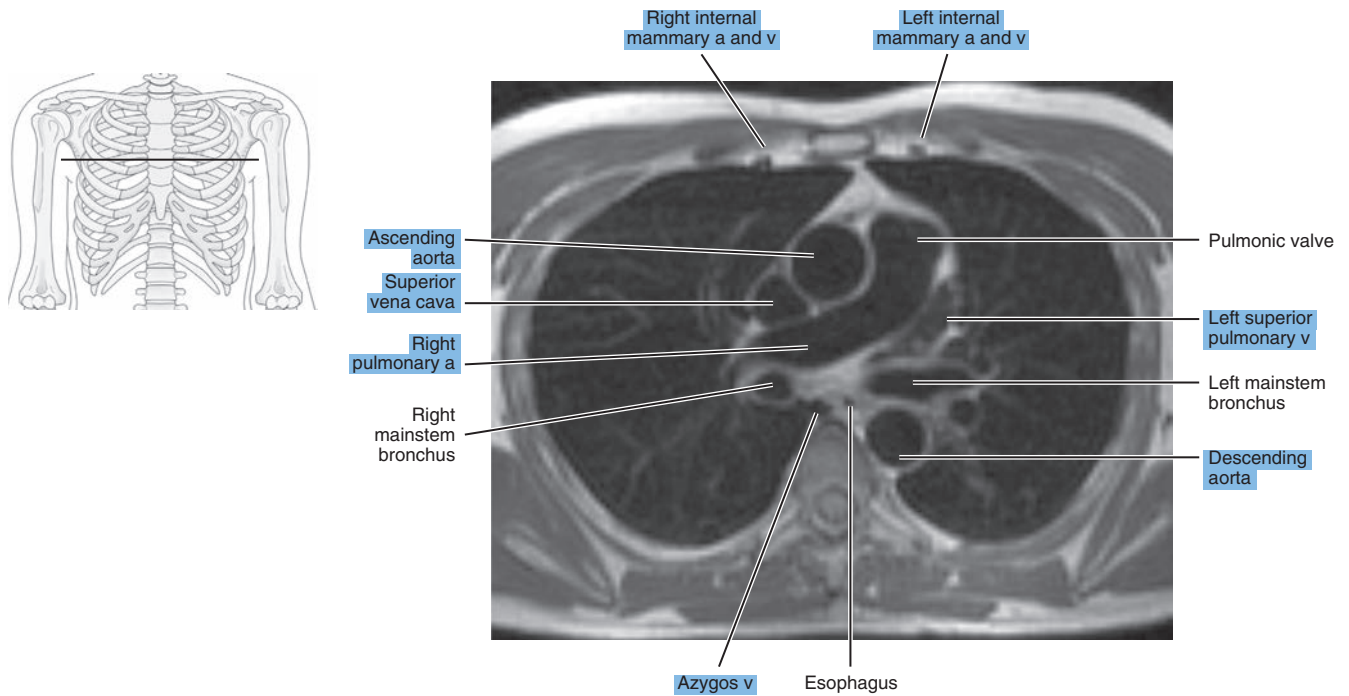


Figure 4.1.5

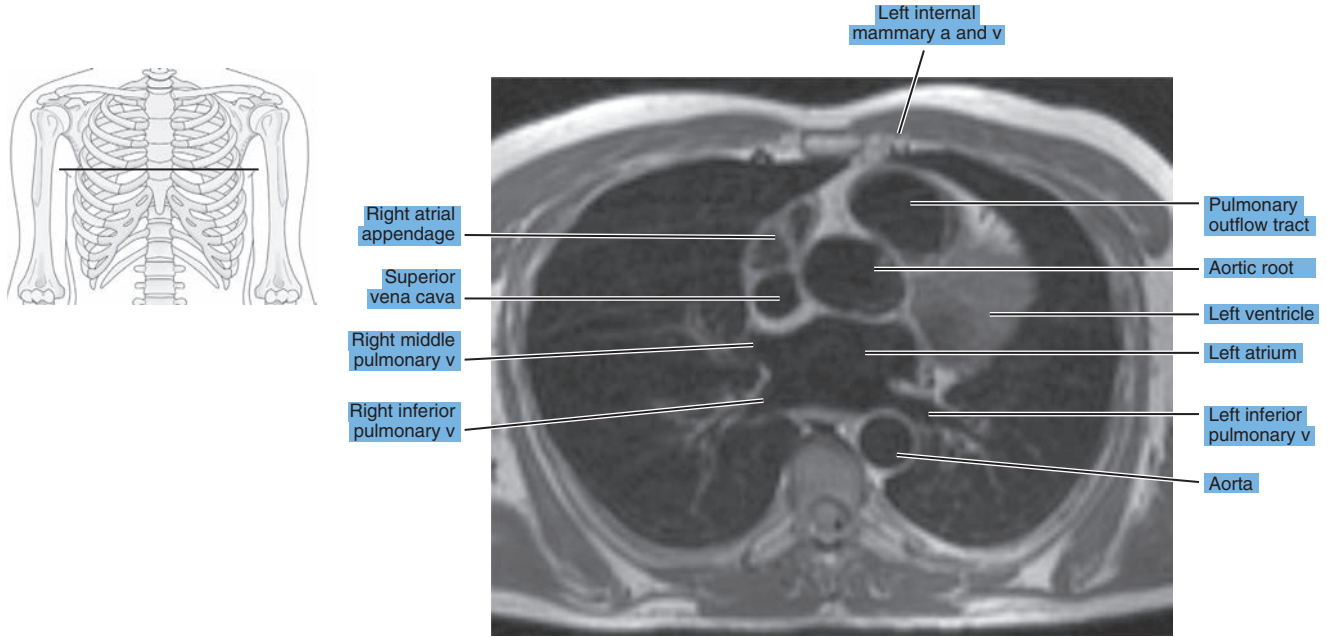


Figure 4.1.6

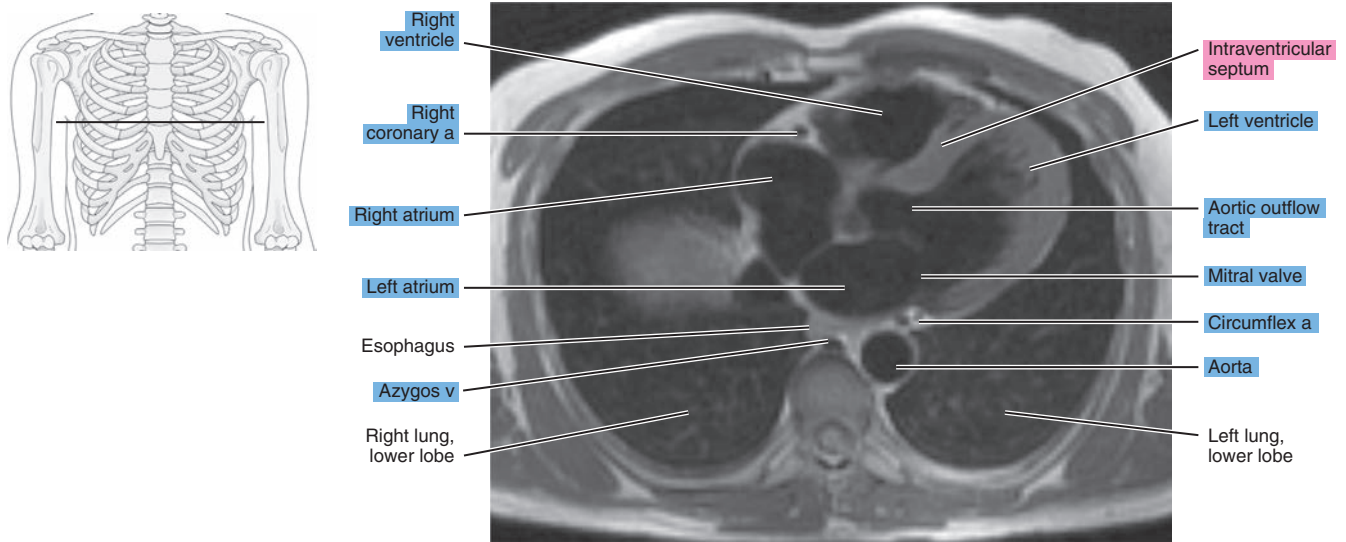
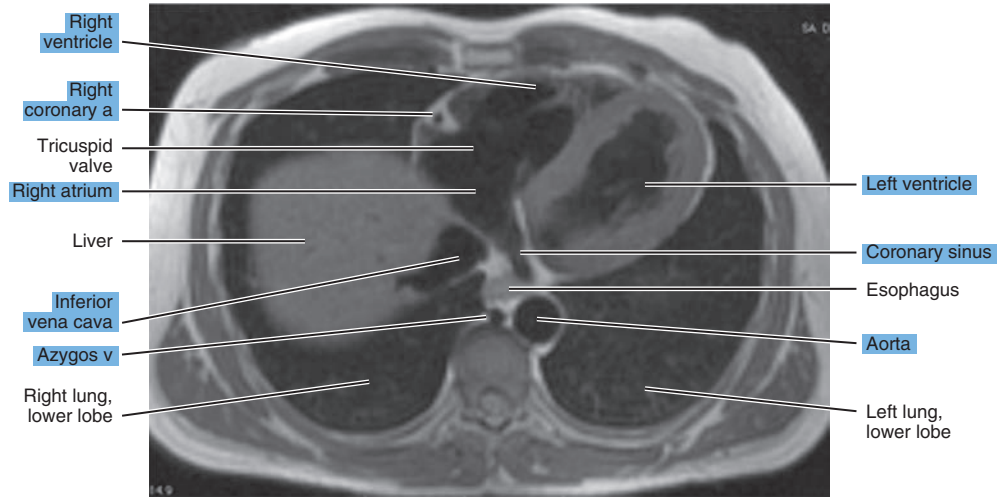
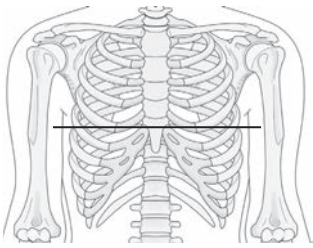


Figure 4.1.7





# SAGITTAL

Figure 4.2.1

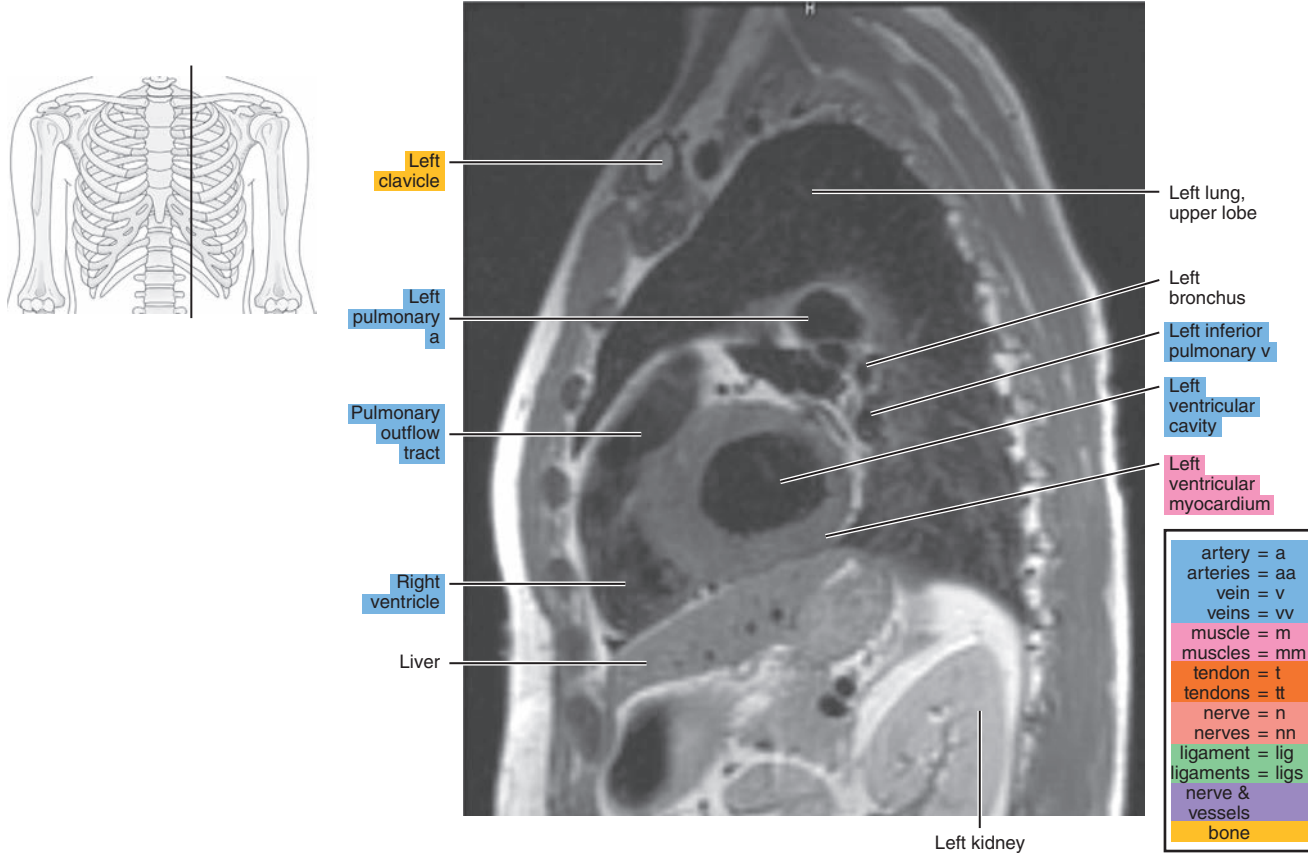


Figure 4.2.2

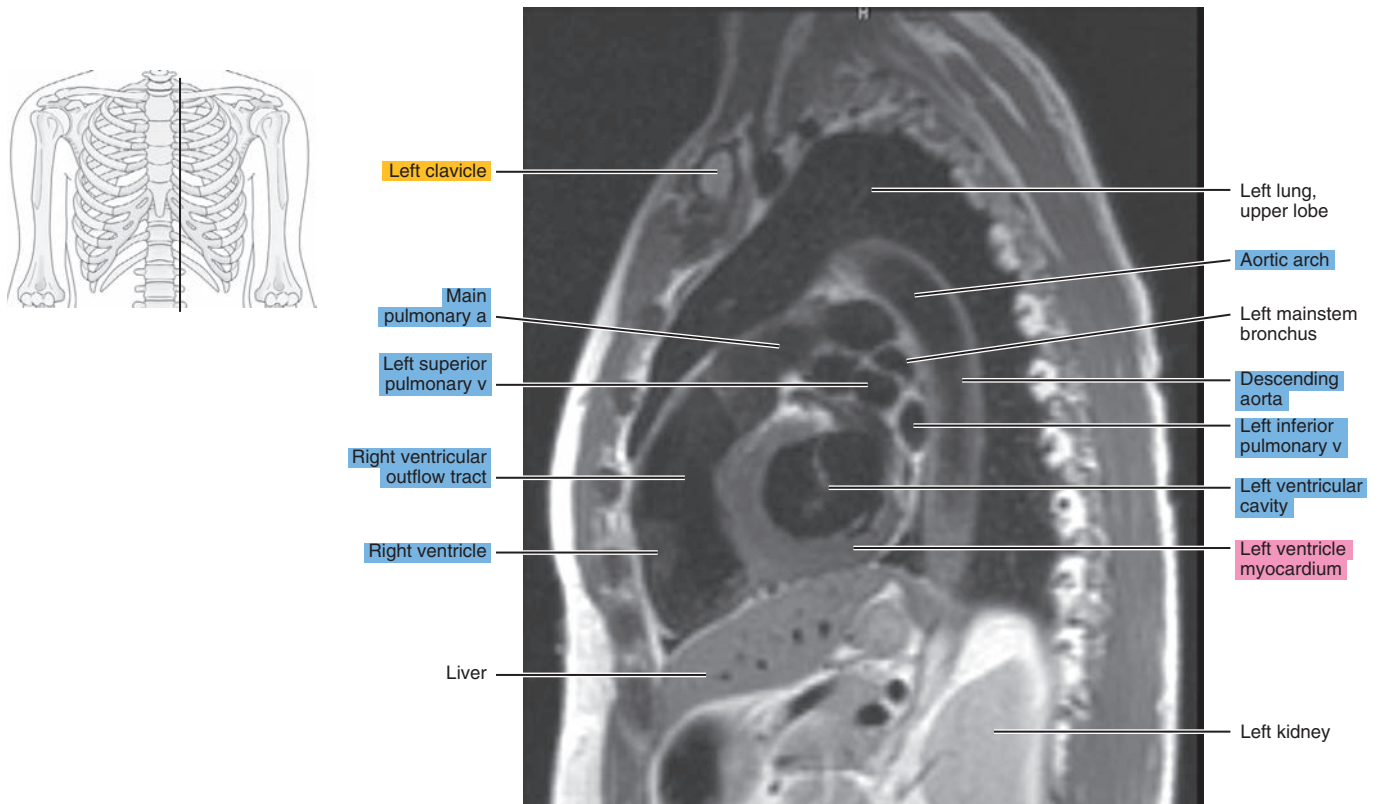




Figure 4.2.3

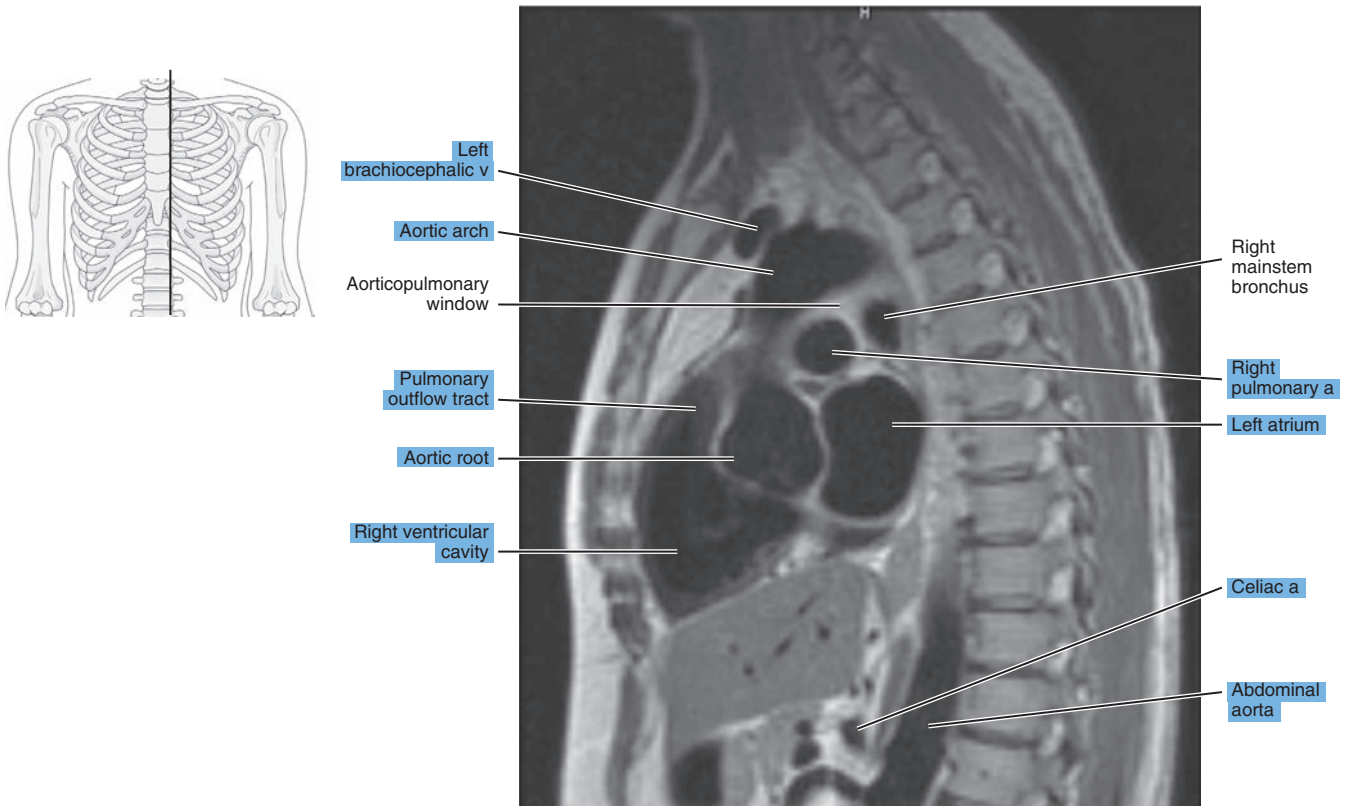


Figure 4.2.4

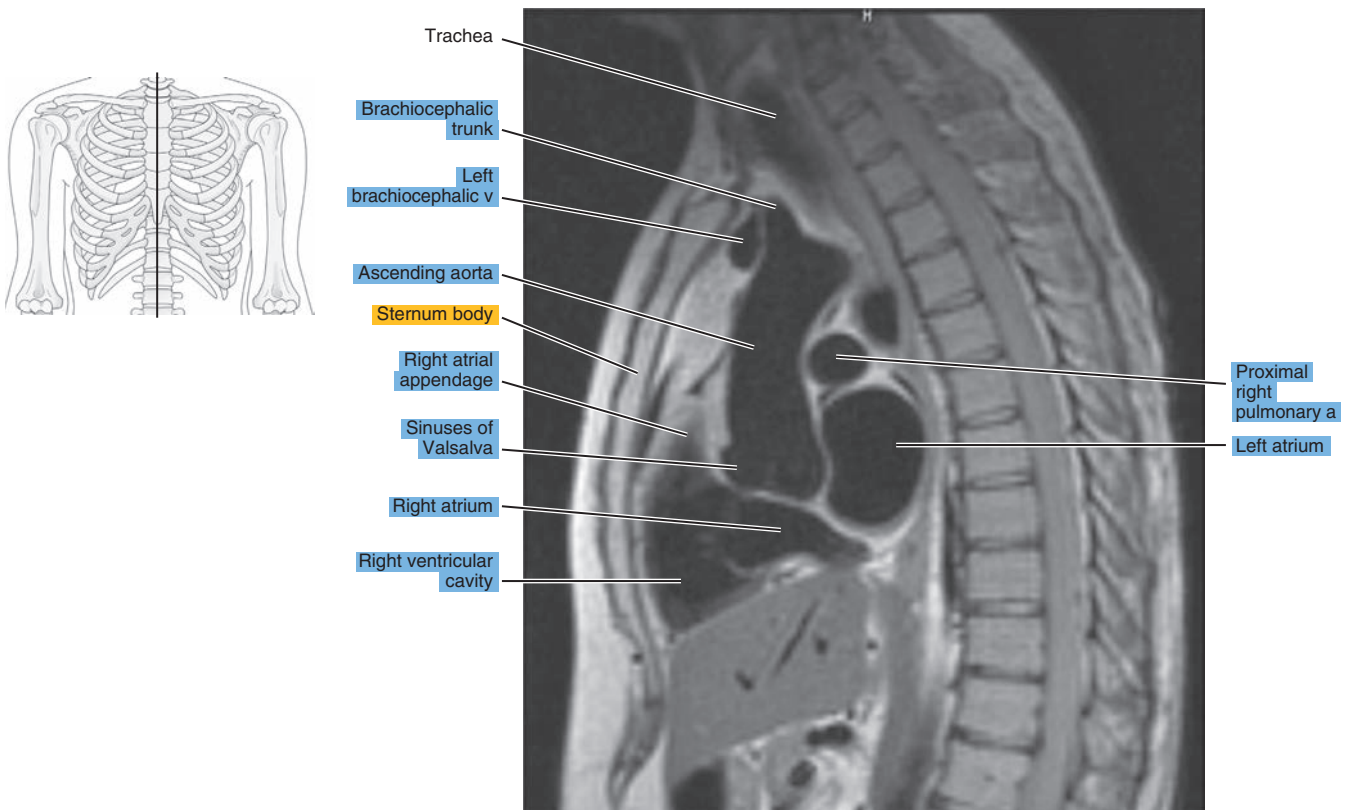
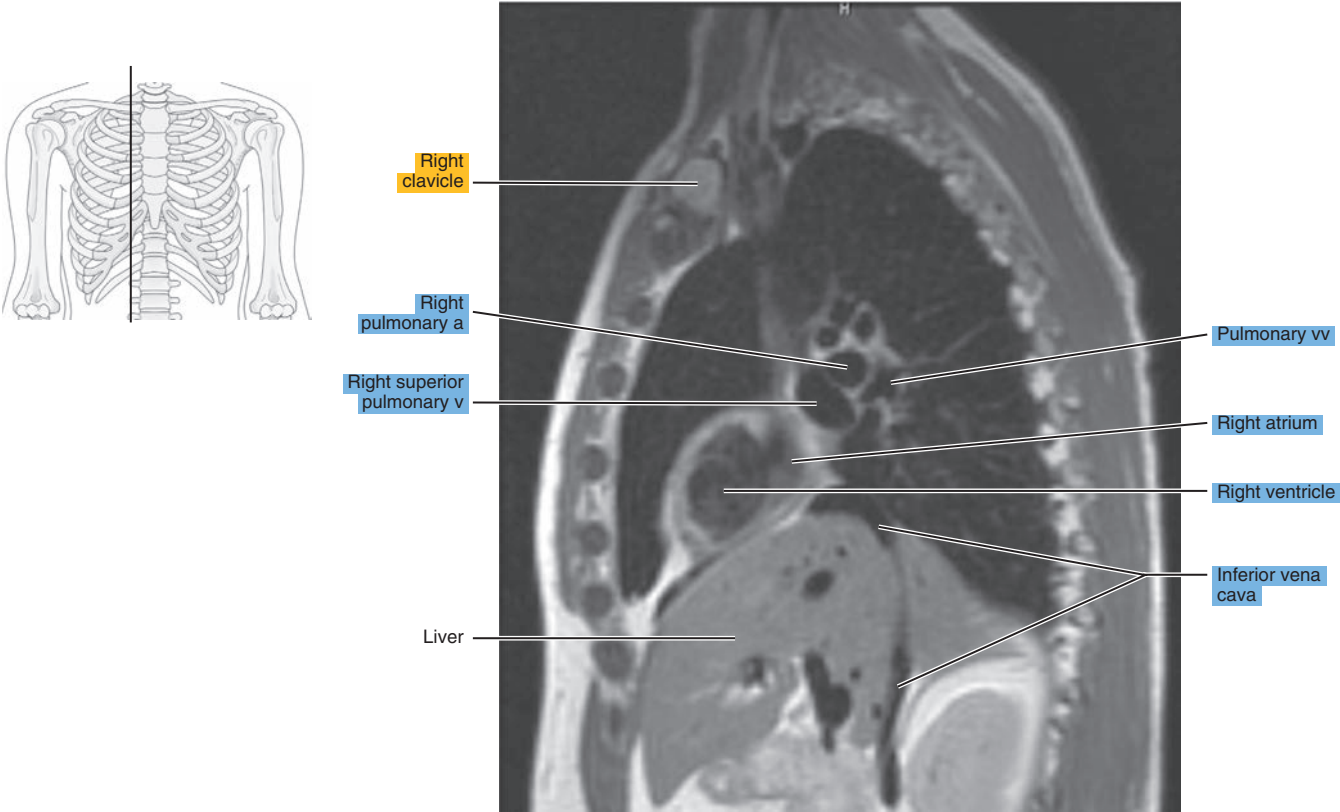


Figure 4.2.5



# CORONAL

Figure 4.3.1

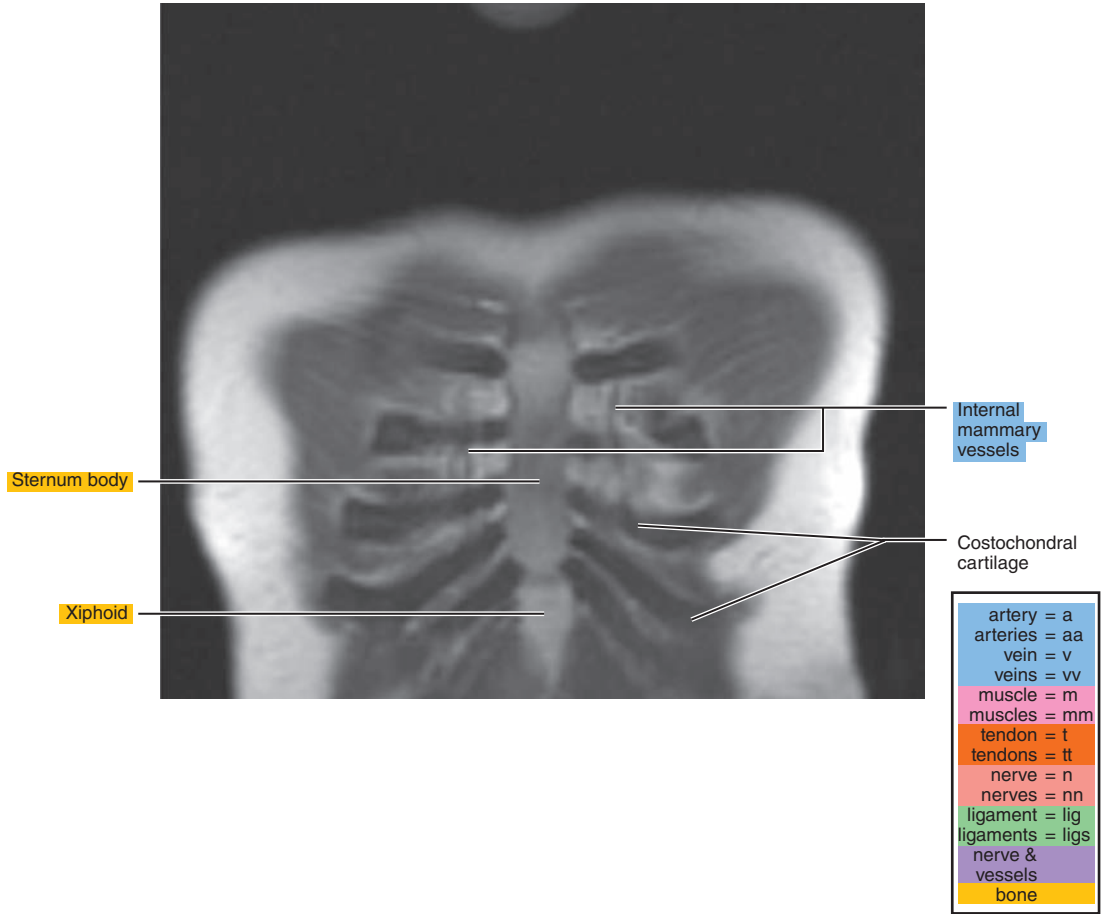
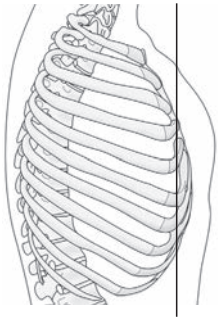


Figure 4.3.2

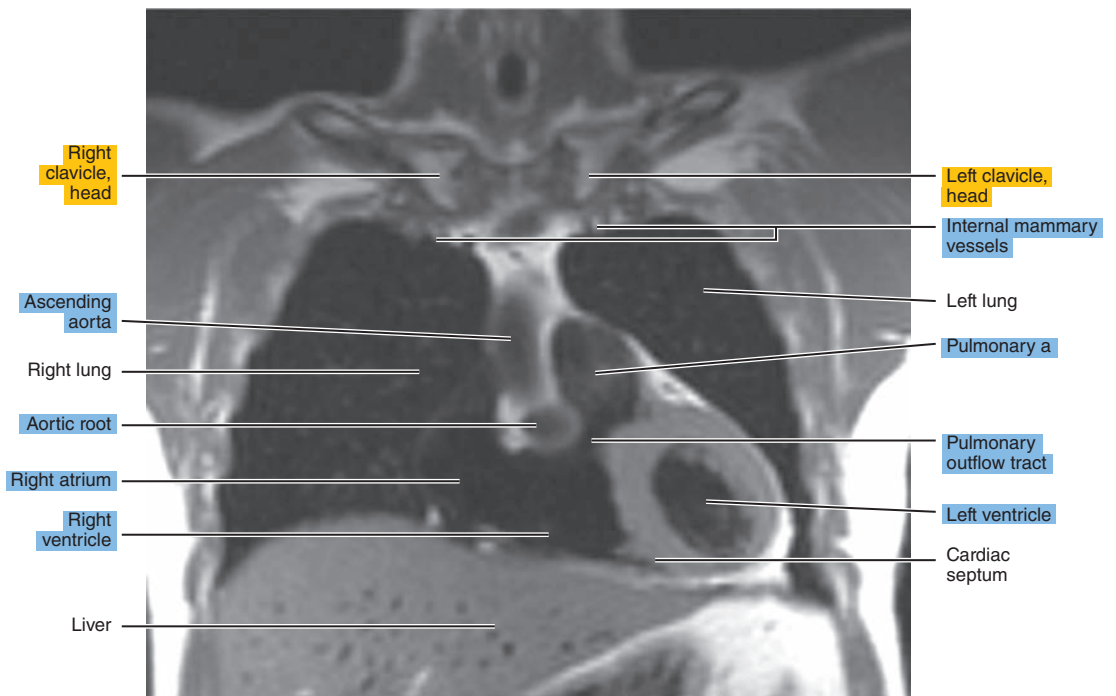
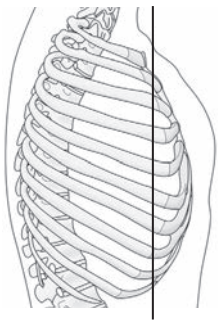


Figure 4.3.3

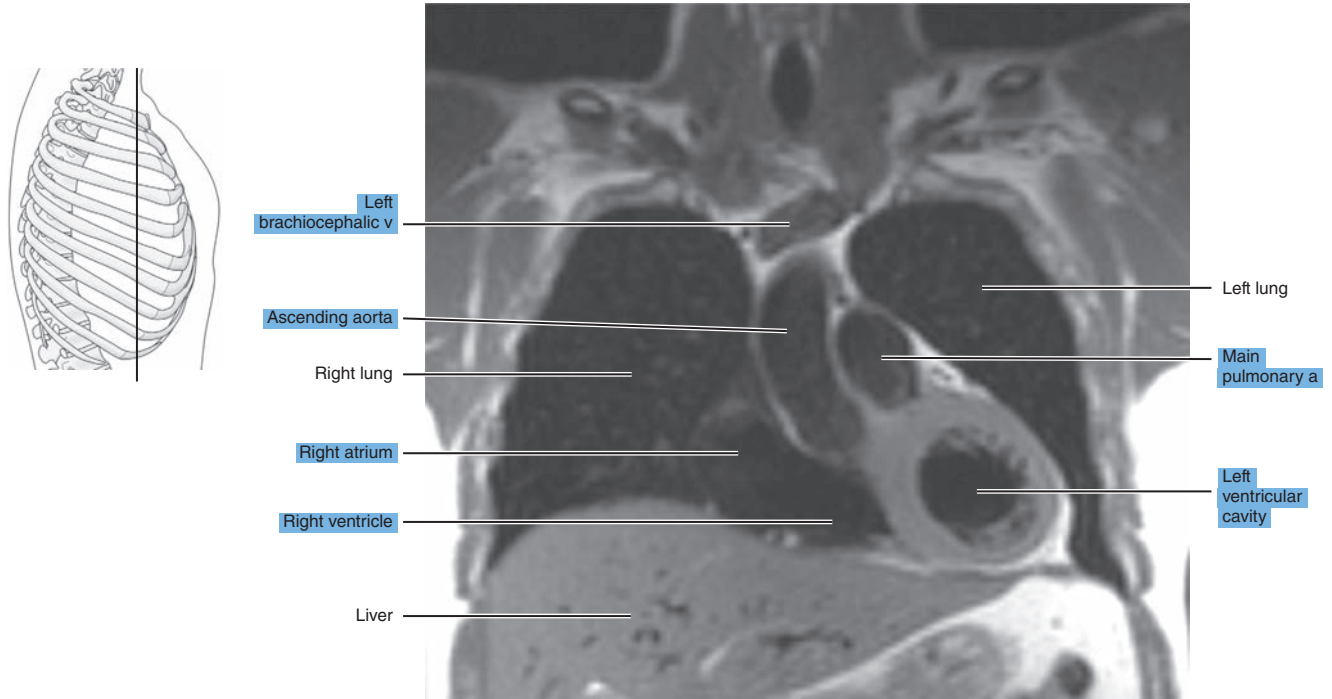


Figure 4.3.4

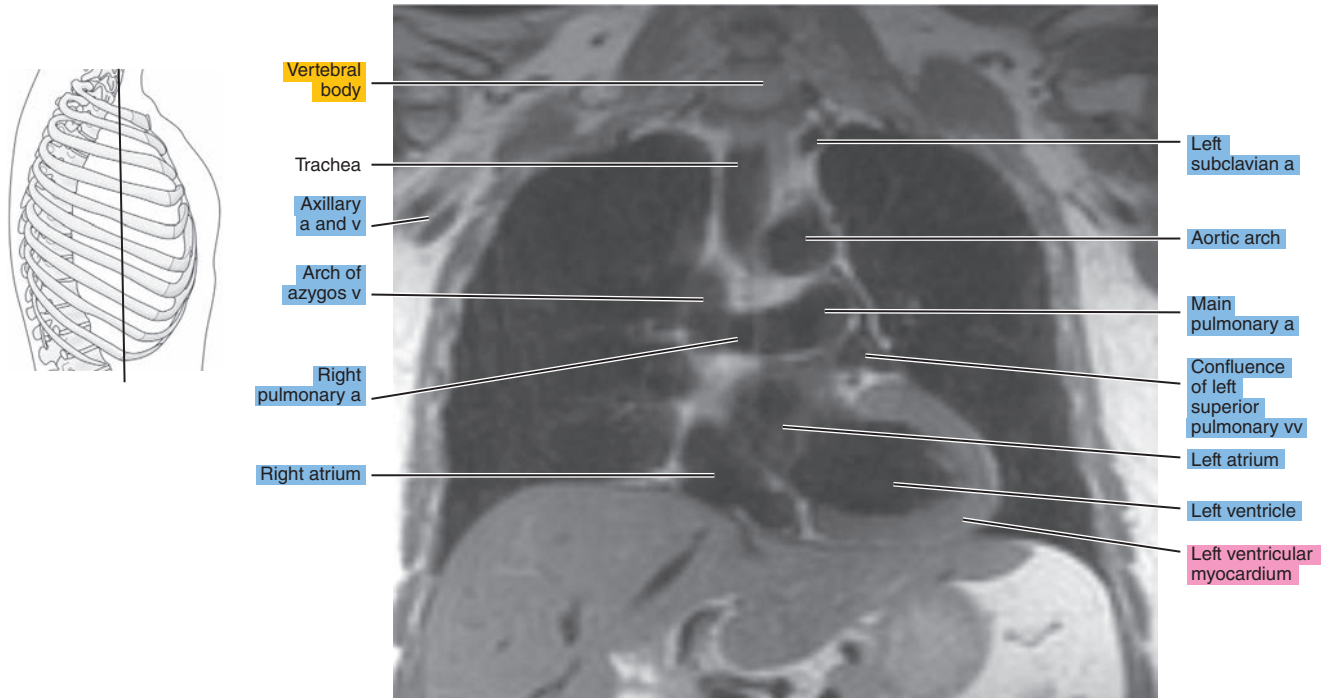
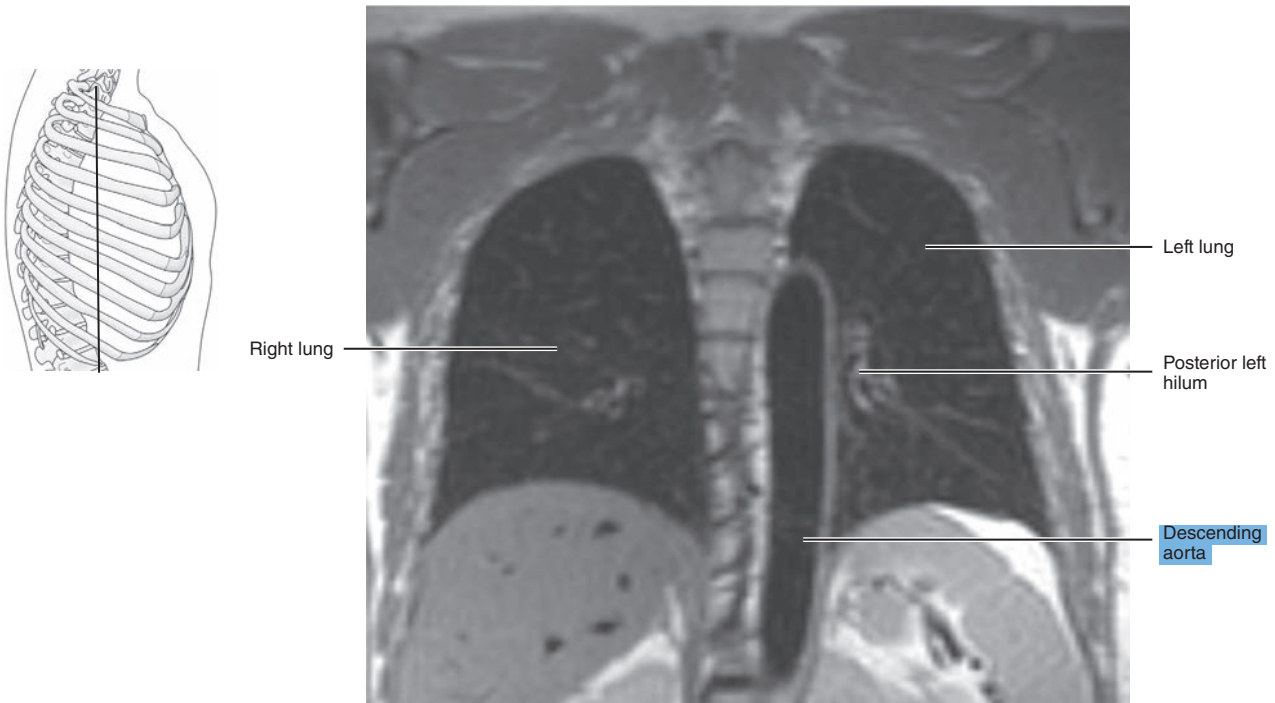


Figure 4.3.5





*Chapter*  
**5**

**MRI of the Pectoral Girdle  
and Chest Wall**

# AXIAL

Figure 5.1.1

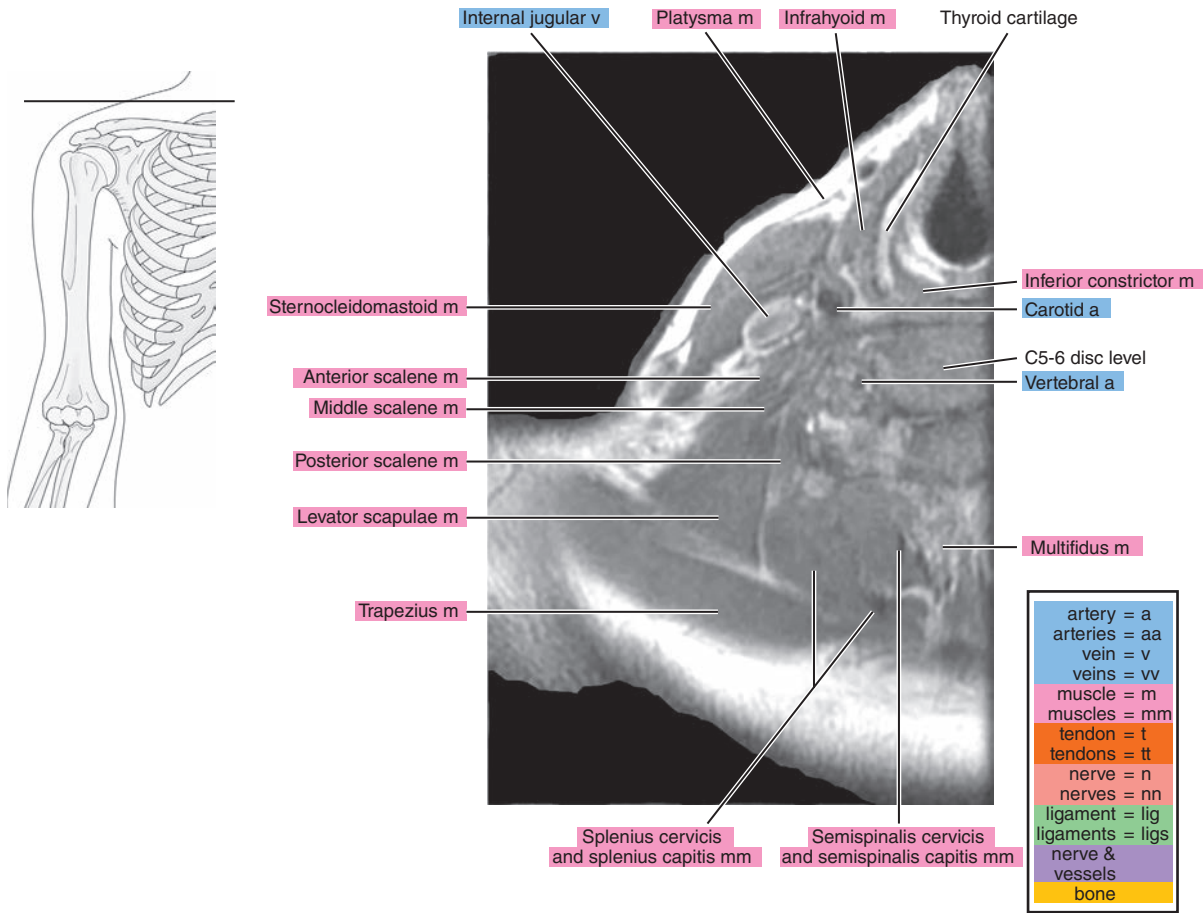


Figure 5.1.2

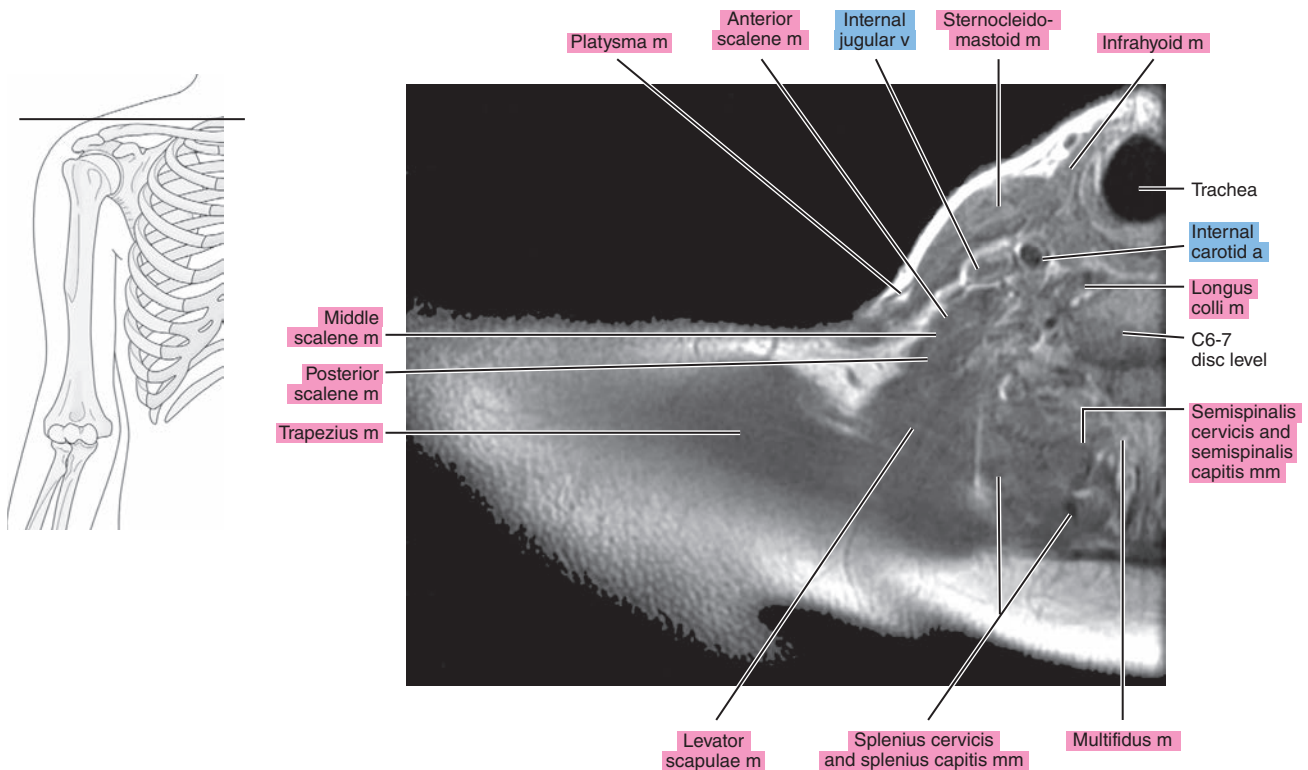


Figure 5.1.3

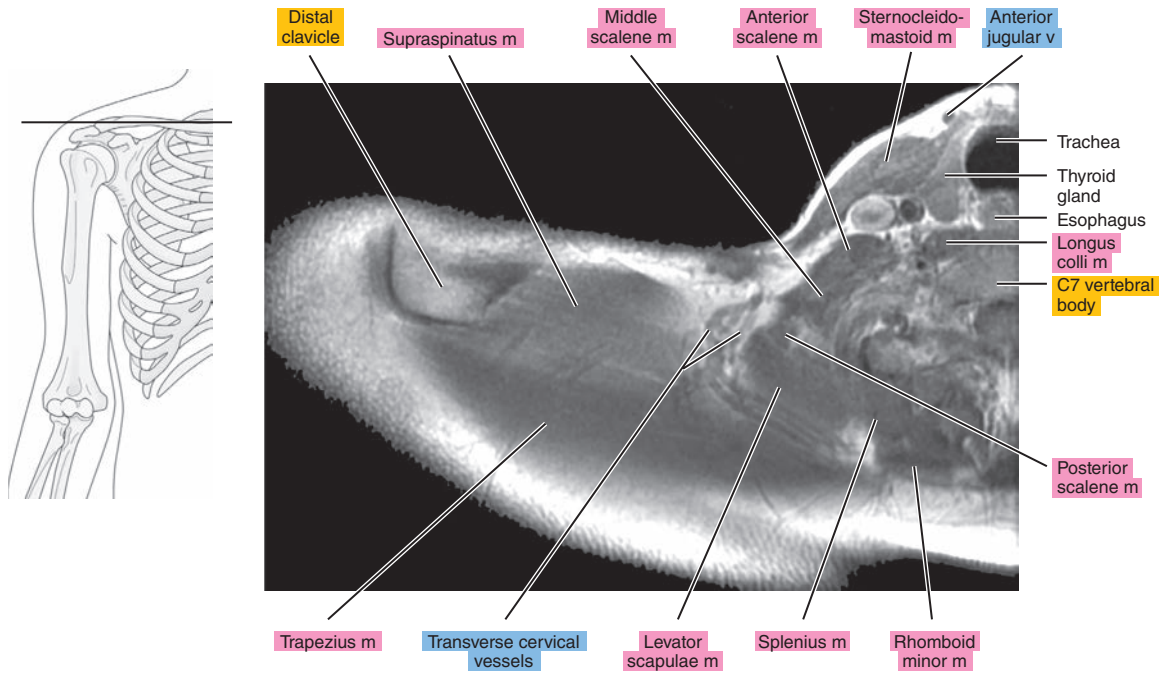


Figure 5.1.4

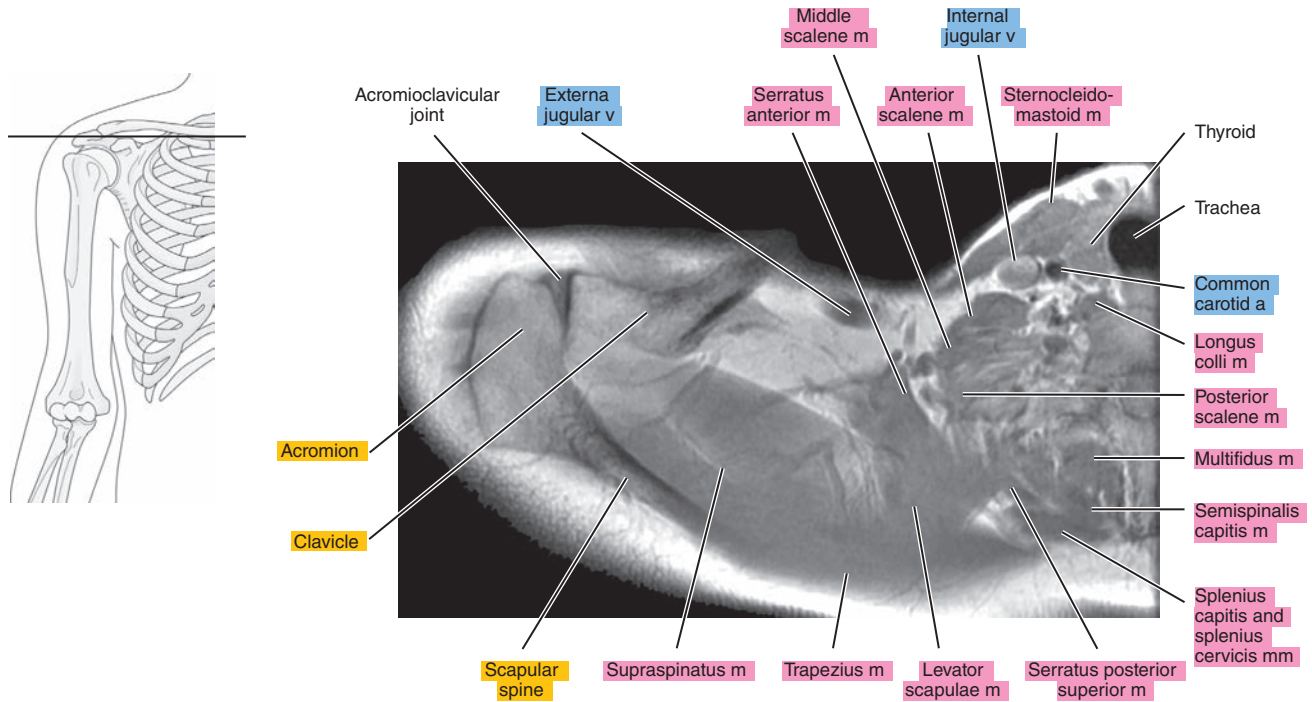


Figure 5.1.5

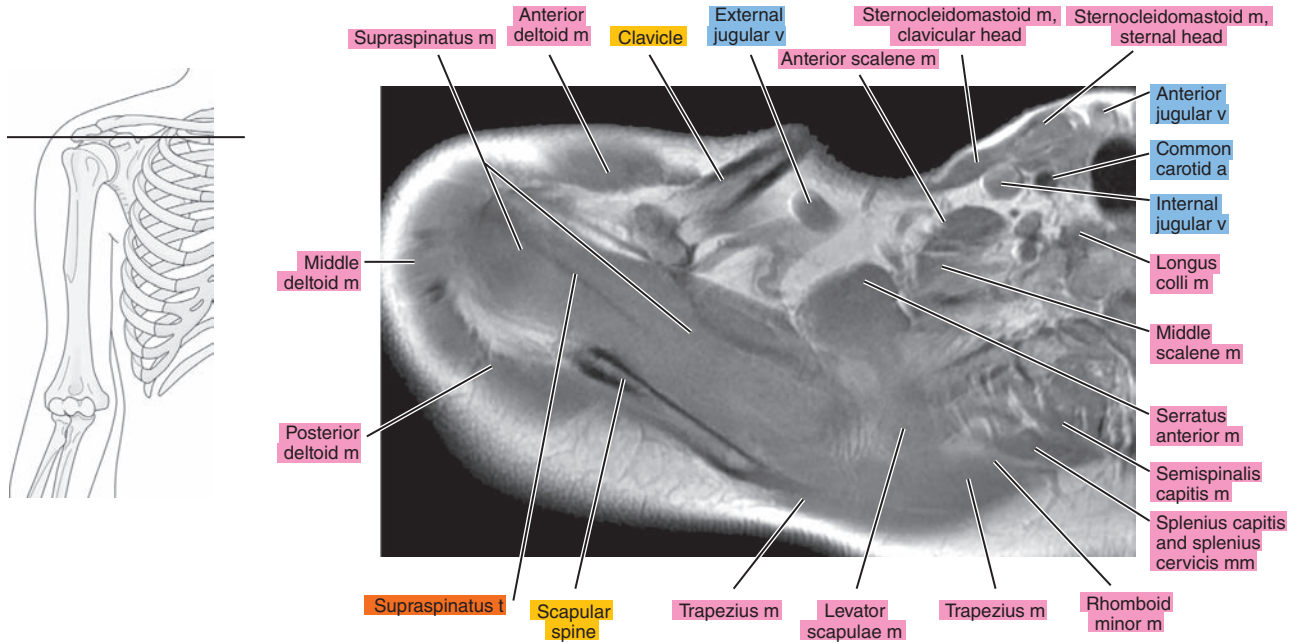


Figure 5.1.6

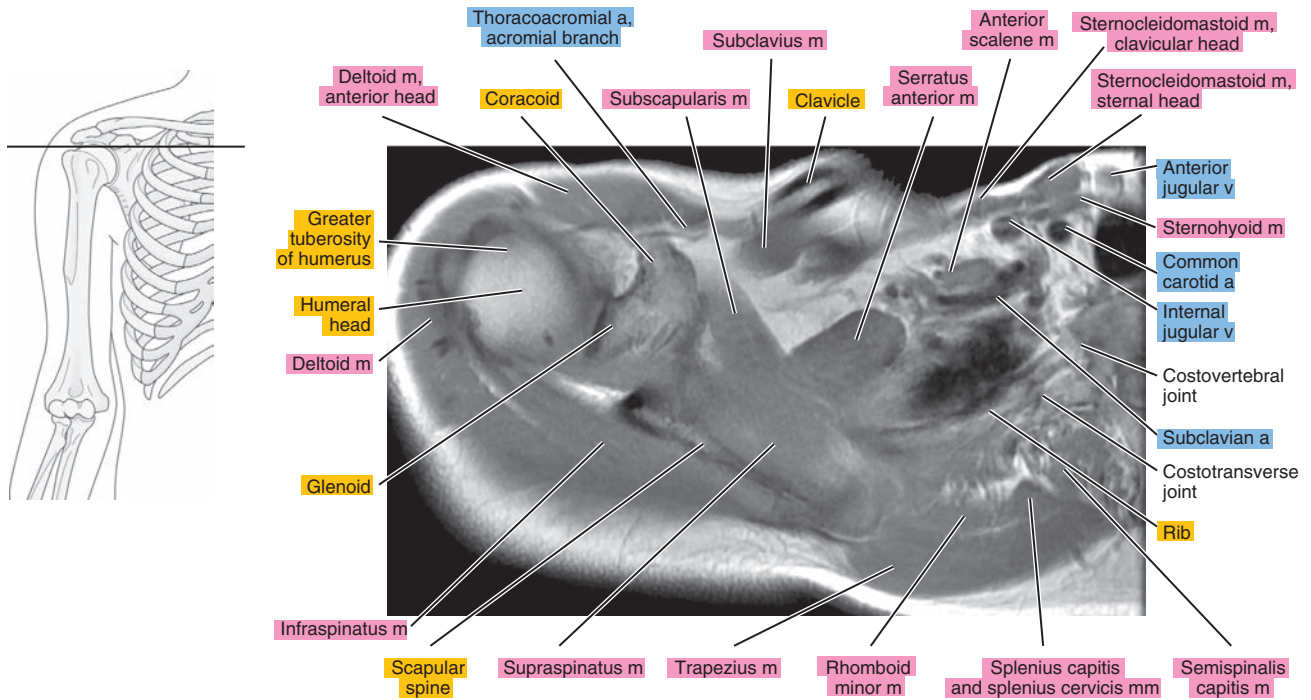




Figure 5.1.7

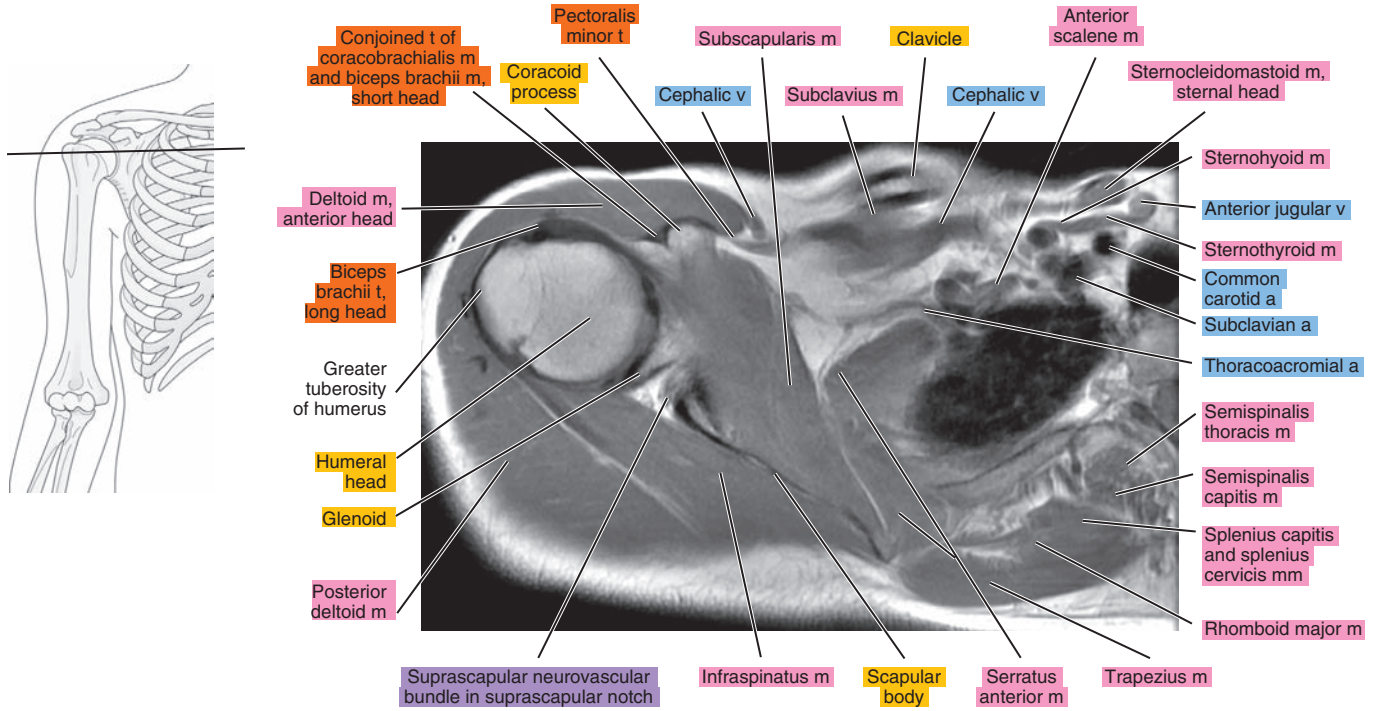


Figure 5.1.8

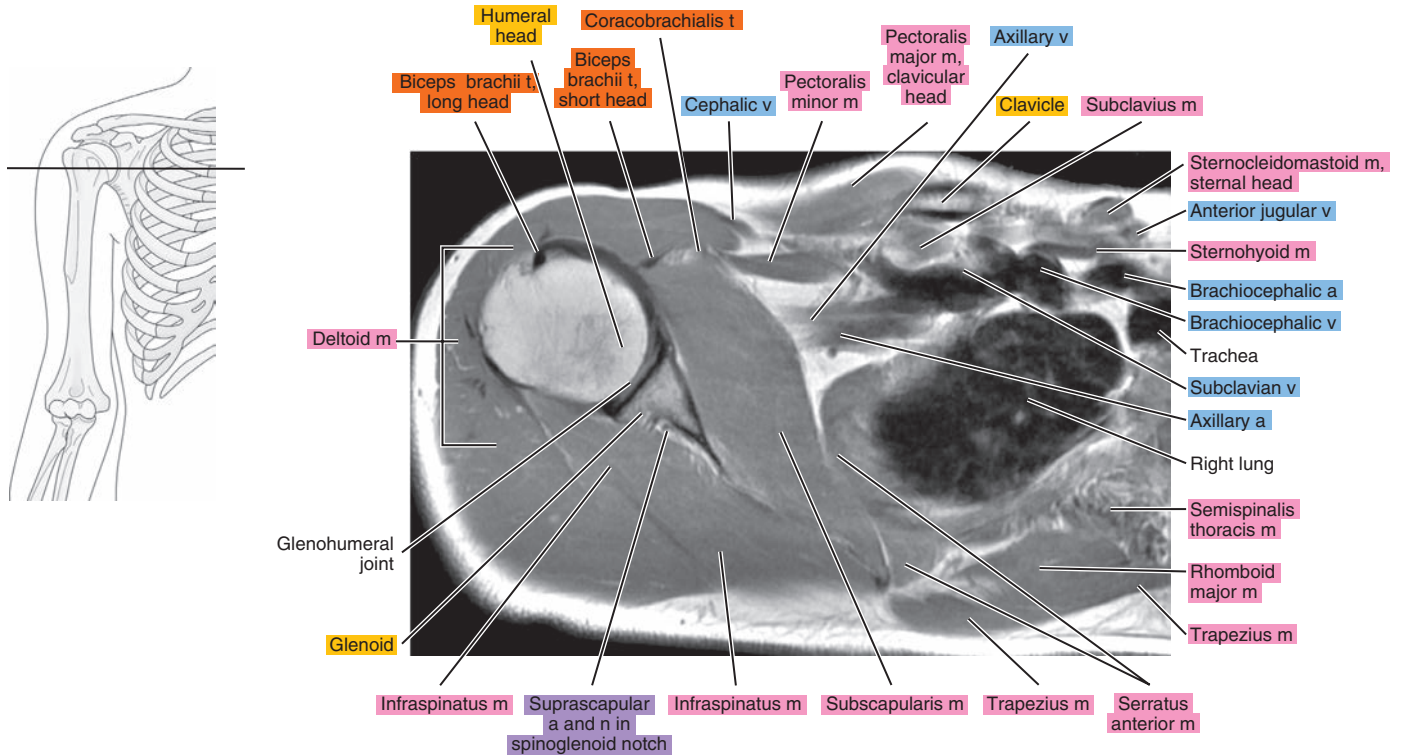




Figure 5.1.9

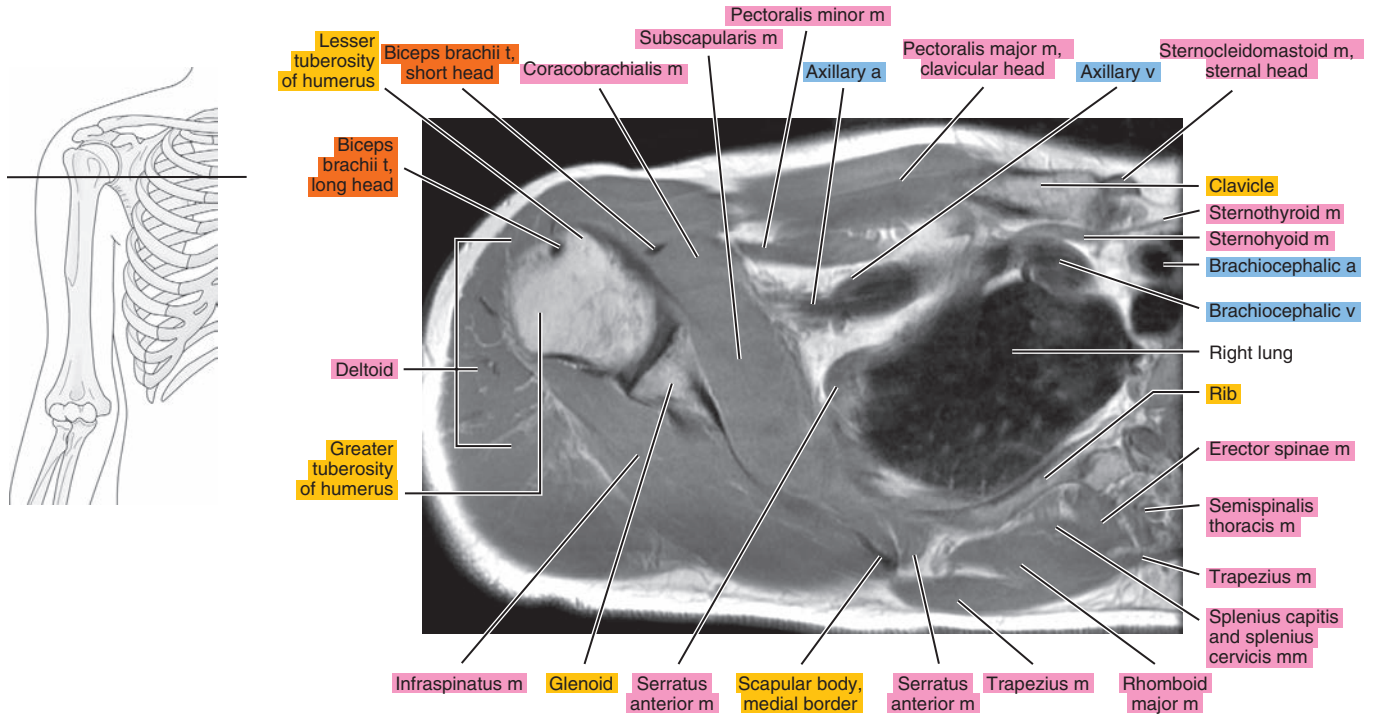


Figure 5.1.10

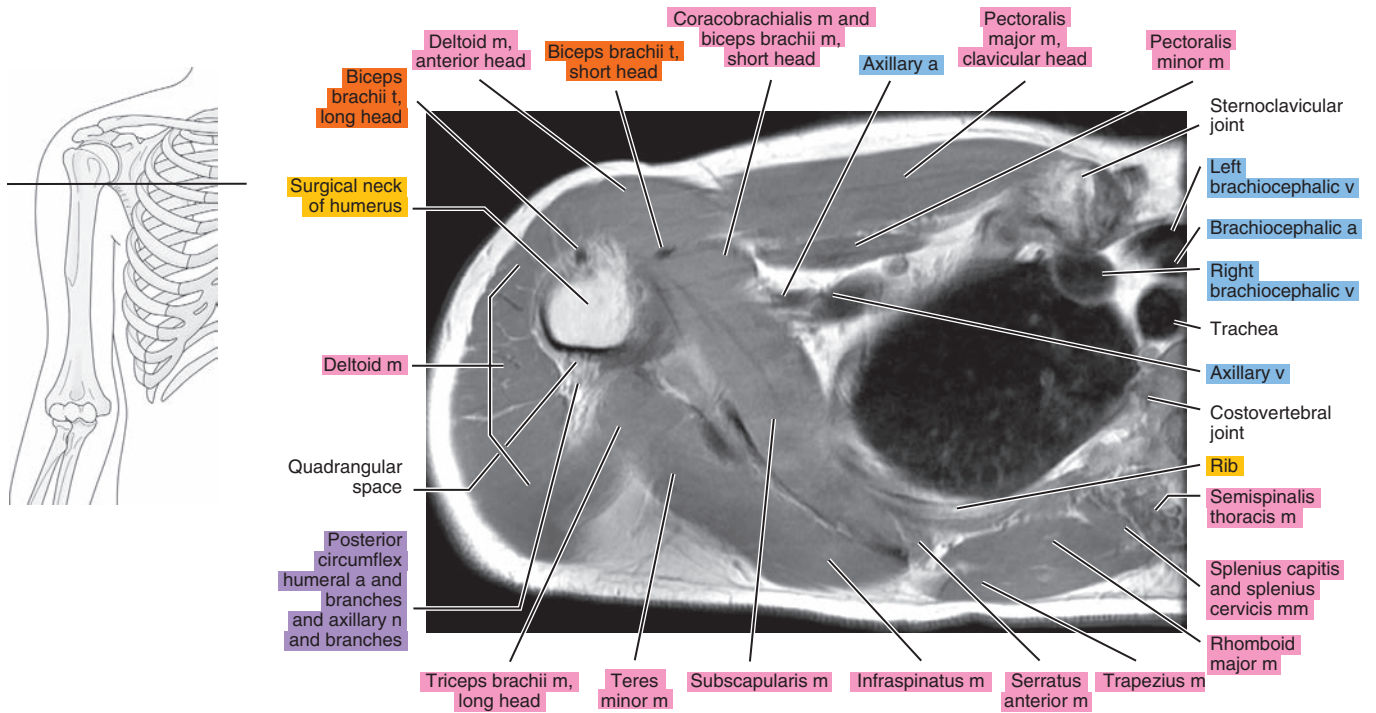


Figure 5.1.11

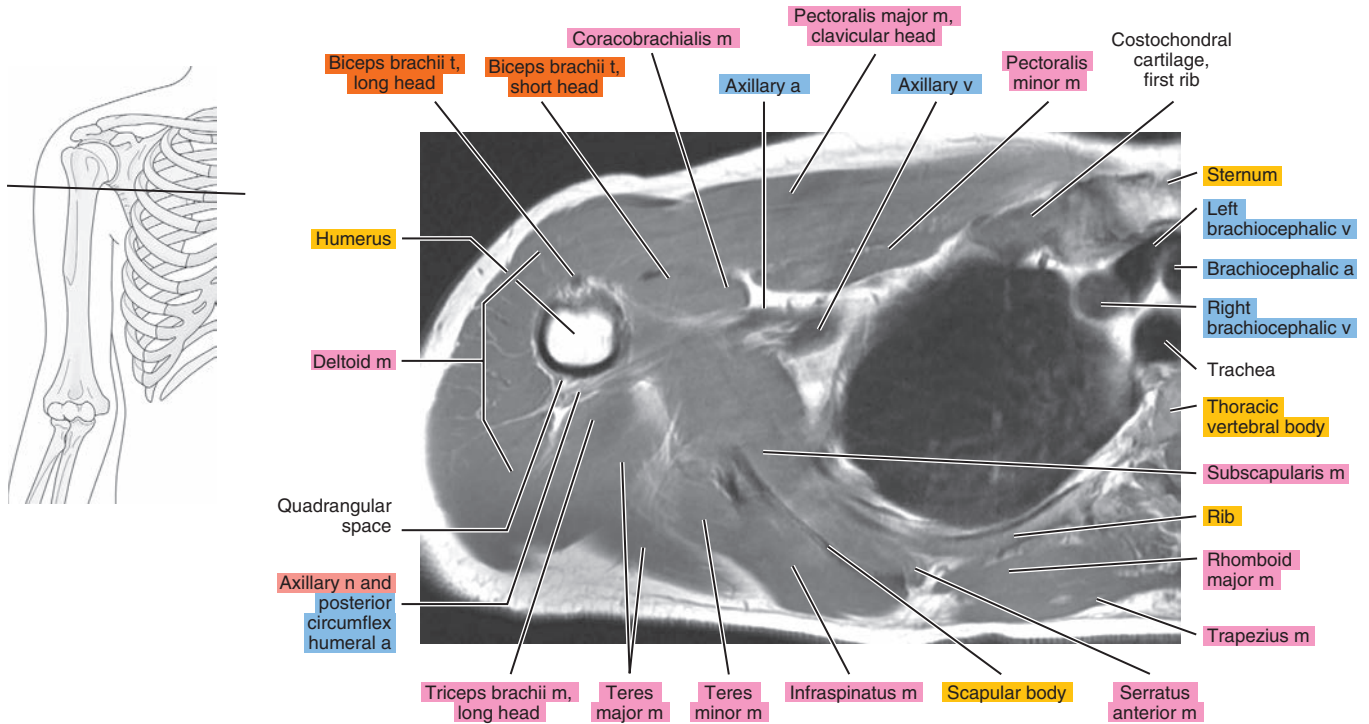


Figure 5.1.12

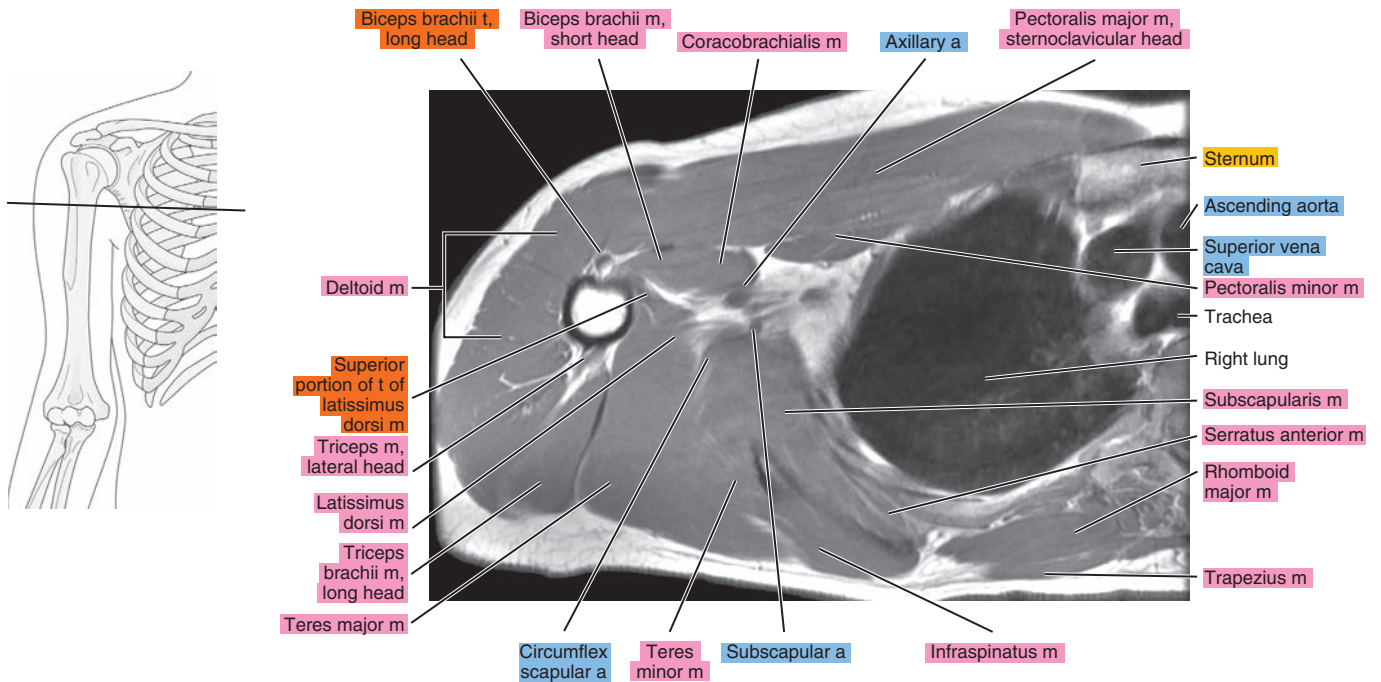


Figure 5.1.13

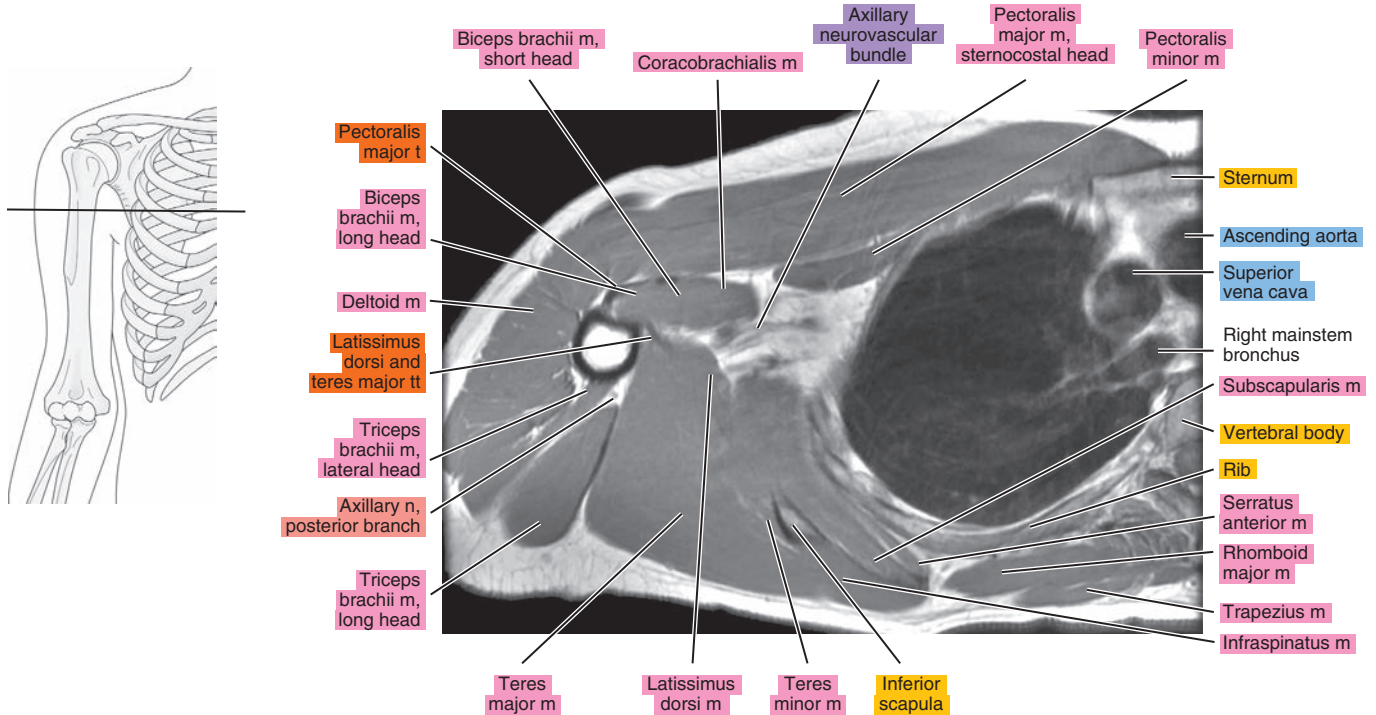


Figure 5.1.14

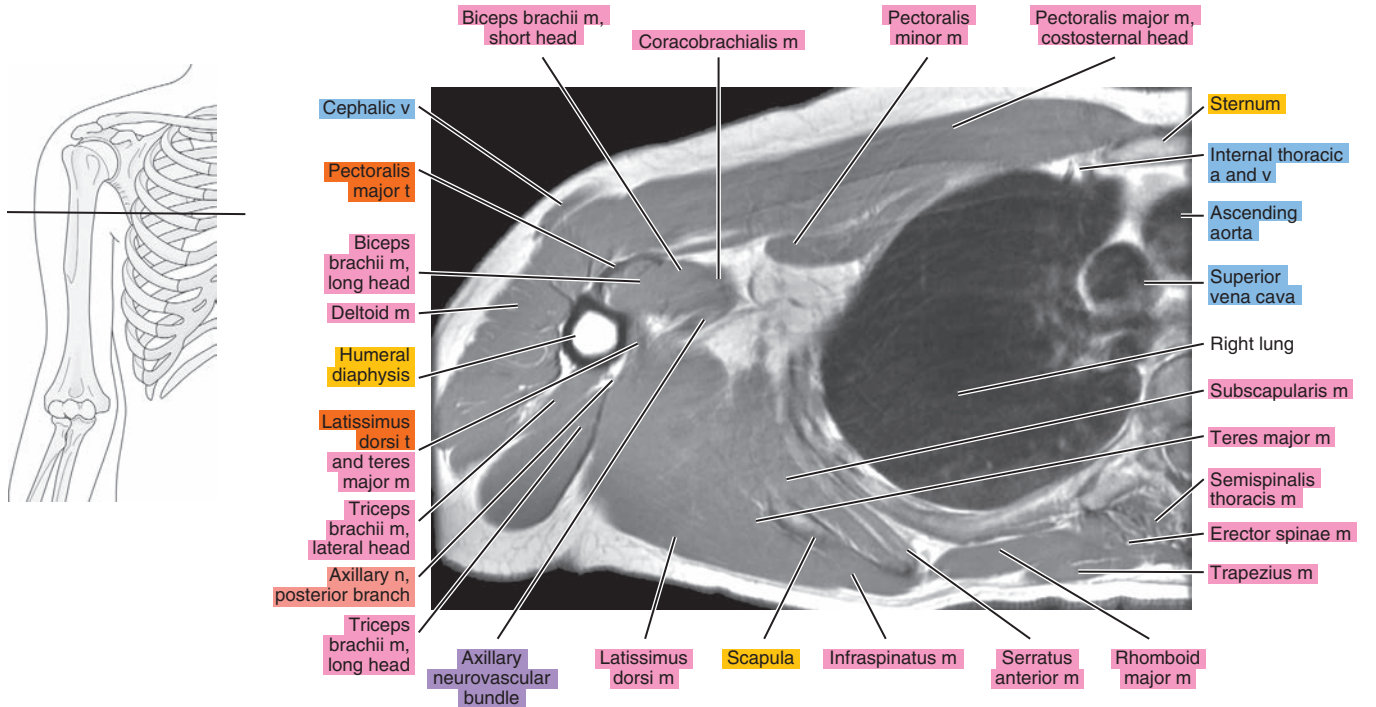




Figure 5.1.15

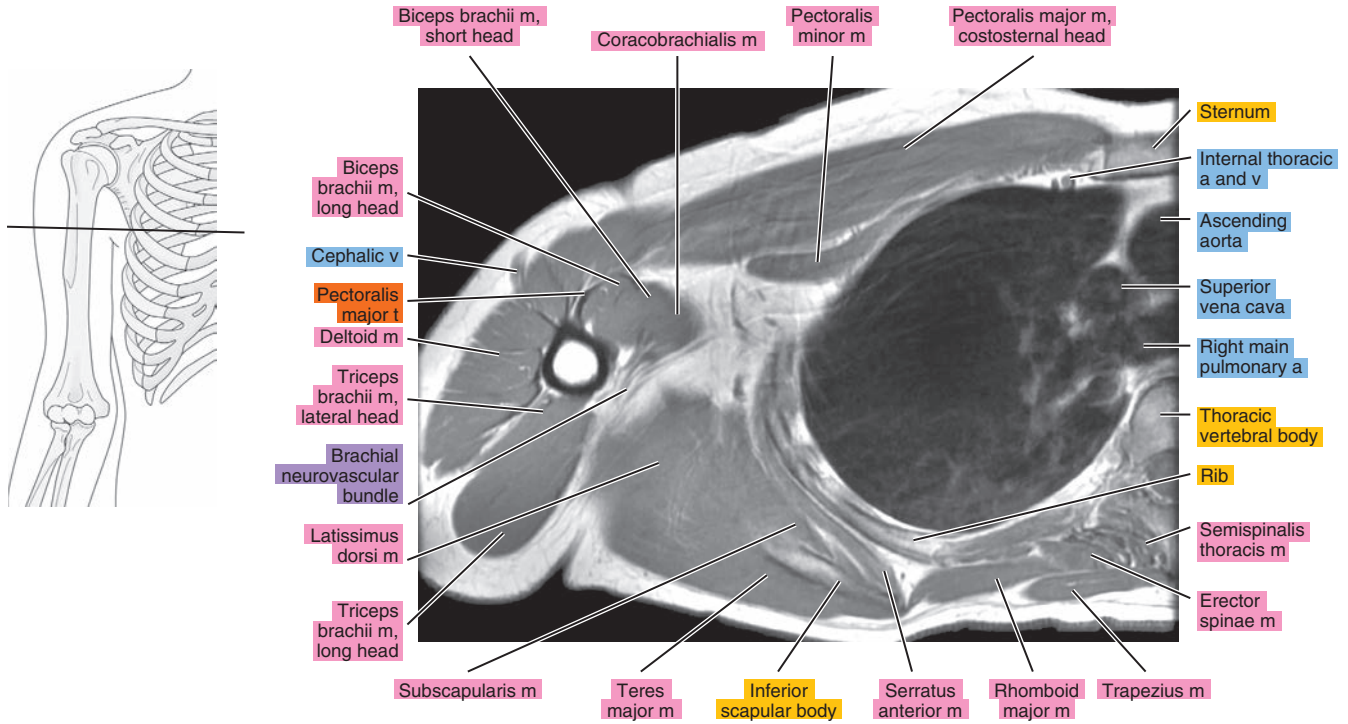


Figure 5.1.16

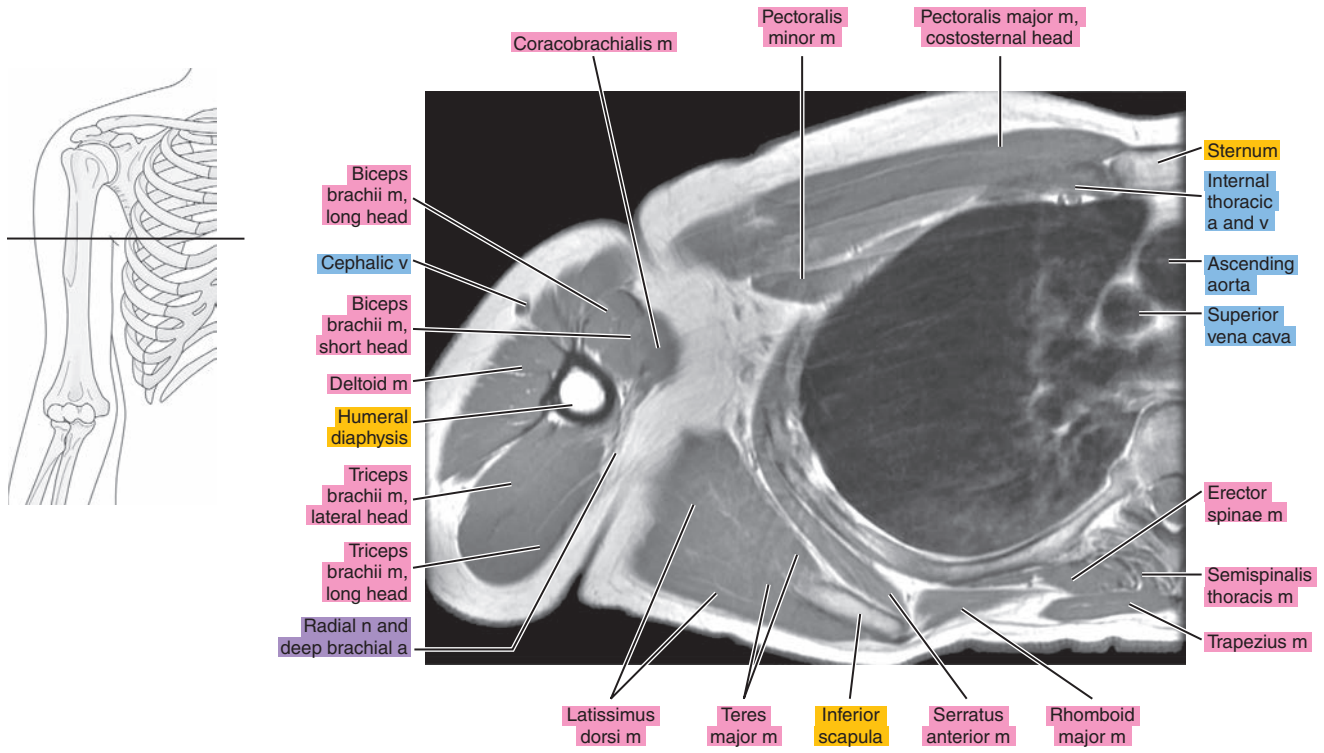


Figure 5.1.17

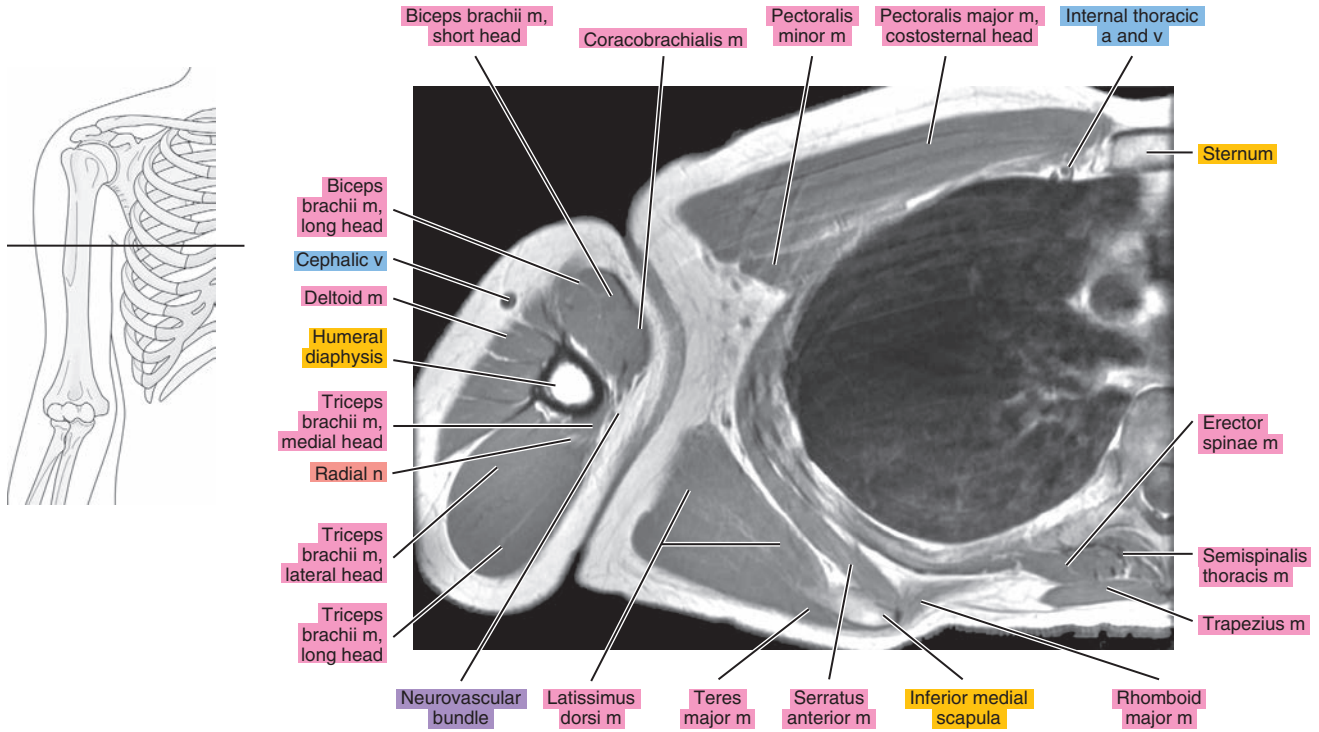


Figure 5.1.18

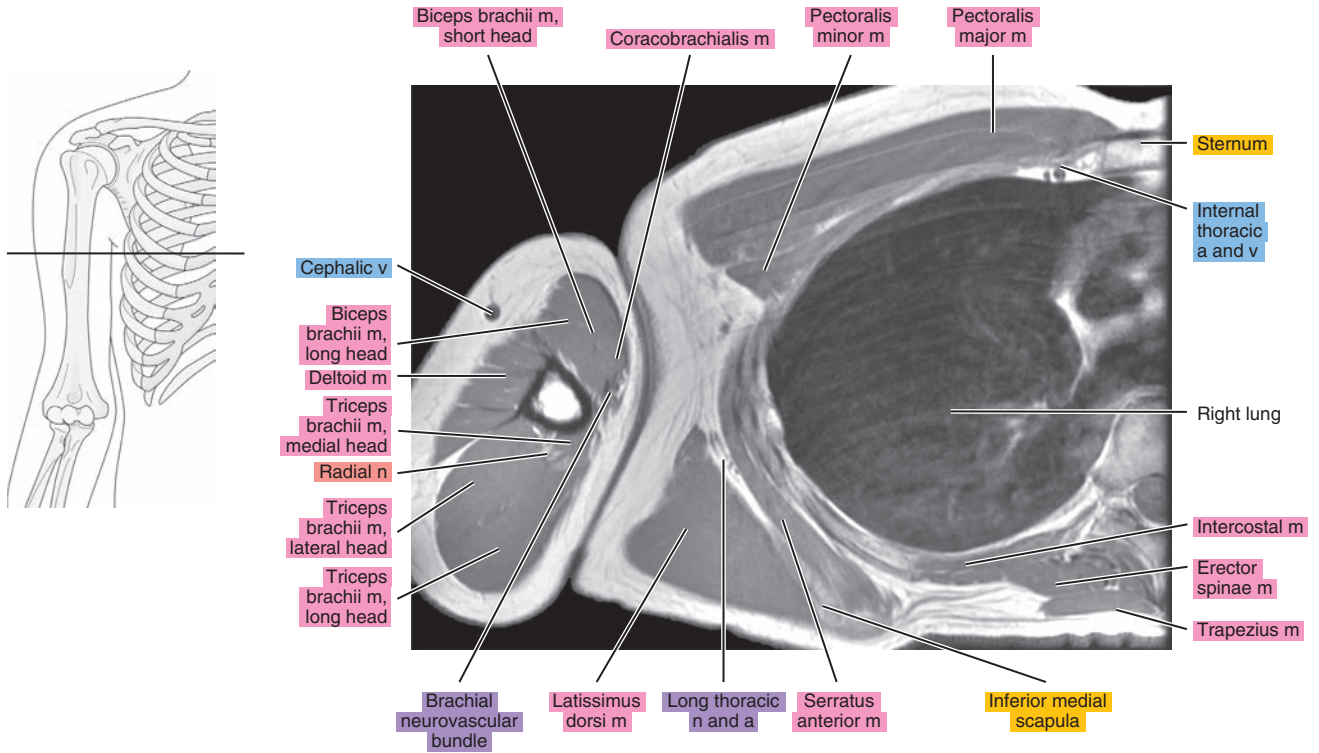
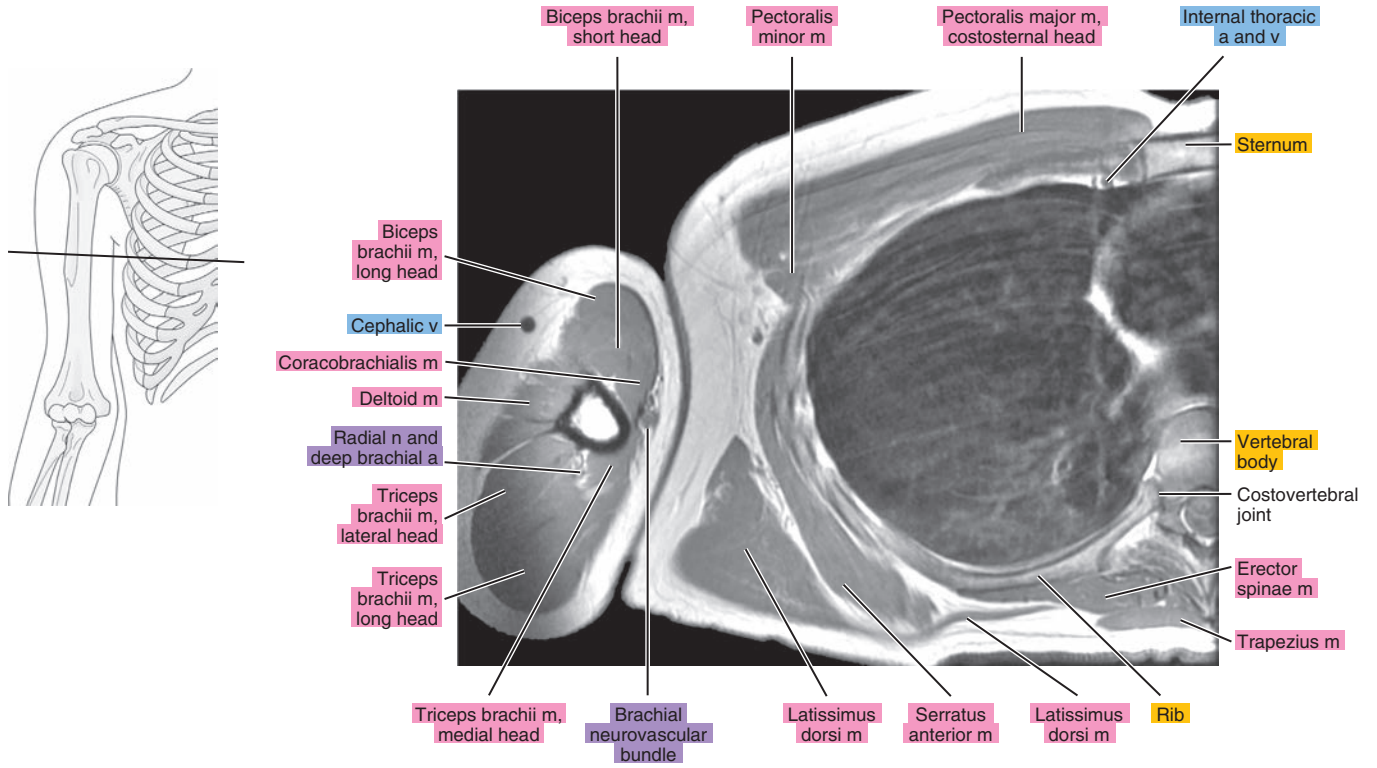




Figure 5.1.19



# SAGITTAL

Figure 5.2.1

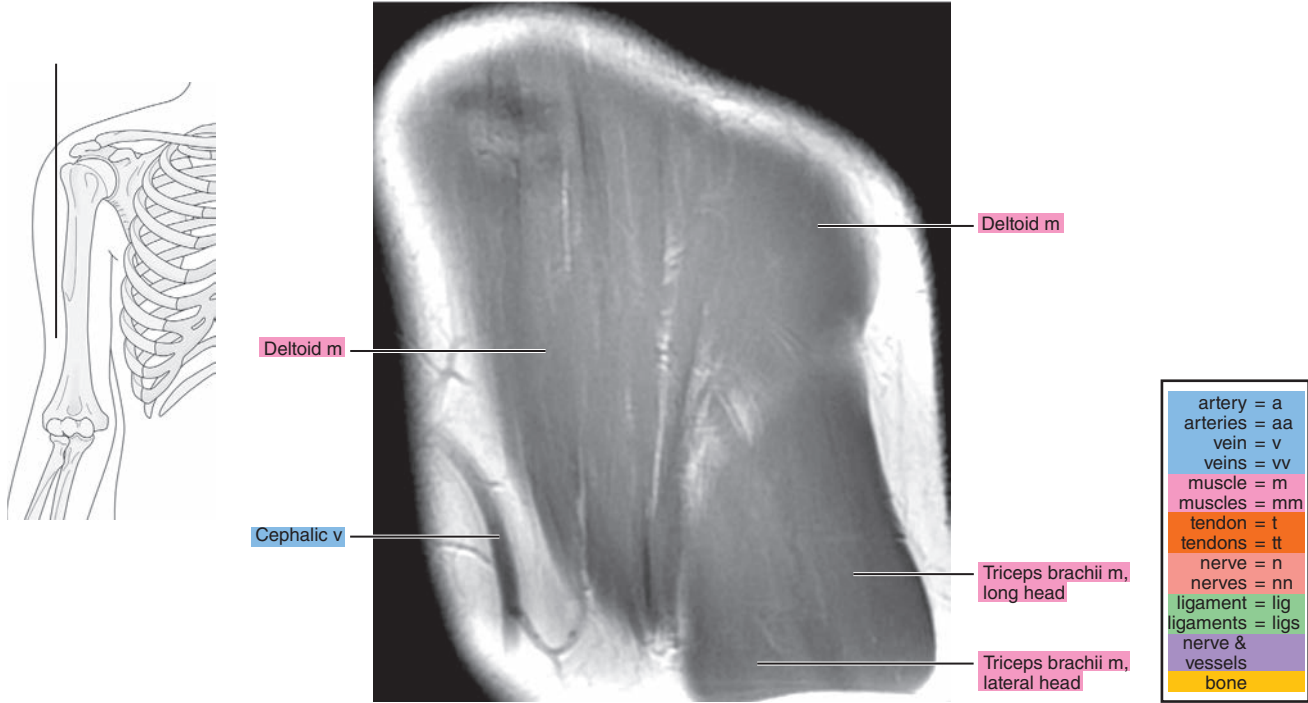


Figure 5.2.2

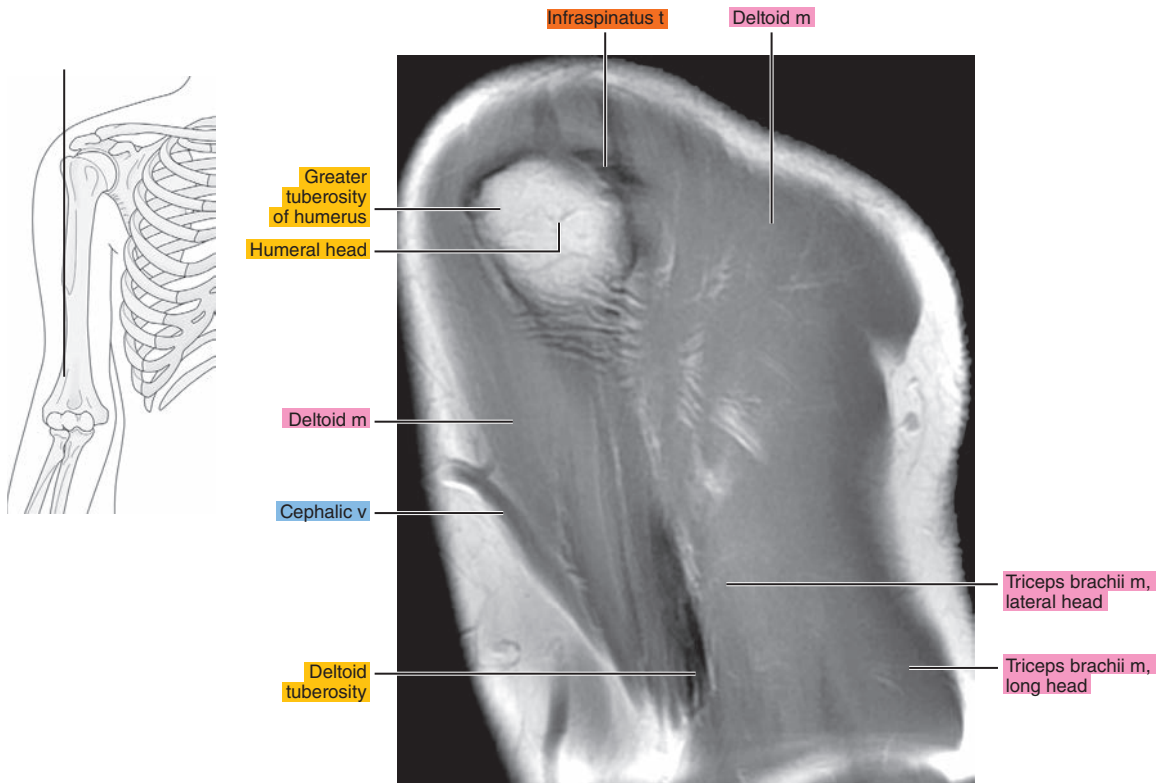


Figure 5.2.3

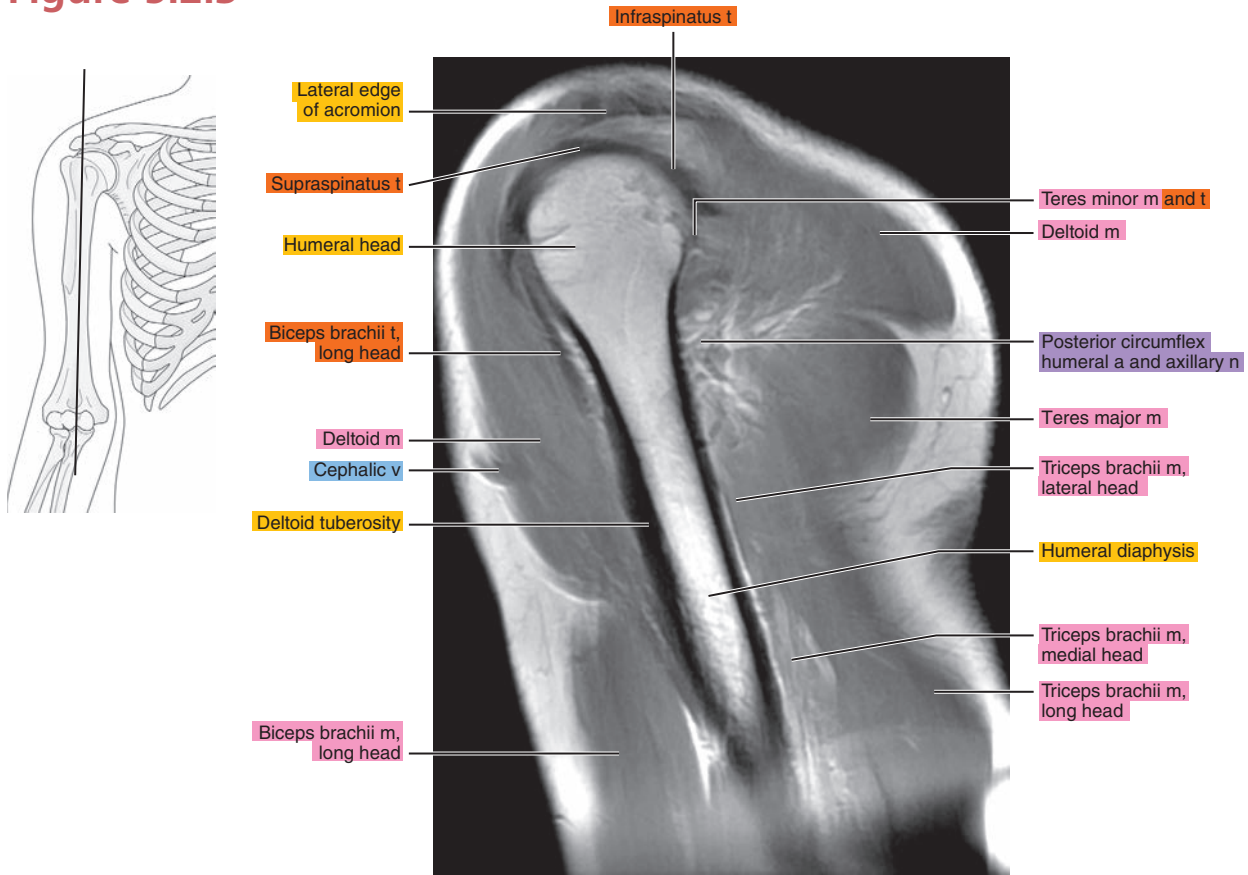


Figure 5.2.4

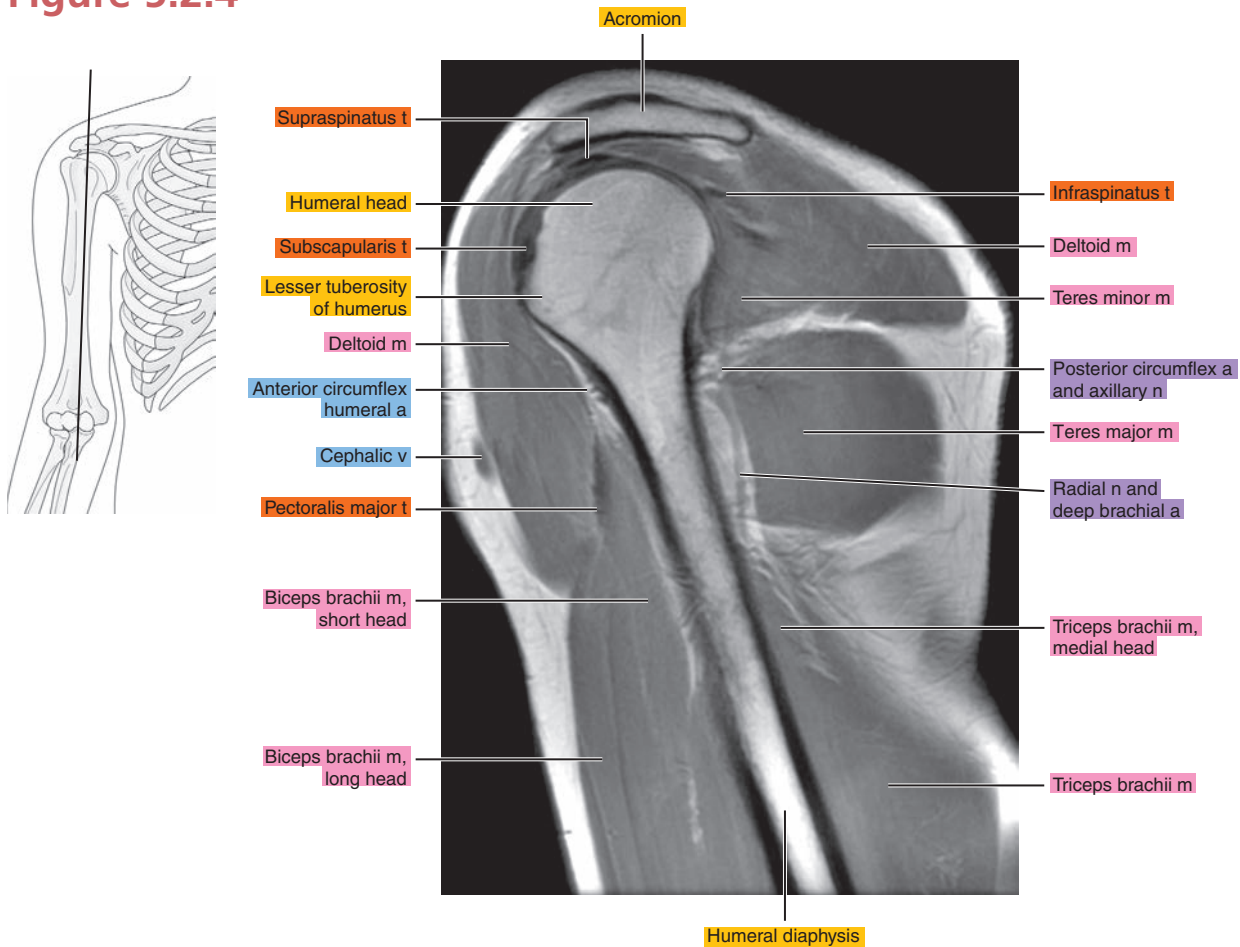


Figure 5.2.5

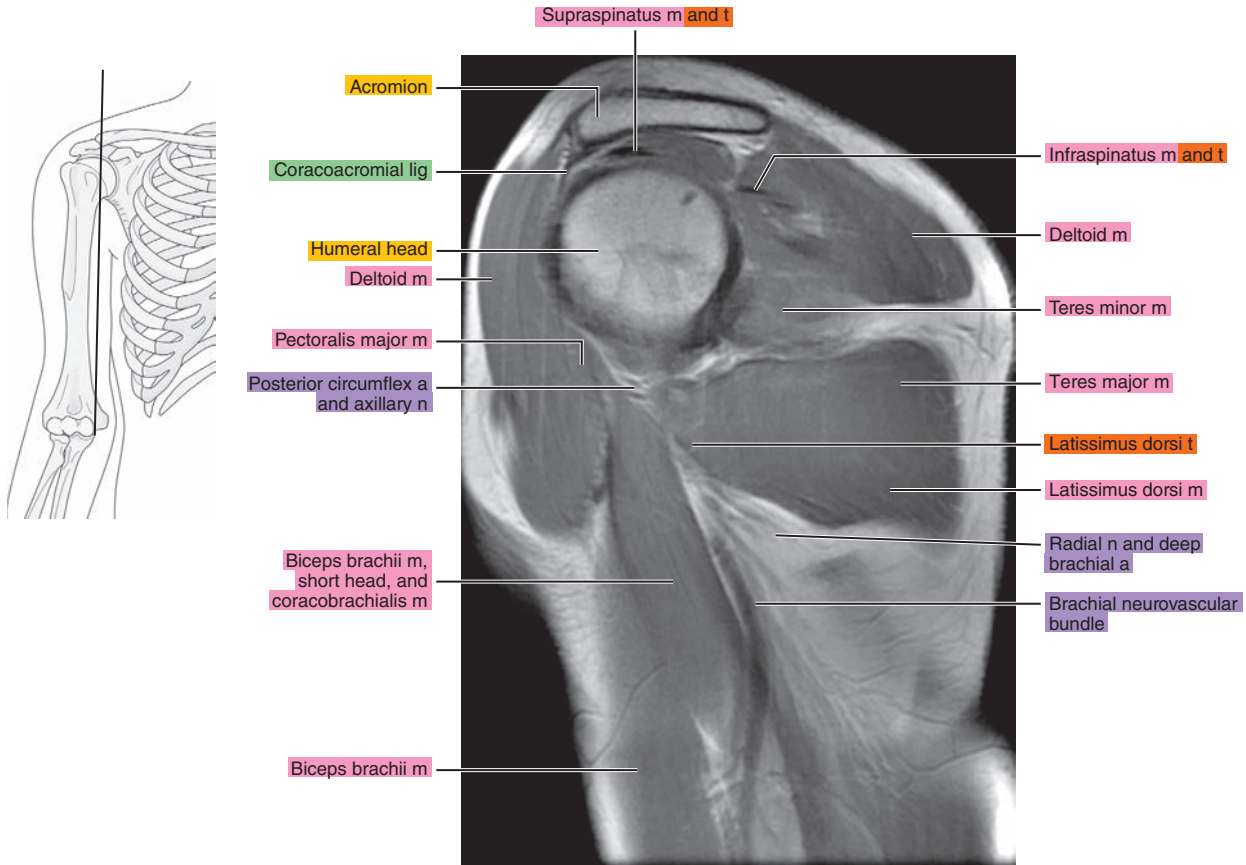


Figure 5.2.6

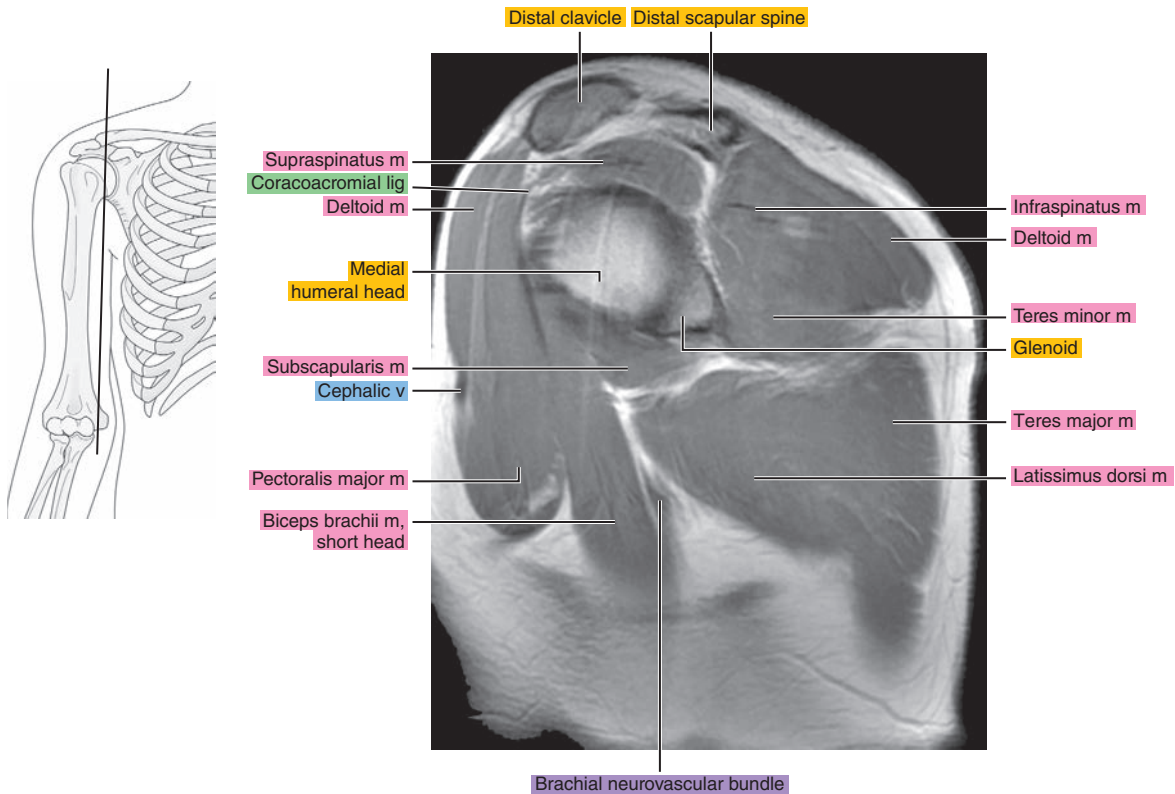




Figure 5.2.7

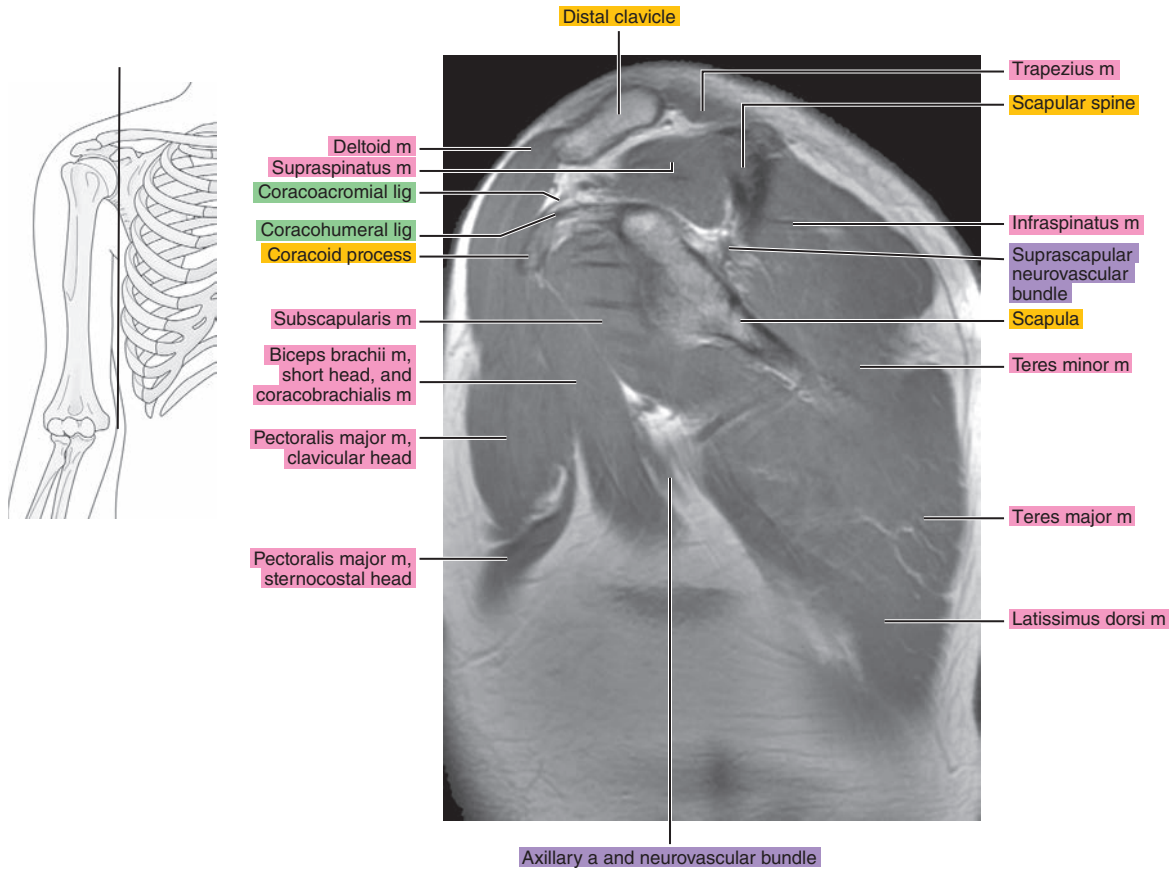


Figure 5.2.8

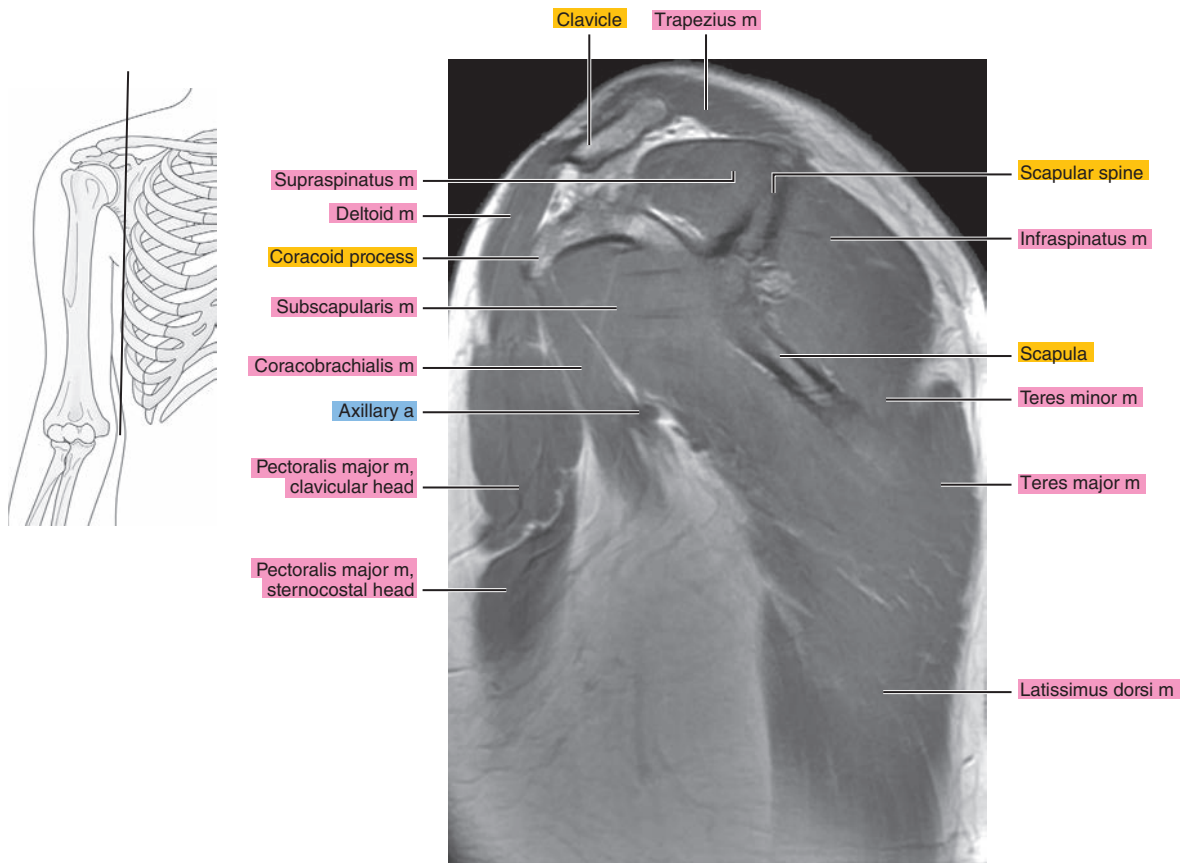




Figure 5.2.9

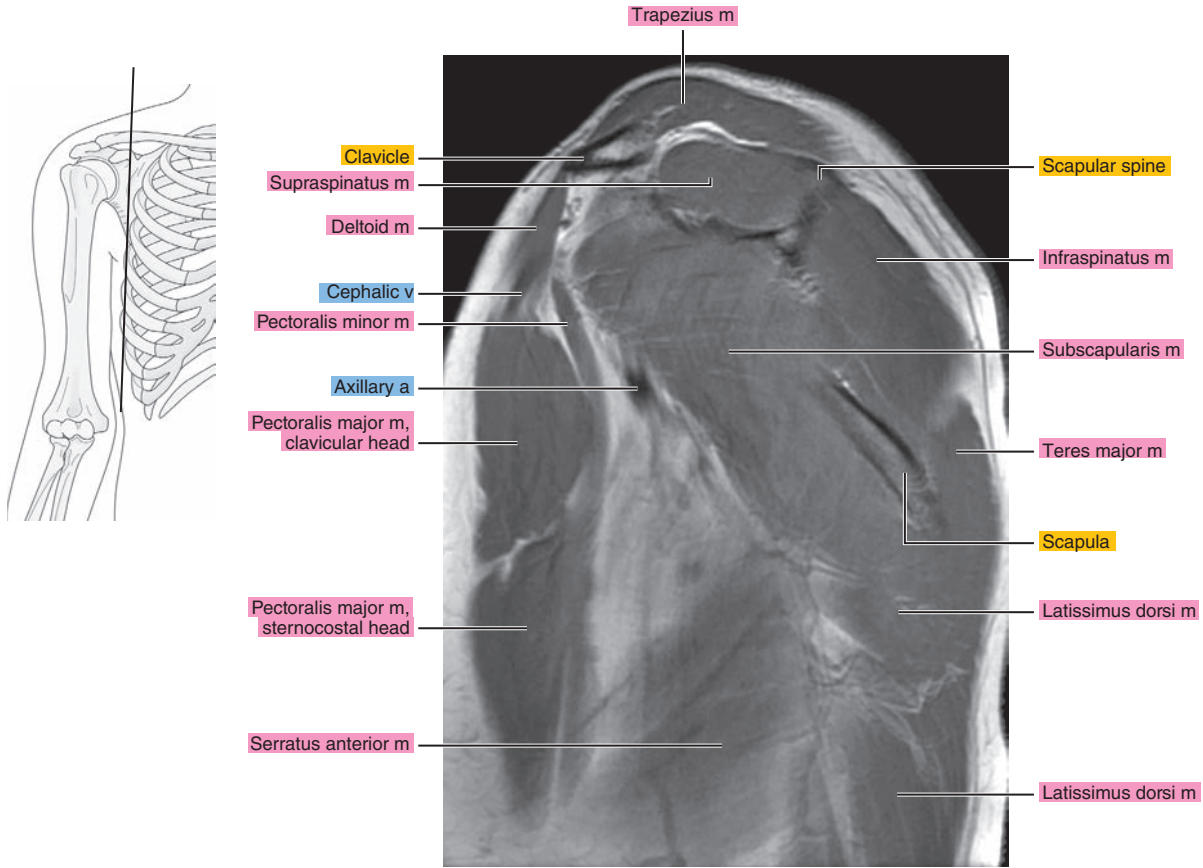


Figure 5.2.10

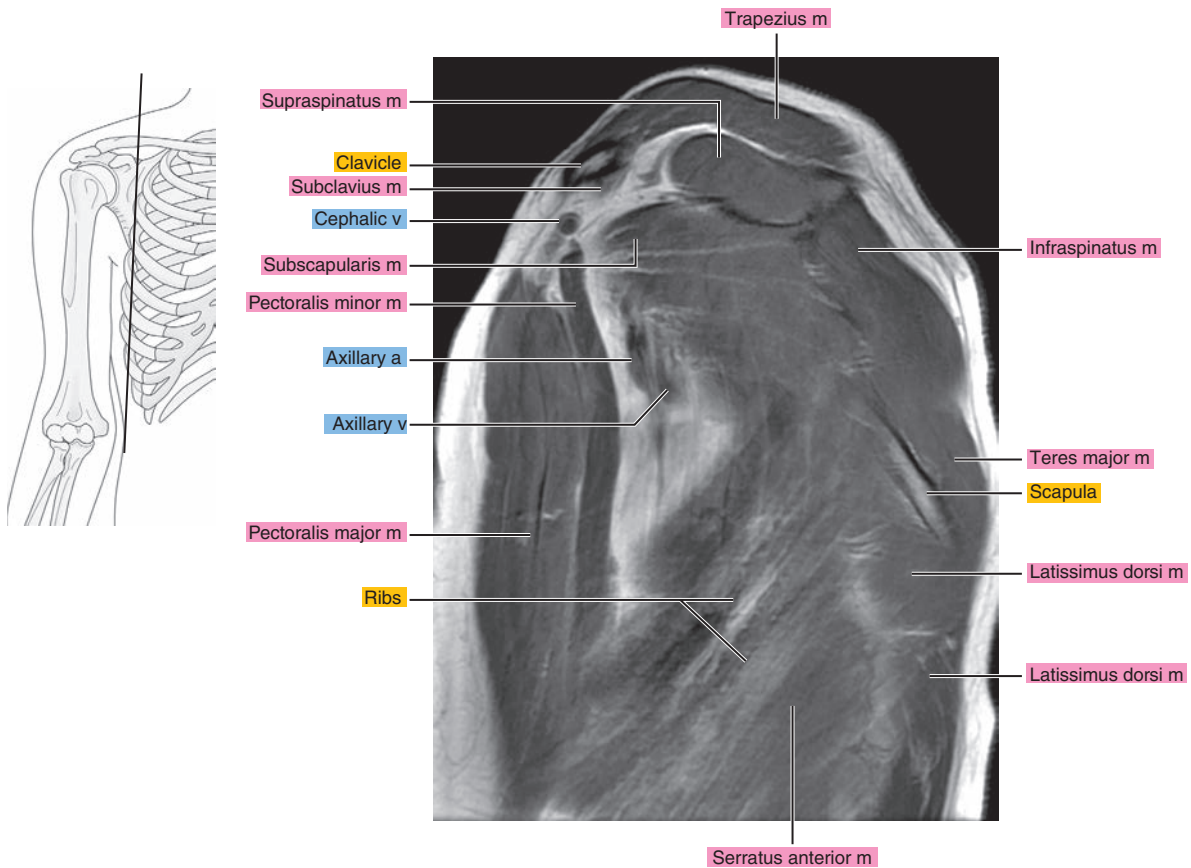


Figure 5.2.11

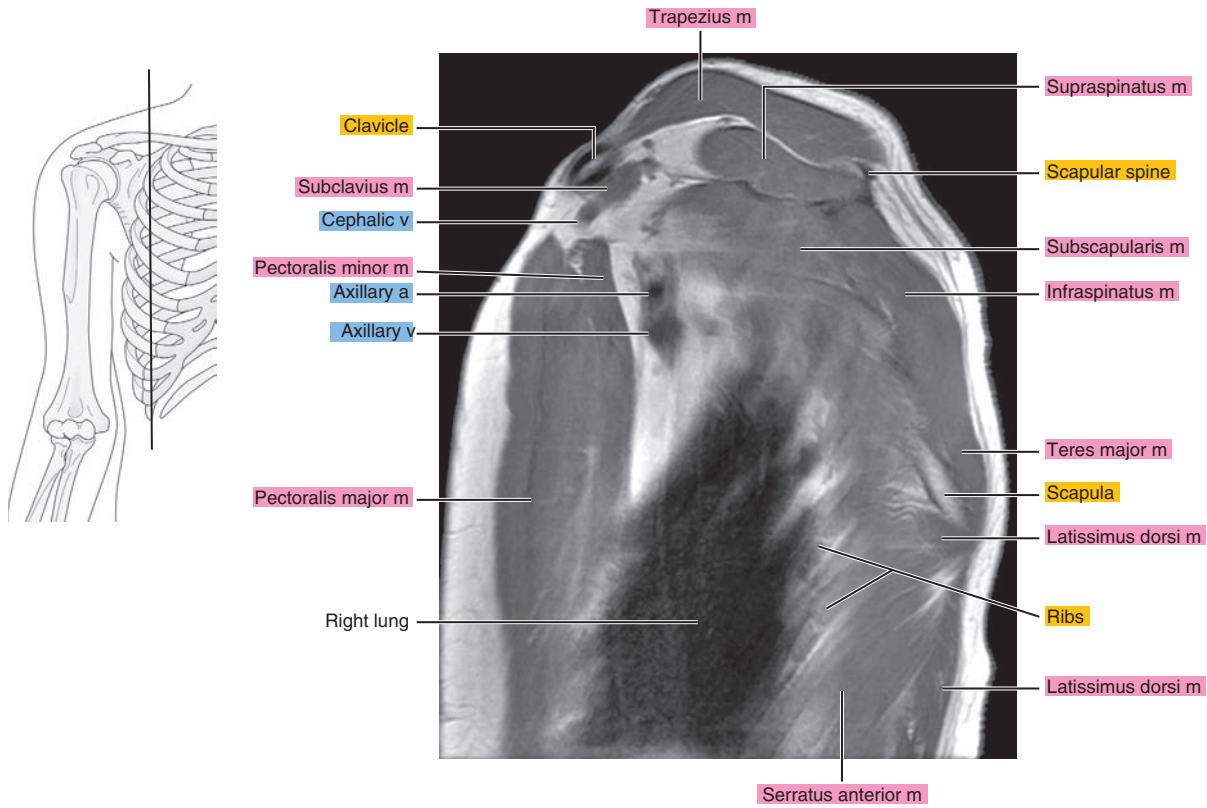


Figure 5.2.12

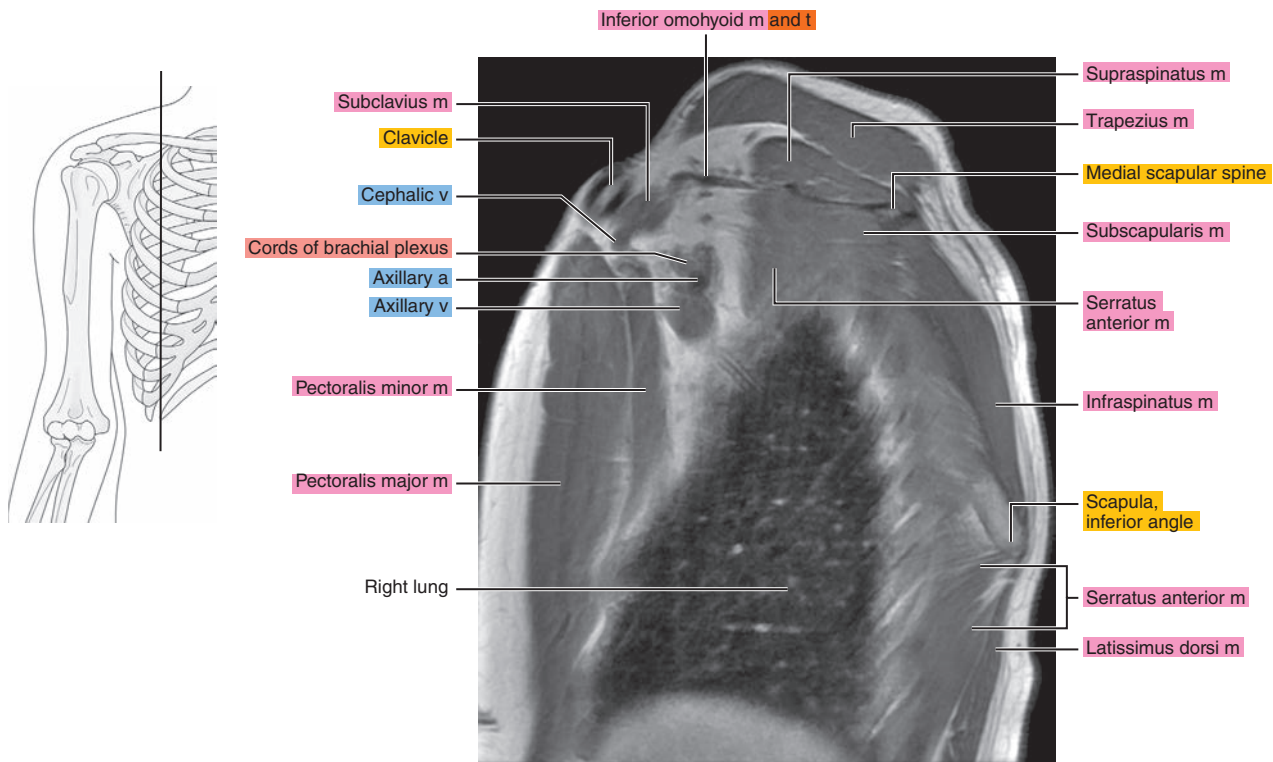


Figure 5.2.13

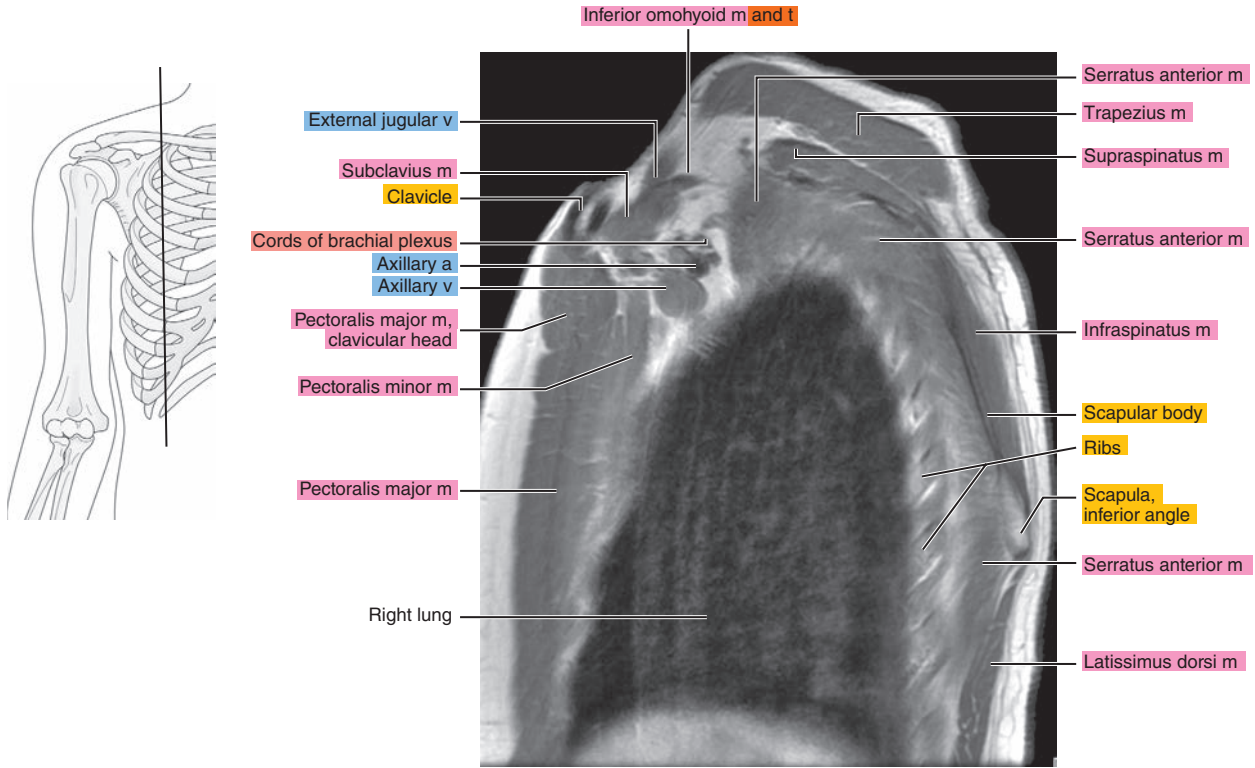


Figure 5.2.14

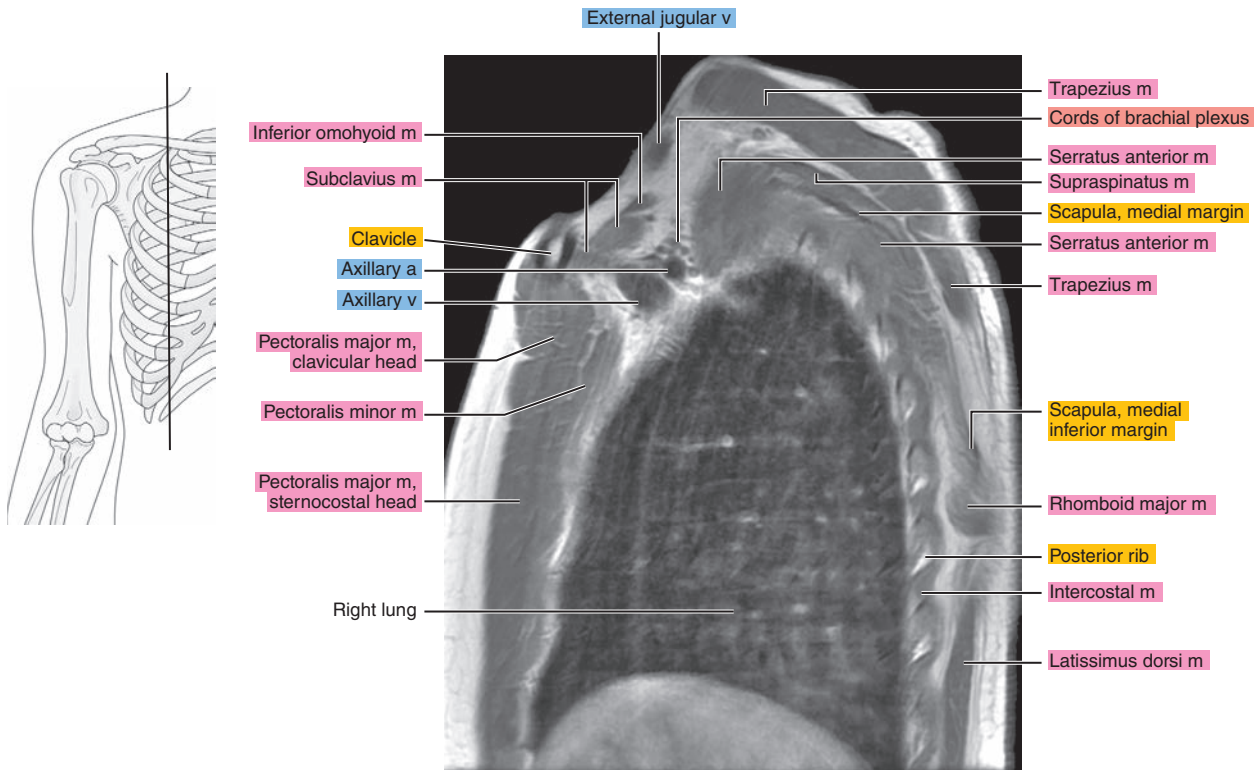




Figure 5.2.15

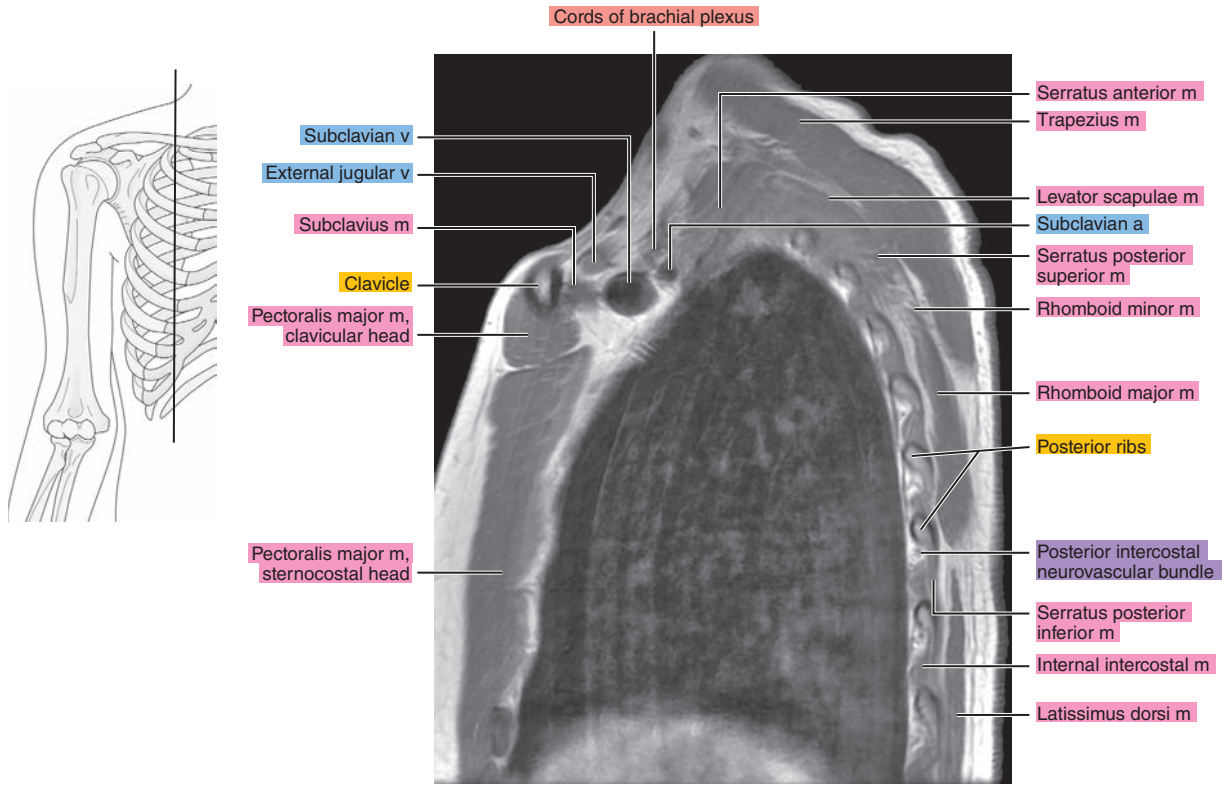


Figure 5.2.16

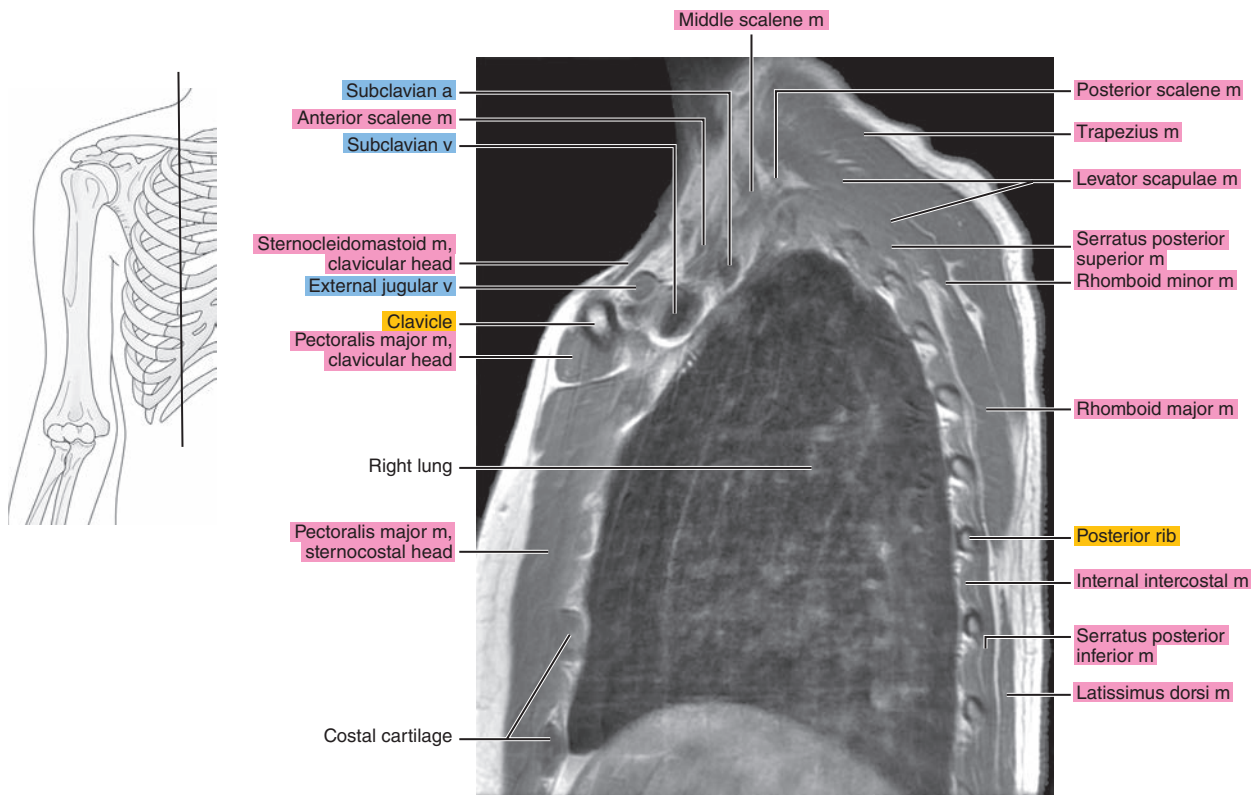


Figure 5.2.17

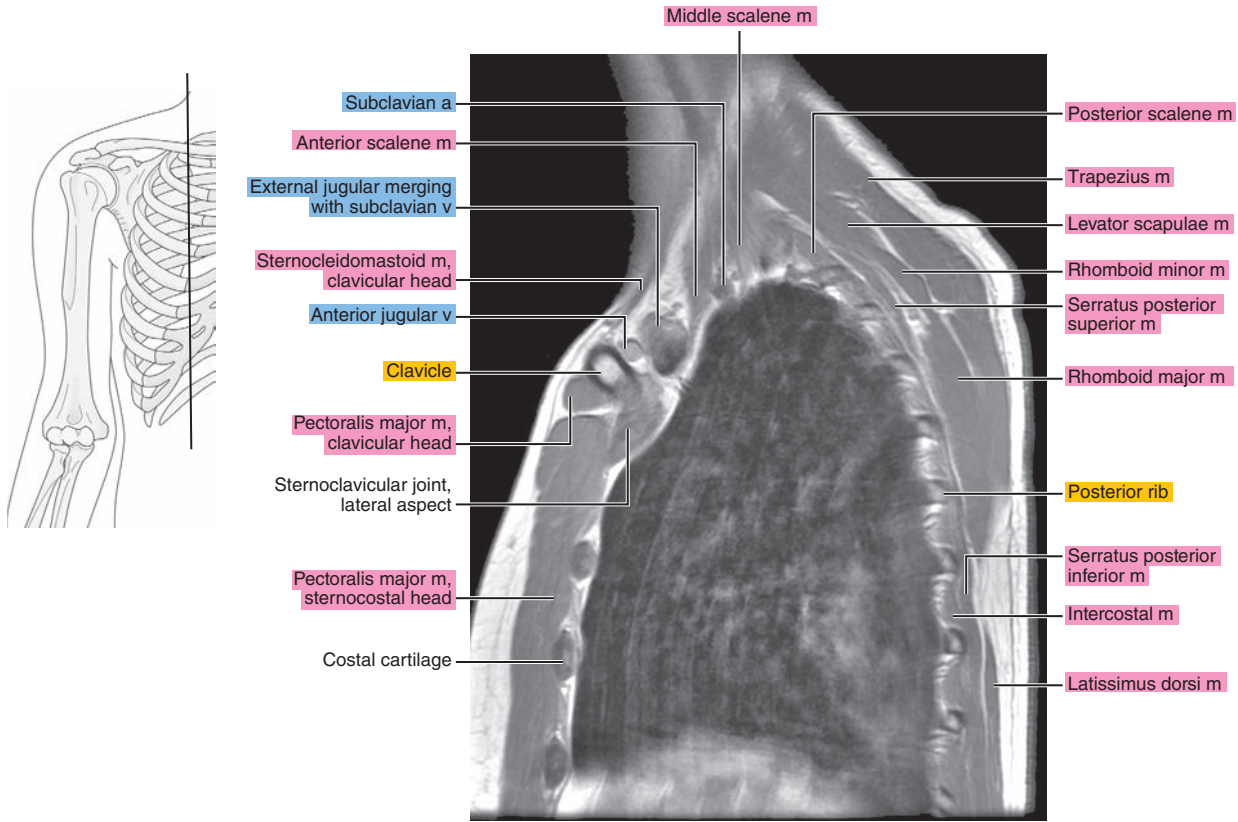


Figure 5.2.18

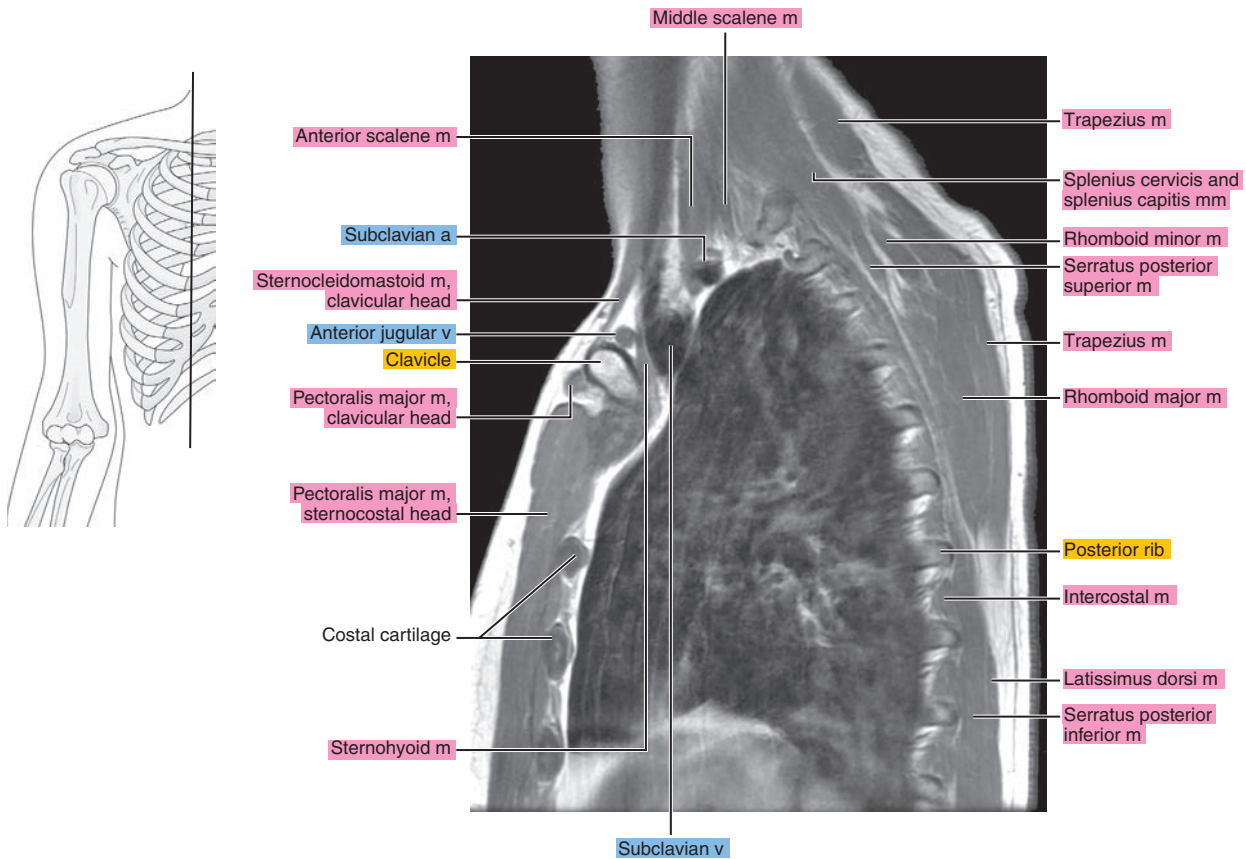
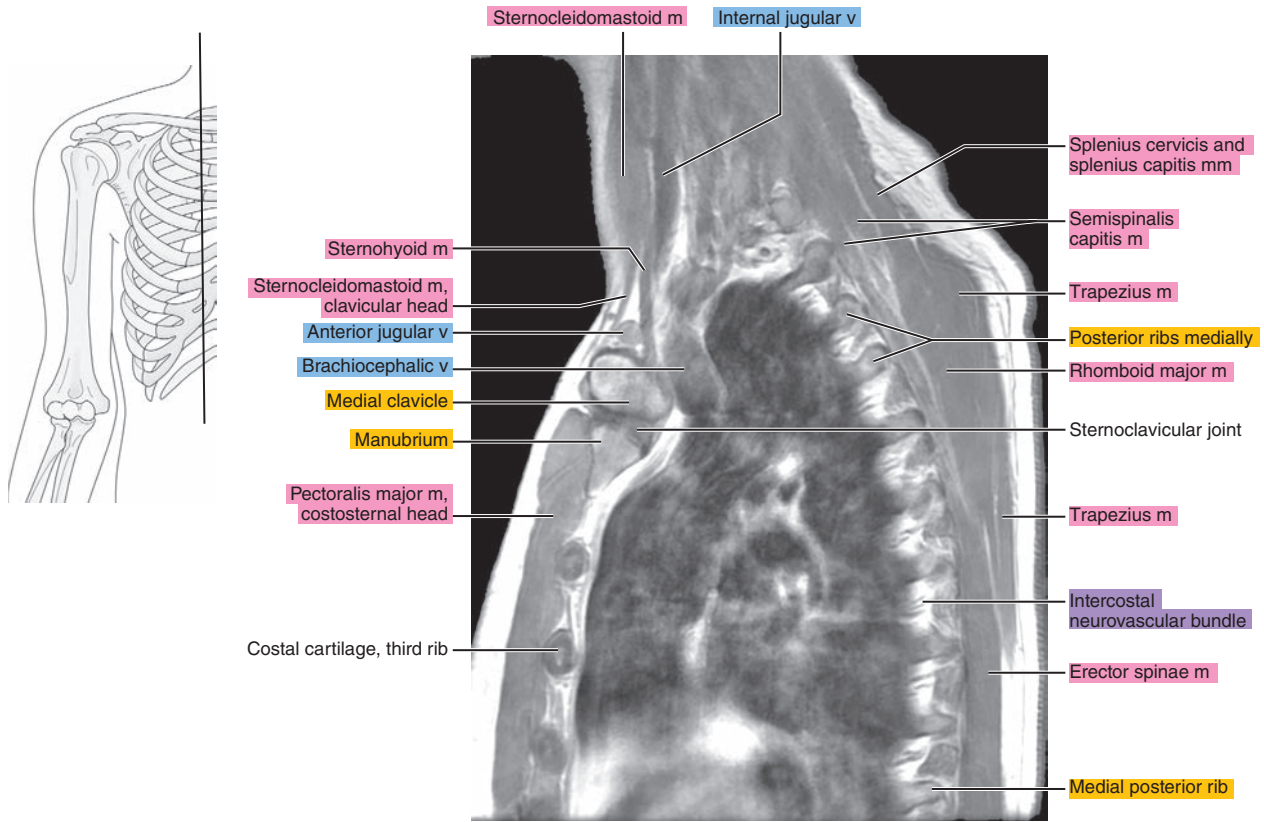




Figure 5.2.19



# CORONAL

Figure 5.3.1

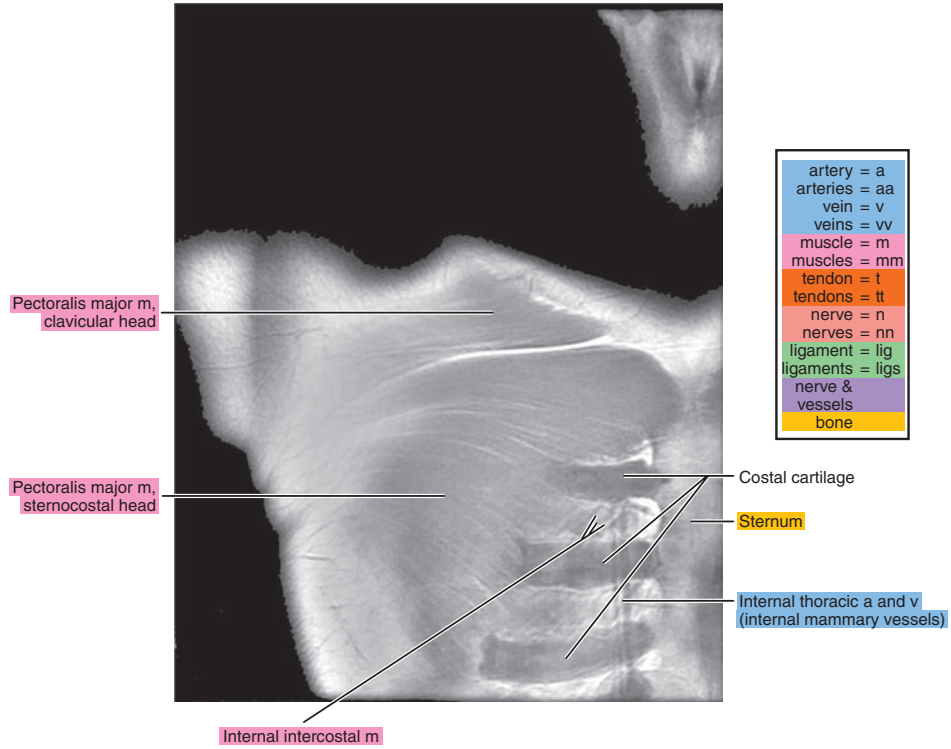
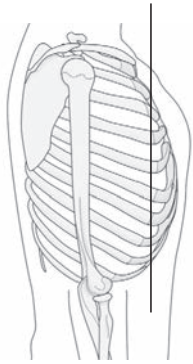


Figure 5.3.2

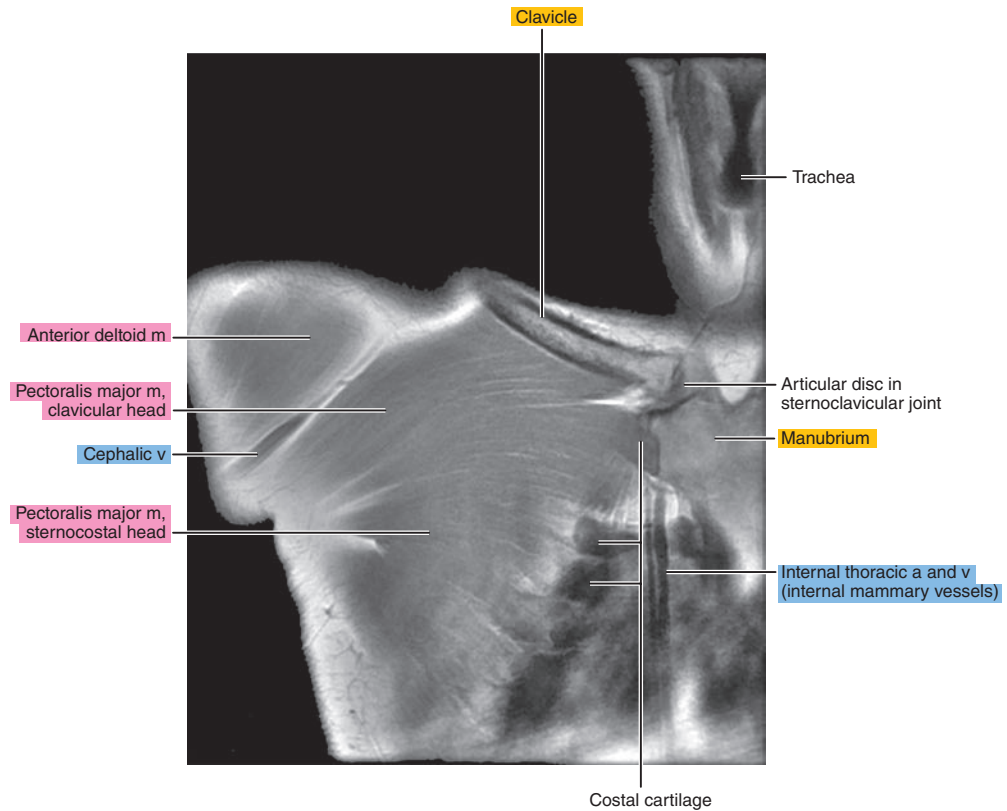
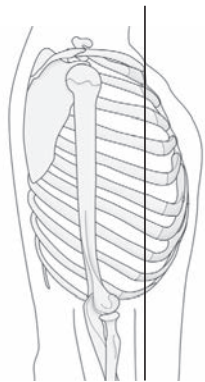


Figure 5.3.3

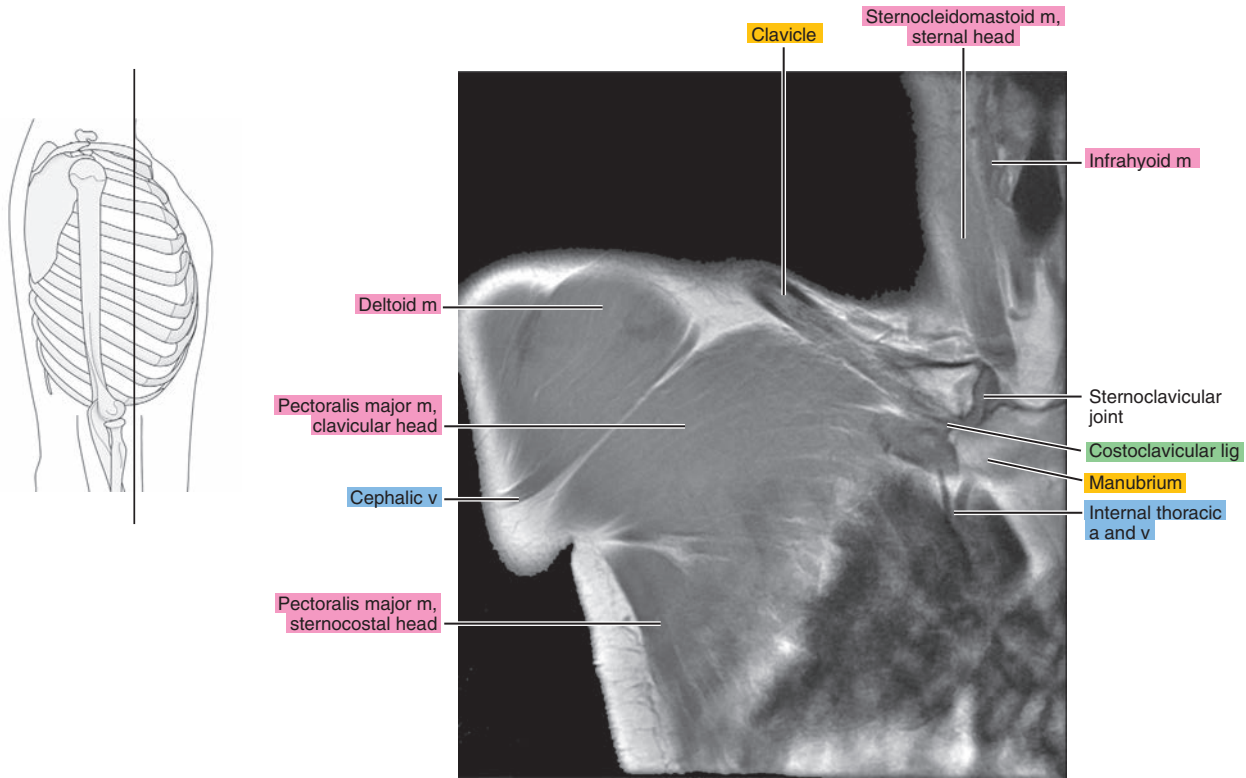


Figure 5.3.4

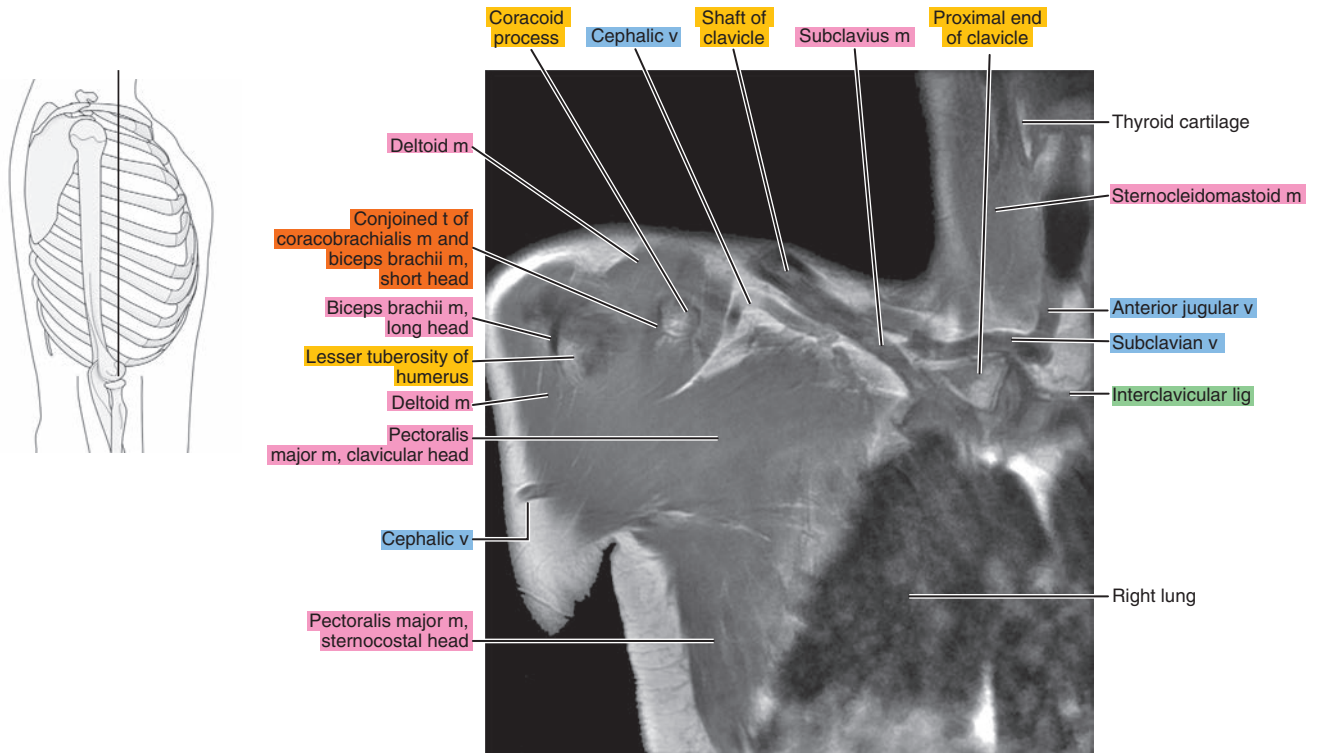


Figure 5.3.5

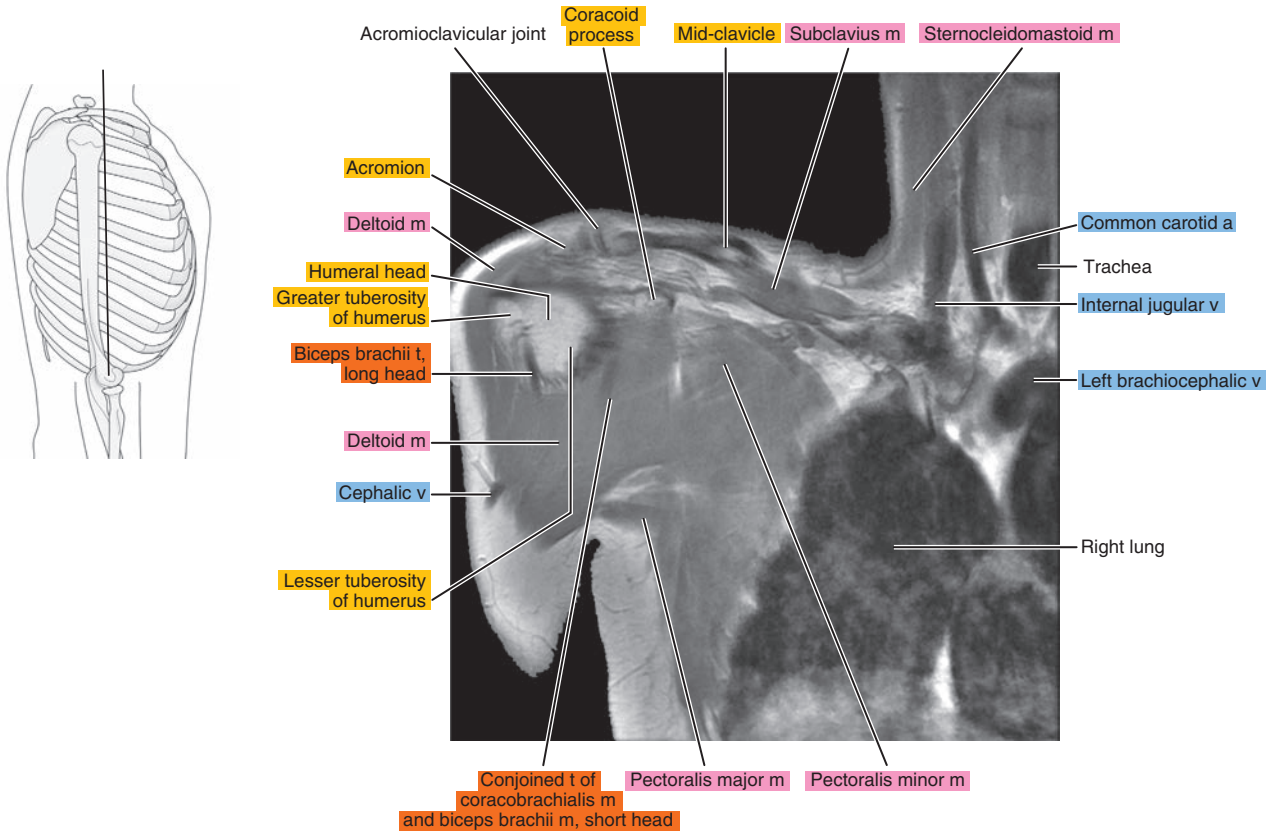


Figure 5.3.6

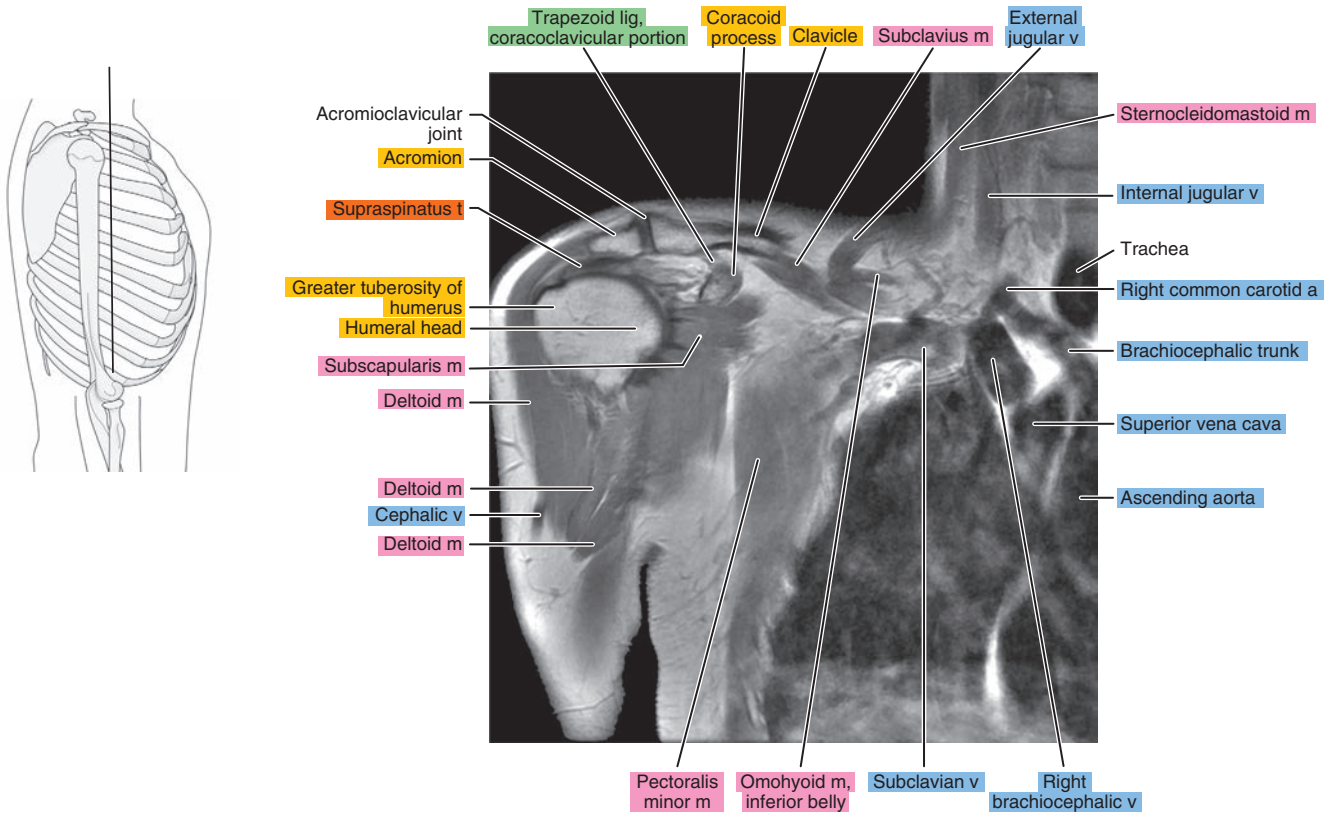




Figure 5.3.7

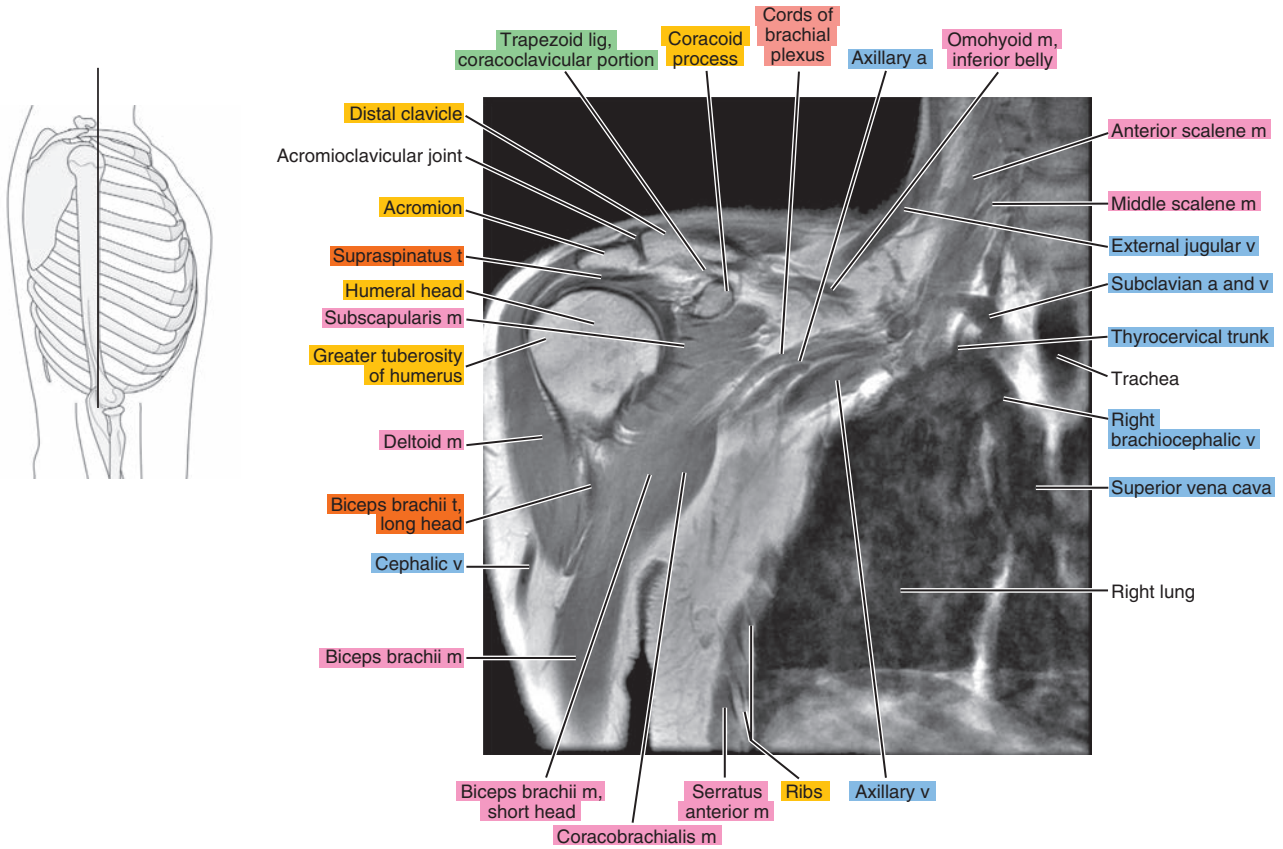


Figure 5.3.8

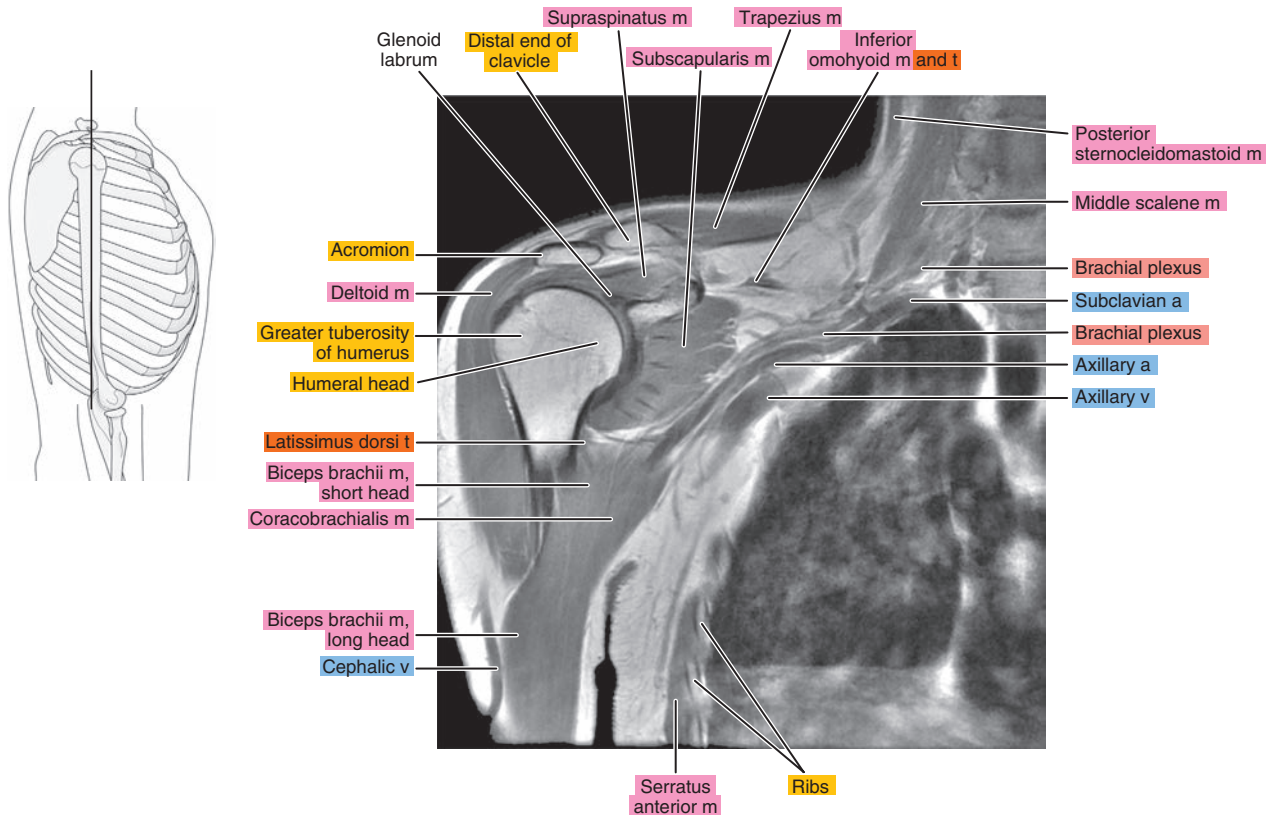


Figure 5.3.9

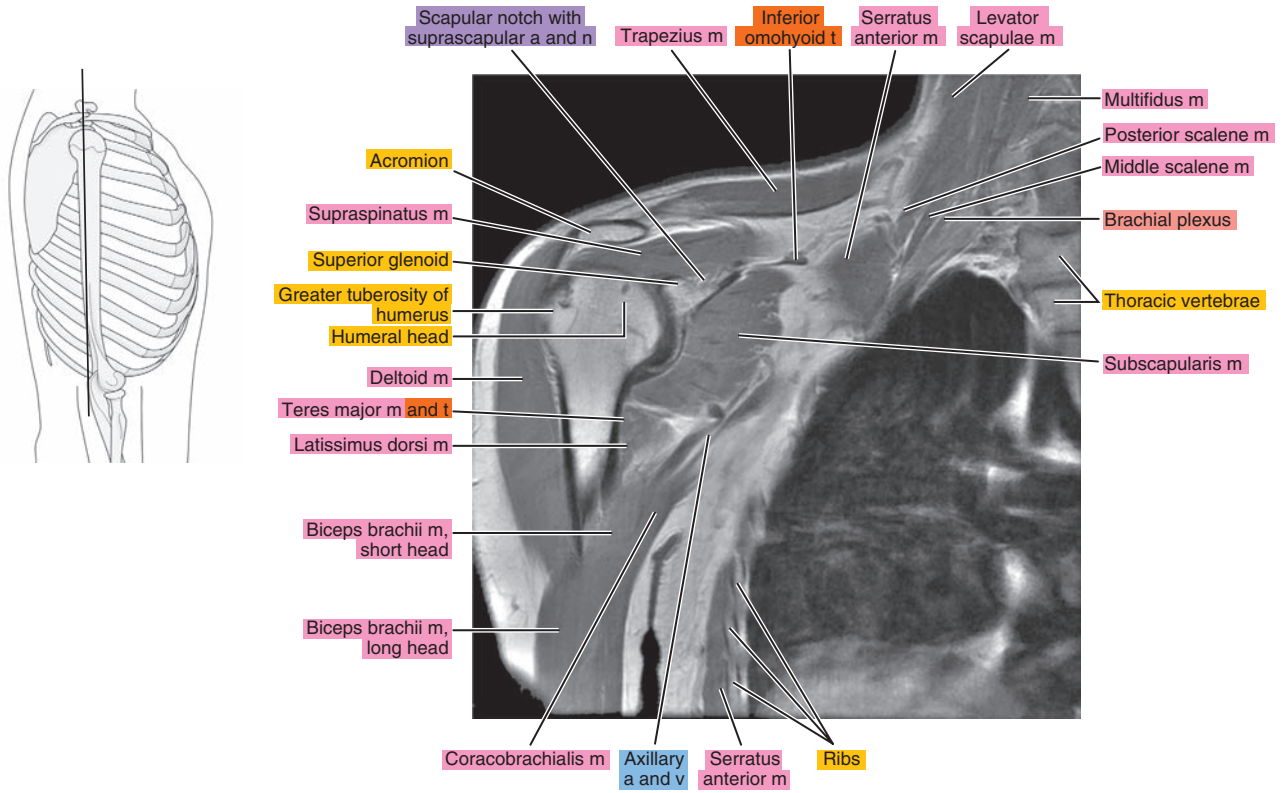


Figure 5.3.10

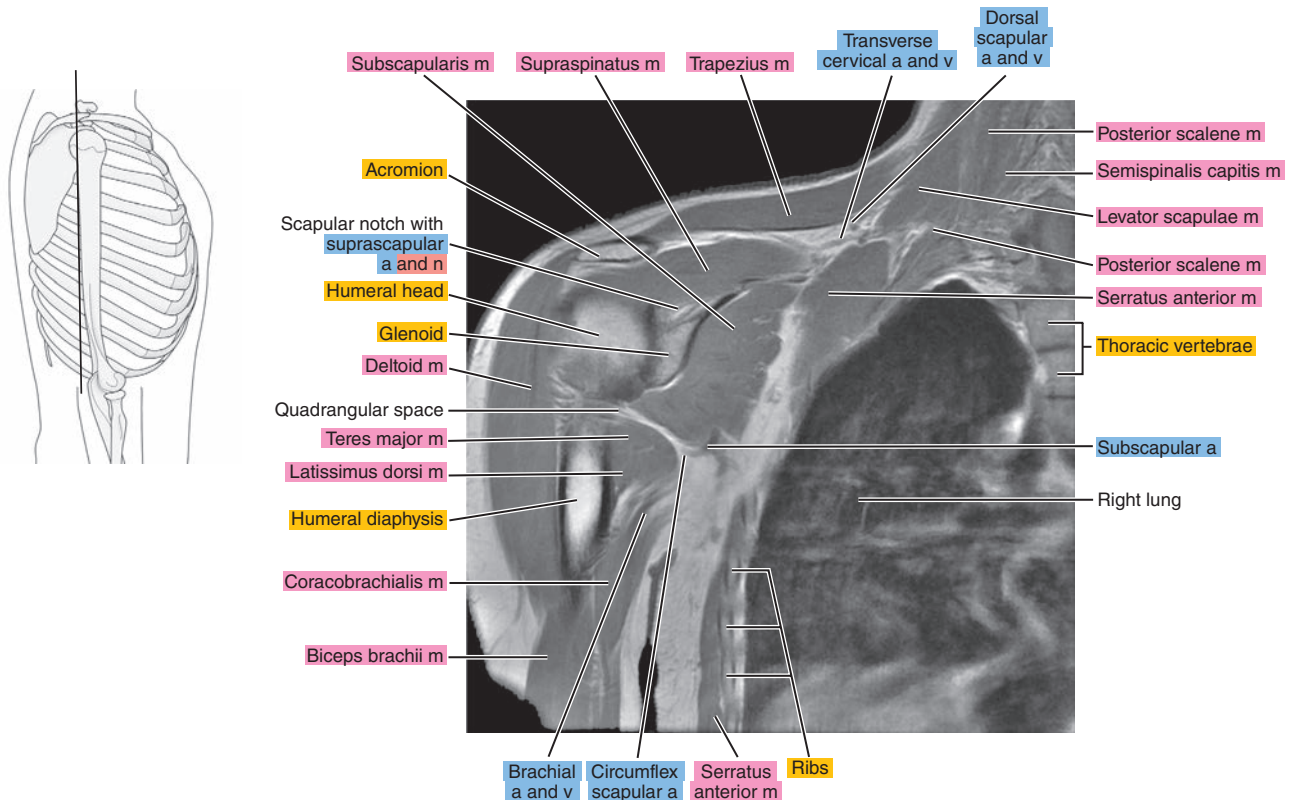


Figure 5.3.11

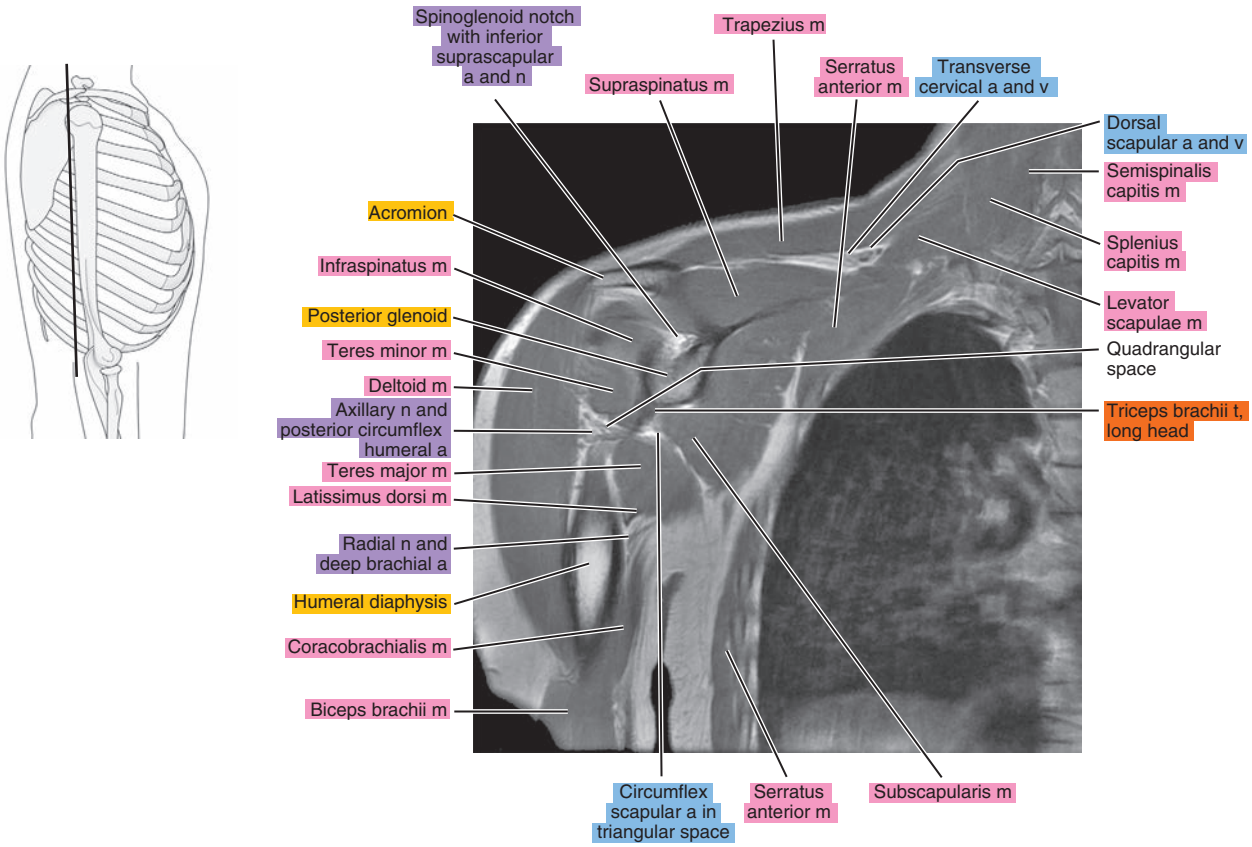


Figure 5.3.12

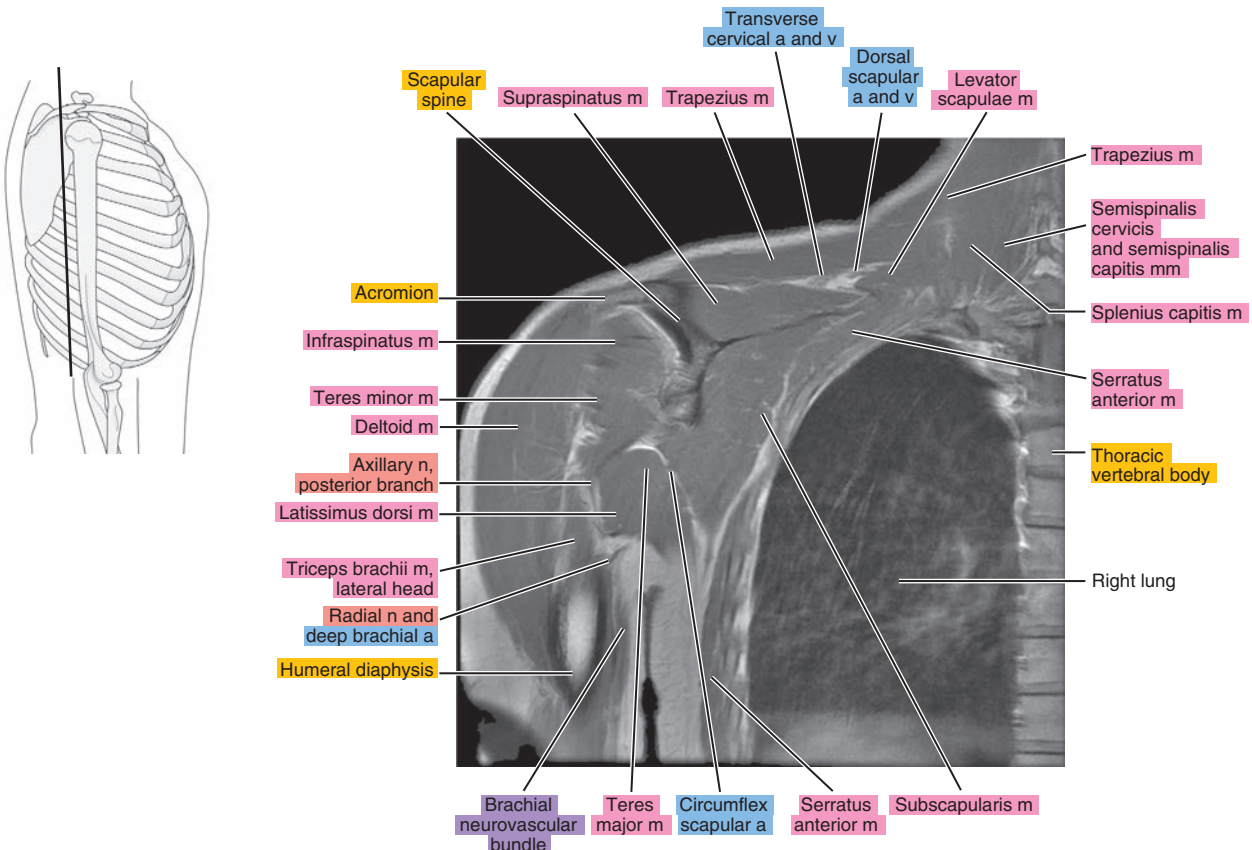




Figure 5.3.13

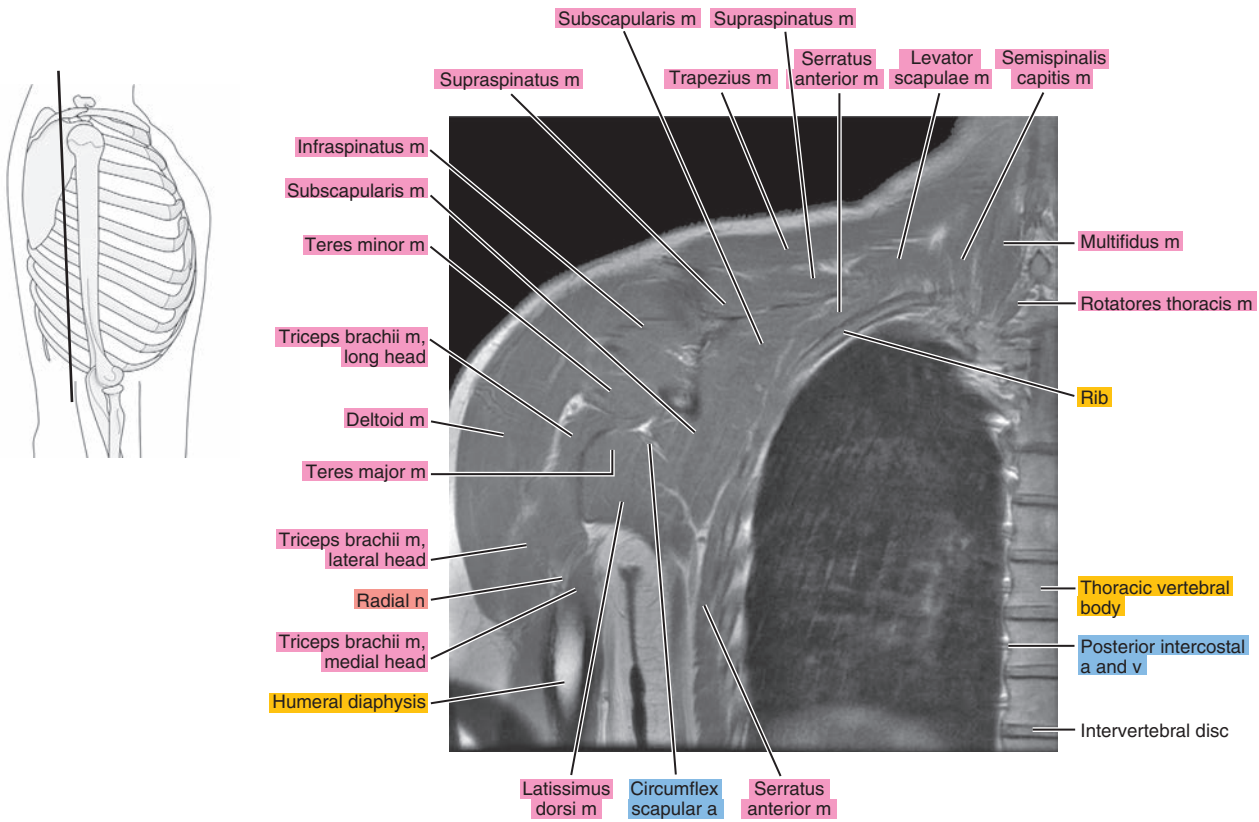


Figure 5.3.14

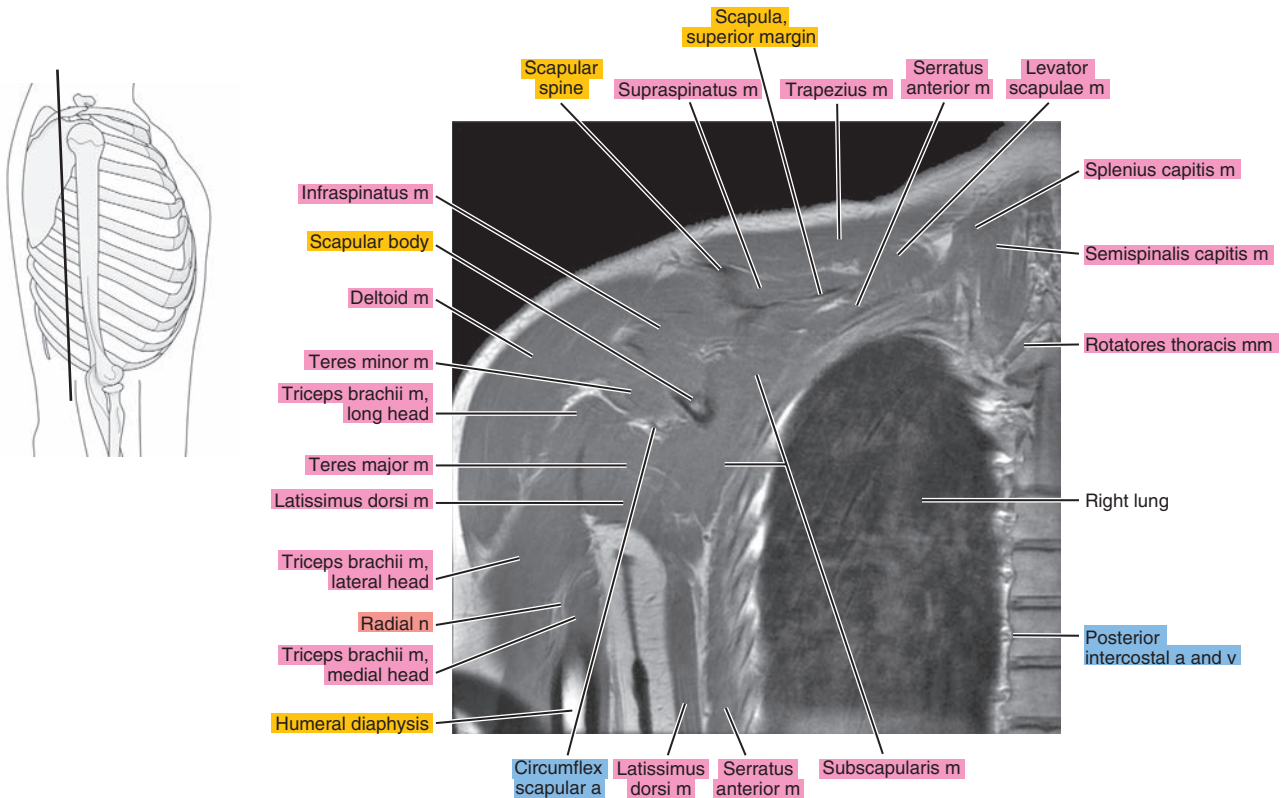




Figure 5.3.15

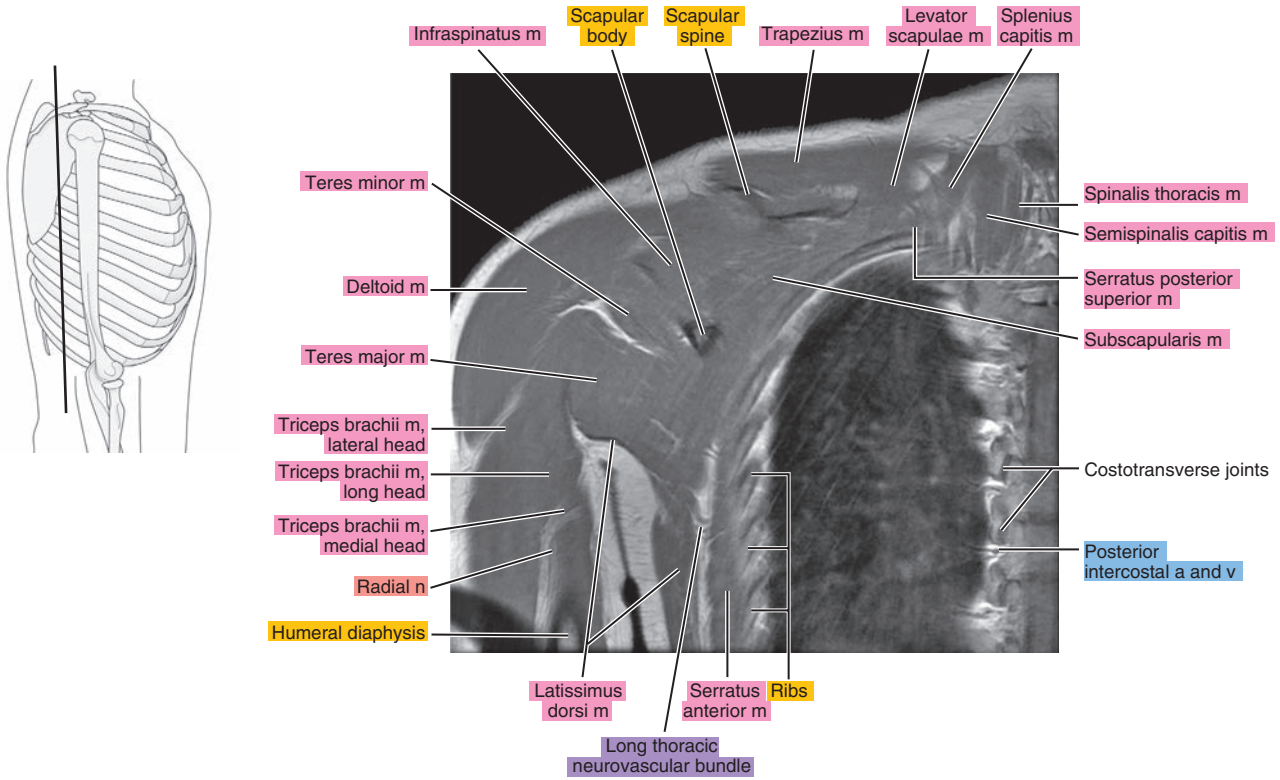


Figure 5.3.16

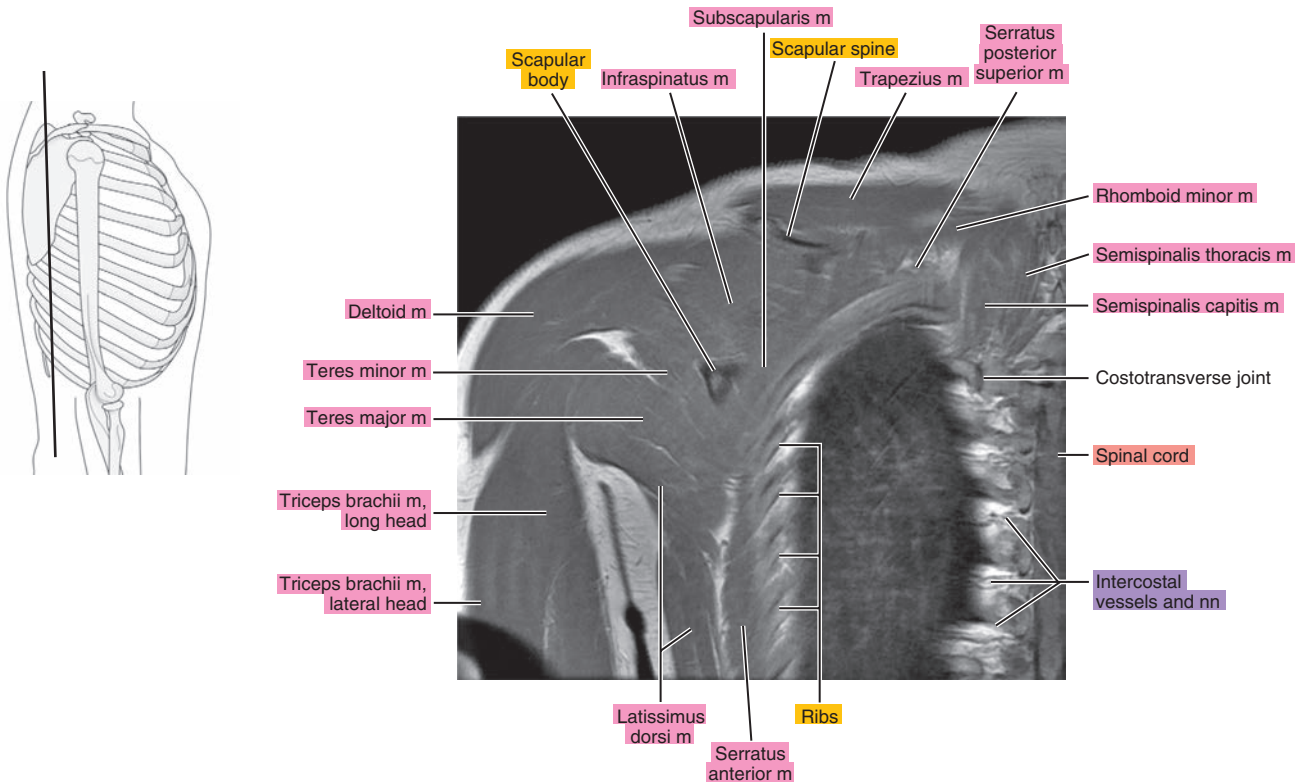


Figure 5.3.17

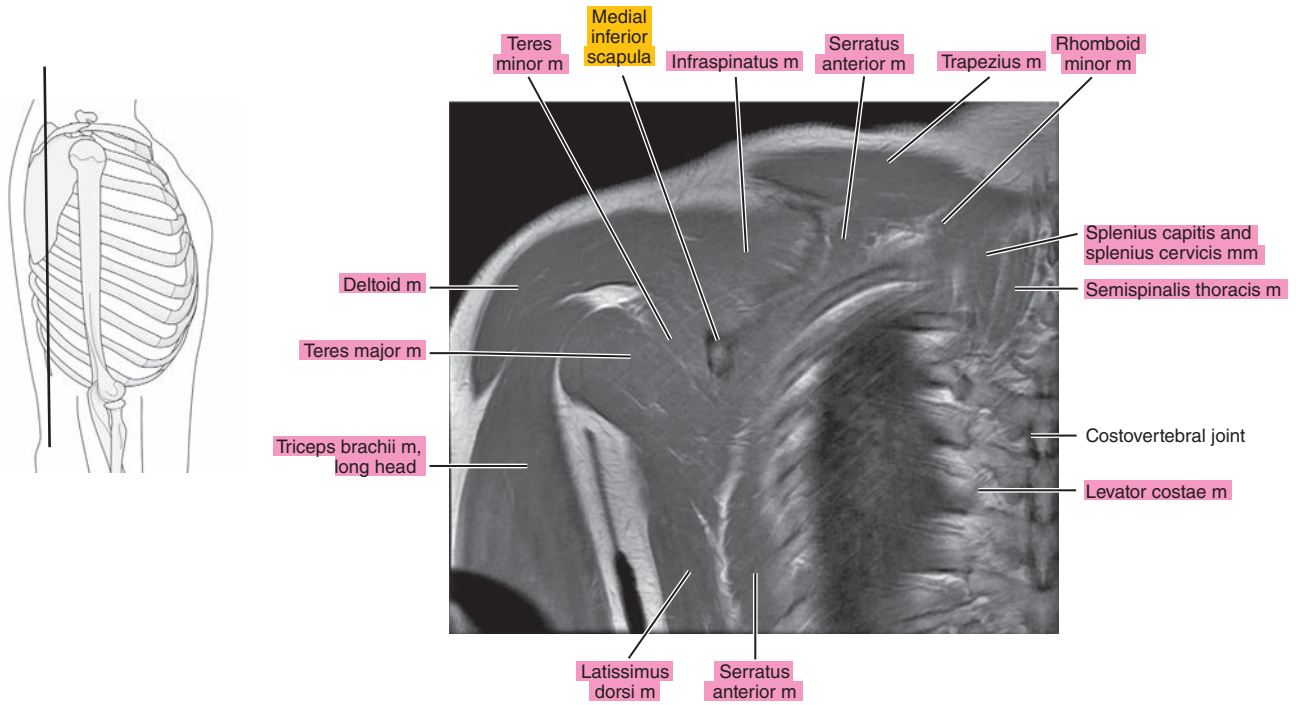


Figure 5.3.18

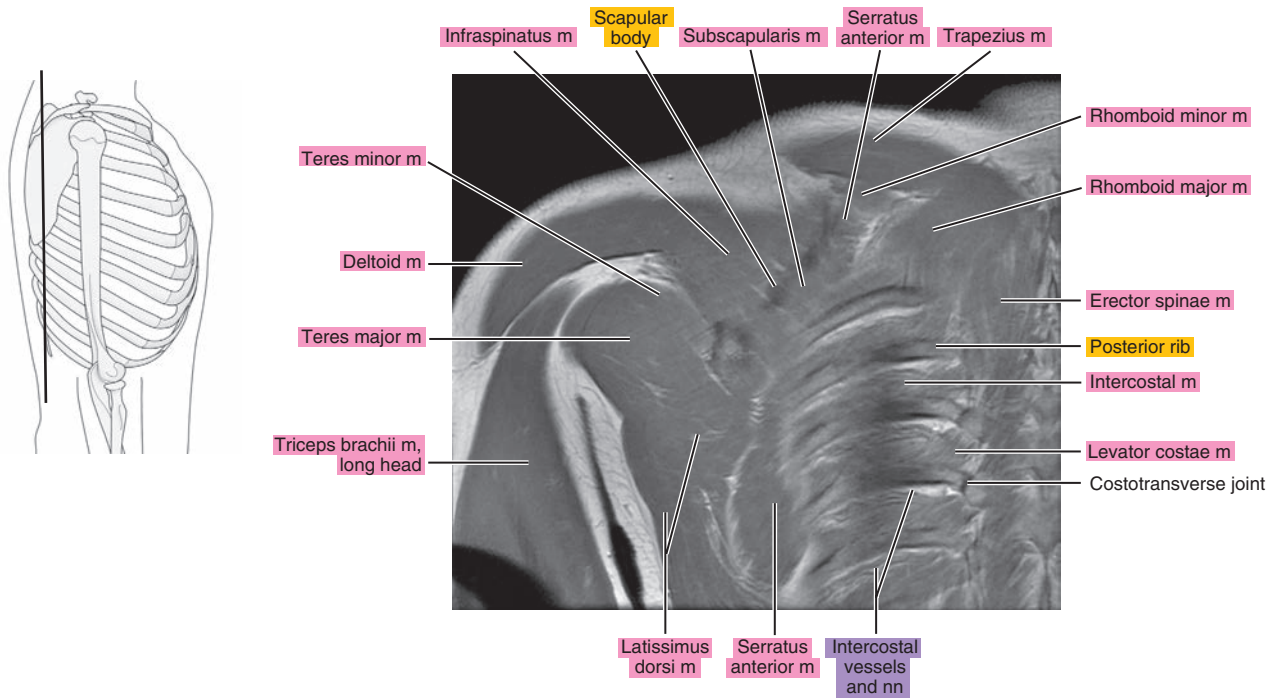


Figure 5.3.19

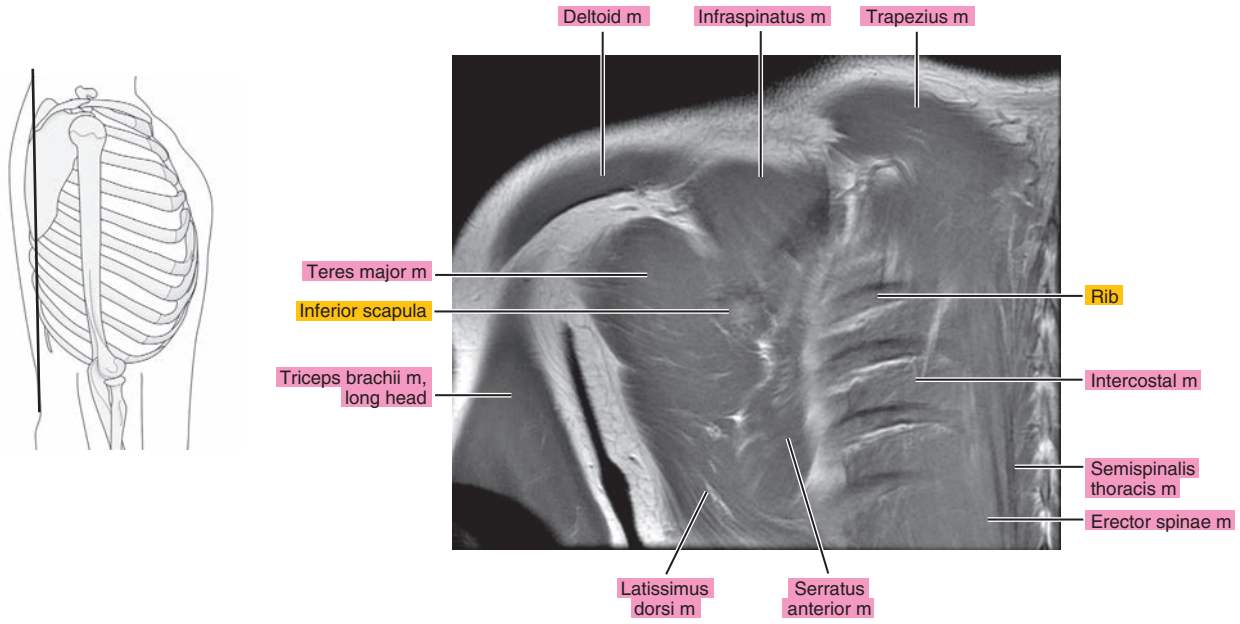
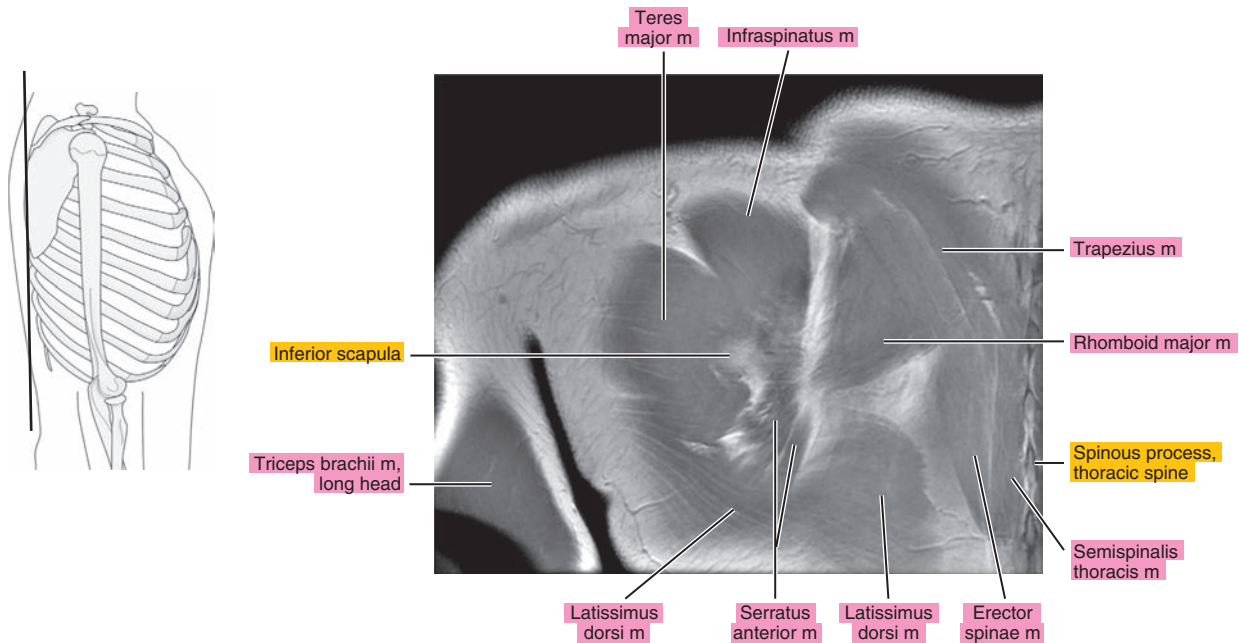


Figure 5.3.20



*Chapter*  
**6**

**MRI of the Shoulder**



# AXIAL

Figure 6.1.1

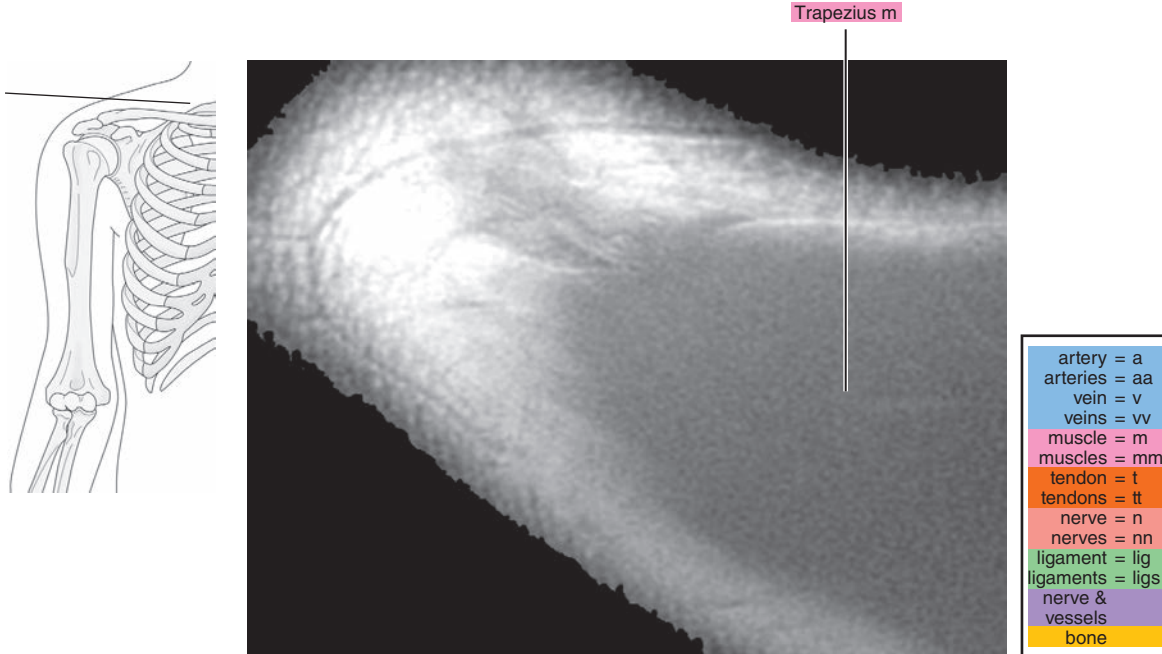


Figure 6.1.2

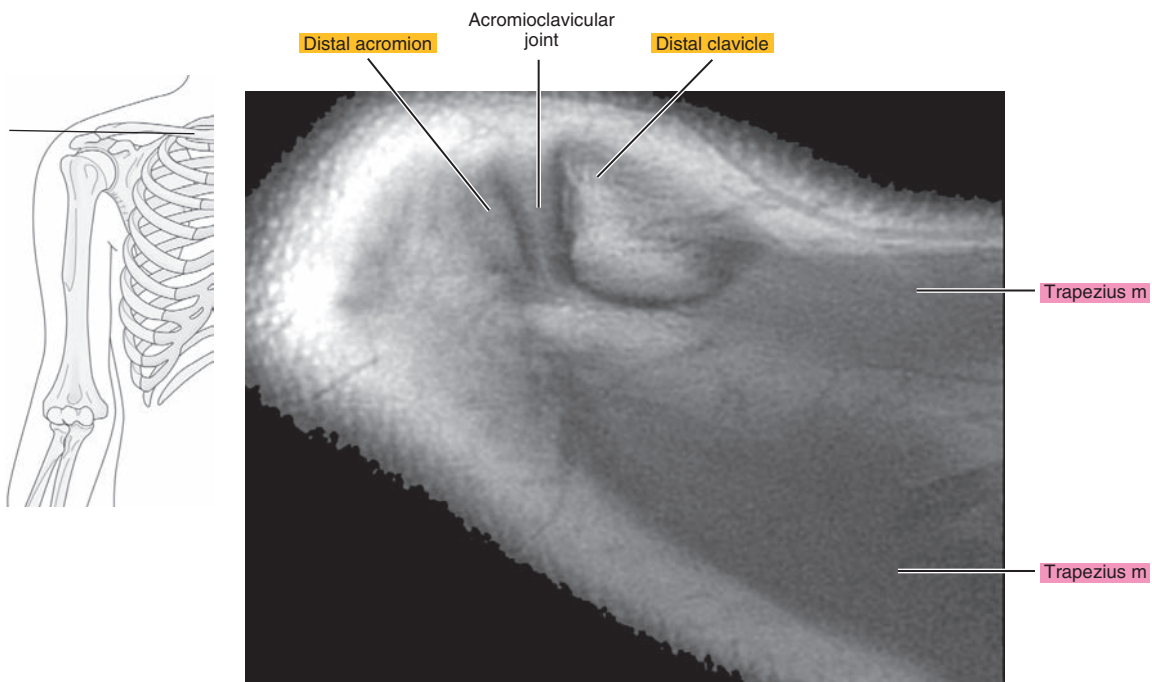


Figure 6.1.3

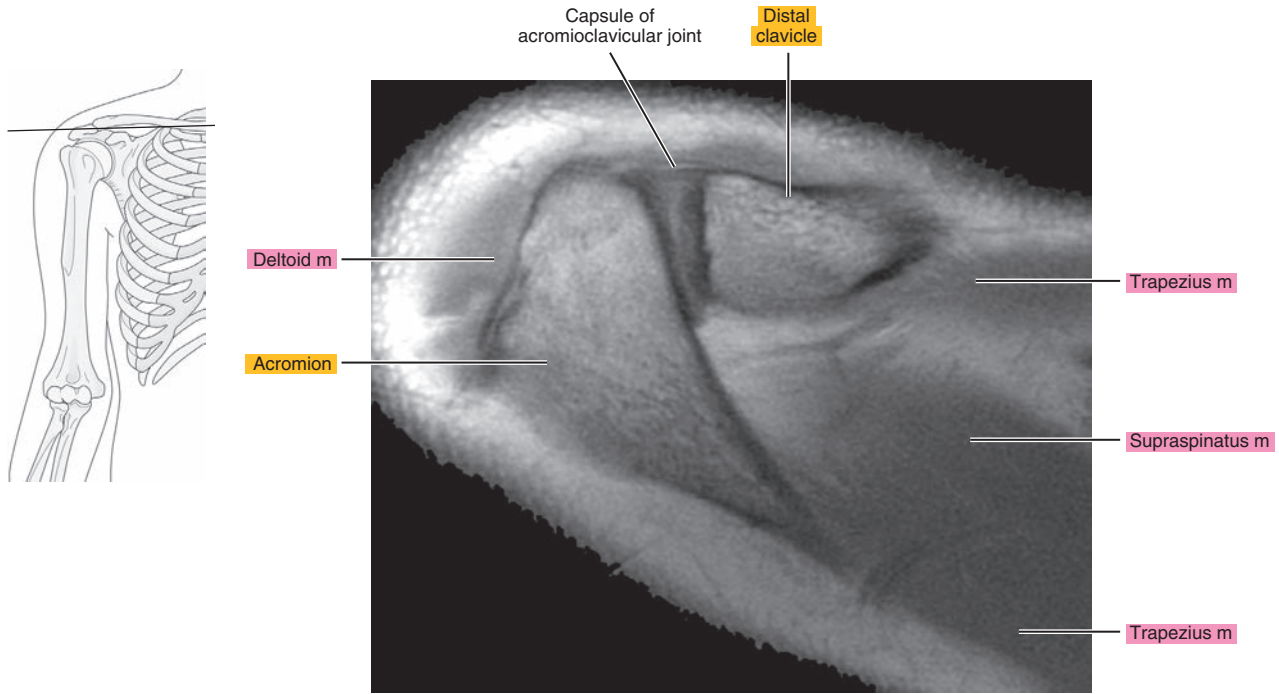


Figure 6.1.4

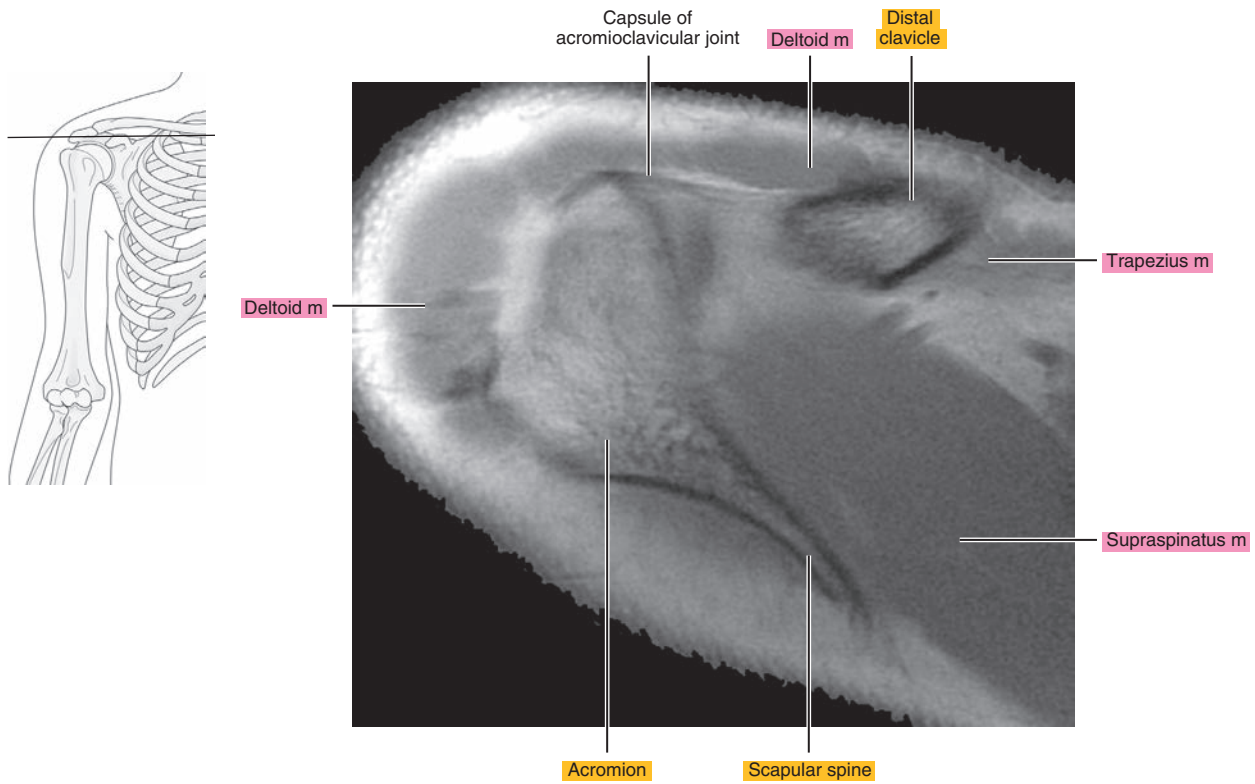


Figure 6.1.5

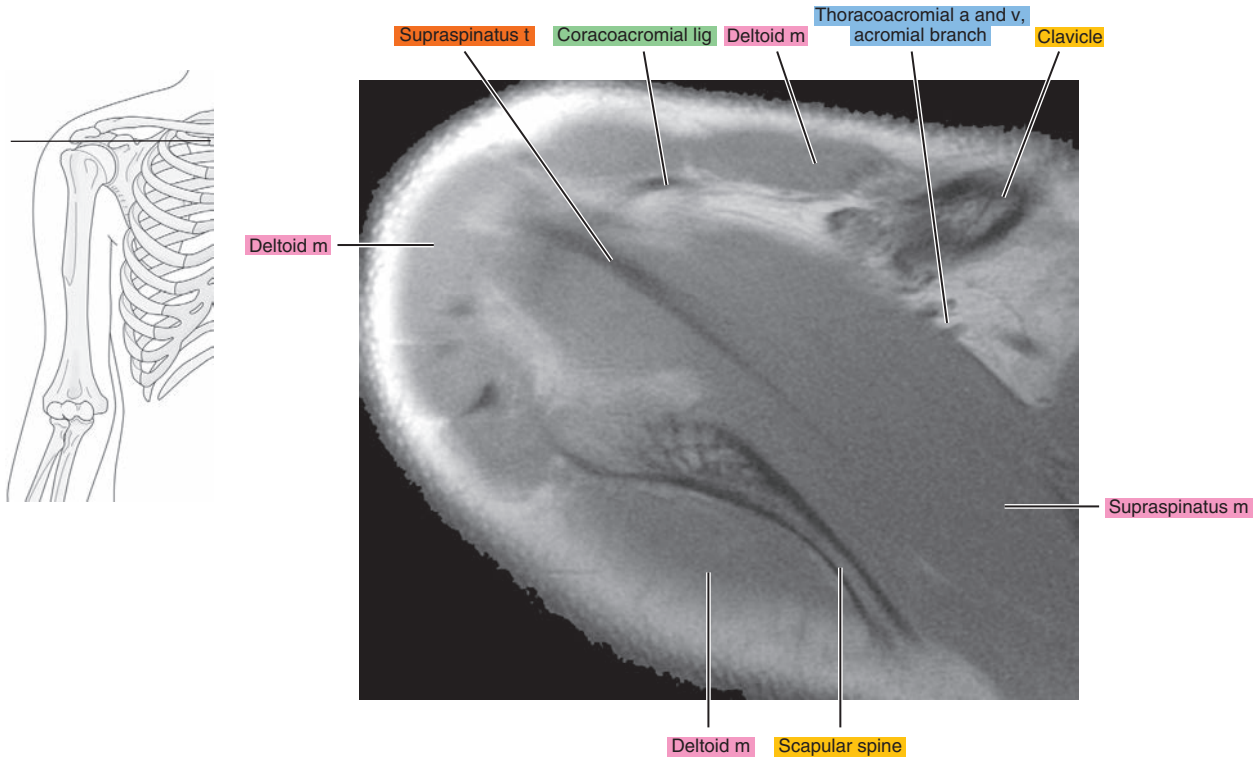


Figure 6.1.6

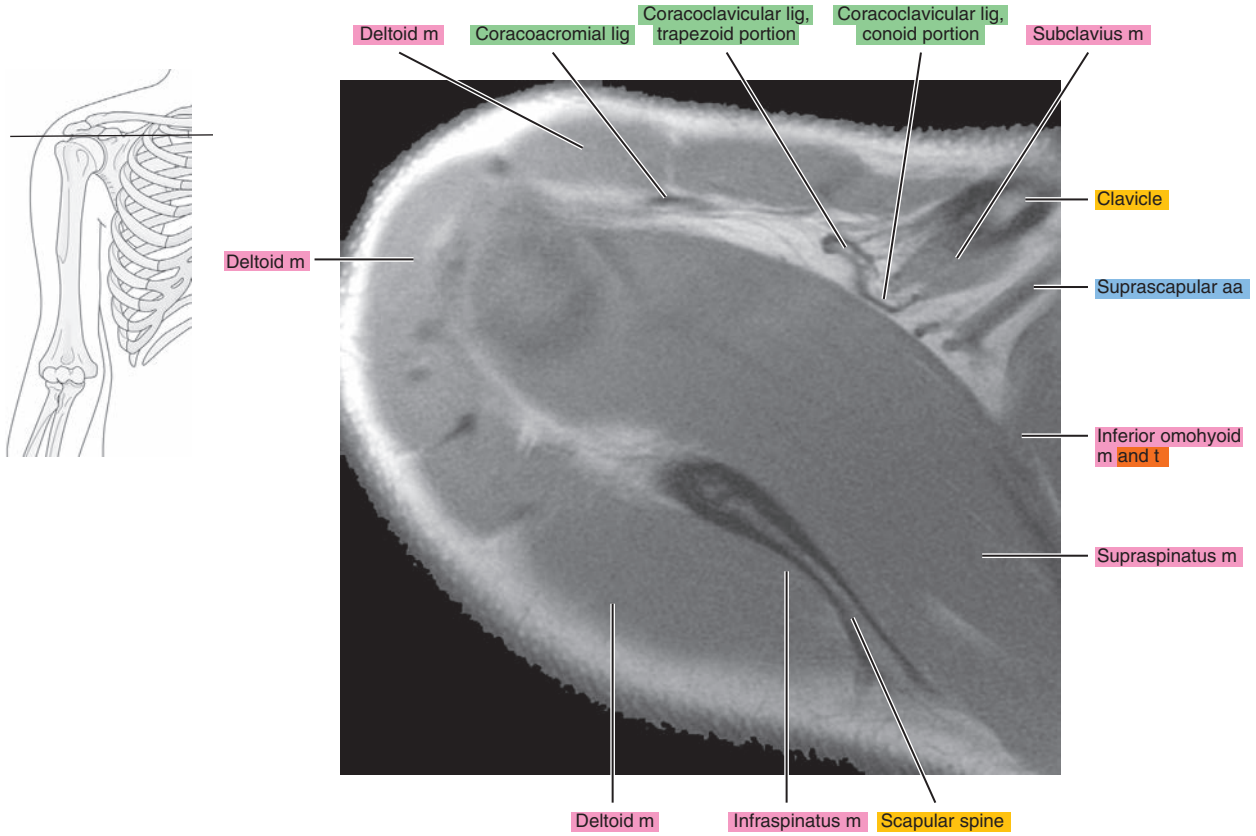


Figure 6.1.7

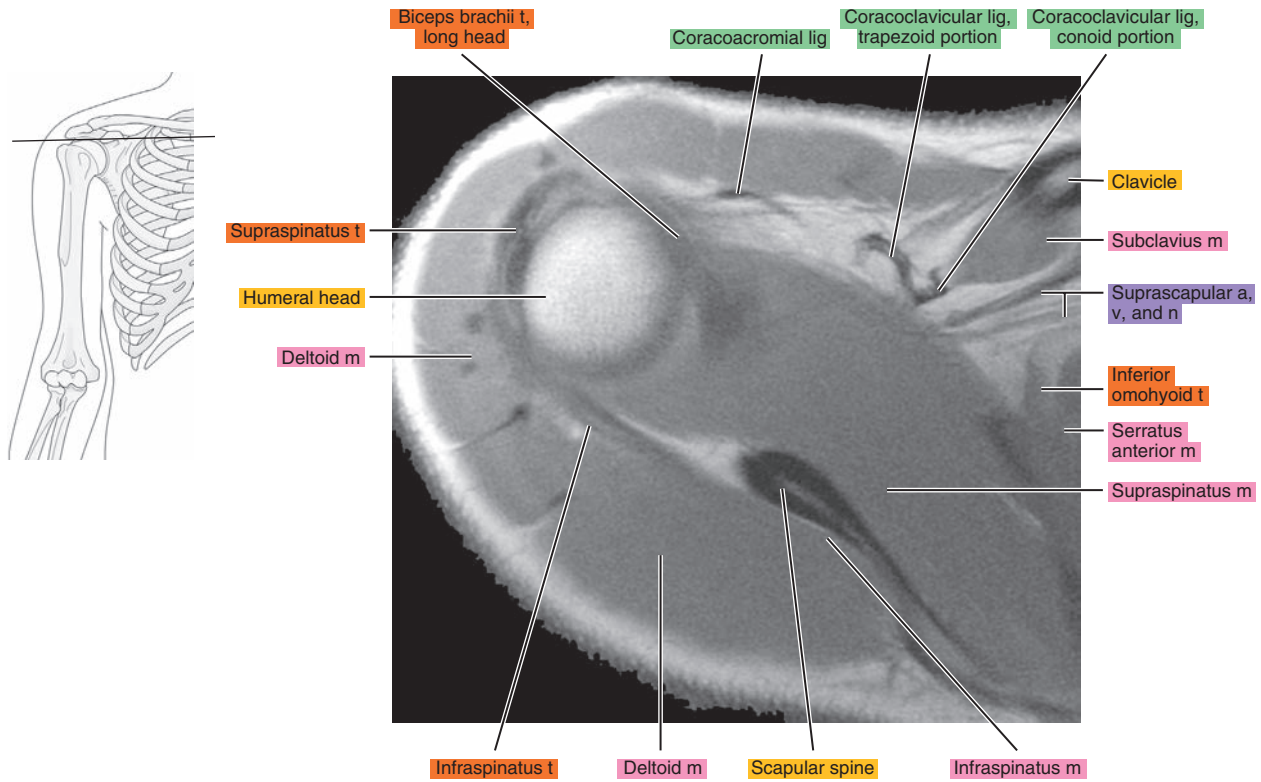


Figure 6.1.8

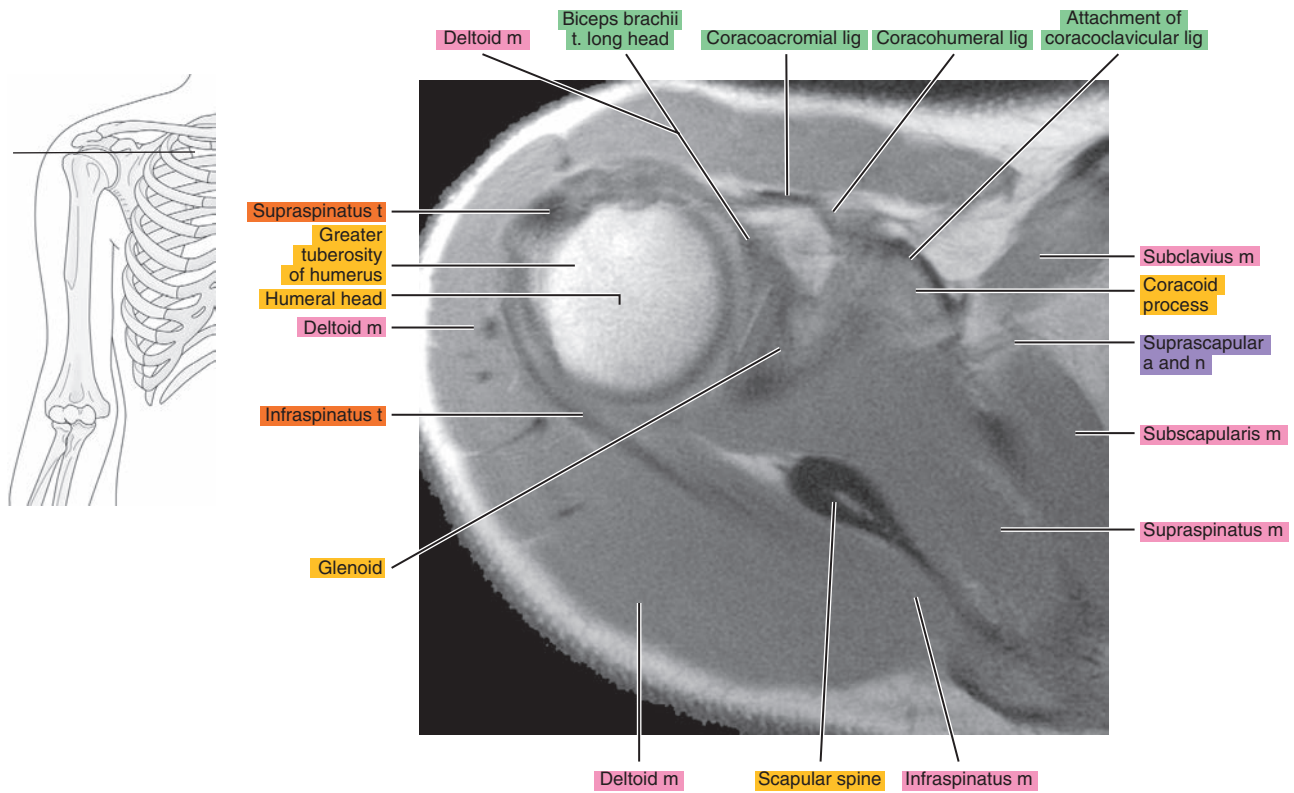




Figure 6.1.9

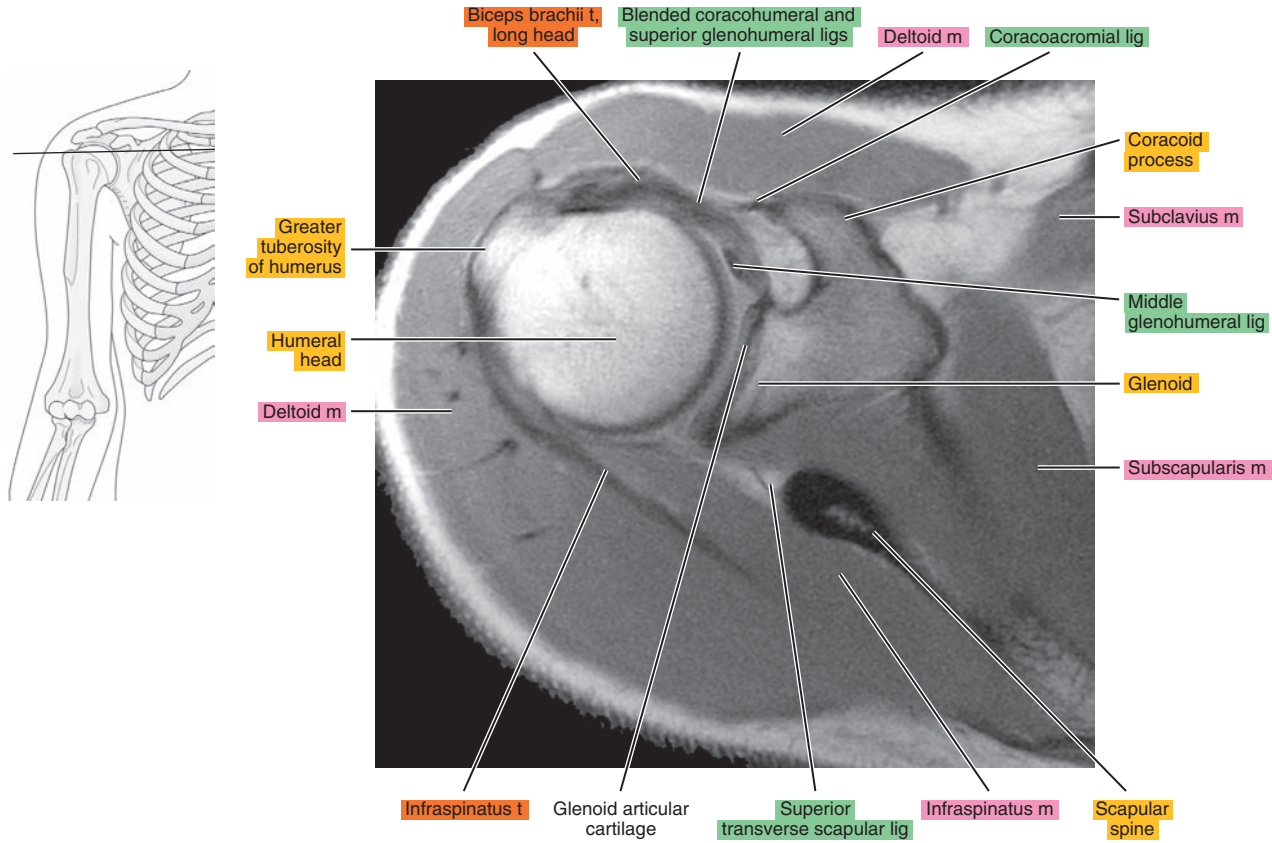


Figure 6.1.10

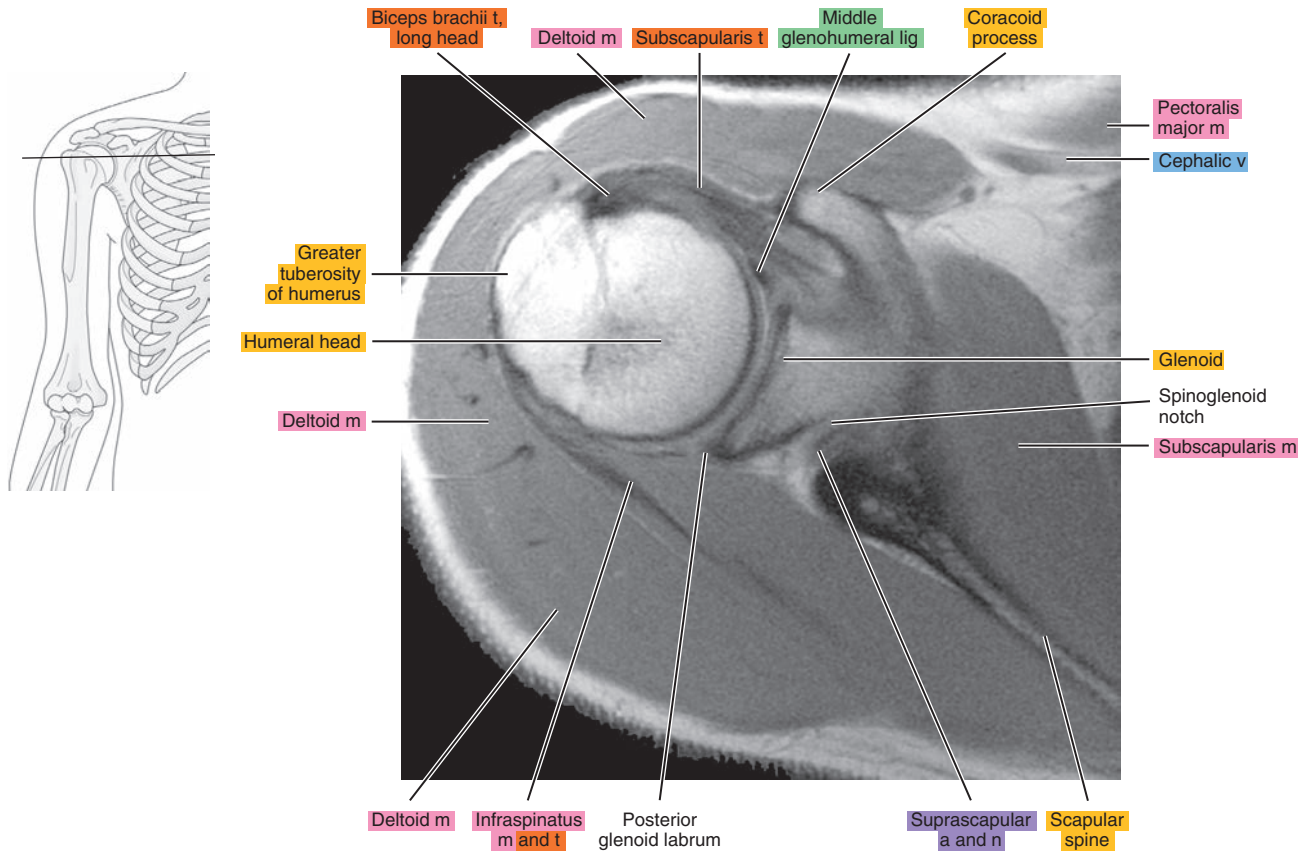


Figure 6.1.11

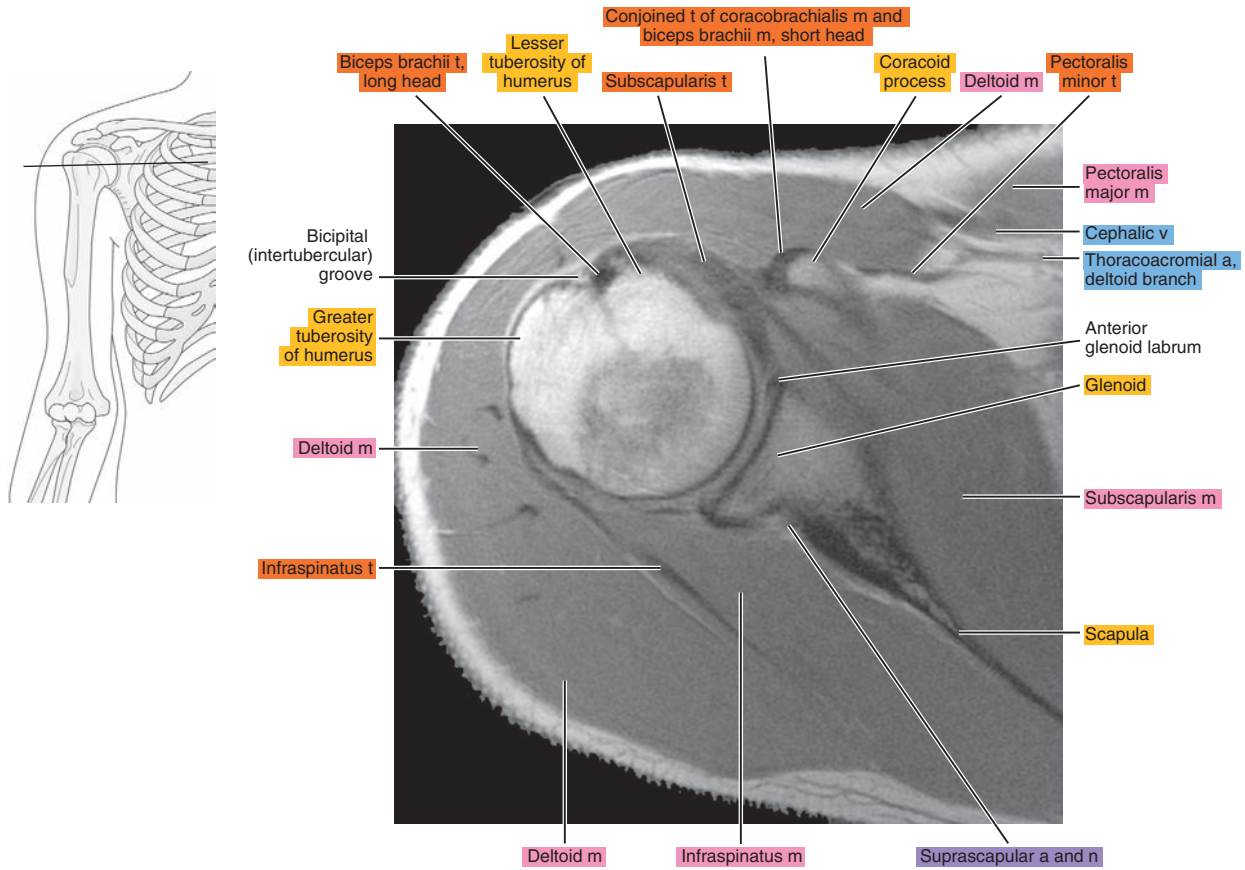


Figure 6.1.12

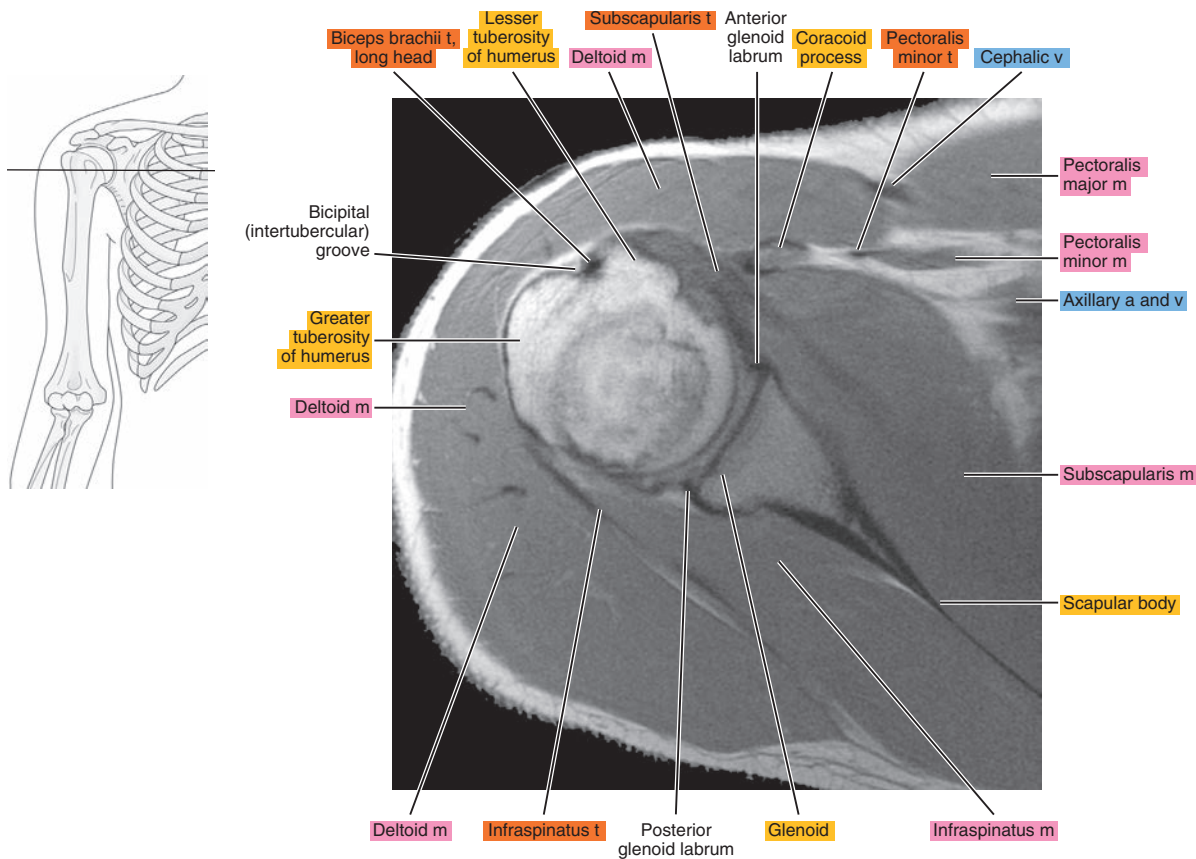


Figure 6.1.13

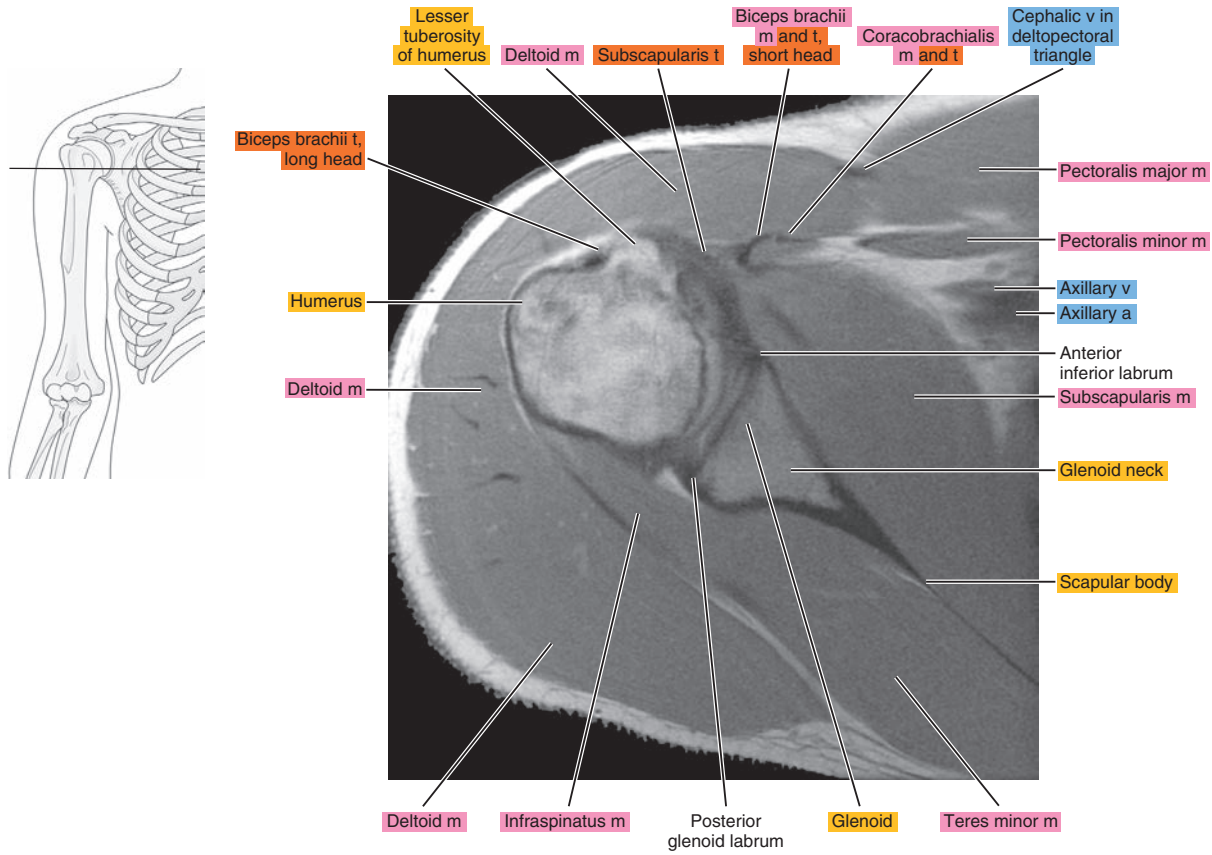


Figure 6.1.14

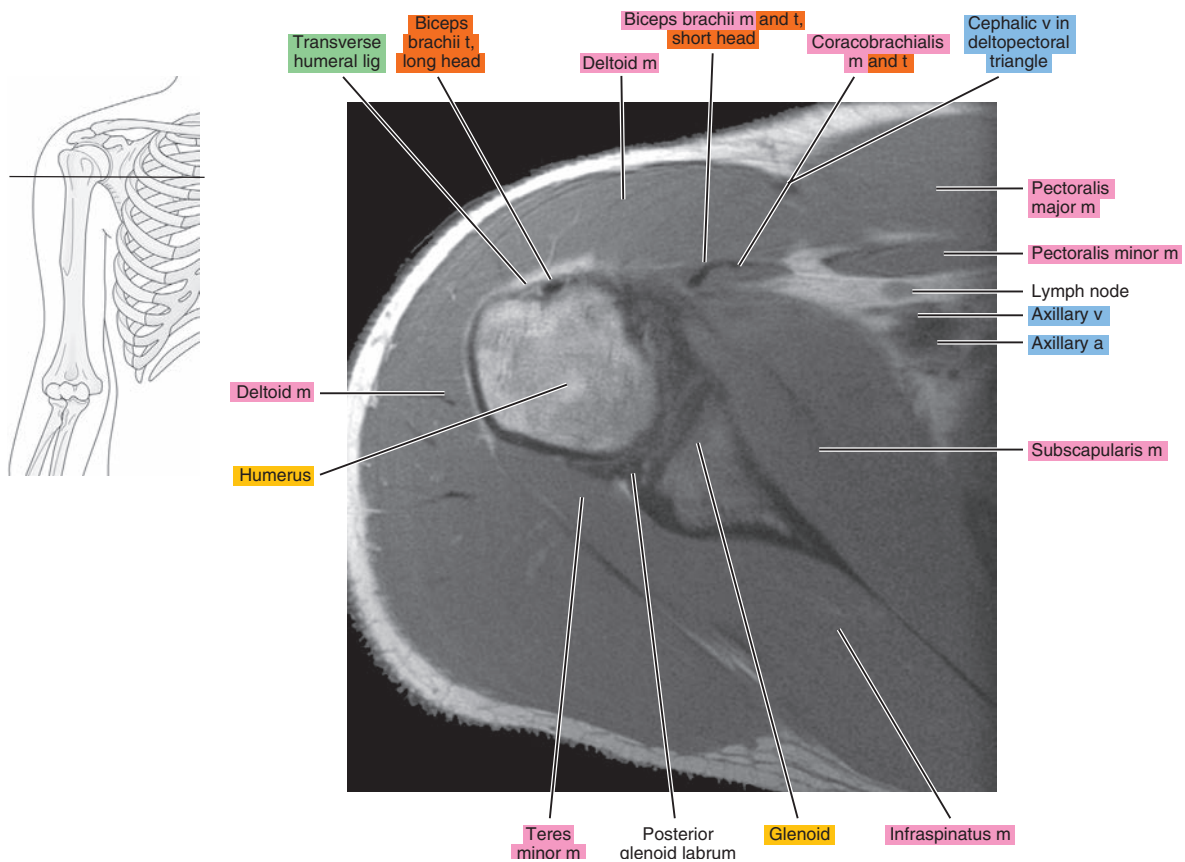




Figure 6.1.15

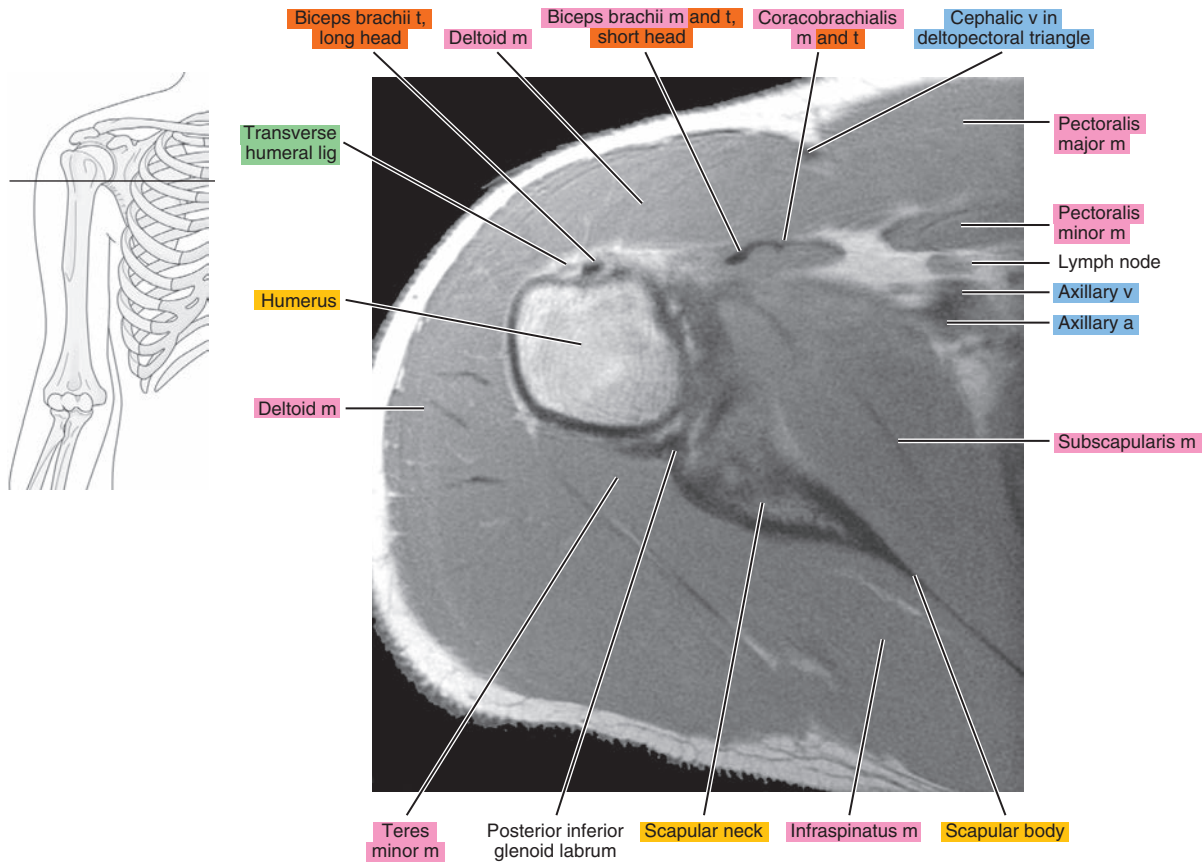


Figure 6.1.16

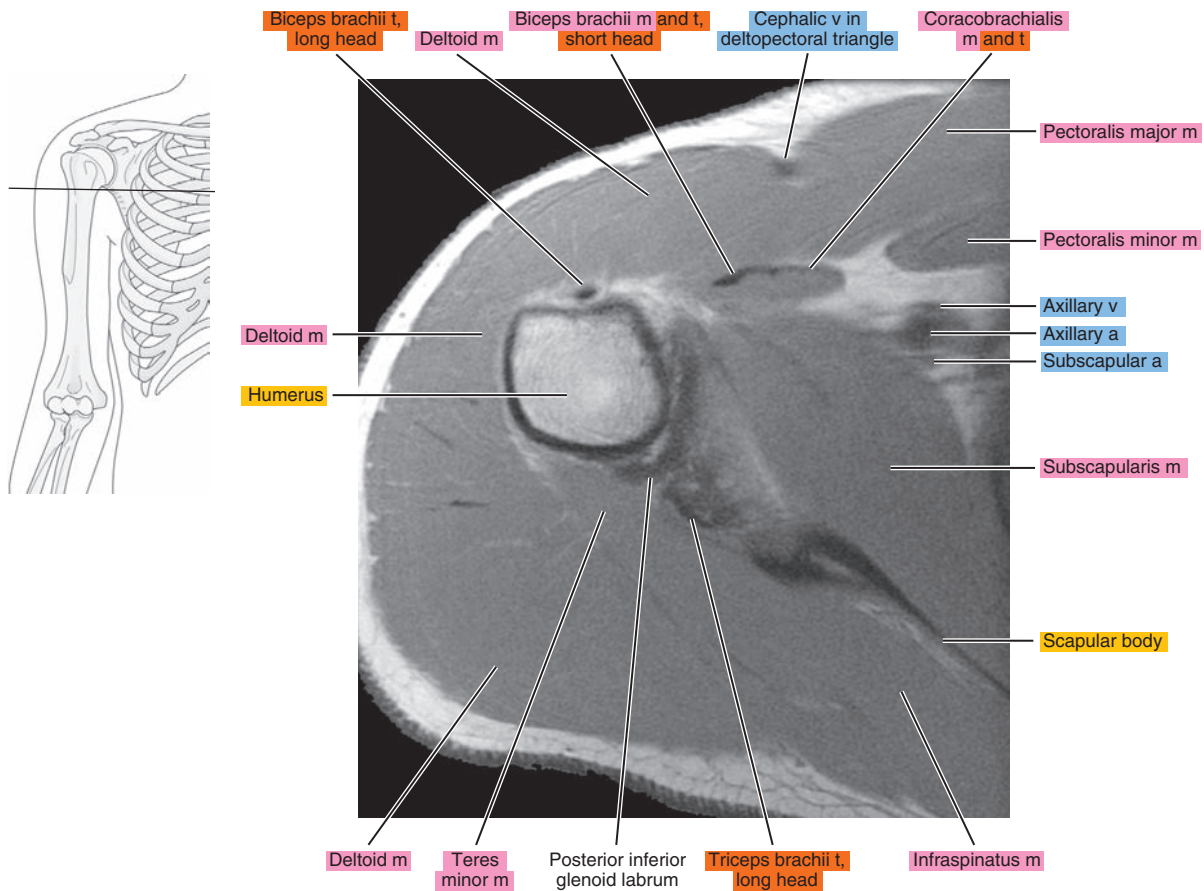




Figure 6.1.17

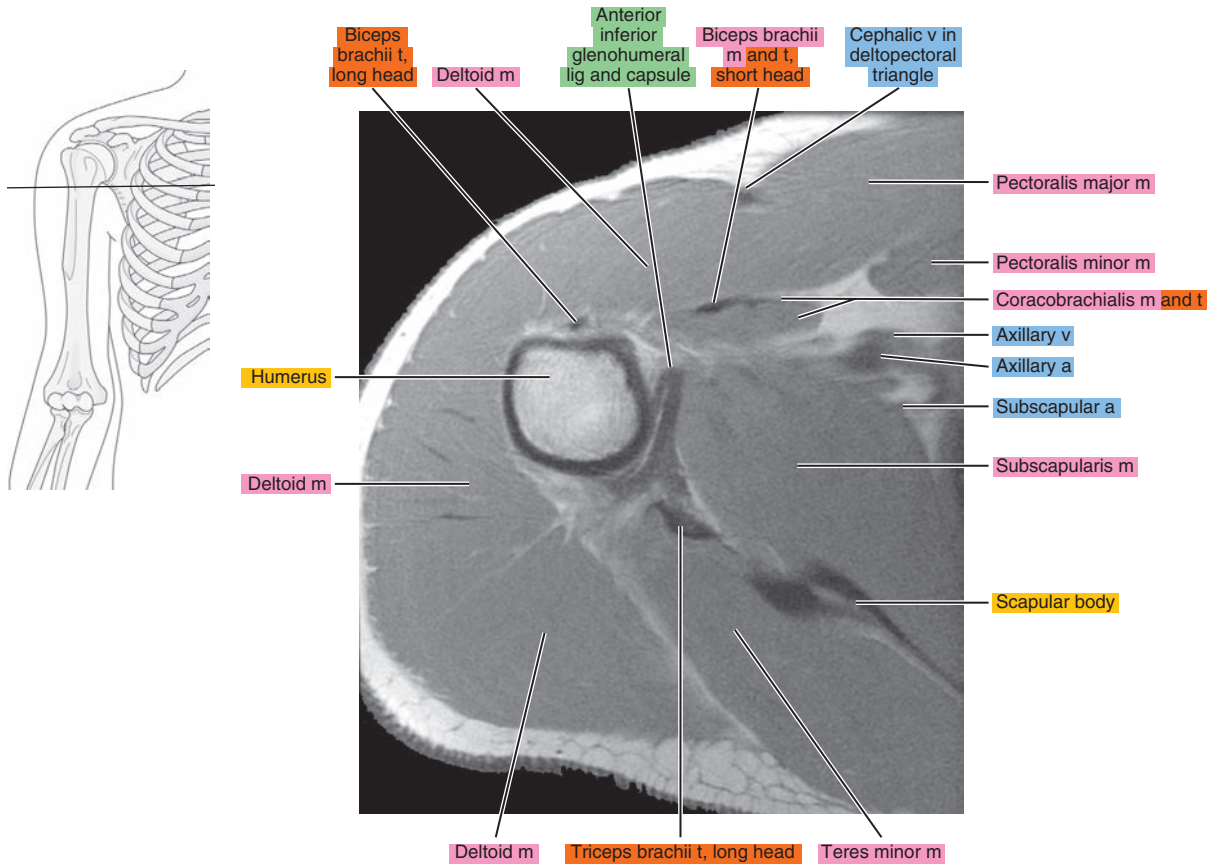


Figure 6.1.18

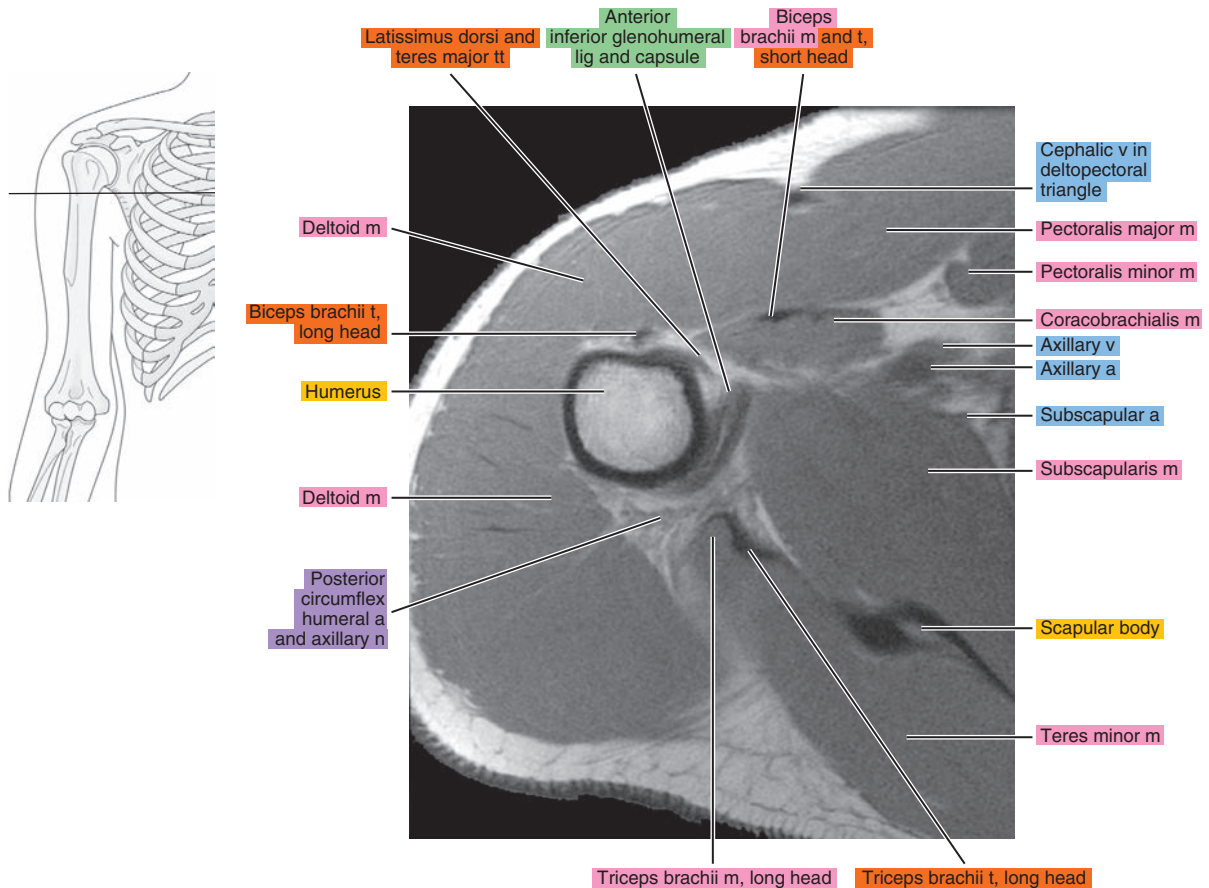


Figure 6.1.19

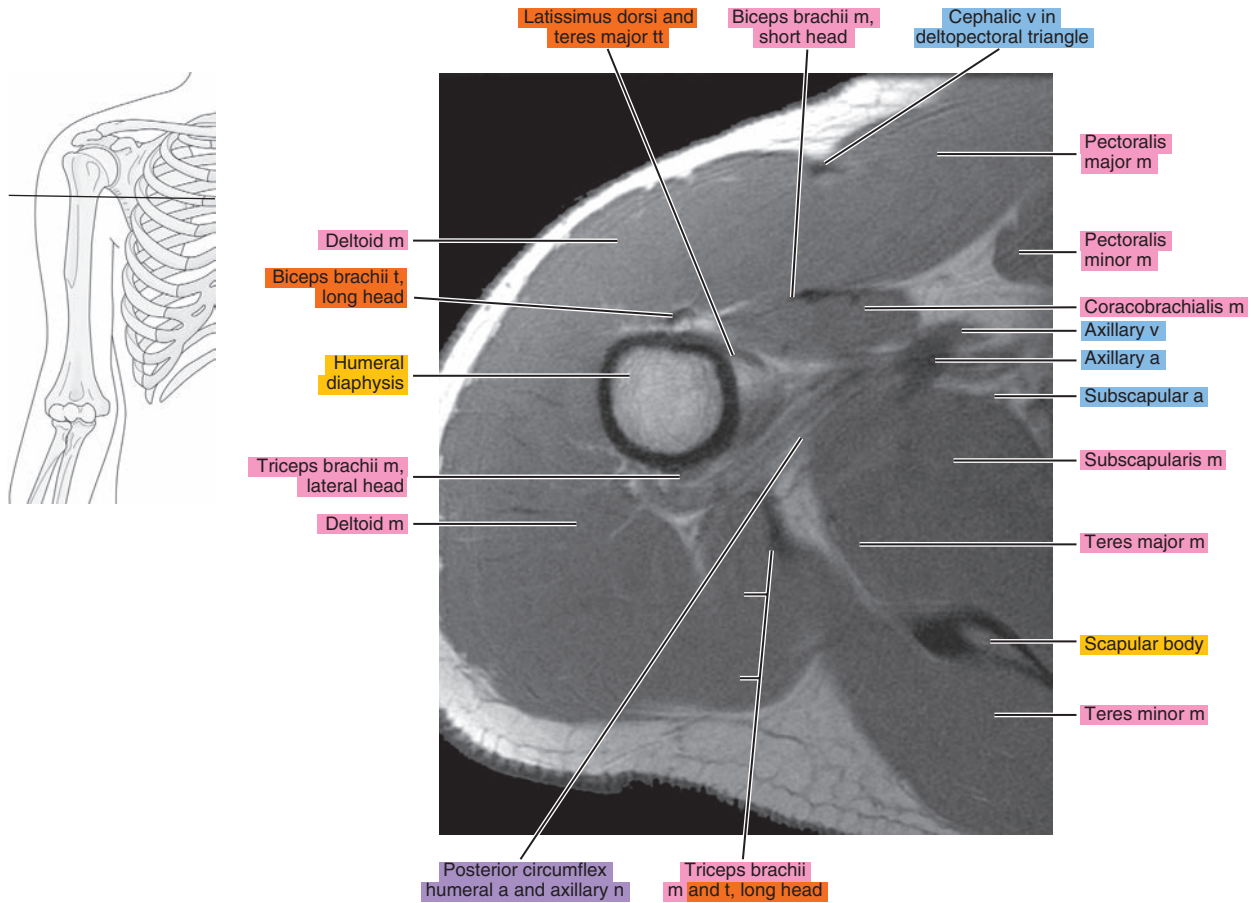
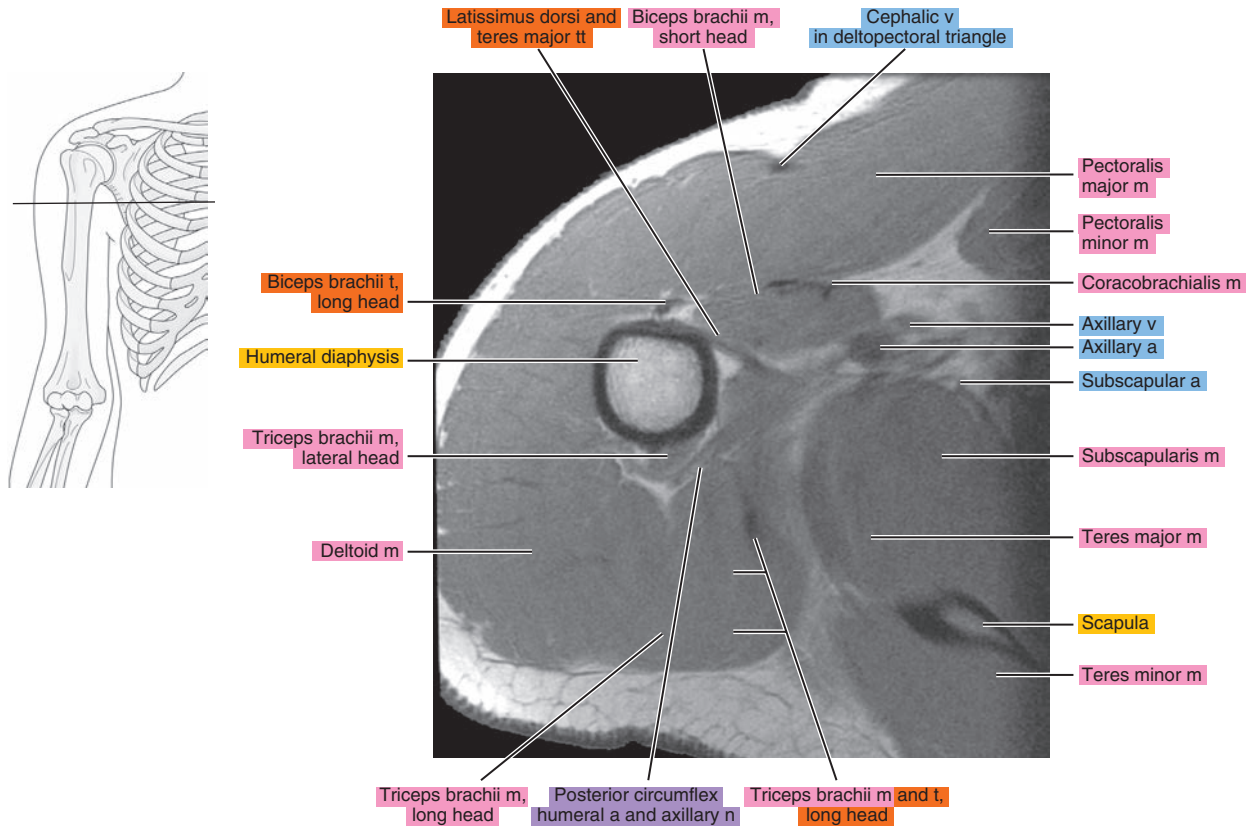
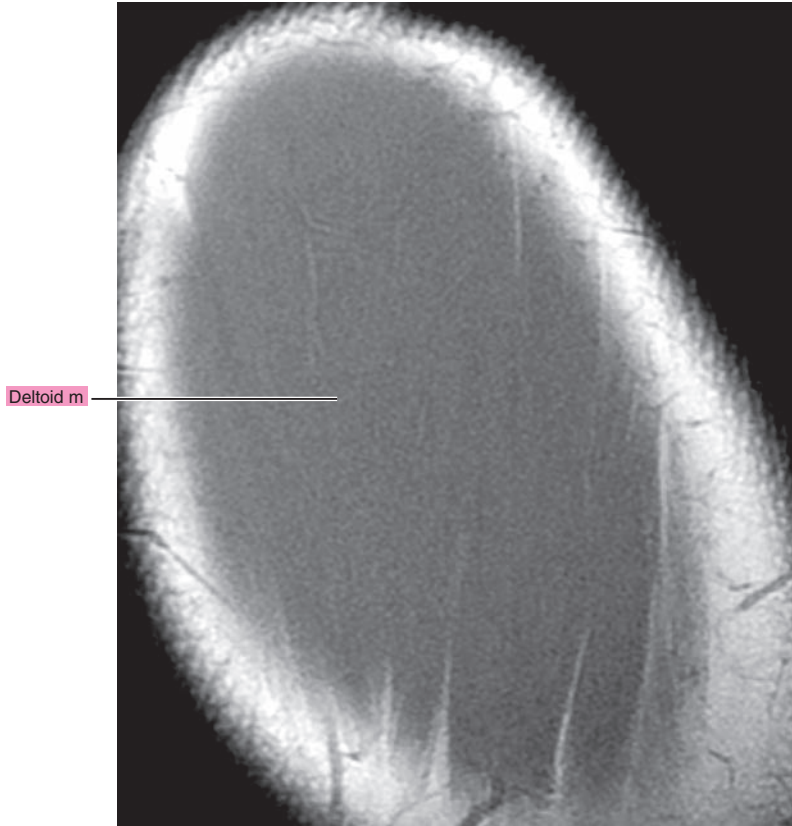
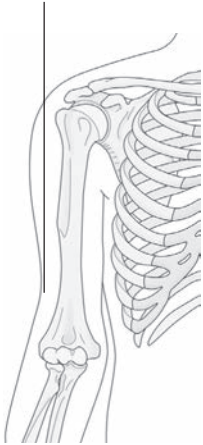


Figure 6.1.20



# OBLIQUE SAGITTAL

Figure 6.2.1



artery = a
arteries = aa
vein = v
veins = vv
muscle = m
muscles = mm
tendon = t
tendons = tt
nerve = n
nerves = nn
ligament = lig
ligaments = ligs
nerve & vessels
bone

Figure 6.2.2

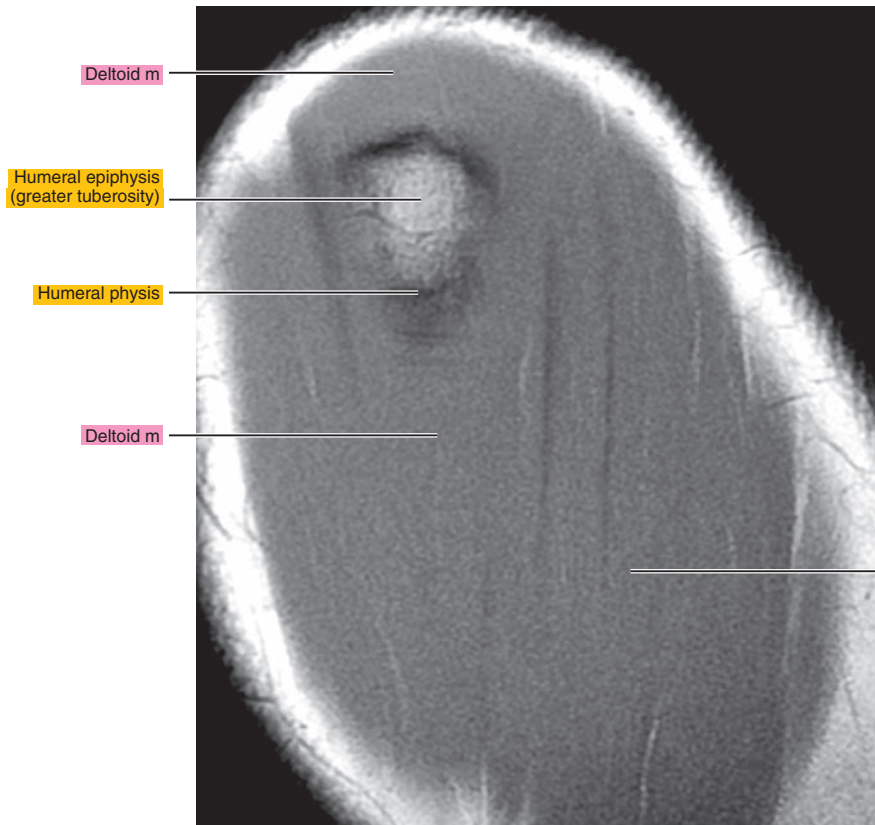
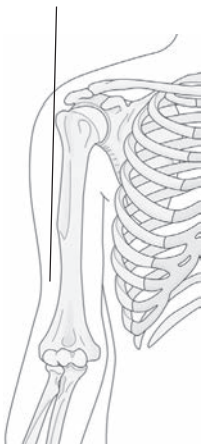




Figure 6.2.3

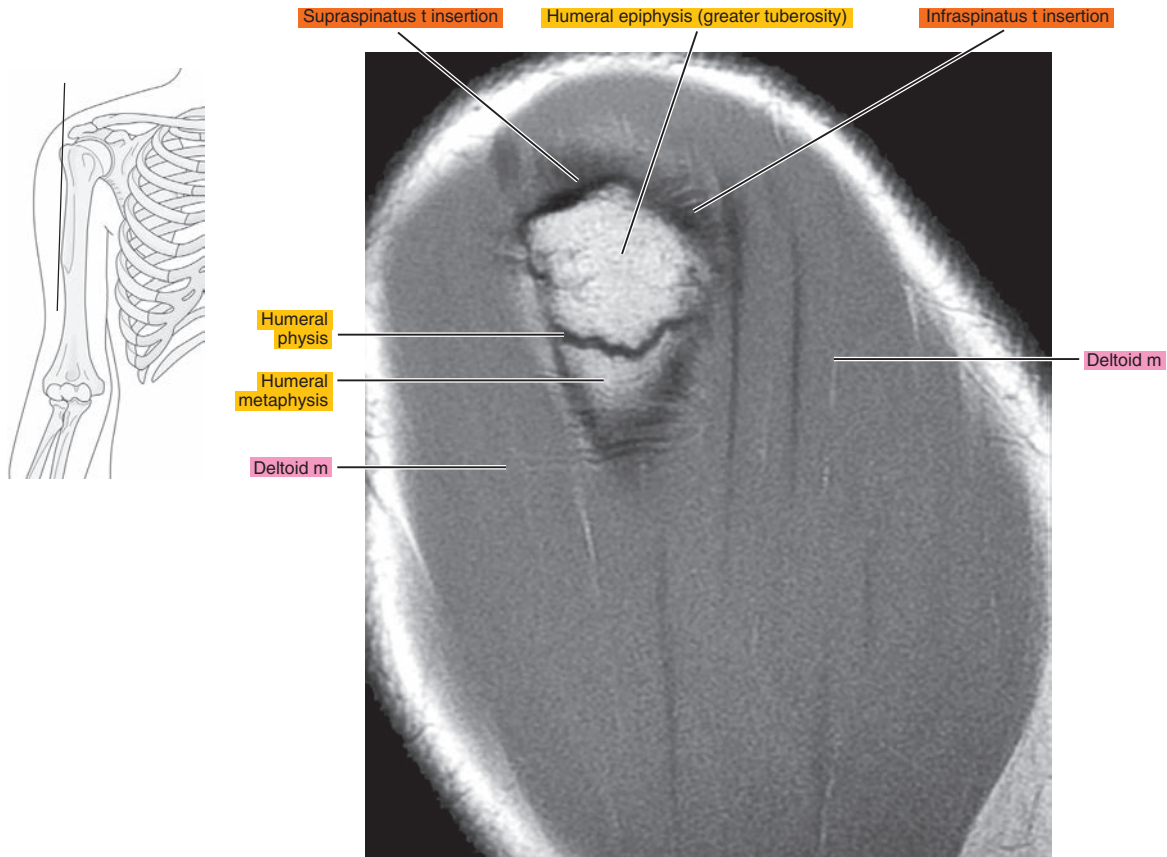


Figure 6.2.4

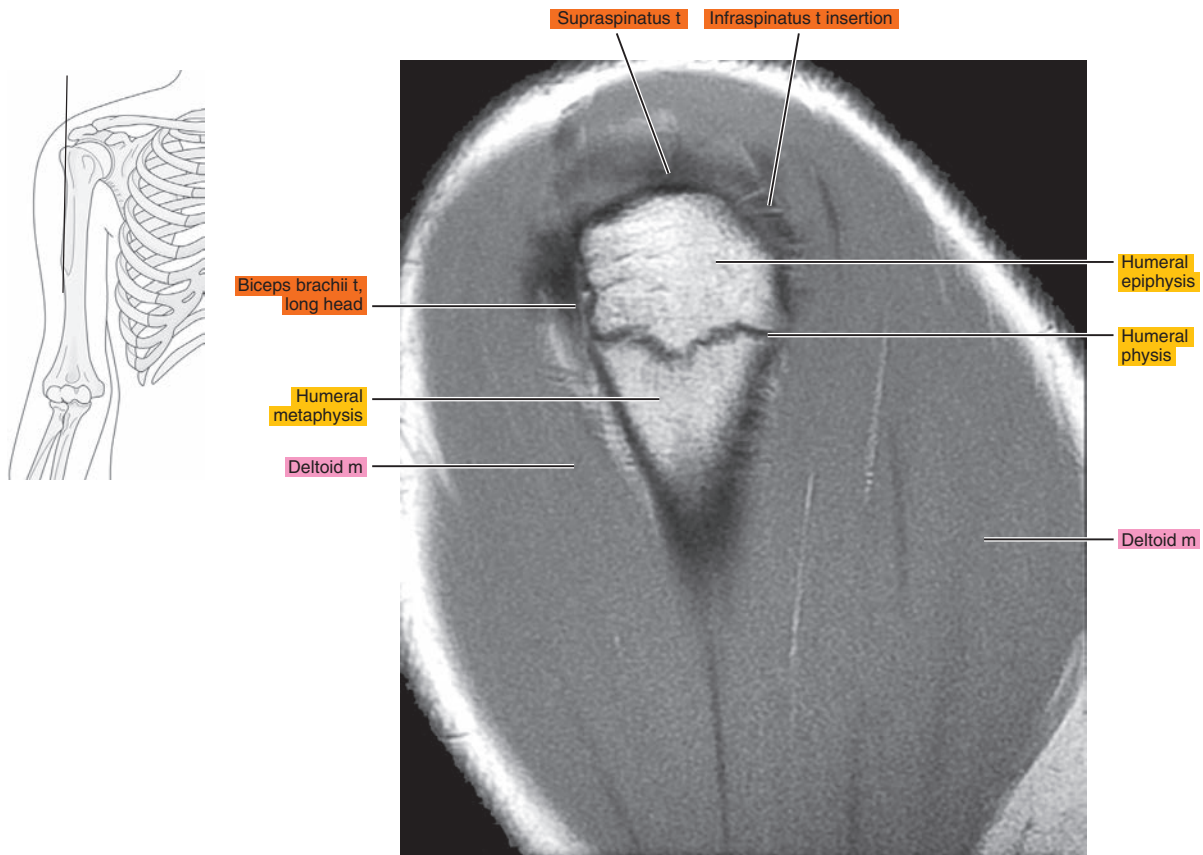




Figure 6.2.5

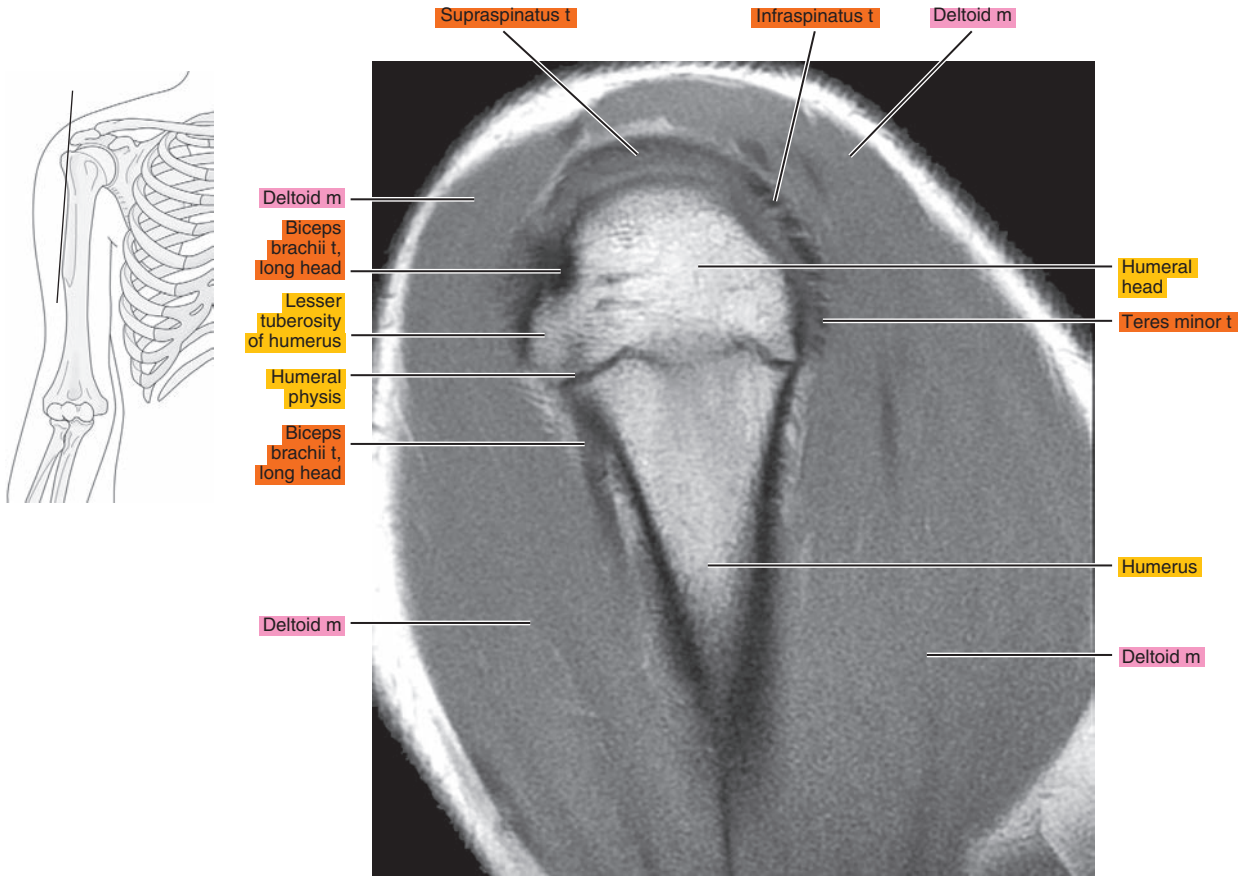


Figure 6.2.6

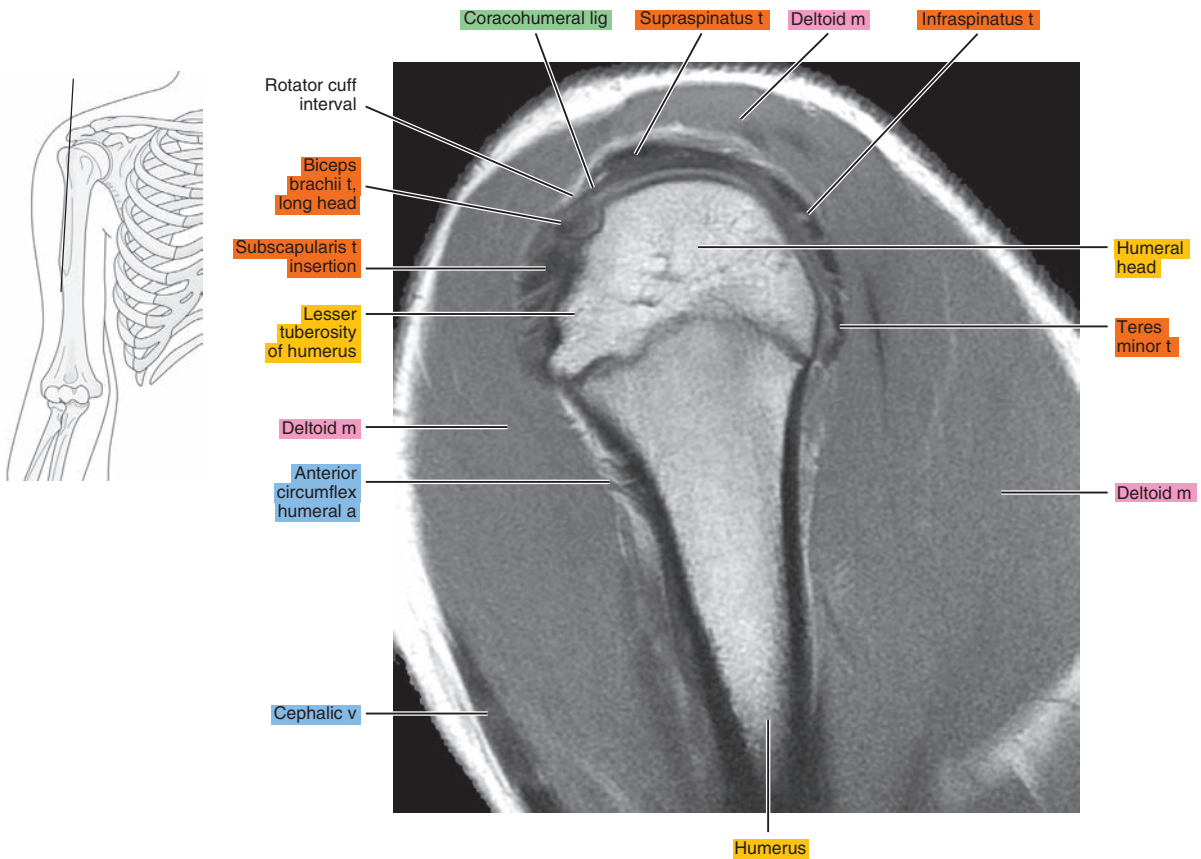


Figure 6.2.7

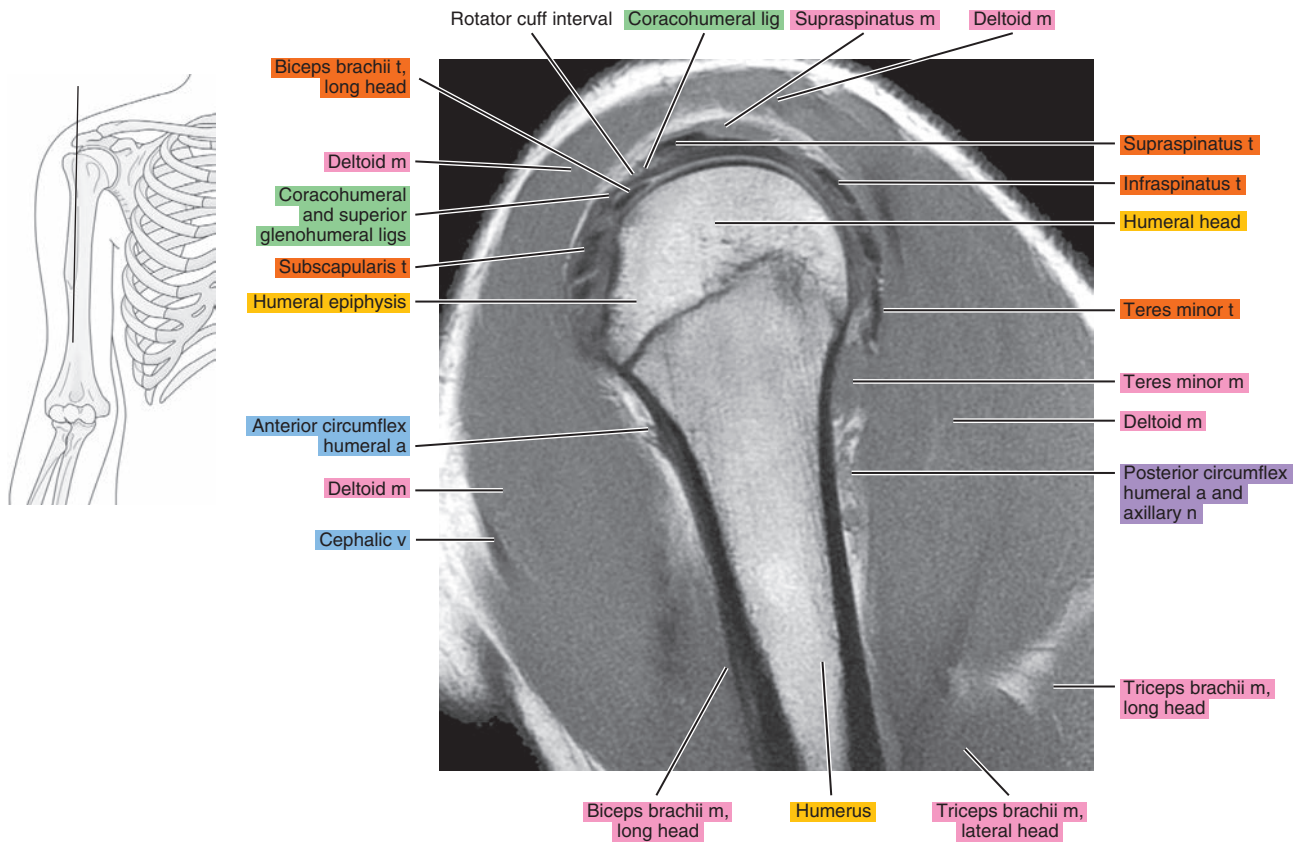


Figure 6.2.8

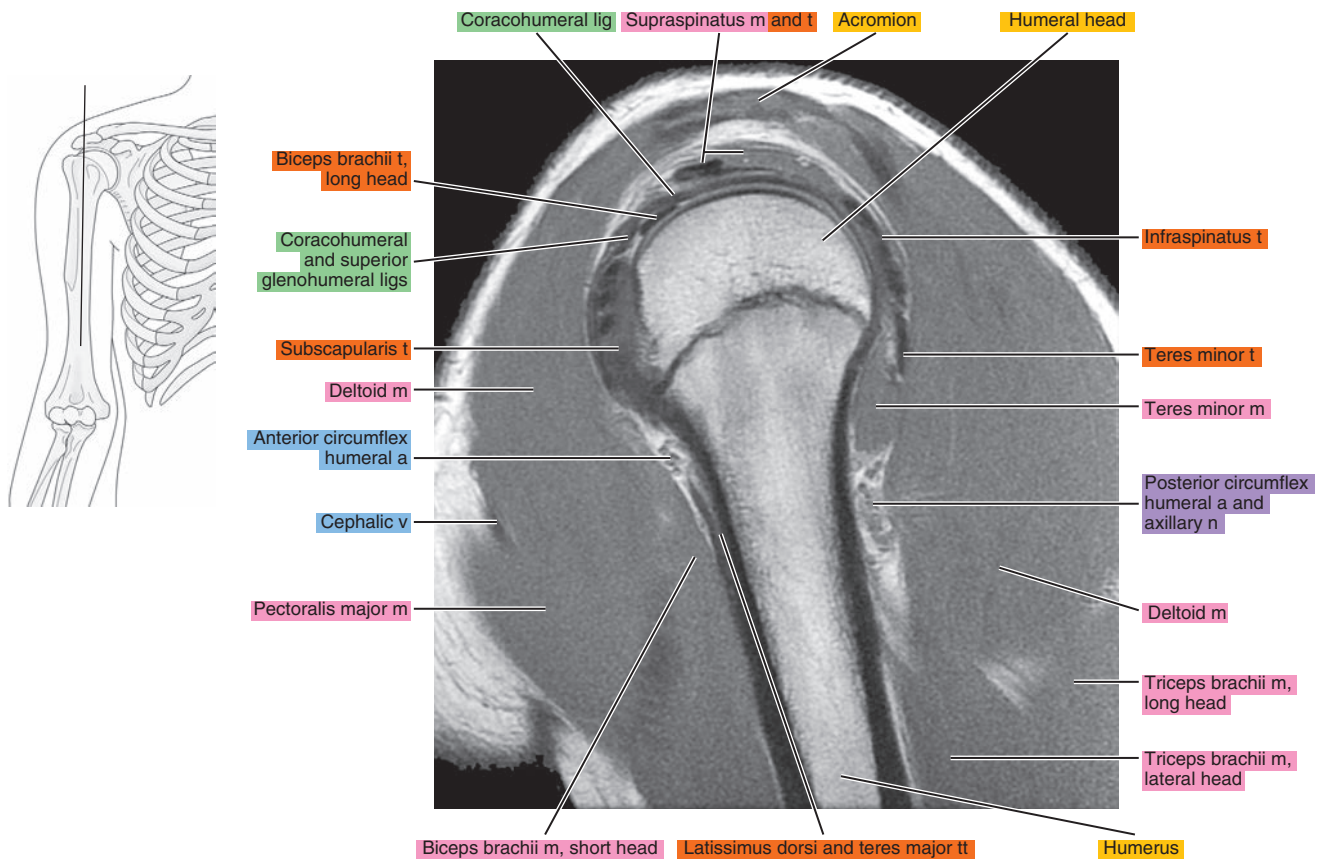




Figure 6.2.9

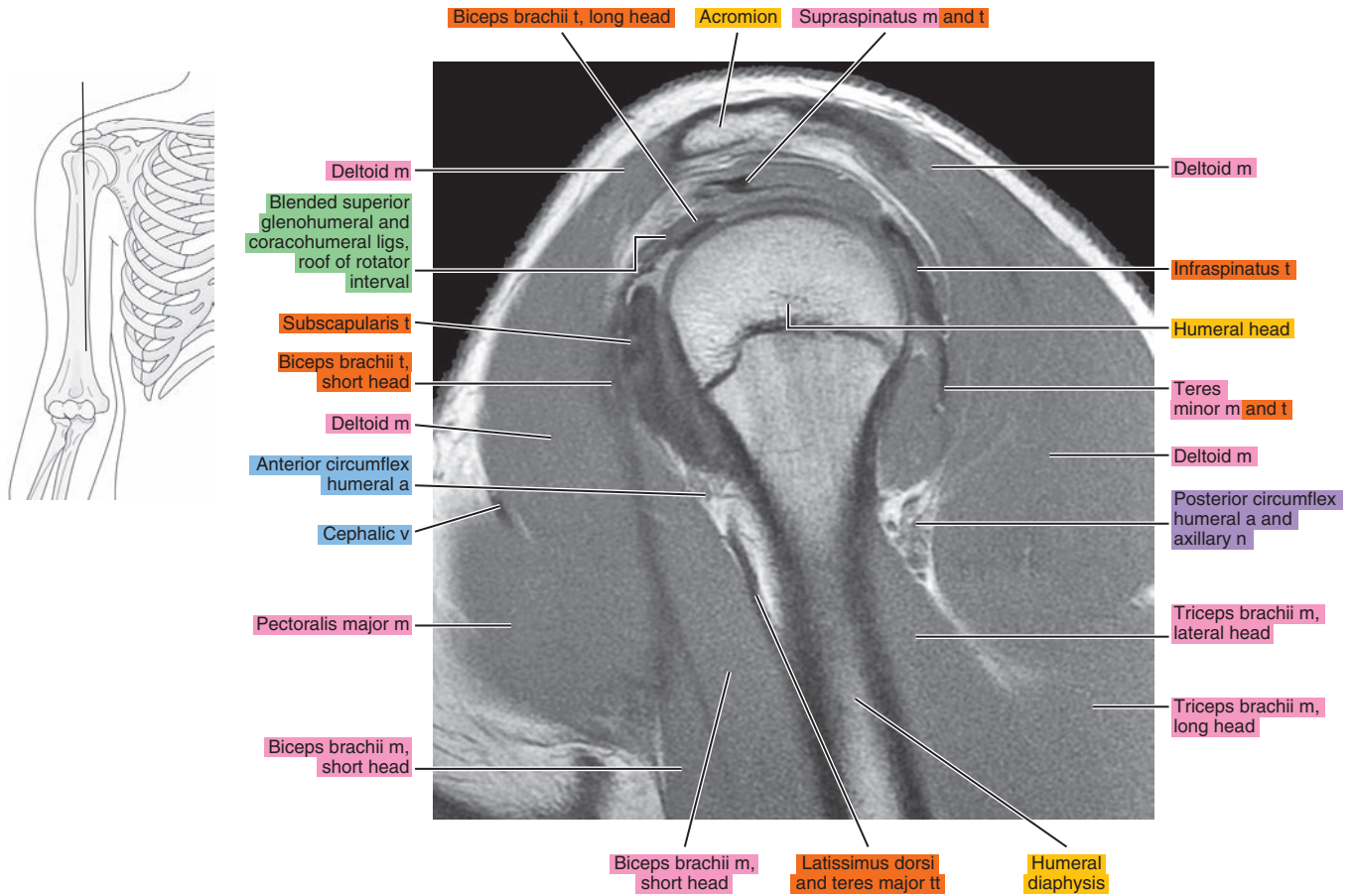


Figure 6.2.10

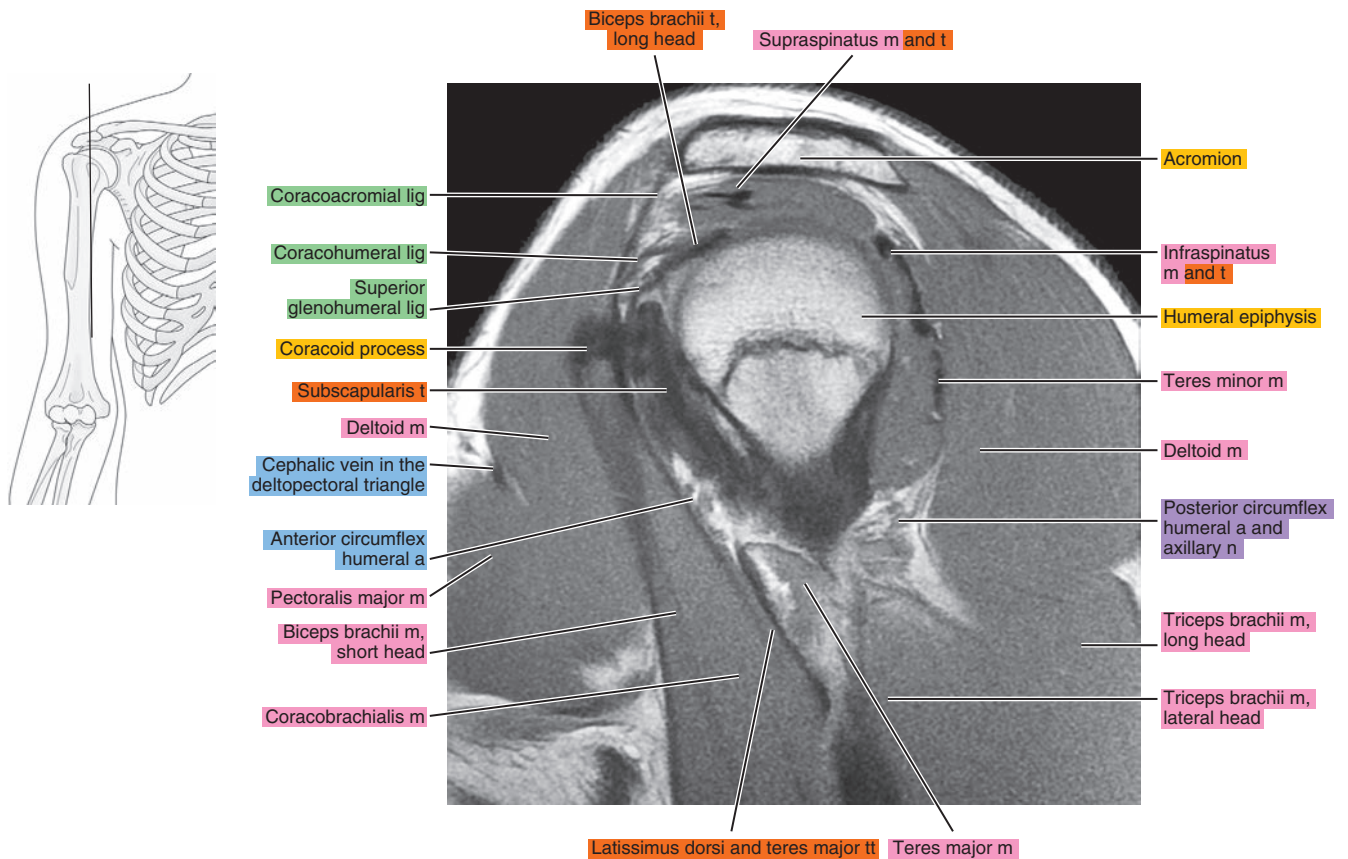


Figure 6.2.11

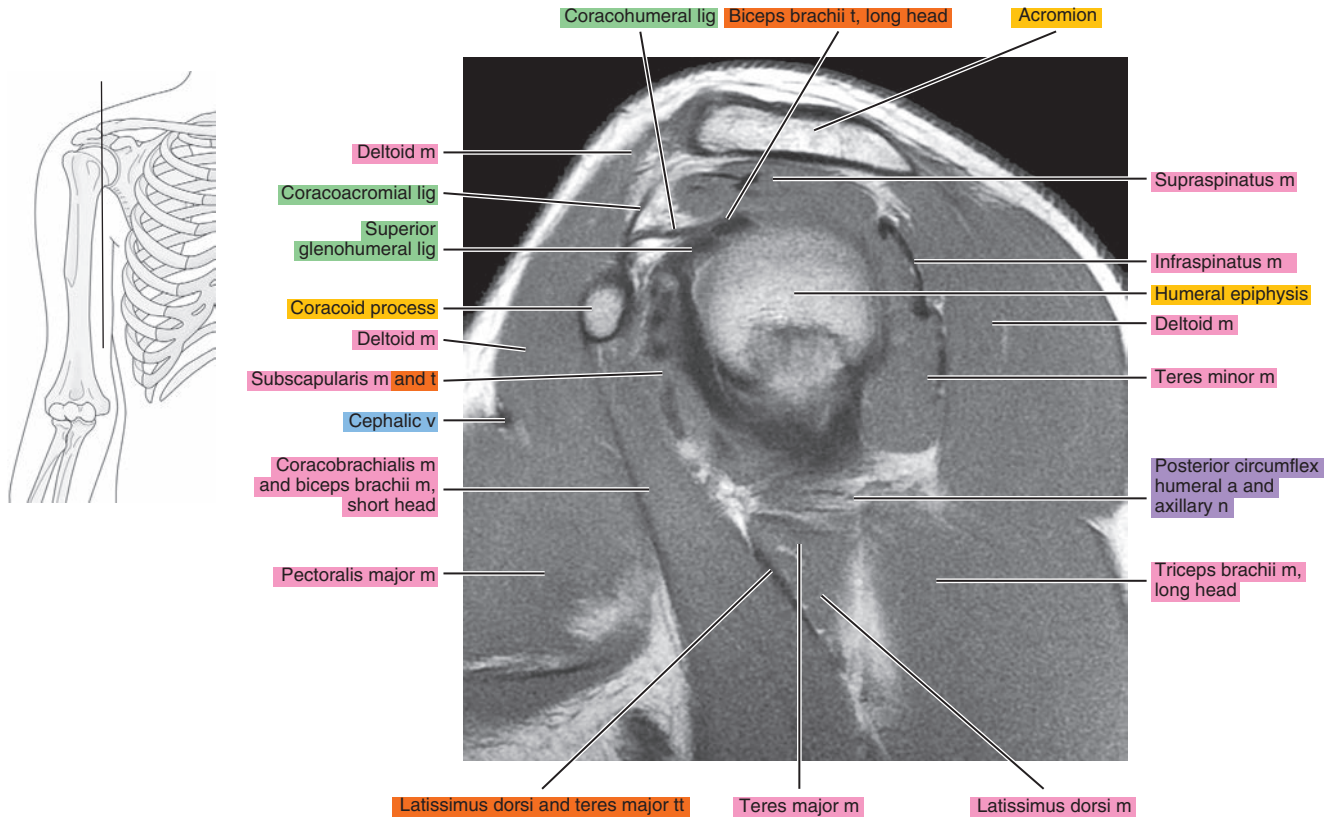


Figure 6.2.12

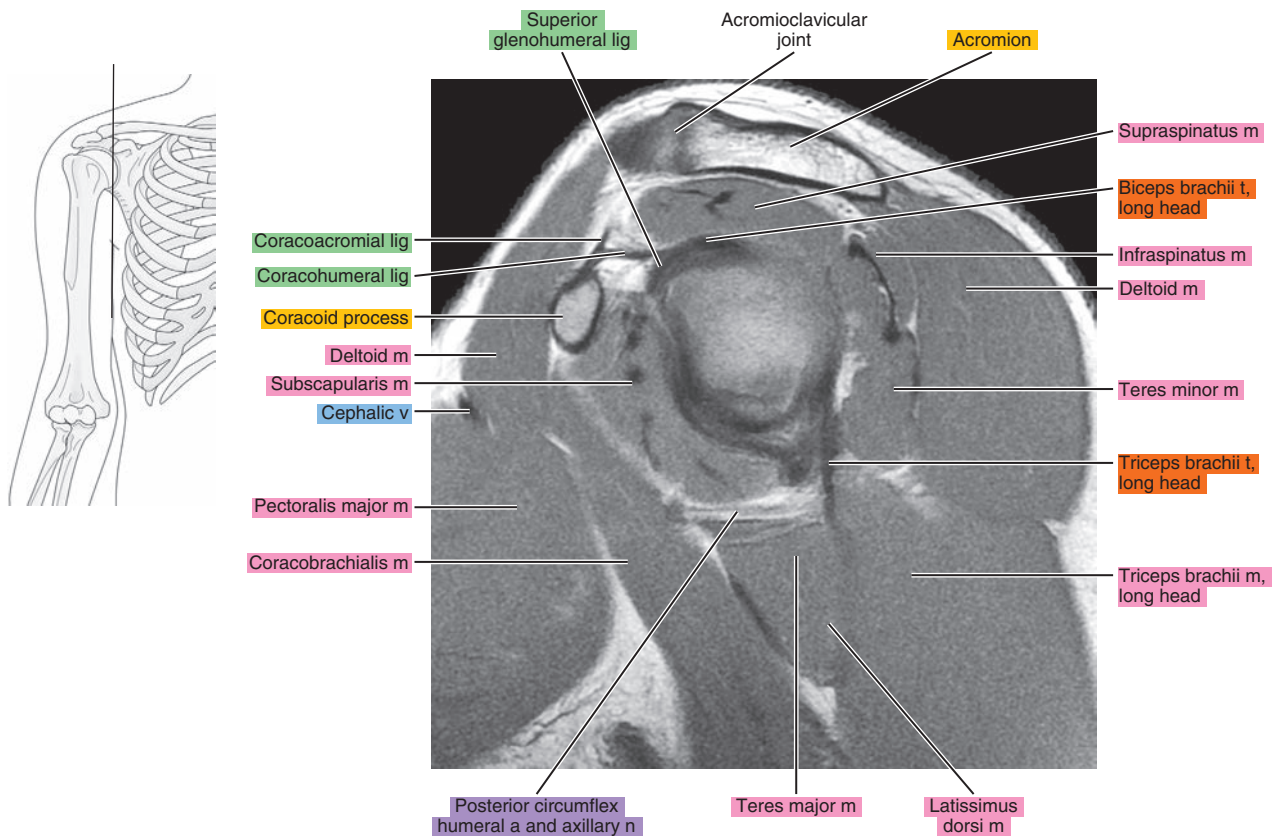




Figure 6.2.13

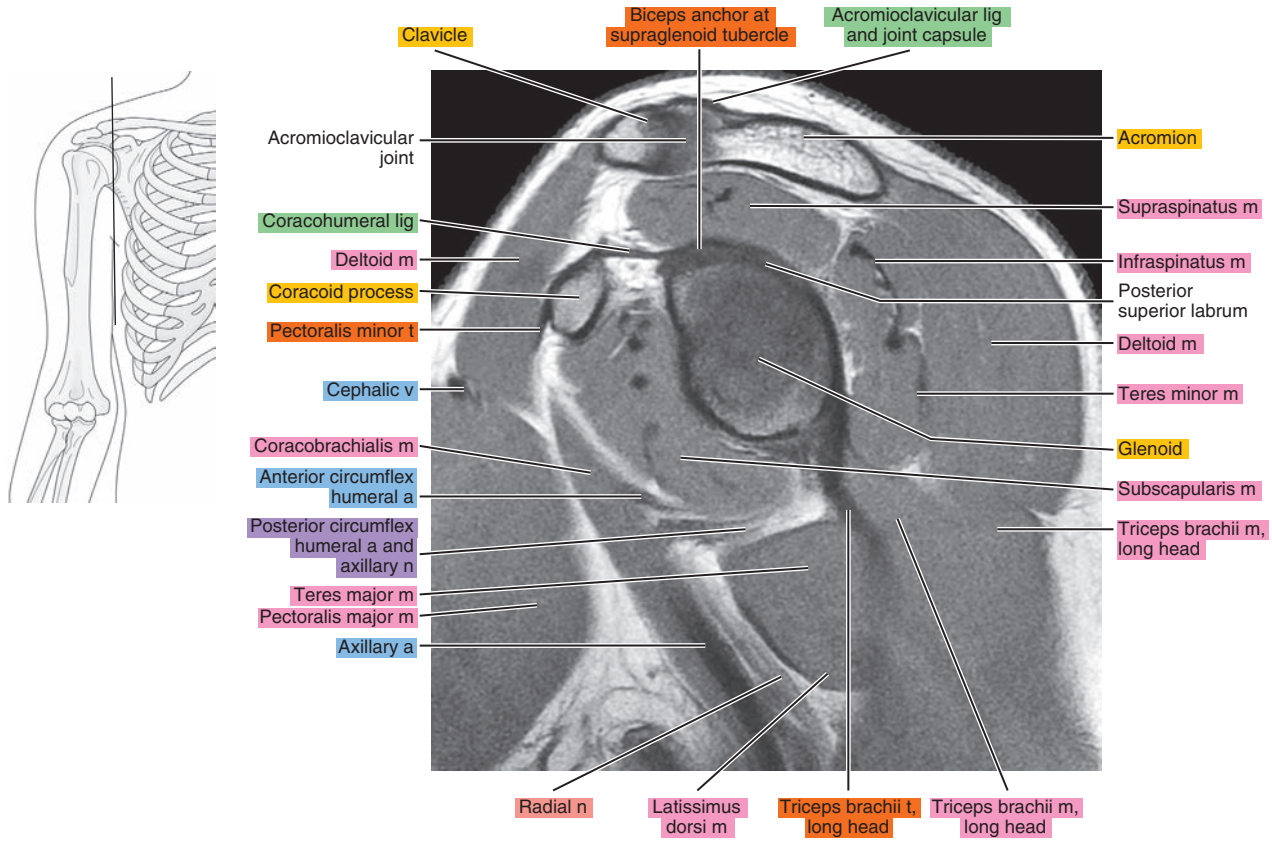


Figure 6.2.14

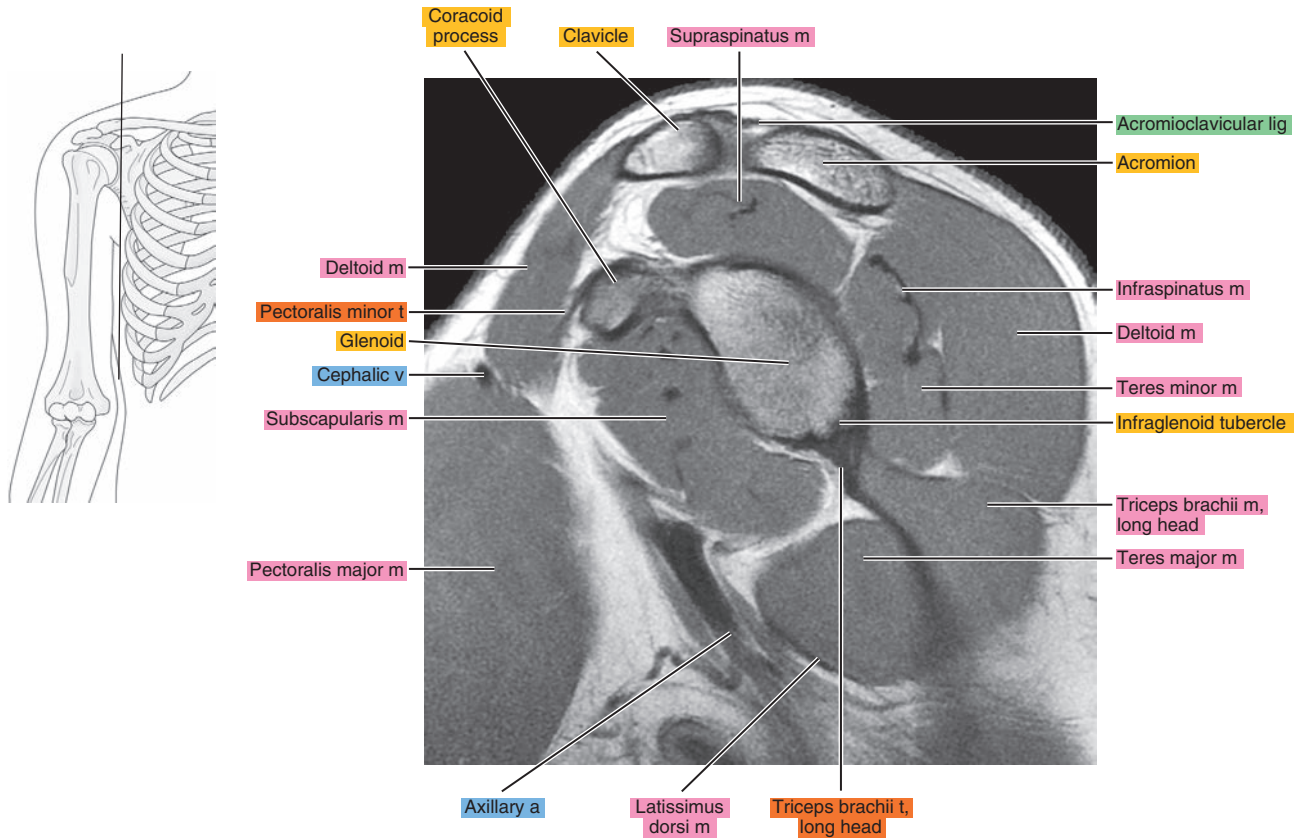


Figure 6.2.15

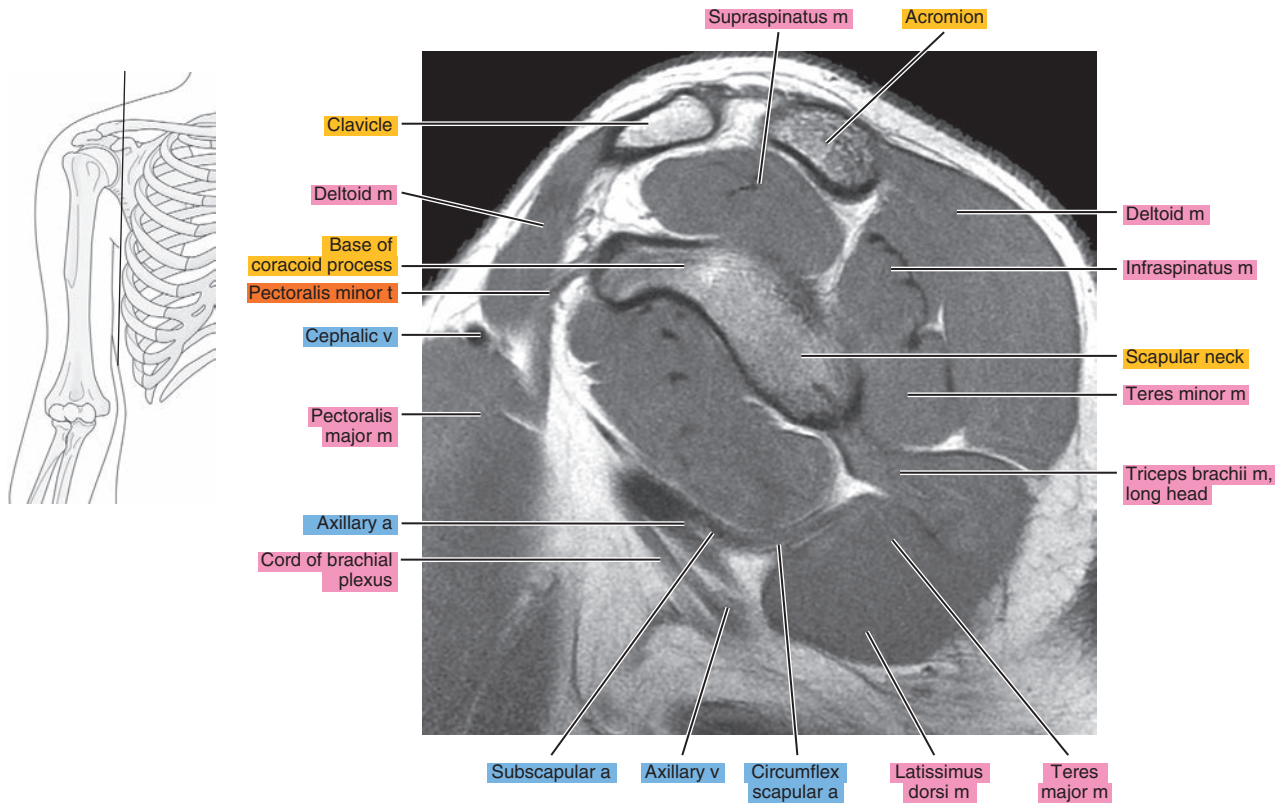


Figure 6.2.16

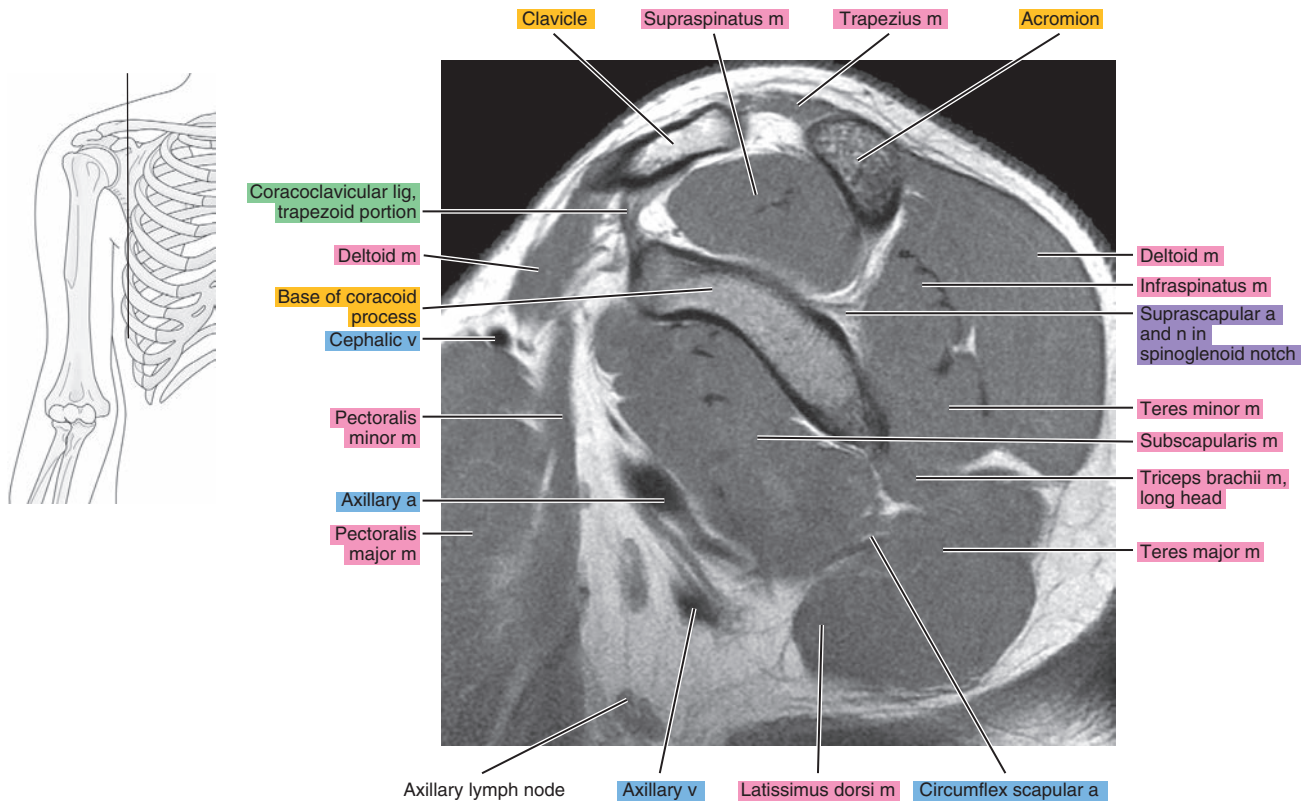




Figure 6.2.17

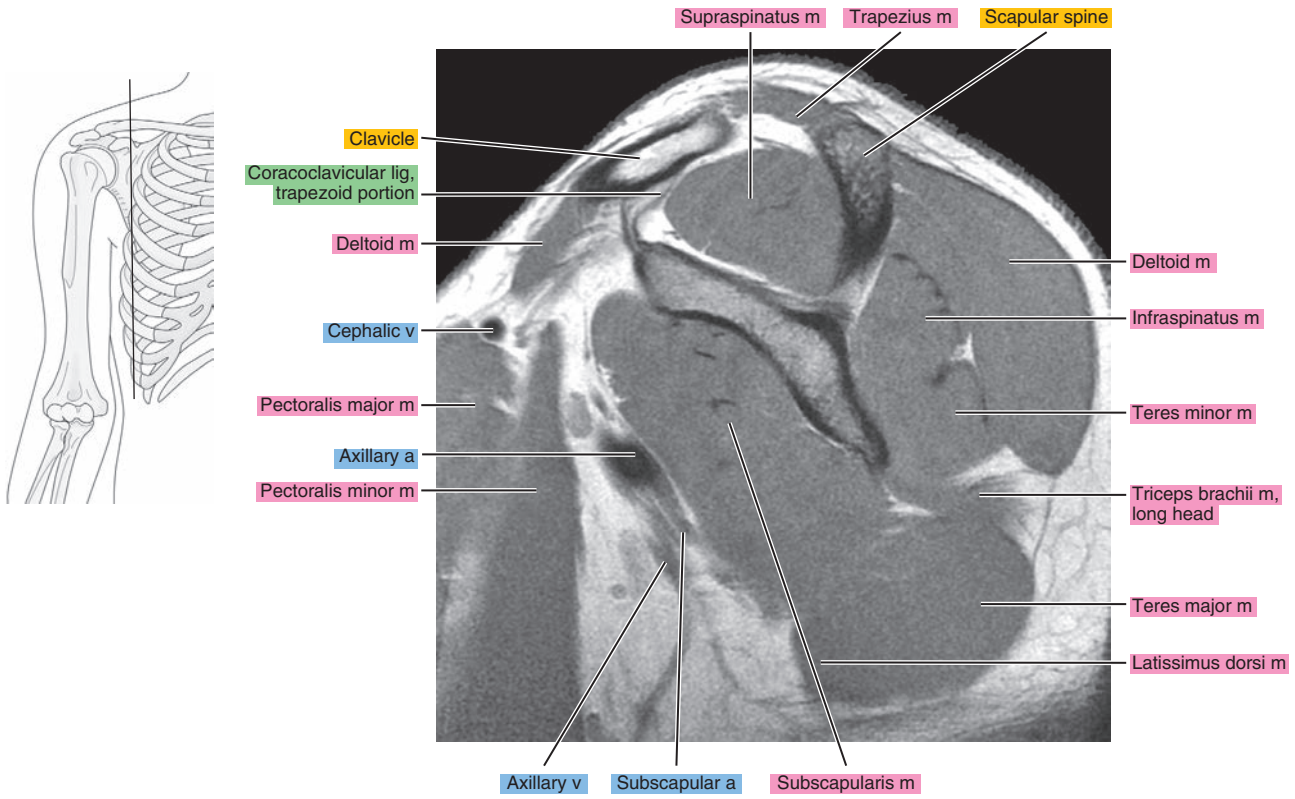


Figure 6.2.18

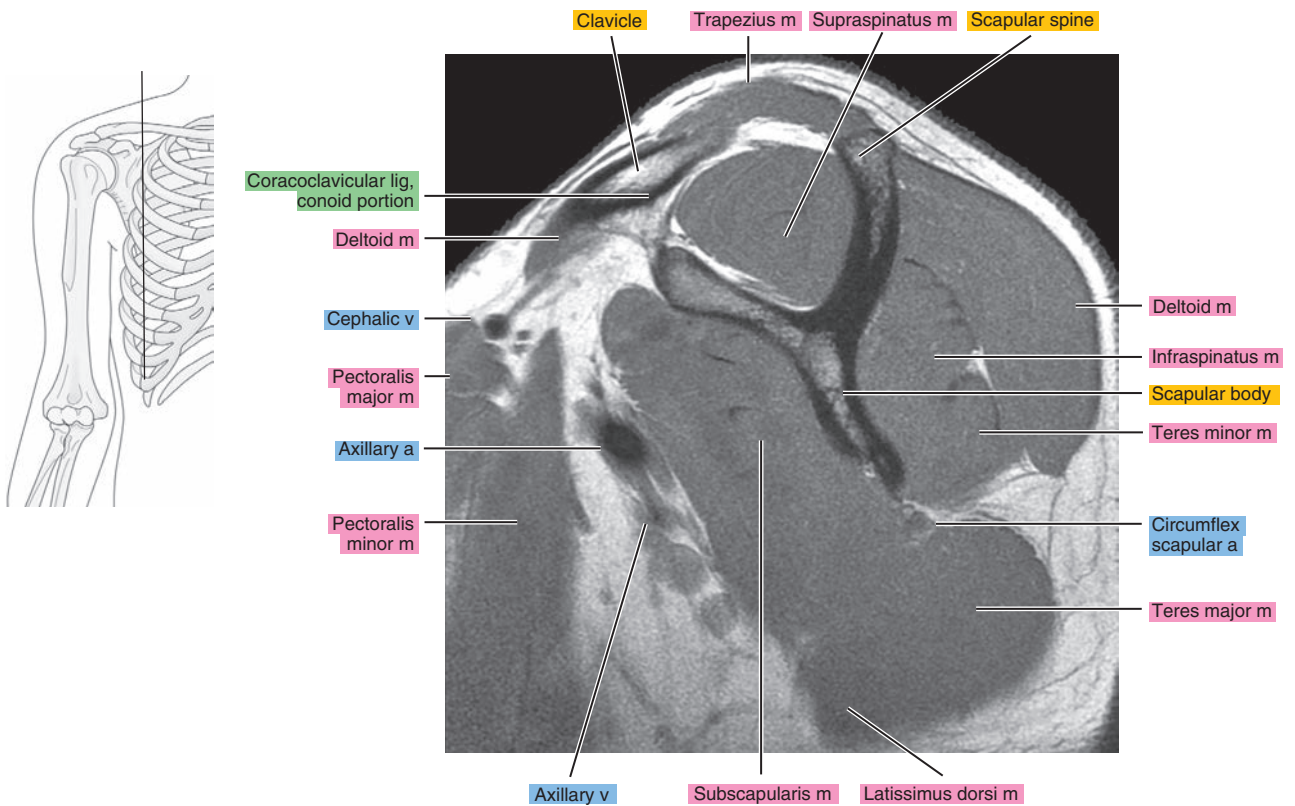


Figure 6.2.19

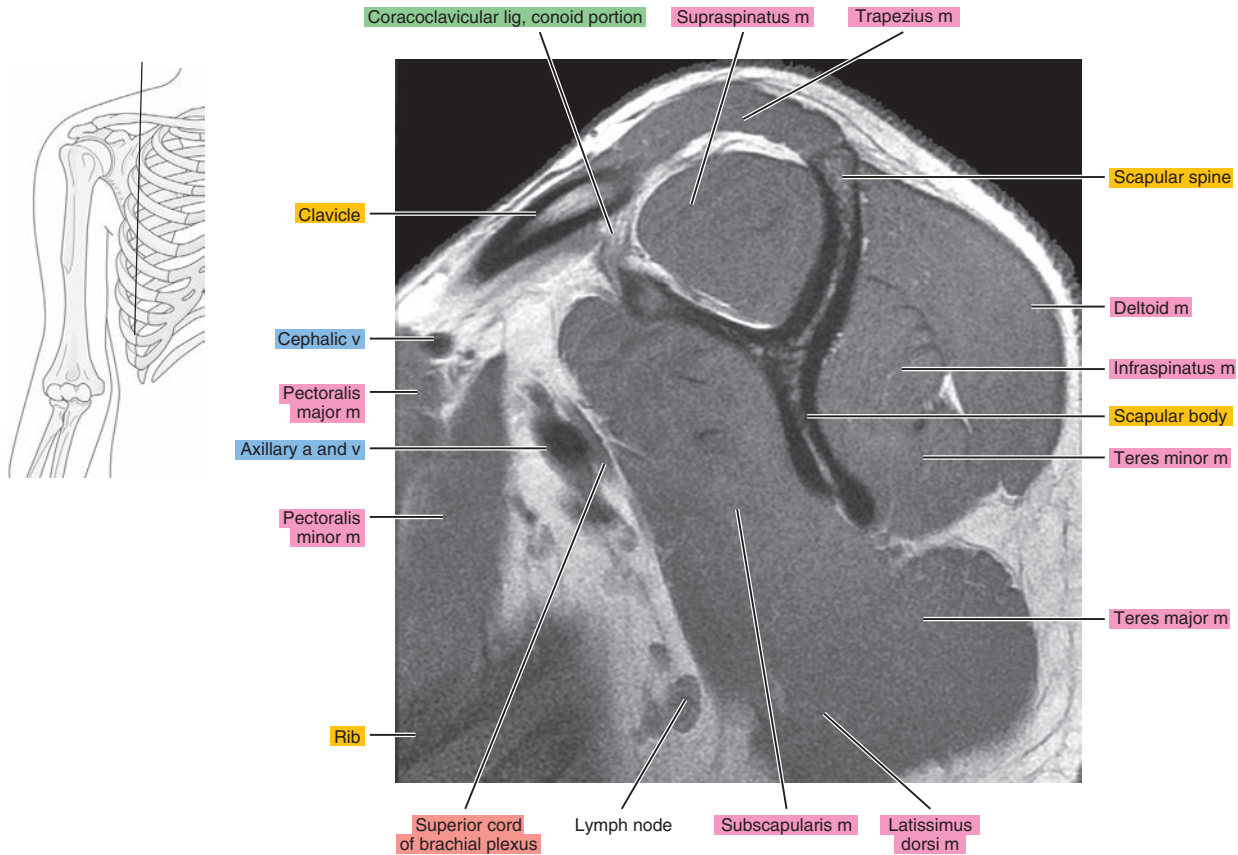
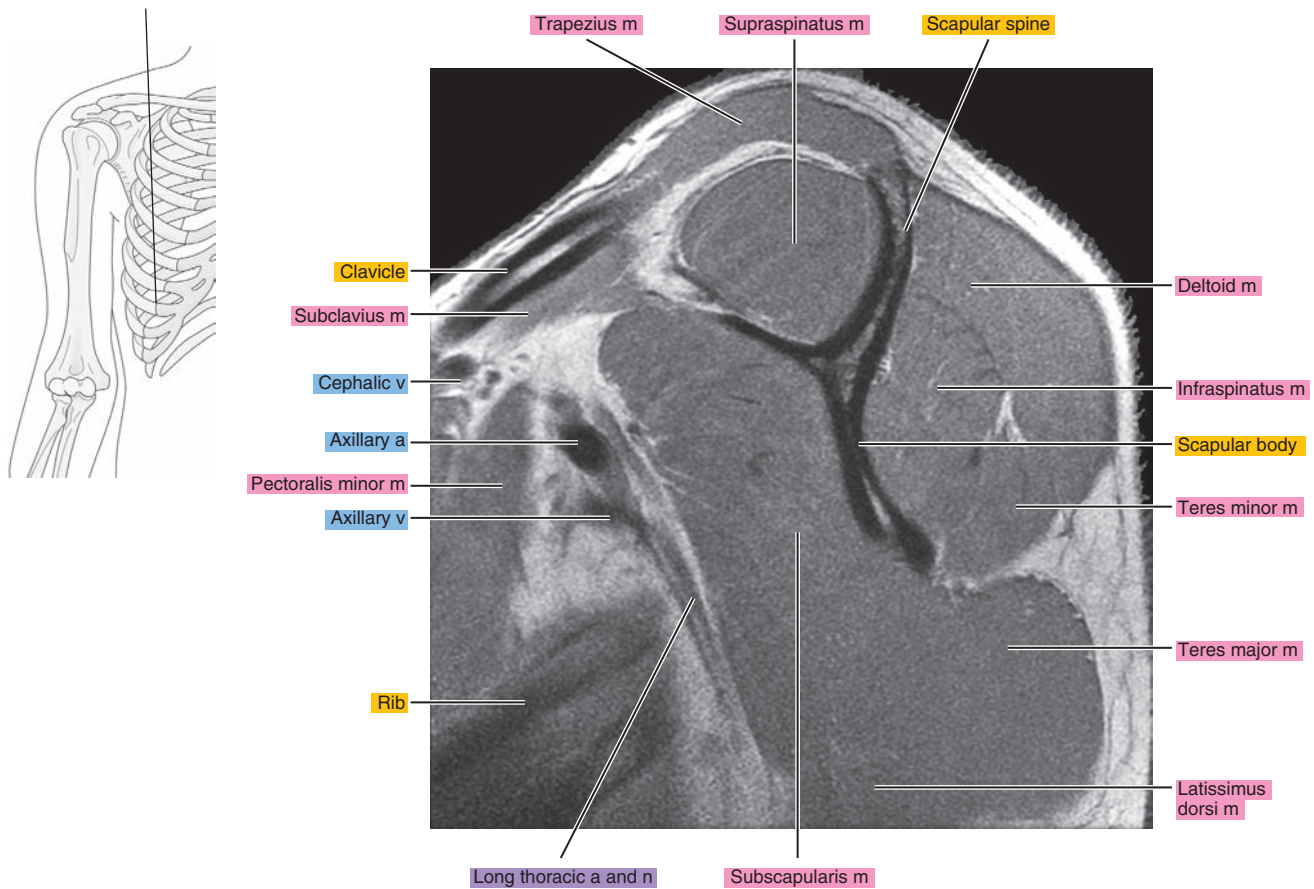


Figure 6.2.20





# OBLIQUE CORONAL

Figure 6.3.1

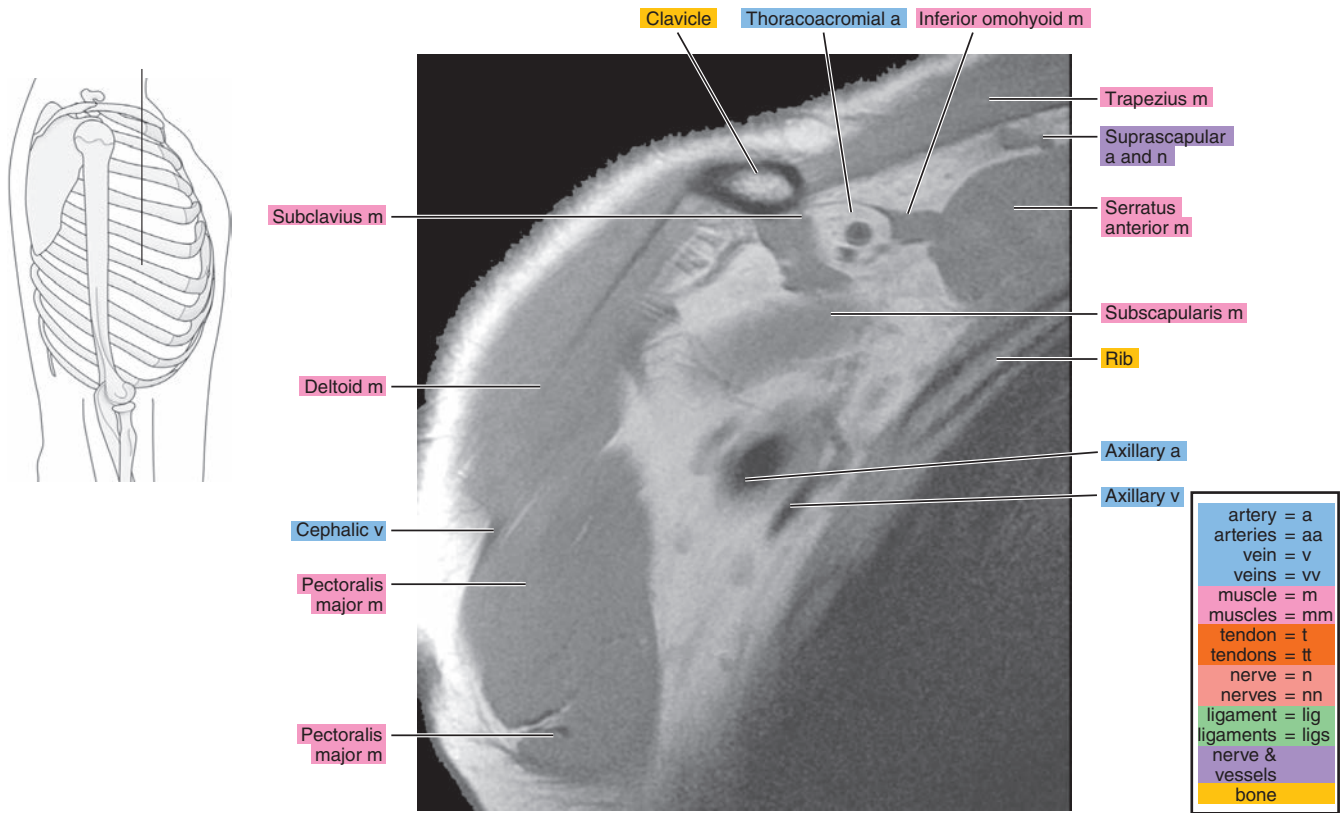


Figure 6.3.2

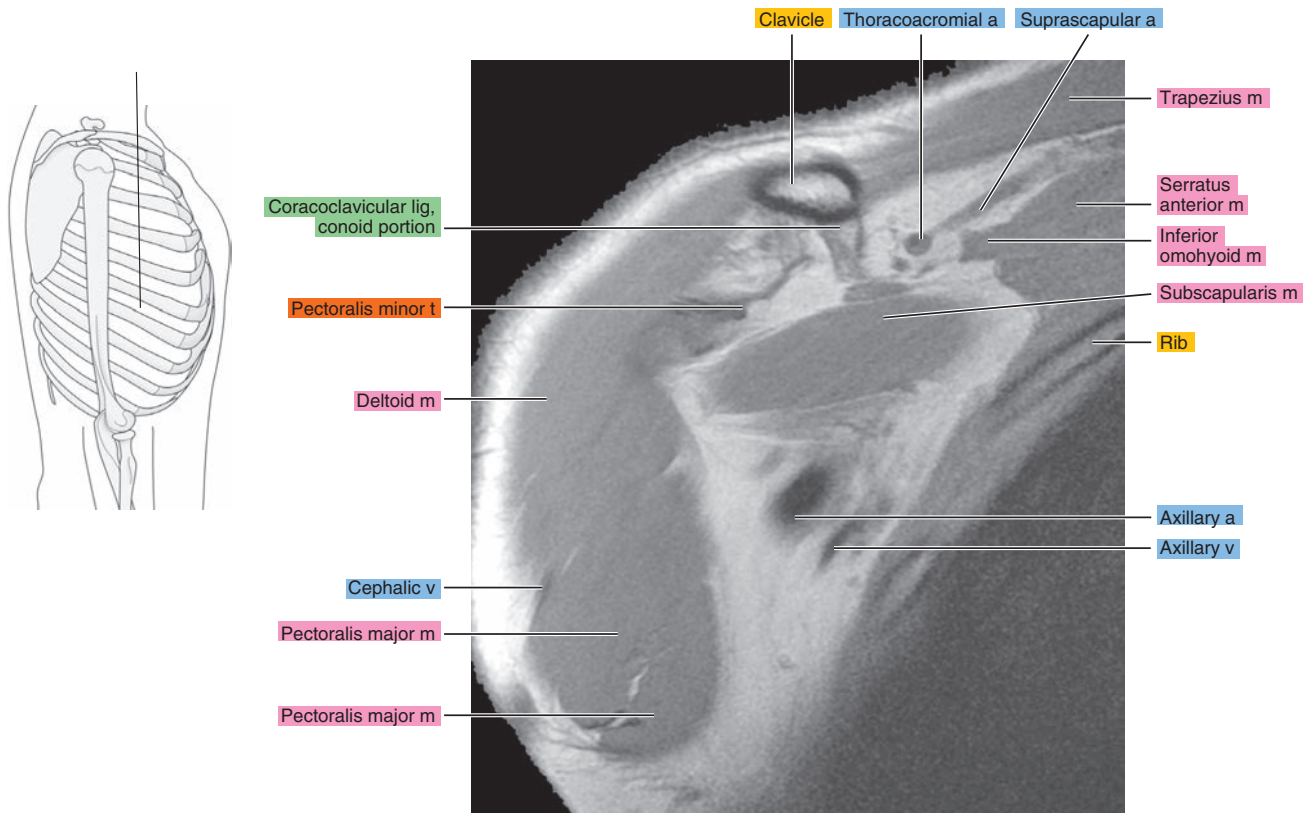


Figure 6.3.3

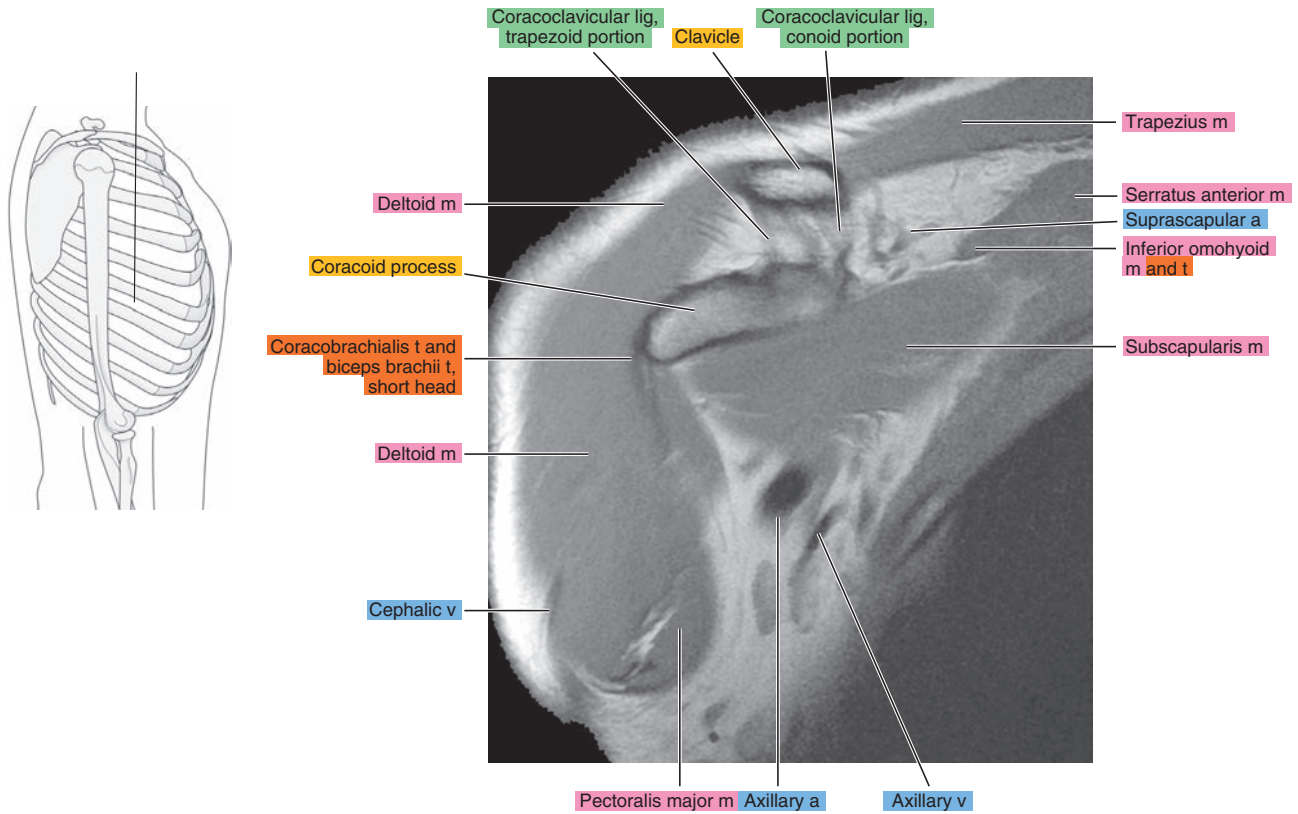


Figure 6.3.4

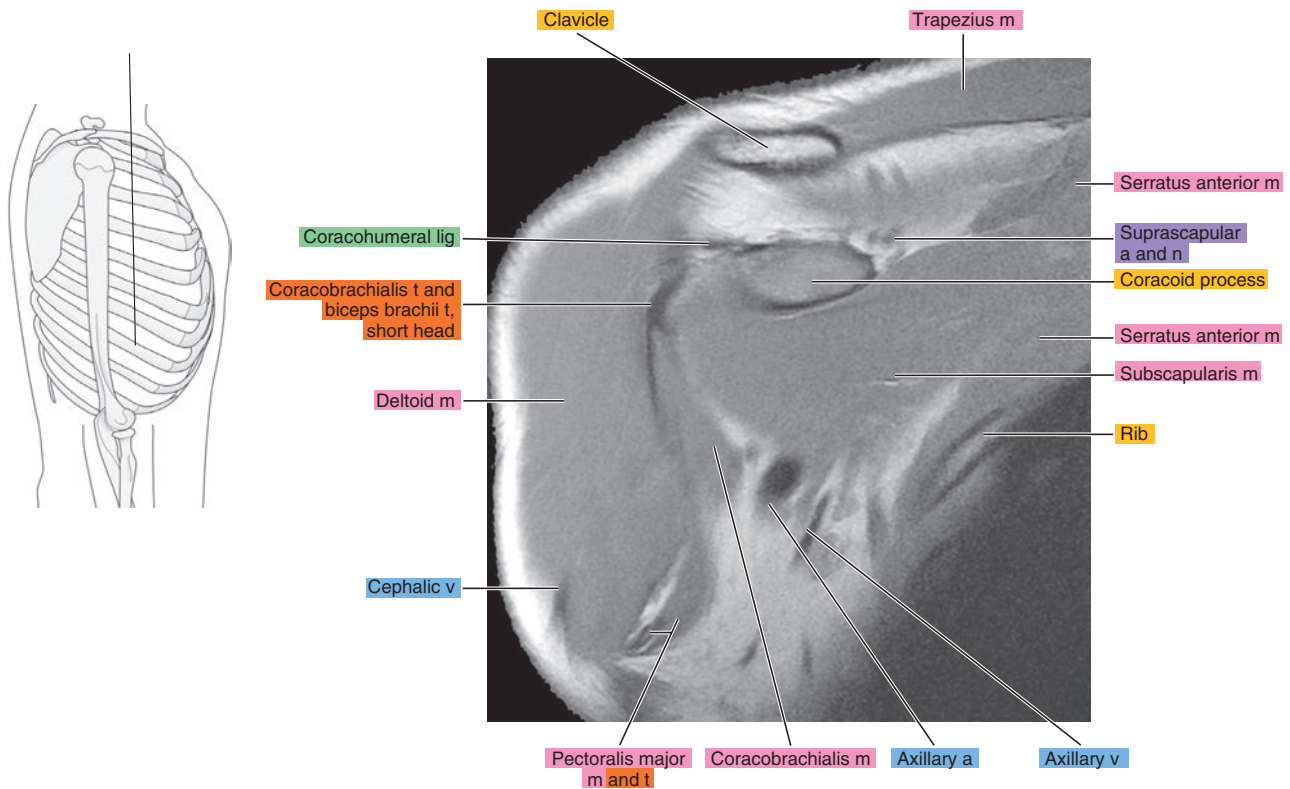


Figure 6.3.5

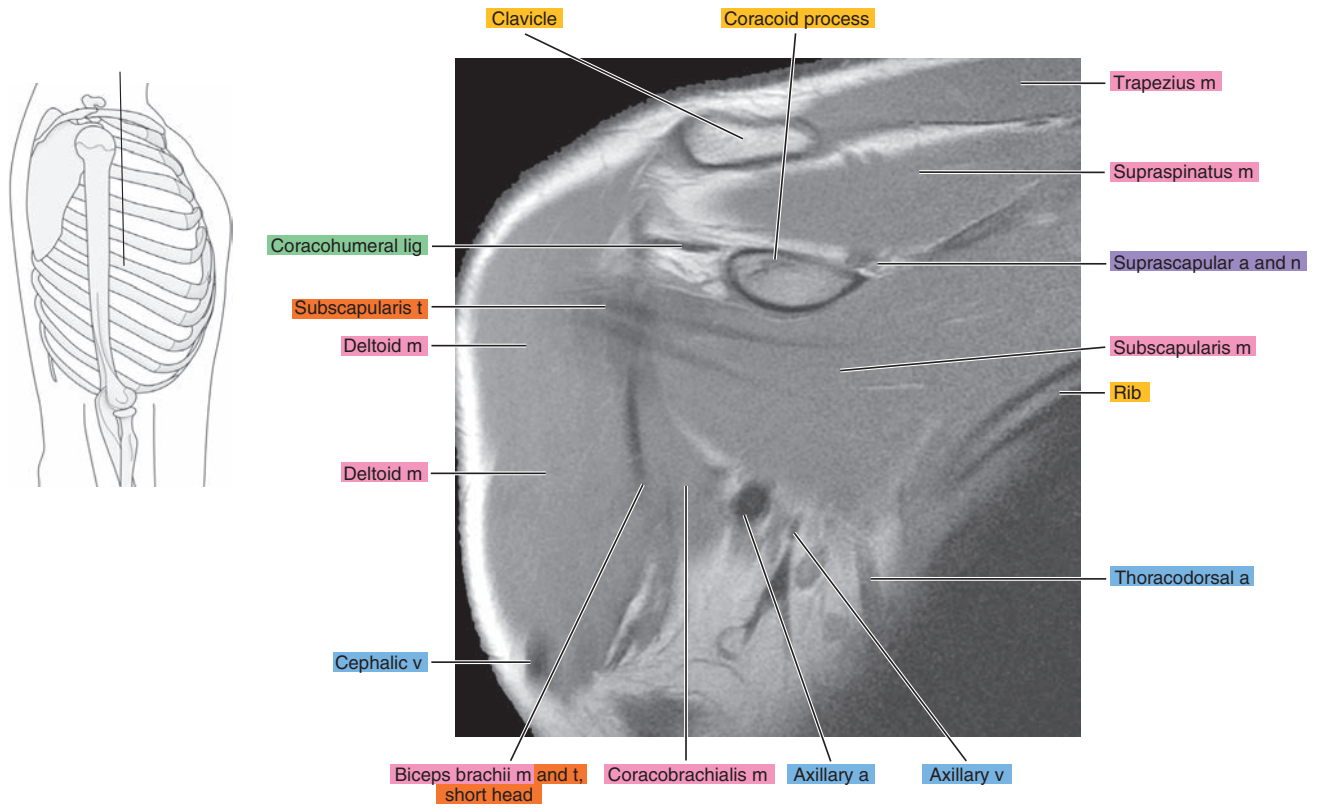


Figure 6.3.6

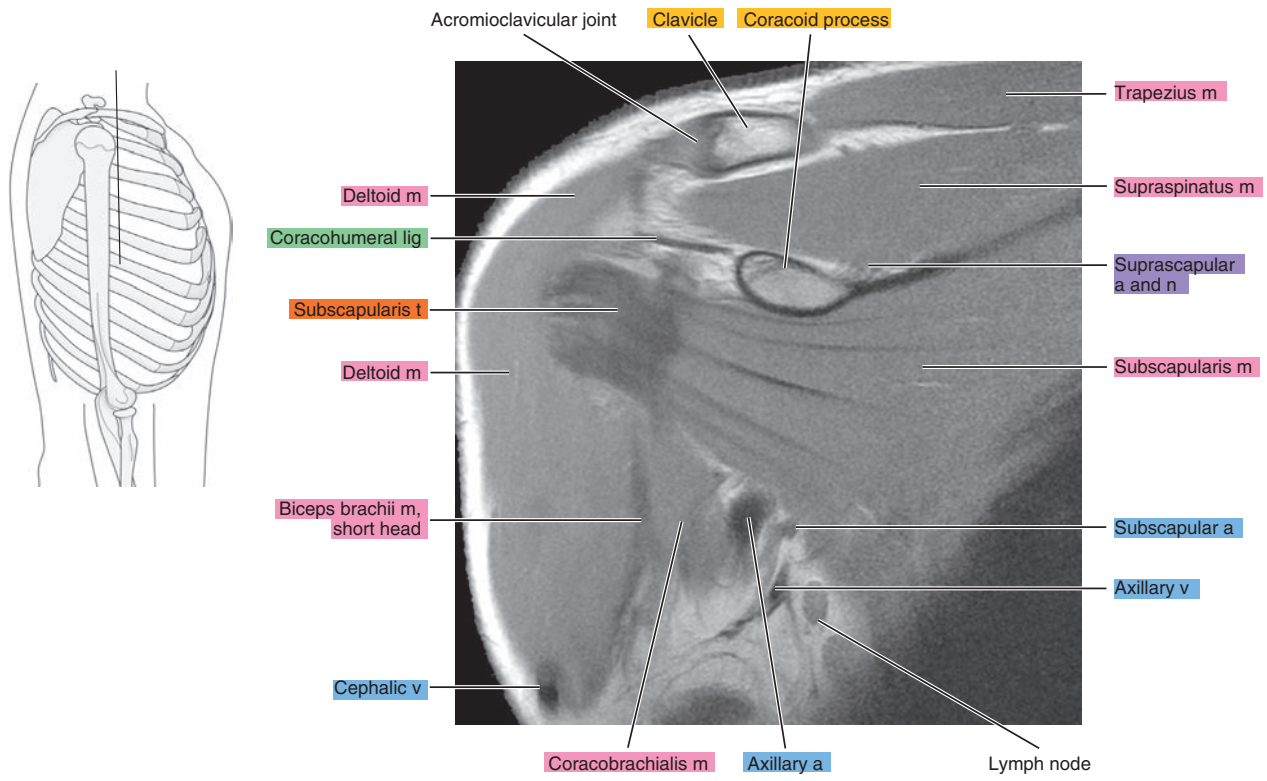




Figure 6.3.7

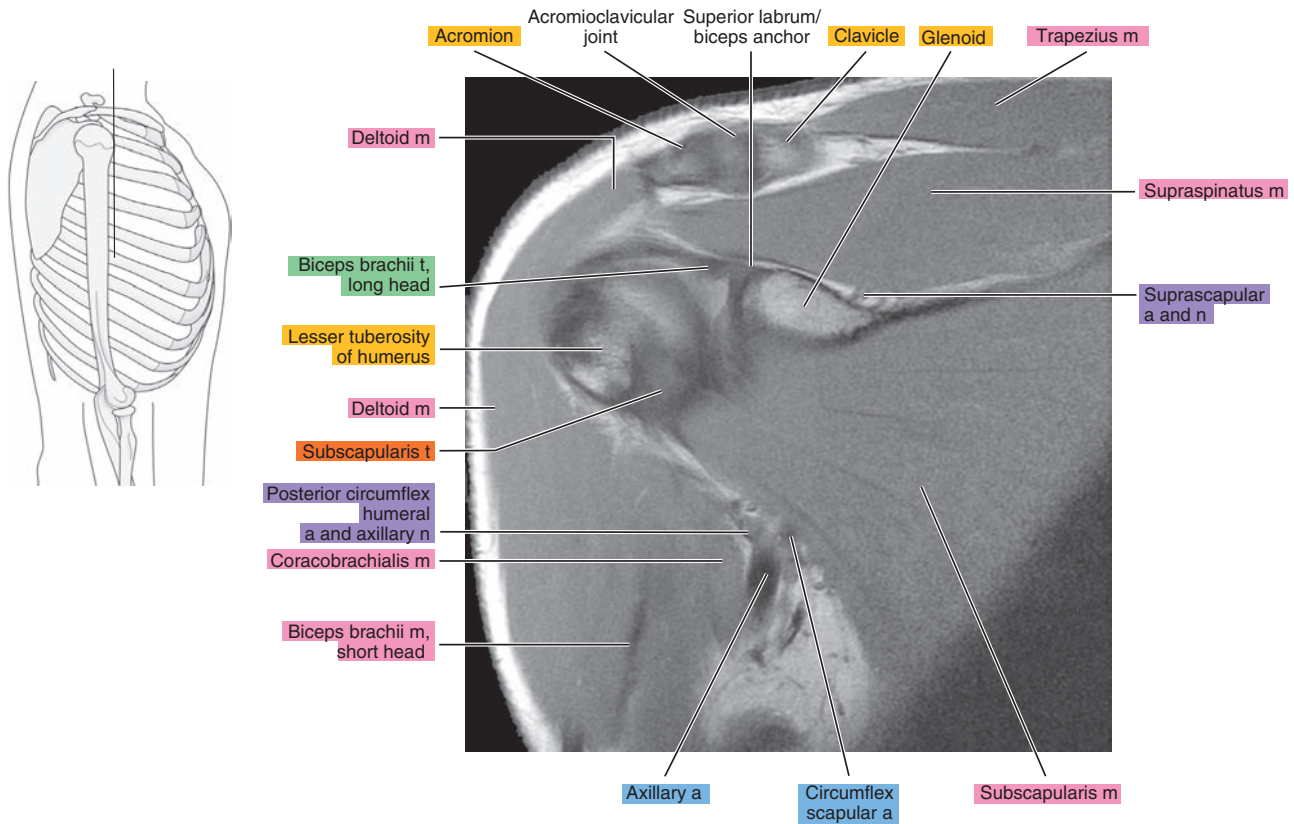


Figure 6.3.8

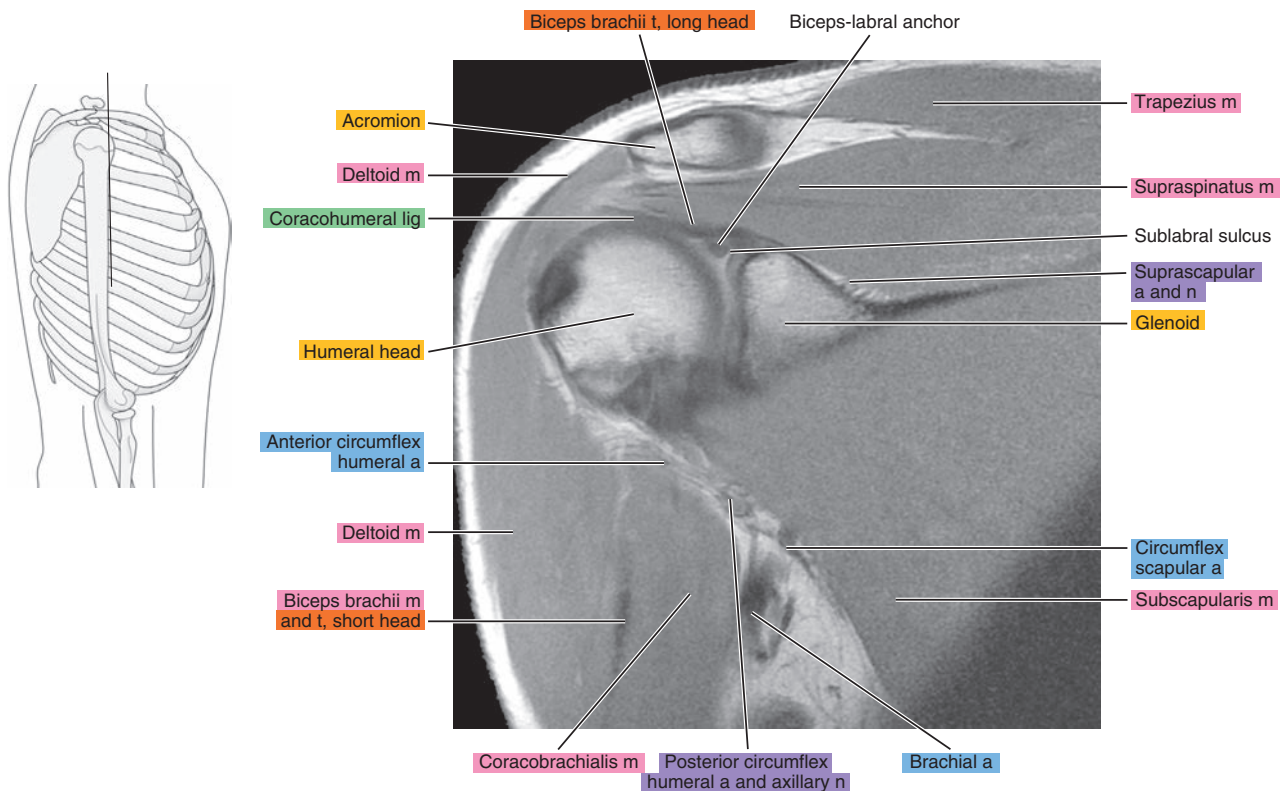




Figure 6.3.9

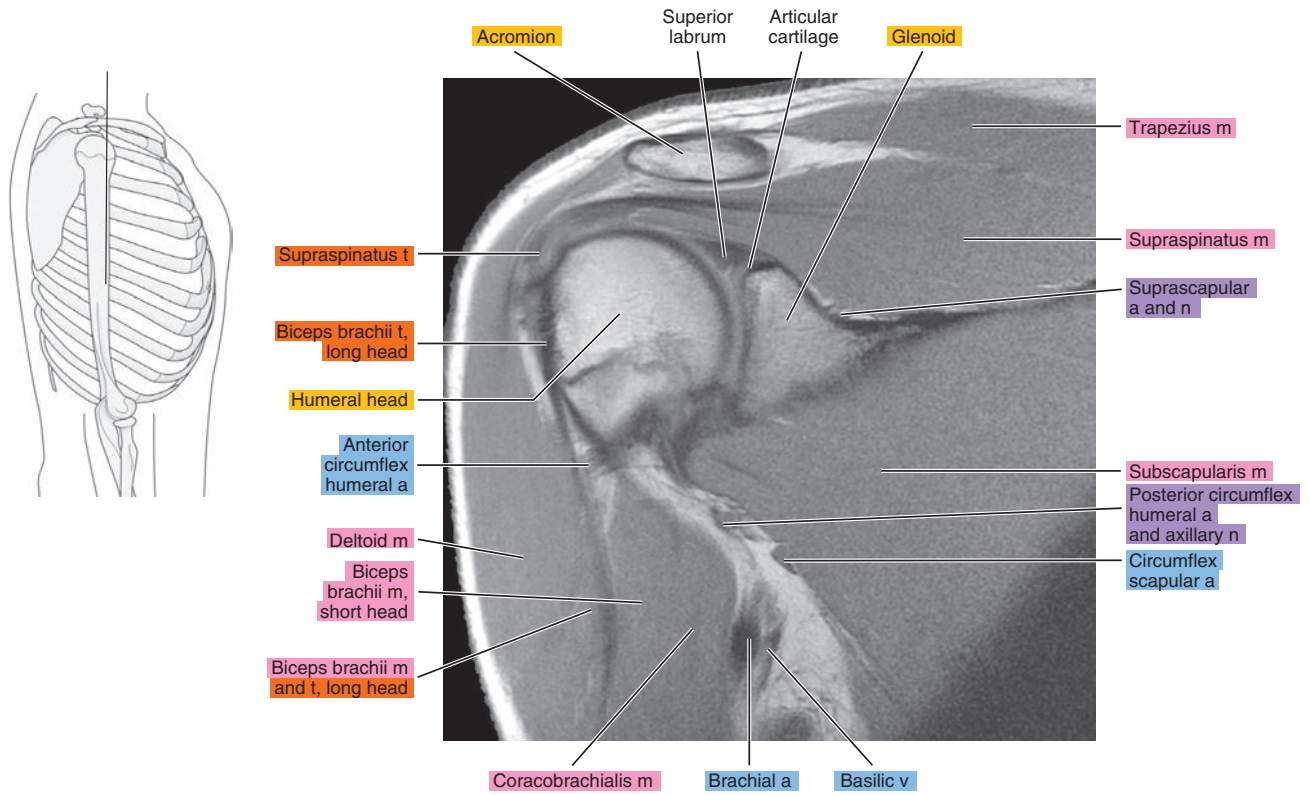


Figure 6.3.10

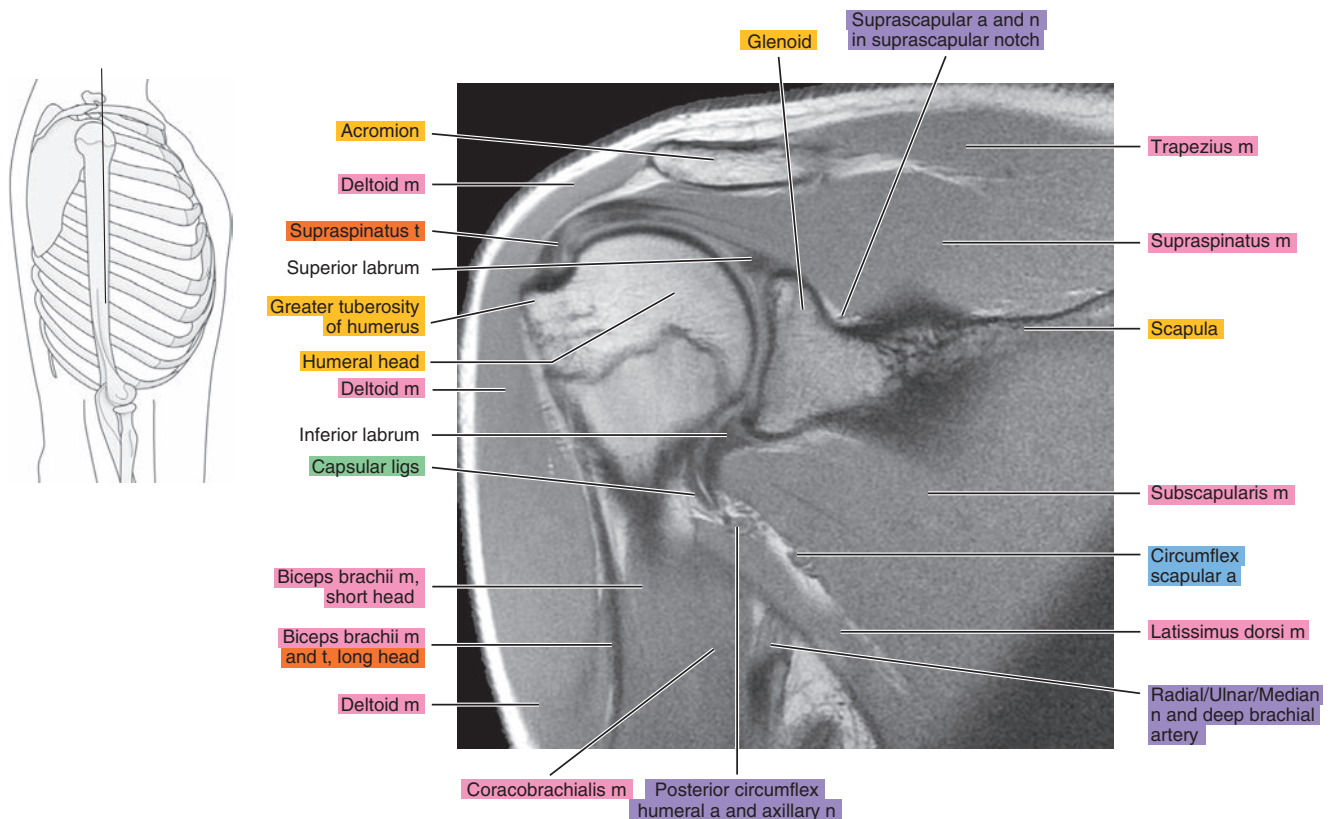


Figure 6.3.11

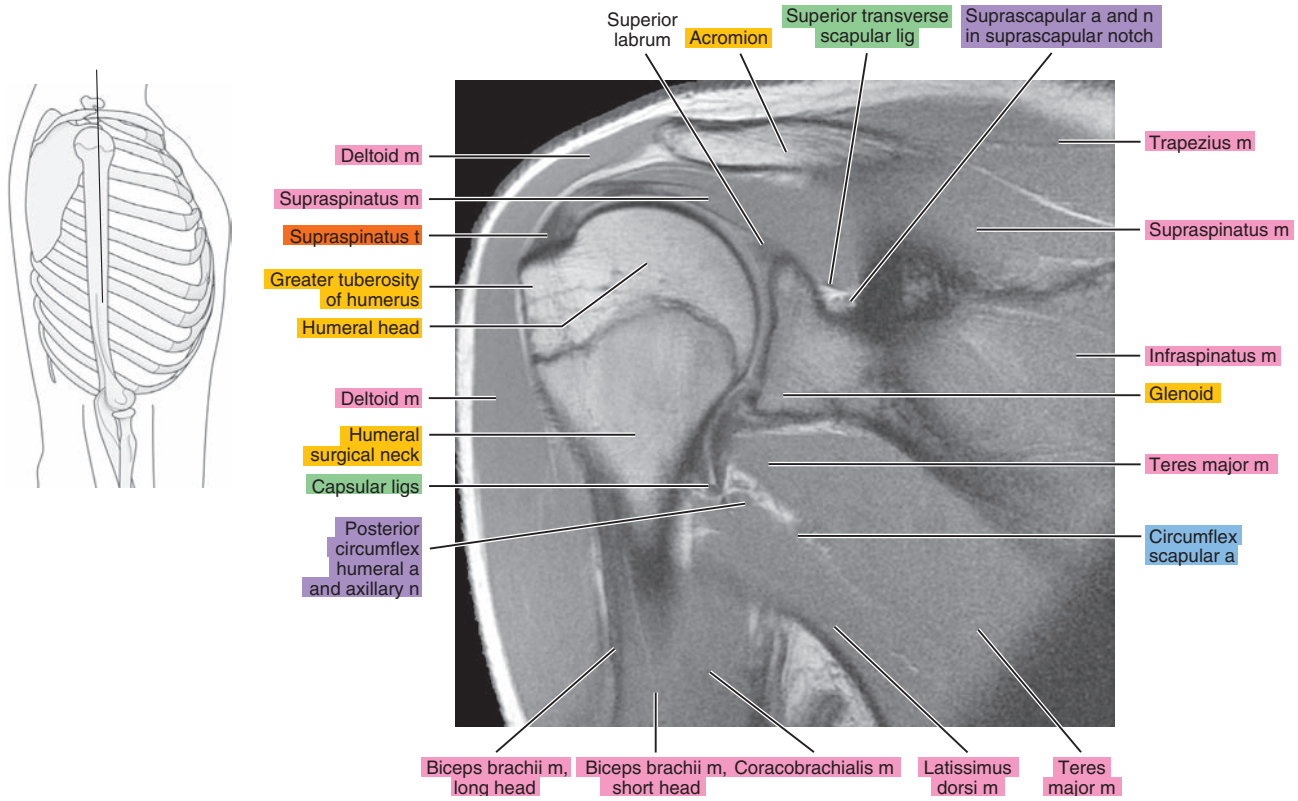


Figure 6.3.12

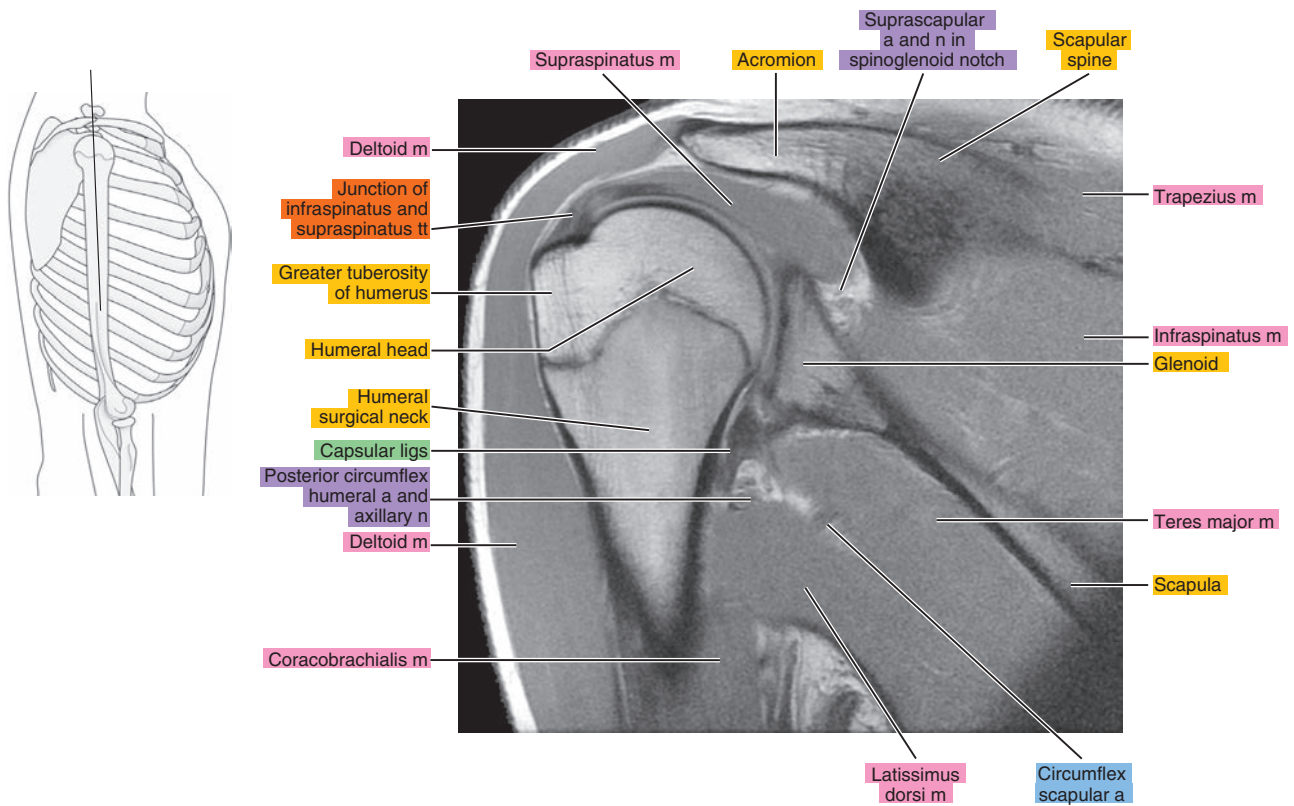


Figure 6.3.13

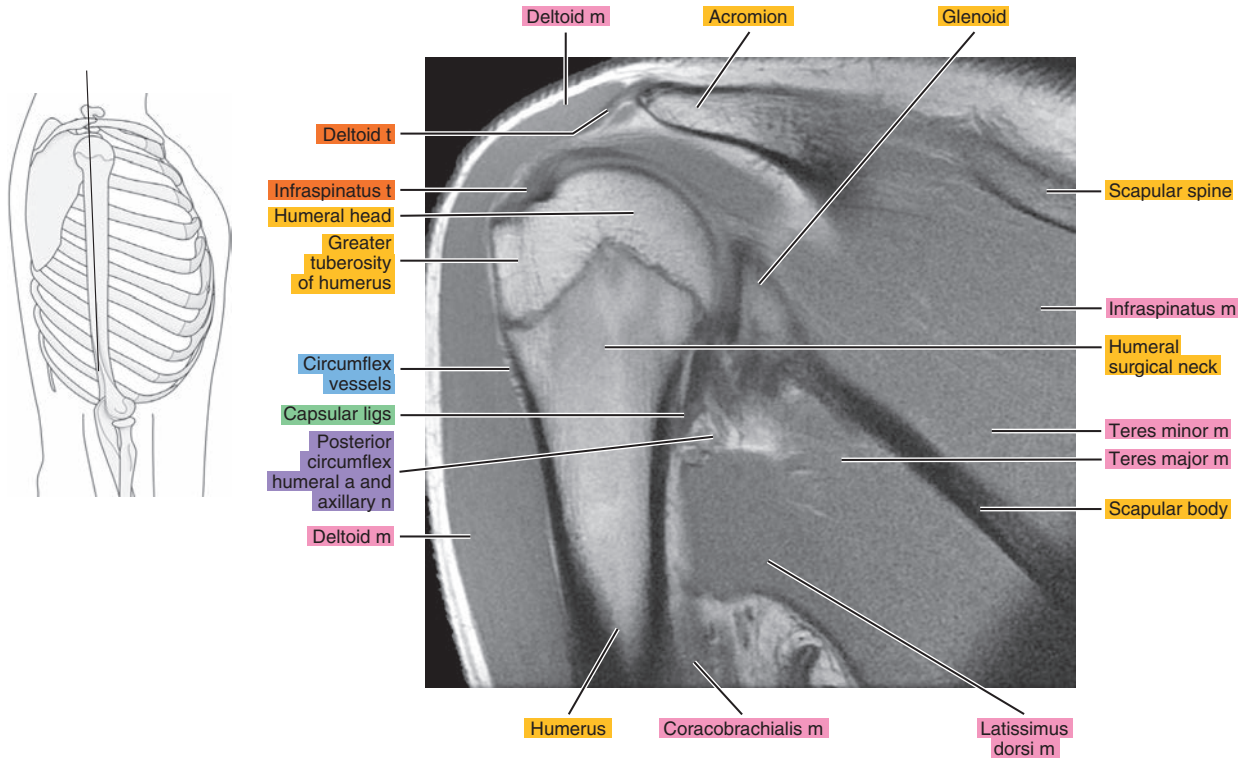


Figure 6.3.14

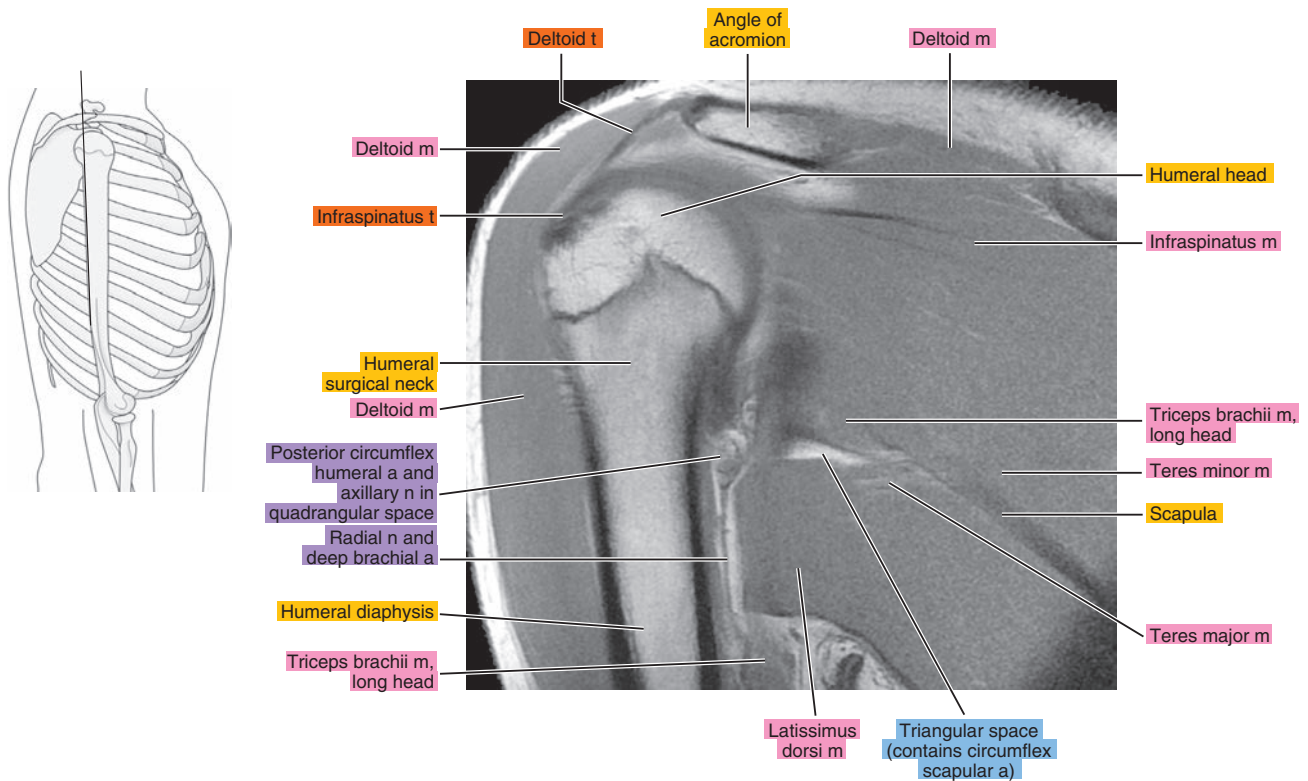




Figure 6.3.15

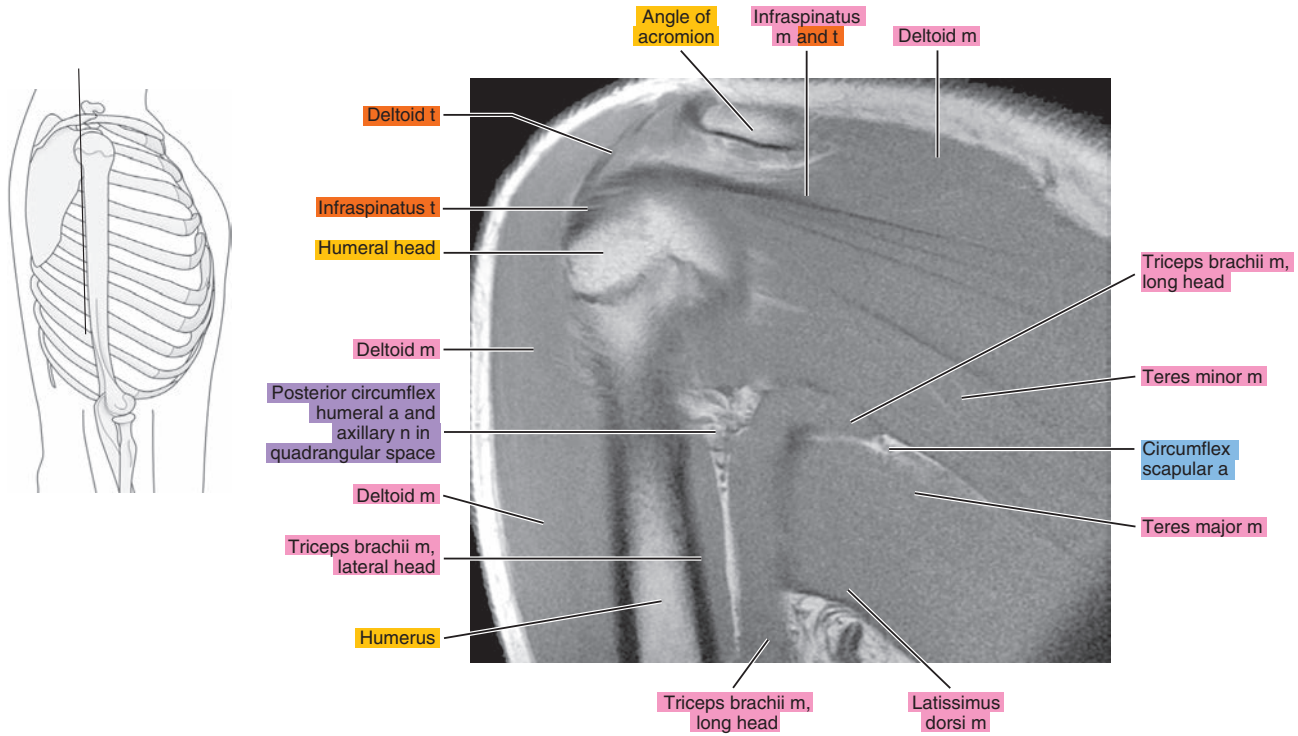


Figure 6.3.16

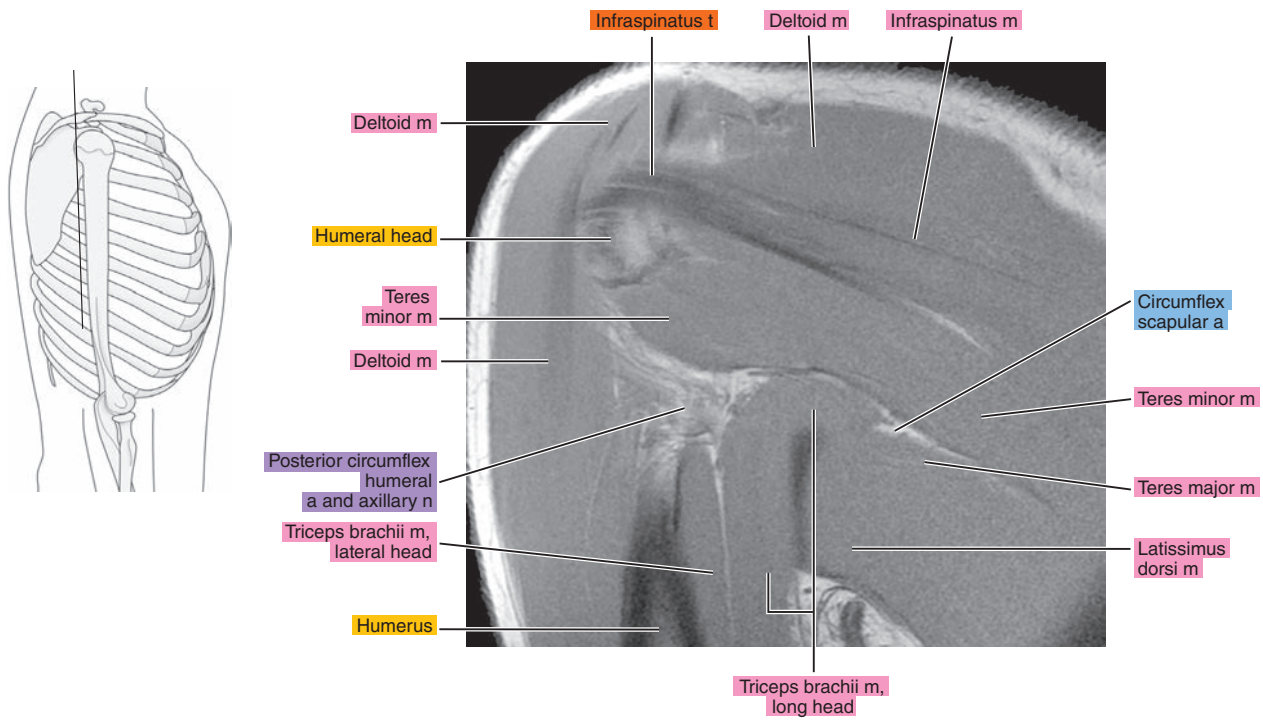




Figure 6.3.17

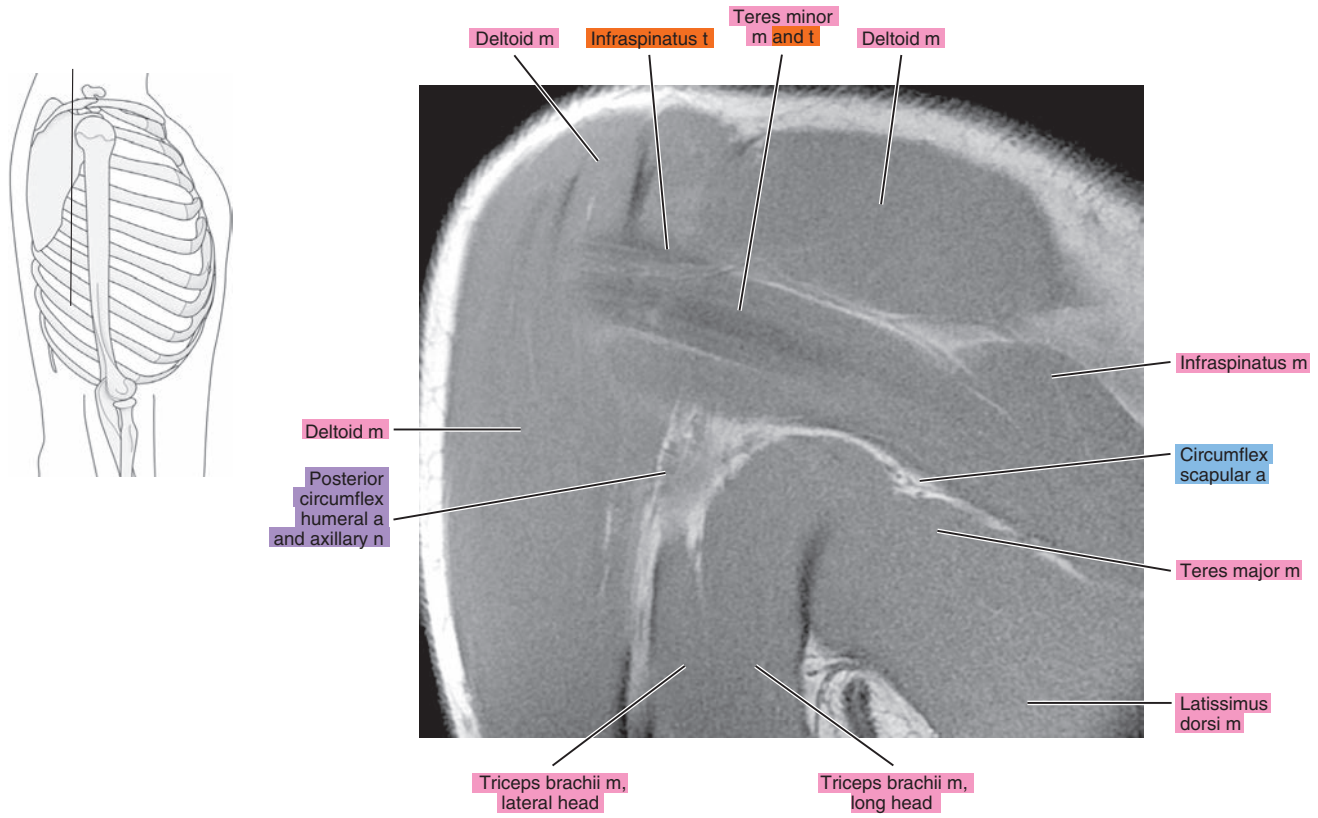


Figure 6.3.18

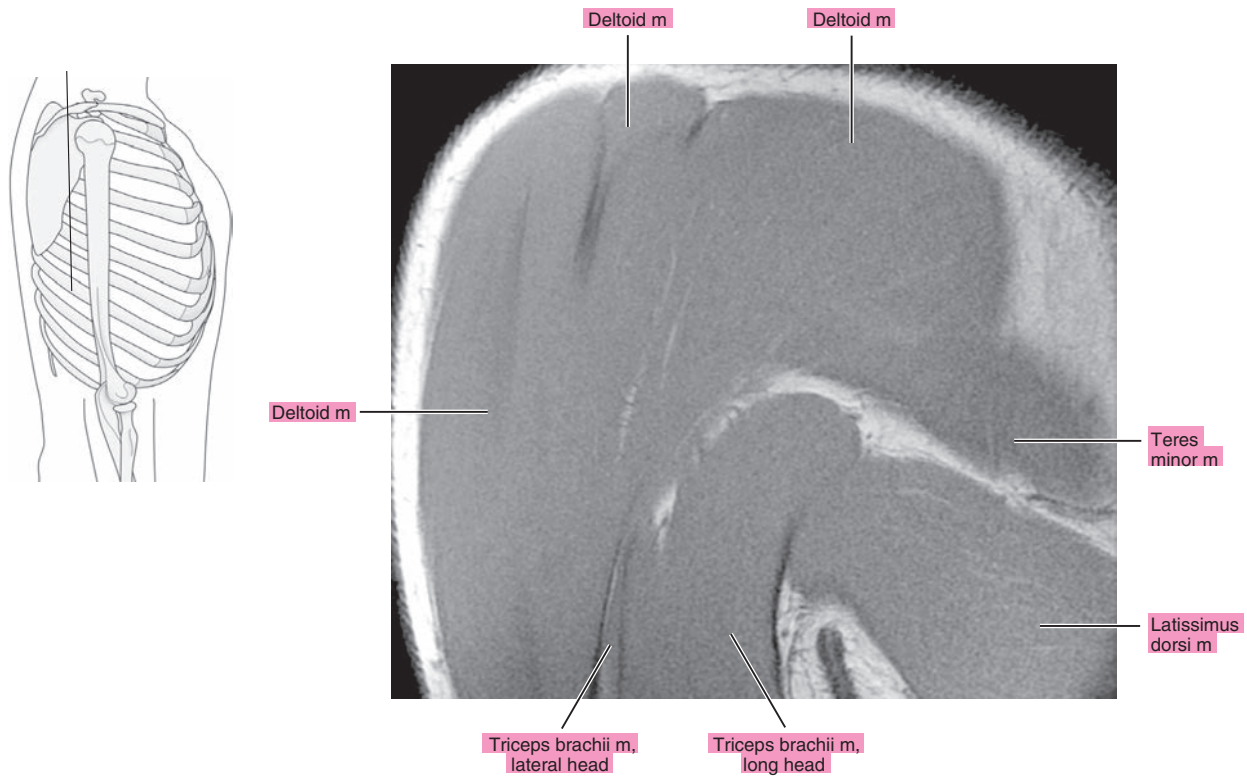


Figure 6.3.19

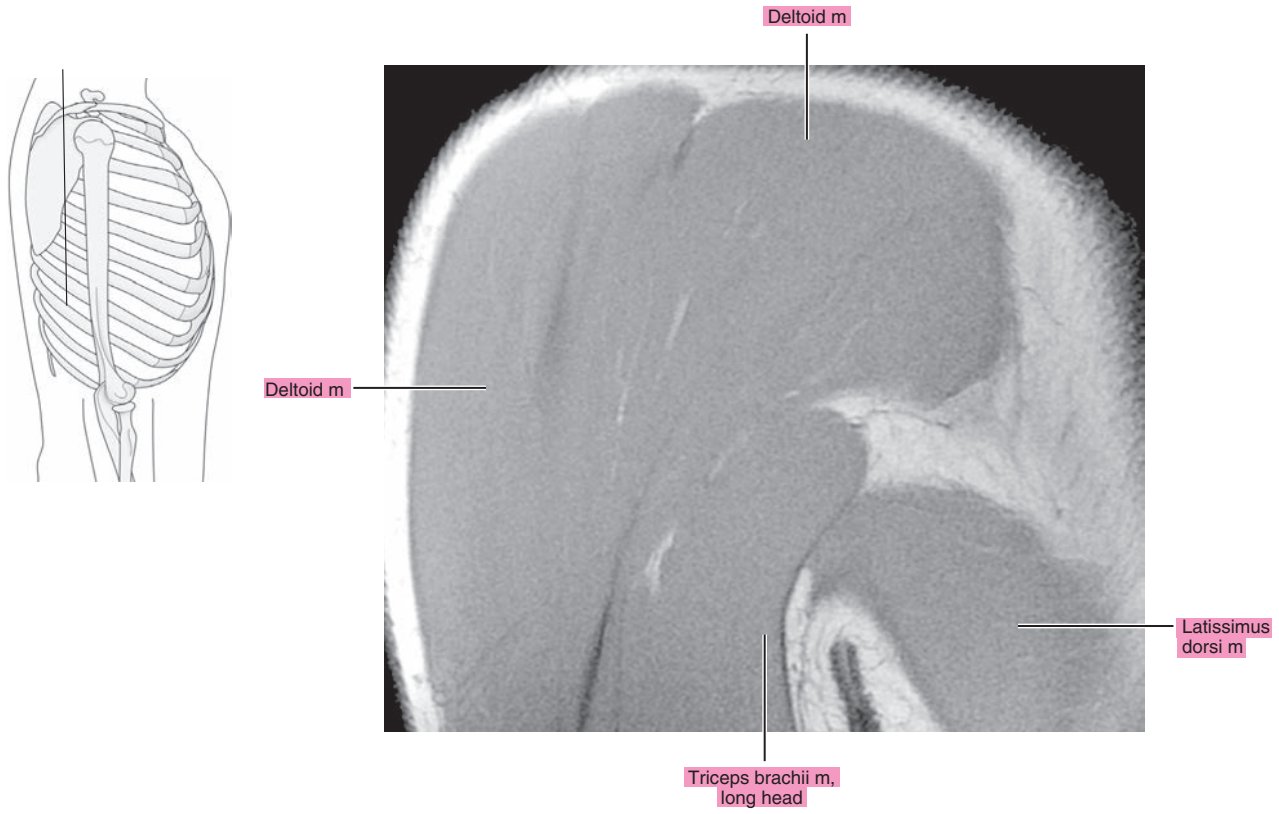
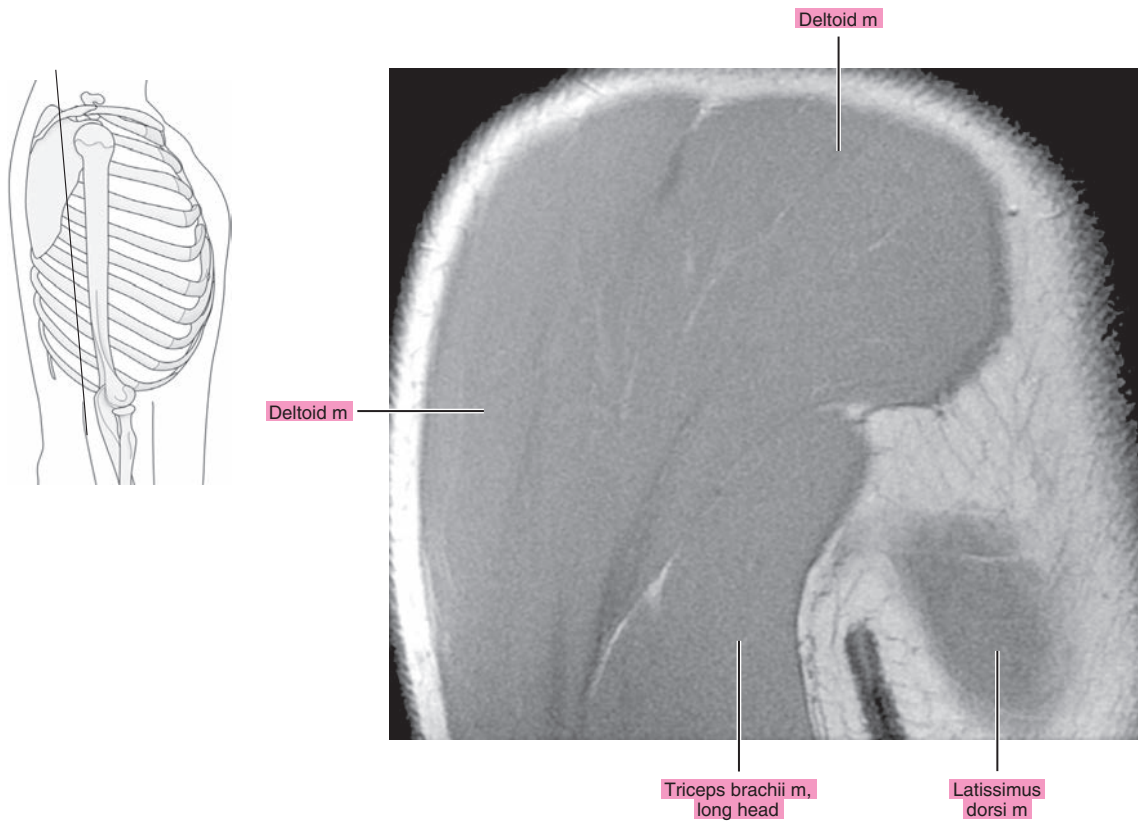


Figure 6.3.20



**Table 6-1. Muscles of the Shoulder**

MUSCLE	ORIGIN	INSERTION	NERVE SUPPLY
<b>Pectoralis major</b>	Medial half of the anterior surface of the clavicle, side and front of the sternum as far as the sixth costal cartilage, front and surfaces of the cartilage of the second through sixth ribs, osseous ends of the sixth and seventh ribs, and aponeurosis of external abdominal oblique	Crest of the greater tubercle of the humerus, lateral lip of the intertubercular groove, deltoid tubercle, and fibrous periosteum of the intertubercular sulcus.	Lateral and medial pectoral (C5 and C6 for the clavicular part and C7, C8, and T1 for the sternocostal part)
<b>Pectoralis minor</b>	Aponeurotic slips from the second through fifth ribs, near costal cartilages	Anterior half of the medial border and upper surface of the coracoid process of the scapula.	Medial and lateral pectoral (C6, C7, and C8)
<b>Subclavius</b>	First rib and its cartilage	Inferior surface of the clavicle between the costal and coracoid tuberosities.	Nerve to subclavian (C5 or C5 and C6)
<b>Deltoid</b>	Lateral border and upper surface of the lateral third of the clavicle, the acromion, and the scapular spine	Deltoid tuberosity of the humerus.	Axillary (C5, C6)
<b>Supraspinatus</b>	Supraspinous fossa and investing fascia	Shoulder capsule and superior facet of the greater tubercle of the humerus.	Suprascapular (C4, C5, and C6)
<b>Infraspinatus</b>	Infraspinous fossa, scapular spine, investing (deep) fascia, and adjacent aponeurotic septa	Shoulder capsule and middle facet of the greater tubercle of the humerus.	Suprascapular (C4, C5, and C6)
<b>Teres minor</b>	Upper two-thirds of the axillary border of the scapula	Shoulder capsule and inferior facet of the greater tubercle of the humerus.	Axillary (C4, C5, and C6)
<b>Subscapularis</b>	Subscapularis fossa	Shoulder capsule and lesser tubercle of the humerus and its shaft immediately below the tubercle.	Two or three subscapular branches from the posterior cord and upper and lower subscapular (C5, C6, and C7)
<b>Teres major</b>	Inferior angle of the scapula	Medial lip of the intertubercular groove of the humerus.	Lower subscapular (C6 and C7)
<b>Latissimus dorsi</b>	Spine and interspinous ligaments of the lower five or six thoracic vertebrae, upper lumbar vertebrae, thoracodorsal fascia, posterior third of the crest of the ilium, and the lateral surface and upper edge of the lower three or four ribs	Muscle tendon inserts onto the ventral side of the lesser tubercle of the humerus and onto the floor of the intertubercular groove ventral to the tendon of the teres major. The tendon may extend to the greater tubercle of the humerus.	Thoracodorsal (C6, C7, and C8)

*Chapter*  
**7**

**MR Arthrography of the  
Shoulder**



# AXIAL

Figure 7.1.1

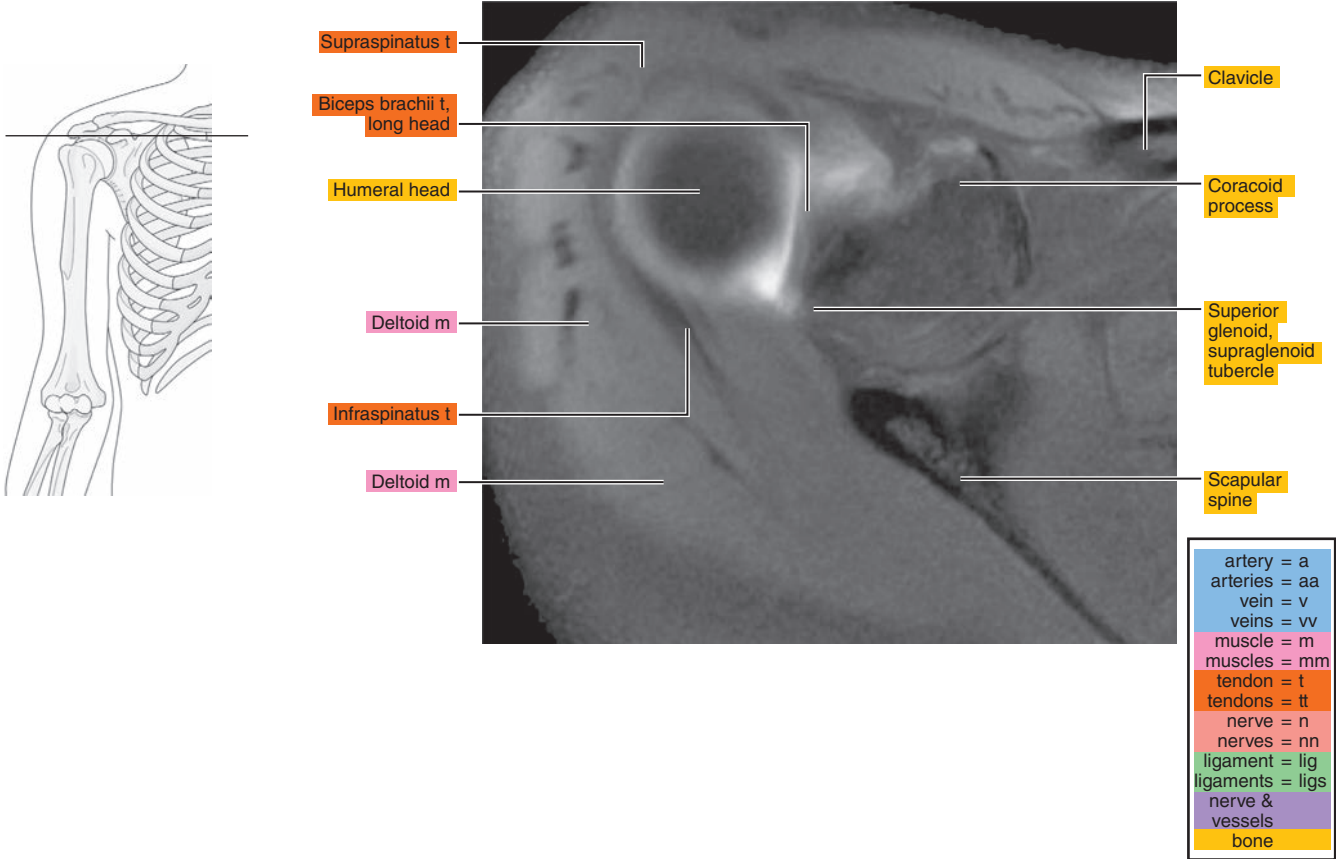


Figure 7.1.2

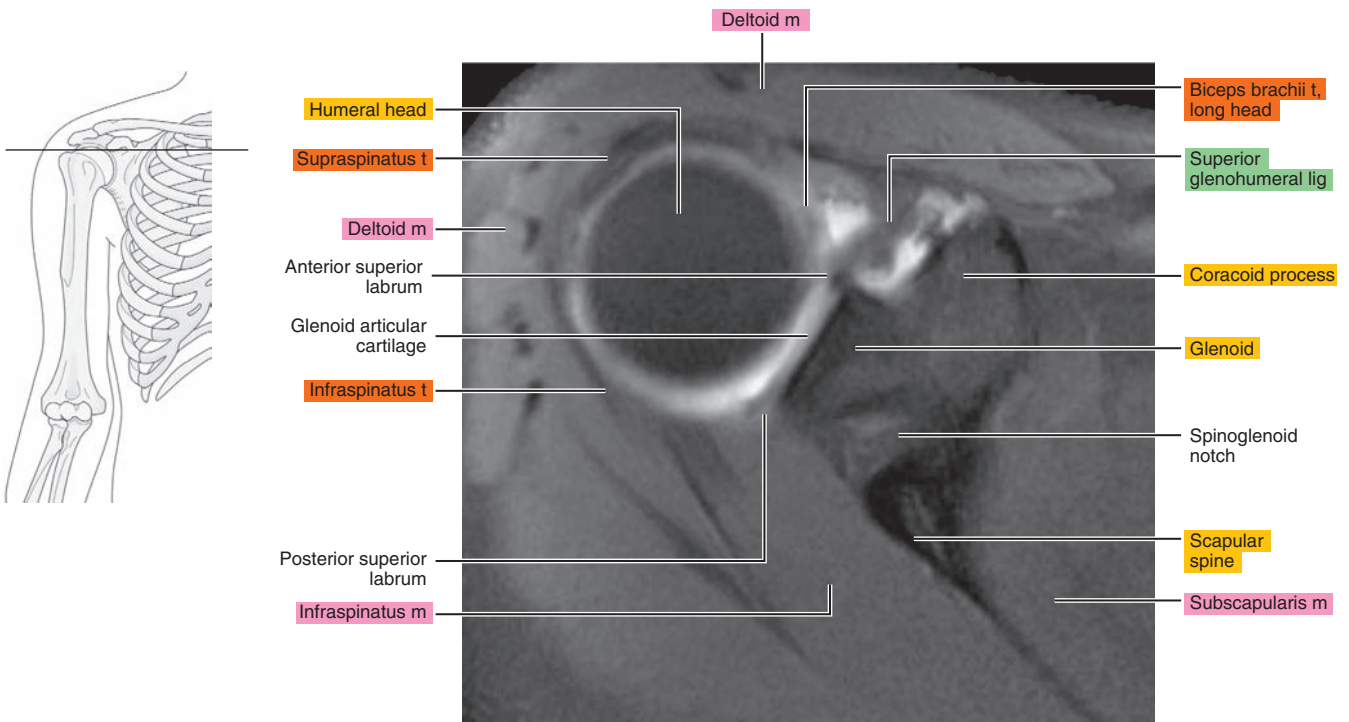


Figure 7.1.3

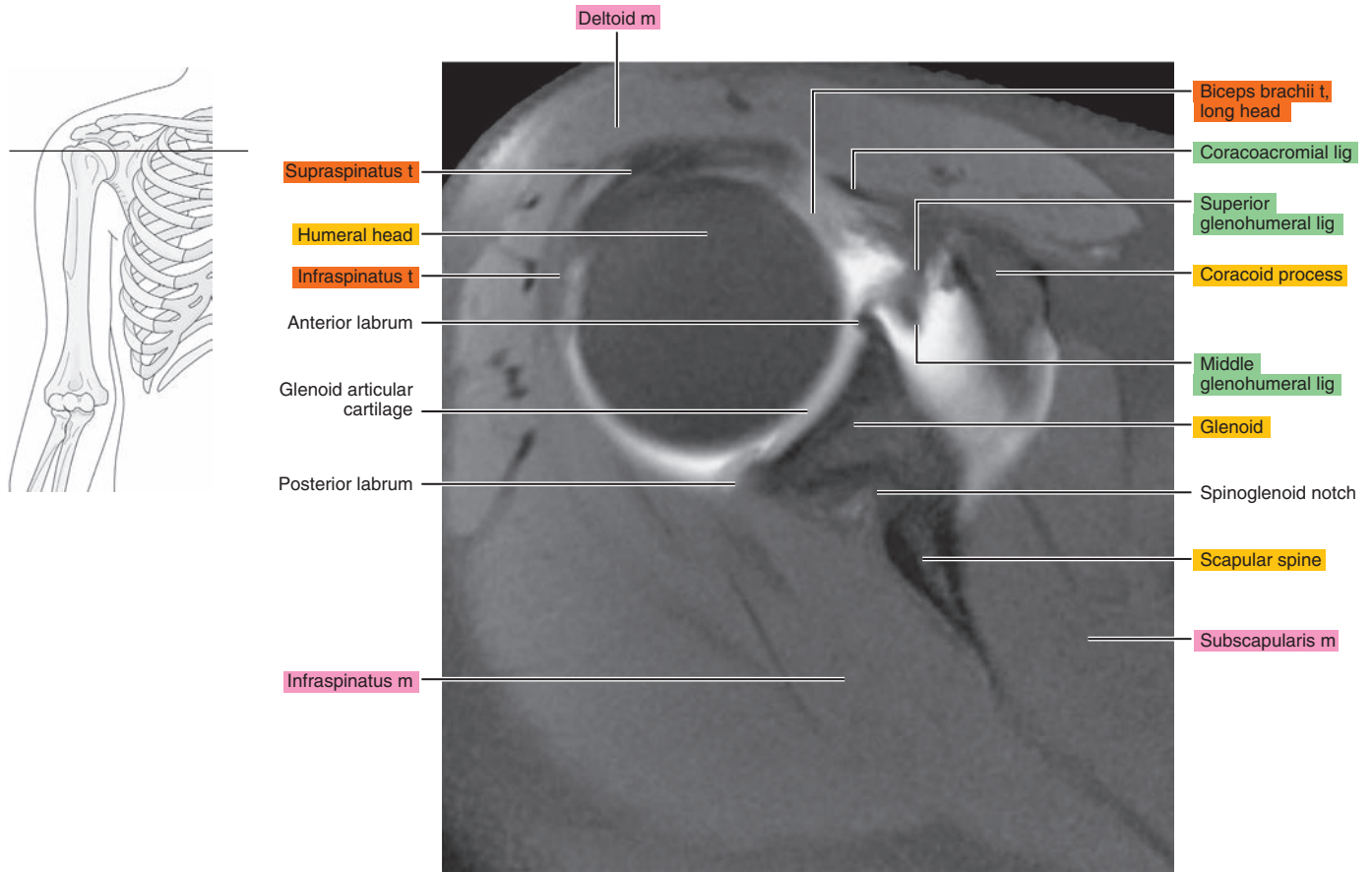


Figure 7.1.4

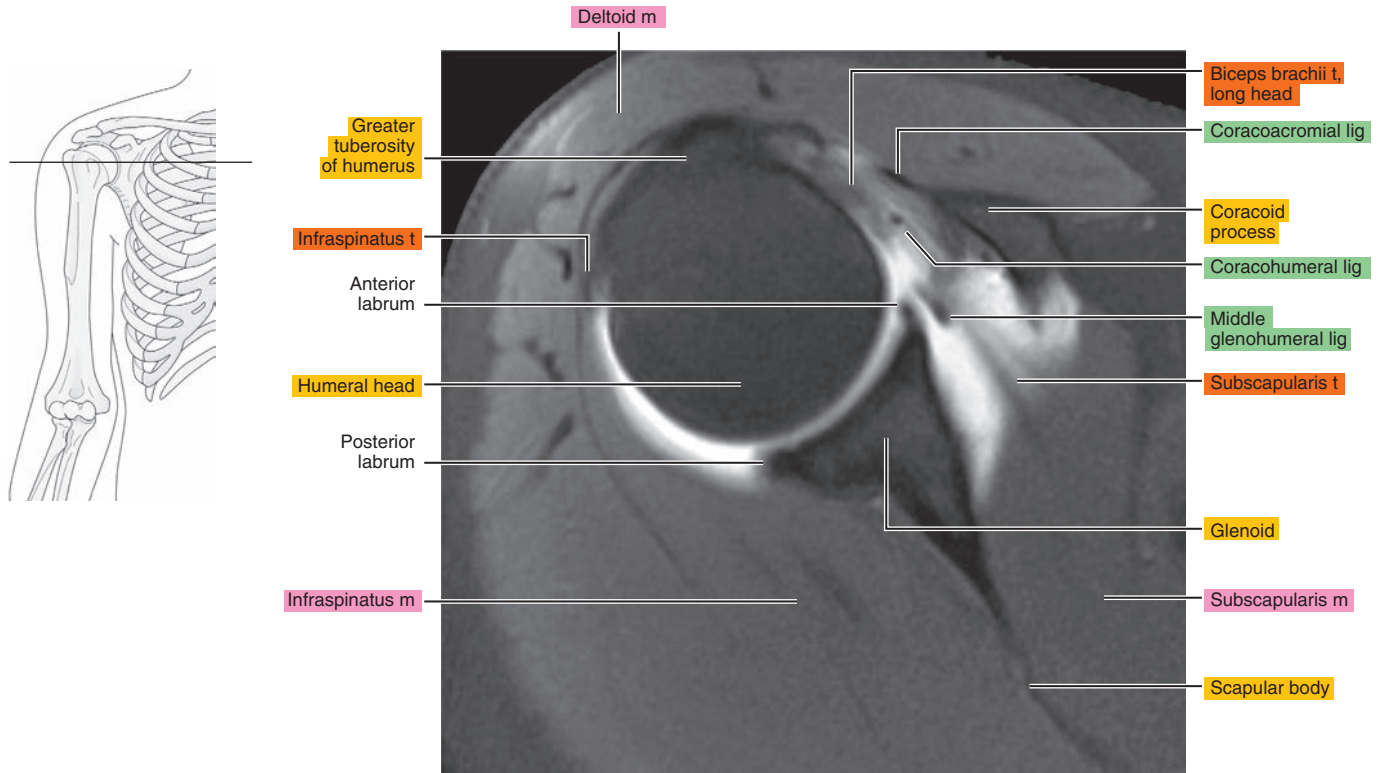


Figure 7.1.5

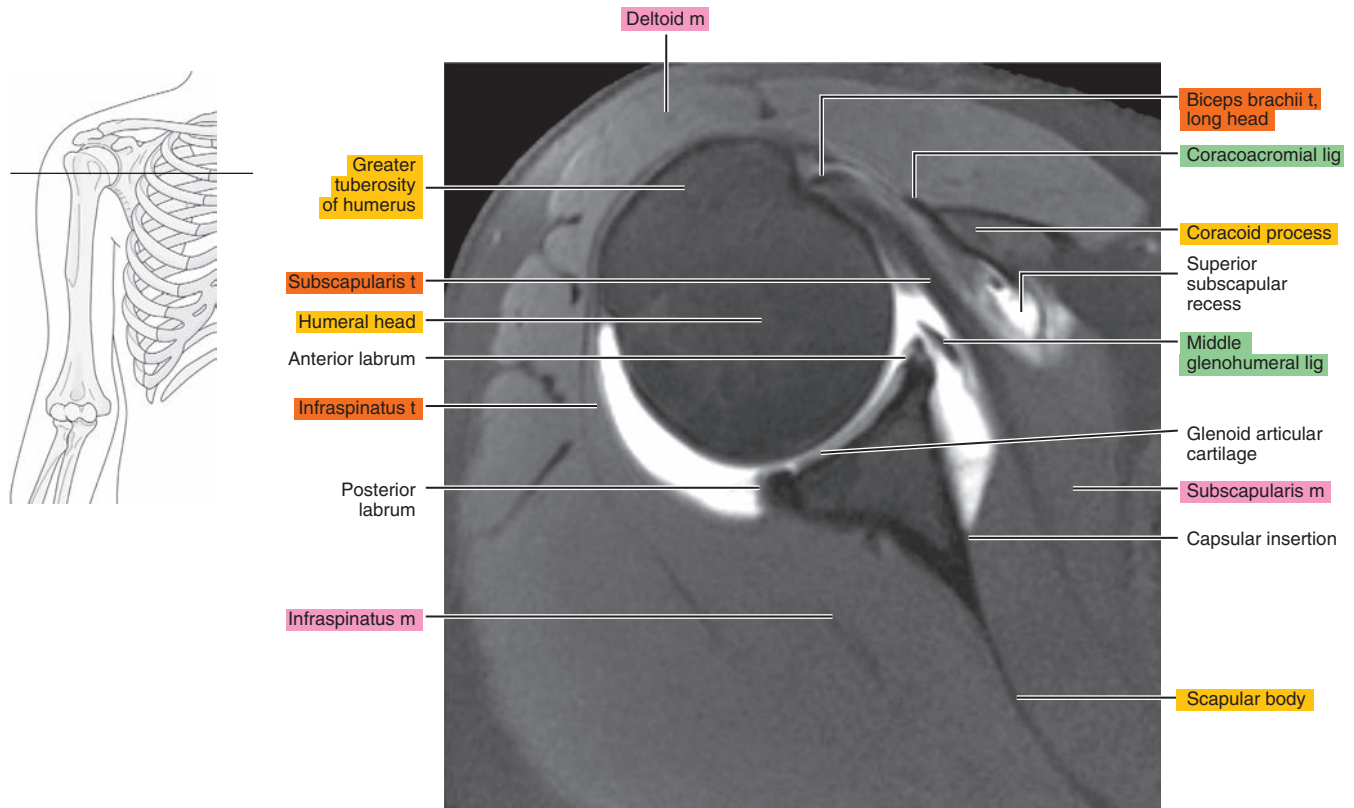


Figure 7.1.6

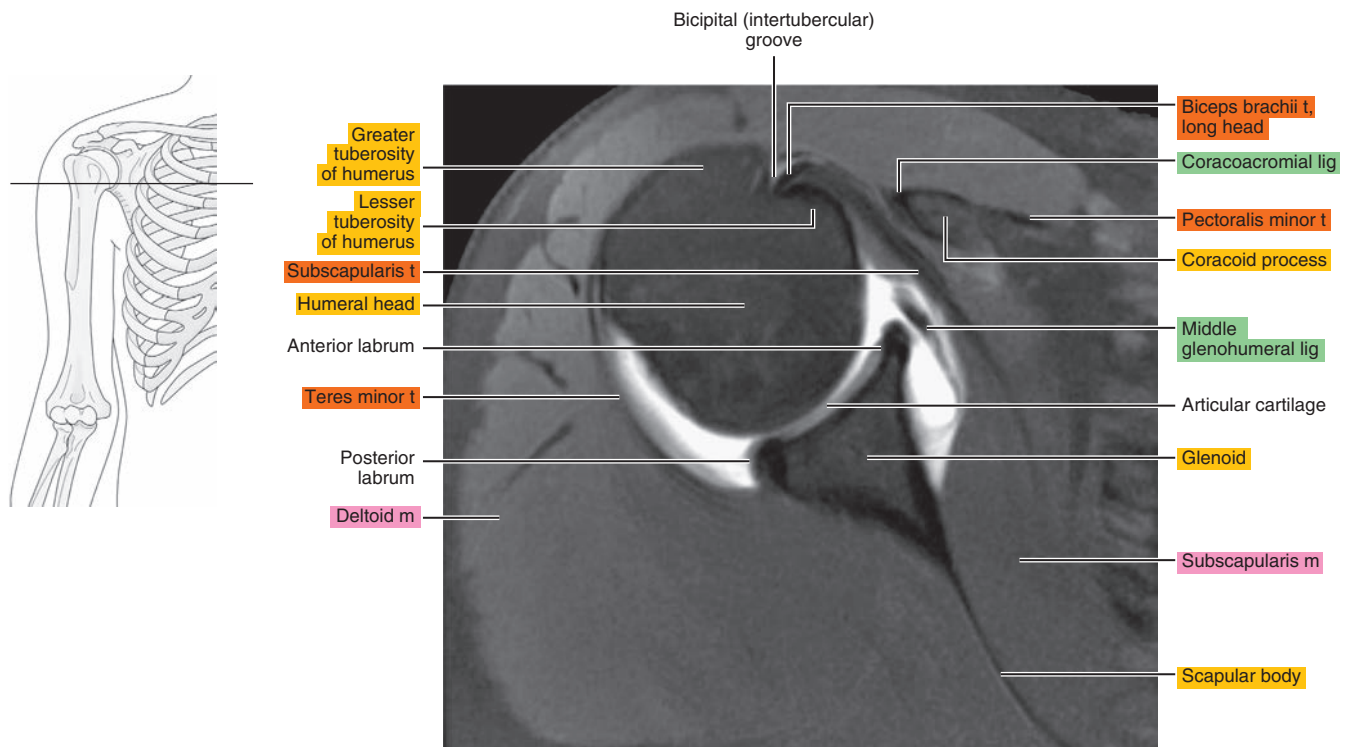


Figure 7.1.7

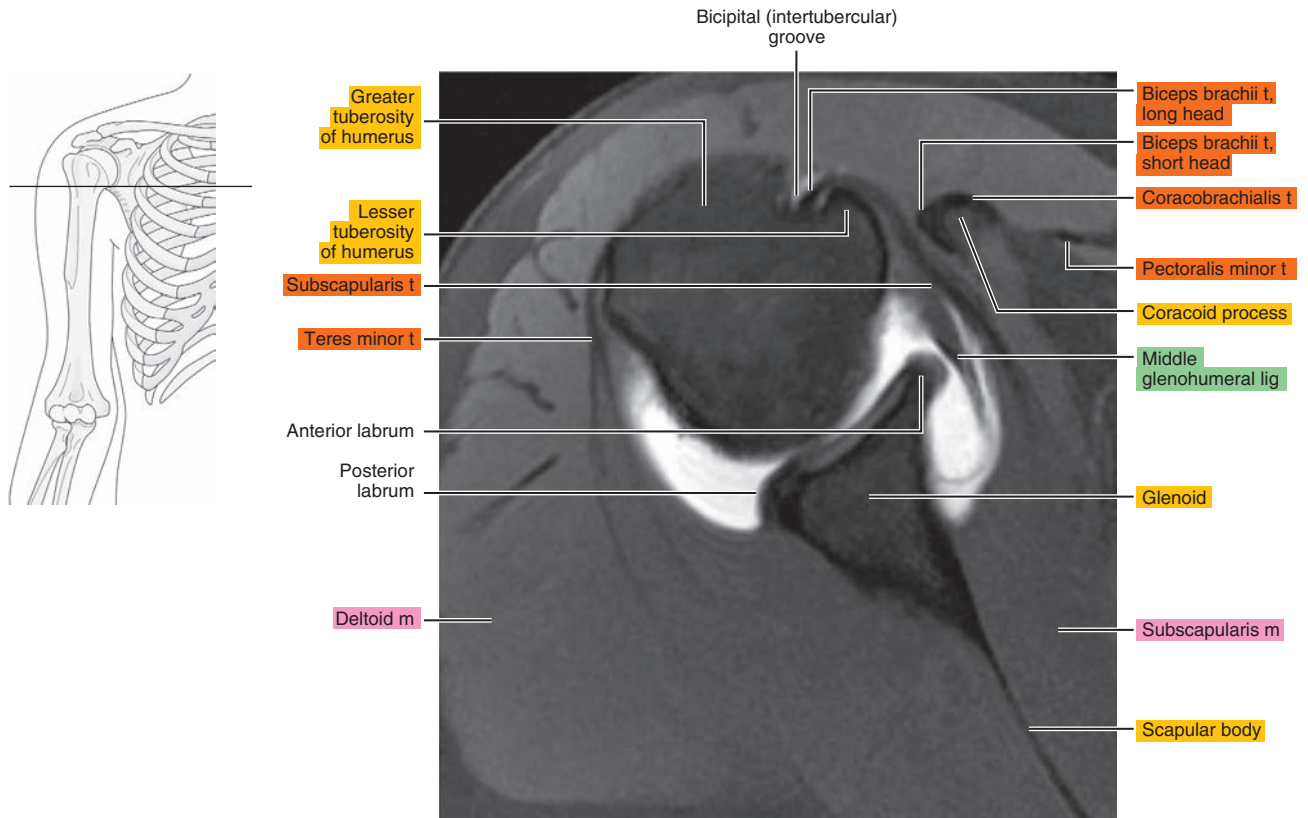


Figure 7.1.8

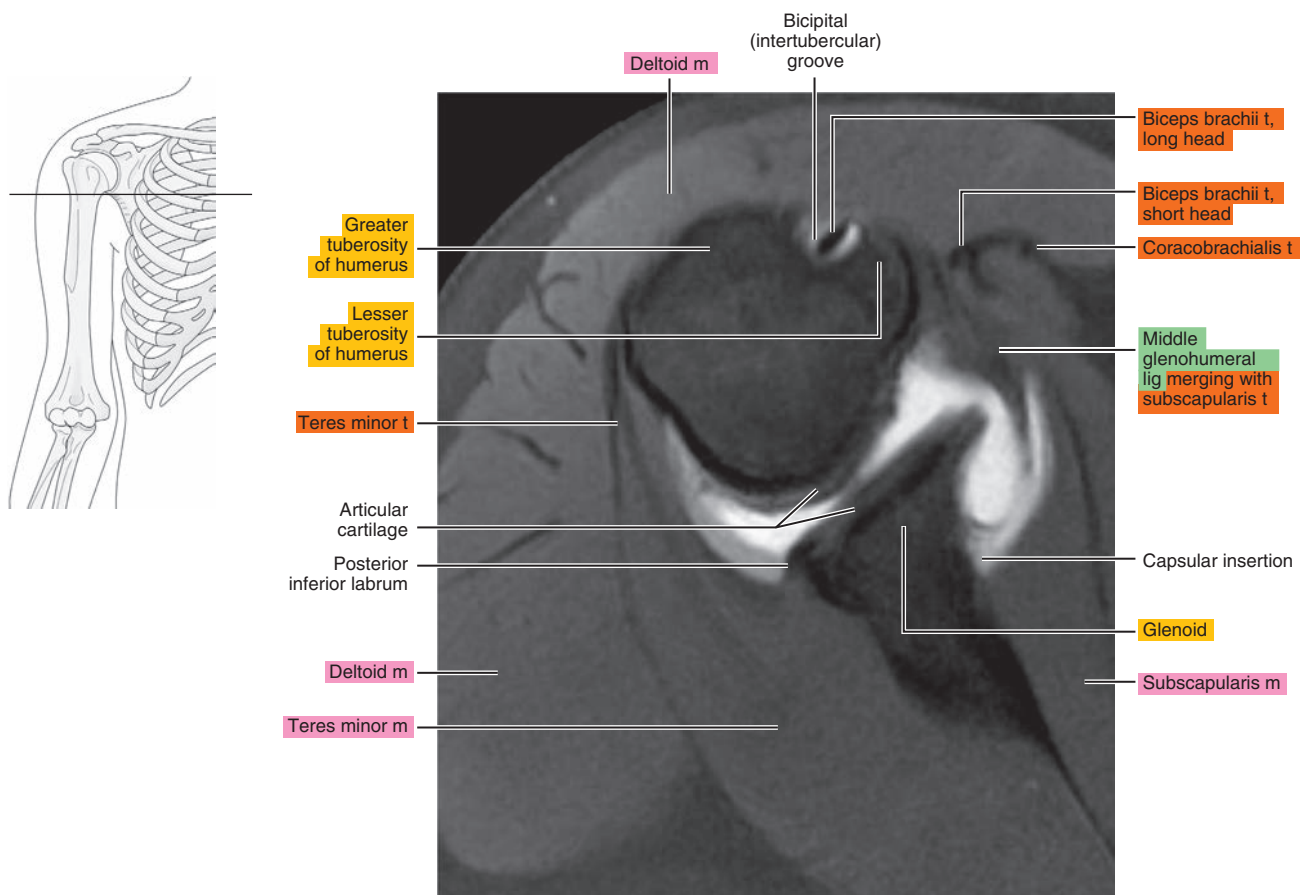




Figure 7.1.9

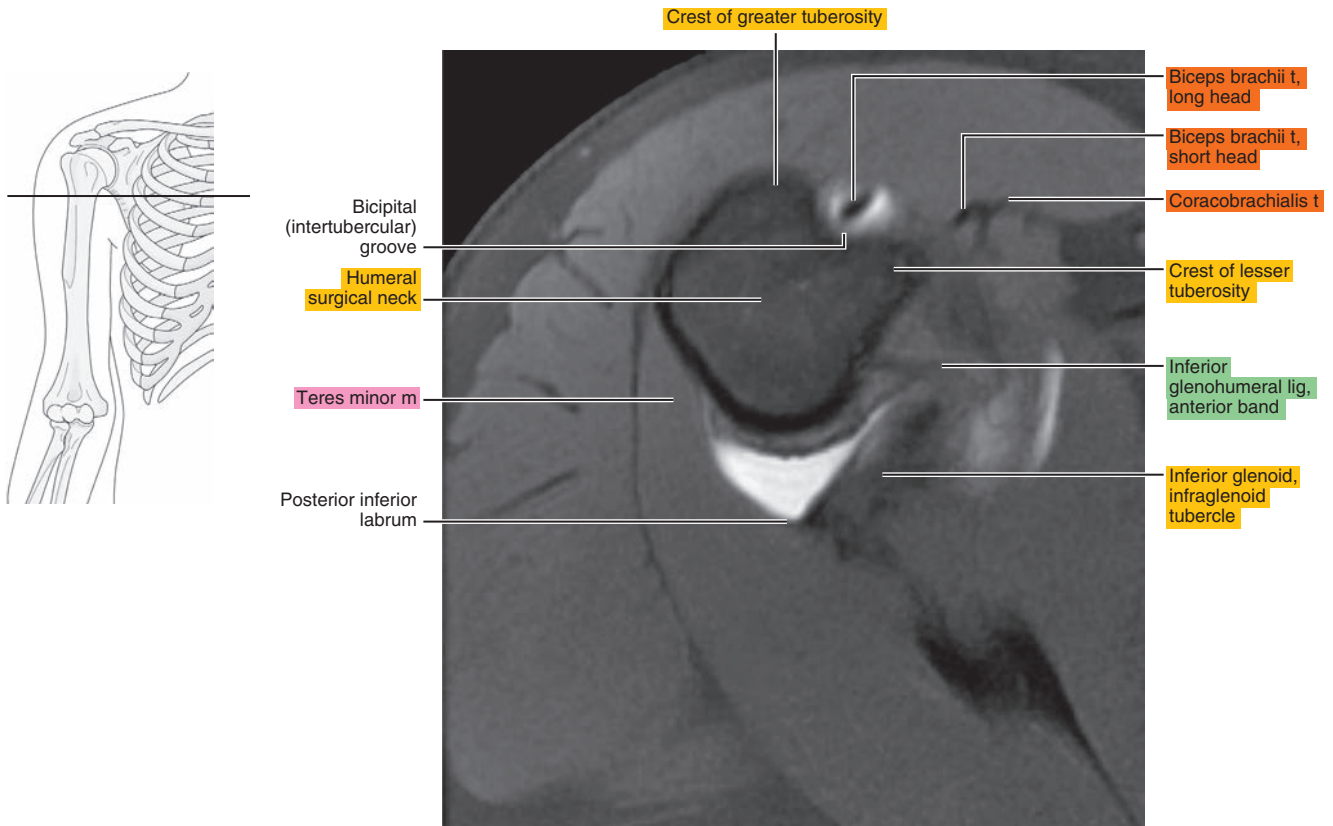
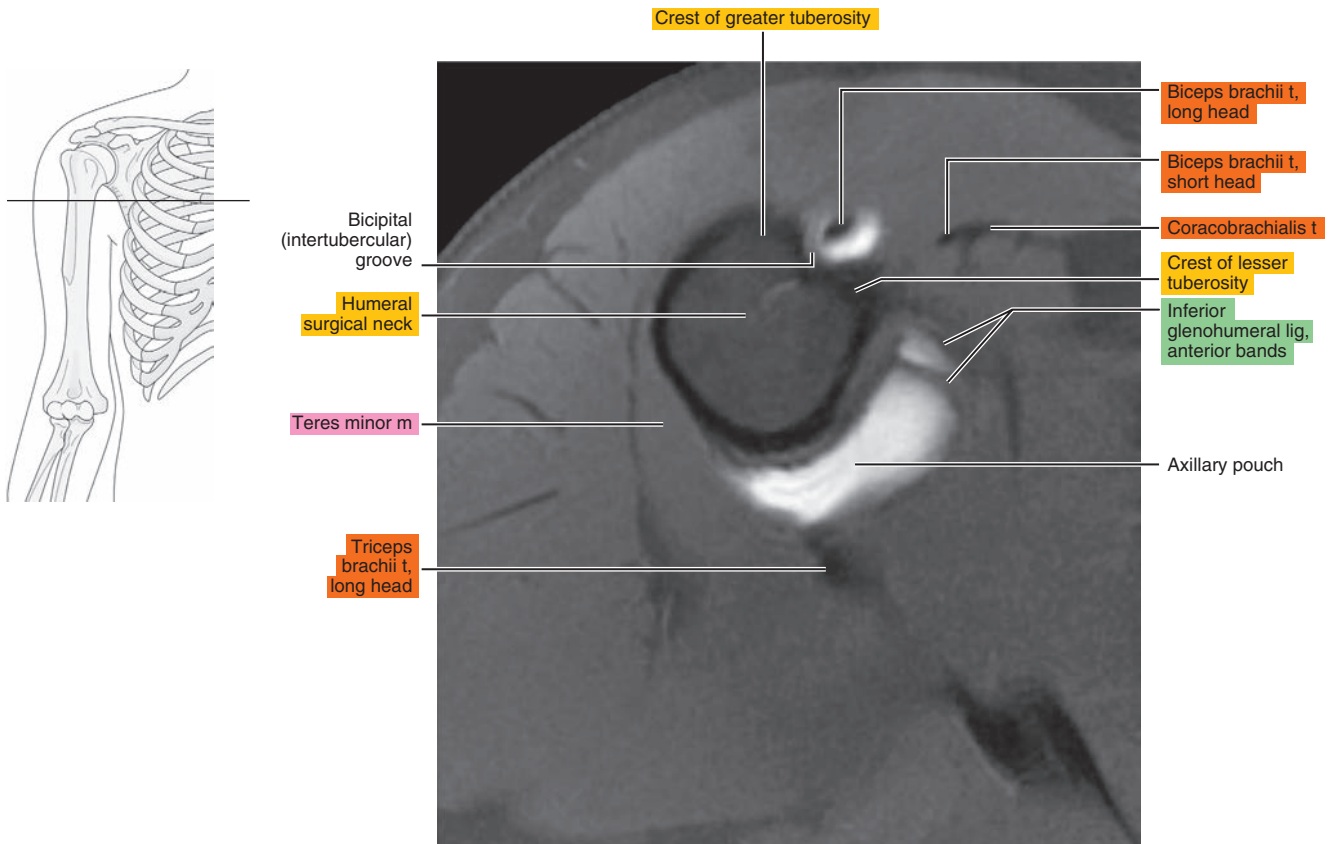


Figure 7.1.10



## OBLIQUE SAGITTAL

Figure 7.2.1

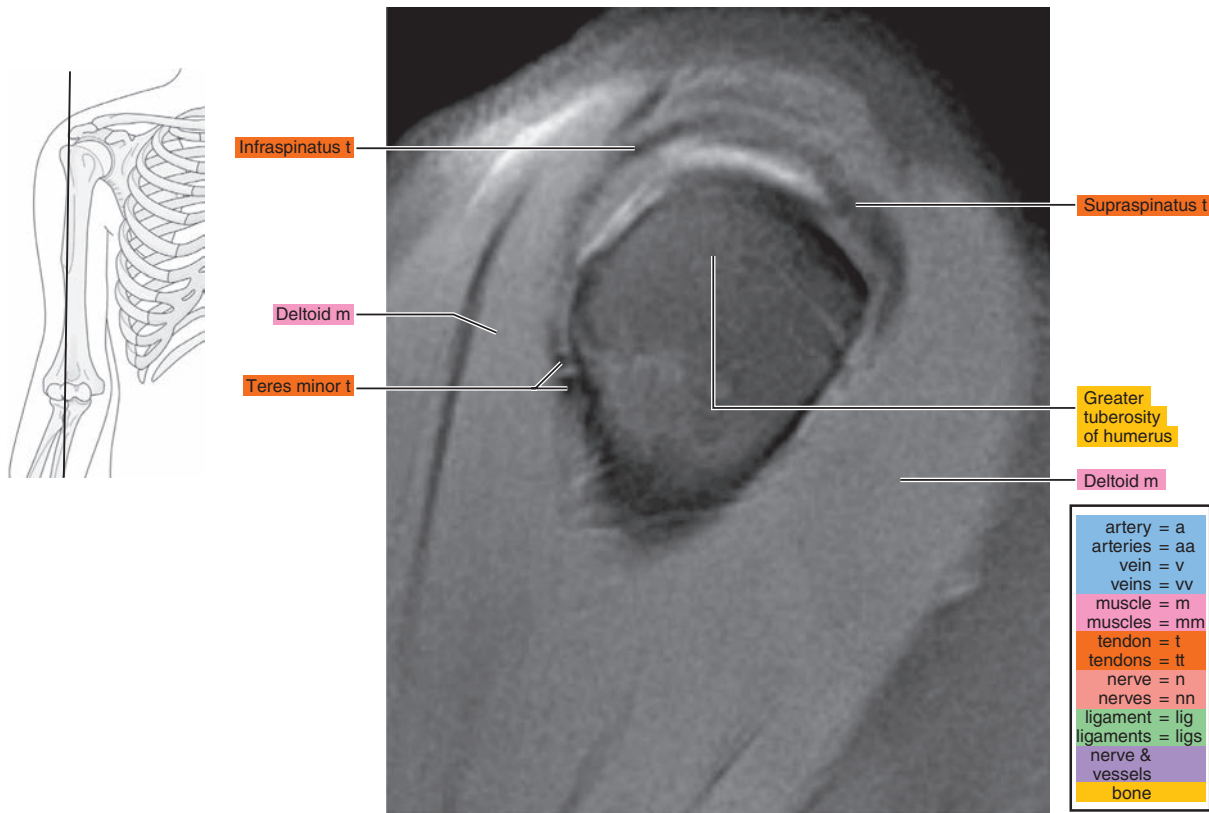


Figure 7.2.2

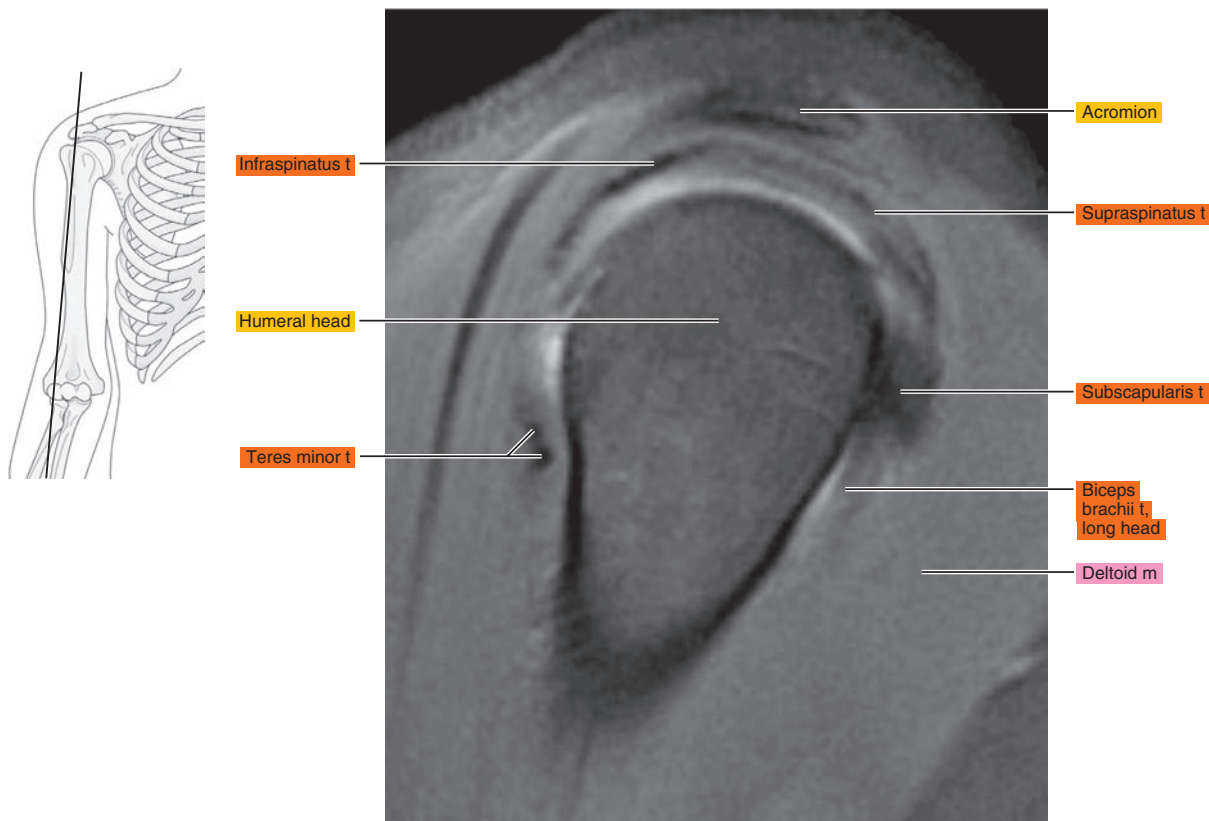


Figure 7.2.3

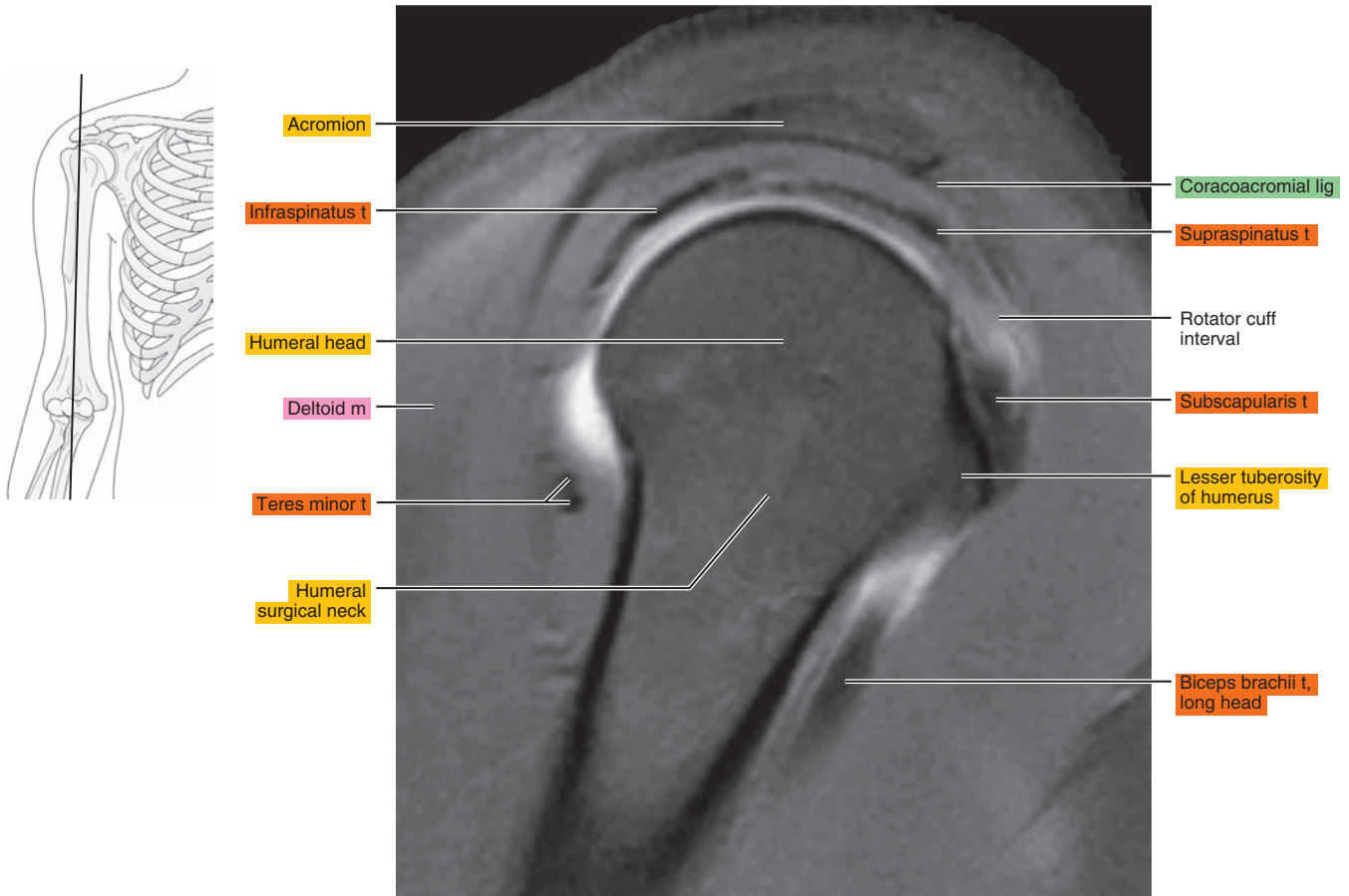


Figure 7.2.4

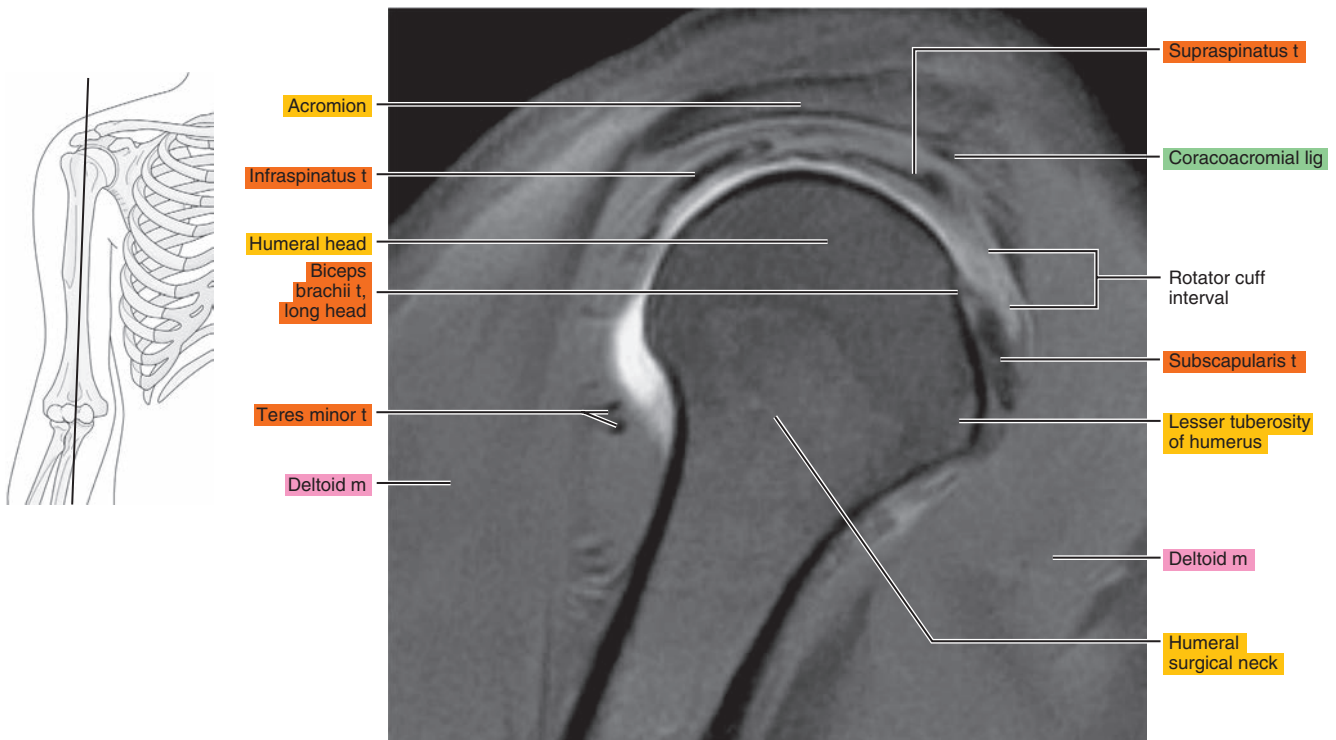


Figure 7.2.5

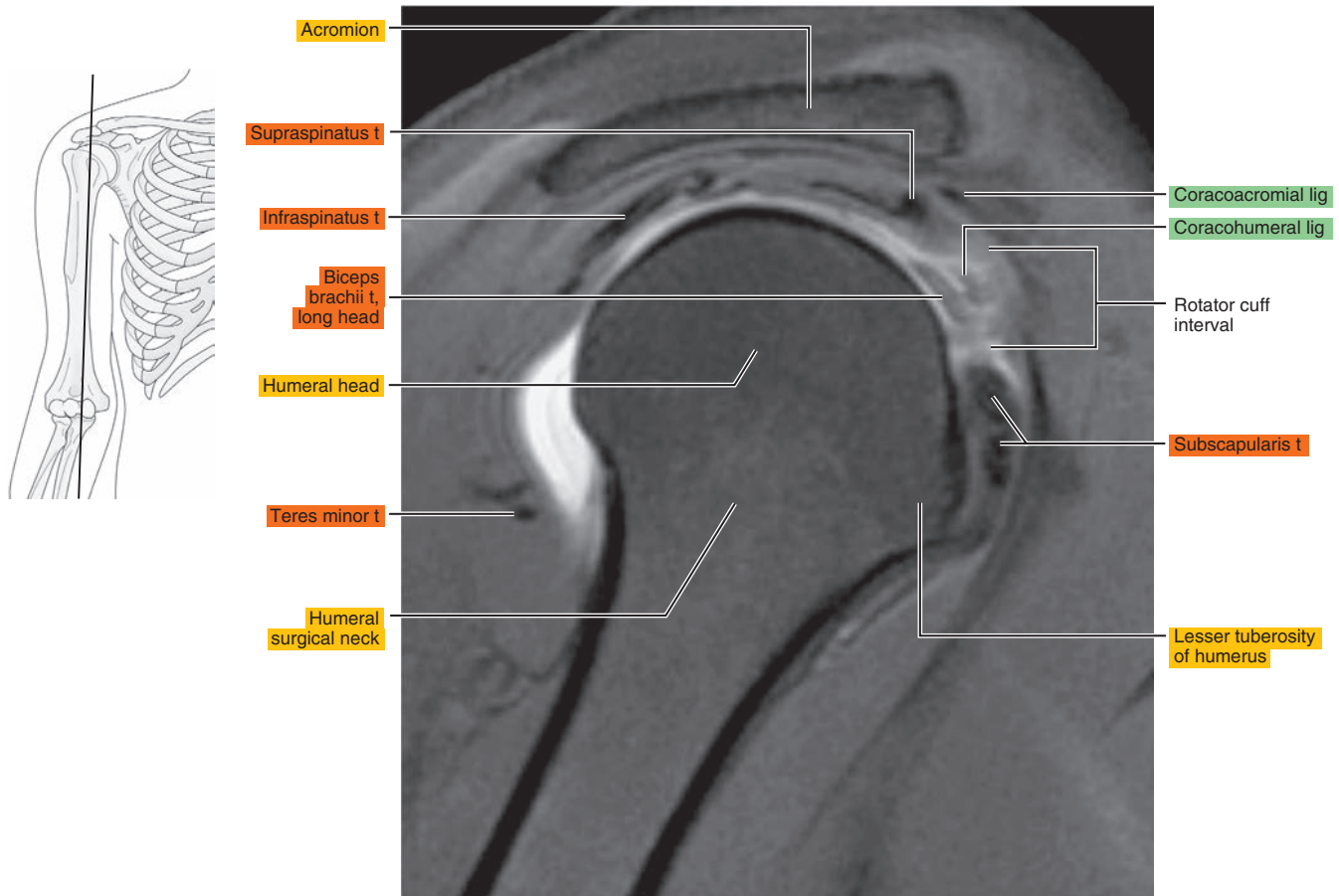


Figure 7.2.6

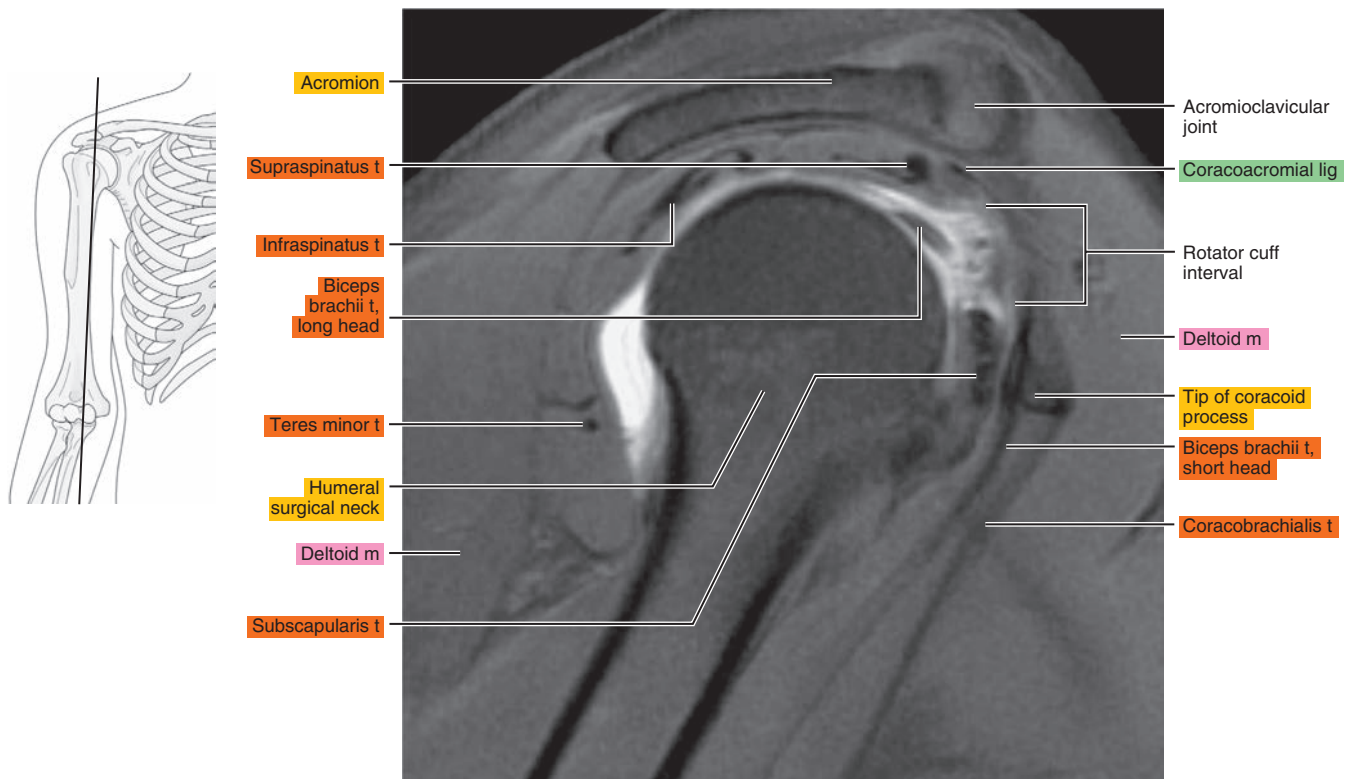




Figure 7.2.7

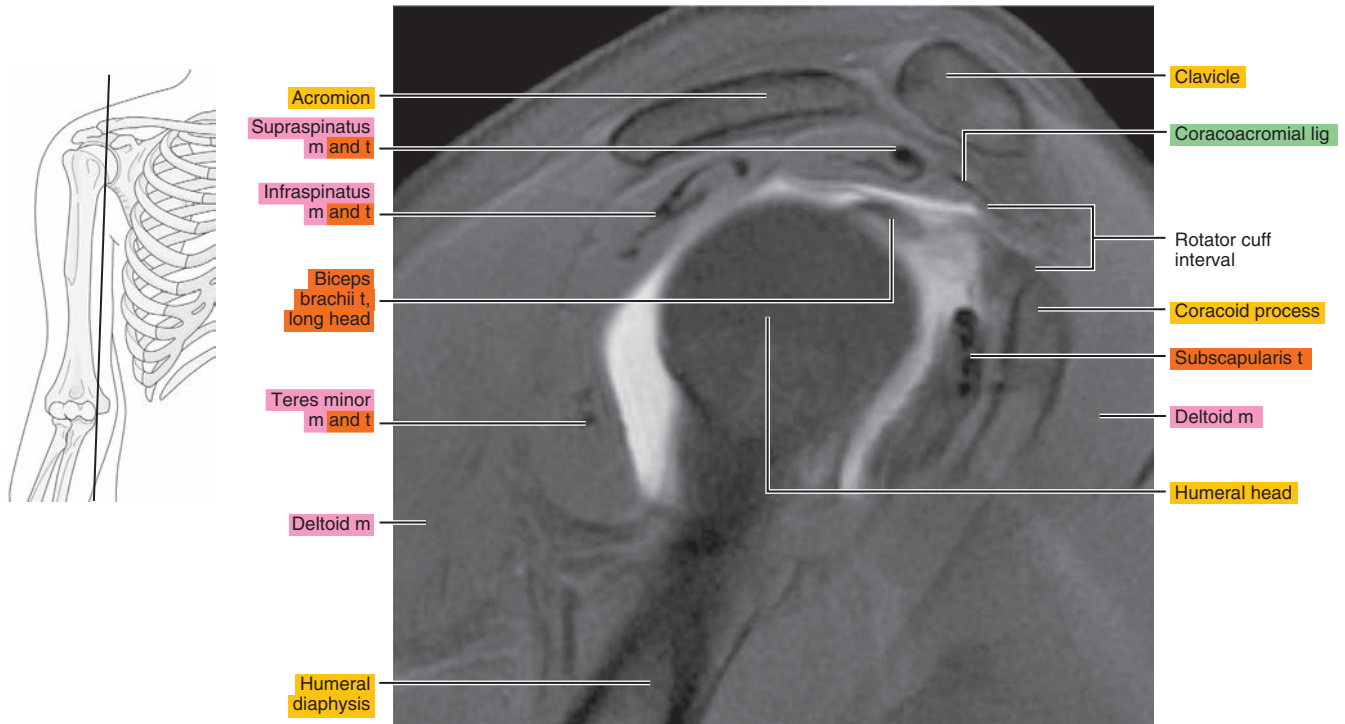


Figure 7.2.8

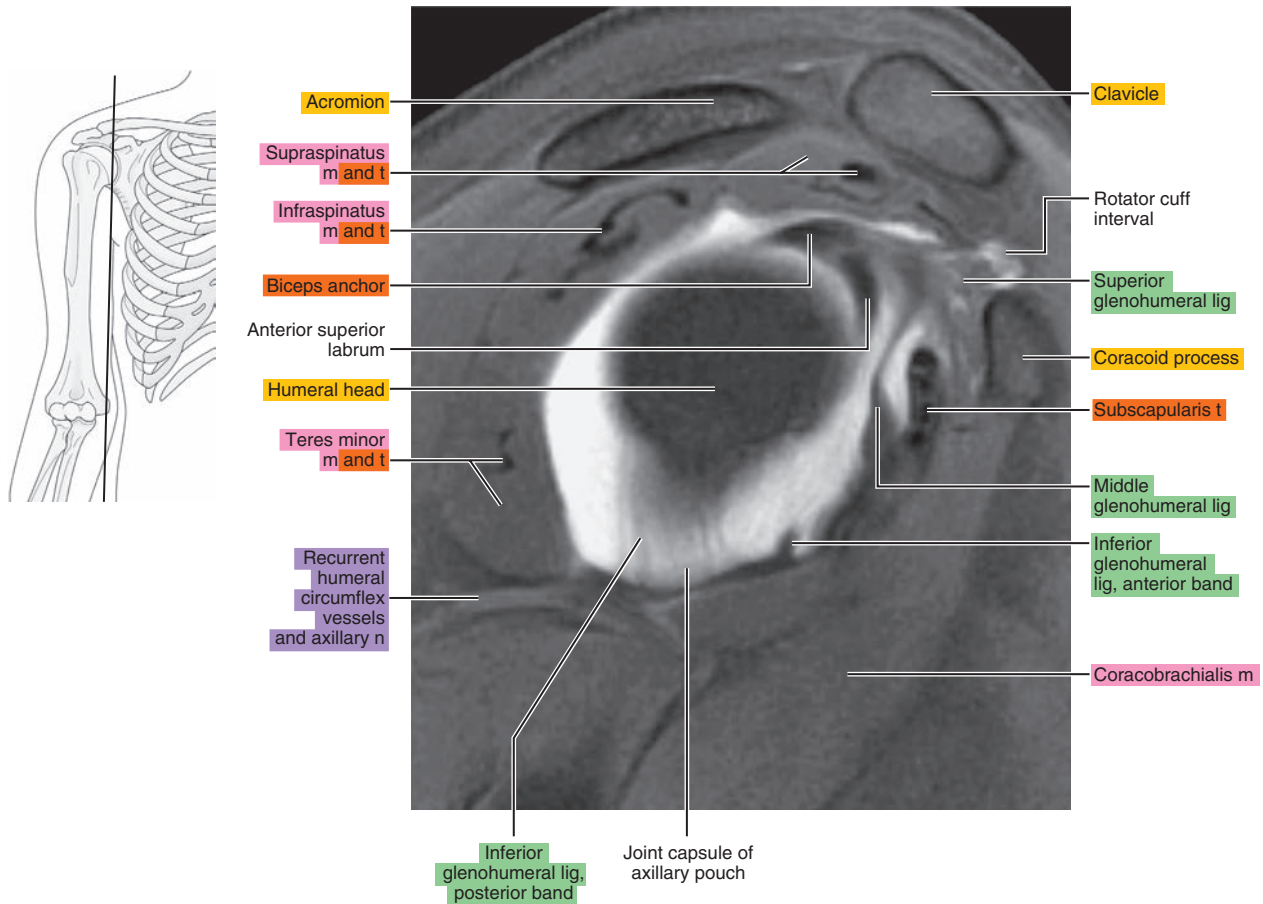


Figure 7.2.9

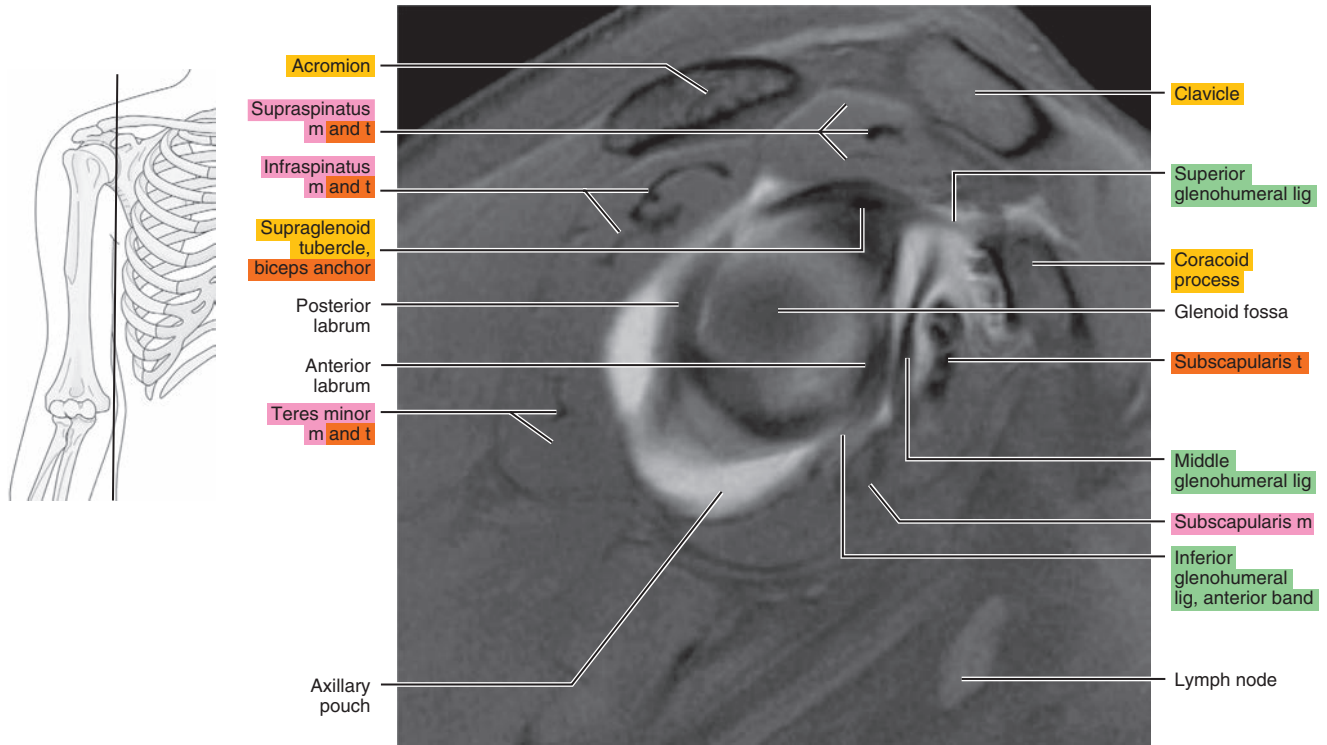


Figure 7.2.10

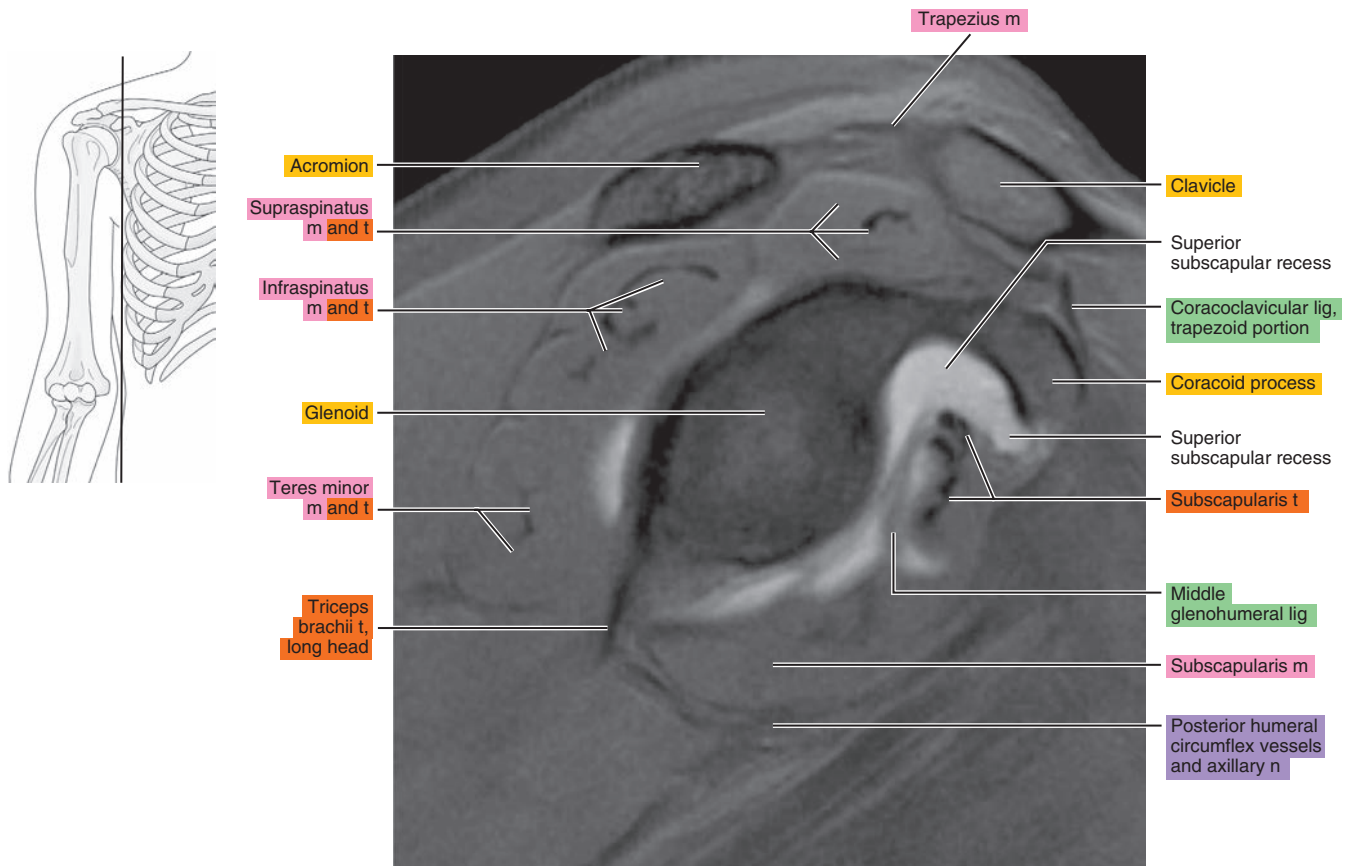
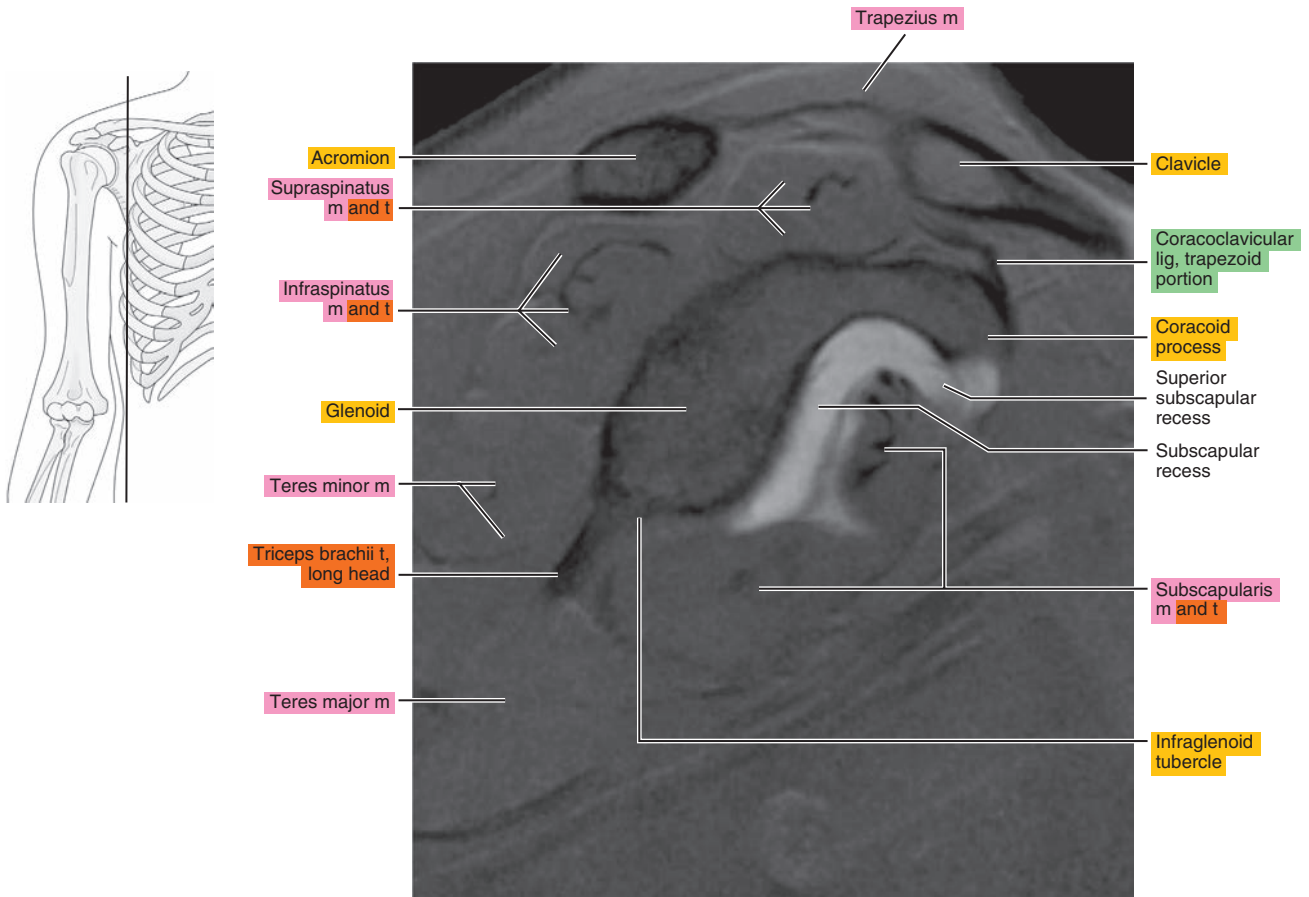


Figure 7.2.11



# OBLIQUE CORONAL

Figure 7.3.1

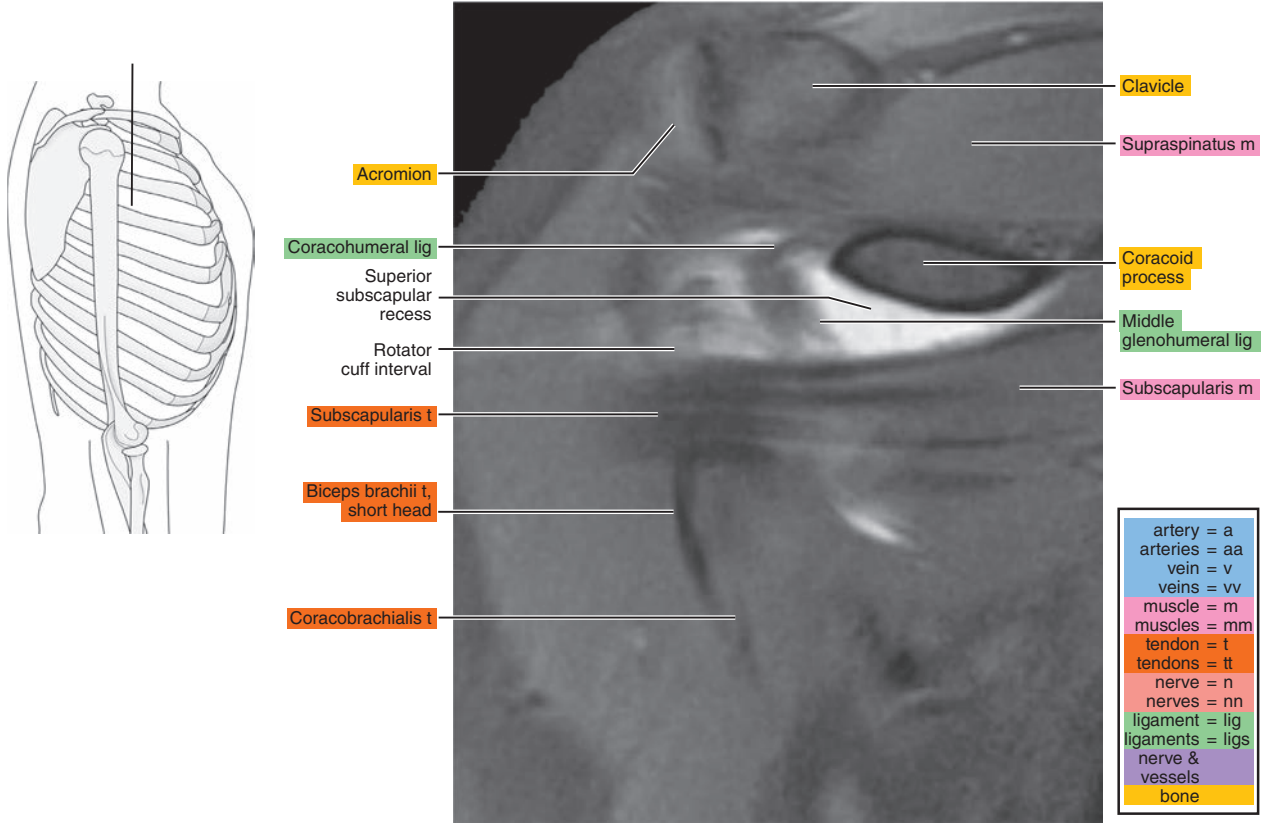


Figure 7.3.2

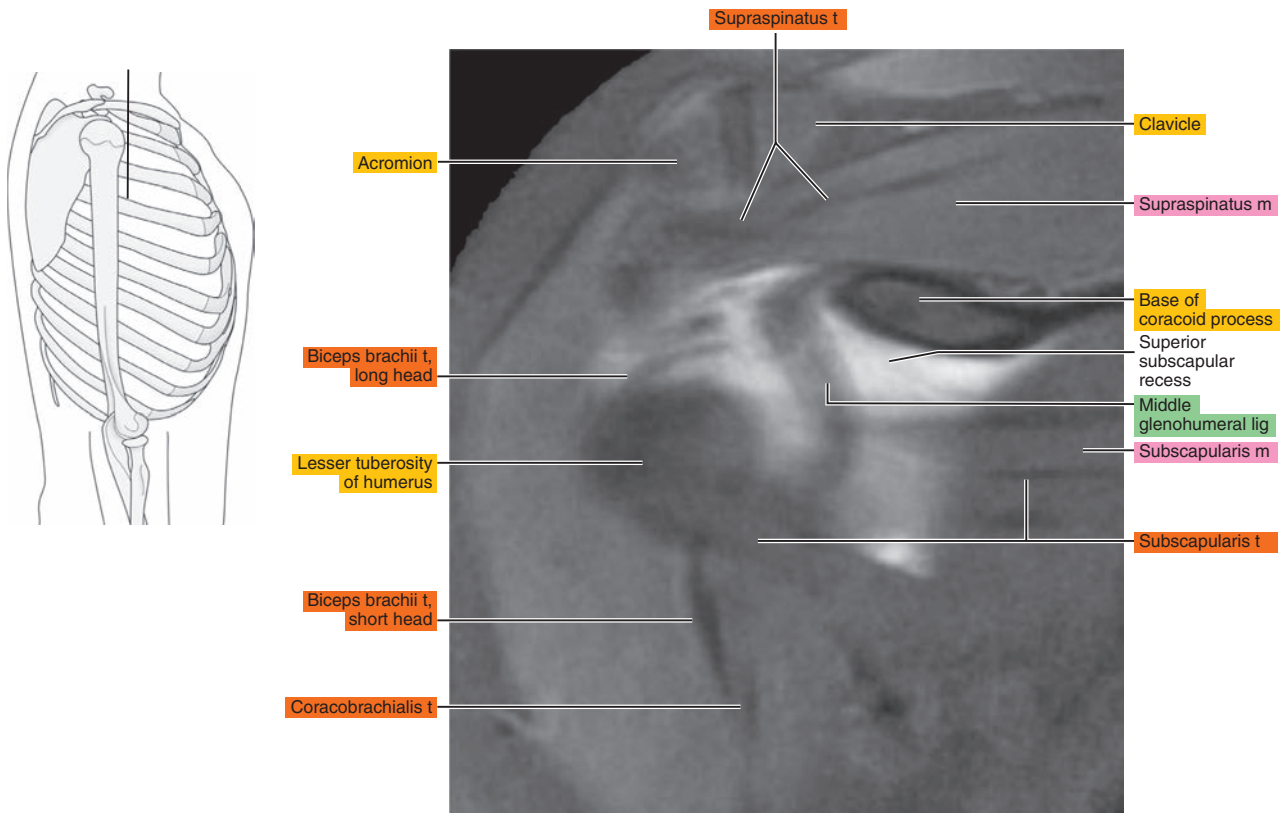




Figure 7.3.3

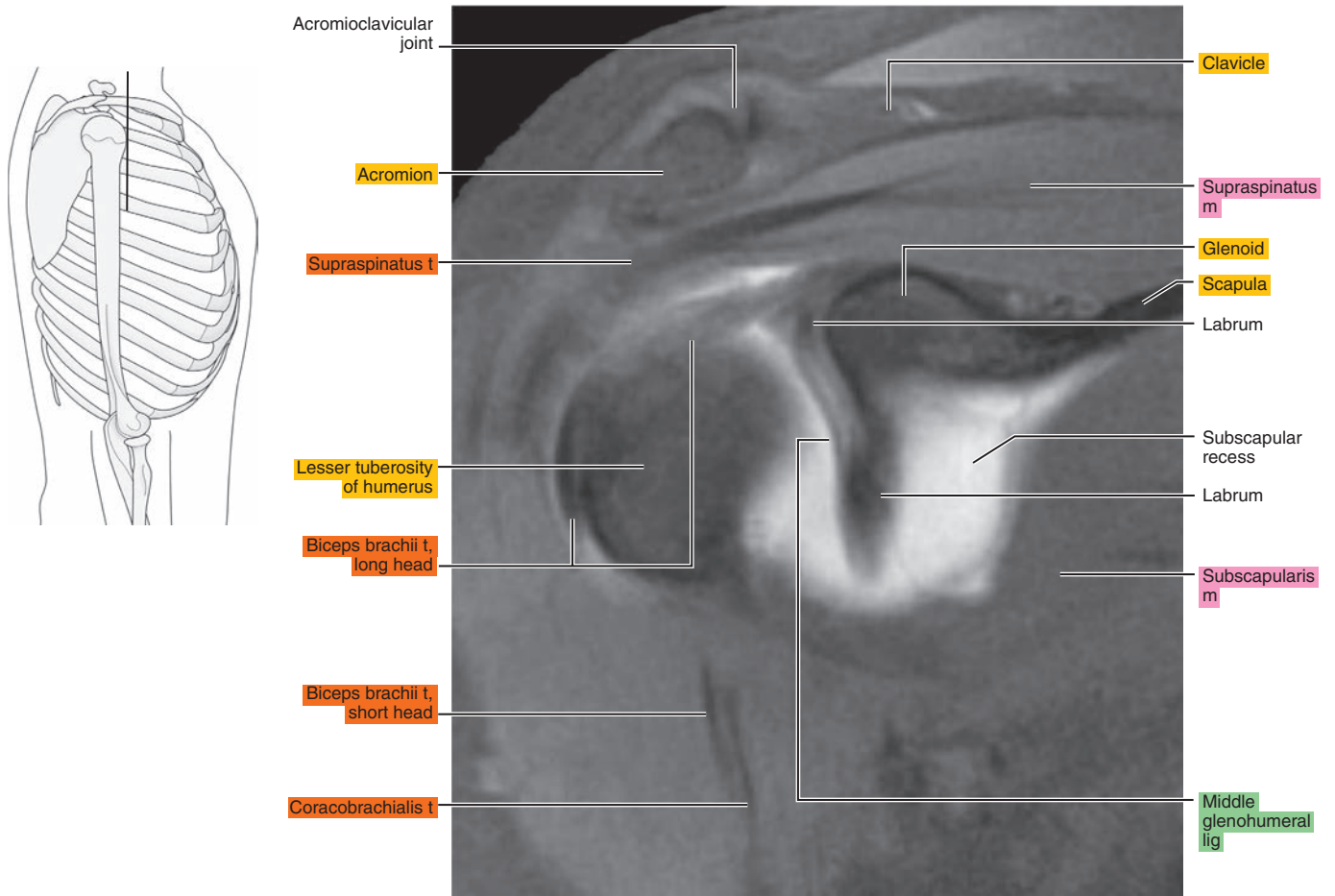


Figure 7.3.4

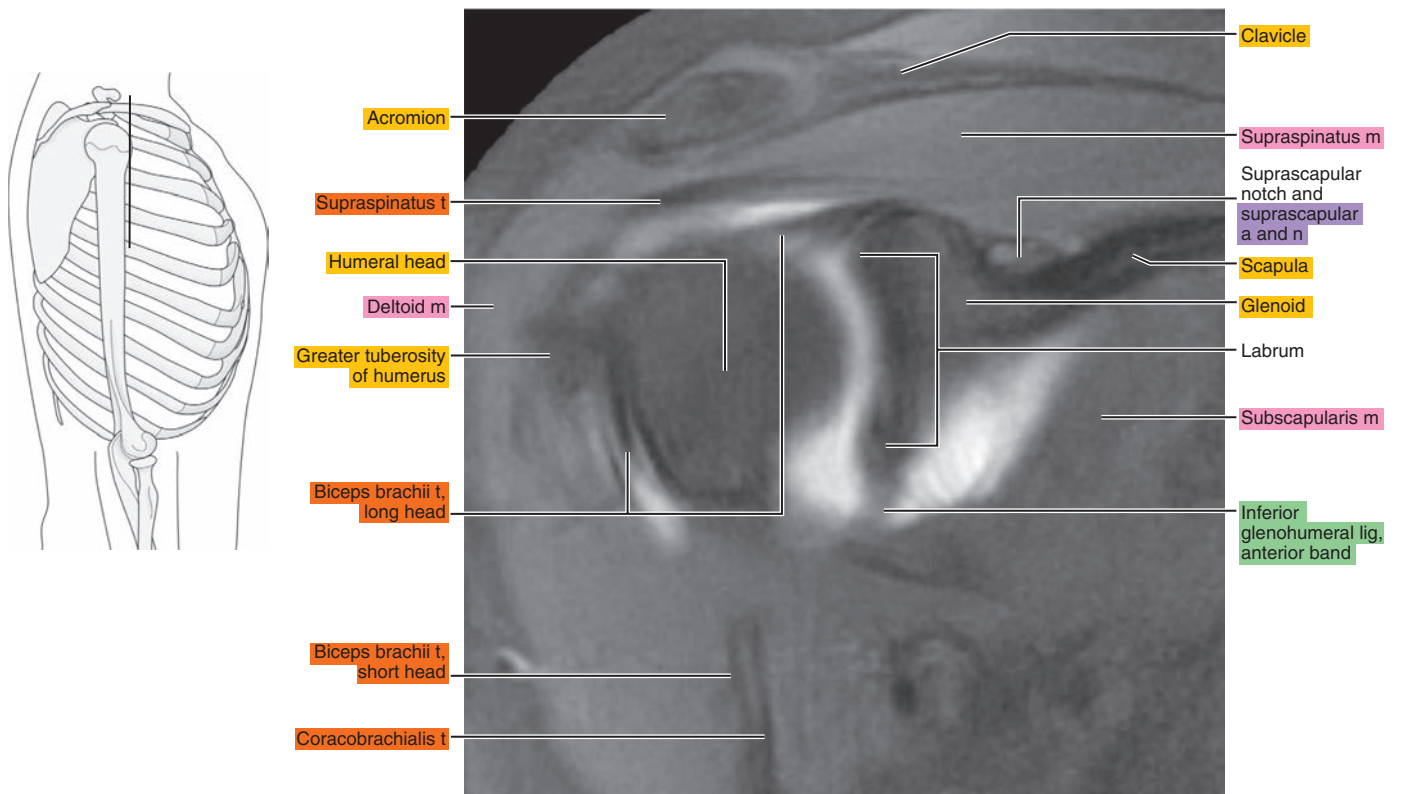


Figure 7.3.5

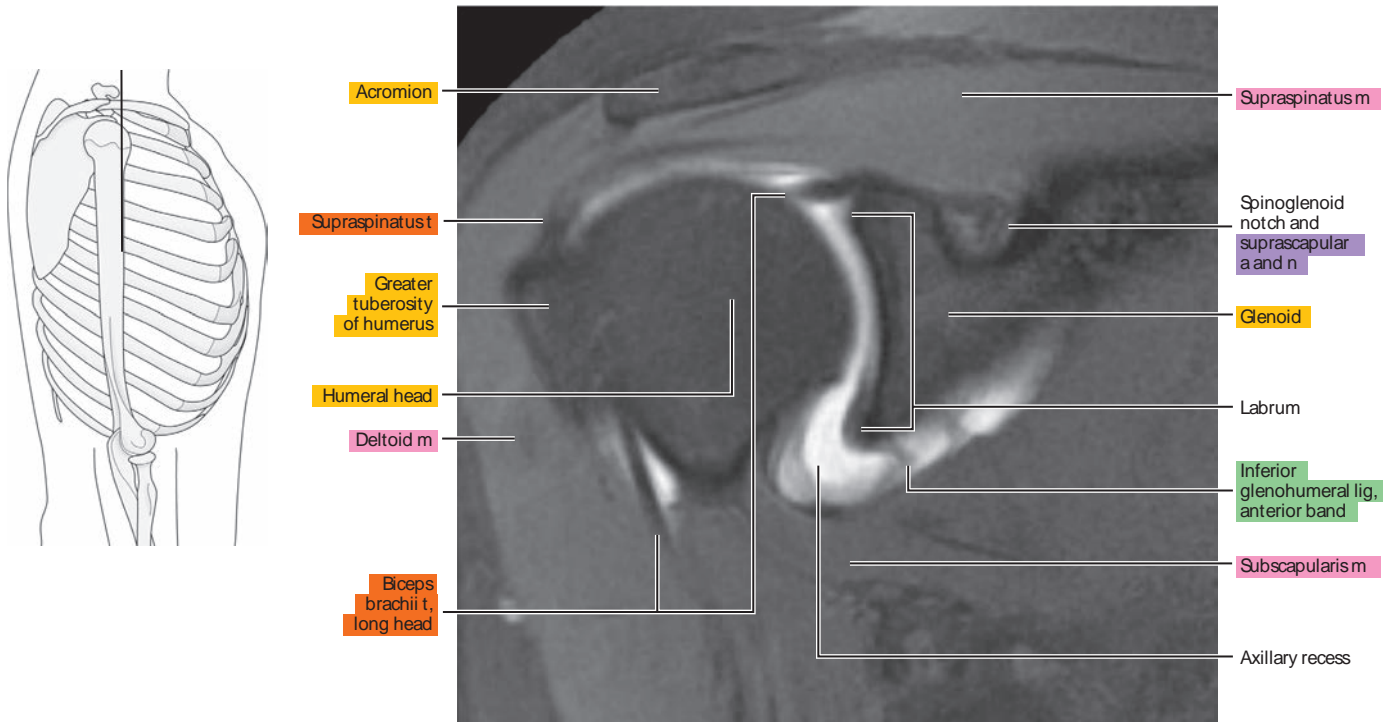


Figure 7.3.6

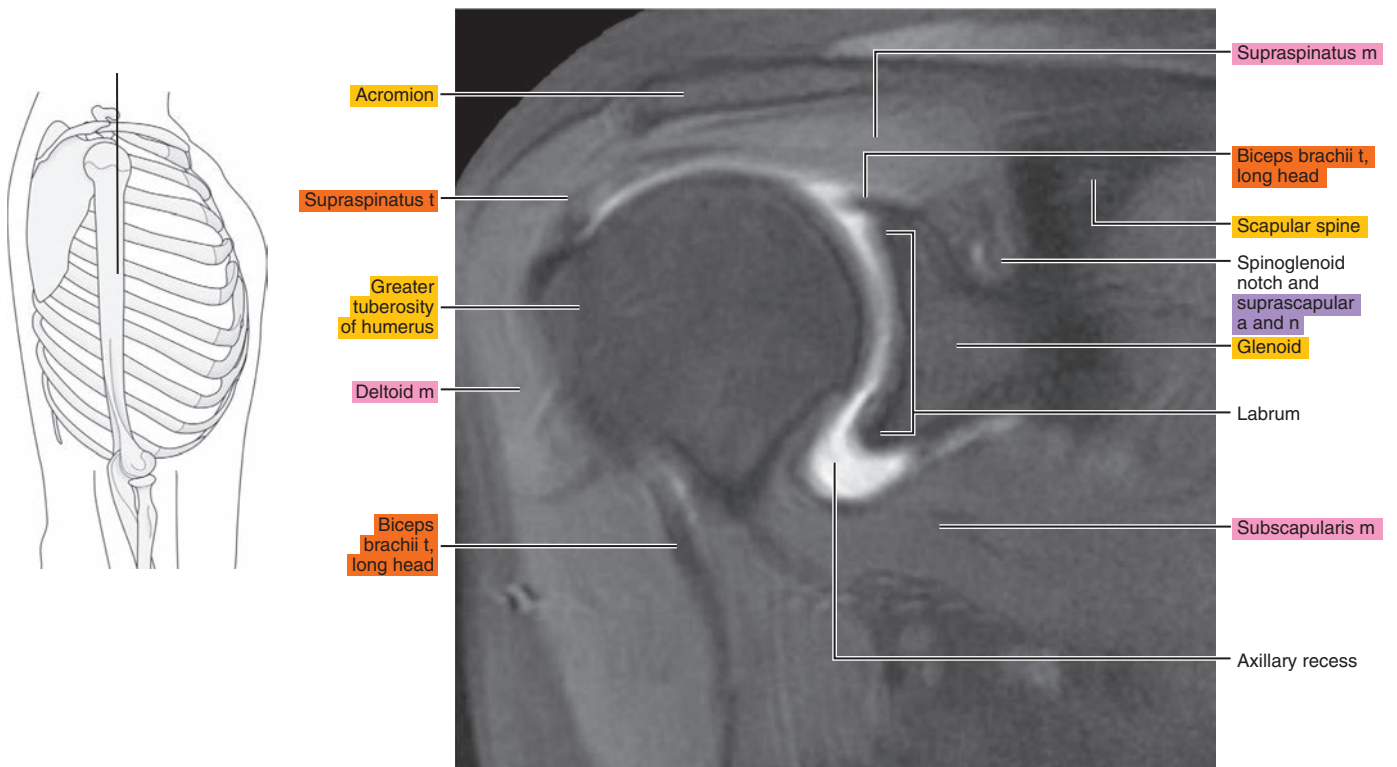


Figure 7.3.7

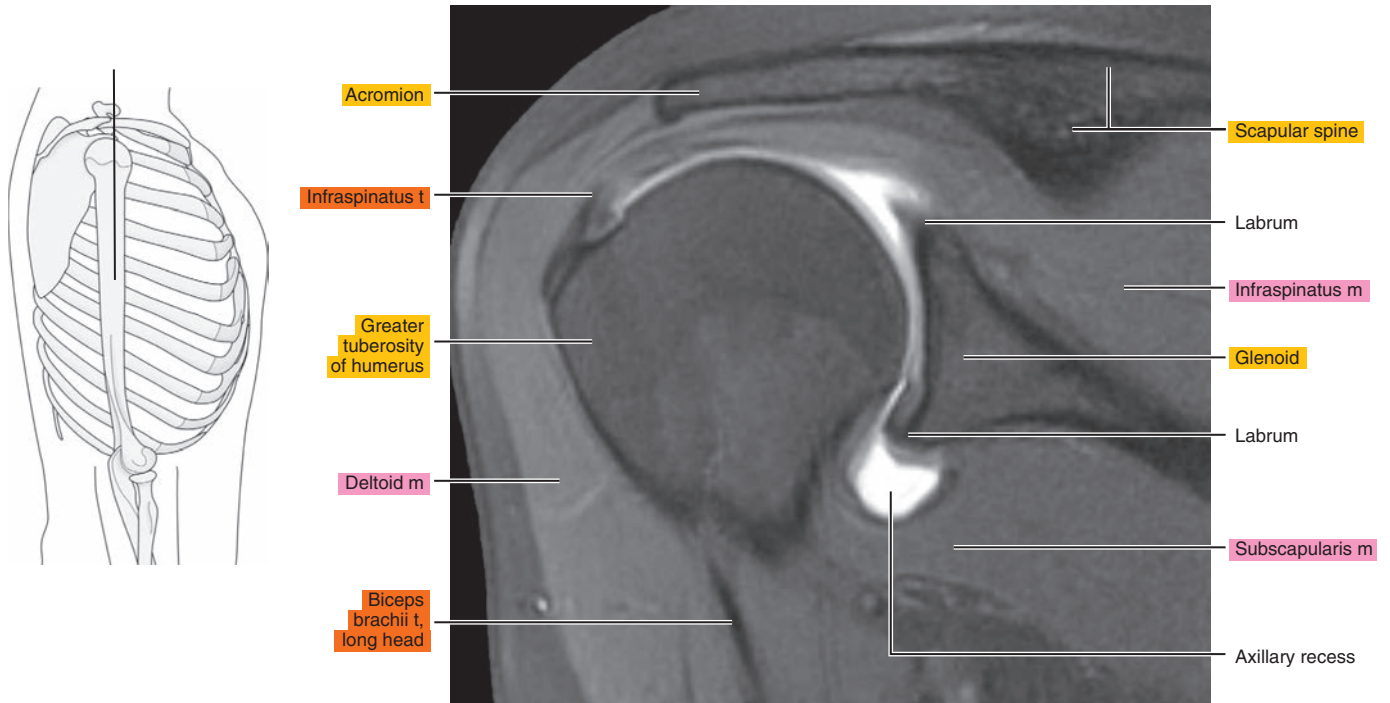


Figure 7.3.8

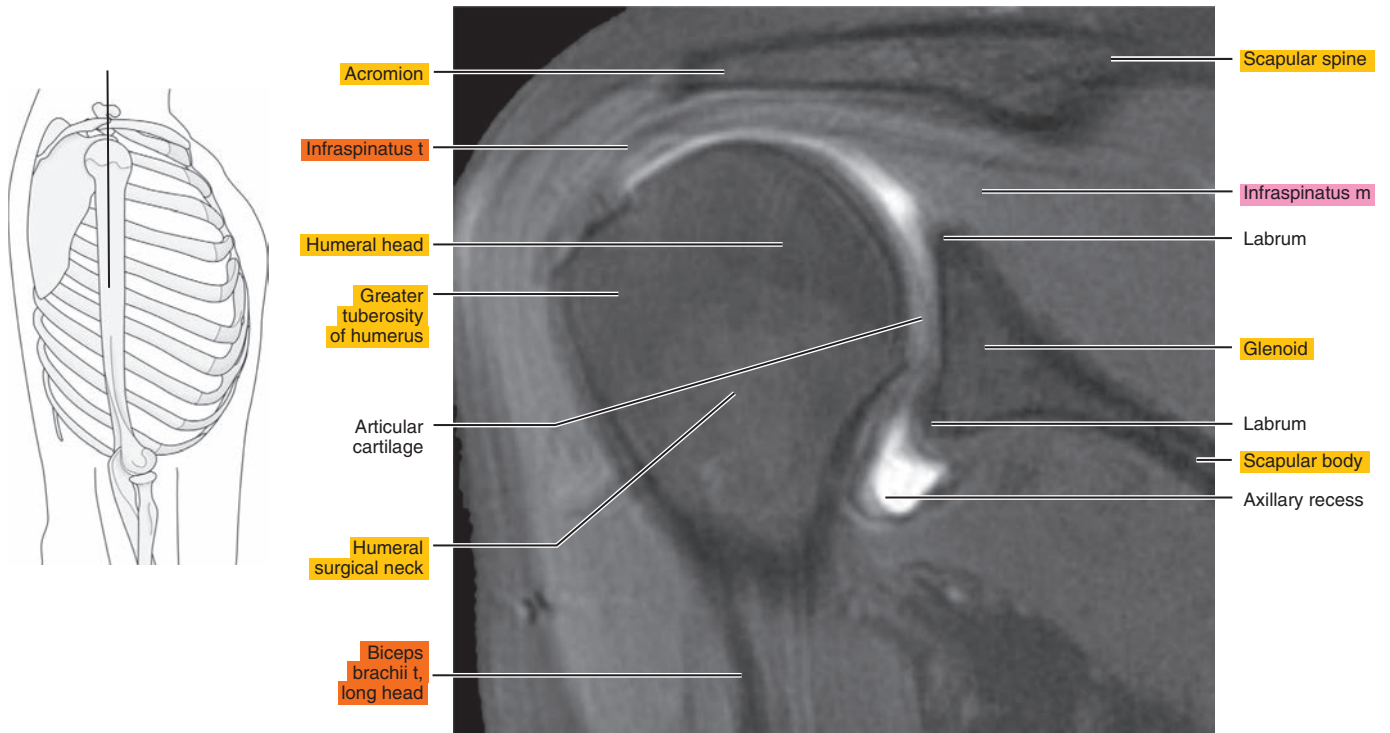


Figure 7.3.9

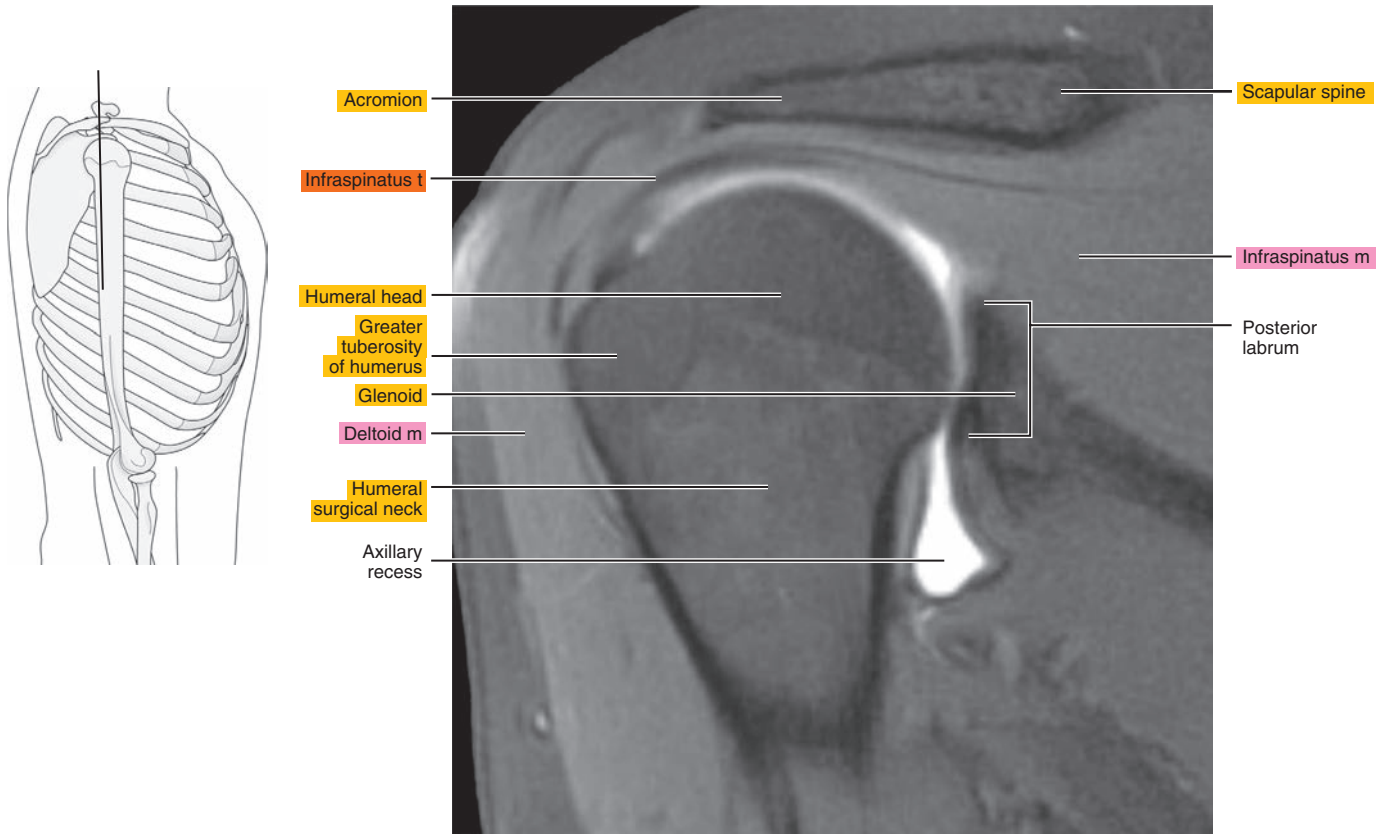


Figure 7.3.10

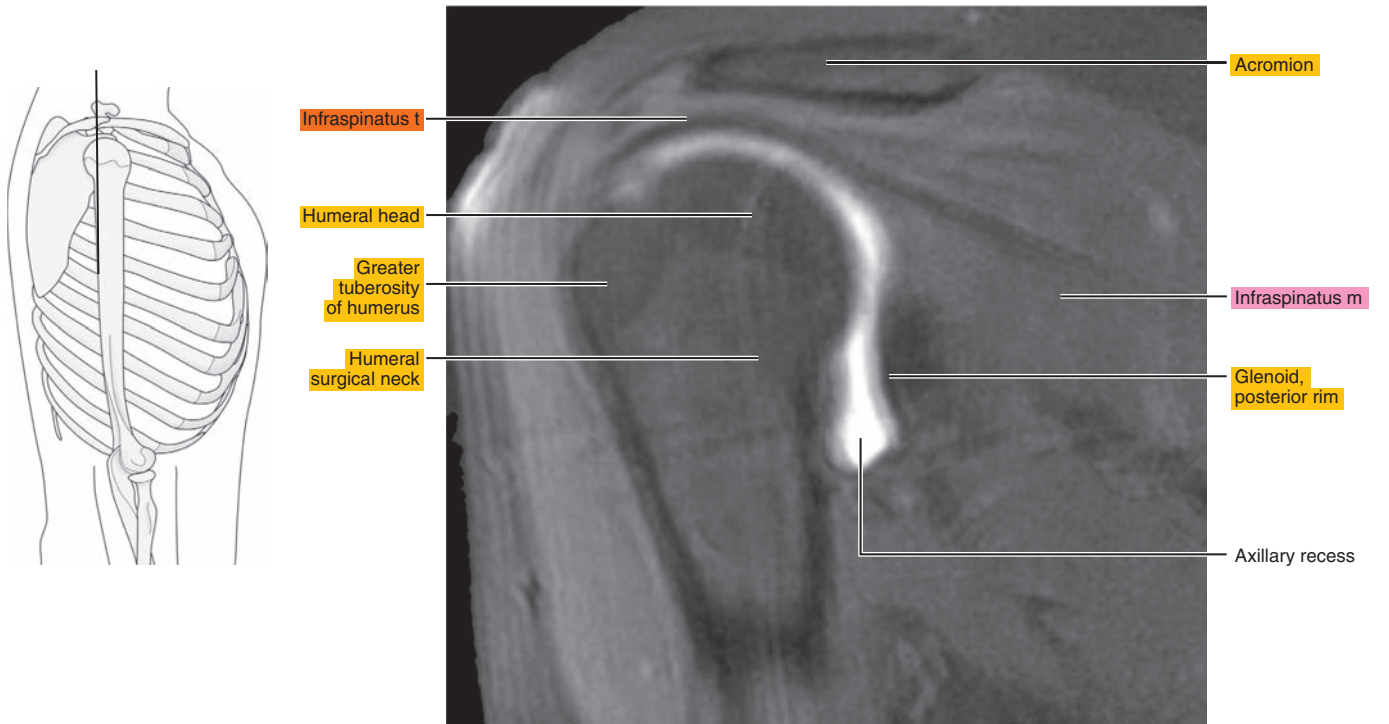




Figure 7.3.11

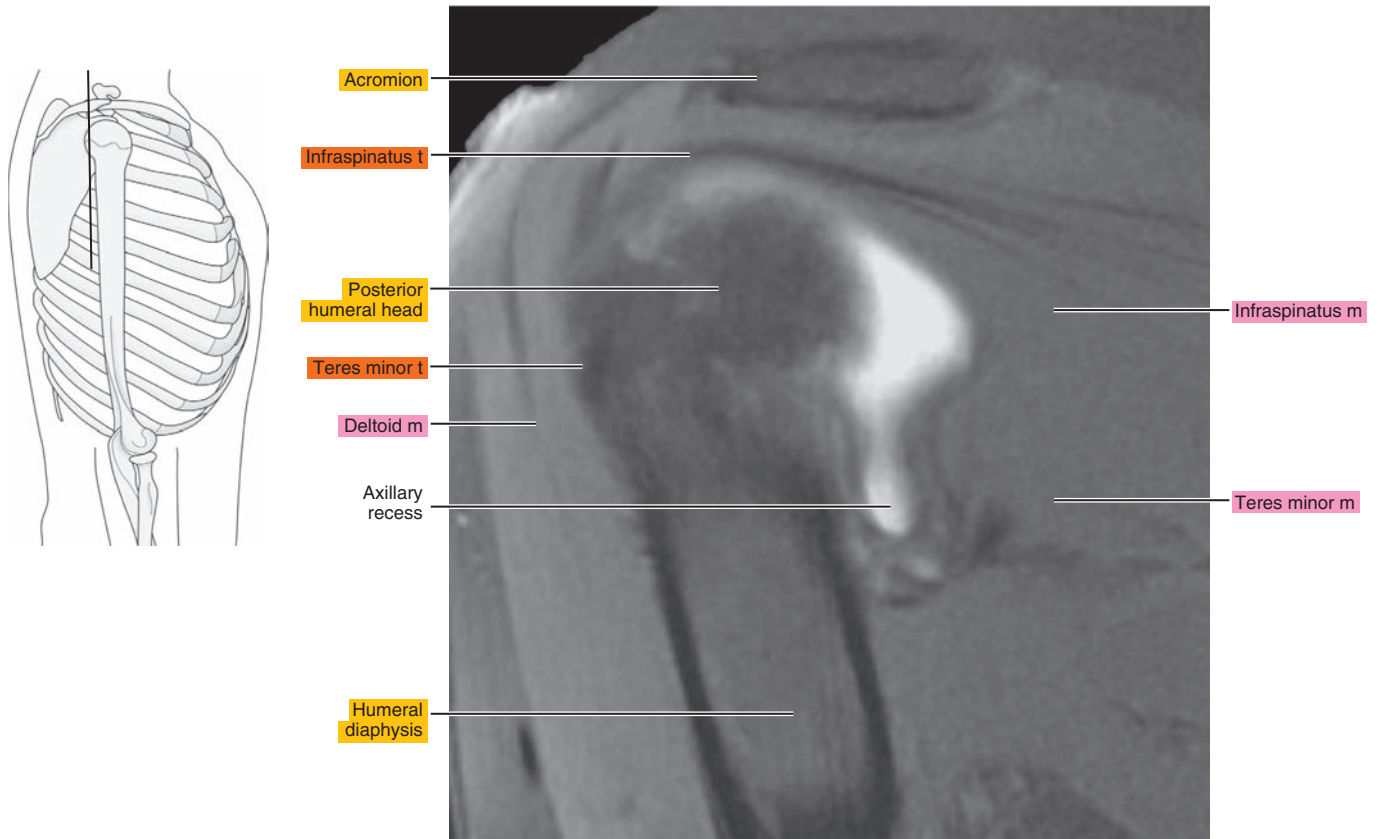



Figure 7.3.12



# ABER (ABDUCTION AND EXTERNAL ROTATION)

Figure 7.4.1

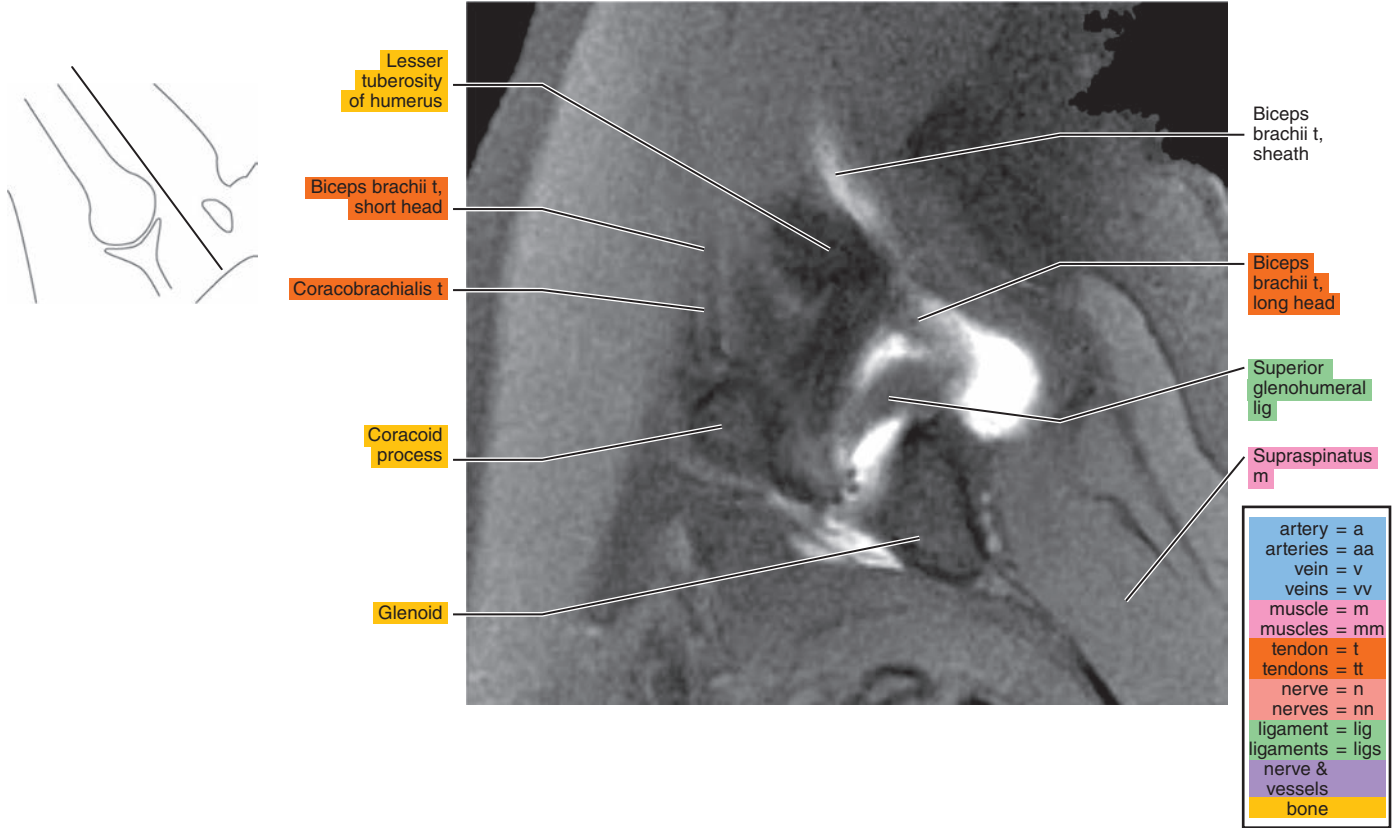


Figure 7.4.2

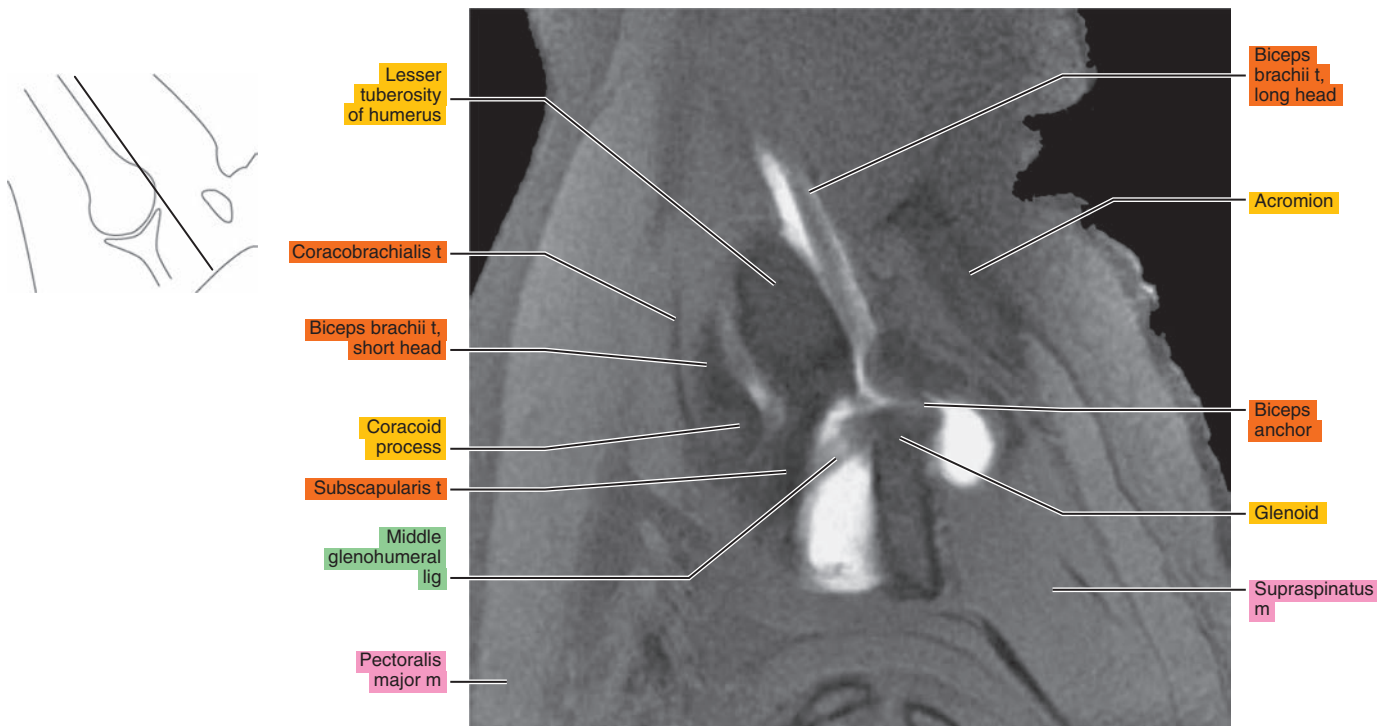


Figure 7.4.3

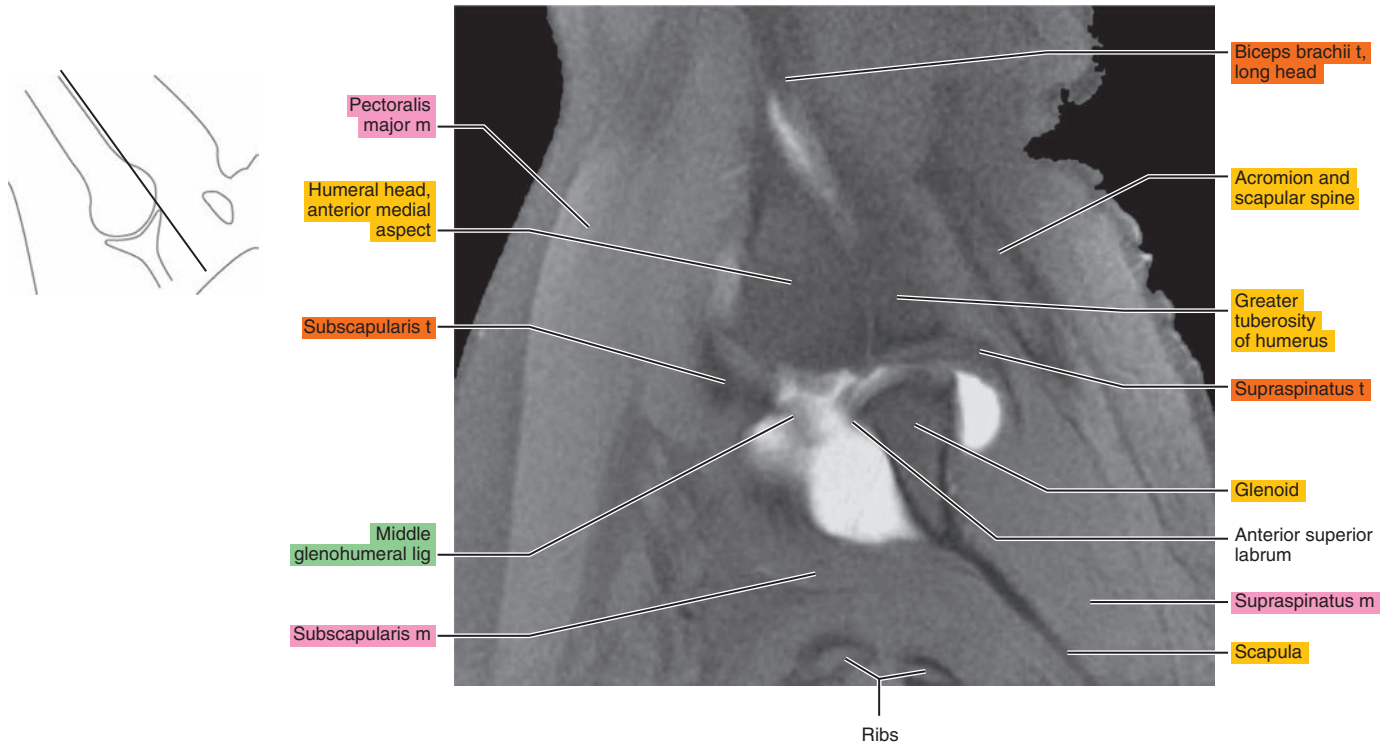


Figure 7.4.4

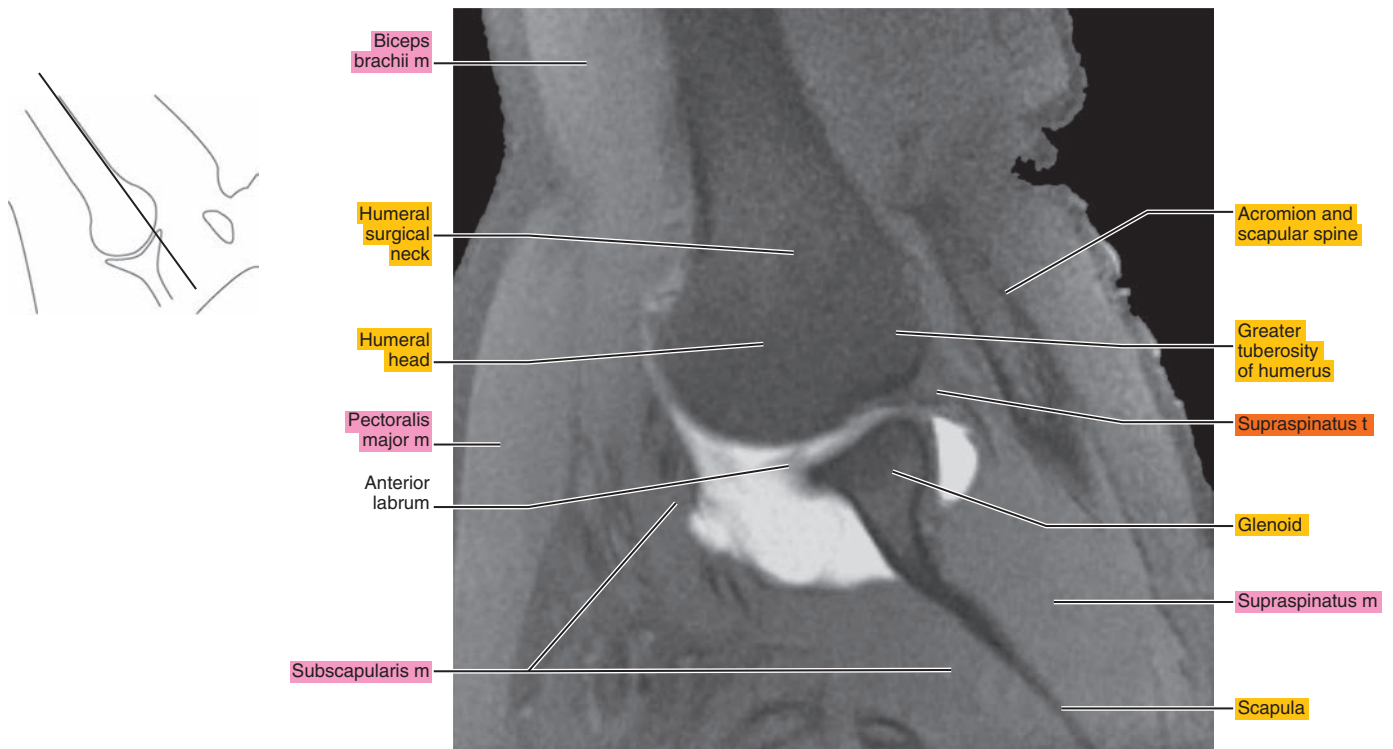


Figure 7.4.5

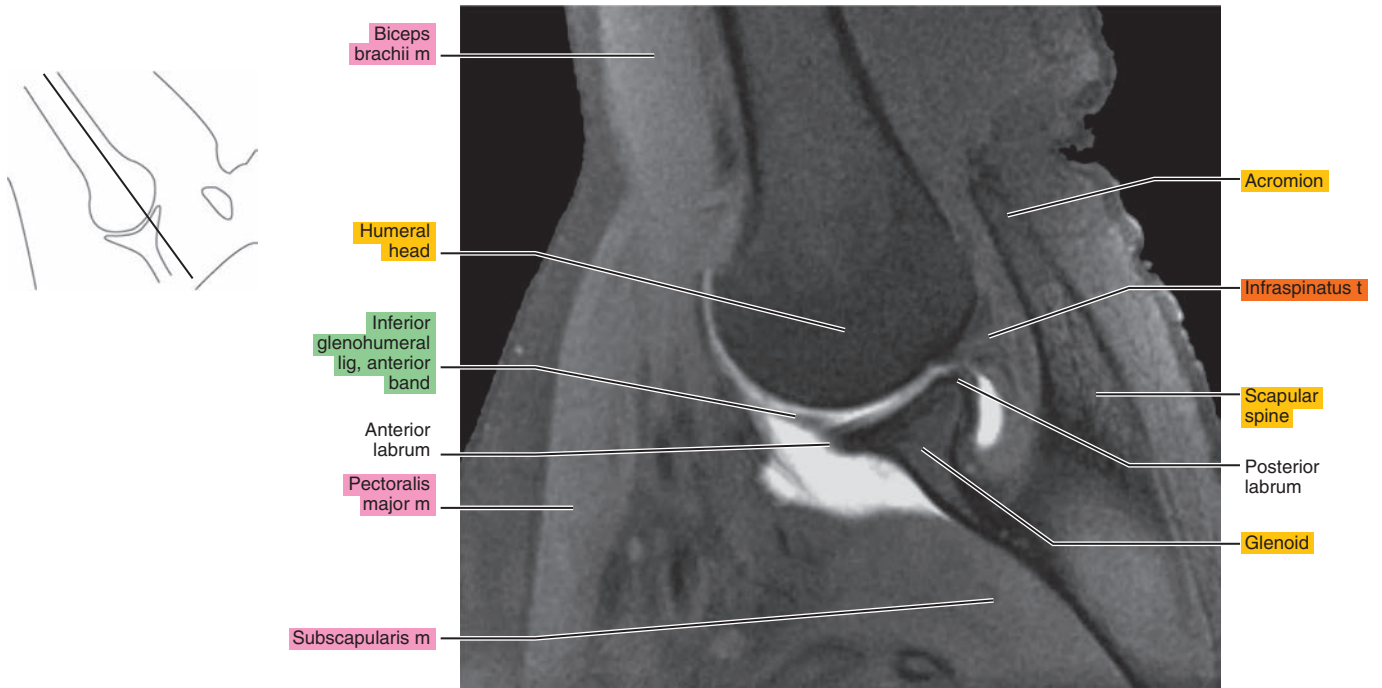


Figure 7.4.6

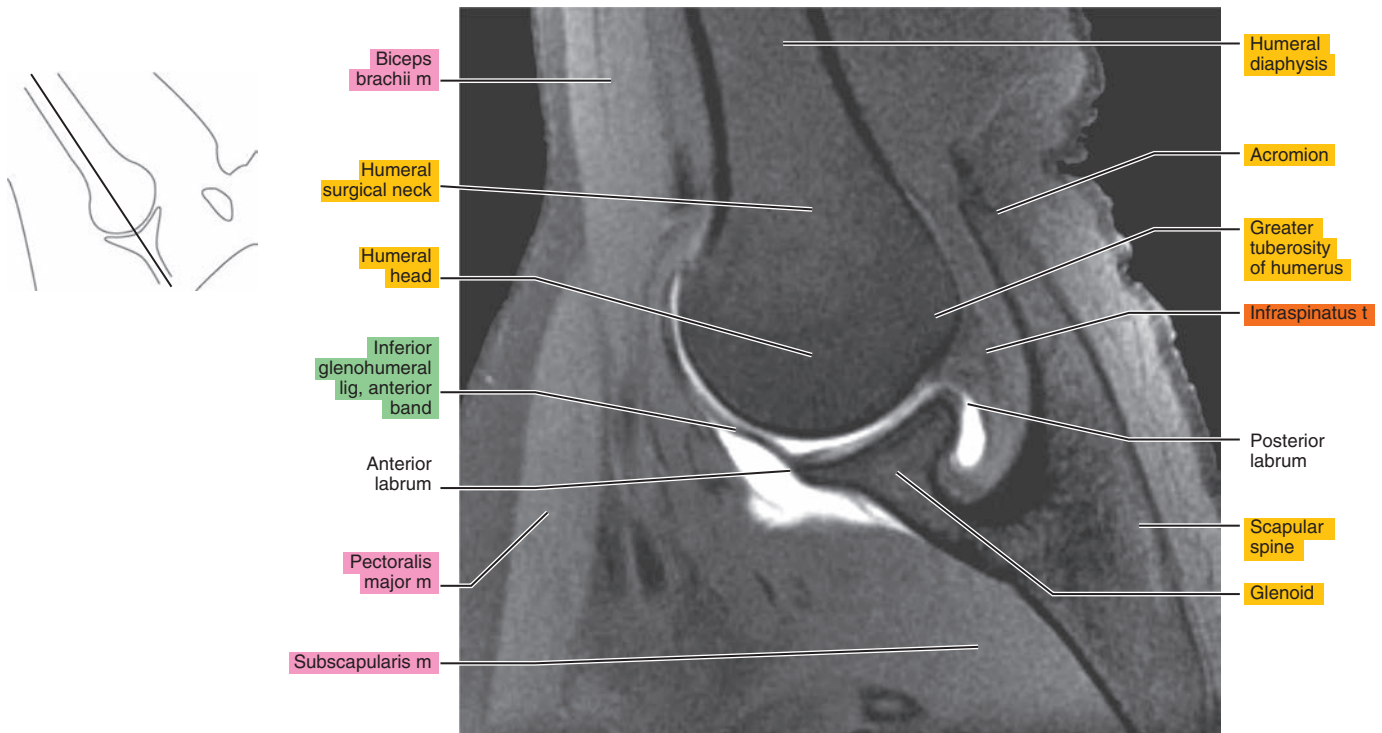




Figure 7.4.7

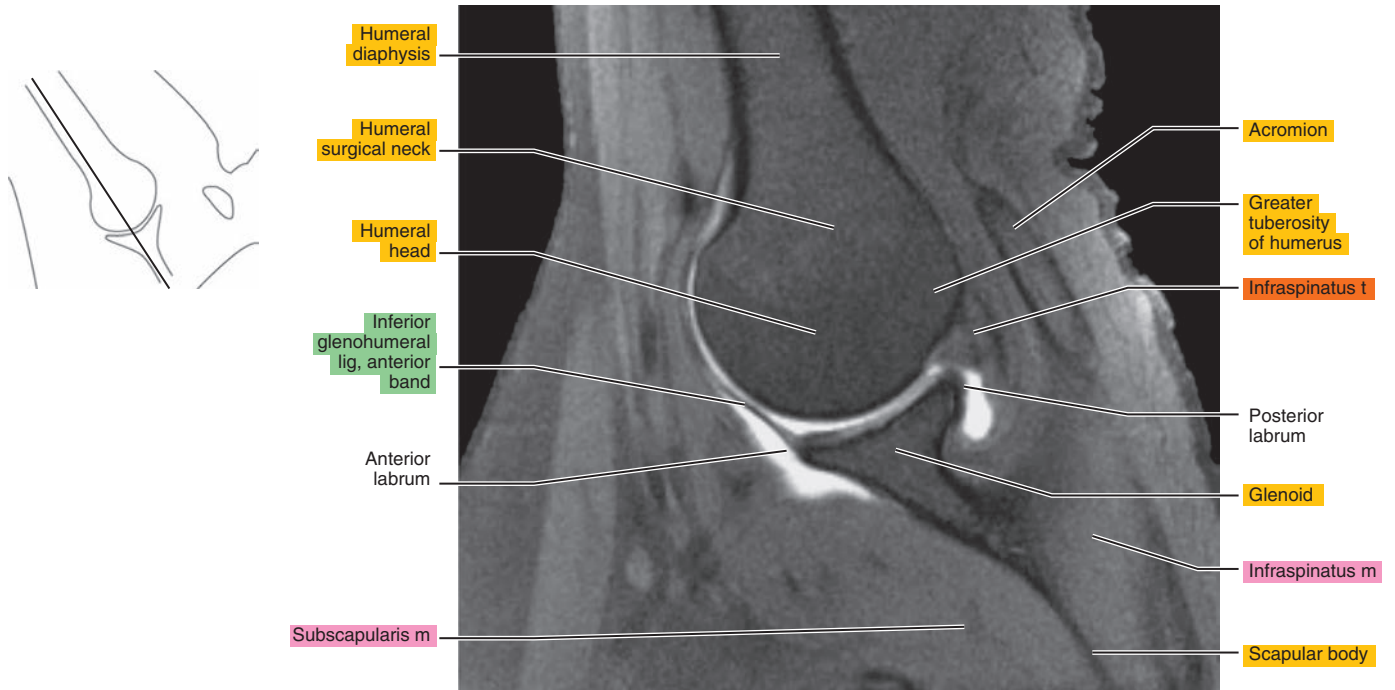


Figure 7.4.8

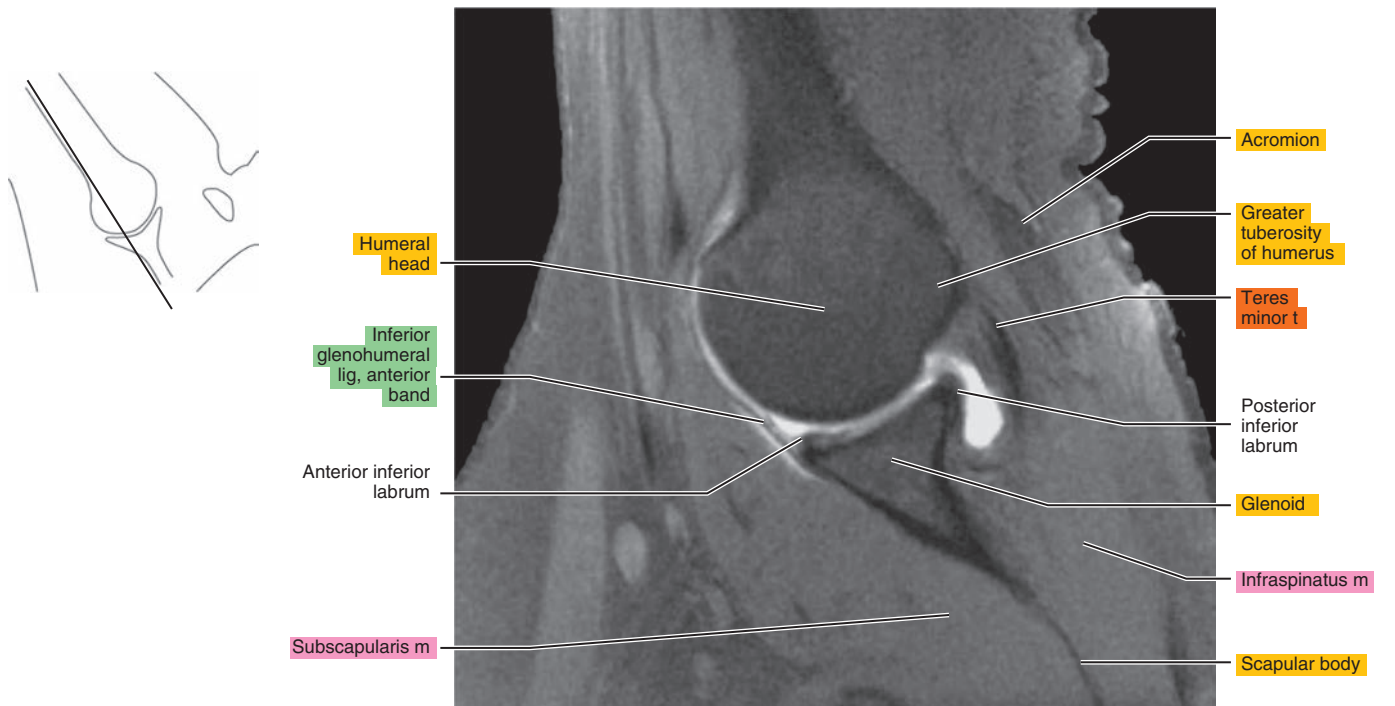


Figure 7.4.9

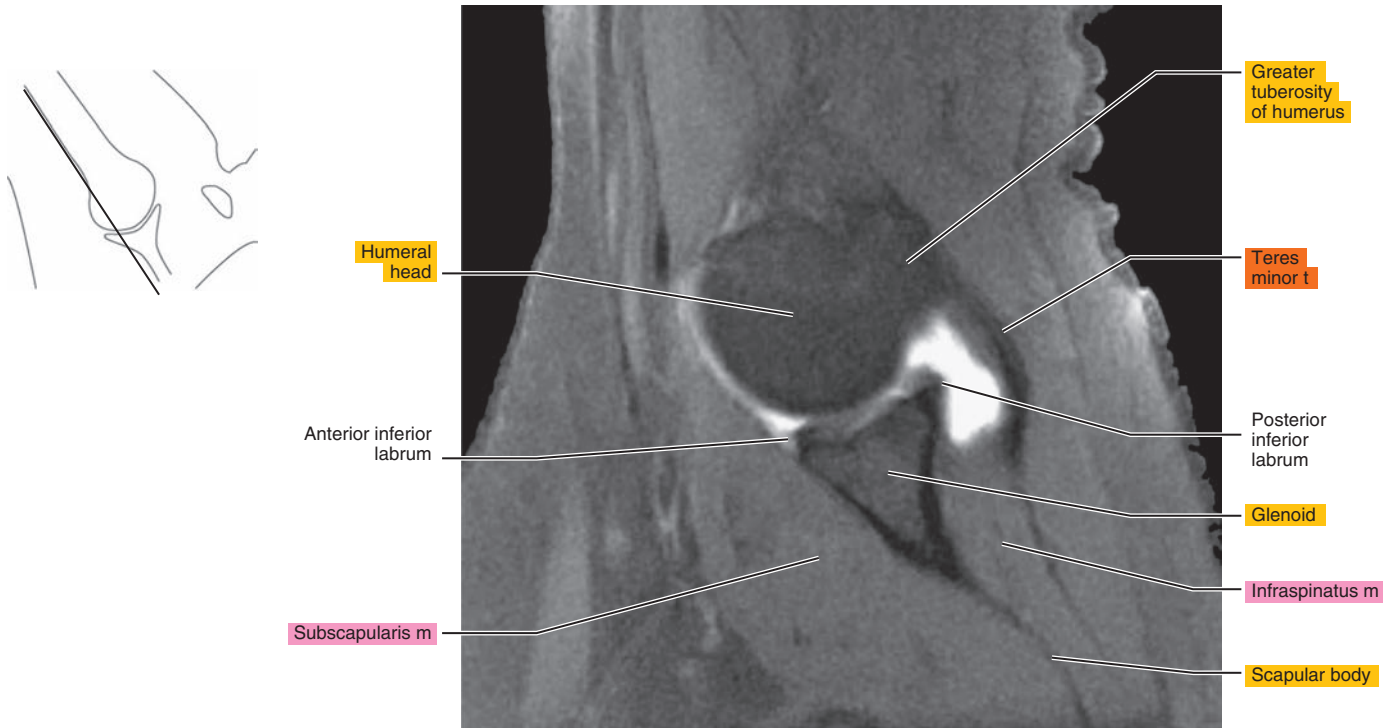


Figure 7.4.10

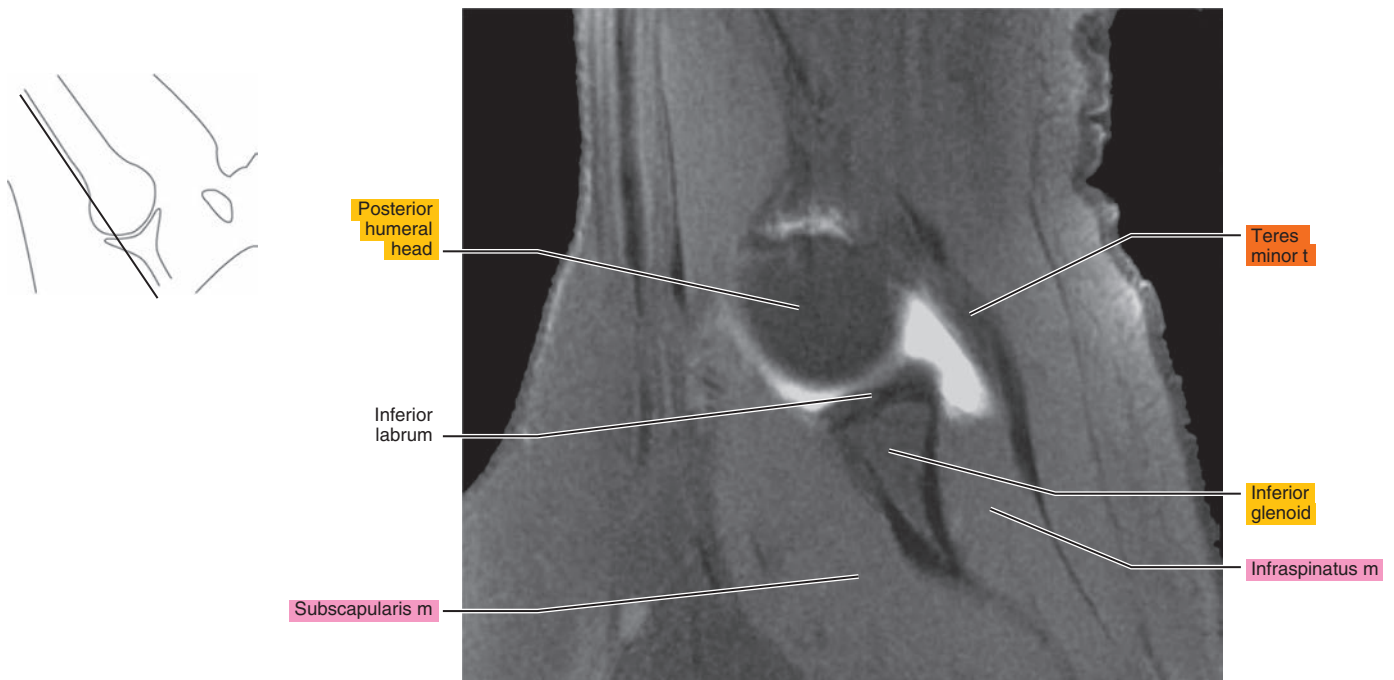
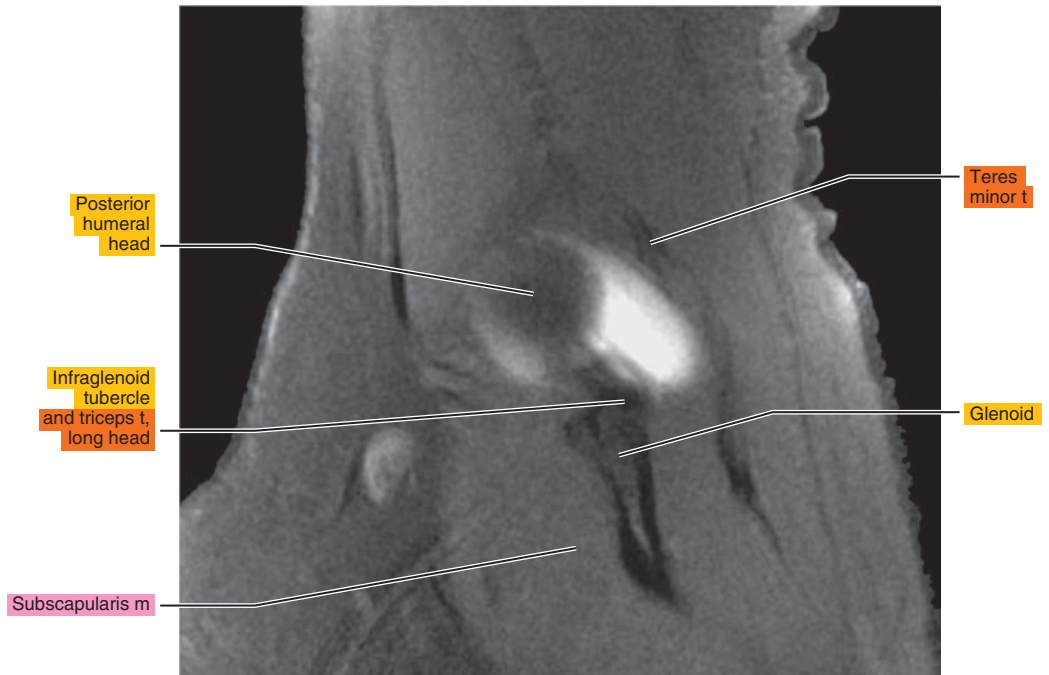
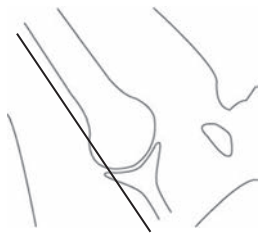


Figure 7.4.11



*Chapter*  
**8**

**MRI of the Arm**



# AXIAL

Figure 8.1.1

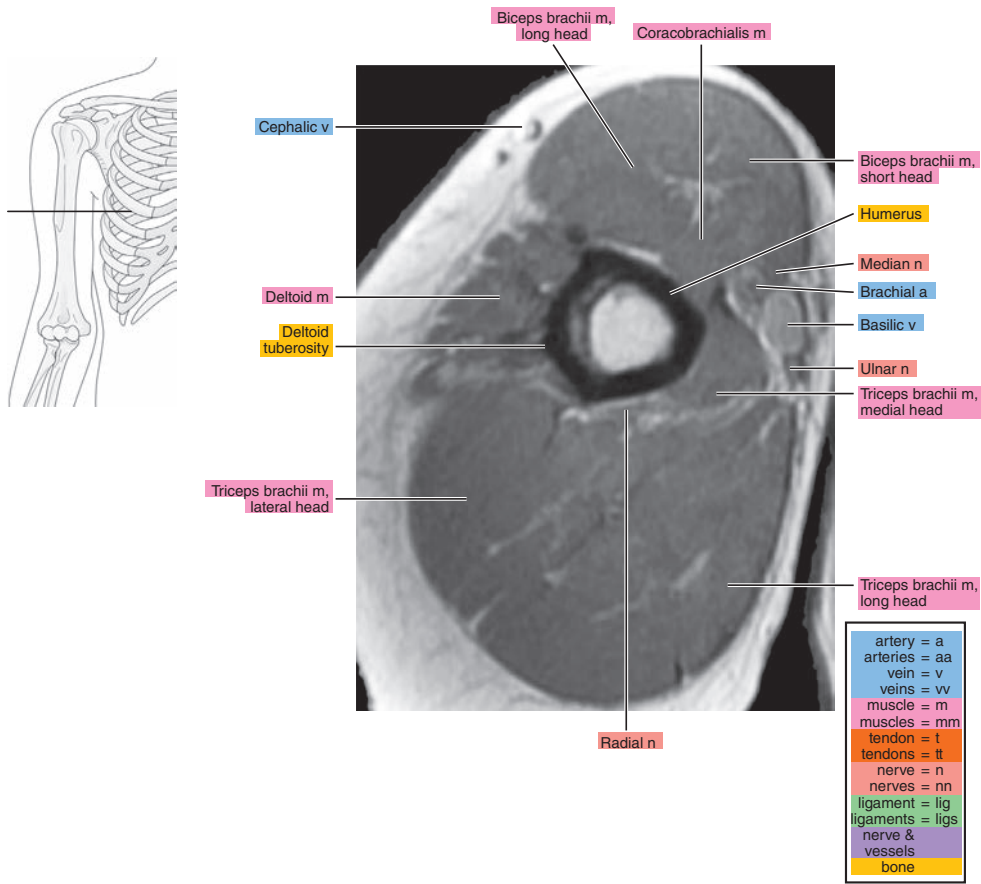


Figure 8.1.2

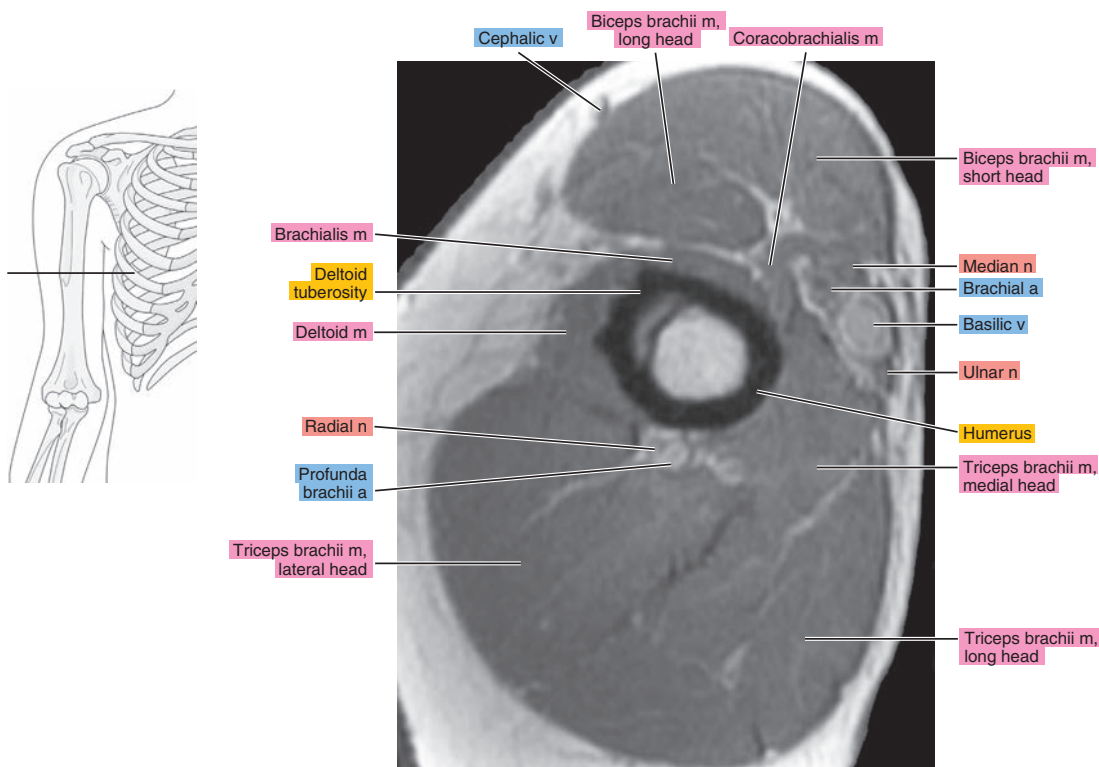


Figure 8.1.3

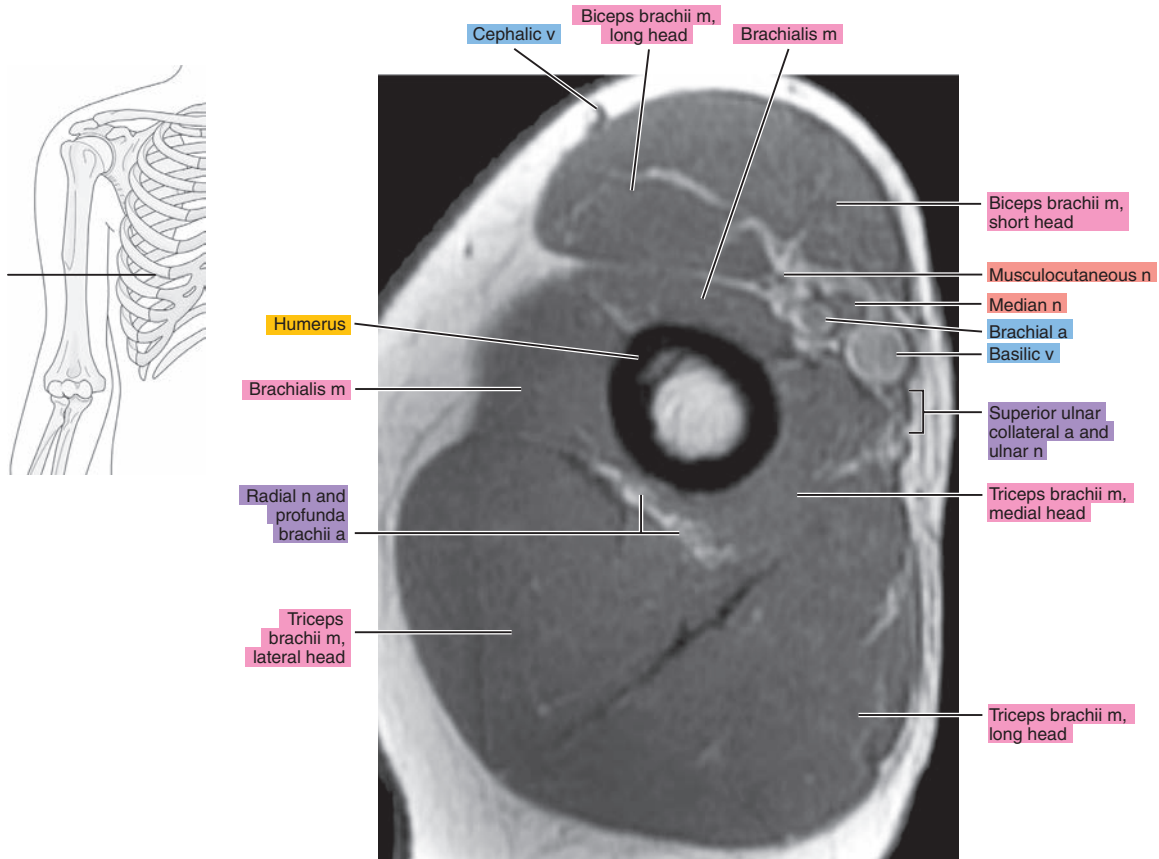


Figure 8.1.4

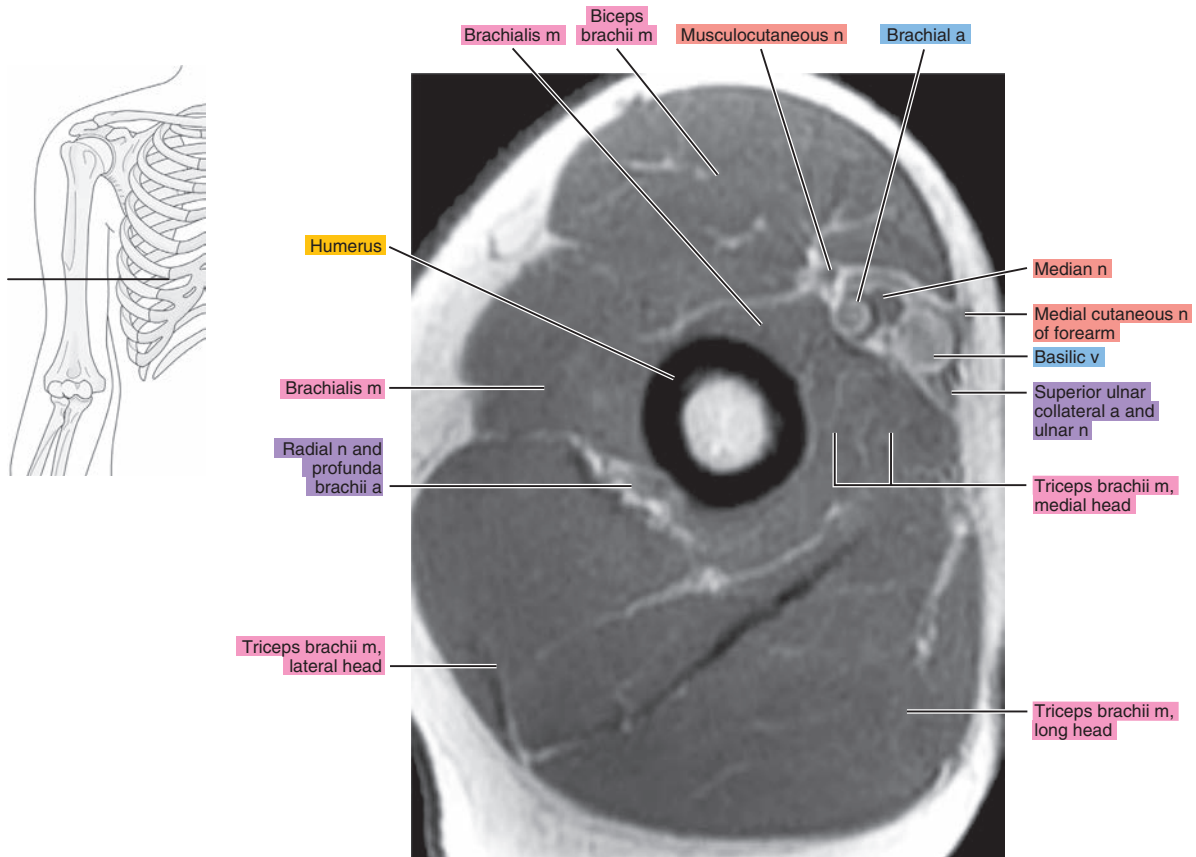


Figure 8.1.5

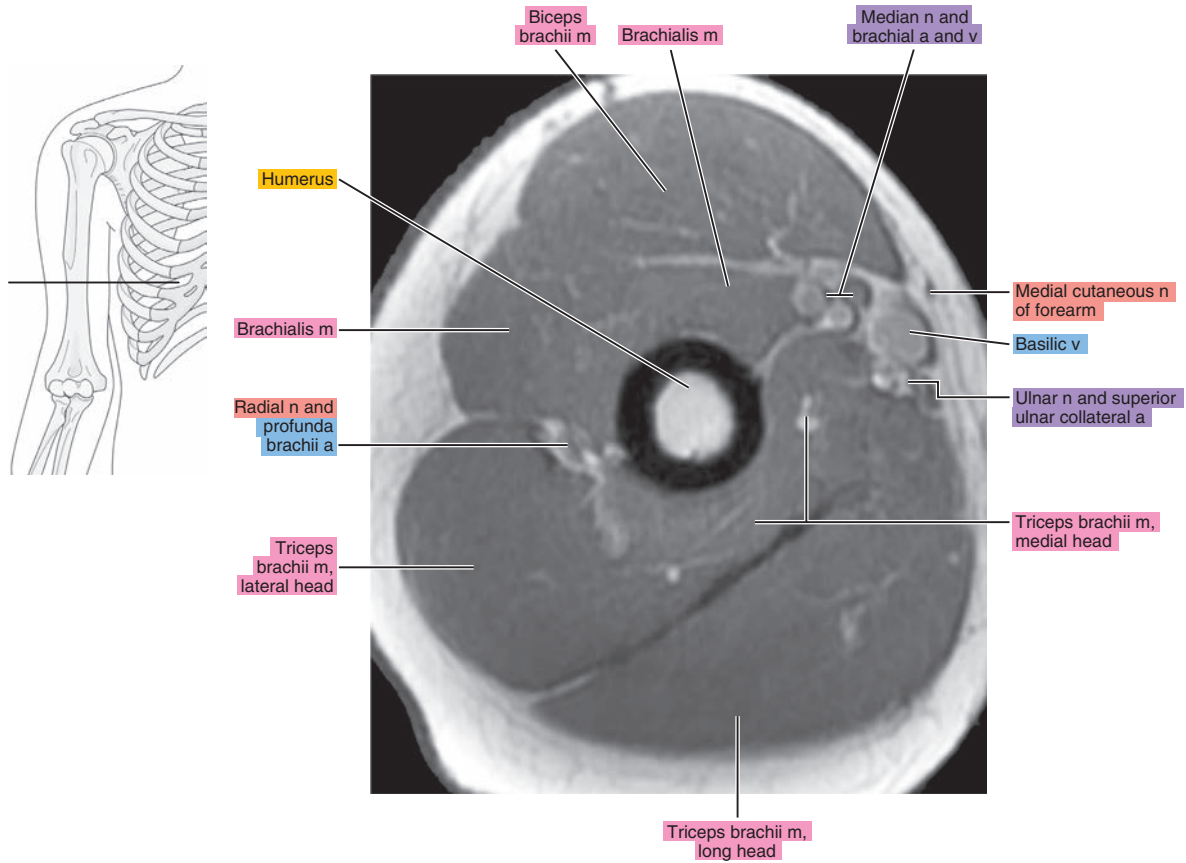


Figure 8.1.6

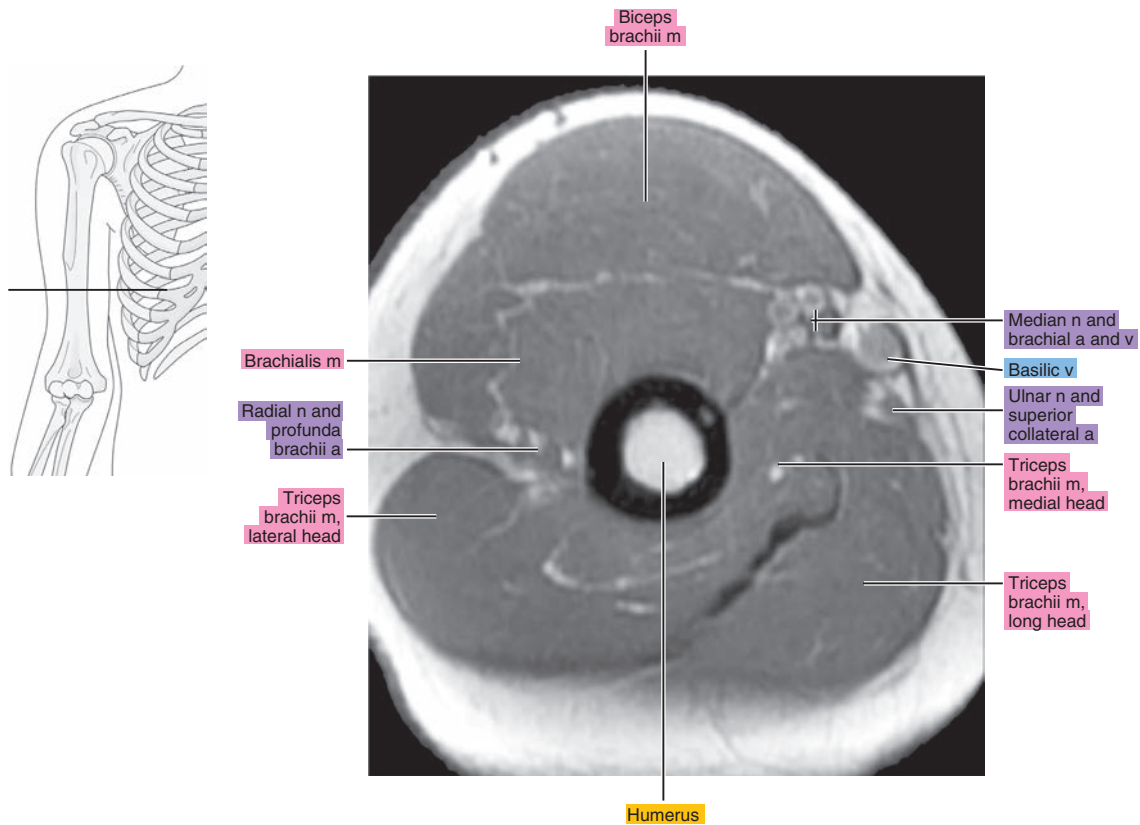


Figure 8.1.7

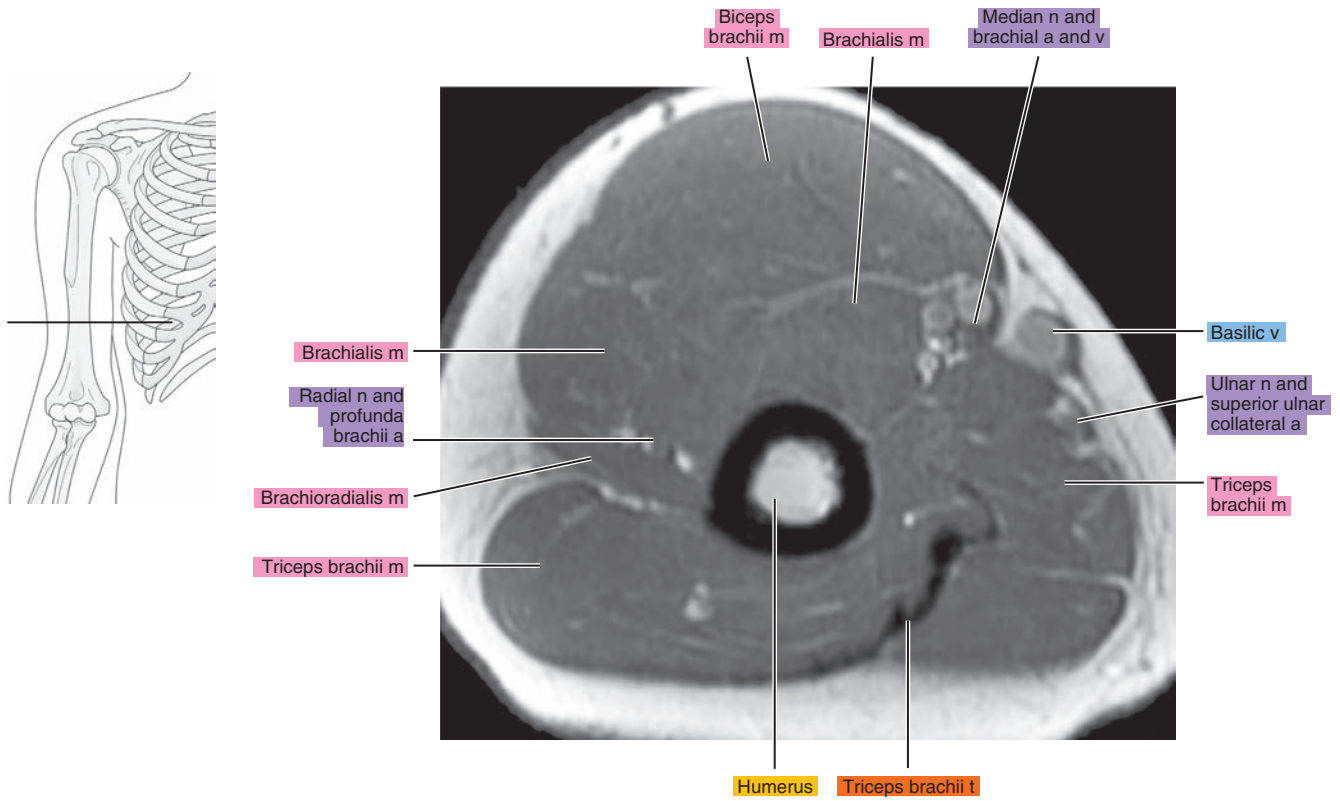


Figure 8.1.8

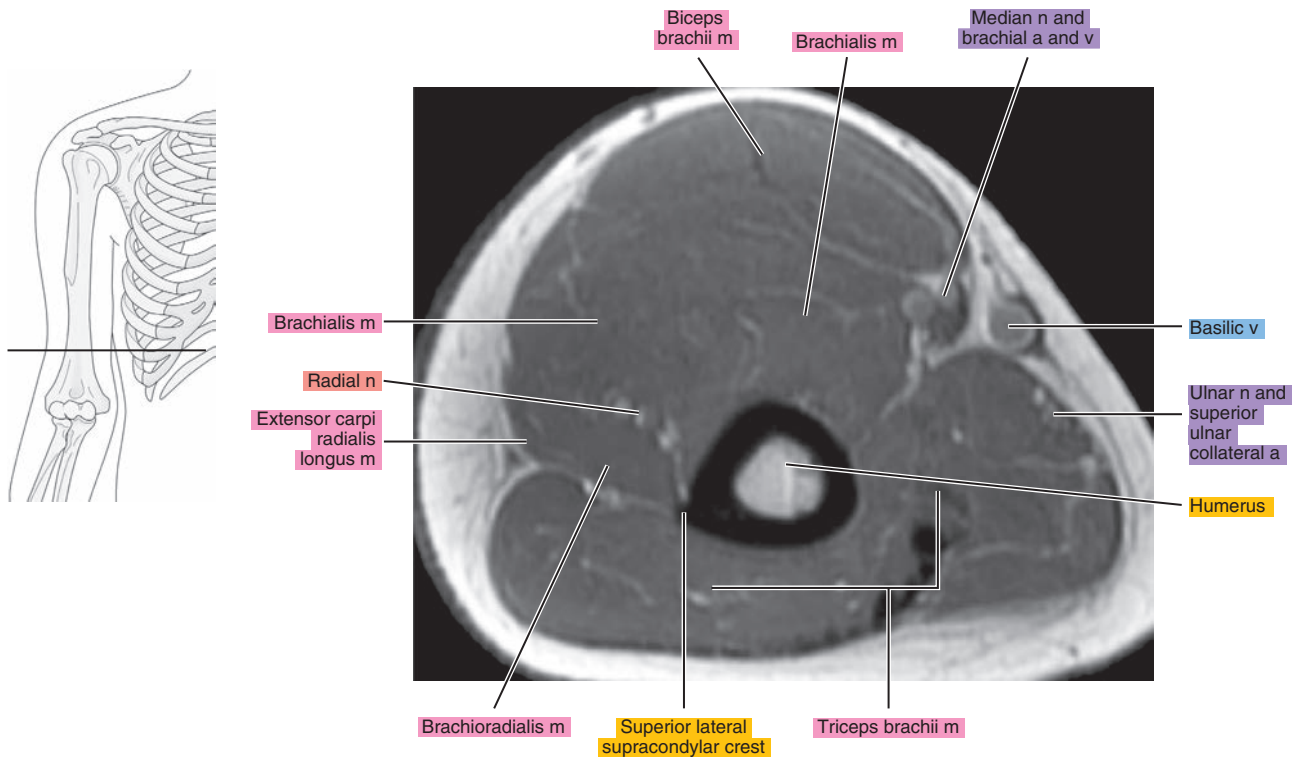




Figure 8.1.9

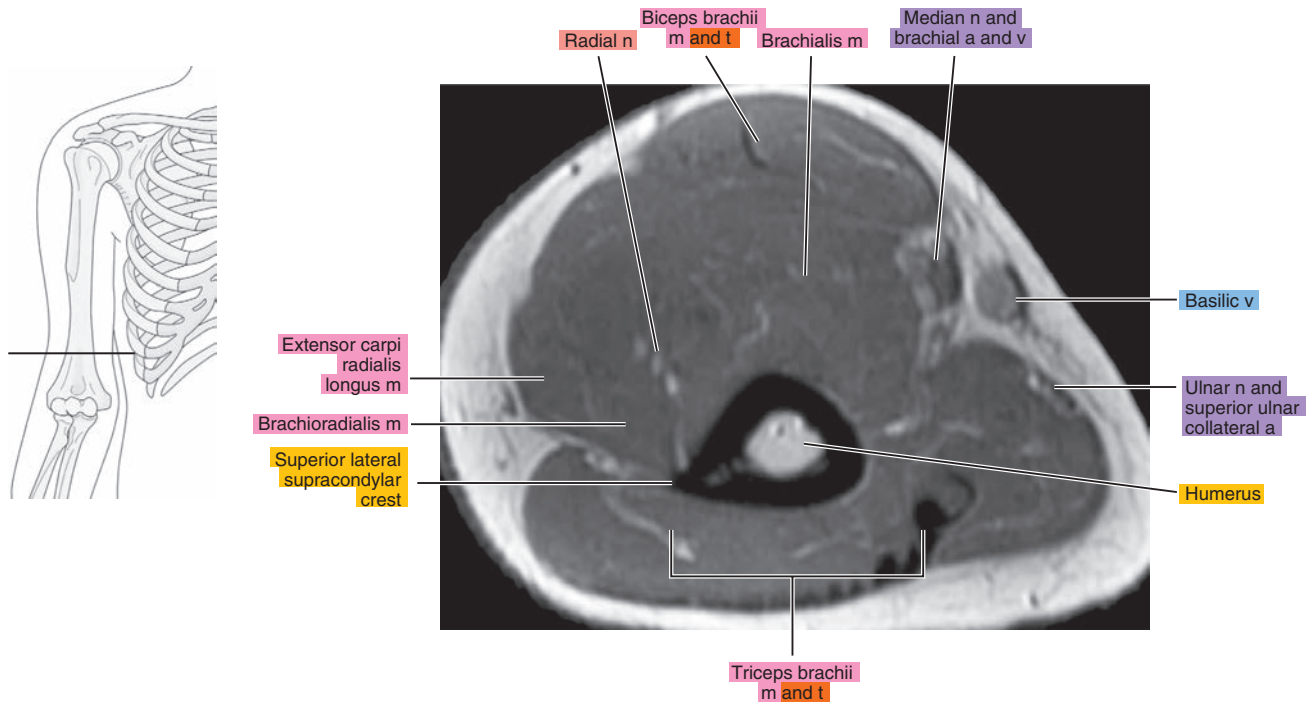


Figure 8.1.10

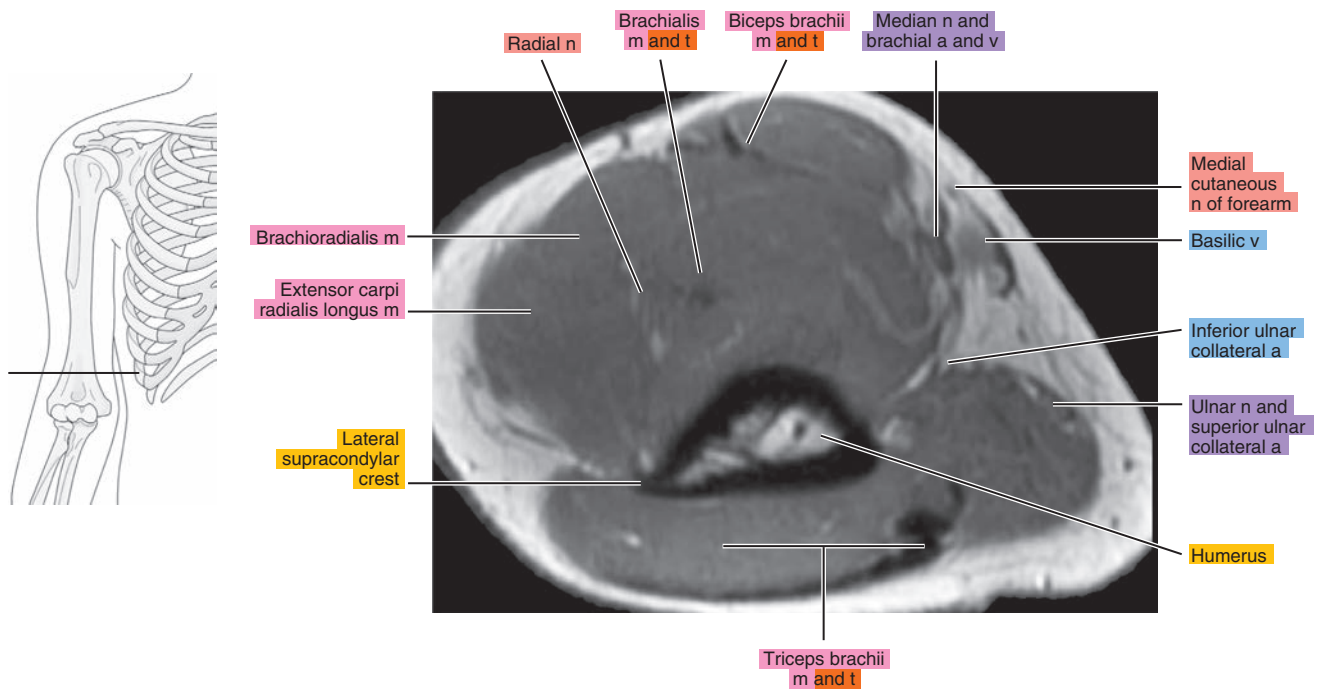
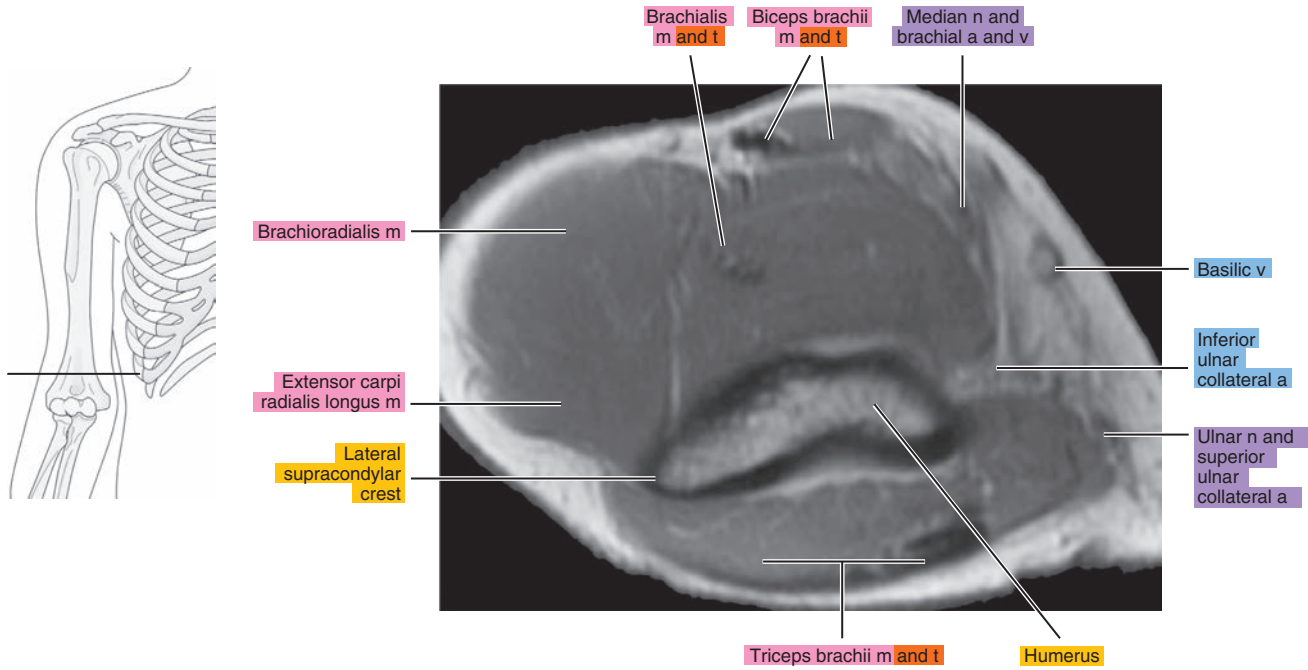


Figure 8.1.11



# SAGITTAL

Figure 8.2.1

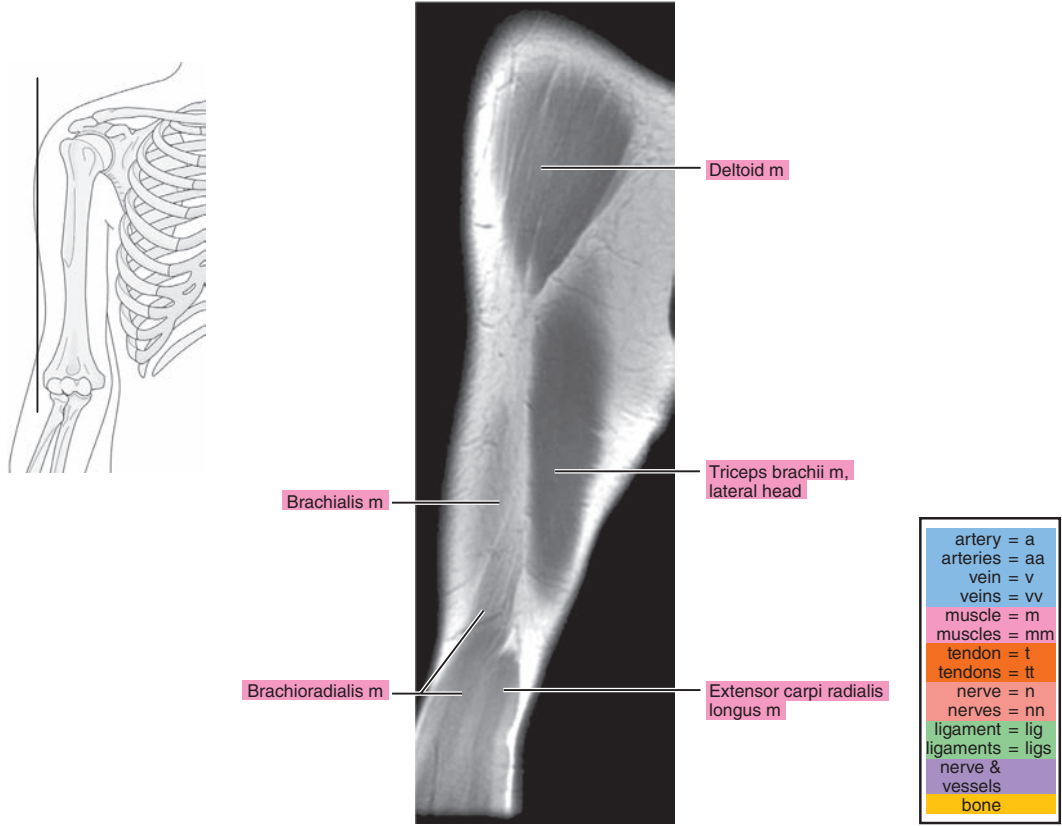


Figure 8.2.2

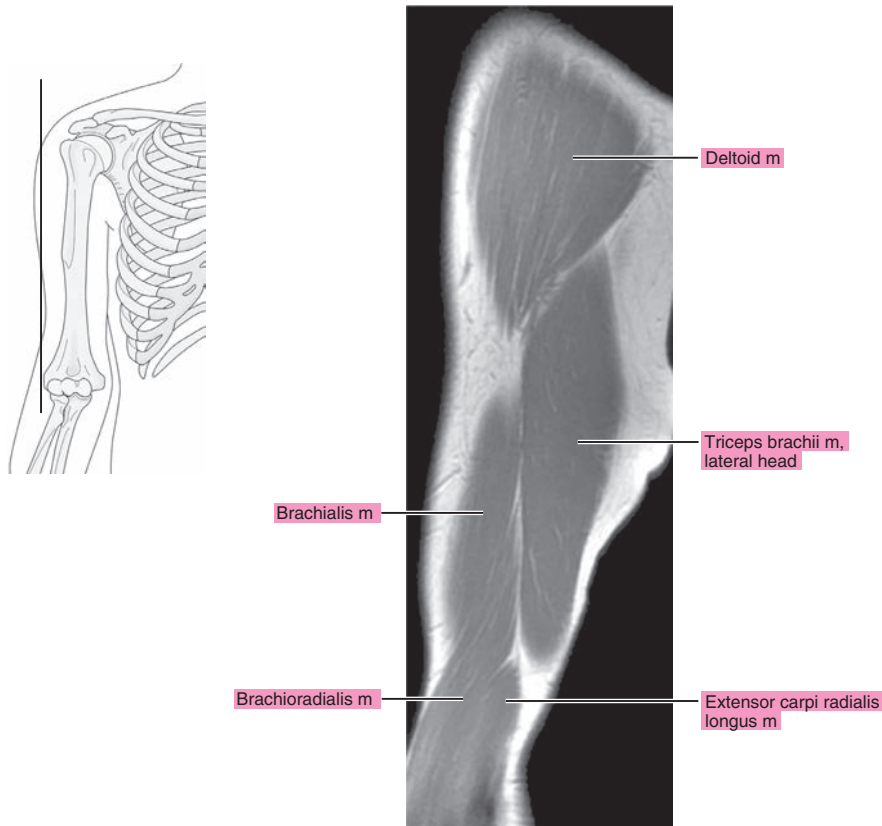


Figure 8.2.3

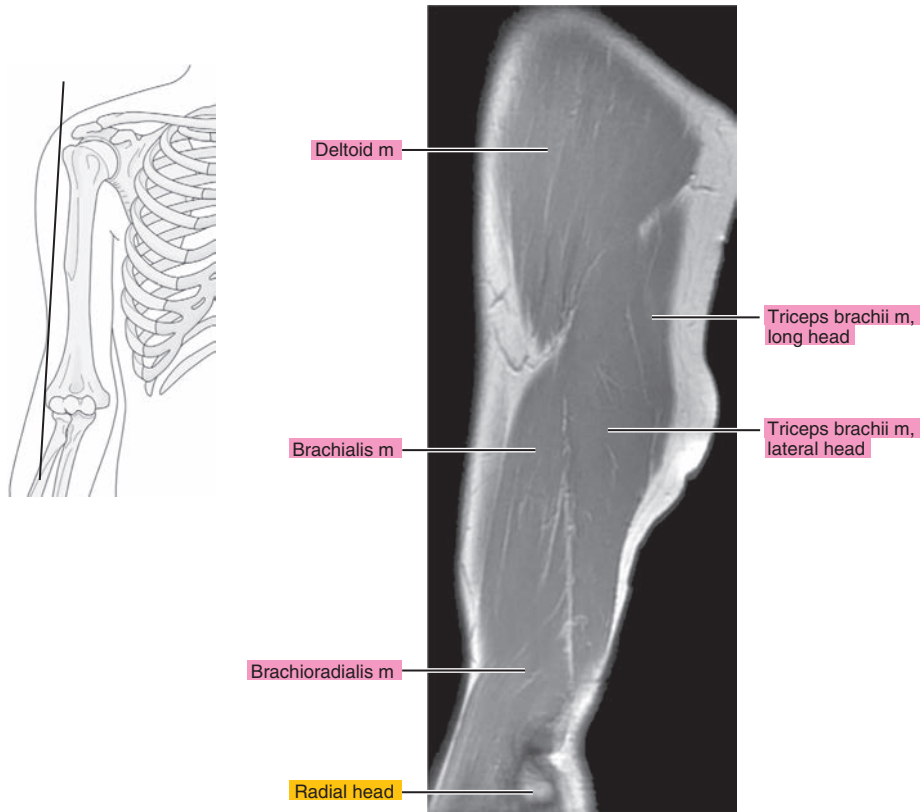


Figure 8.2.4

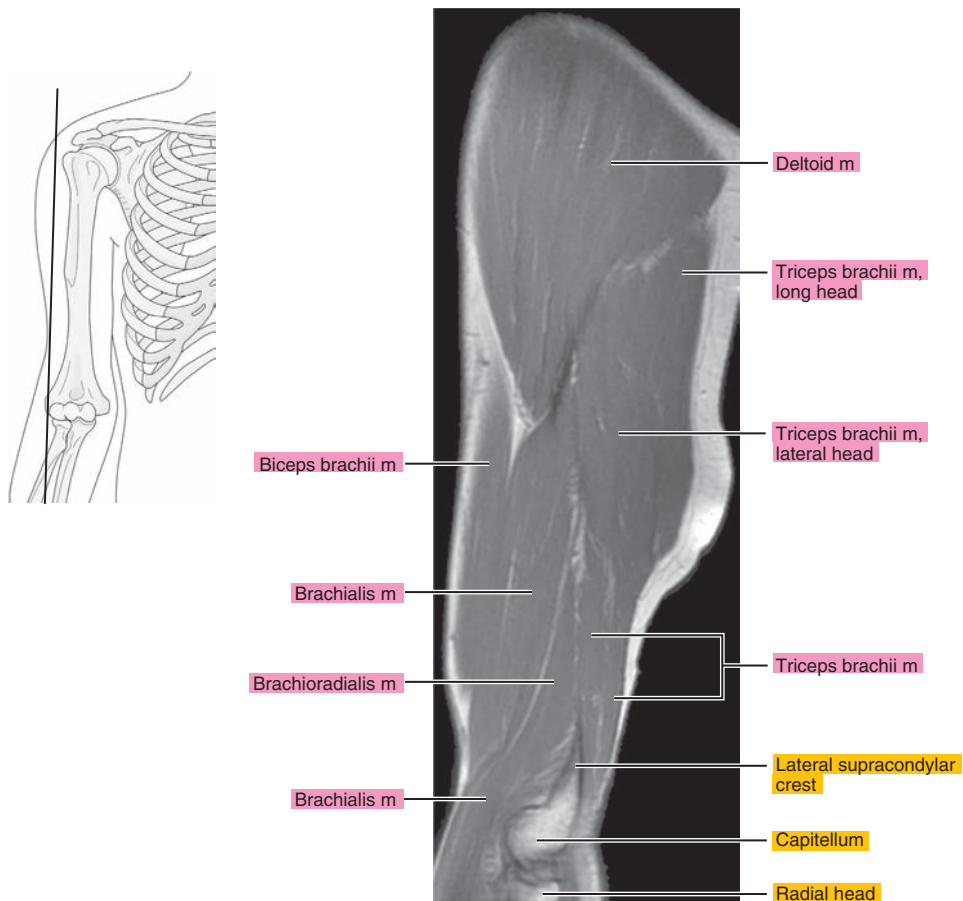




Figure 8.2.5

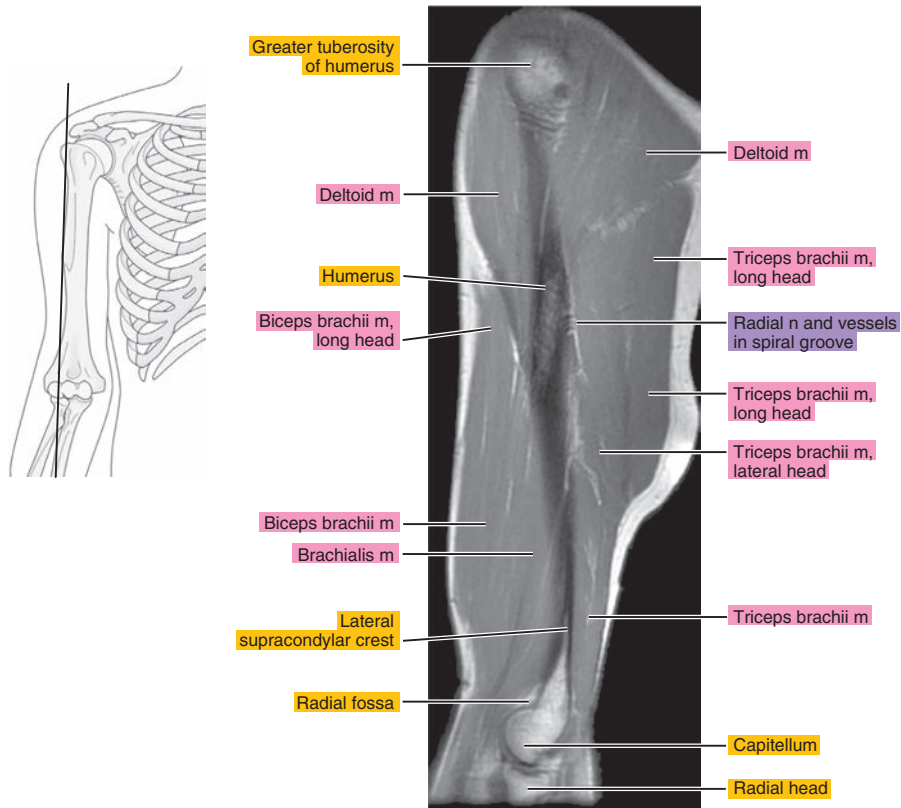


Figure 8.2.6

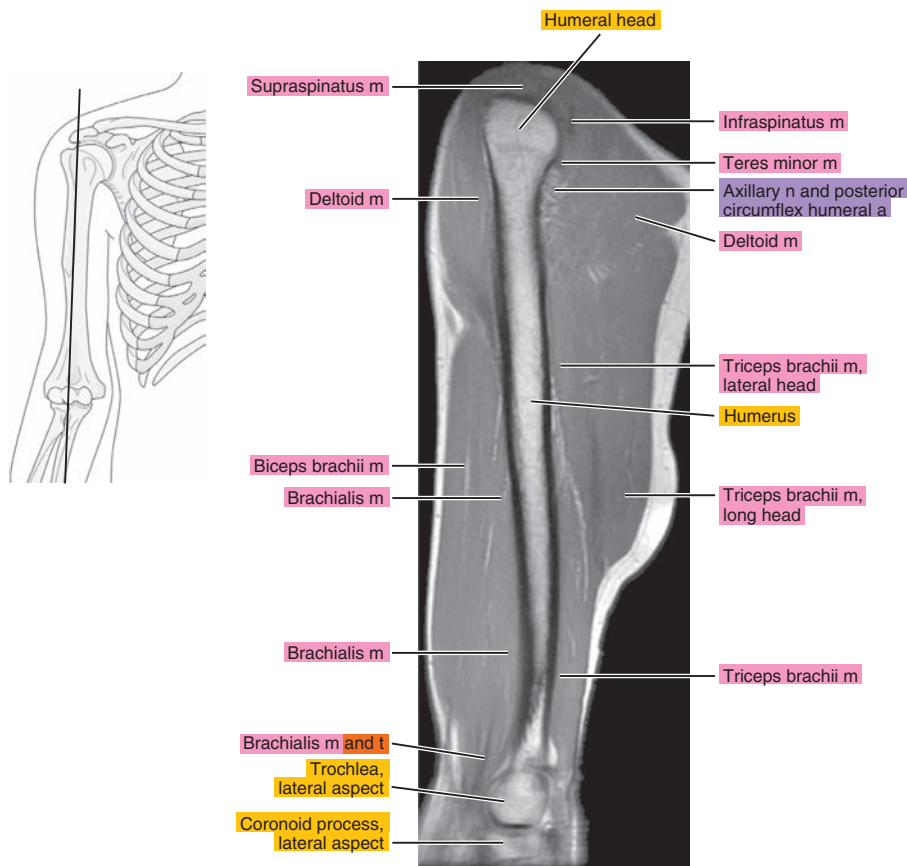


Figure 8.2.7

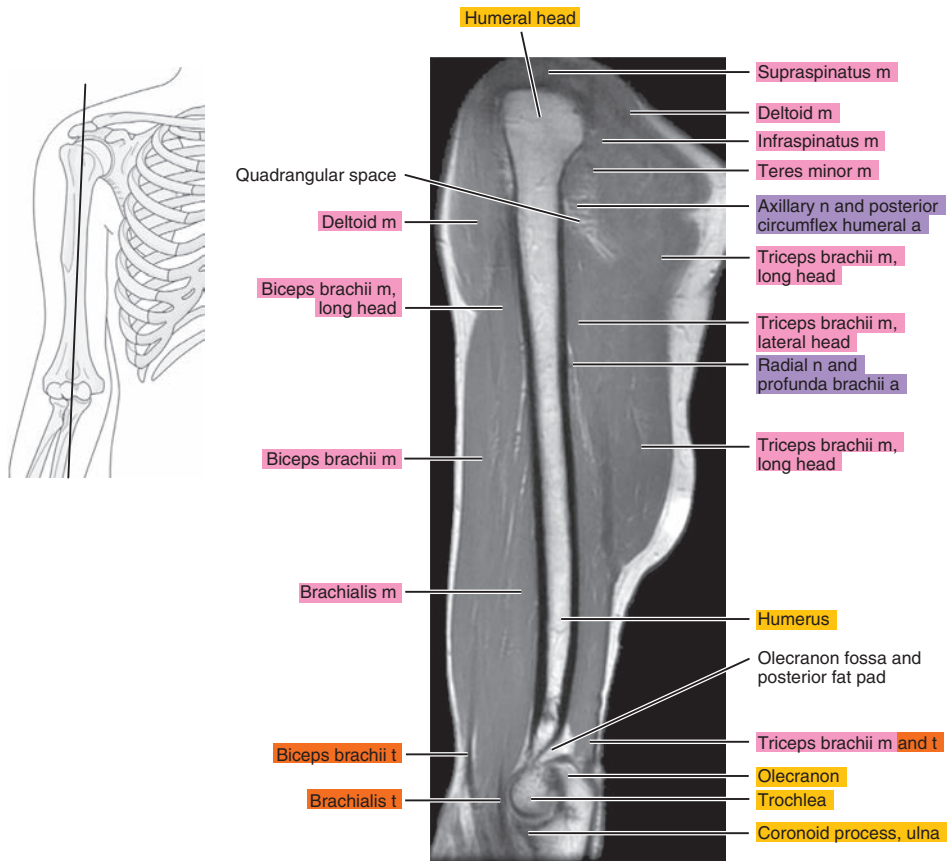


Figure 8.2.8

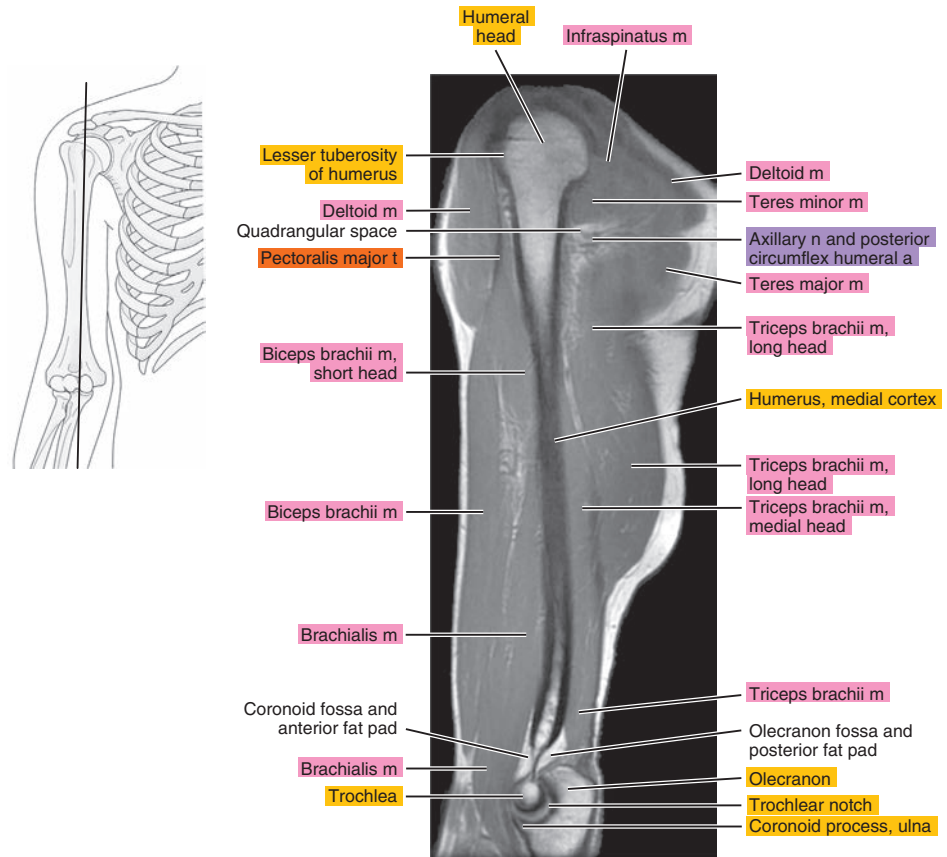


Figure 8.2.9

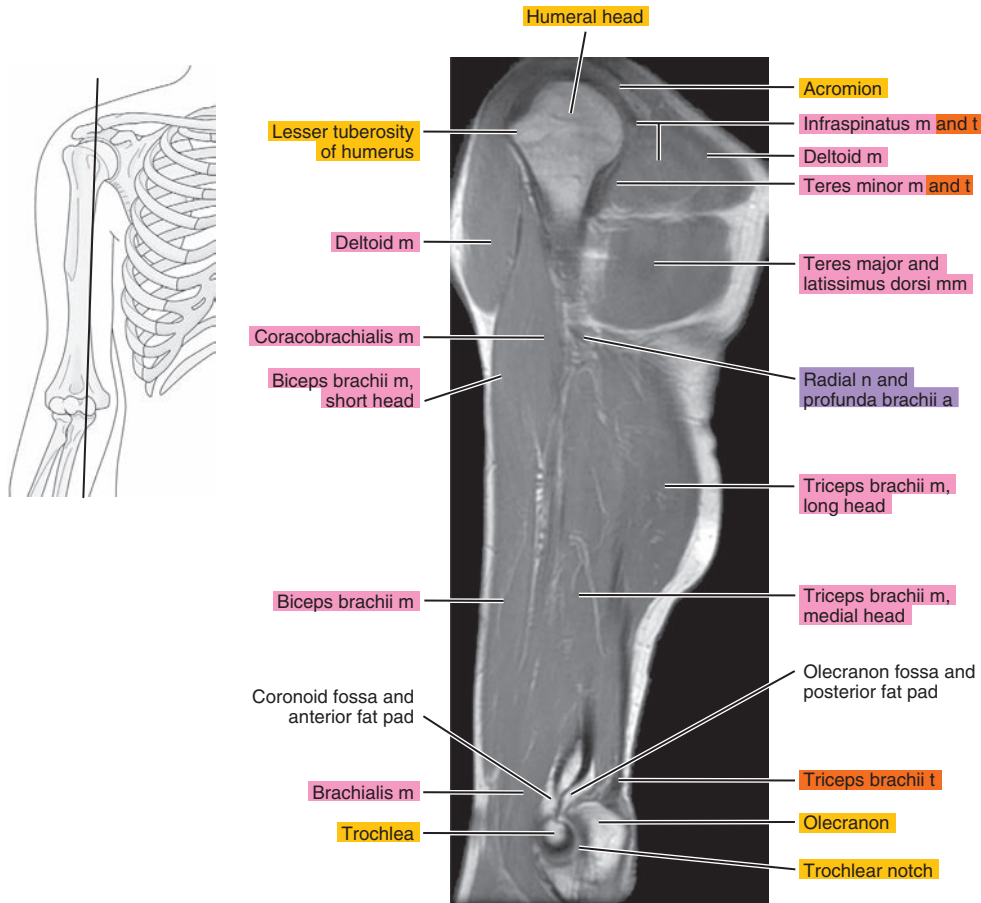


Figure 8.2.10

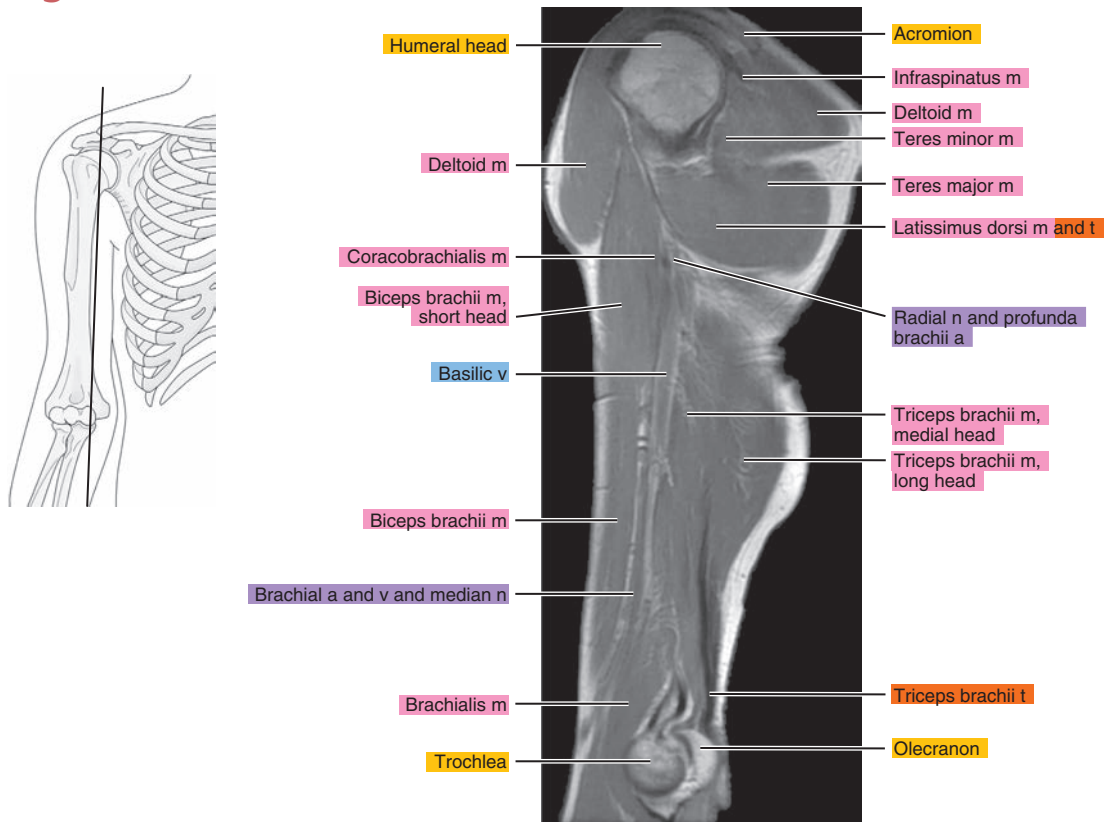


Figure 8.2.11

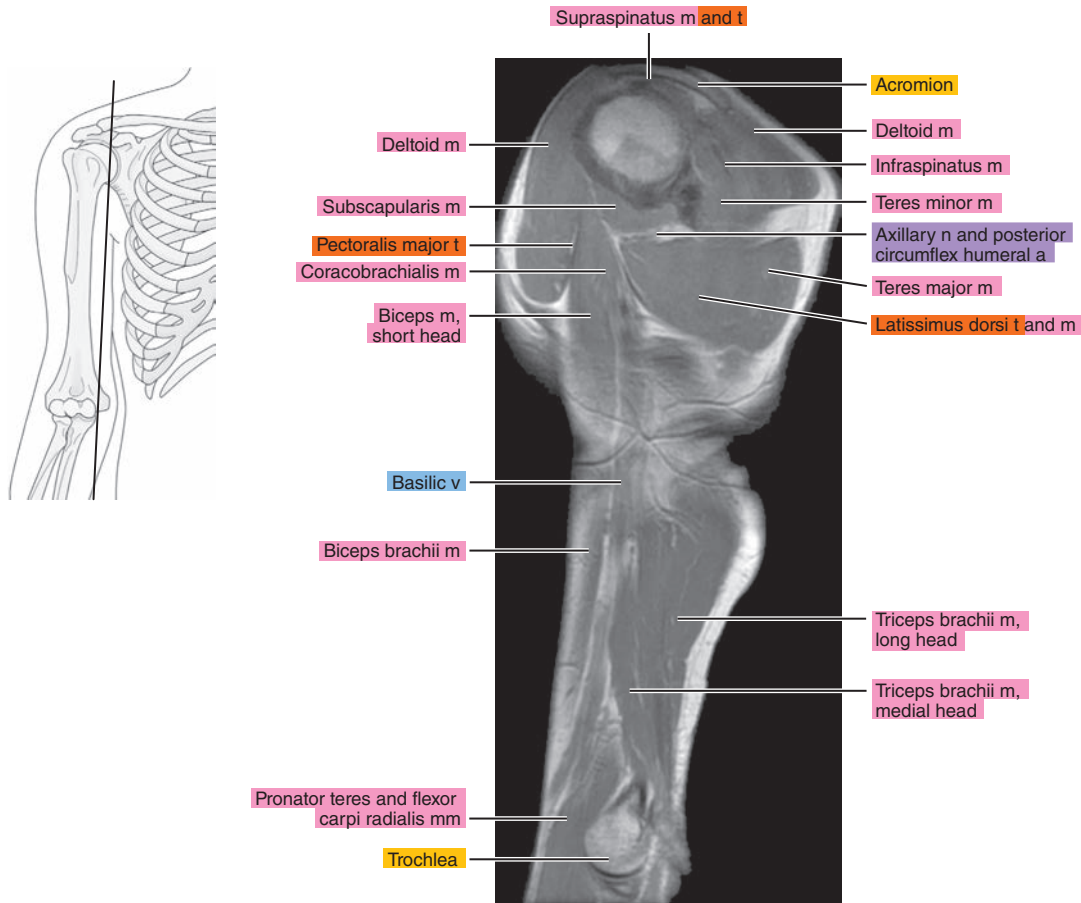


Figure 8.2.12

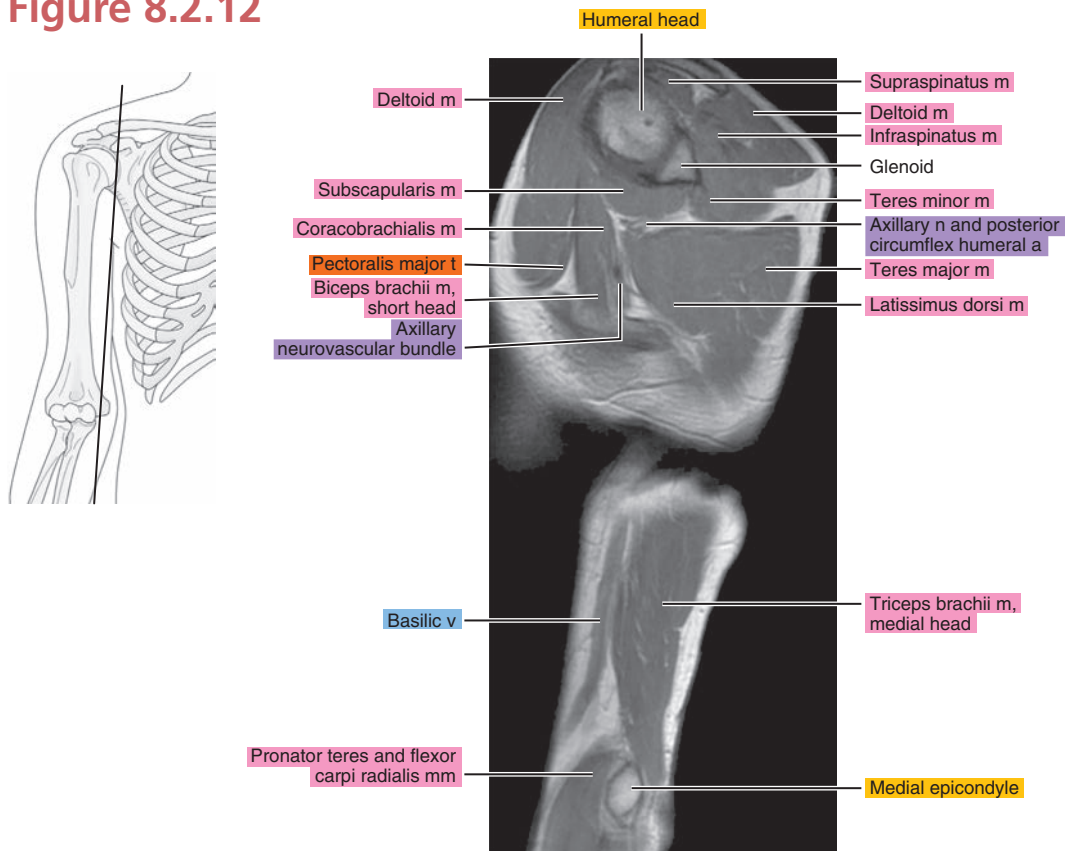
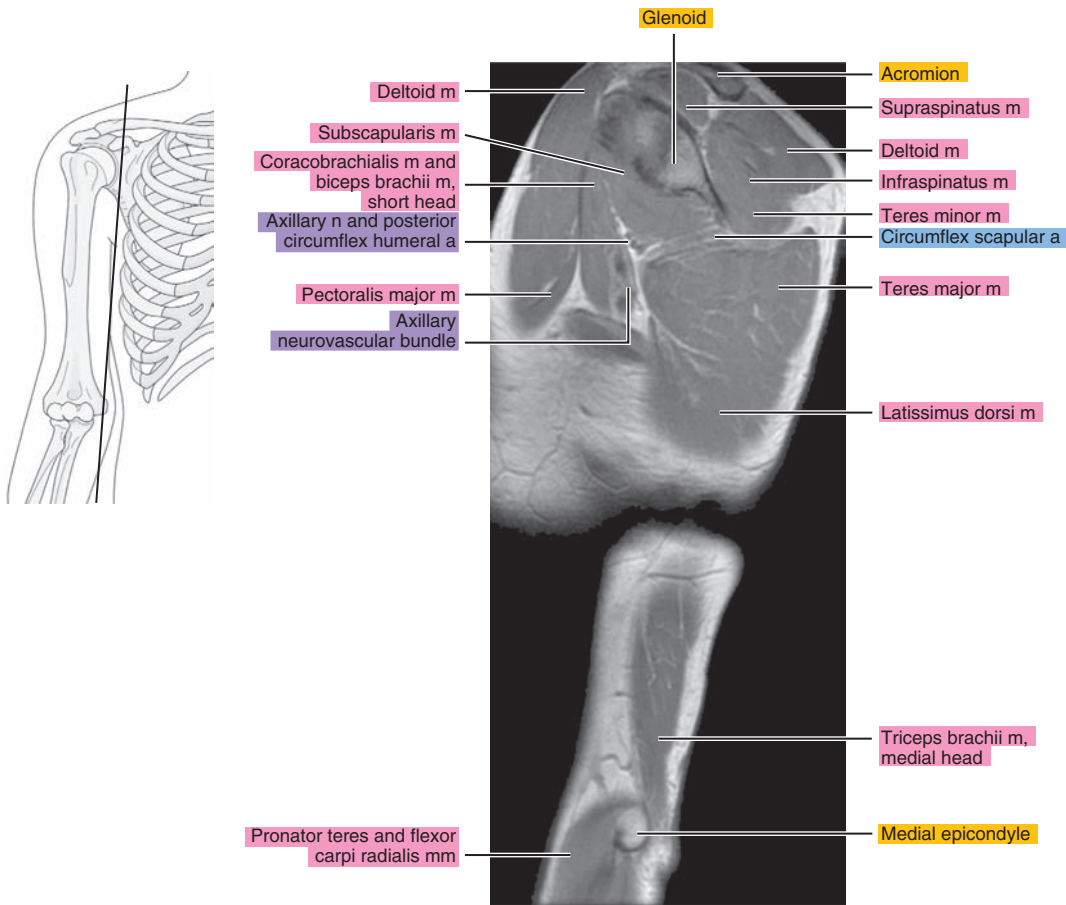




Figure 8.2.13



# CORONAL

Figure 8.3.1

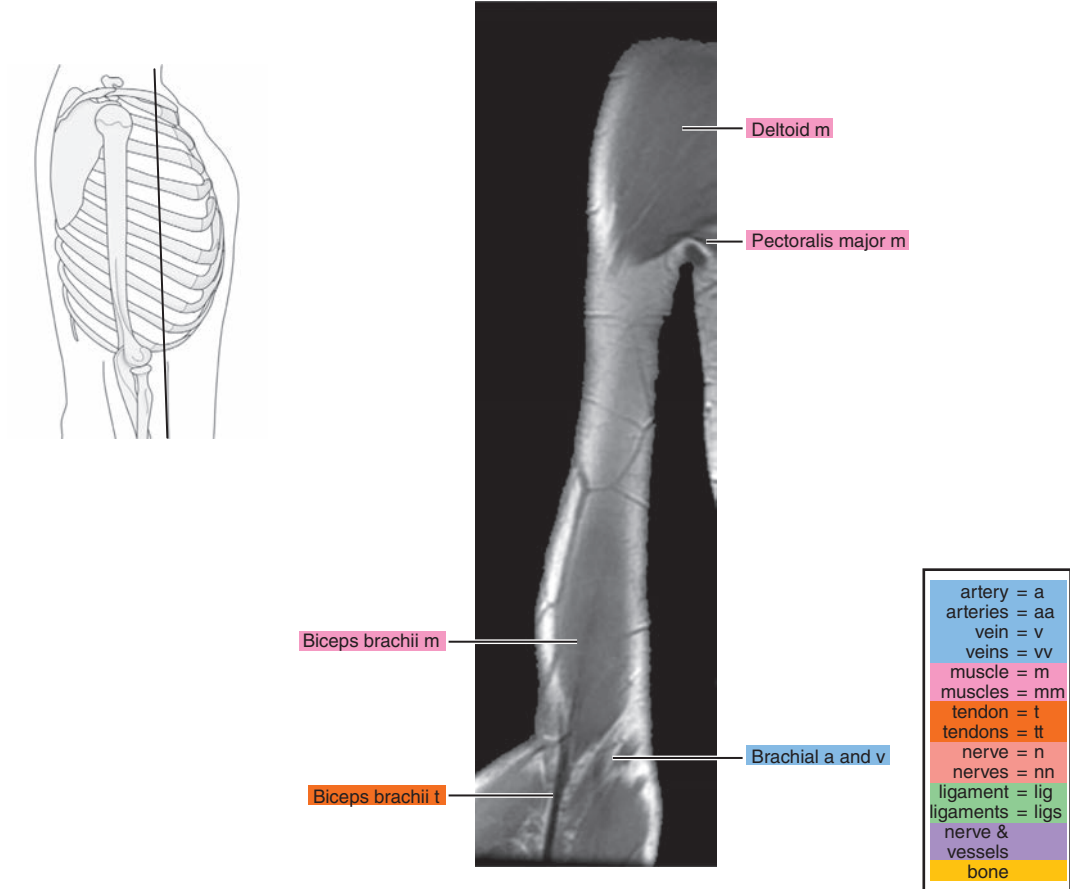


Figure 8.3.2

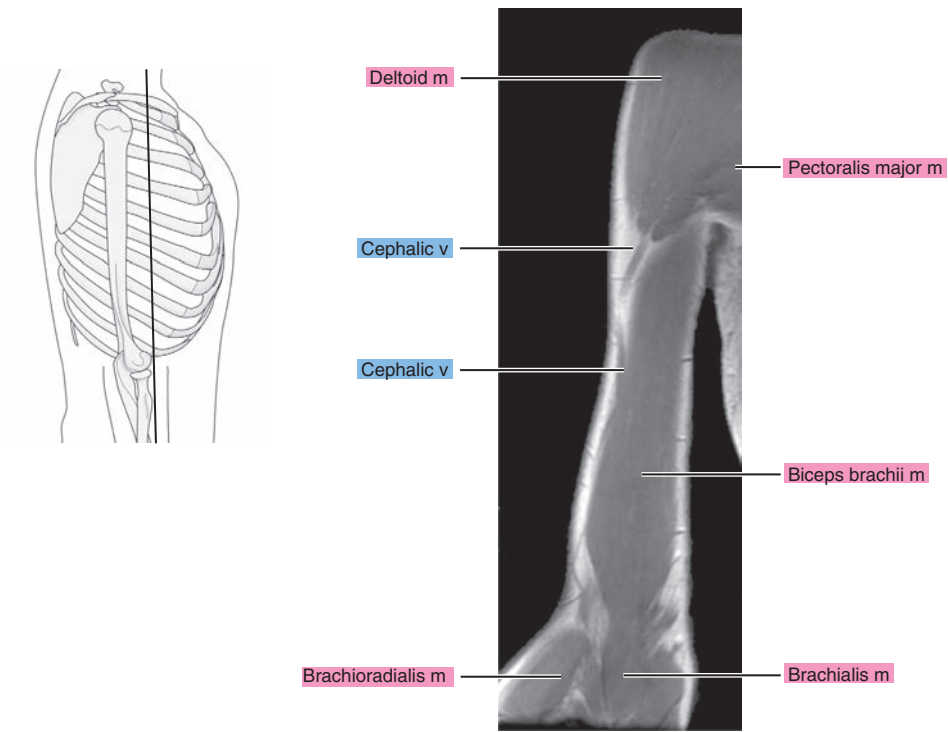


Figure 8.3.3

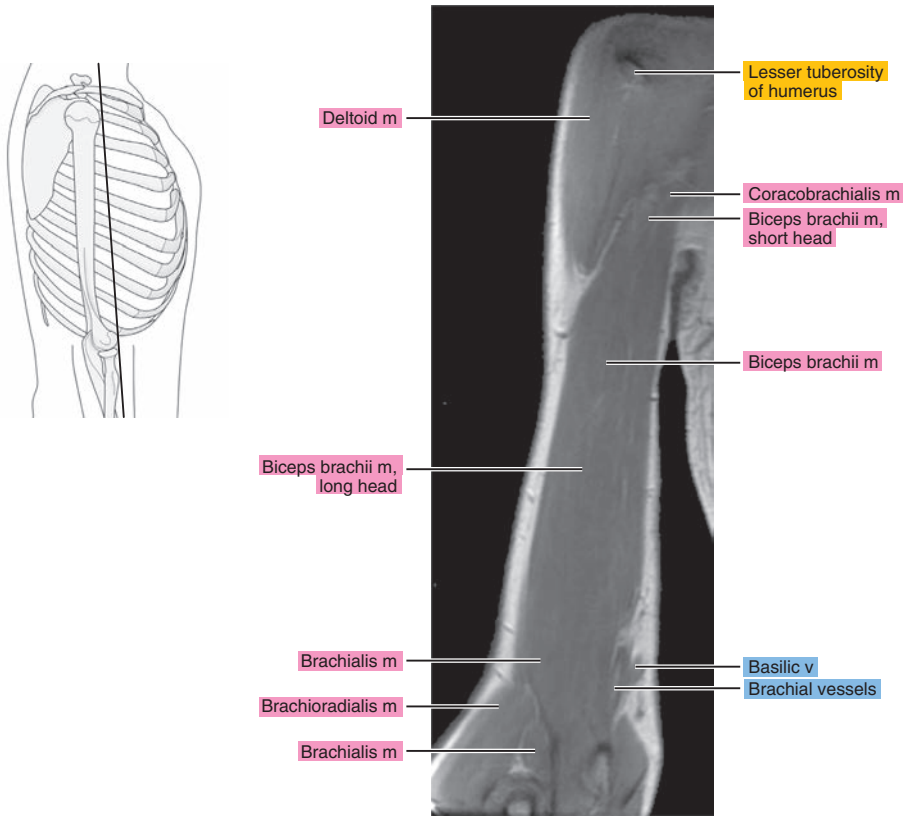


Figure 8.3.4

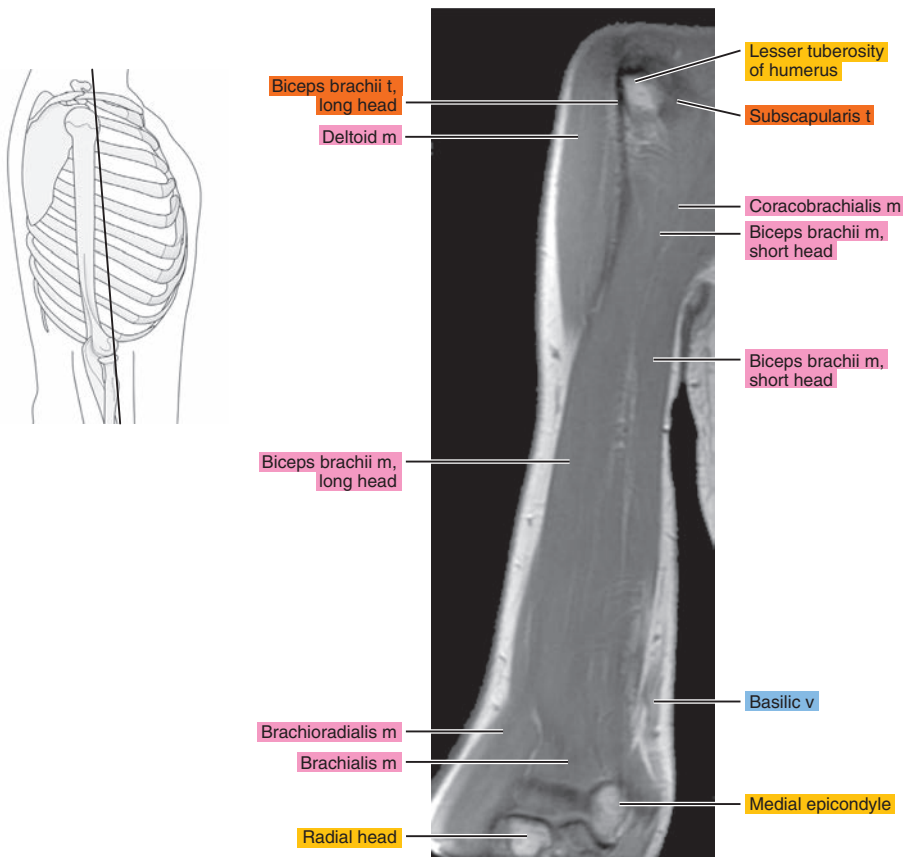


Figure 8.3.5

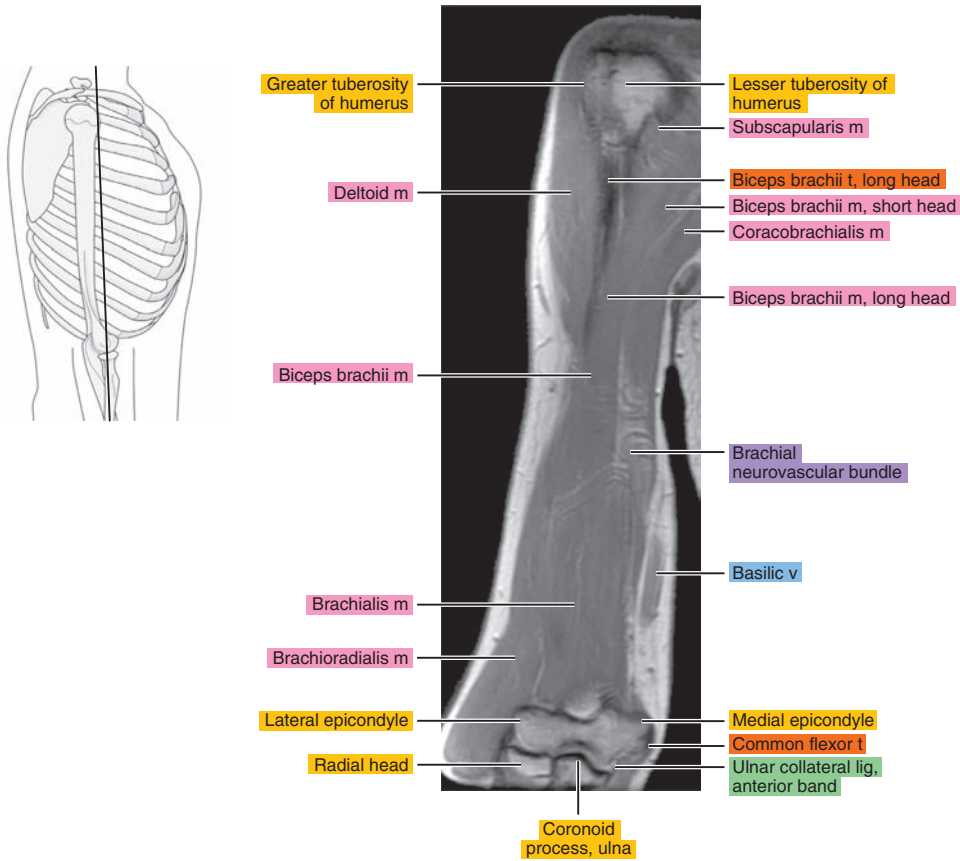


Figure 8.3.6

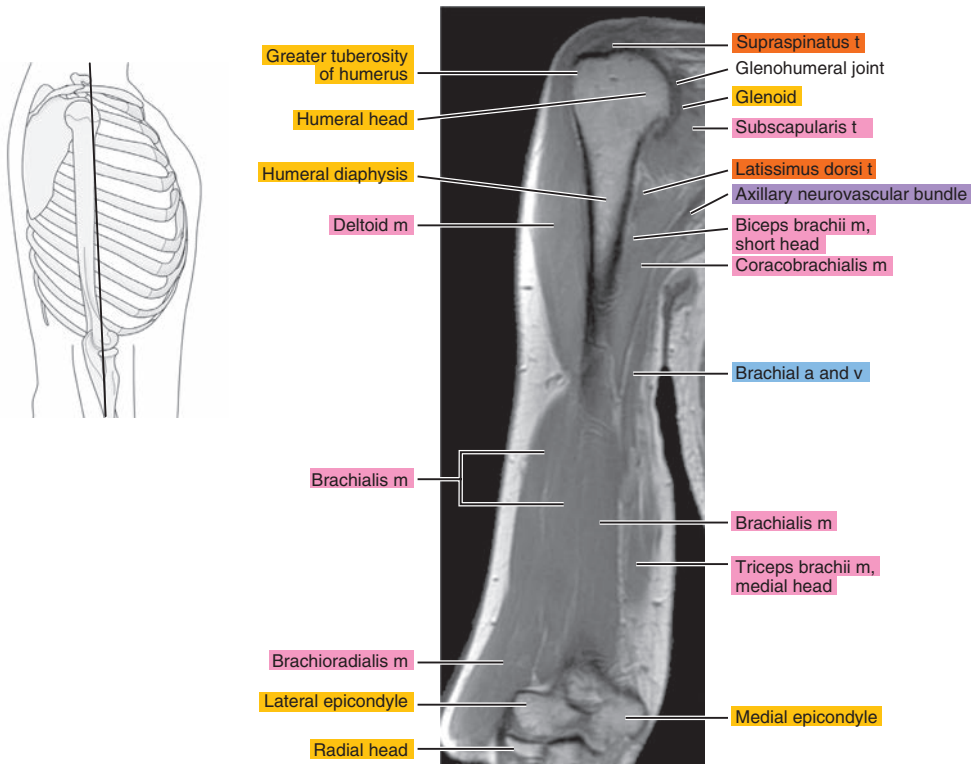




Figure 8.3.7

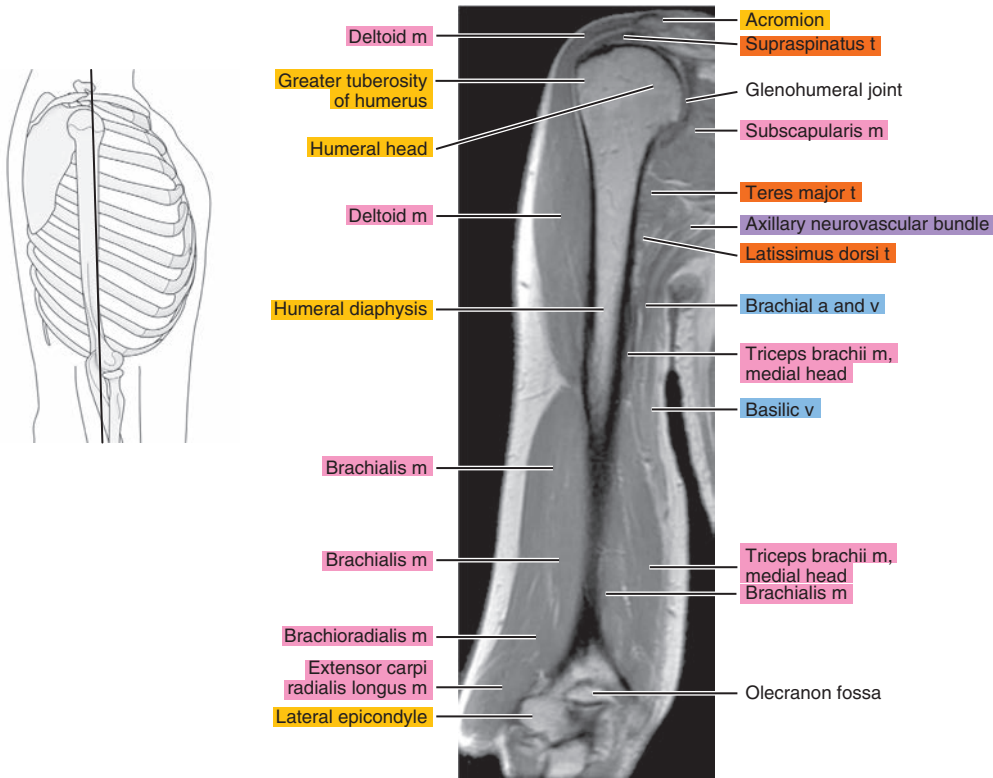


Figure 8.3.8

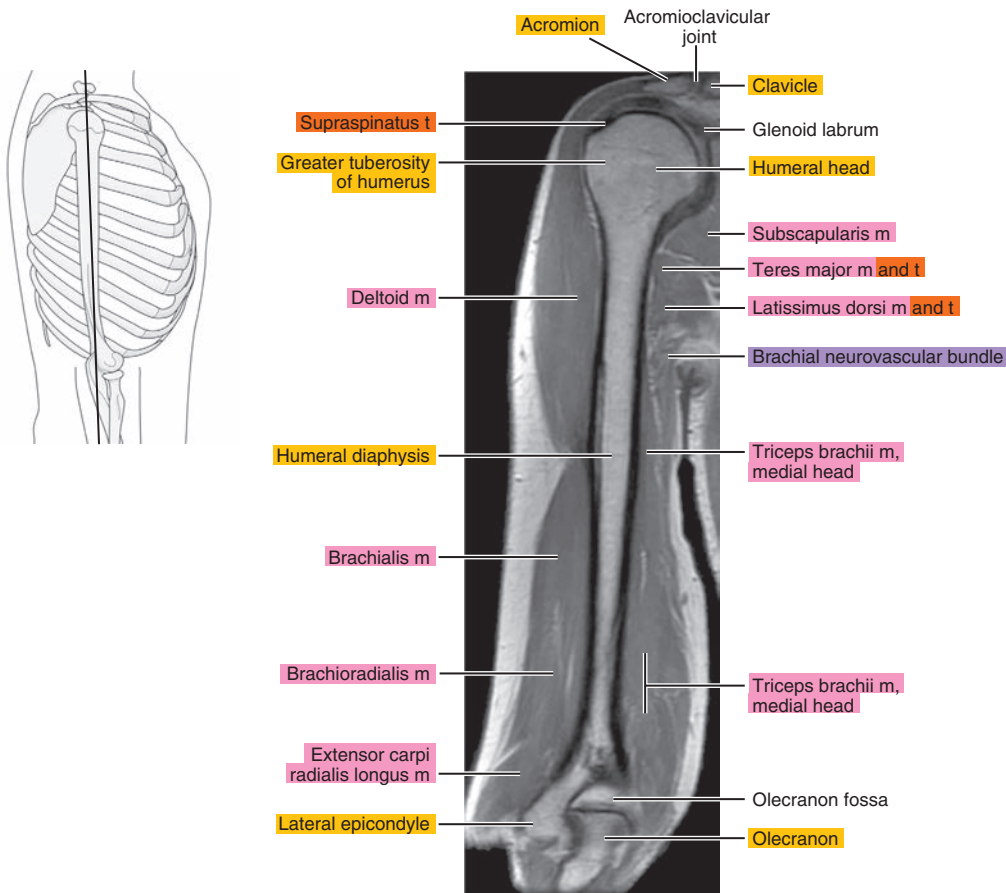


Figure 8.3.9

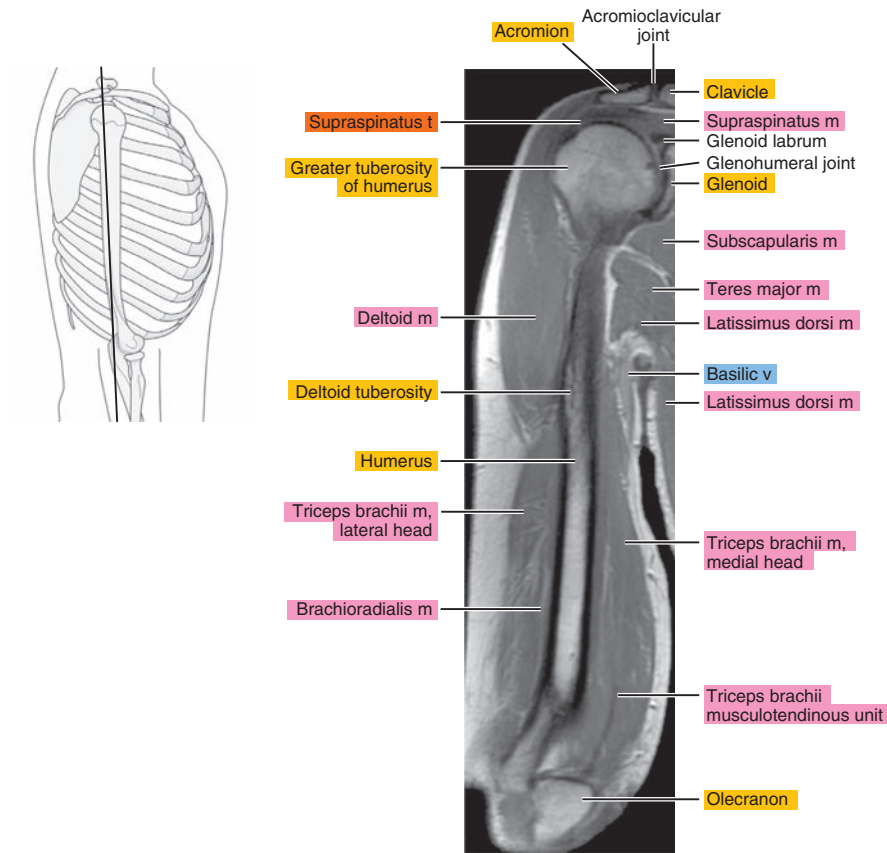


Figure 8.3.10

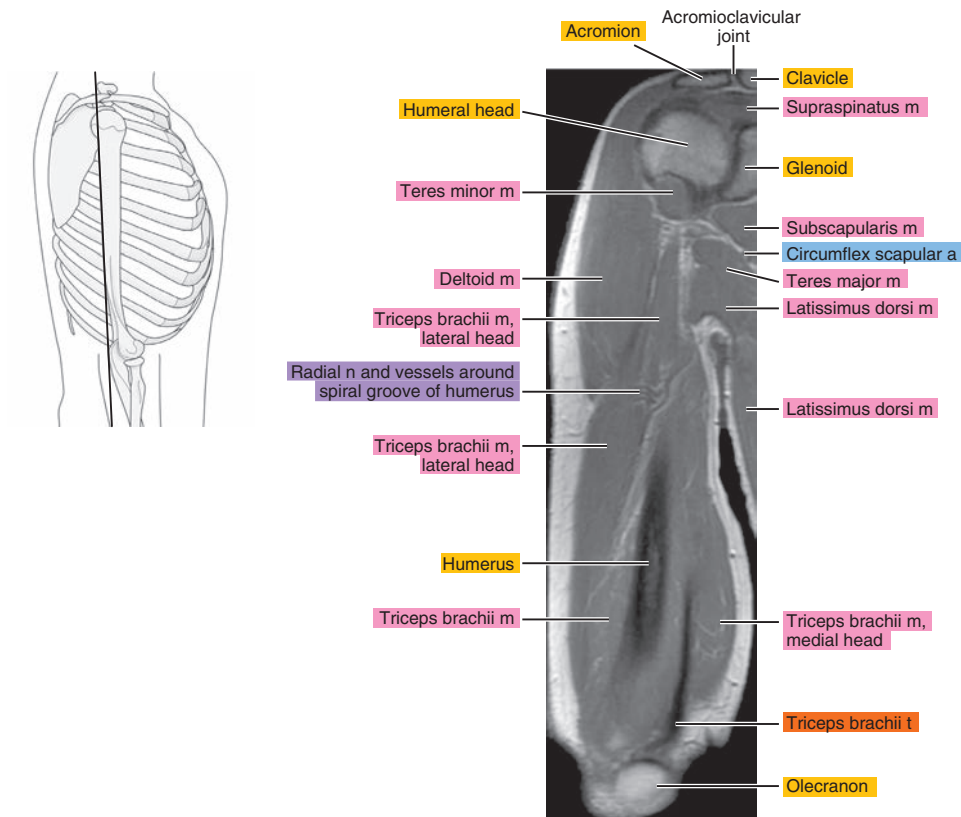


Figure 8.3.11

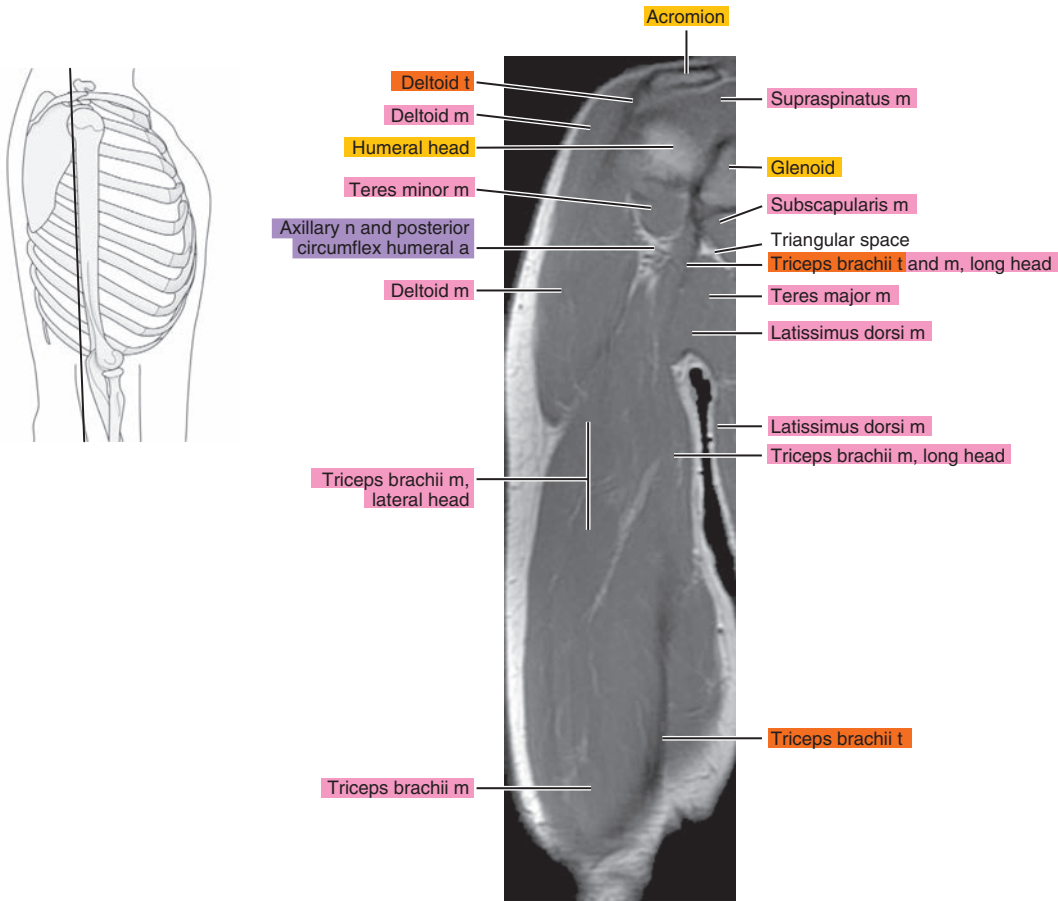


Figure 8.3.12

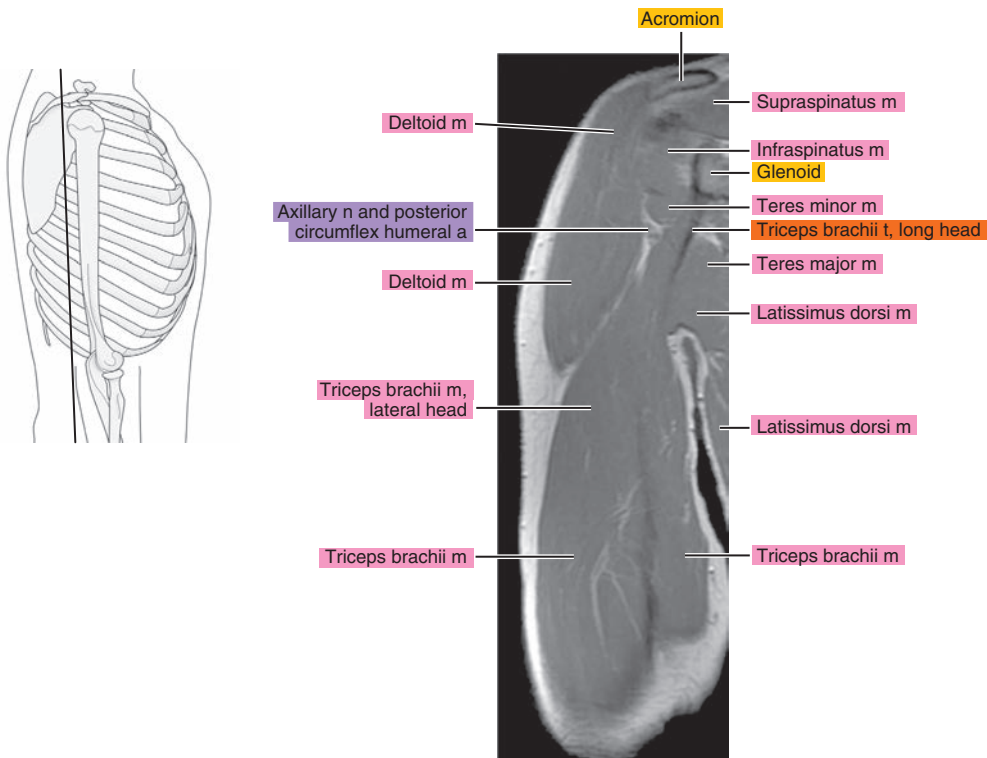


Figure 8.3.13

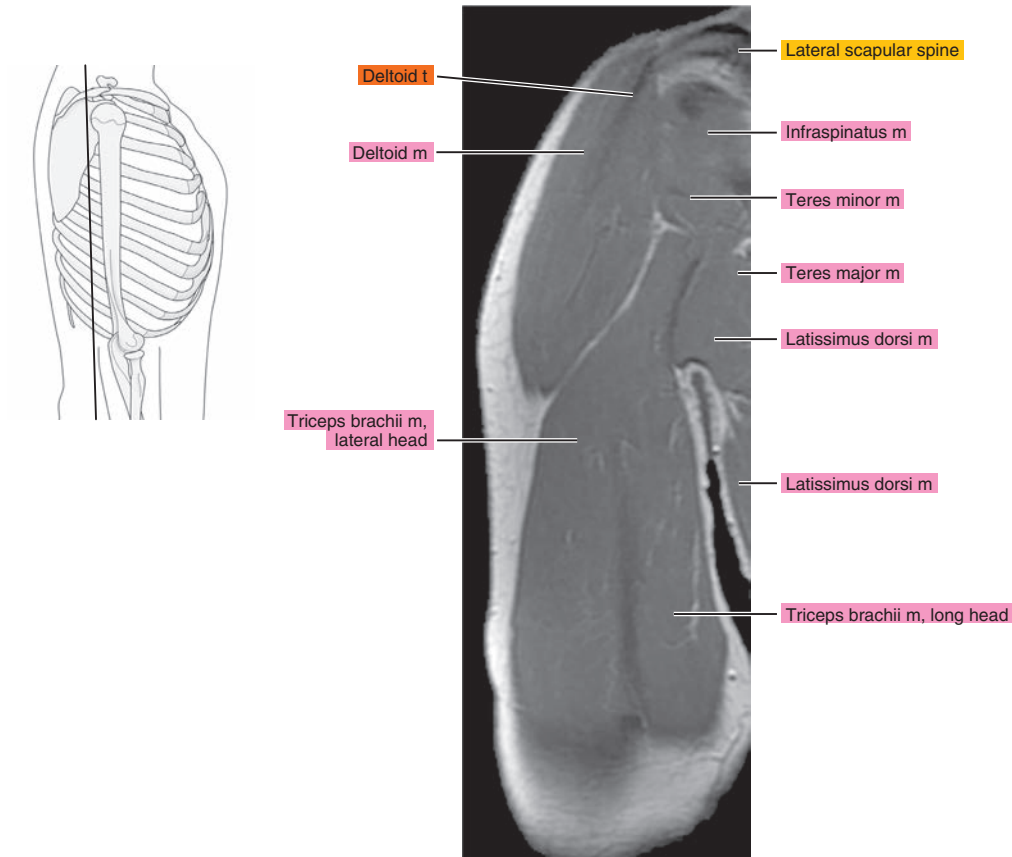


Figure 8.3.14

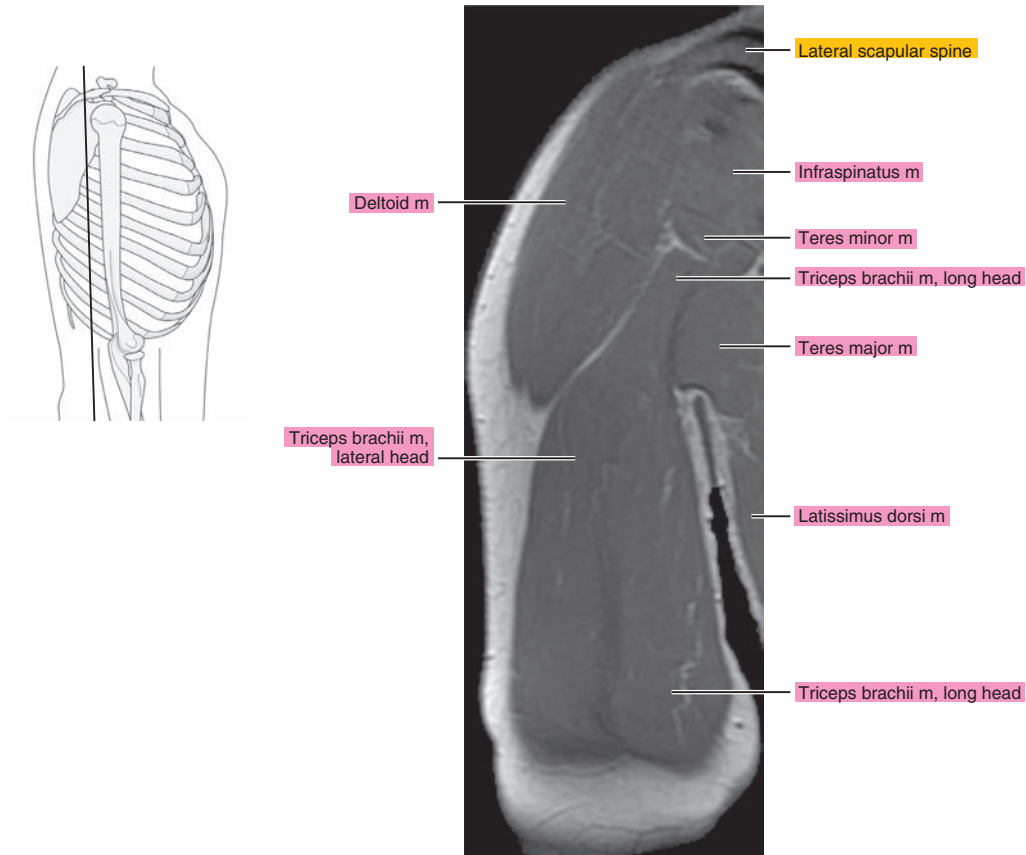




Figure 8.3.15

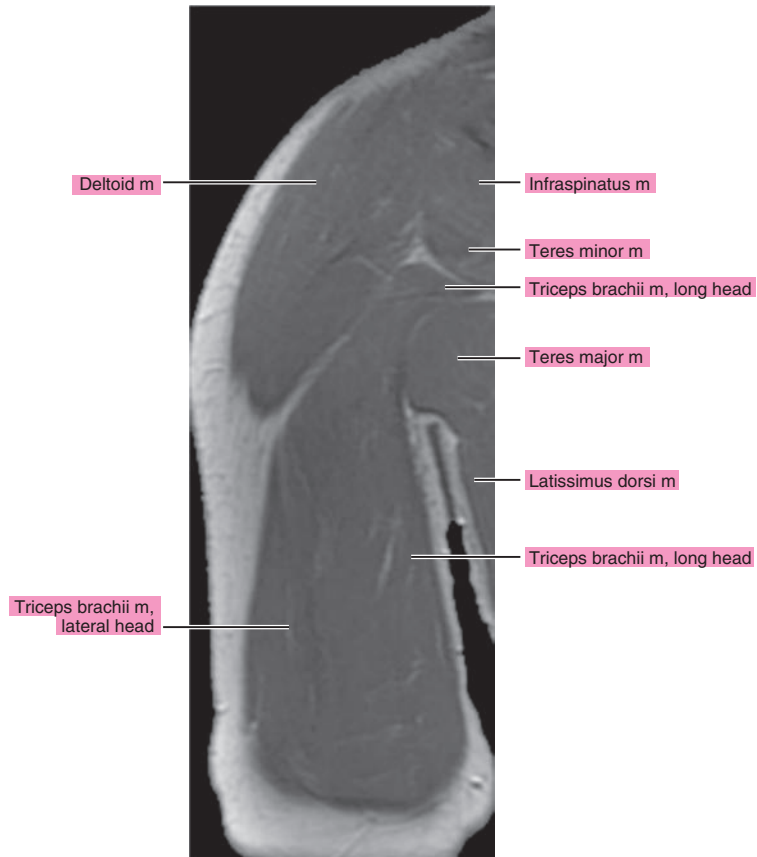
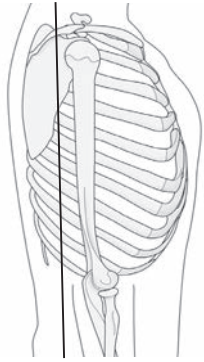


Figure 8.3.16

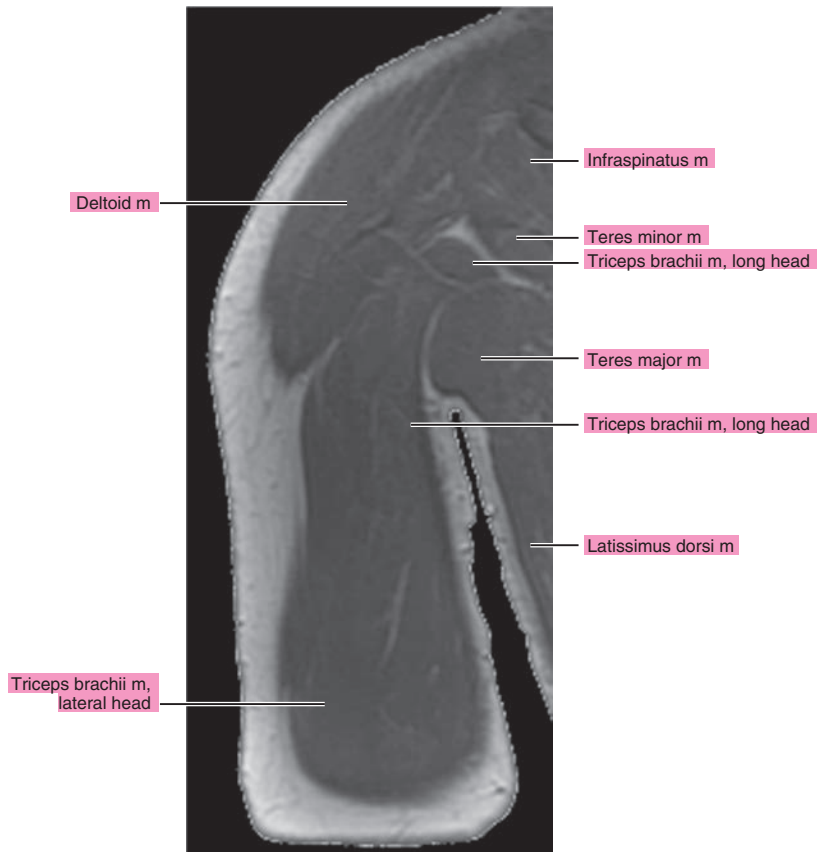
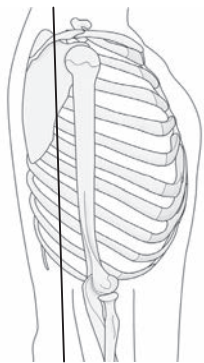


Figure 8.3.17

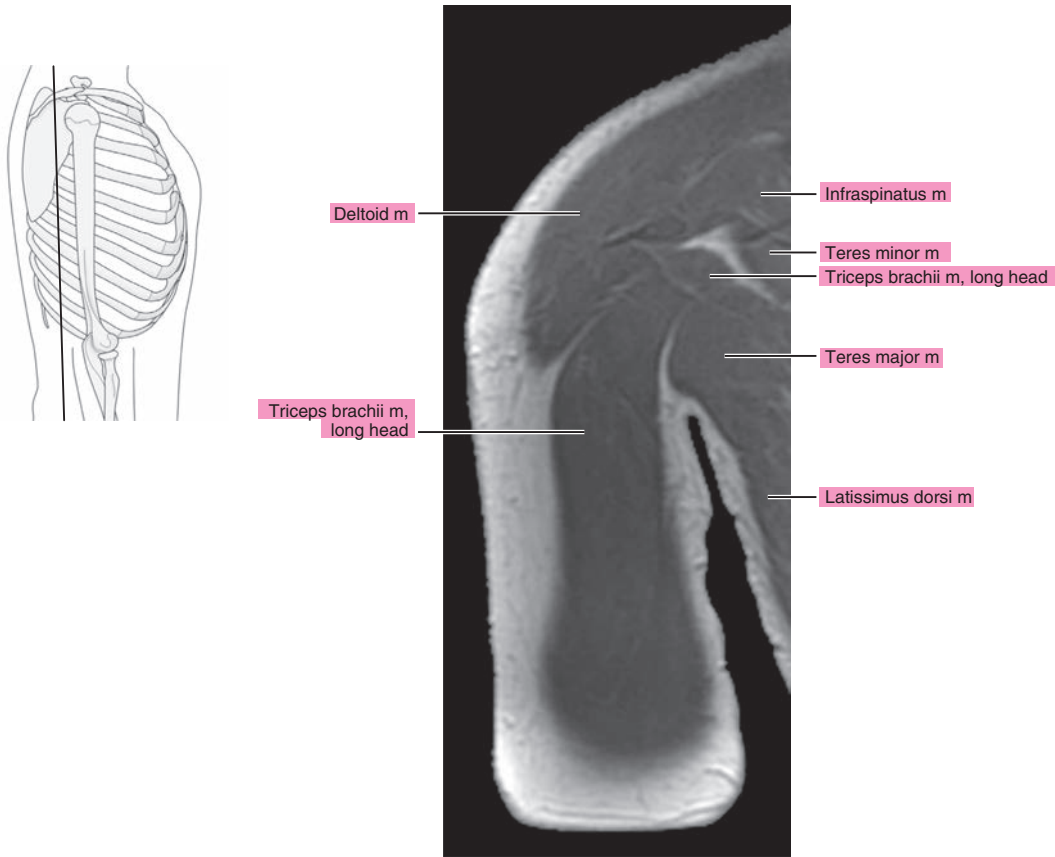
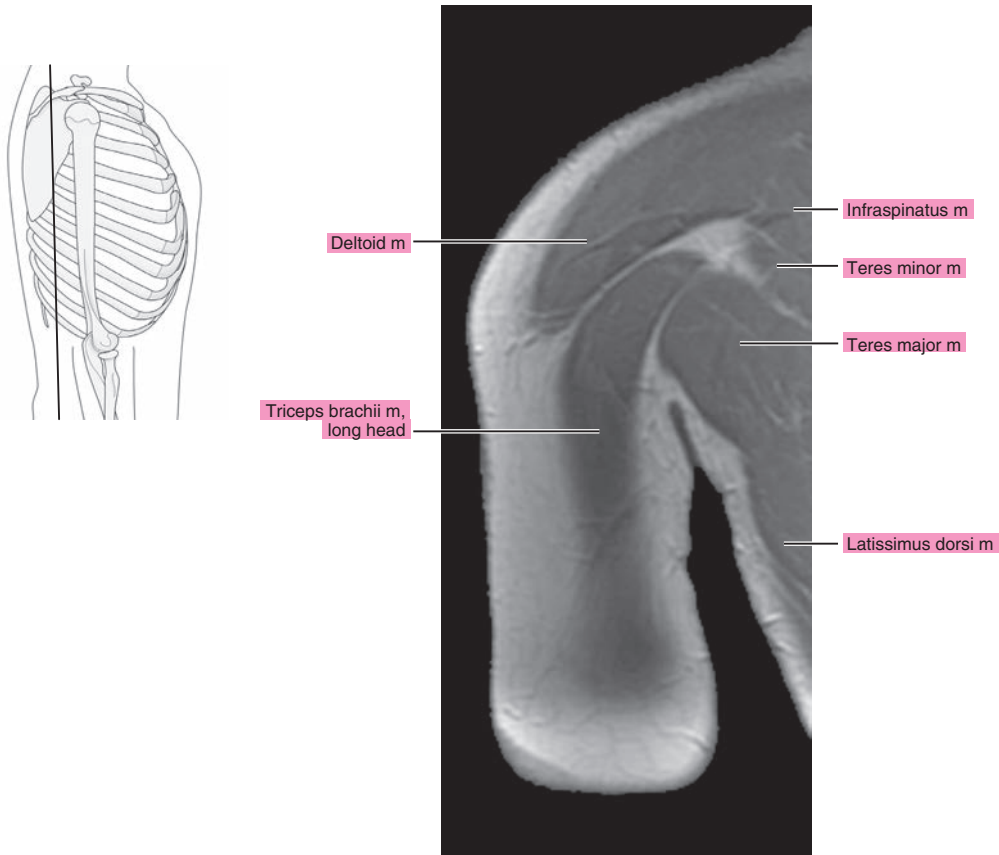


Figure 8.3.18



**Table 8-1. Muscles of the Upper Arm**

MUSCLE	ORIGIN	INSERTION	NERVE SUPPLY
<b>Coracobrachialis</b>	Coracoid process	Shaft of the humerus above the middle of the bone	Musculocutaneous (C5, C6, and C7)
<b>Biceps brachii</b>	Short head, coracoid process; long head, supraglenoid tubercle; and superior part of the glenoid labrum	Tuberosity of the radius and by aponeurotic expansion to the fascia on the ulnar side of the forearm	Musculocutaneous (C5 and C6)
<b>Brachialis</b>	Distal half of the anterior surface of the humerus	Coronoid process and tuberosity of the ulna	Musculocutaneous (C5 and C6)
<b>Triceps</b>	Long head, infraglenoid tuberosity of the scapula; lateral head, from the posterior surface of the humerus; and medial head, from the posterior surface of the humerus below the radial groove and dorsal surfaces of the medial and lateral intermuscular septa	Primary tendon inserts onto the olecranon process of the ulna and laterally, by expansion over the anconeus, into the dorsal fascia of the forearm	Radial (C6, C7, and C8)

*Chapter*  
9

# **MRI of the Elbow**



# AXIAL

Figure 9.1.1

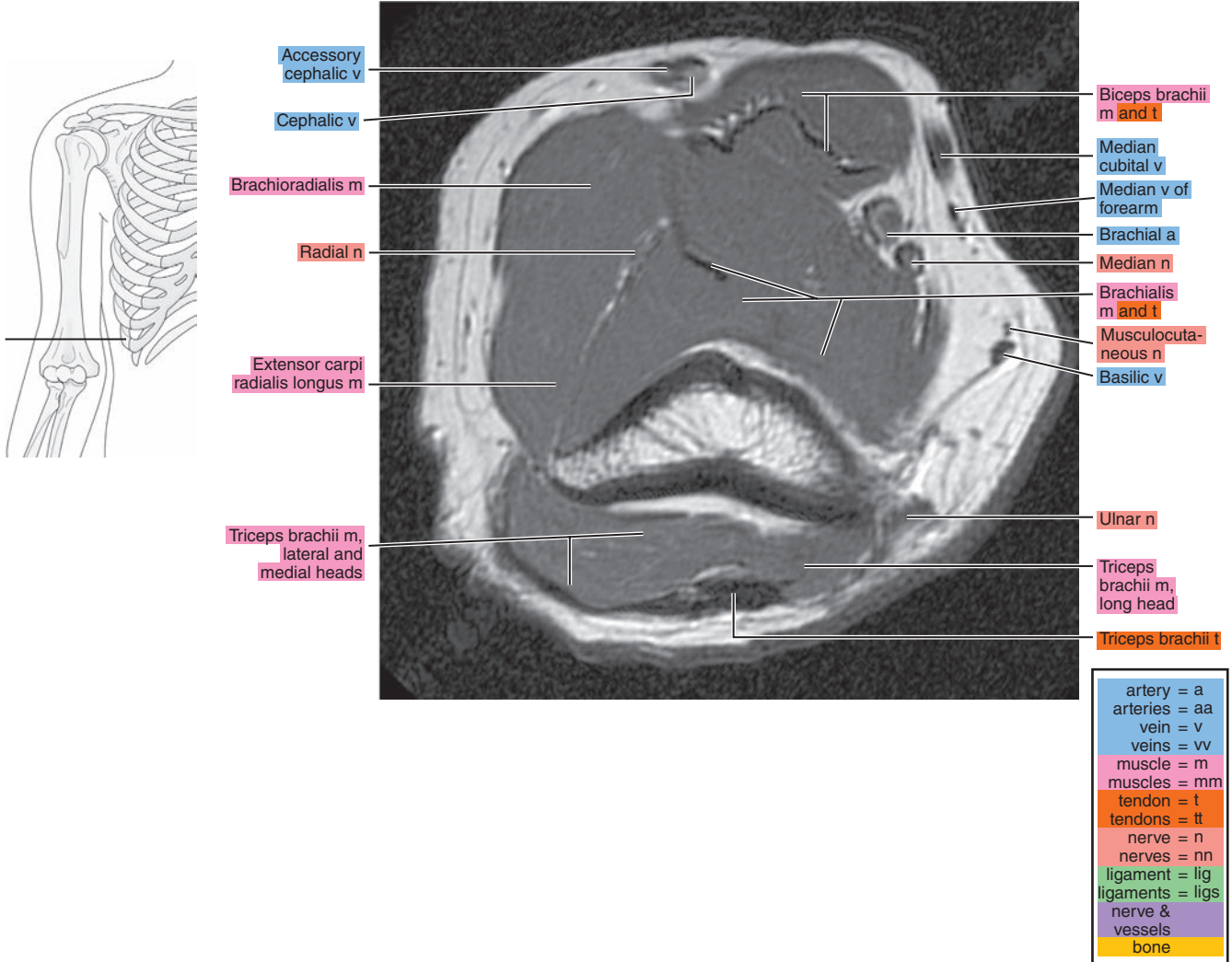


Figure 9.1.2

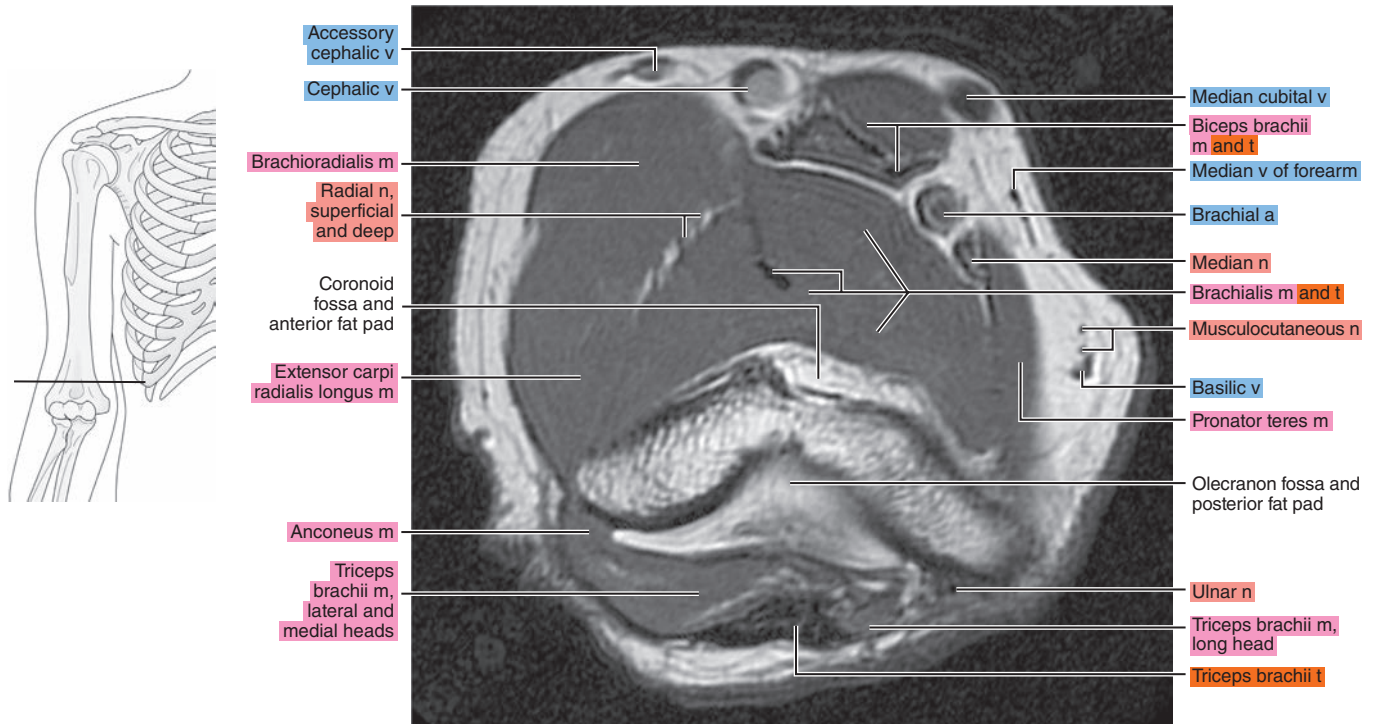


Figure 9.1.3

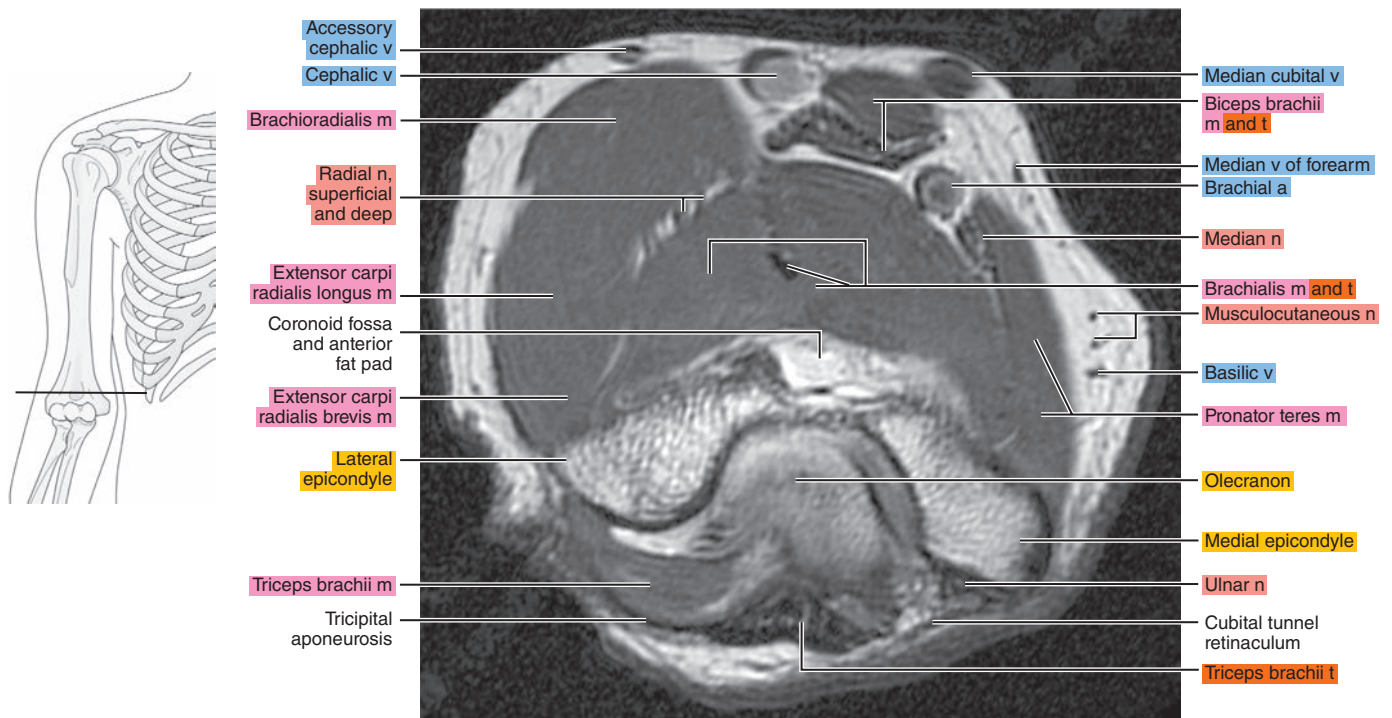


Figure 9.1.4

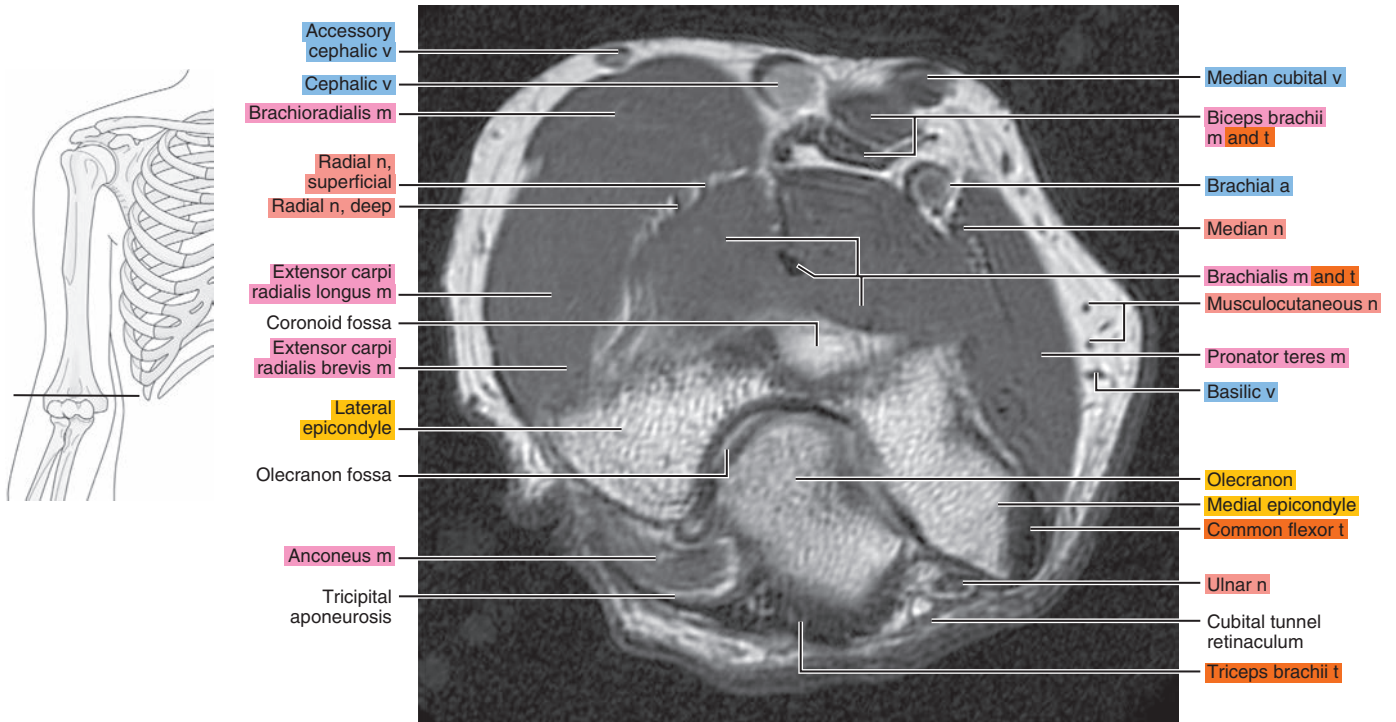


Figure 9.1.5

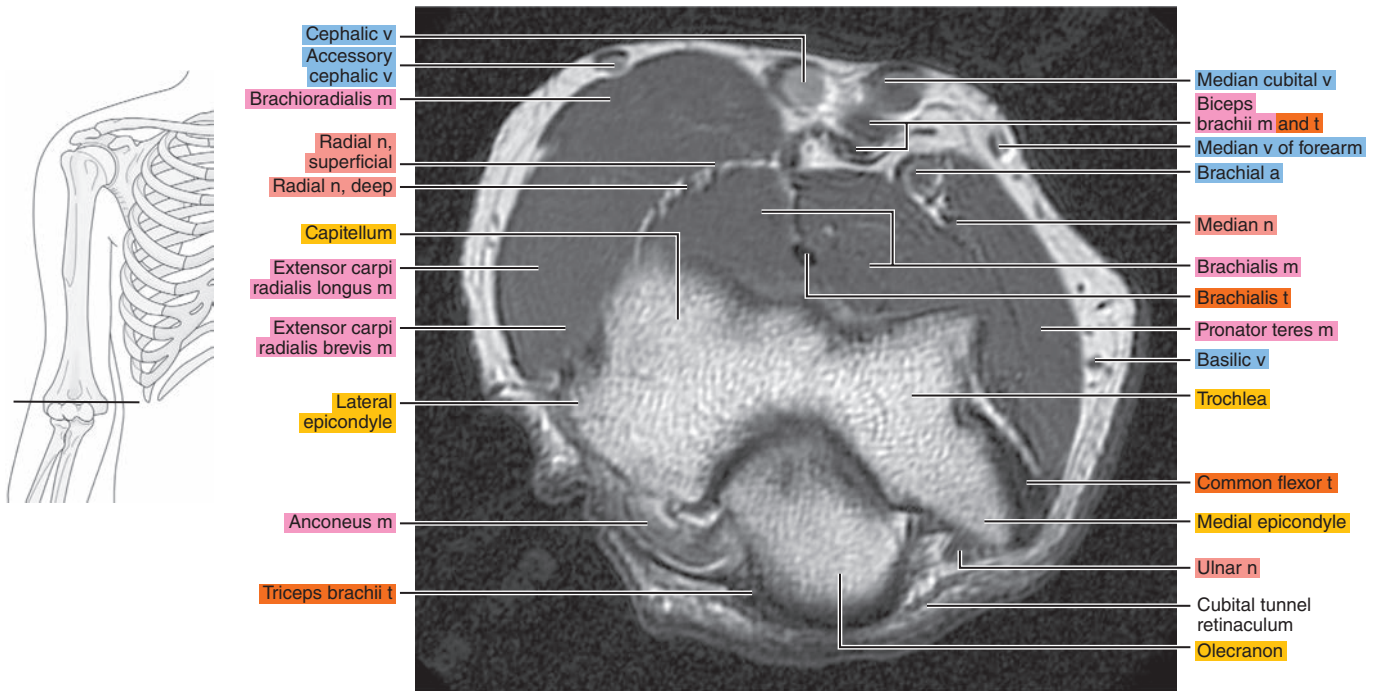
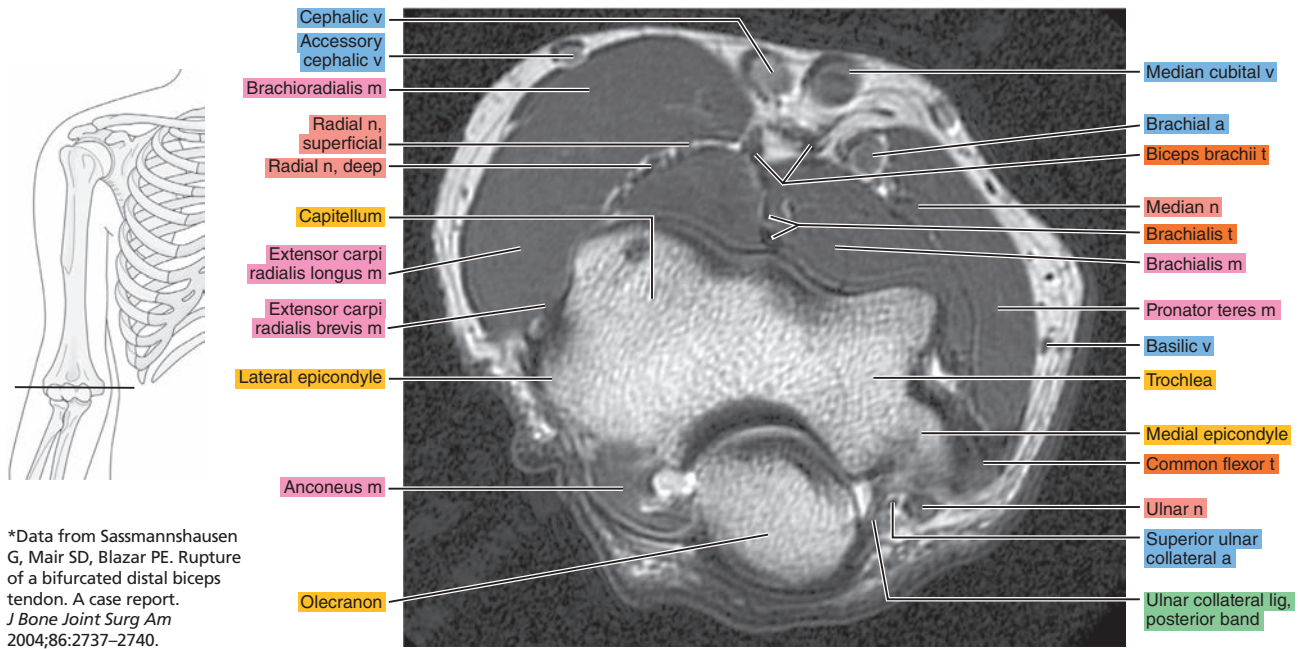


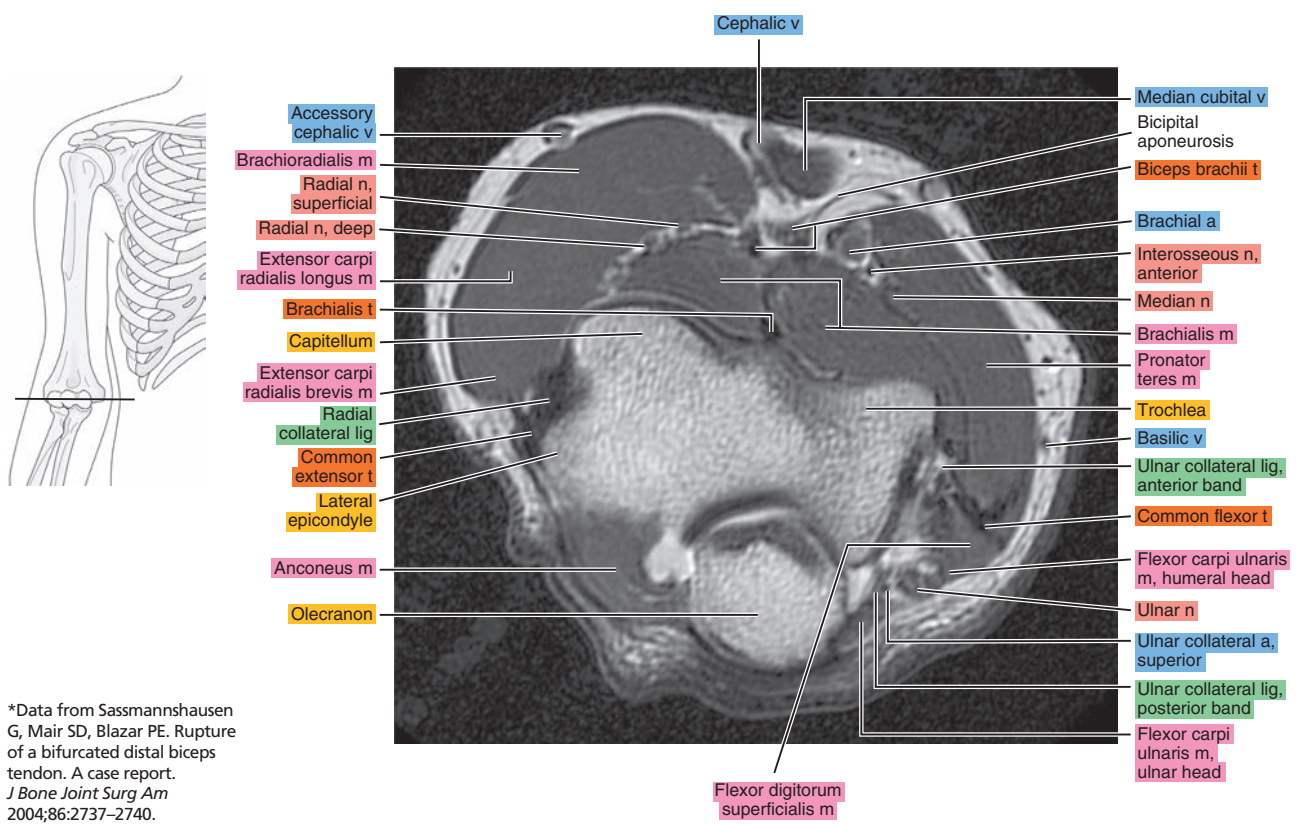


Figure 9.1.6



\*Data from Sassmannshausen G, Mair SD, Blazar PE. Rupture of a bifurcated distal biceps tendon. A case report. *J Bone Joint Surg Am* 2004;86:2737-2740.

Figure 9.1.7



\*Data from Sassmannshausen G, Mair SD, Blazar PE. Rupture of a bifurcated distal biceps tendon. A case report. *J Bone Joint Surg Am* 2004;86:2737-2740.



Figure 9.1.8

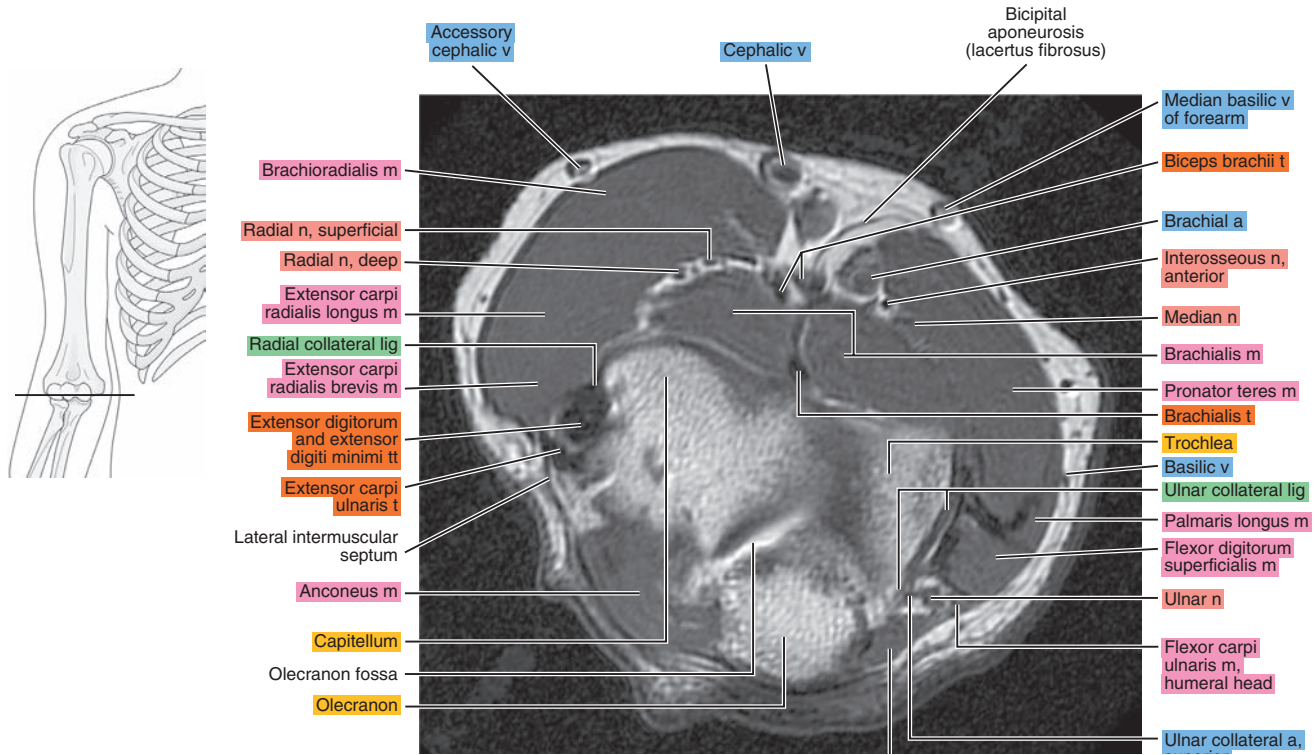


Figure 9.1.9

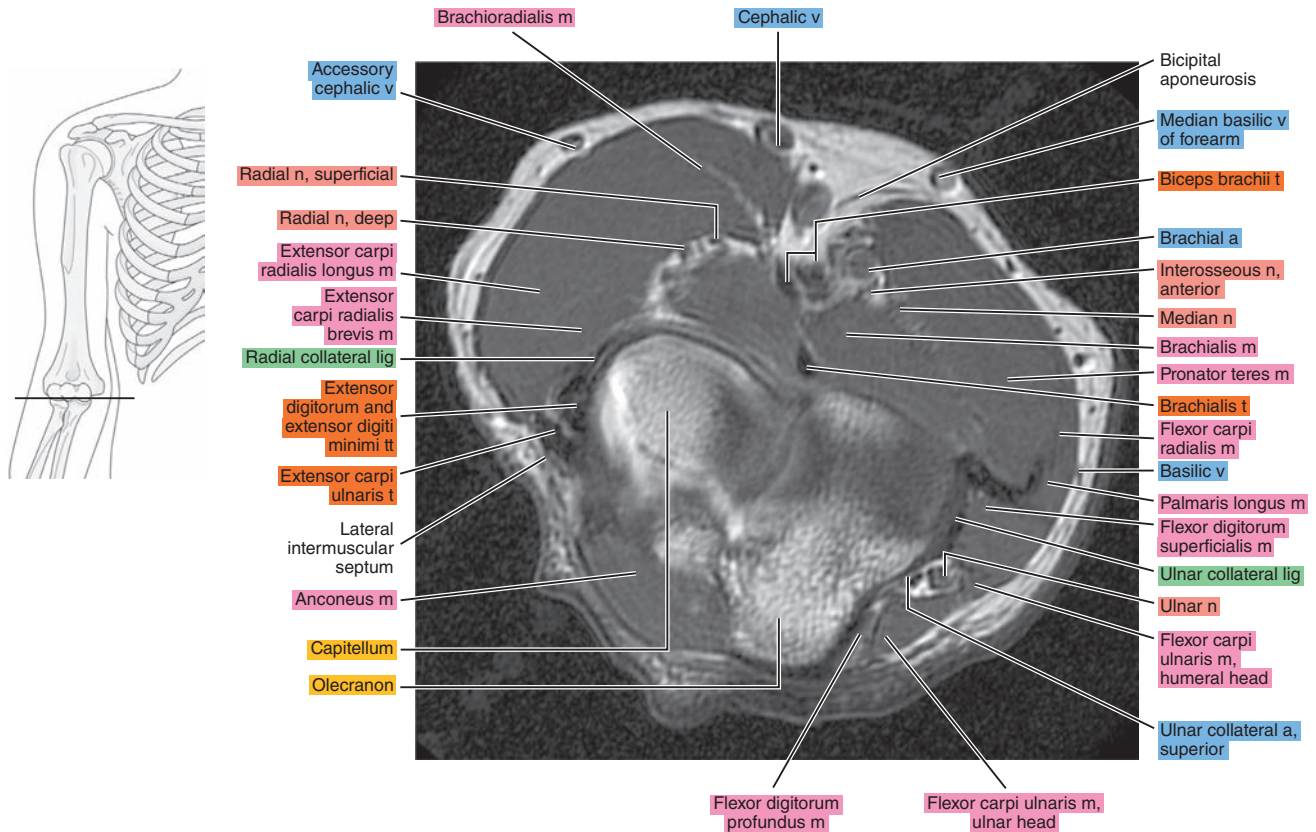


Figure 9.1.10

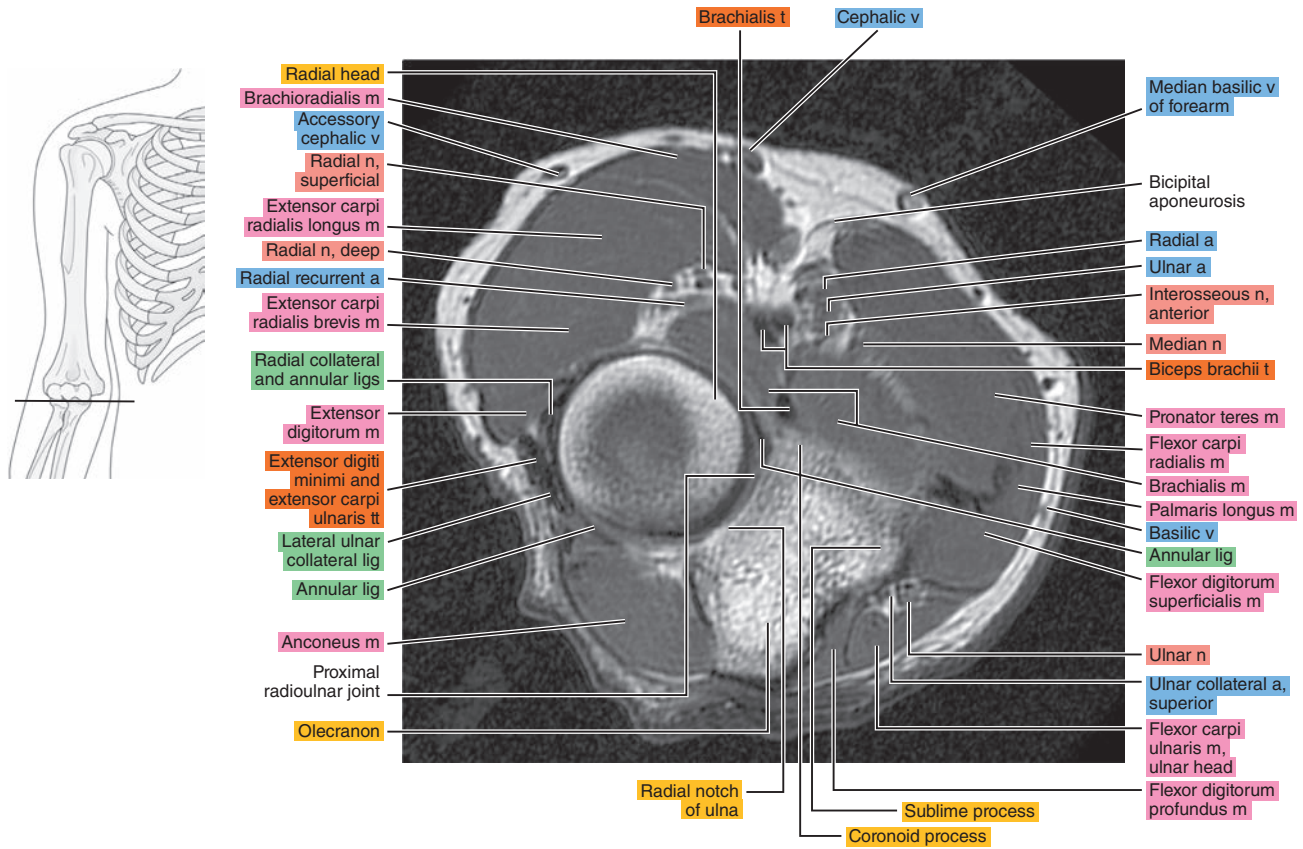


Figure 9.1.11

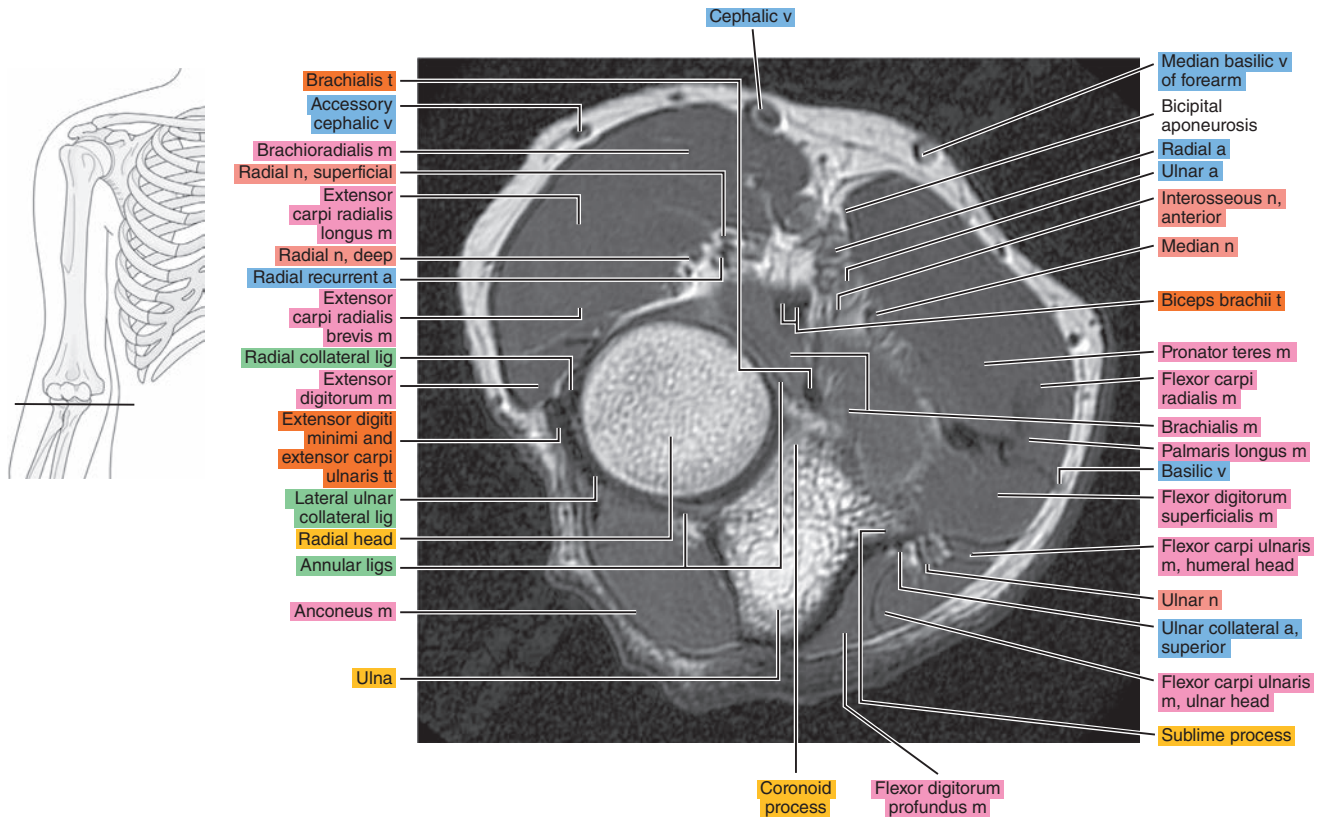




Figure 9.1.12

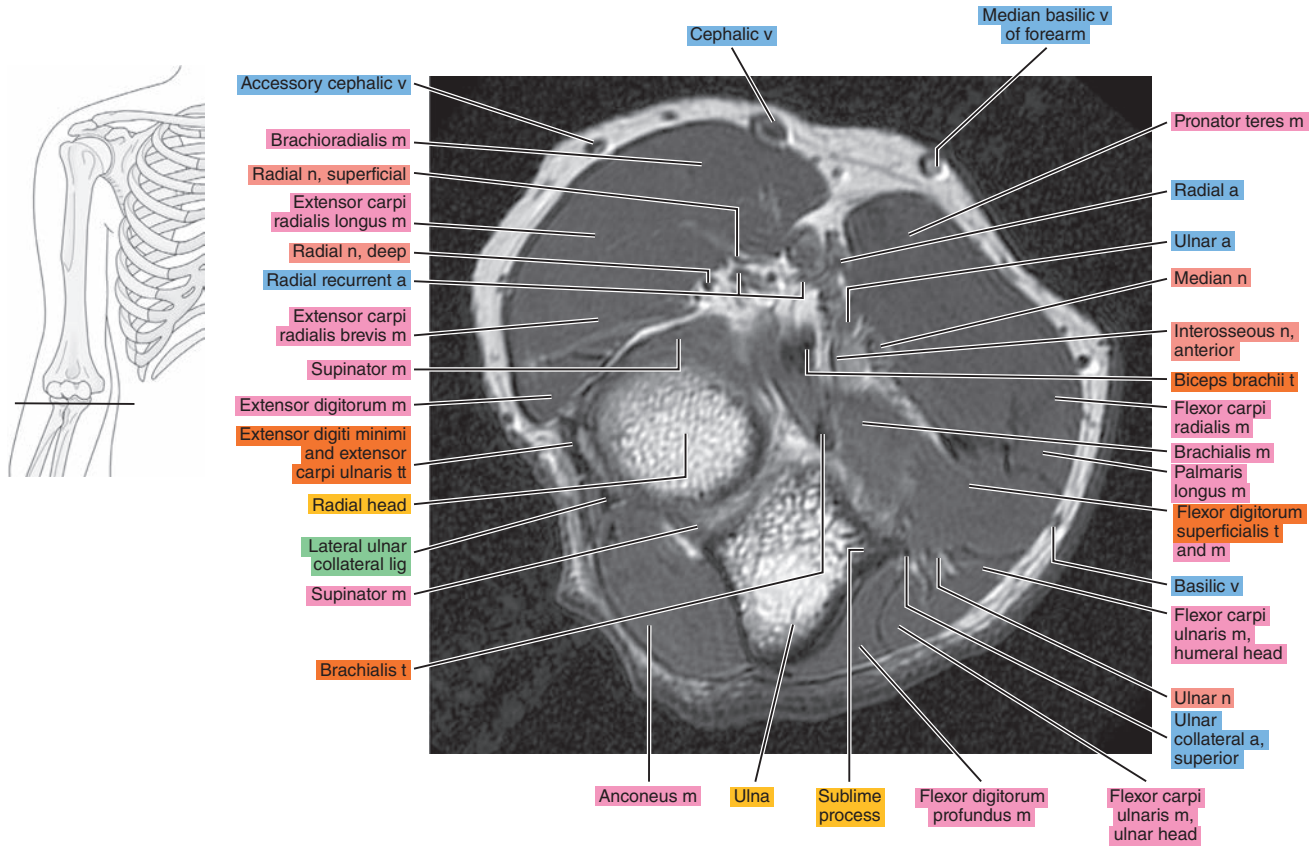


Figure 9.1.13

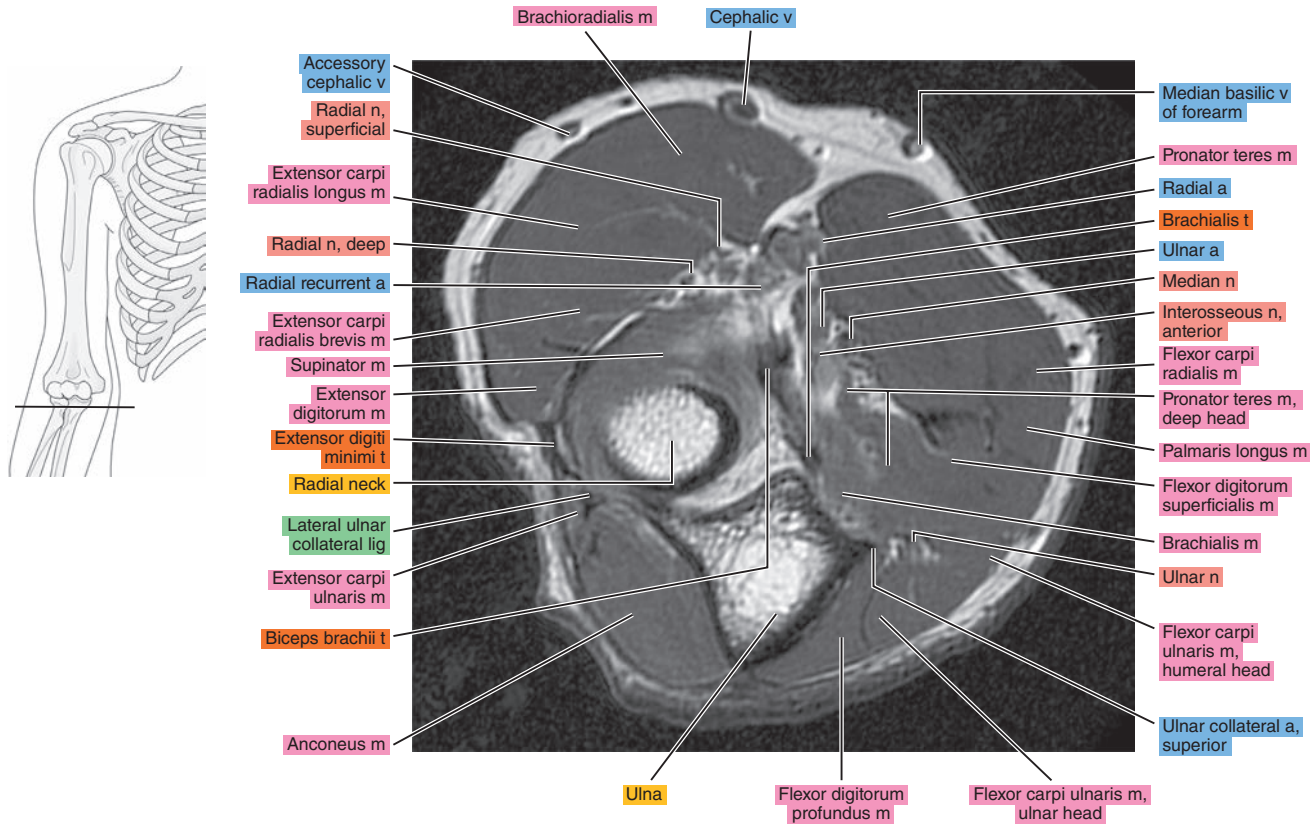


Figure 9.1.14

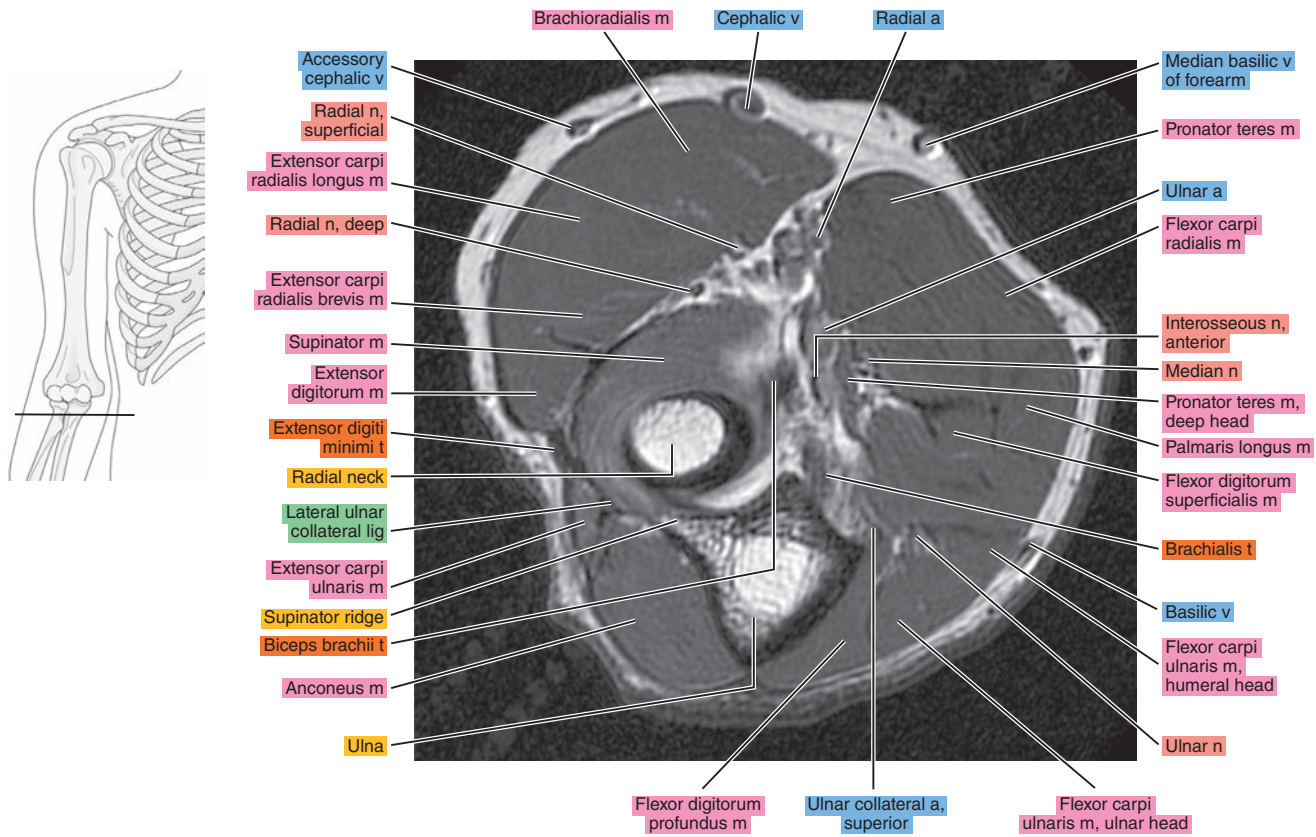


Figure 9.1.15

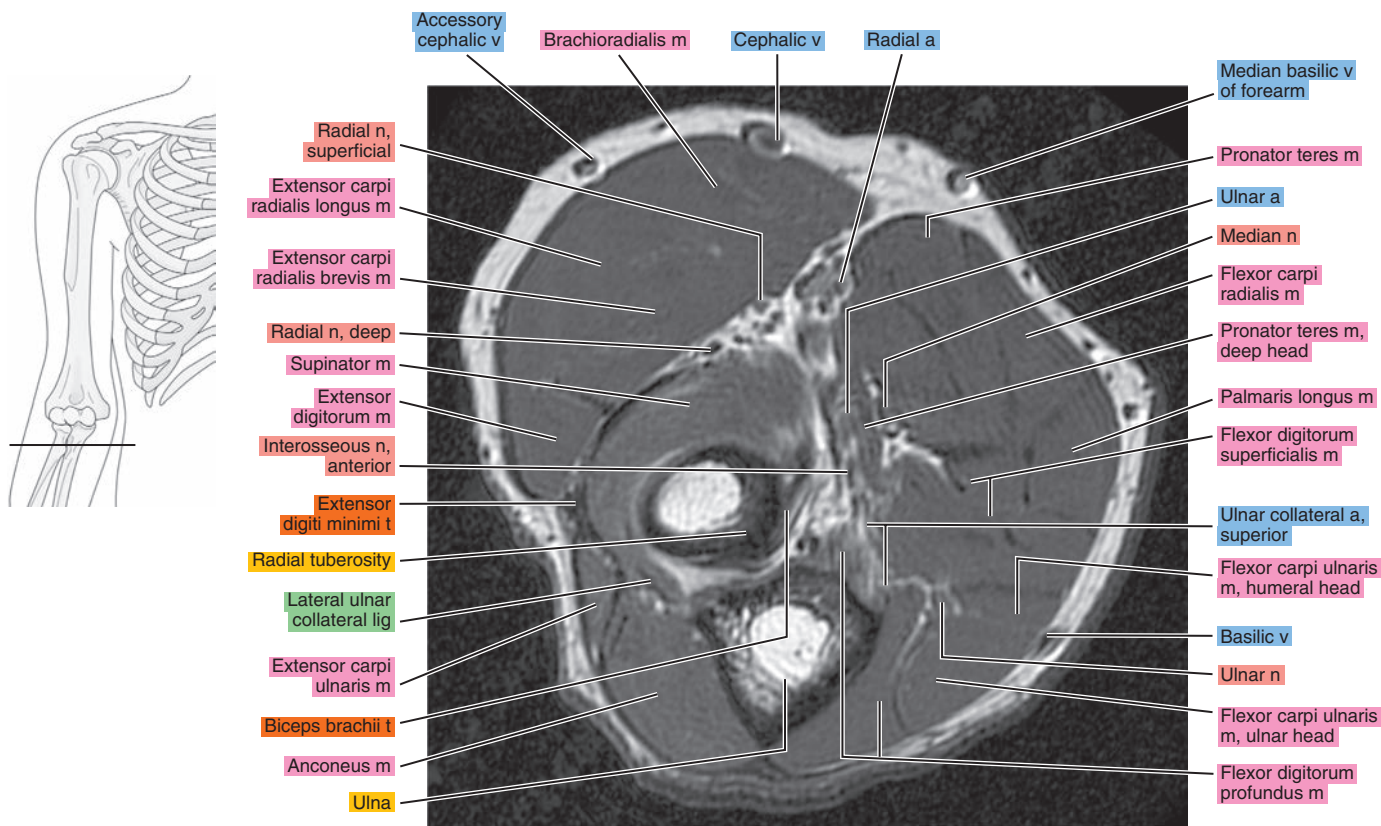




Figure 9.1.16

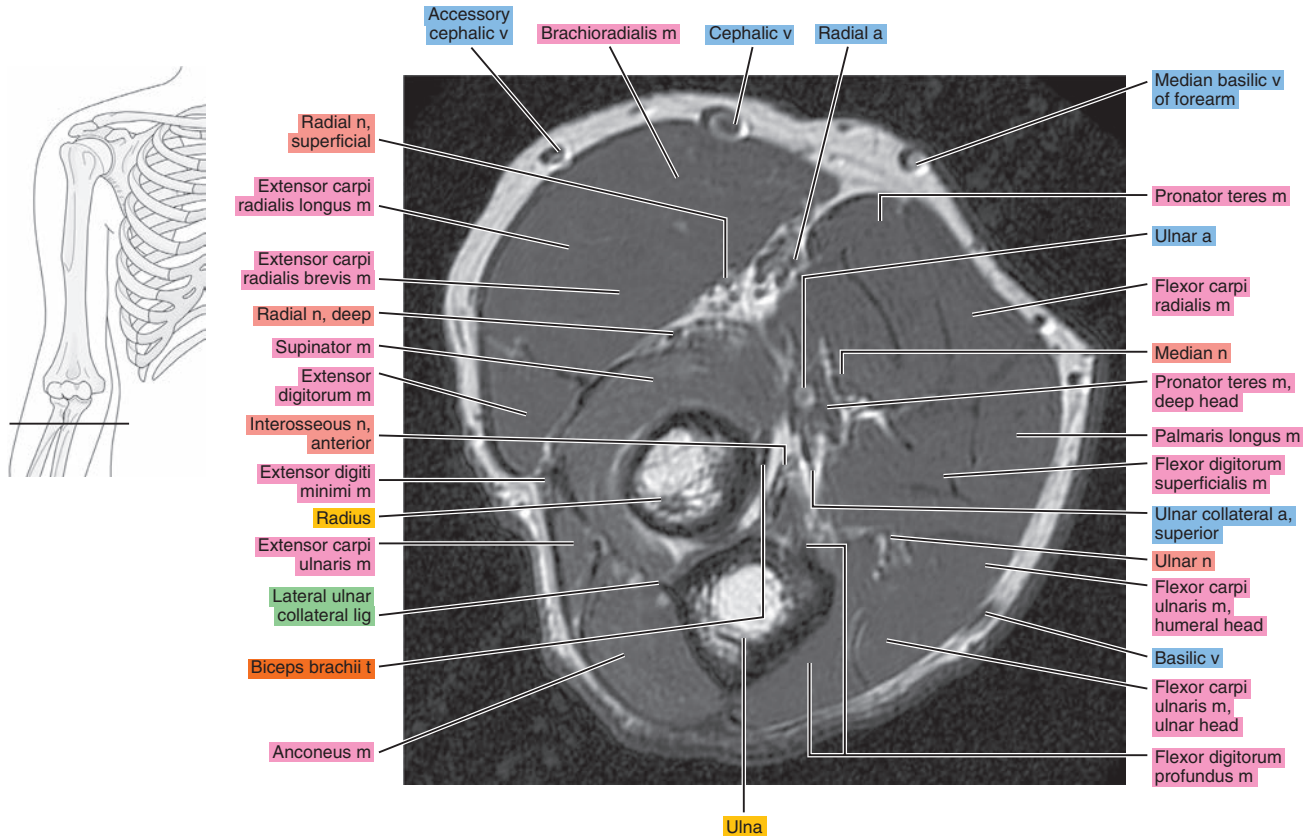


Figure 9.1.17

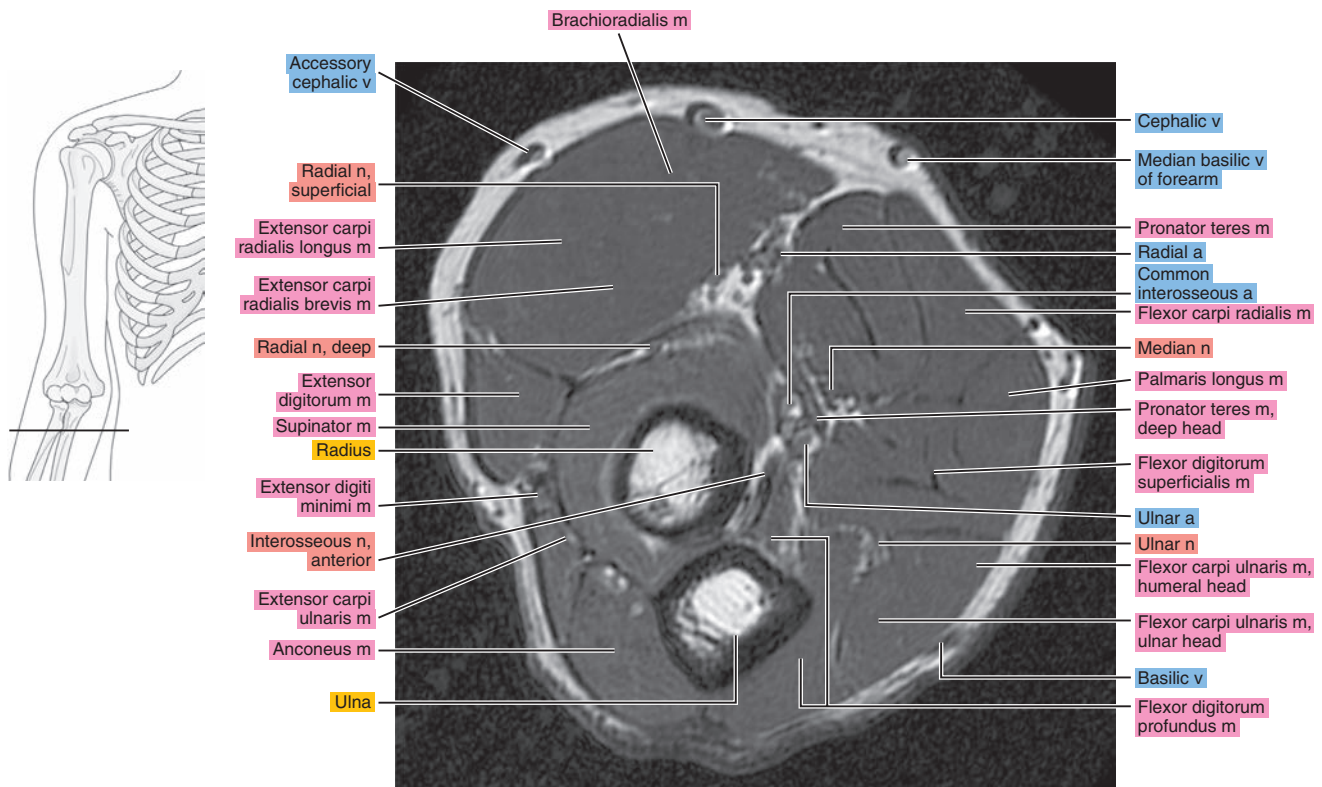


Figure 9.1.18

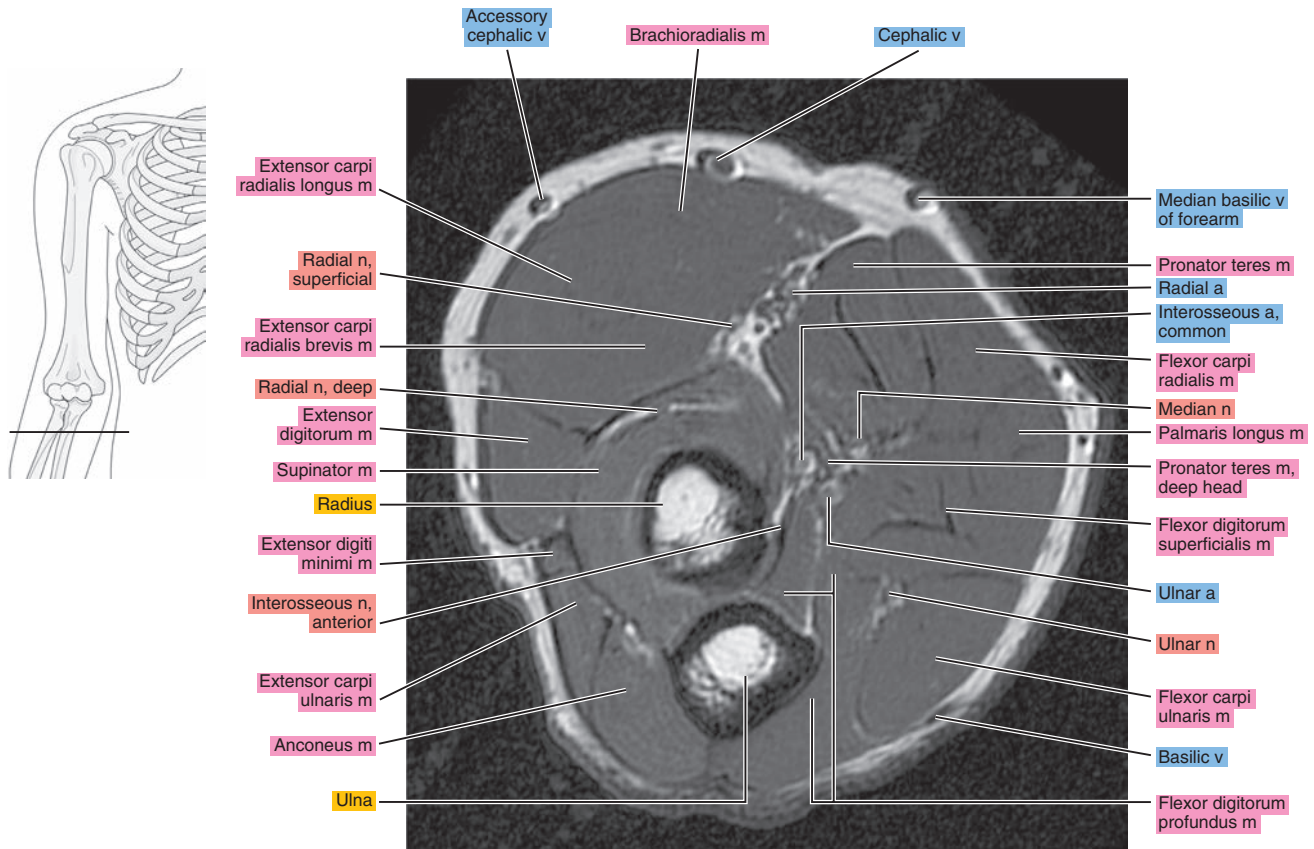


Figure 9.1.19

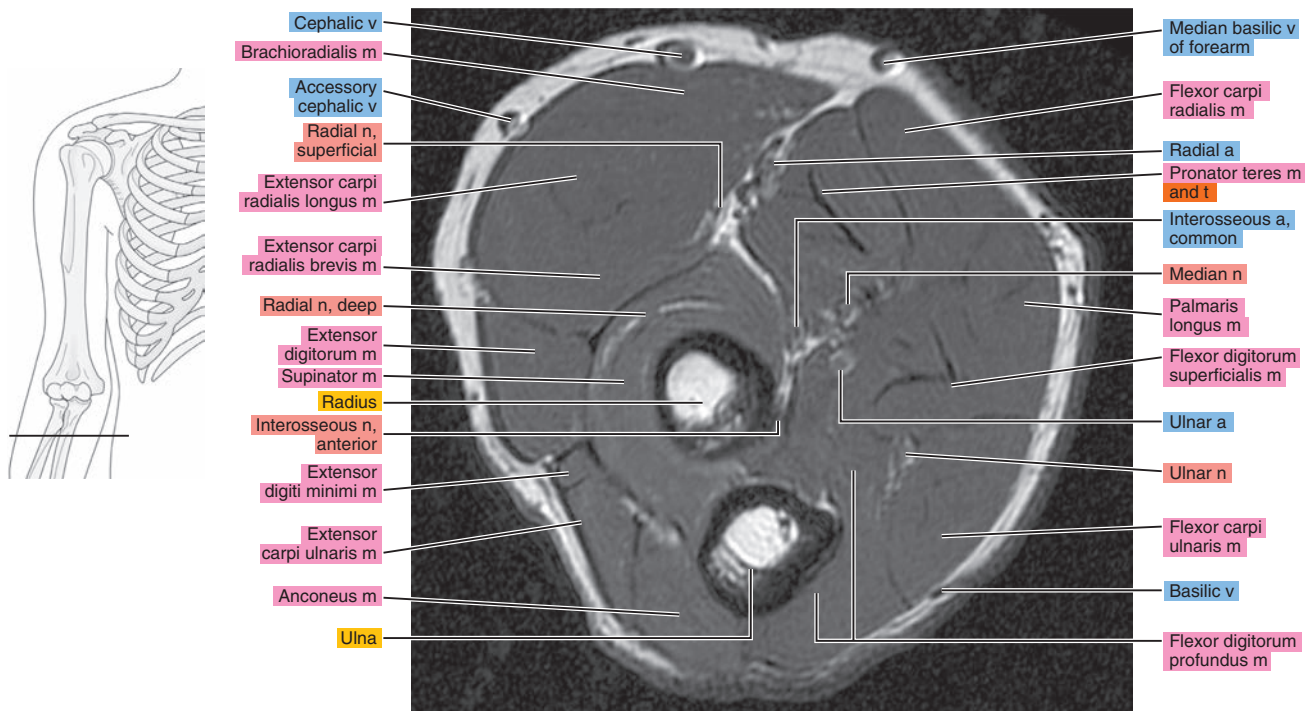
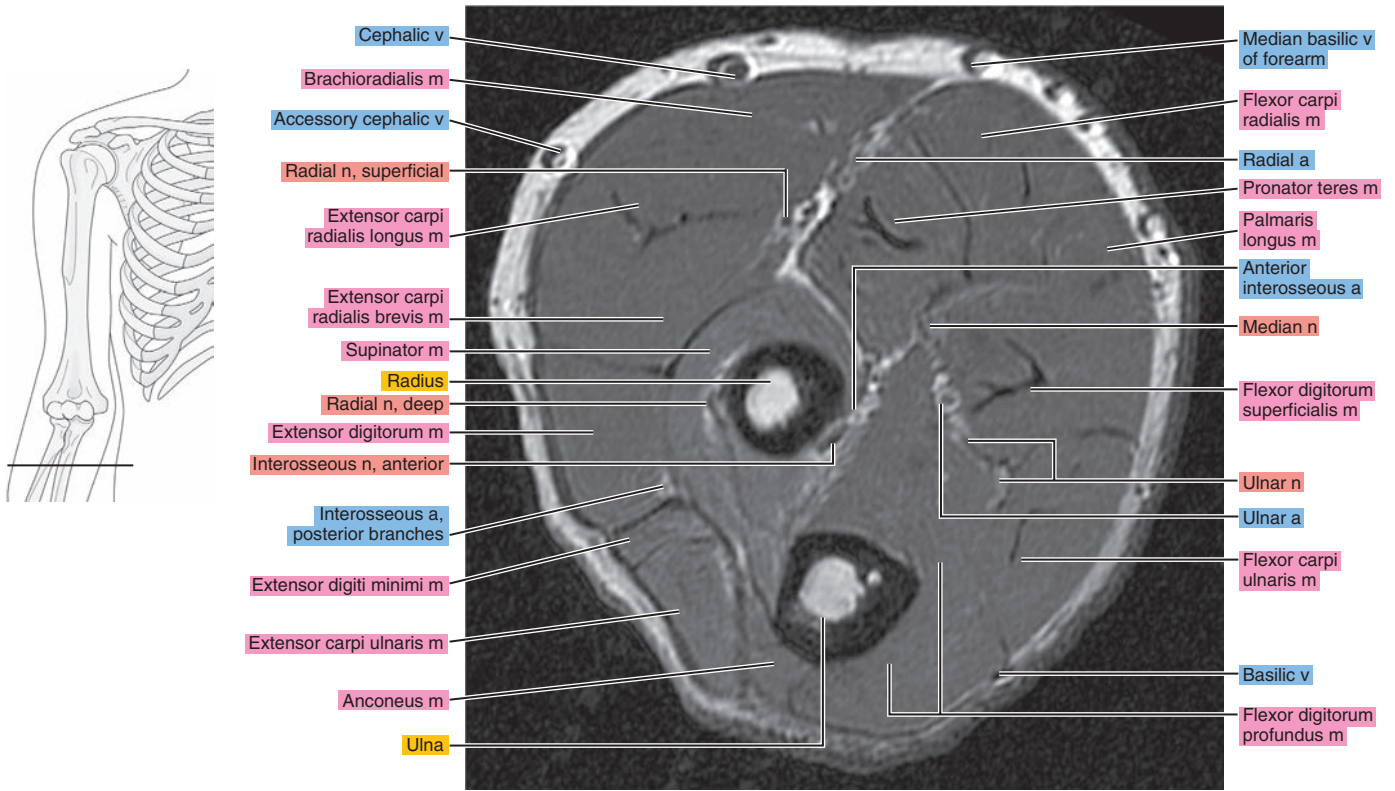


Figure 9.1.20





# OBLIQUE SAGITTAL

Figure 9.2.1

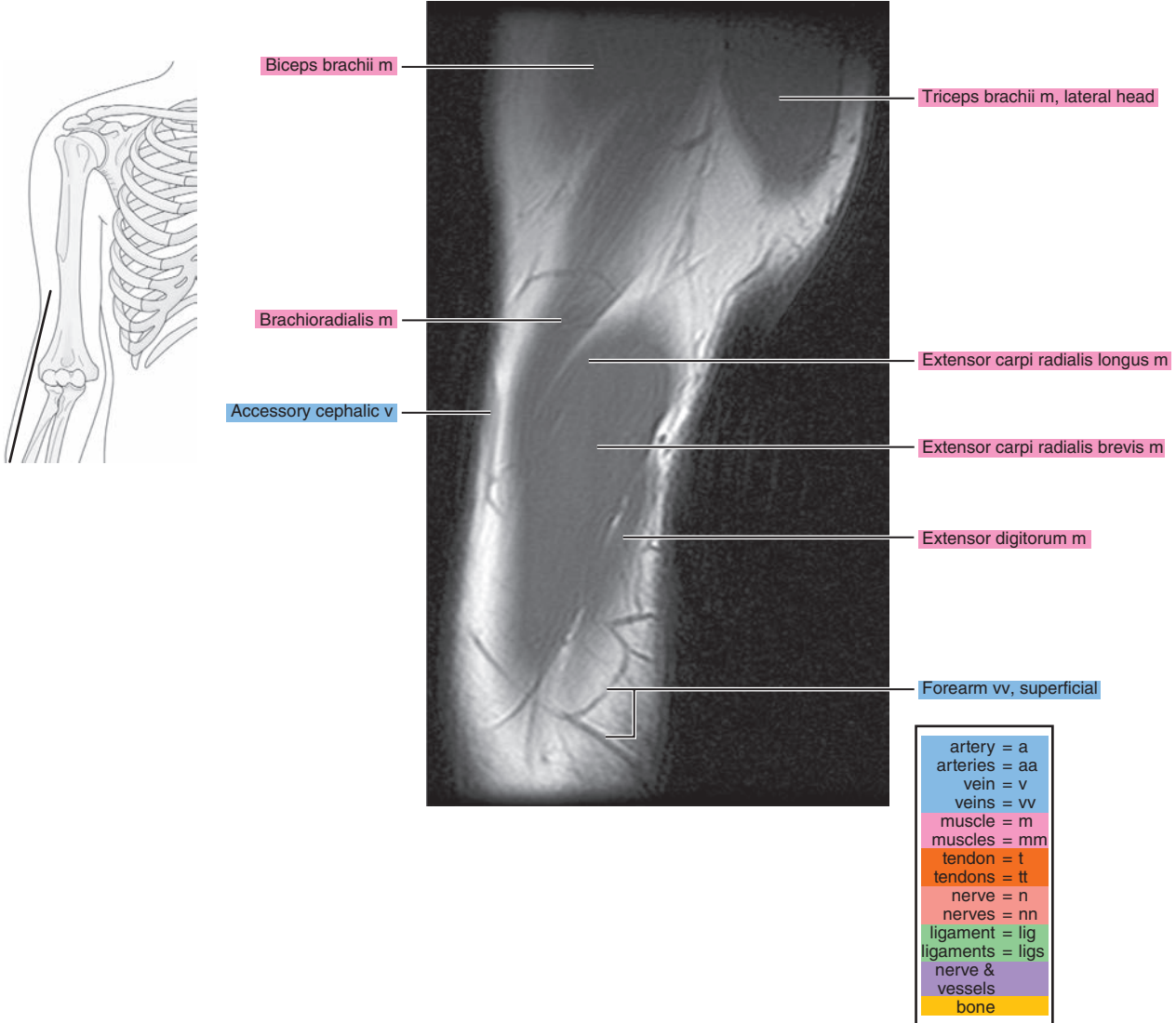




Figure 9.2.2

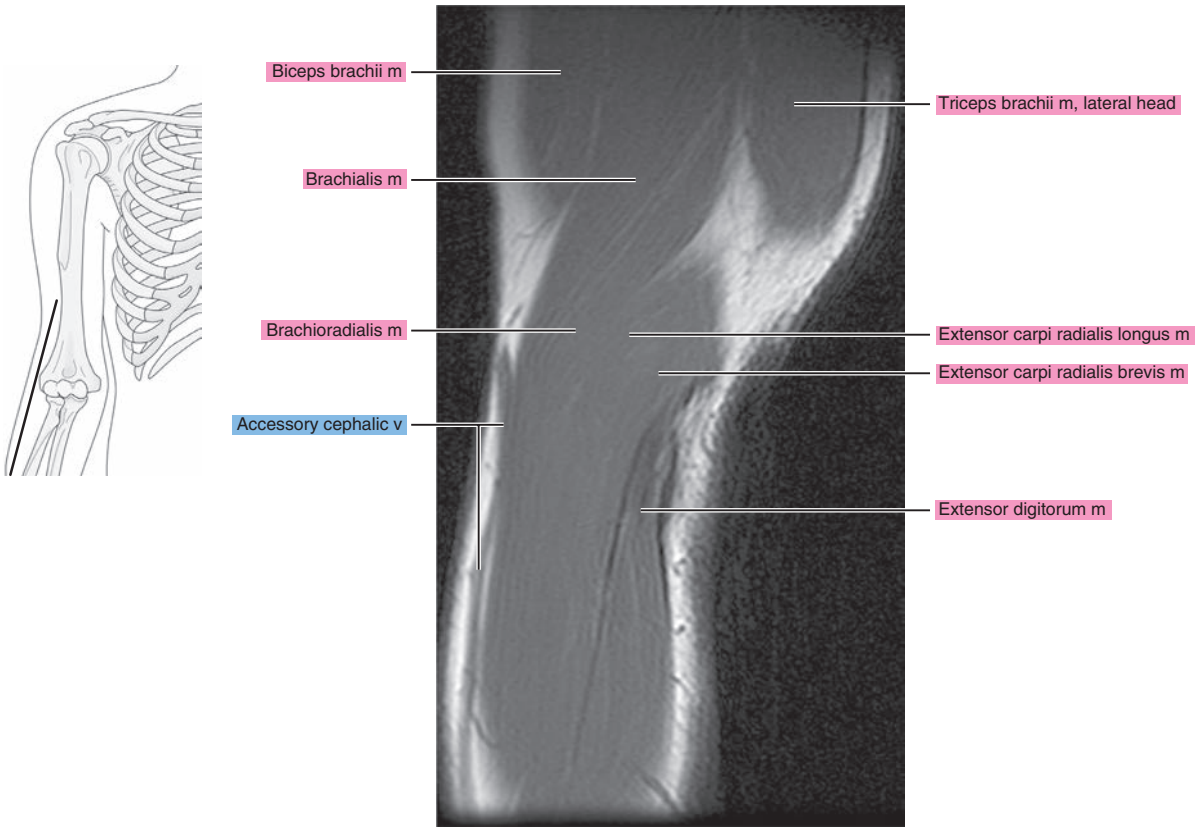


Figure 9.2.3

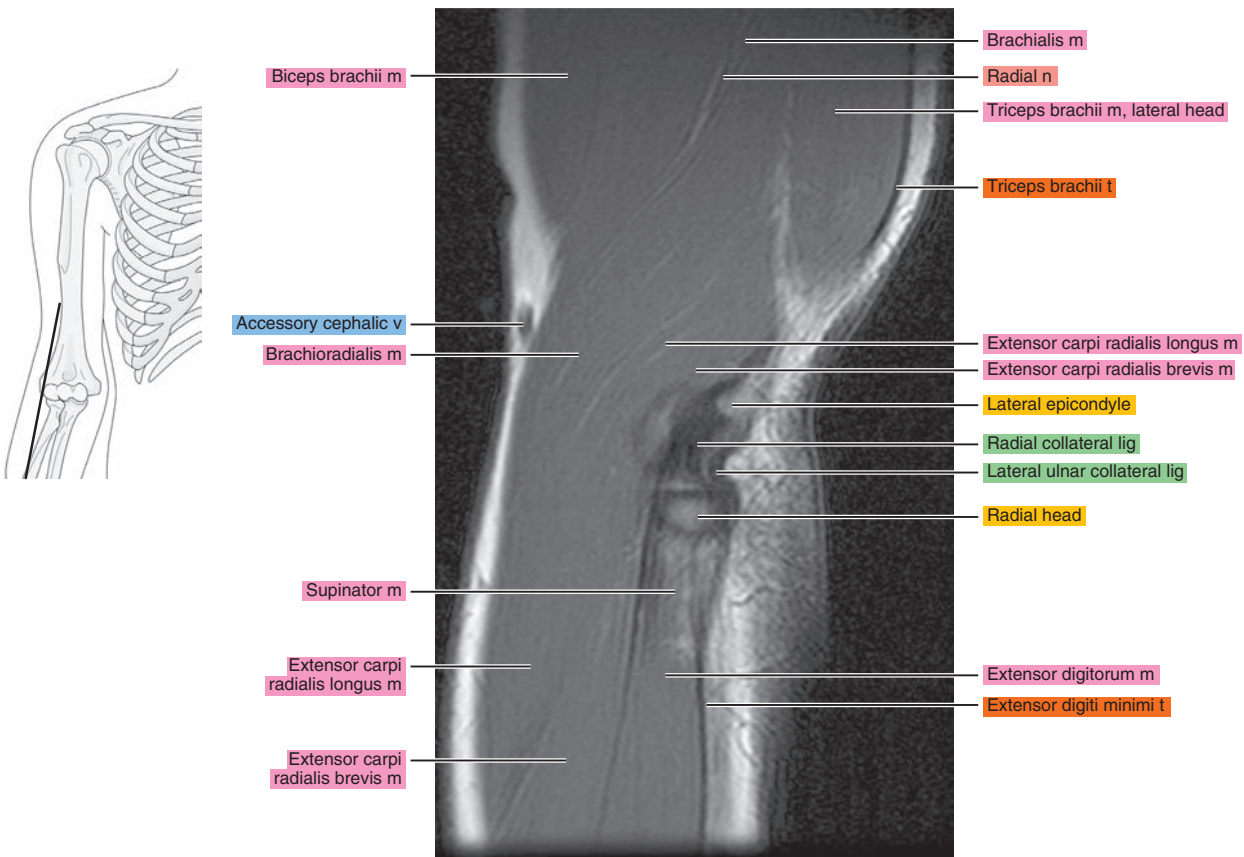


Figure 9.2.4

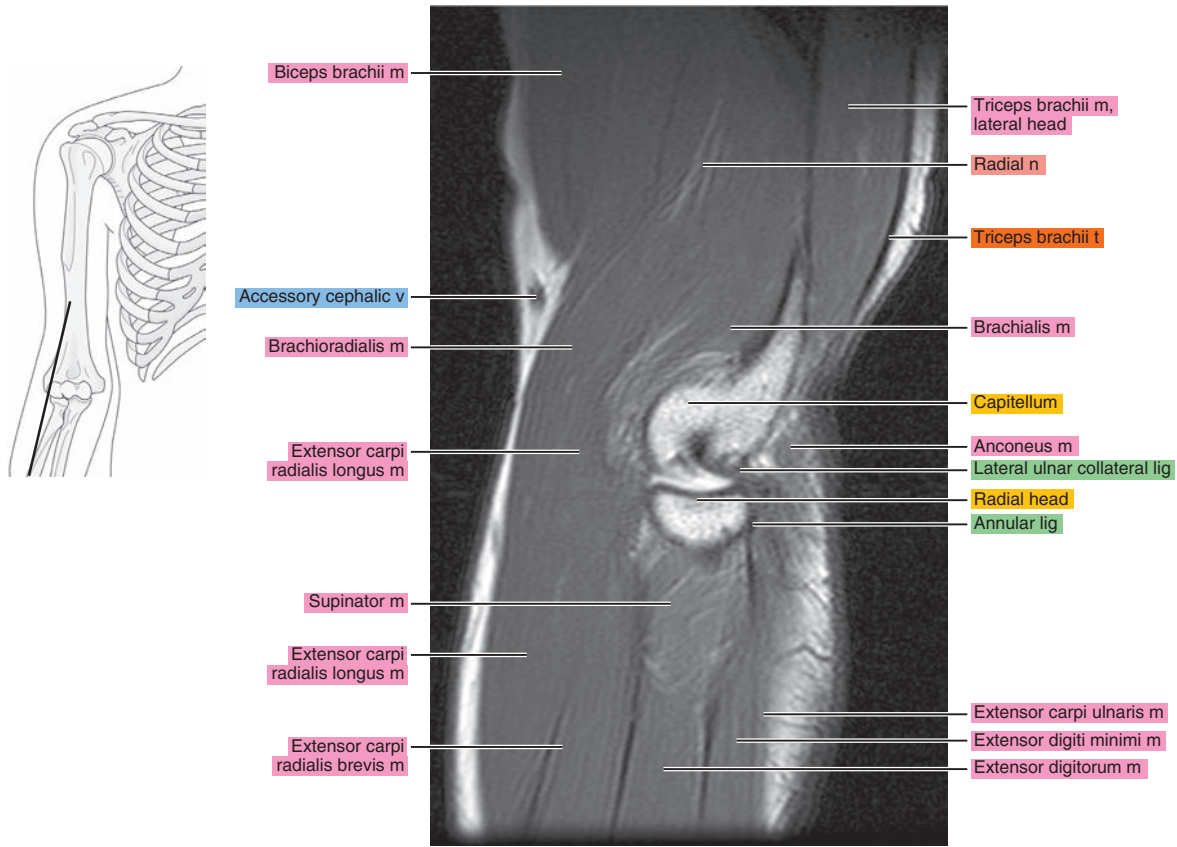


Figure 9.2.5

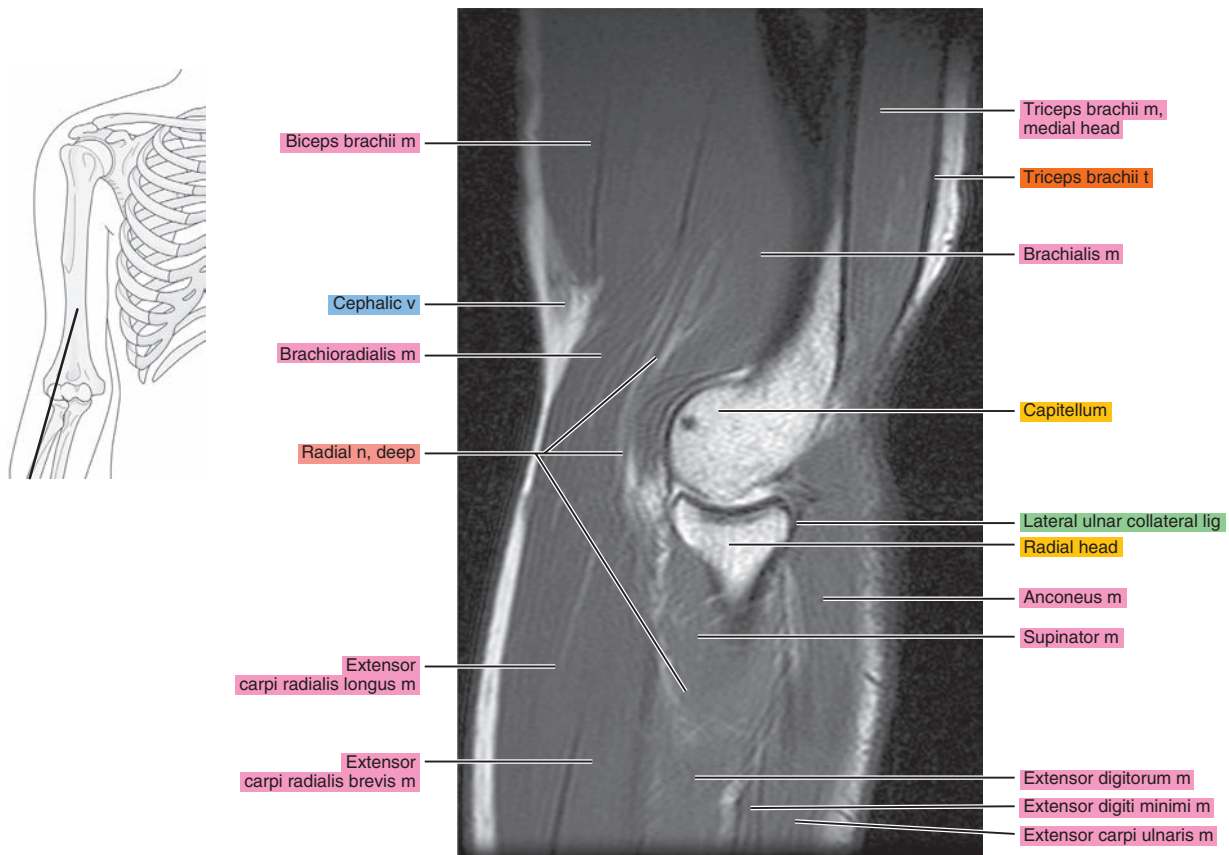


Figure 9.2.6

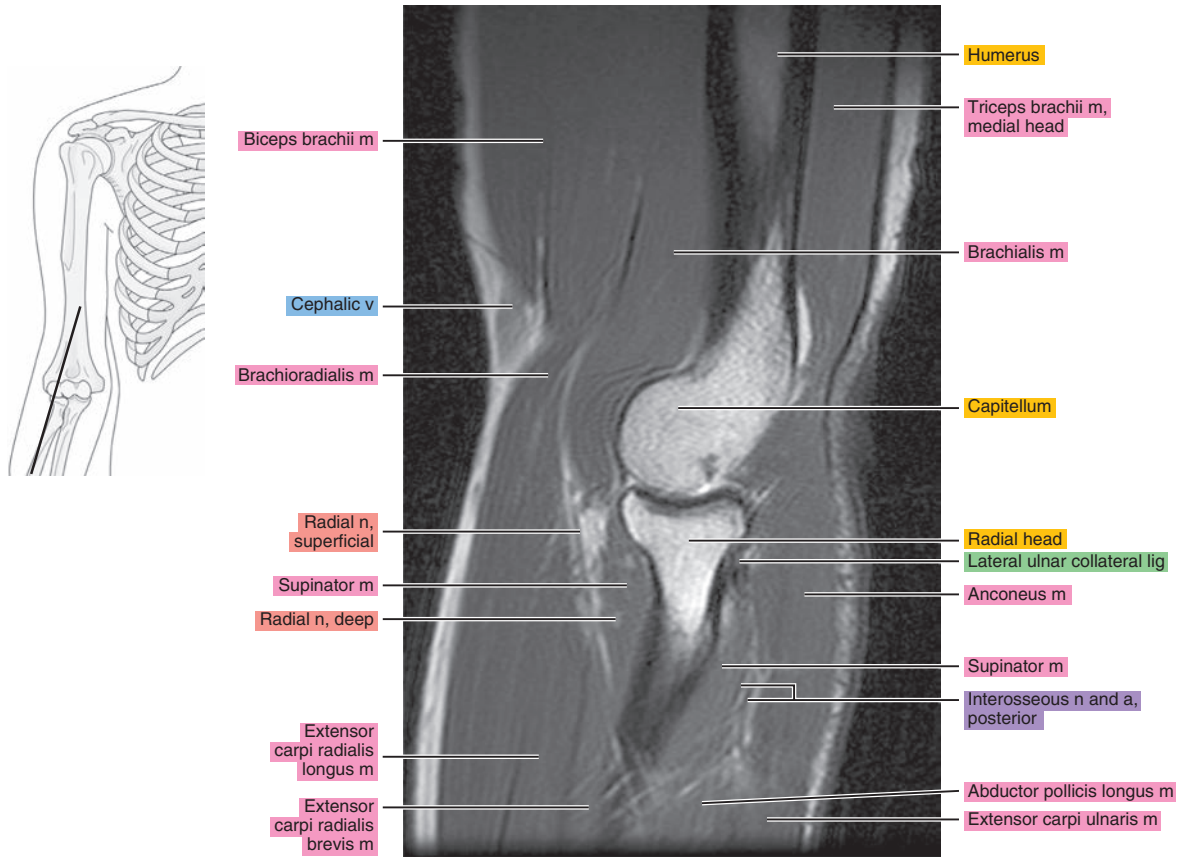


Figure 9.2.7

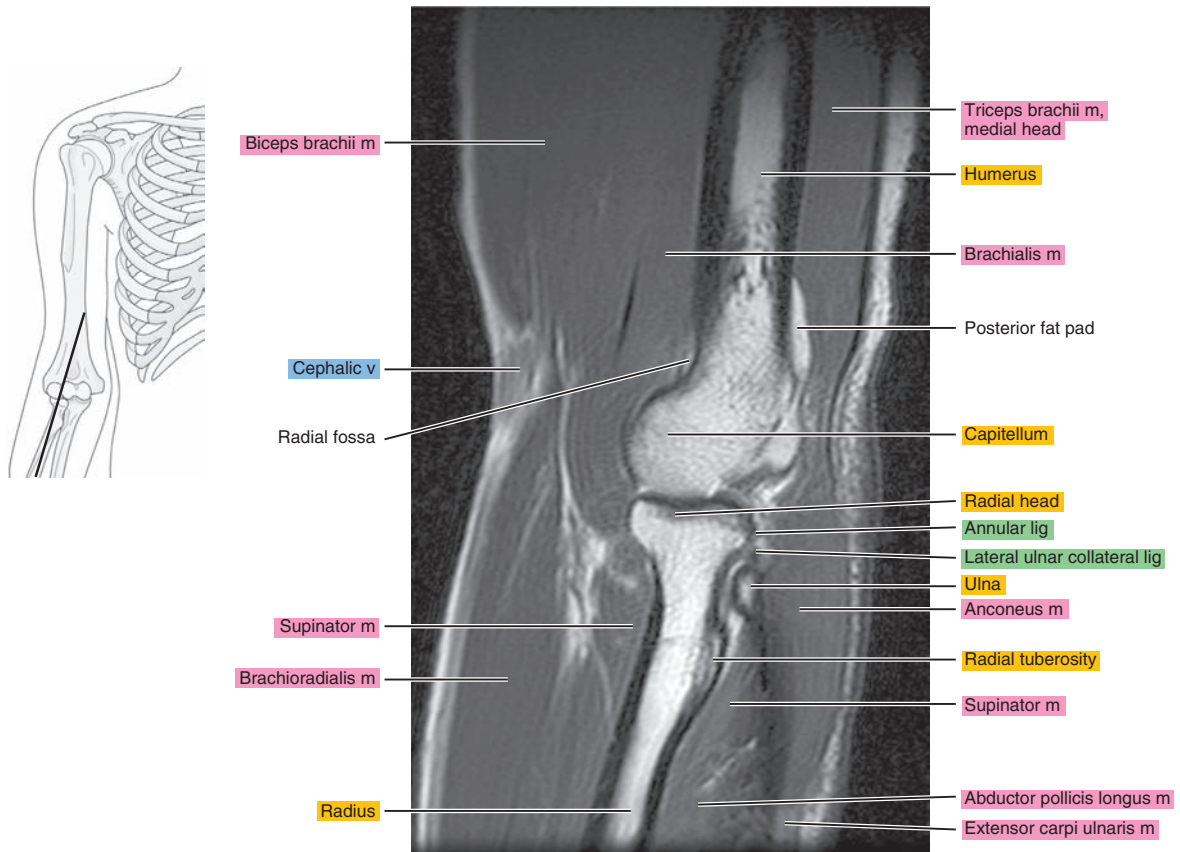




Figure 9.2.8

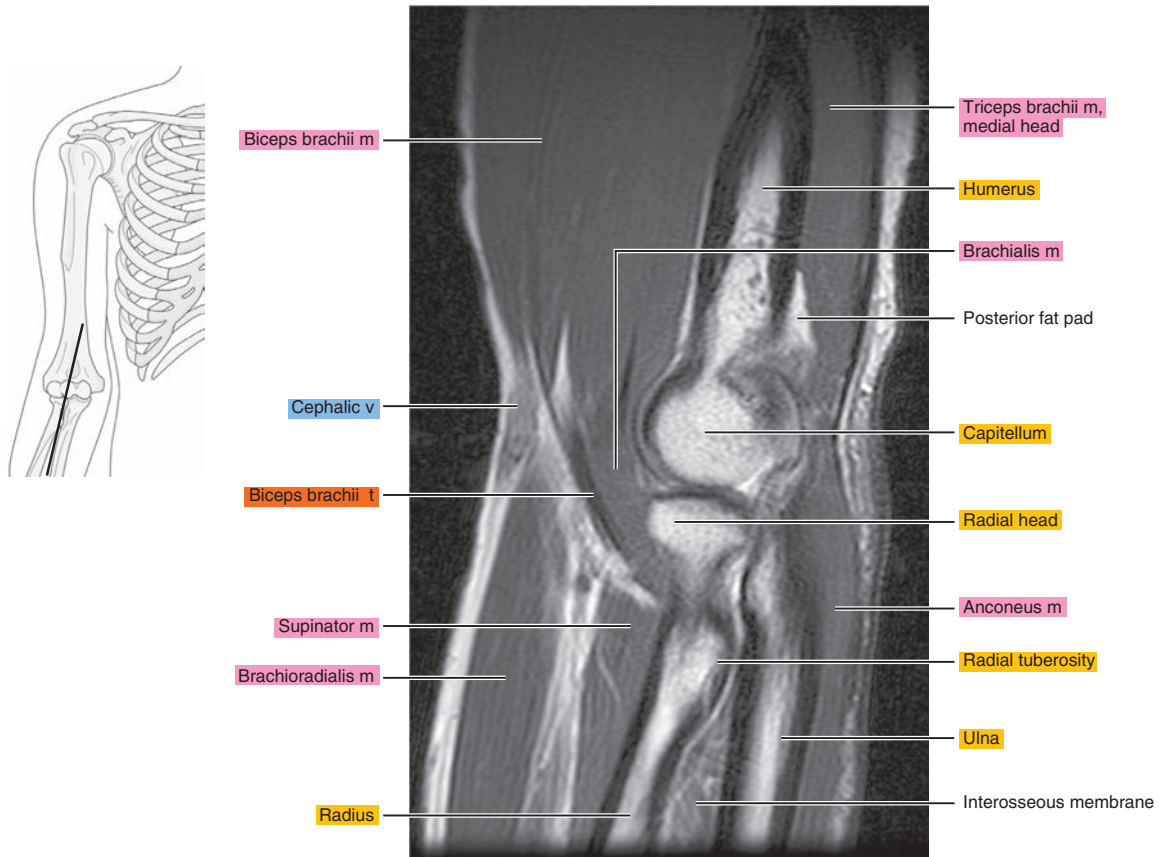


Figure 9.2.9

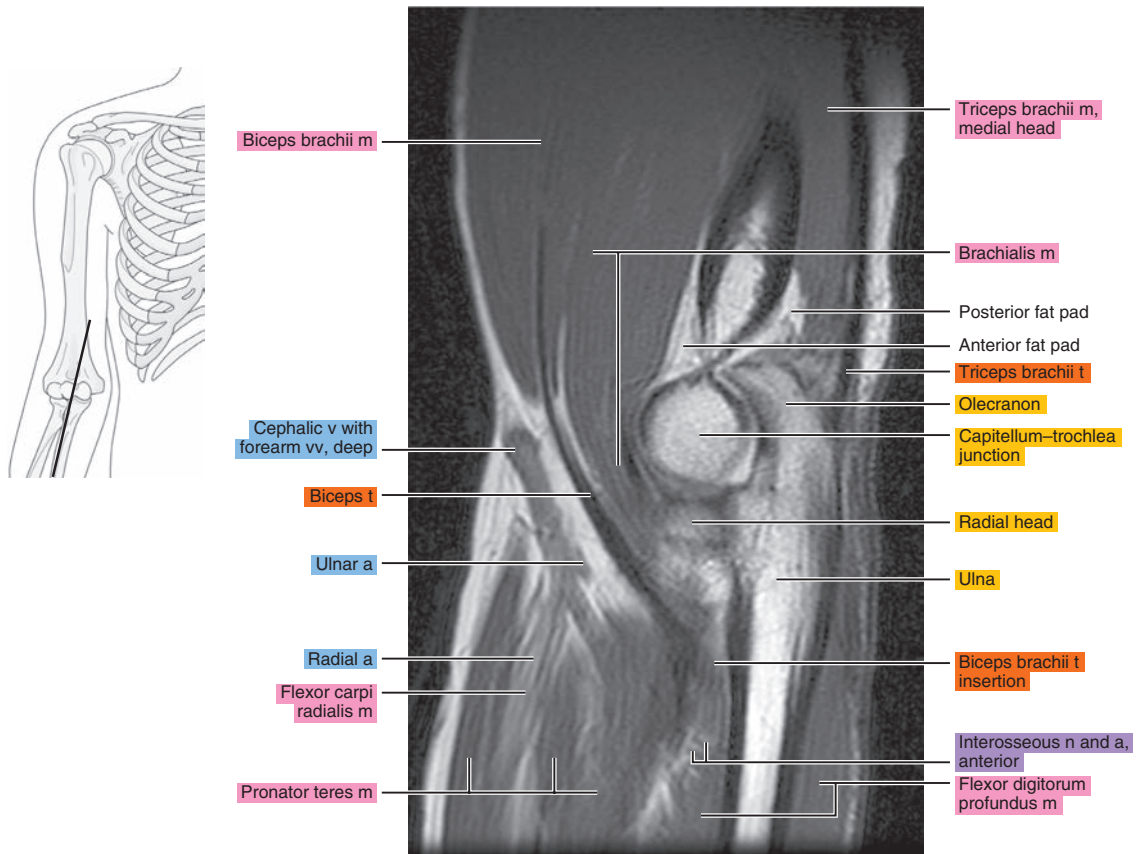




Figure 9.2.10

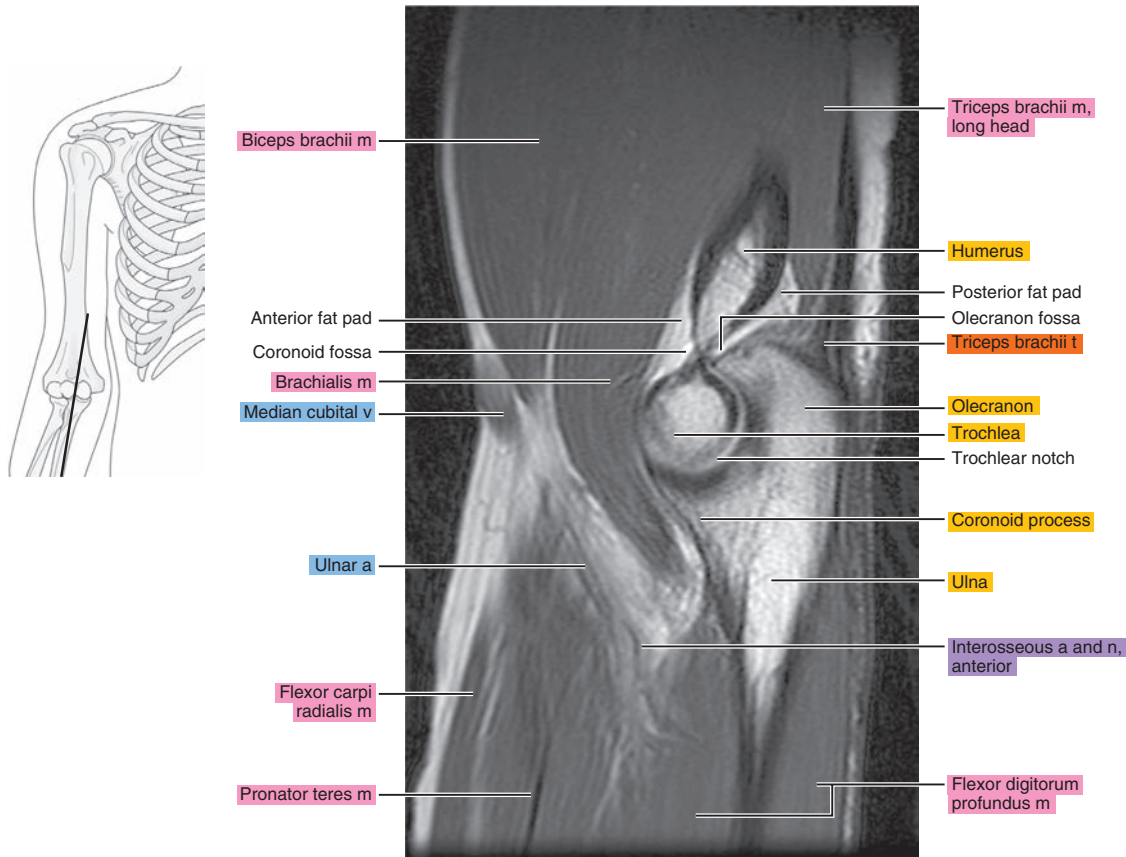


Figure 9.2.11

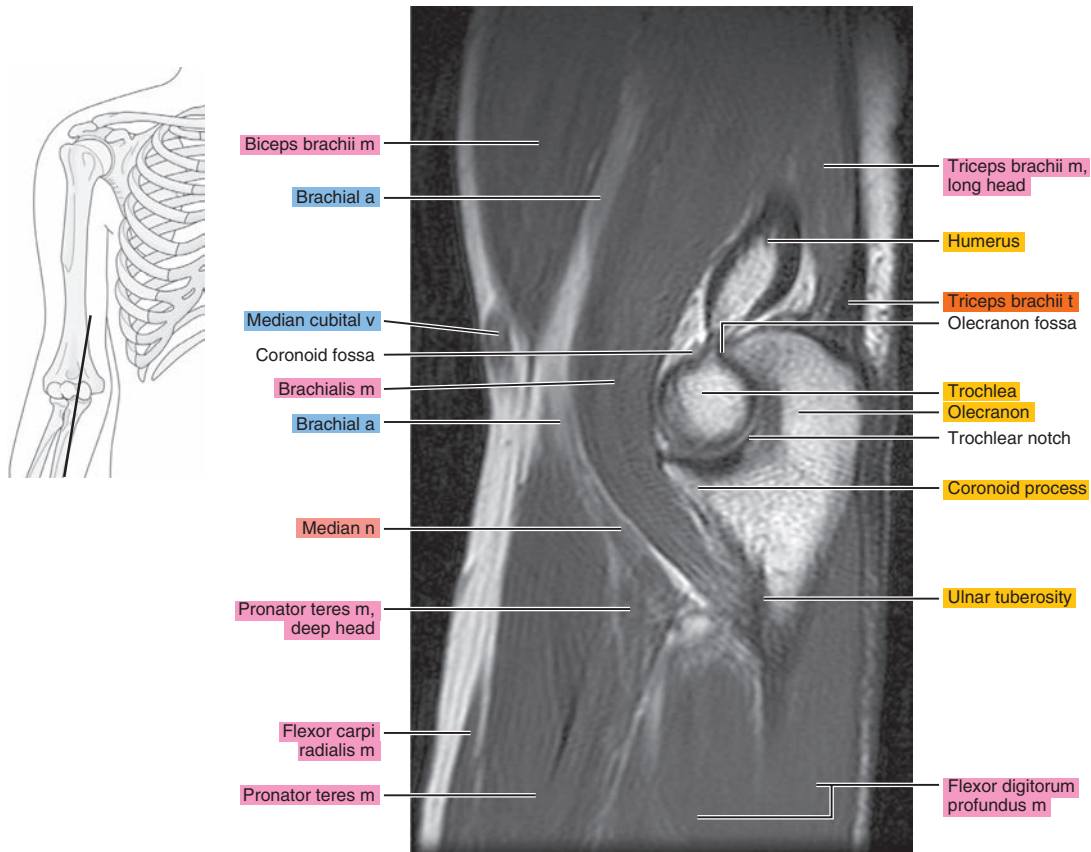


Figure 9.2.12

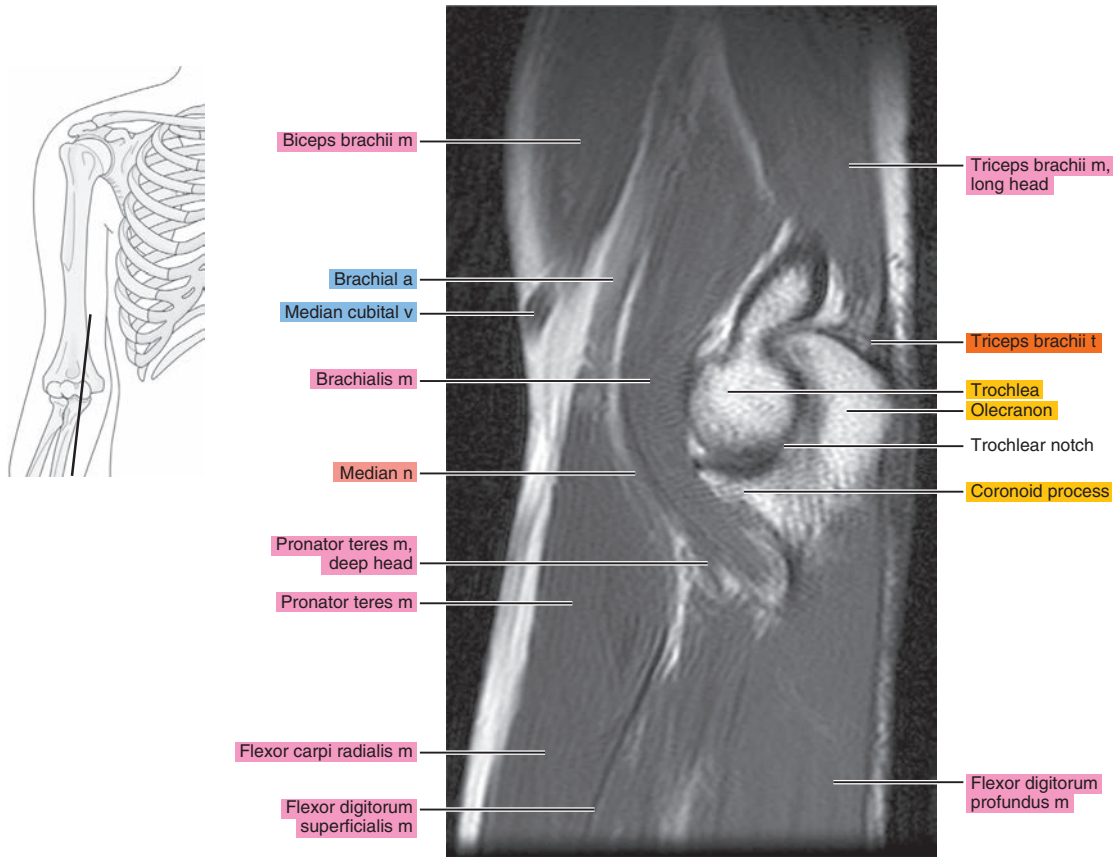


Figure 9.2.13

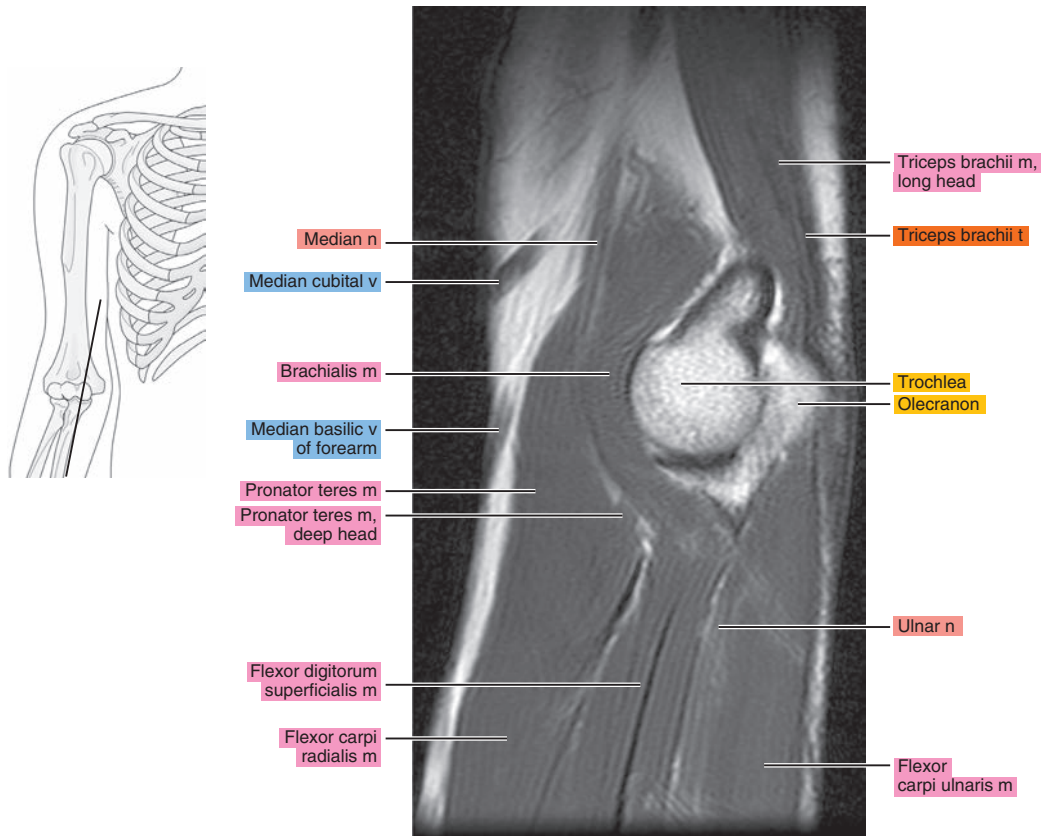


Figure 9.2.14

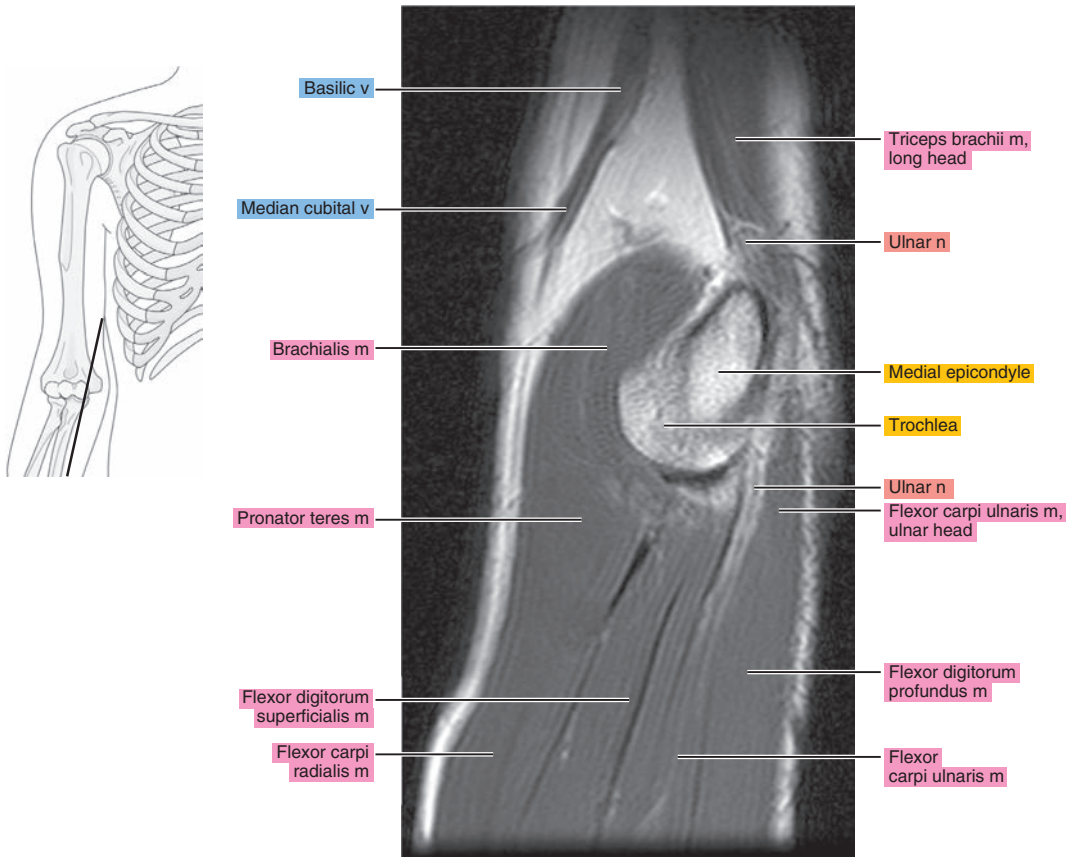


Figure 9.2.15

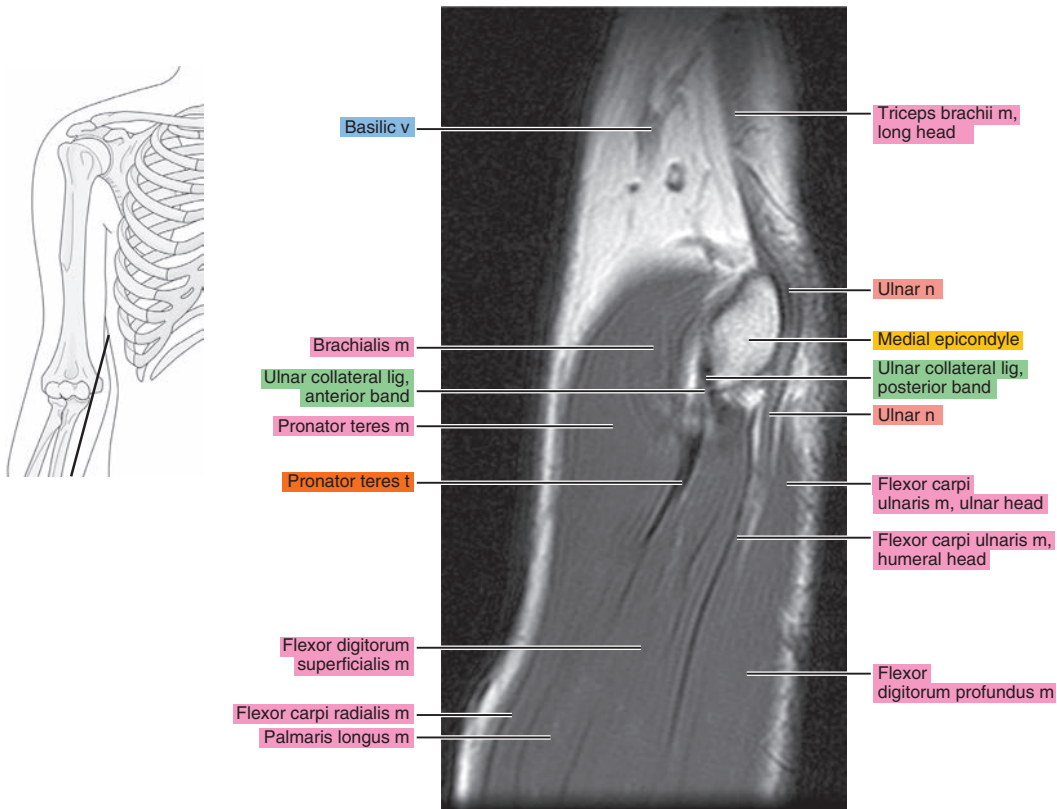


Figure 9.2.16

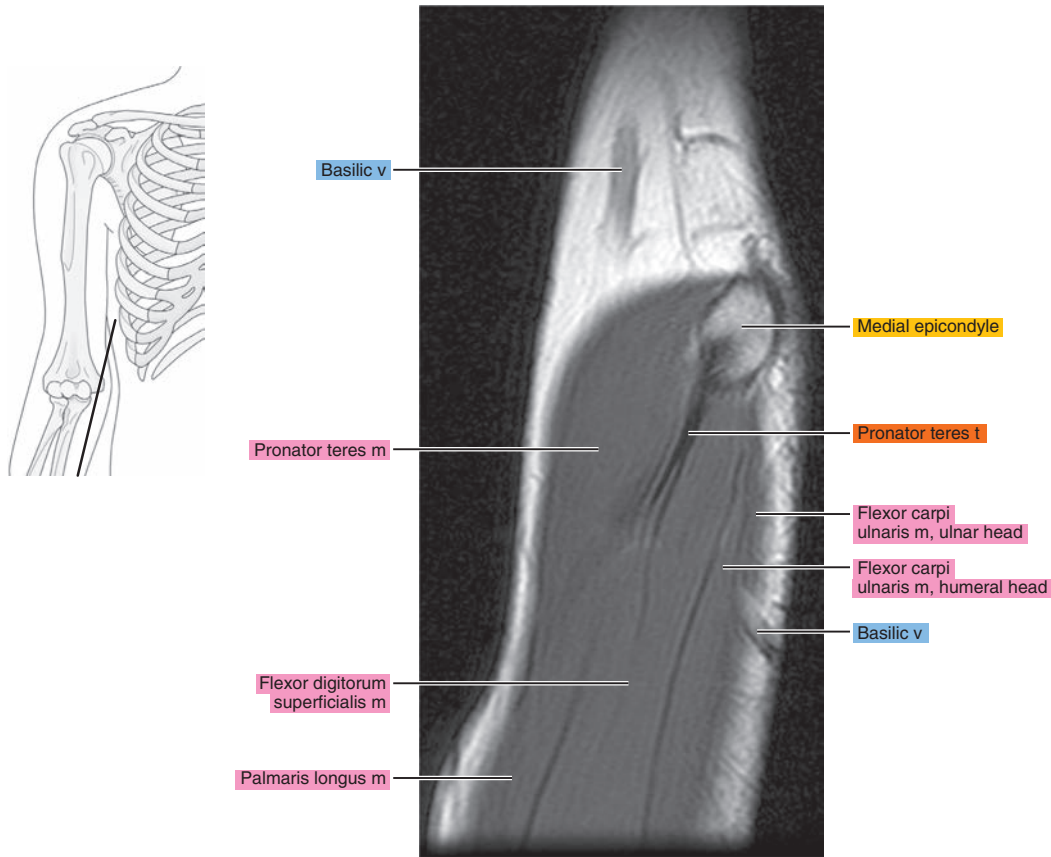
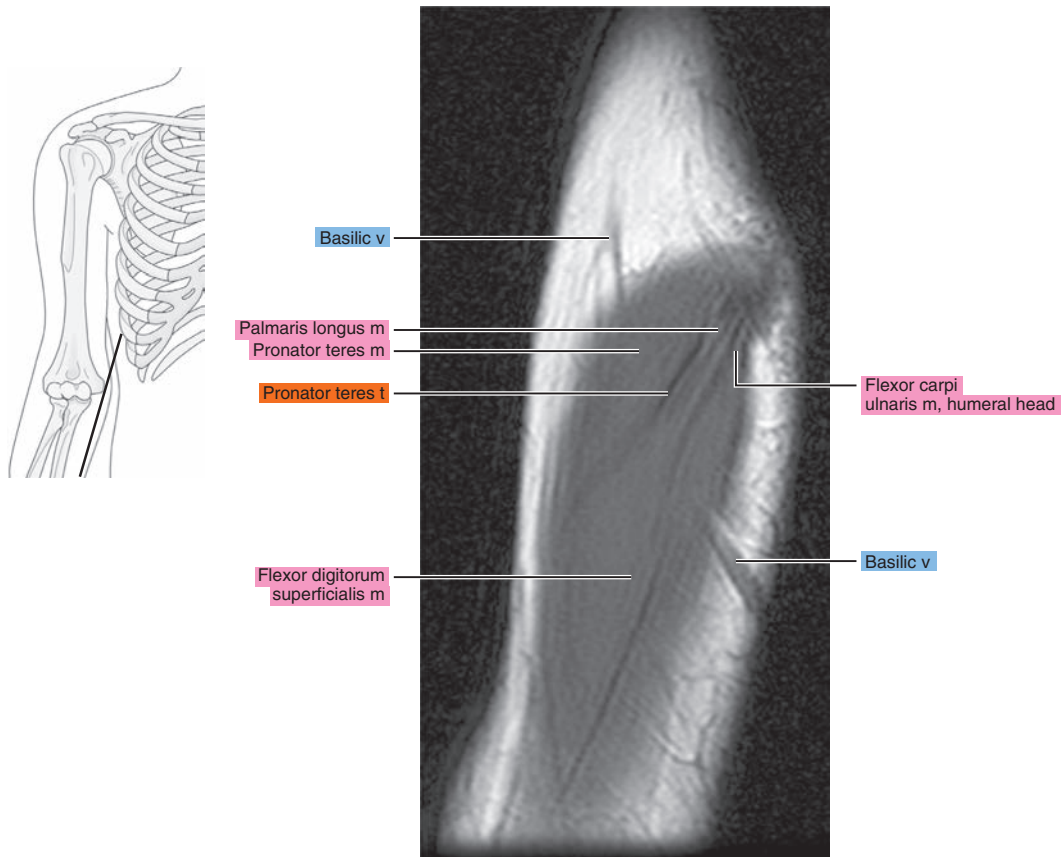


Figure 9.2.17





# OBLIQUE CORONAL

Figure 9.3.1

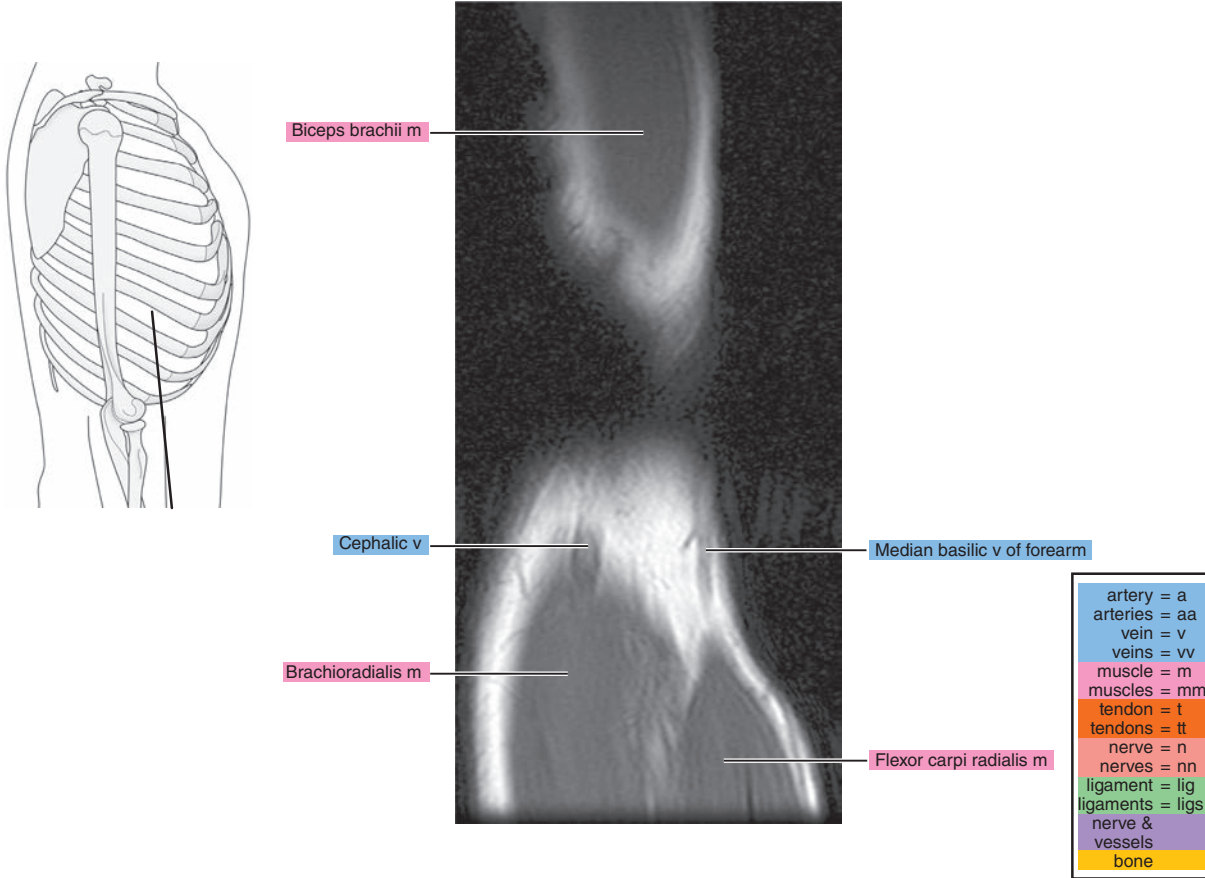


Figure 9.3.2

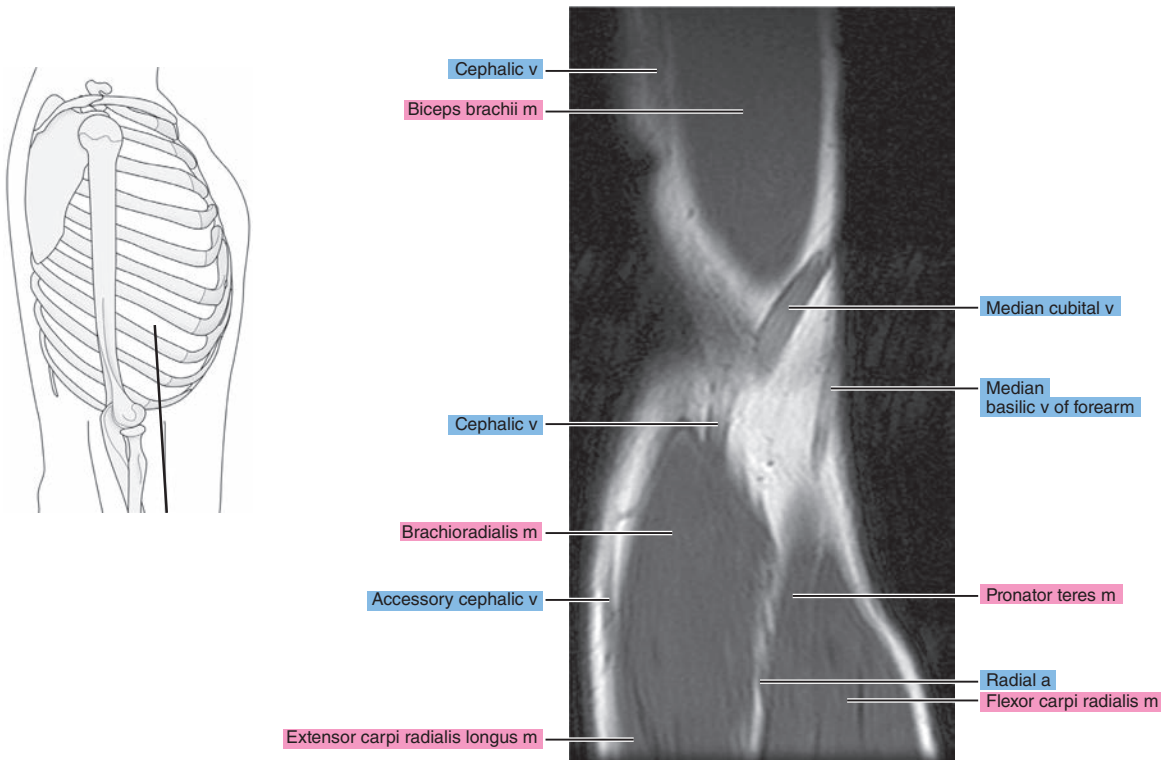


Figure 9.3.3

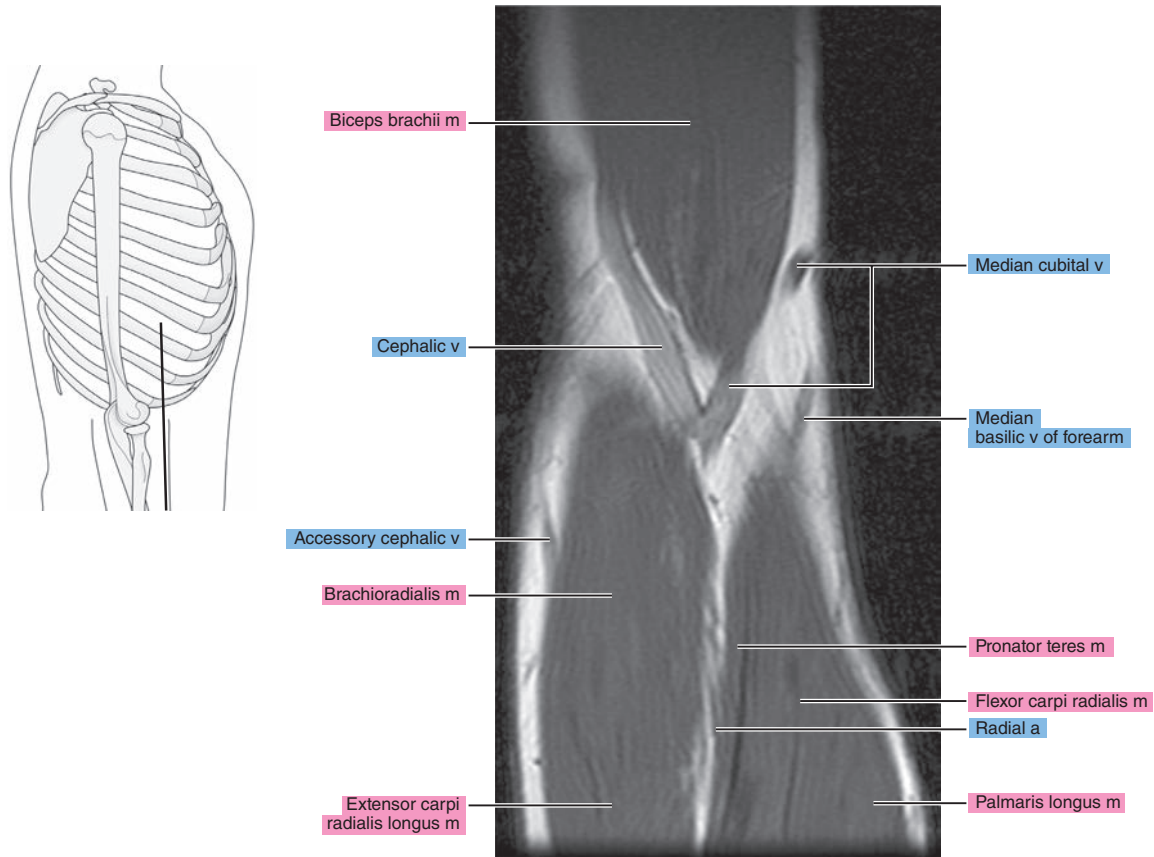


Figure 9.3.4

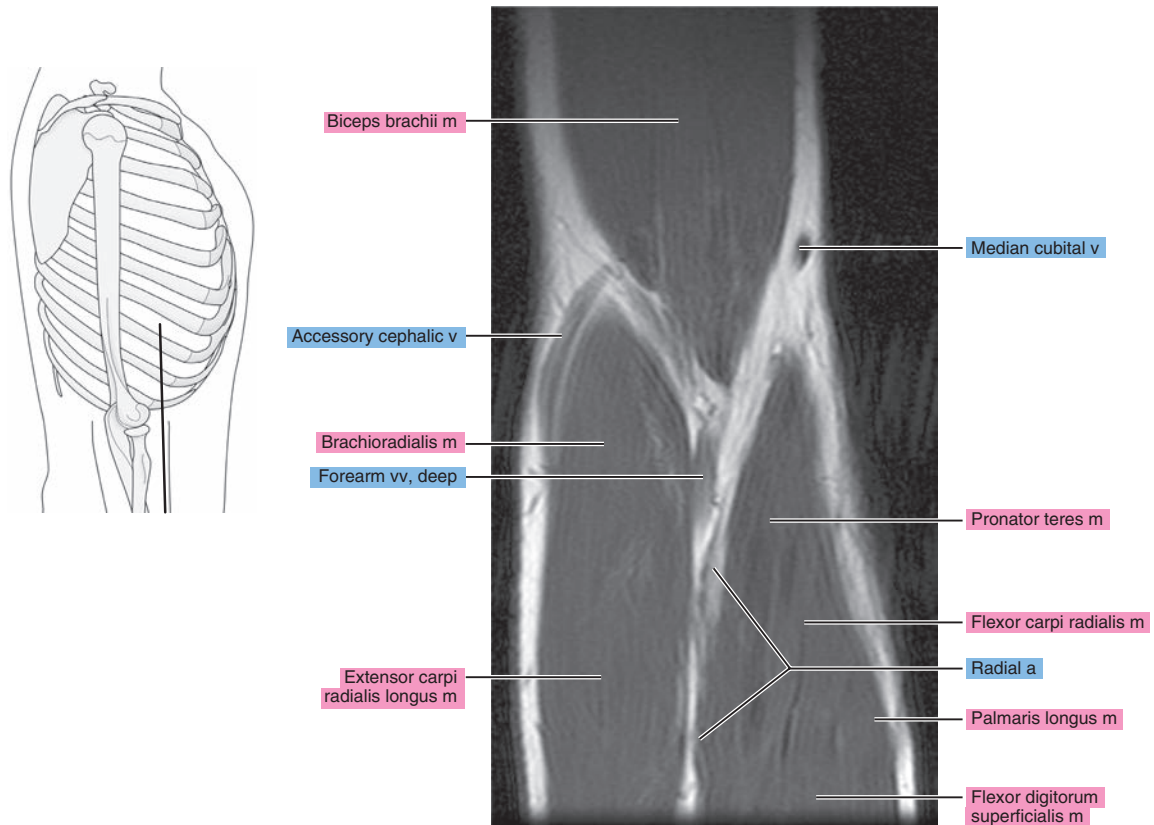


Figure 9.3.5

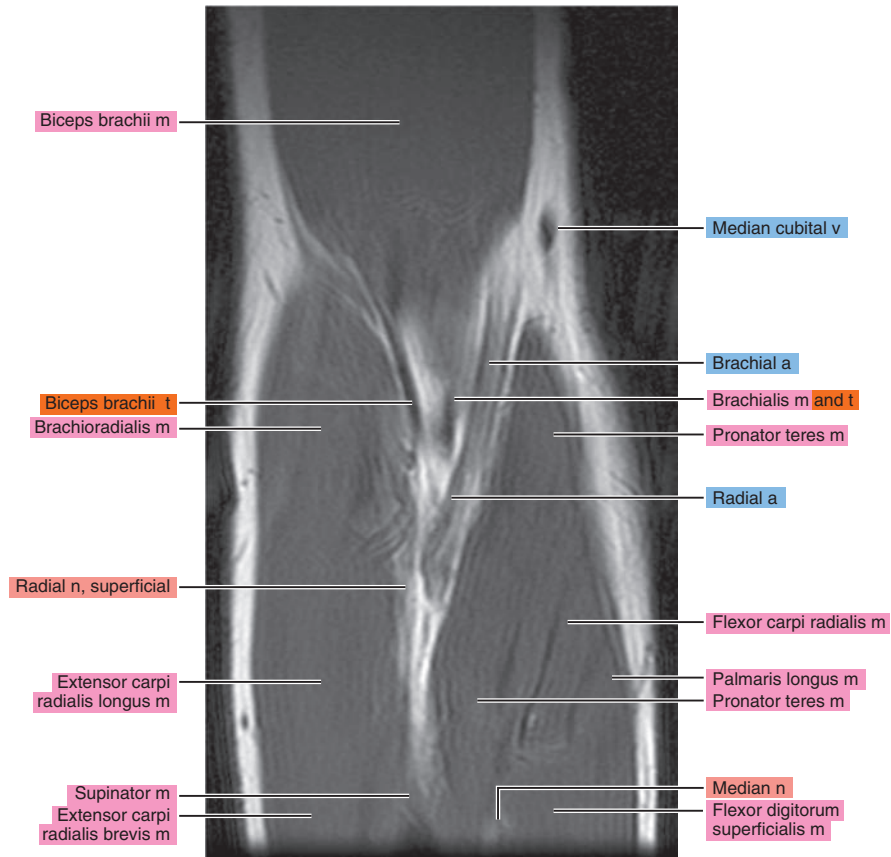
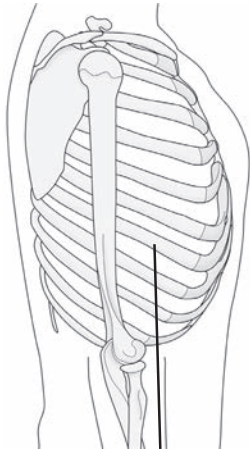


Figure 9.3.6

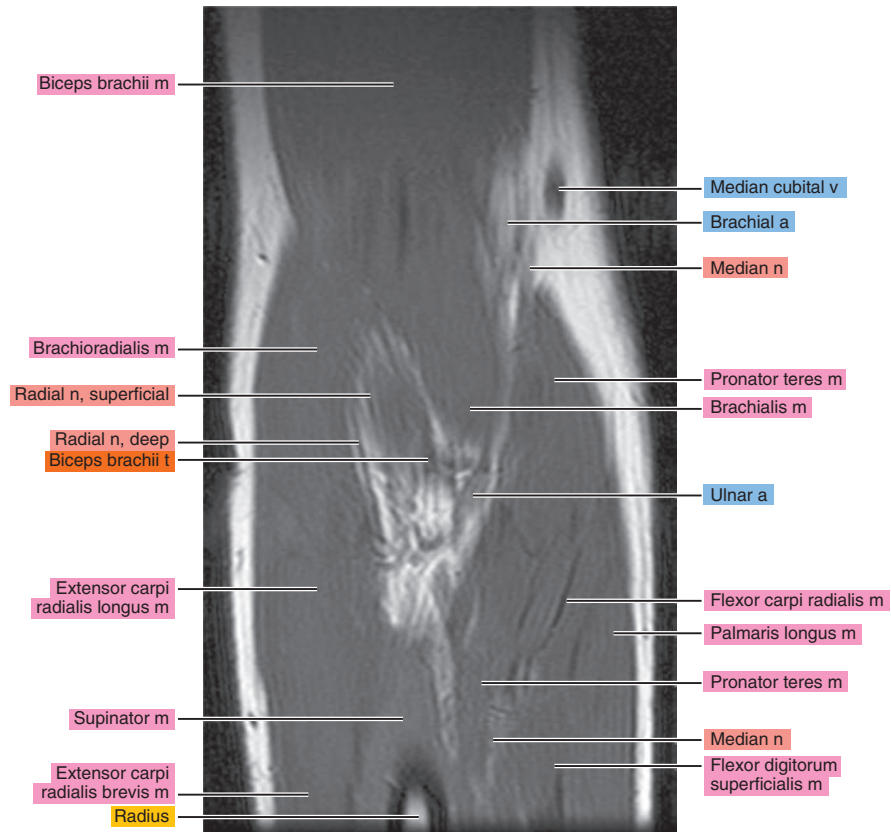
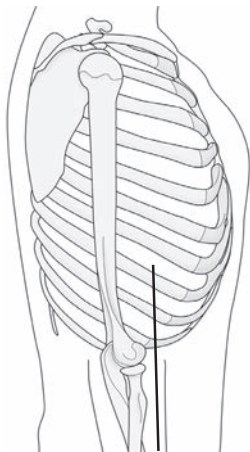




Figure 9.3.7

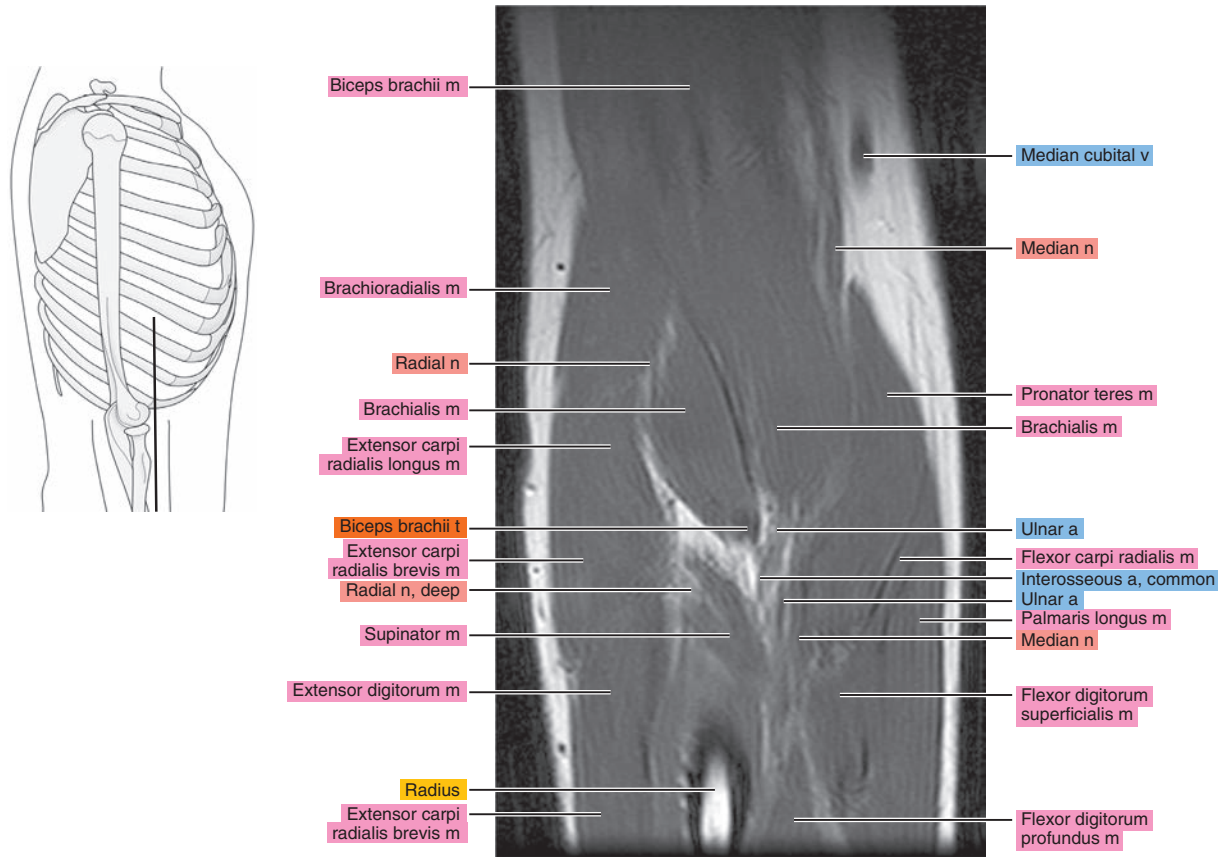


Figure 9.3.8

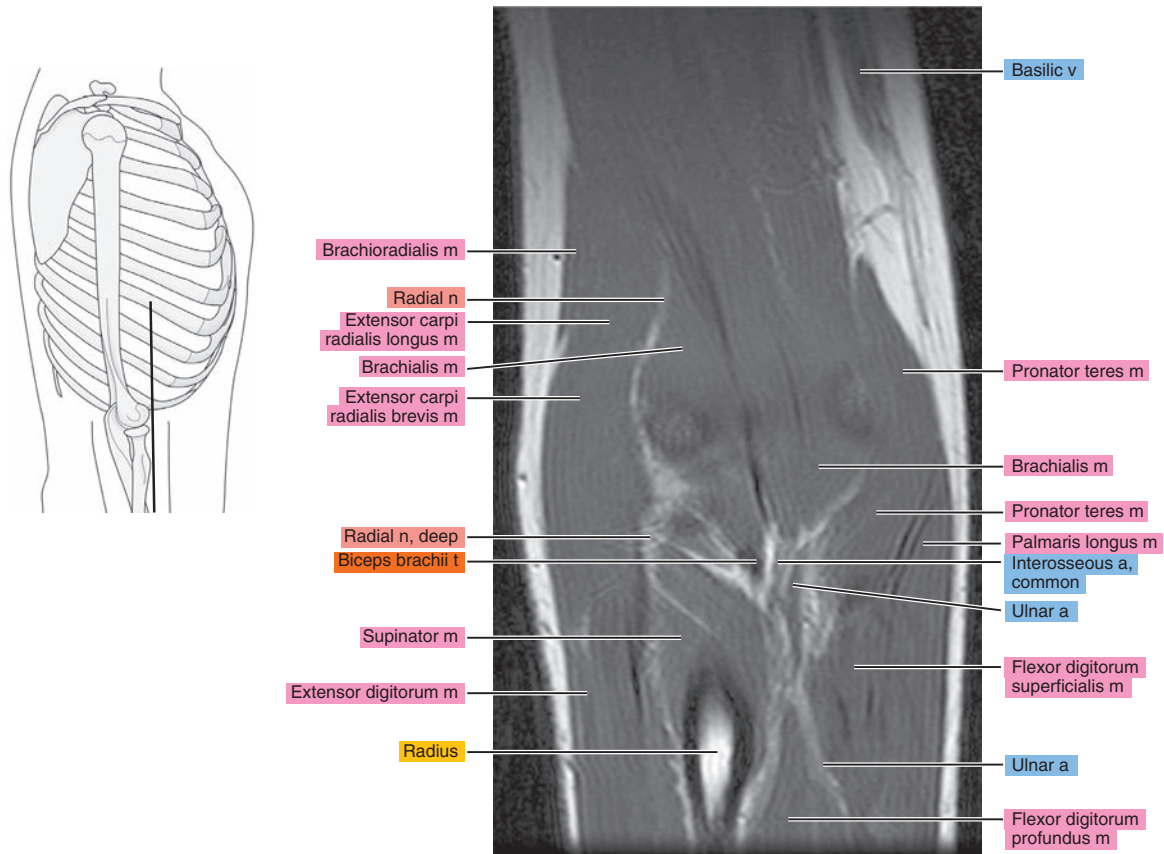




Figure 9.3.9

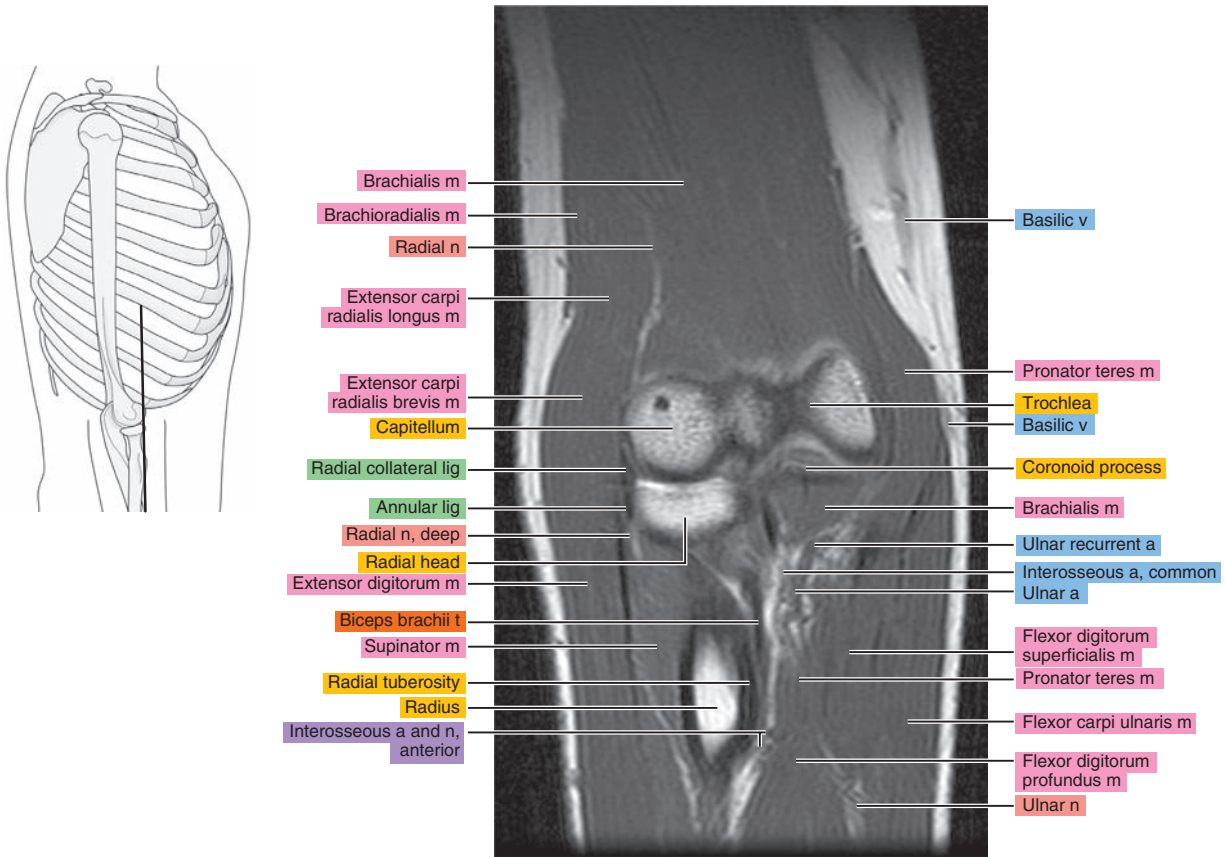


Figure 9.3.10

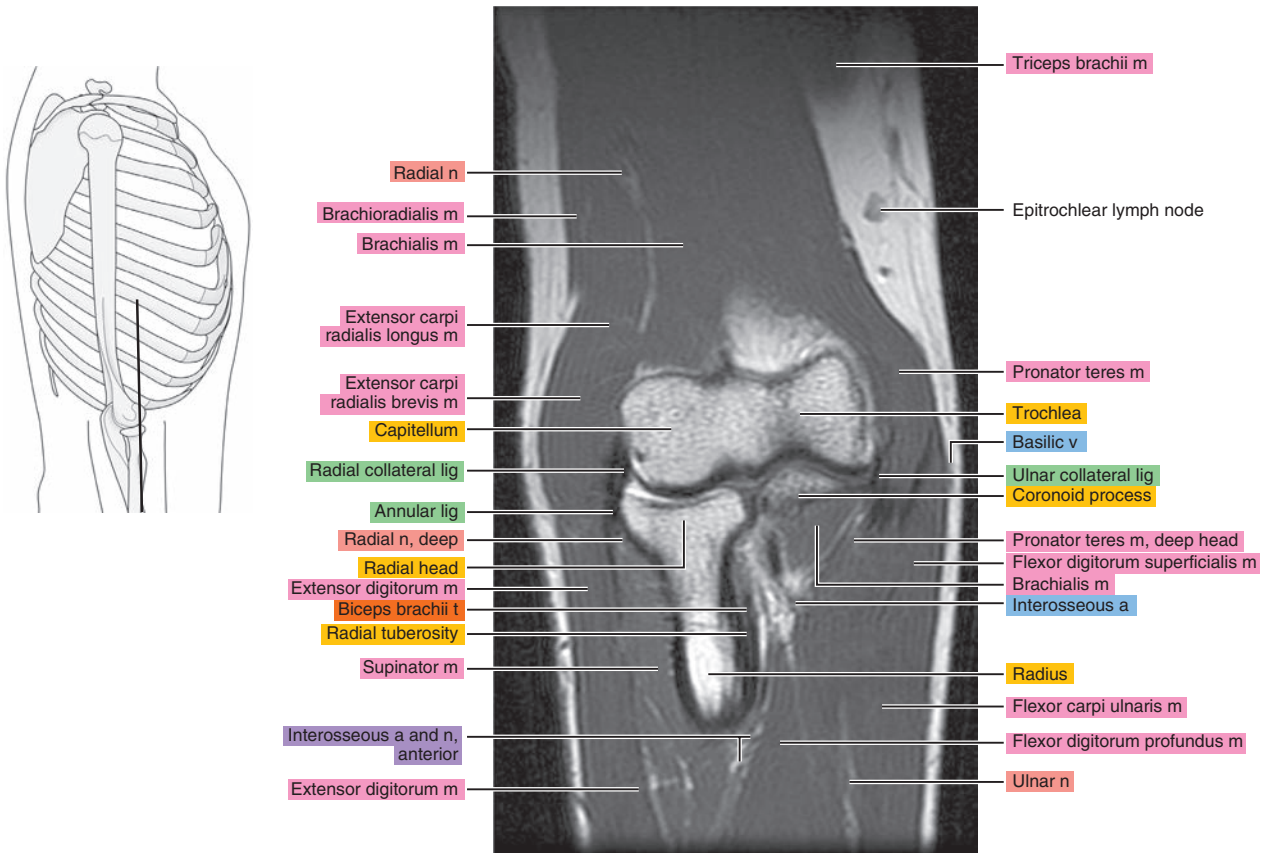


Figure 9.3.11

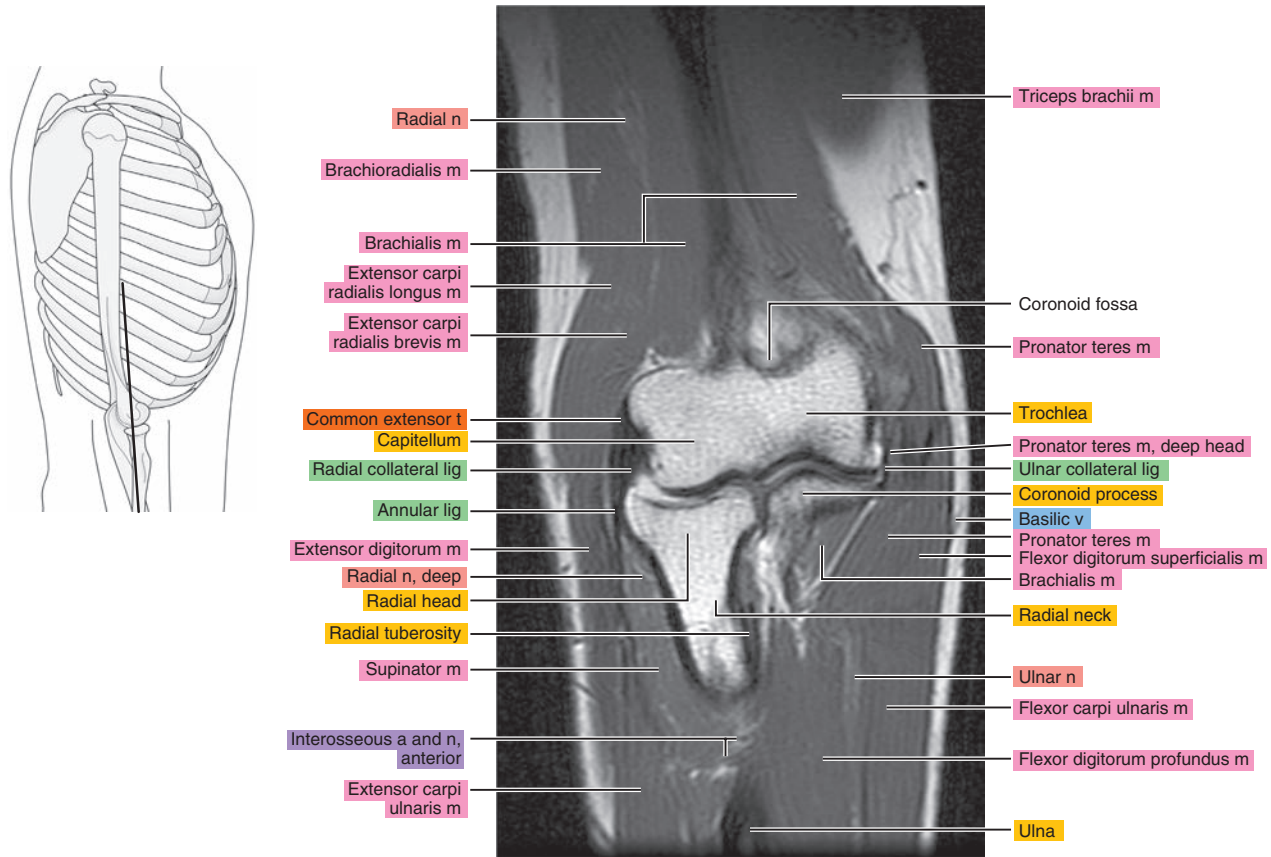


Figure 9.3.12

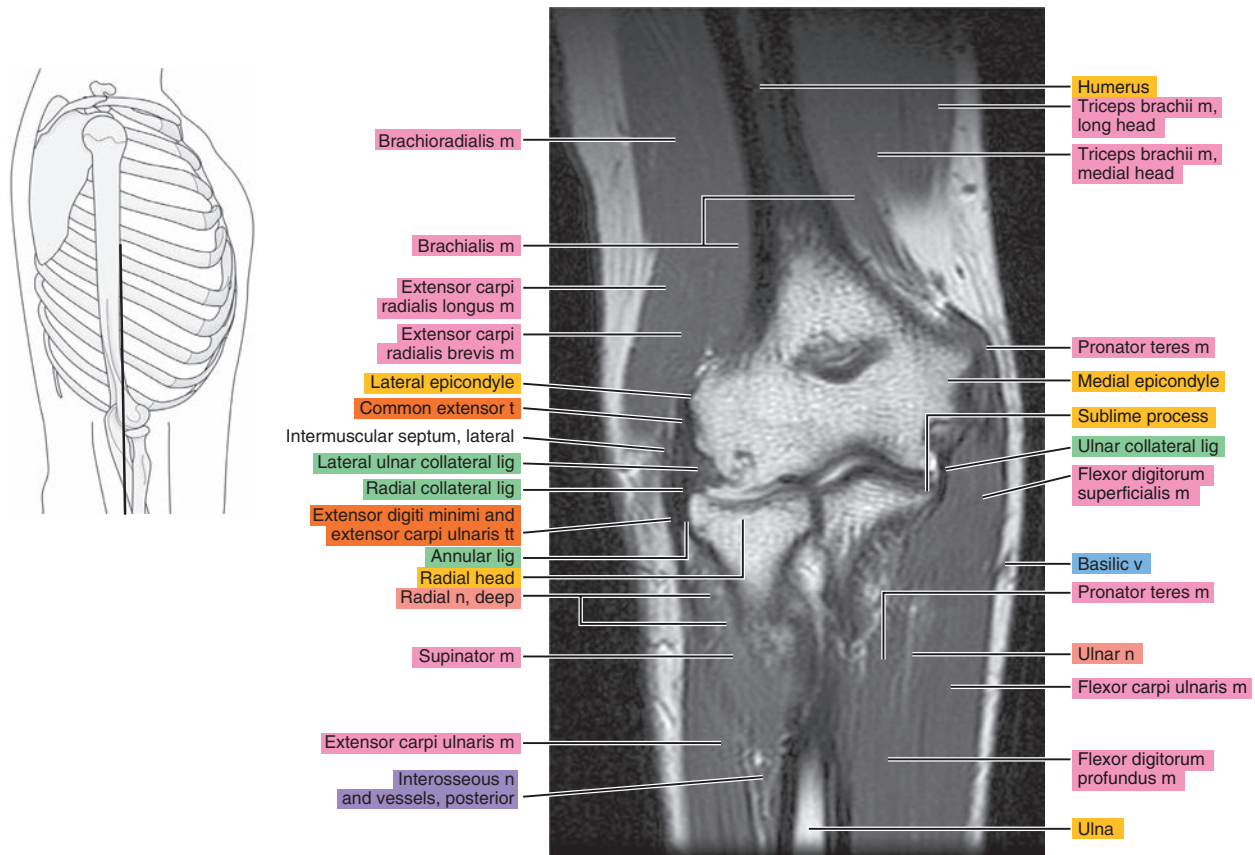


Figure 9.3.13

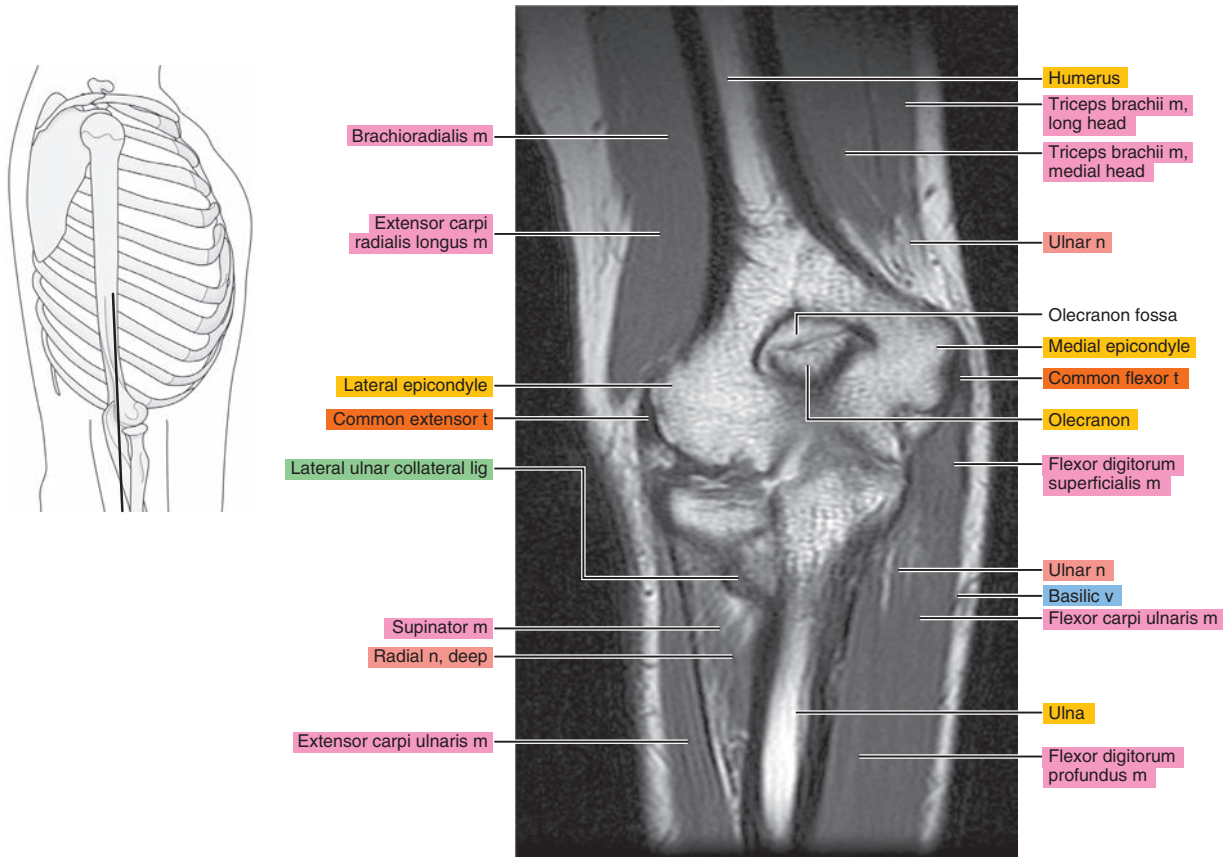


Figure 9.3.14

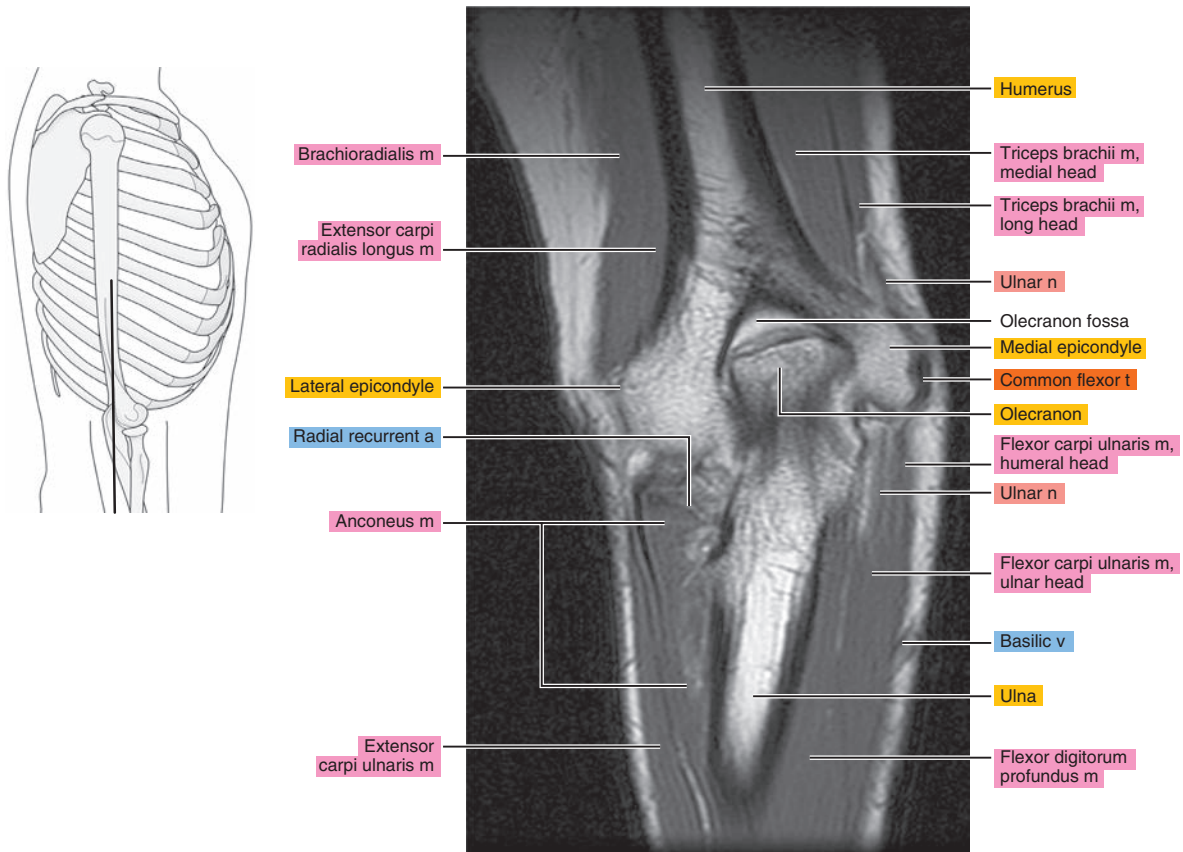




Figure 9.3.15

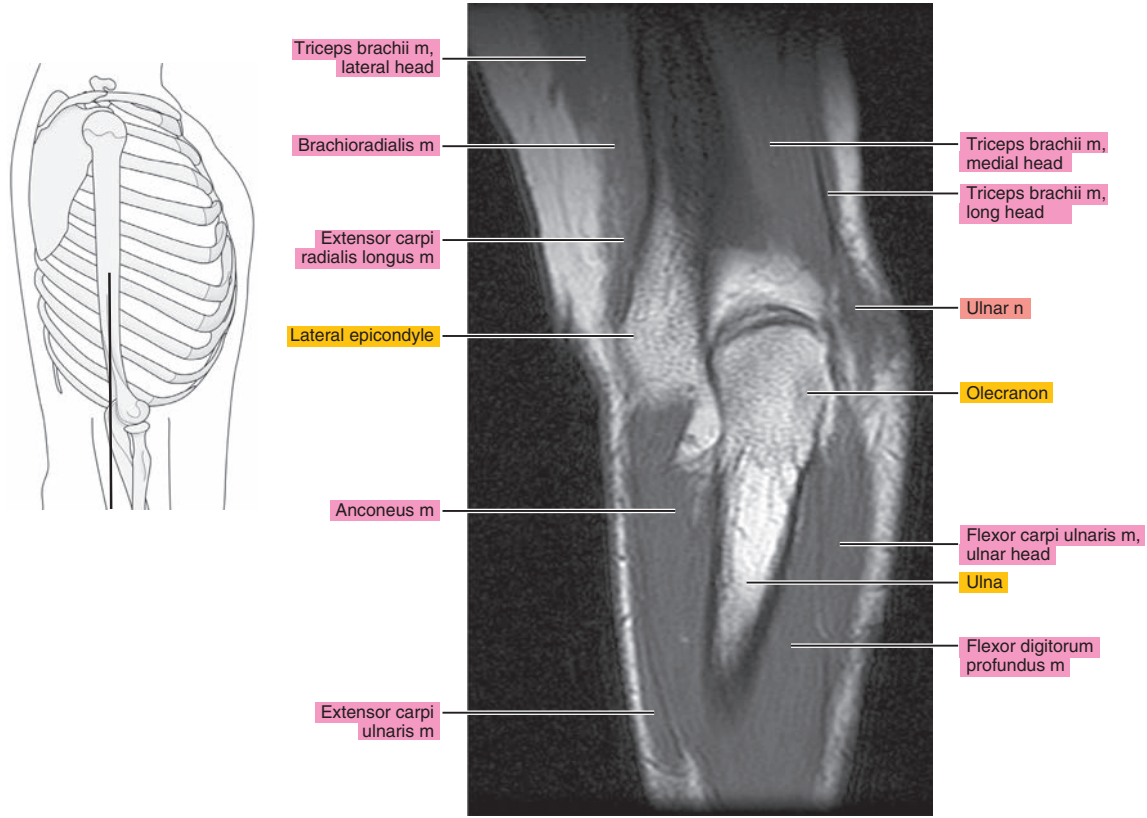


Figure 9.3.16

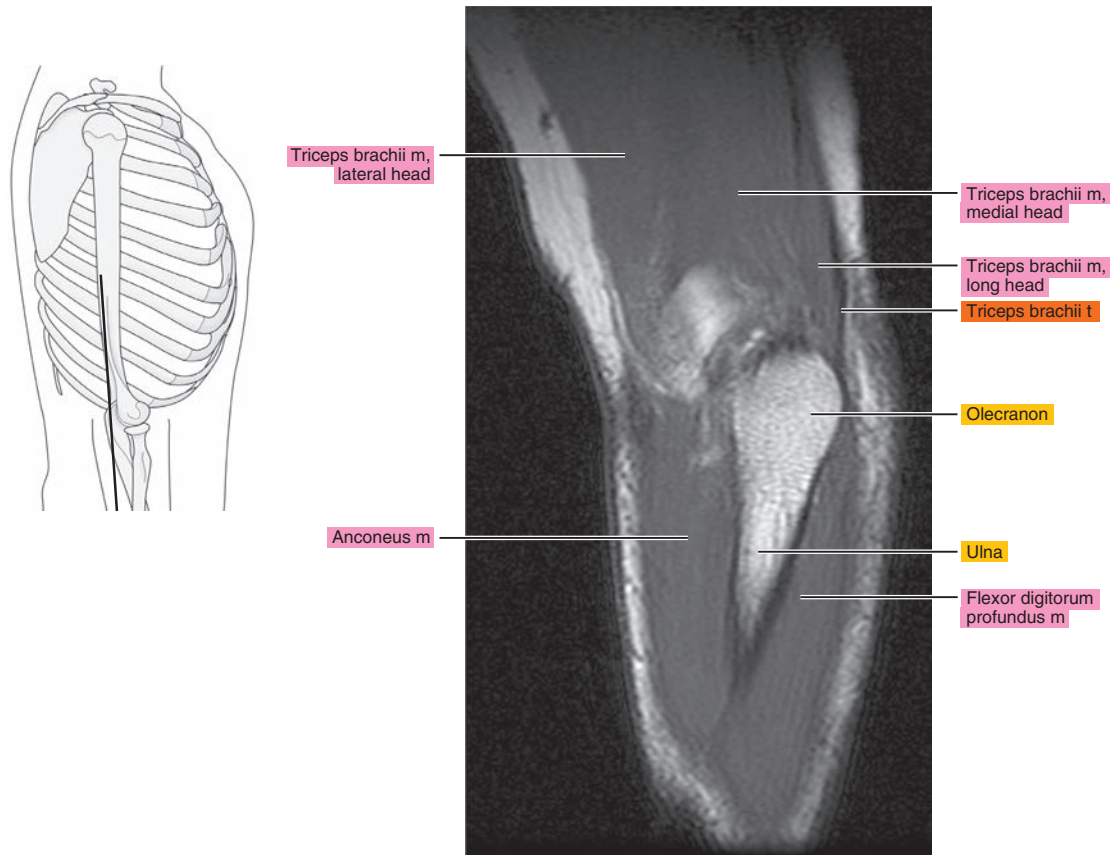
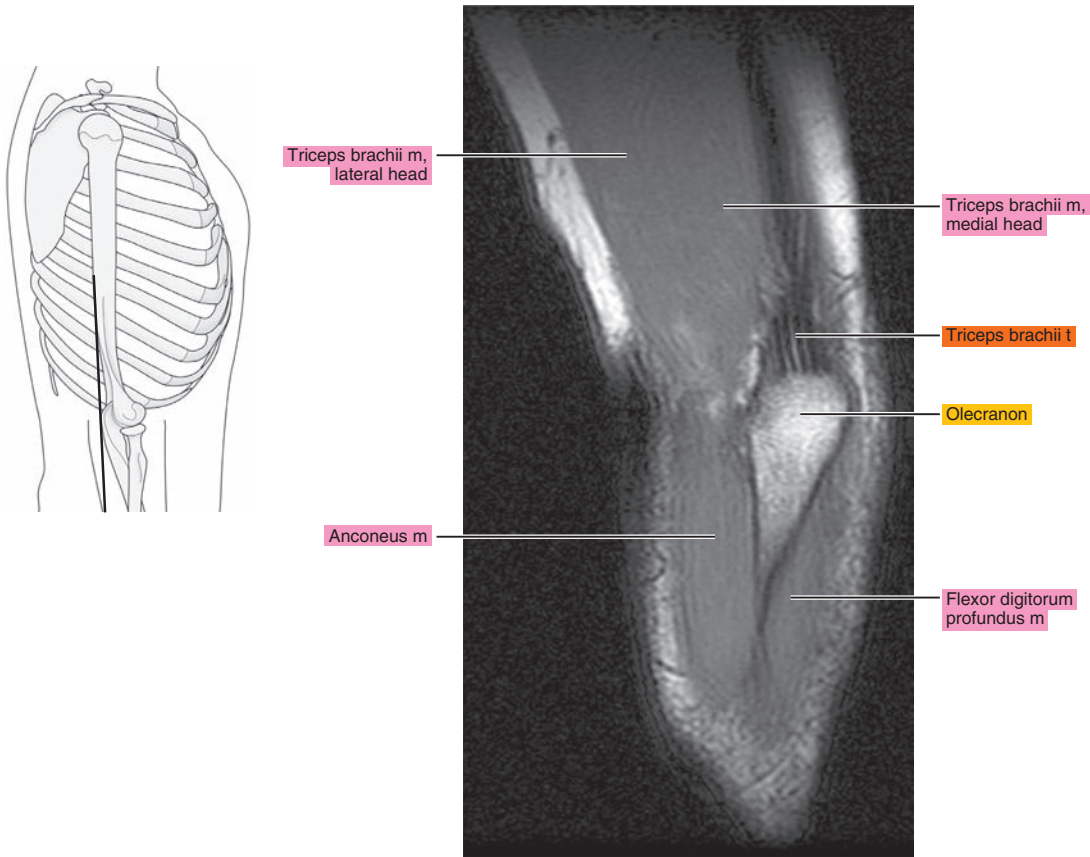




Figure 9.3.17



*Chapter*  
**10**

**MRI of the Forearm**

# AXIAL

Figure 10.1.1

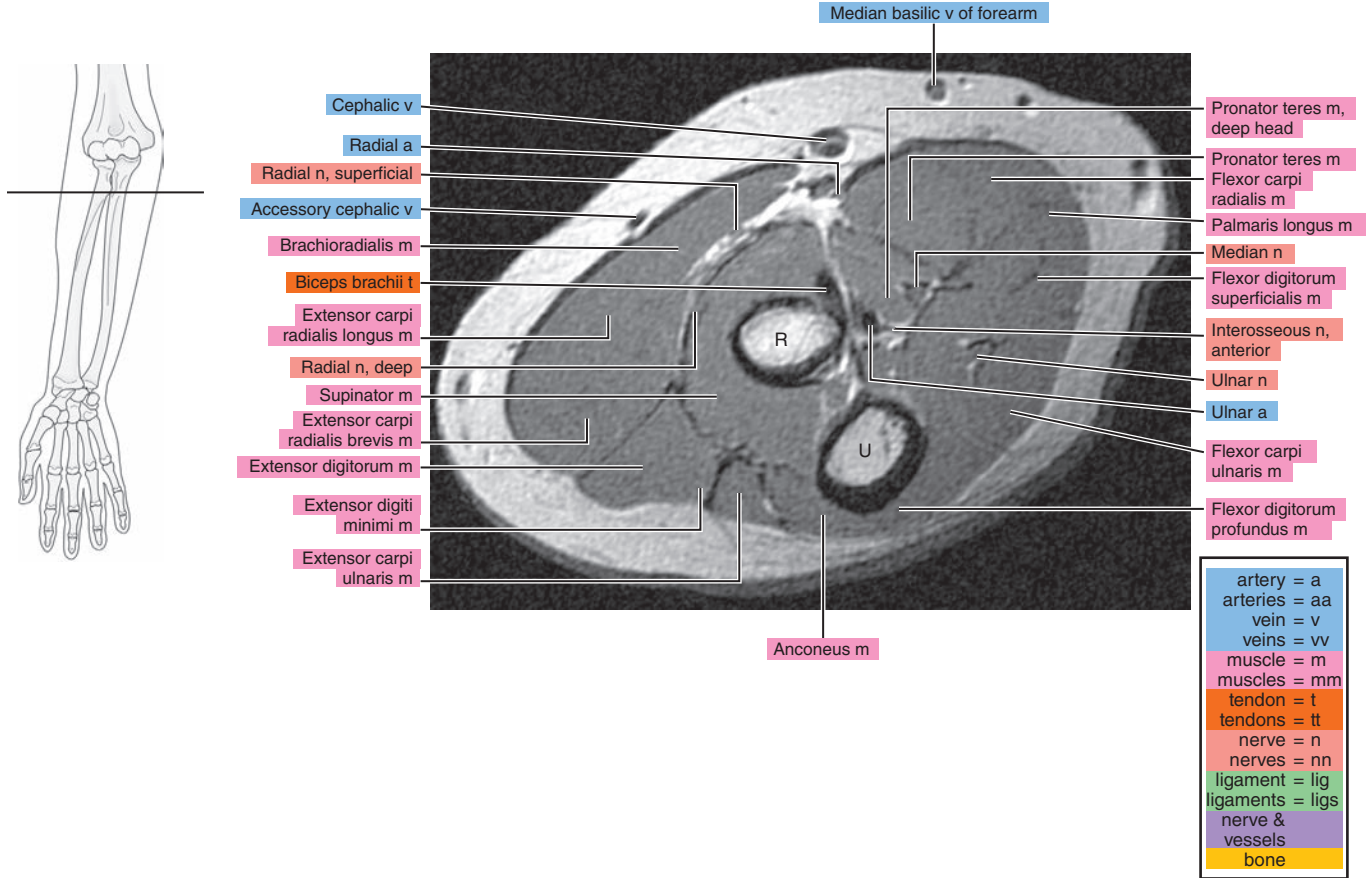


Figure 10.1.2

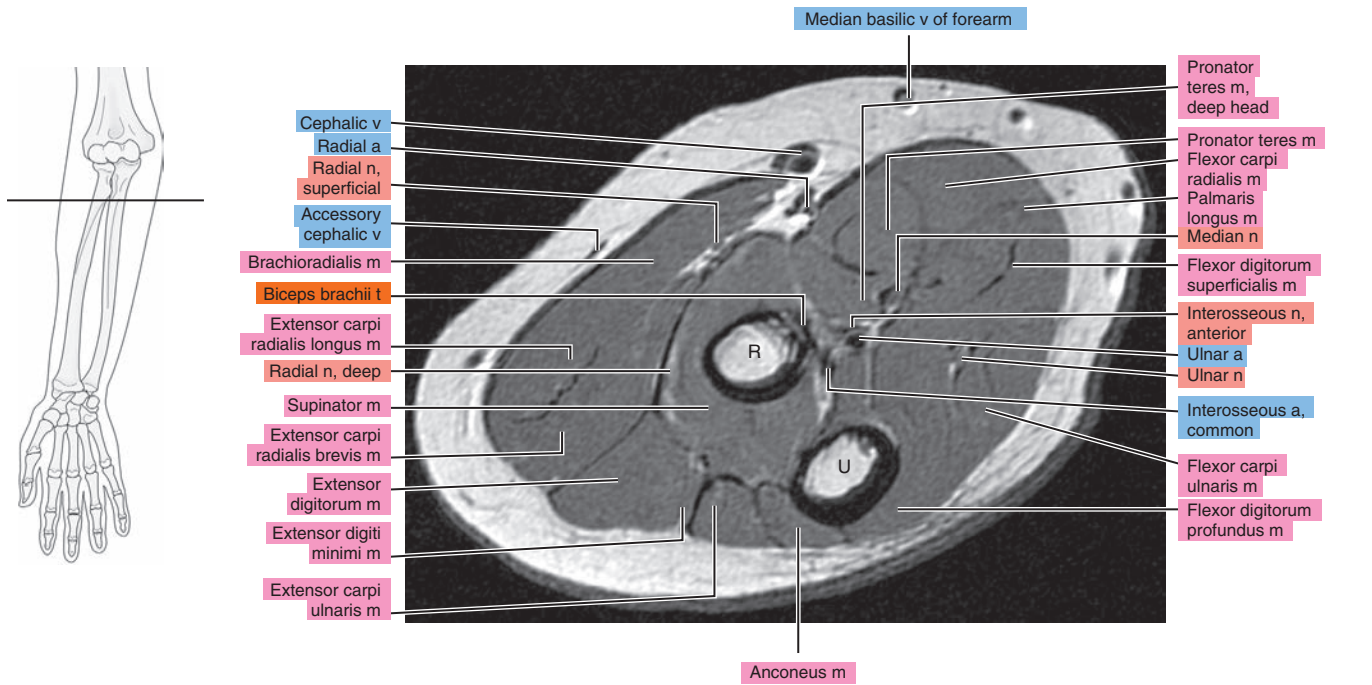


Figure 10.1.3

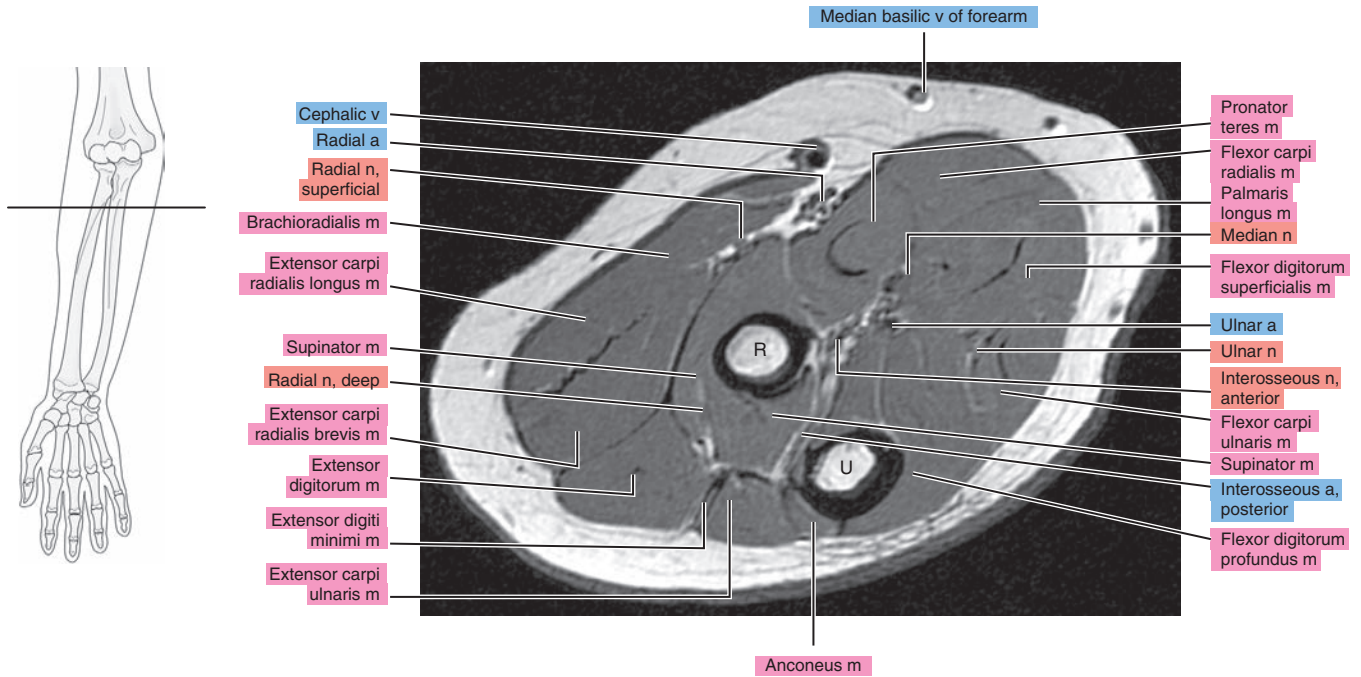


Figure 10.1.4

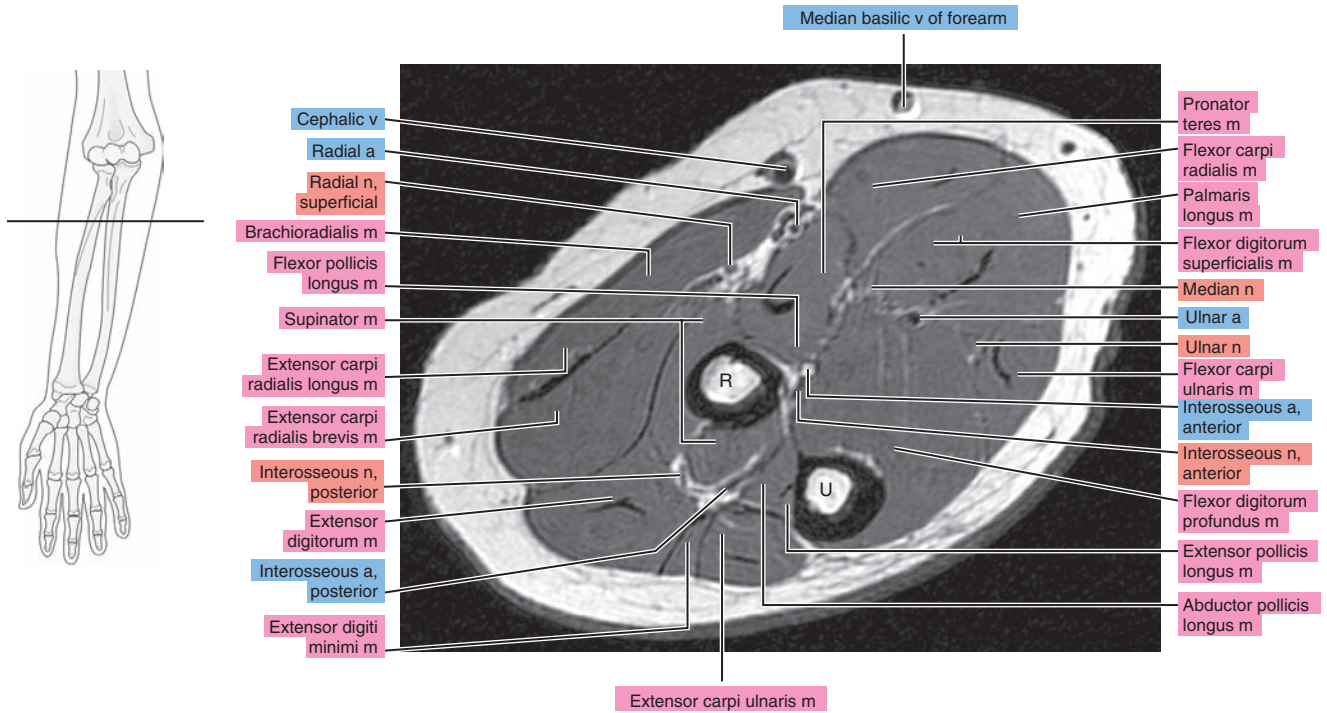




Figure 10.1.5

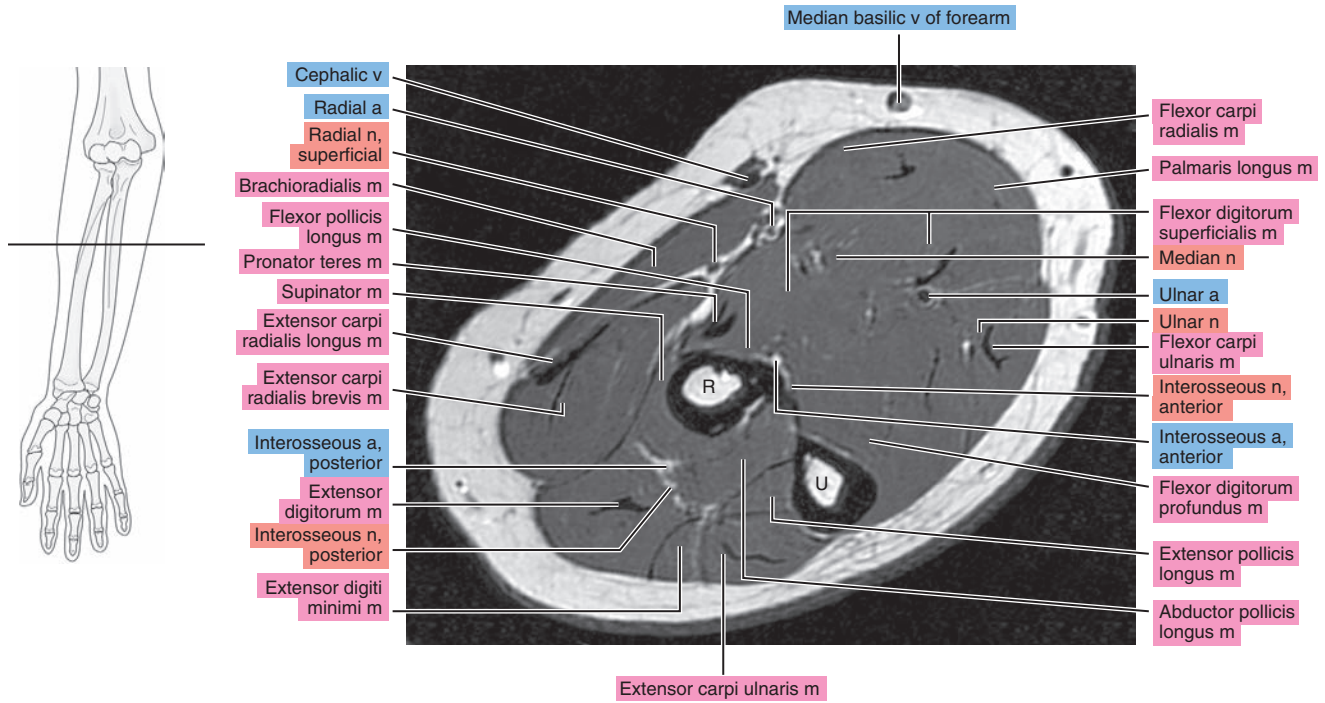


Figure 10.1.6

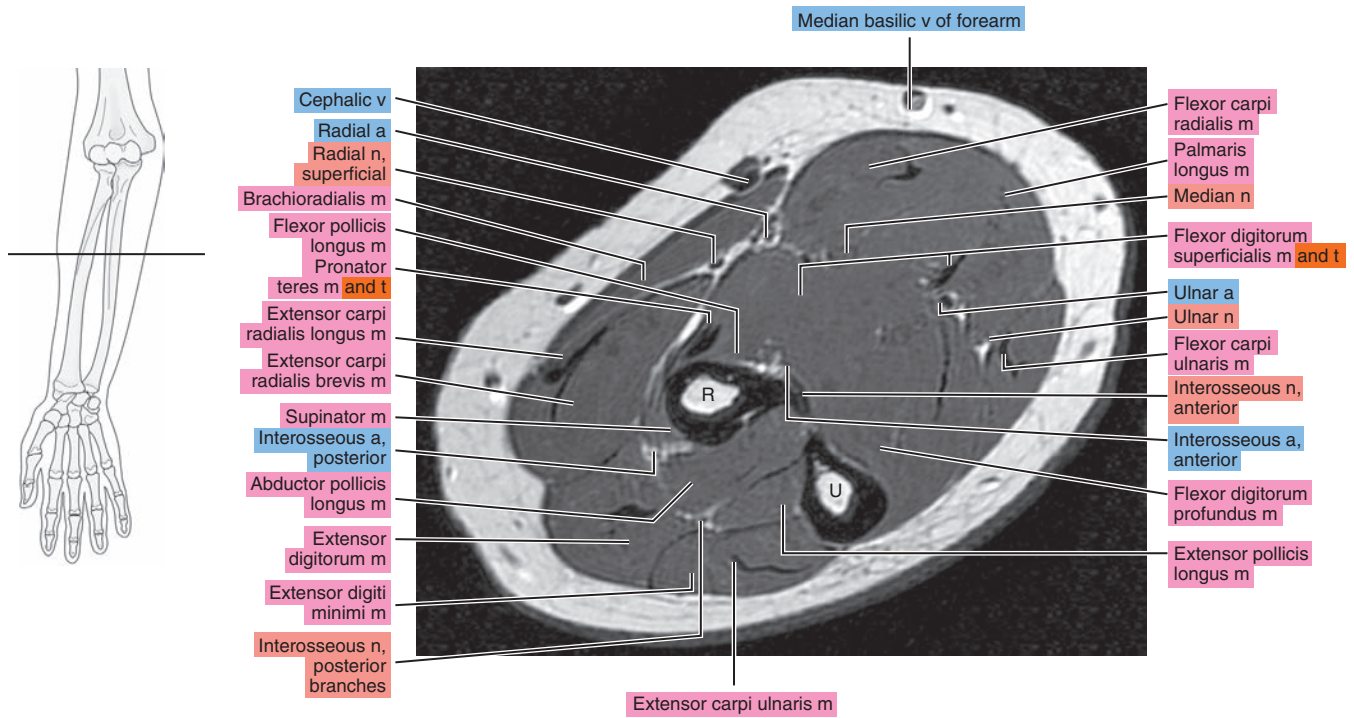


Figure 10.1.7

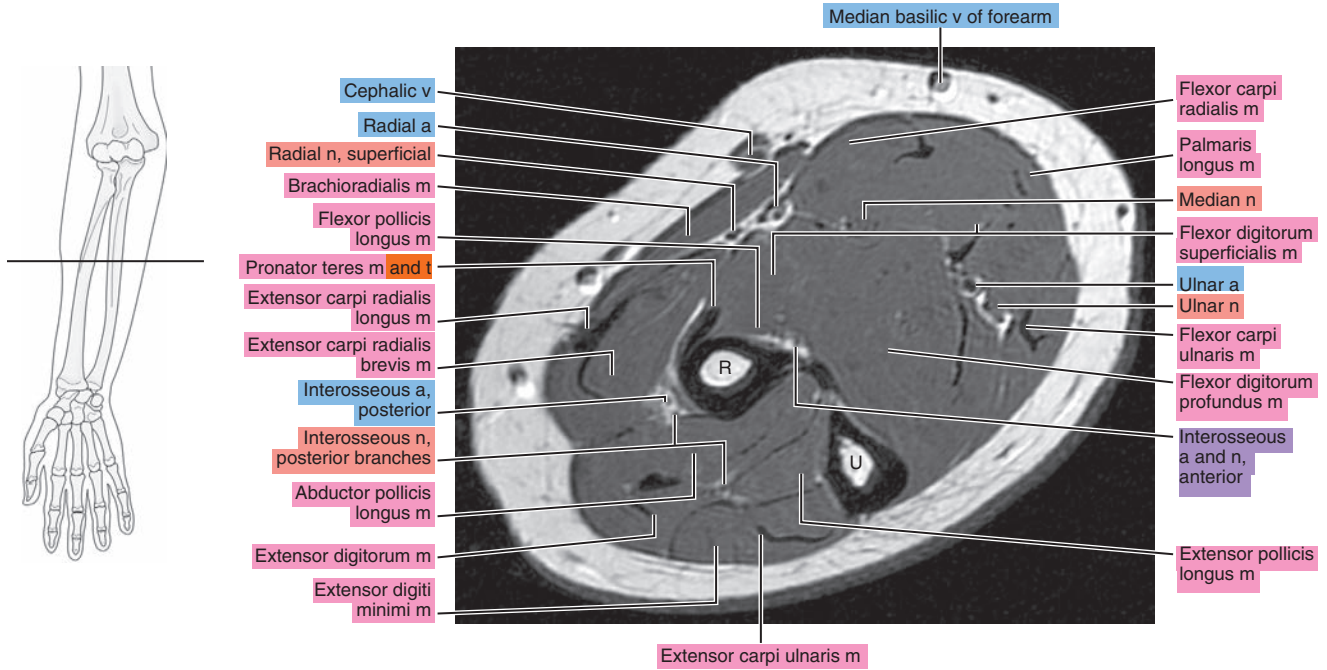


Figure 10.1.8

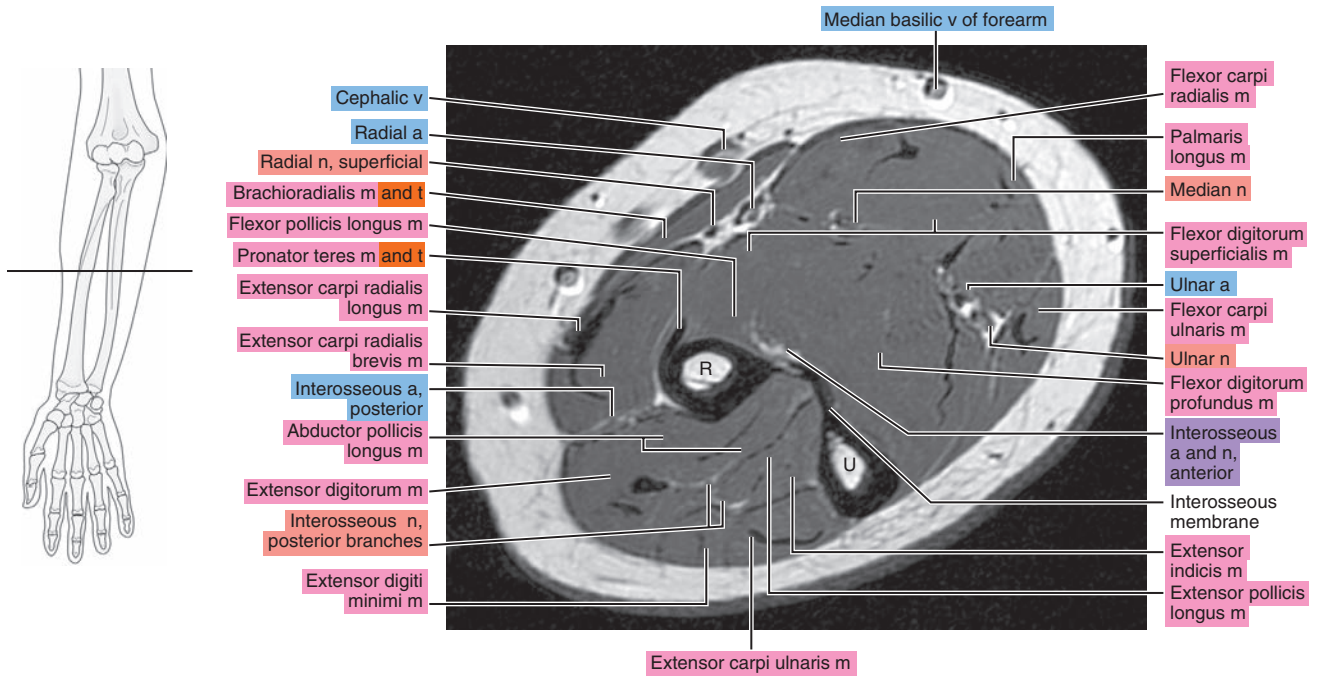


Figure 10.1.9

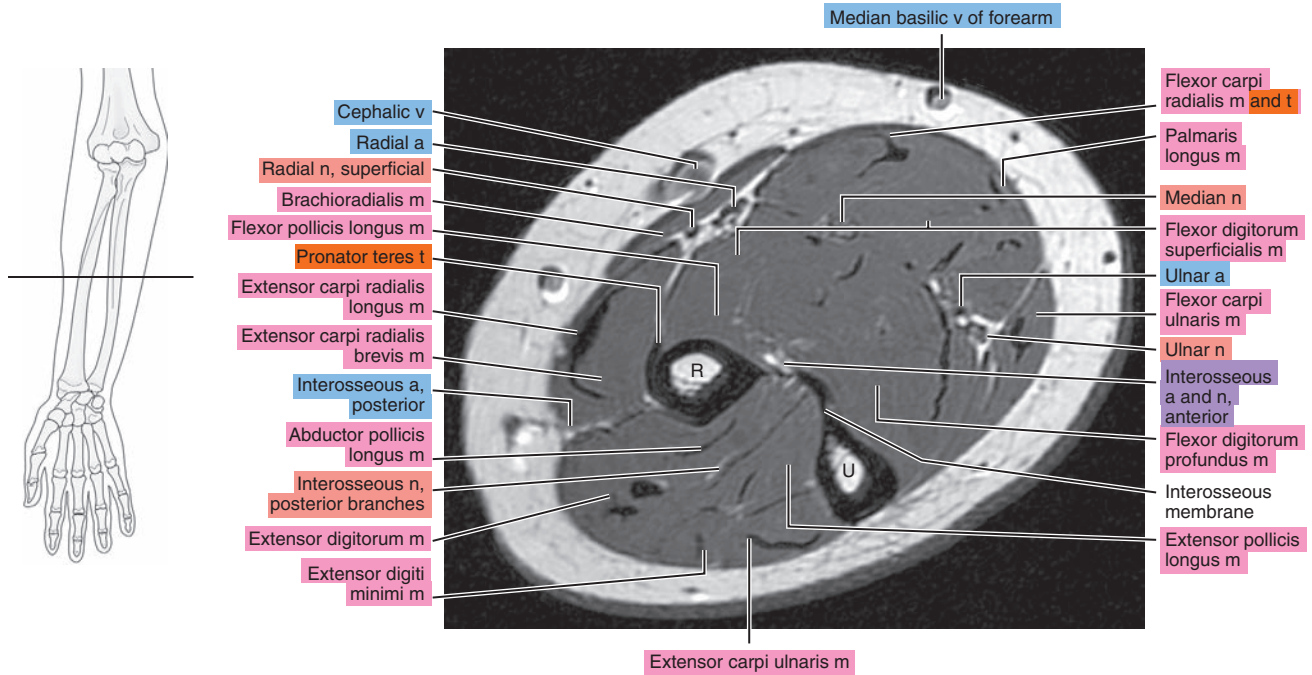


Figure 10.1.10

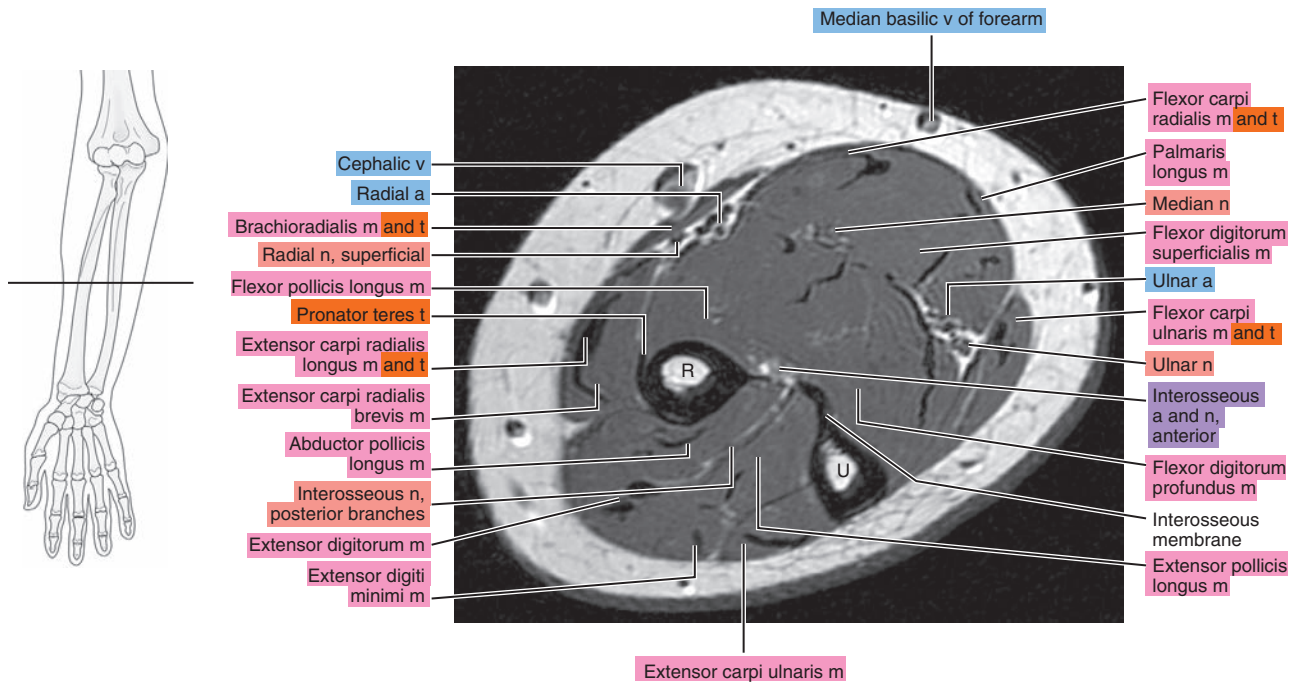




Figure 10.1.11

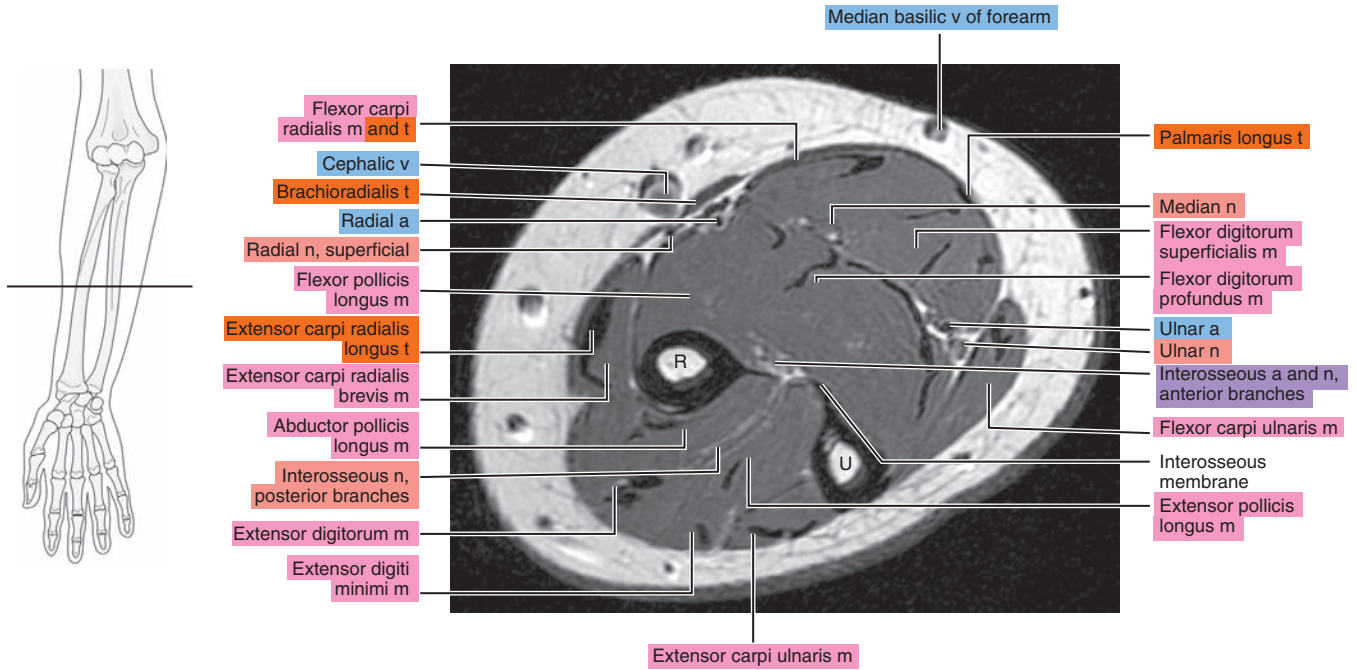


Figure 10.1.12

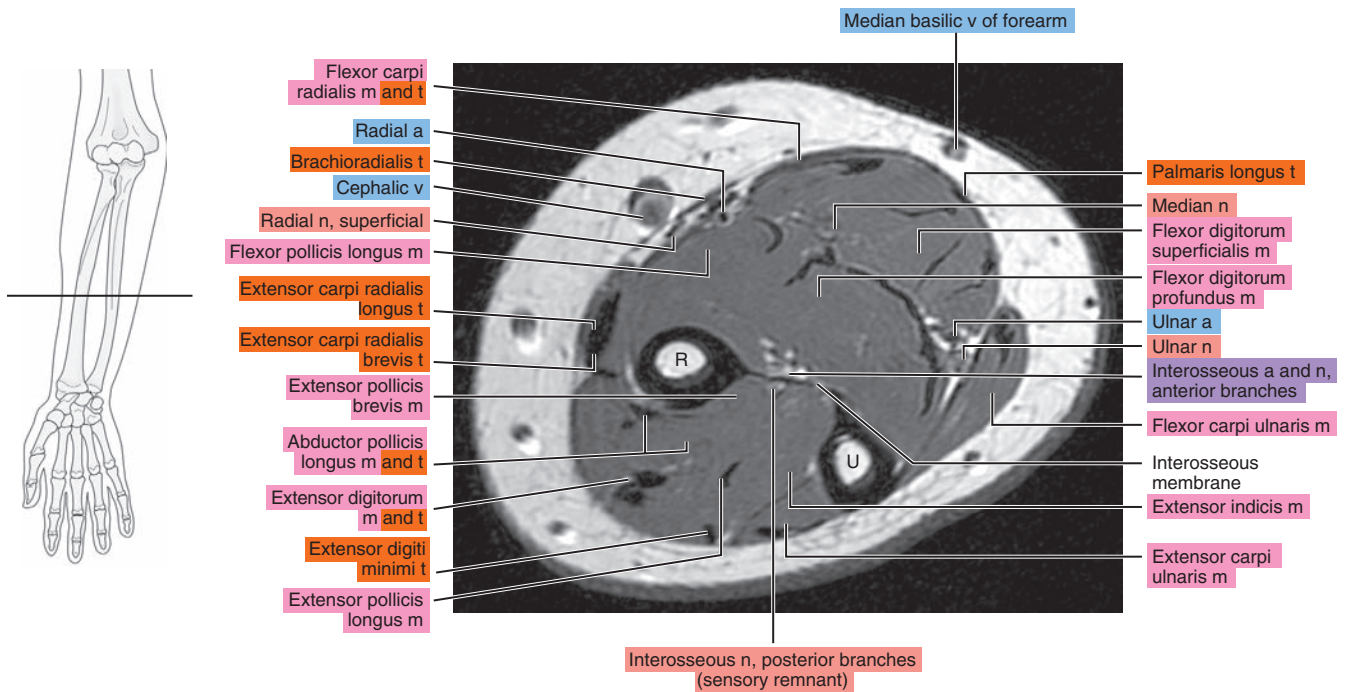




Figure 10.1.13

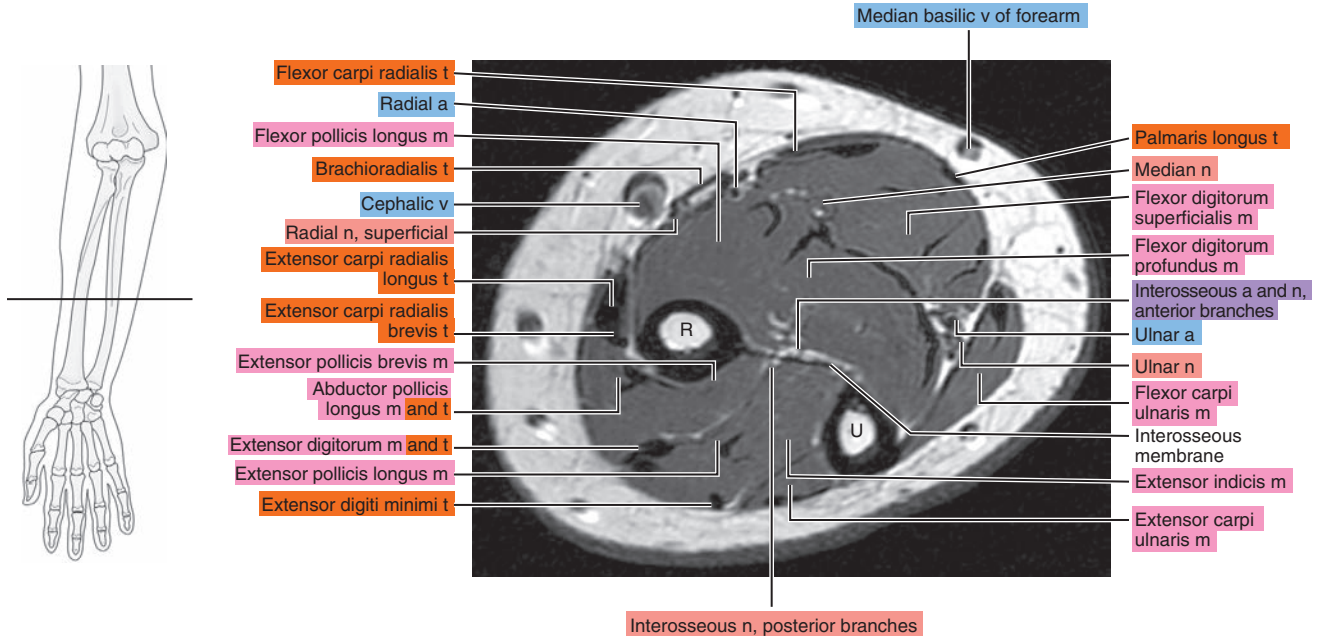


Figure 10.1.14

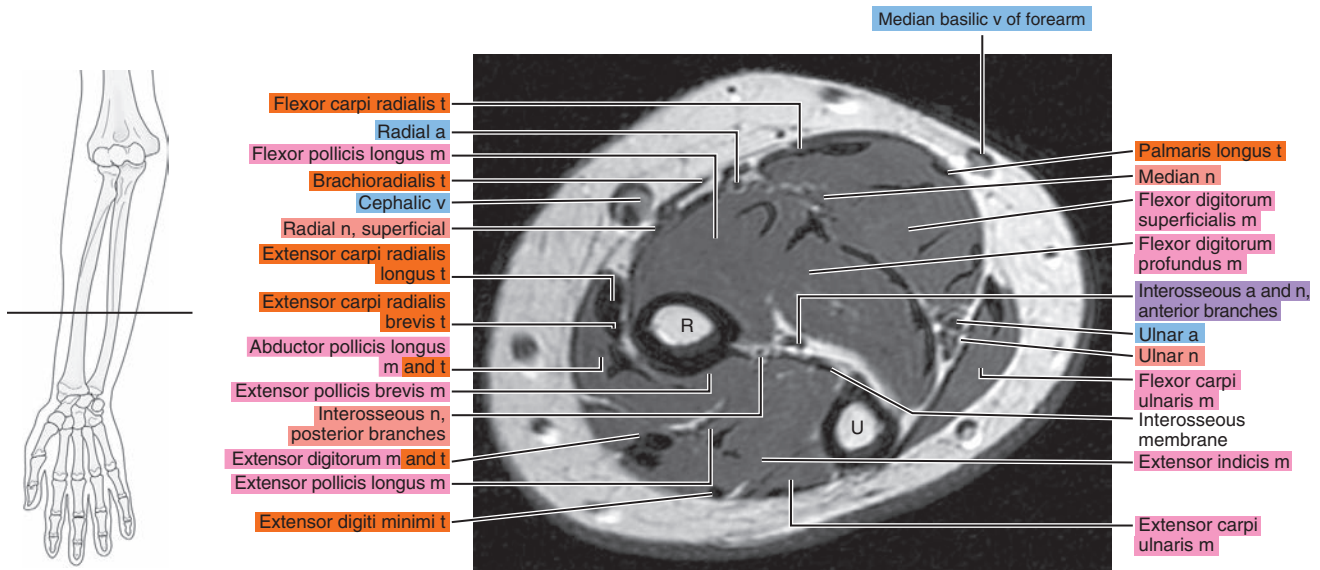


Figure 10.1.15

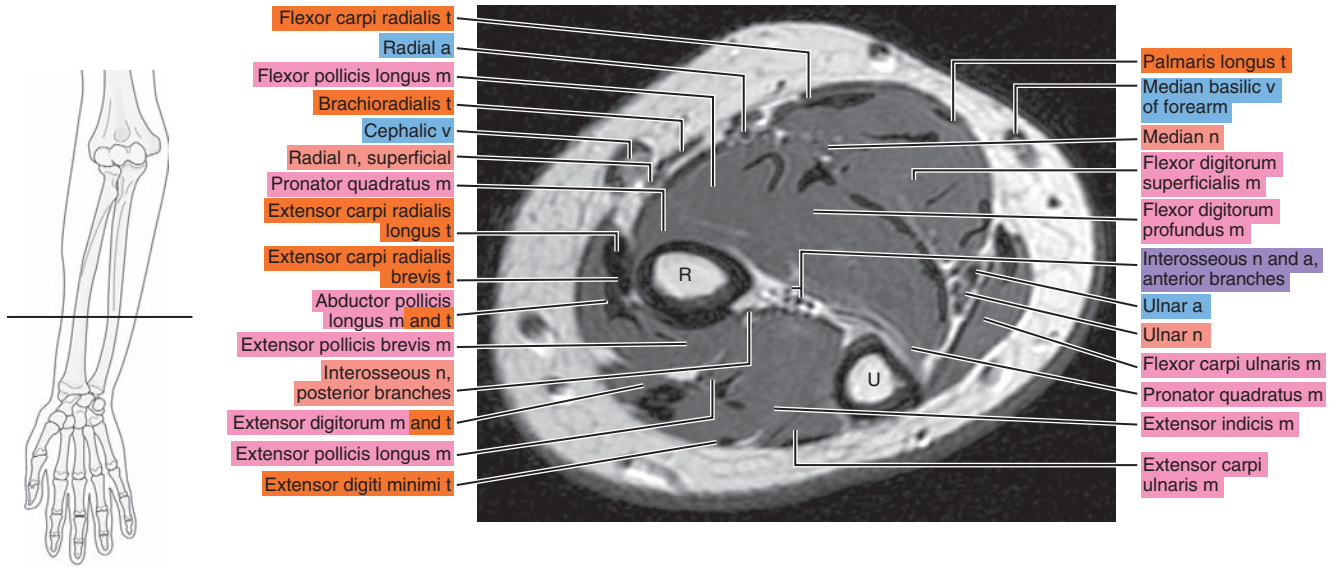


Figure 10.1.16

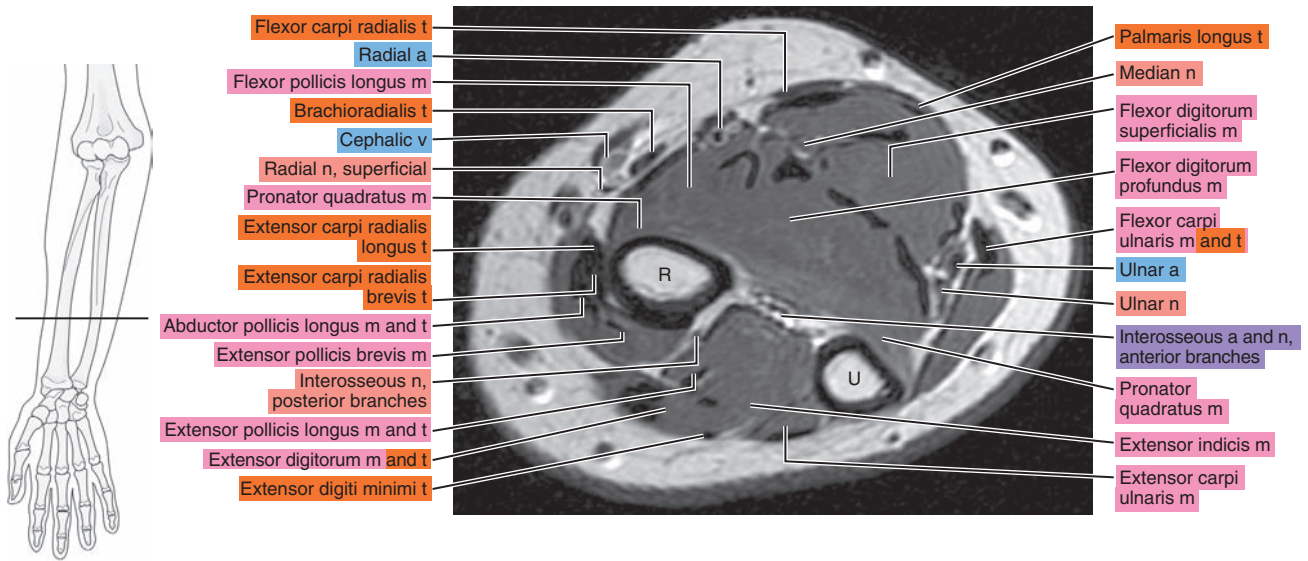


Figure 10.1.17

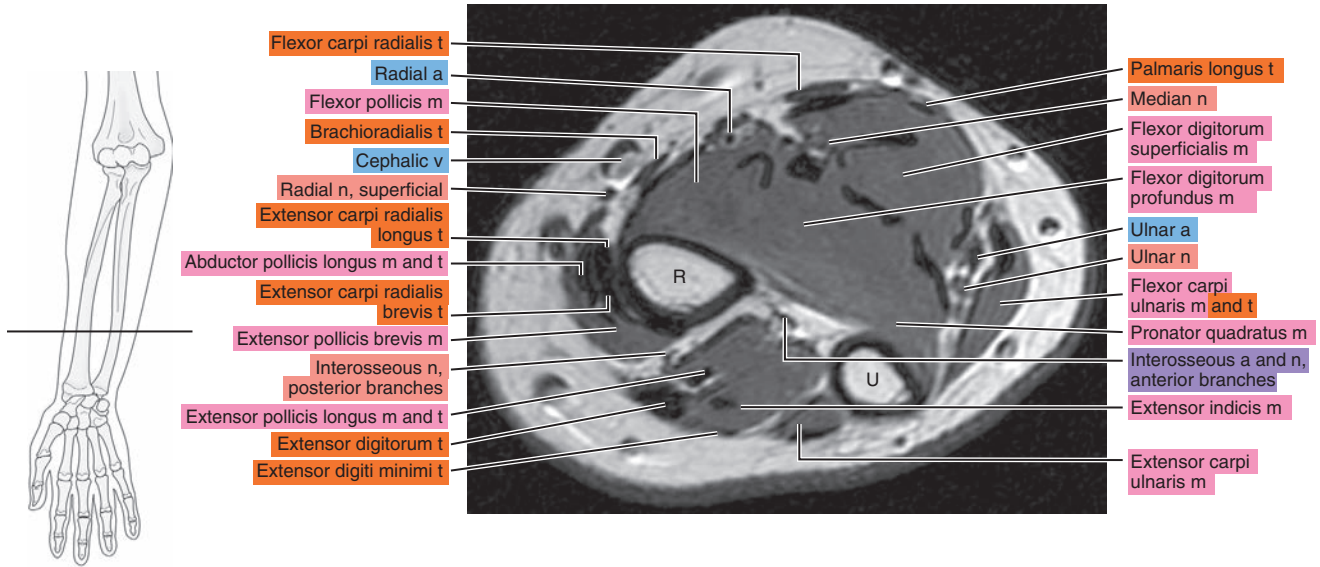


Figure 10.1.18

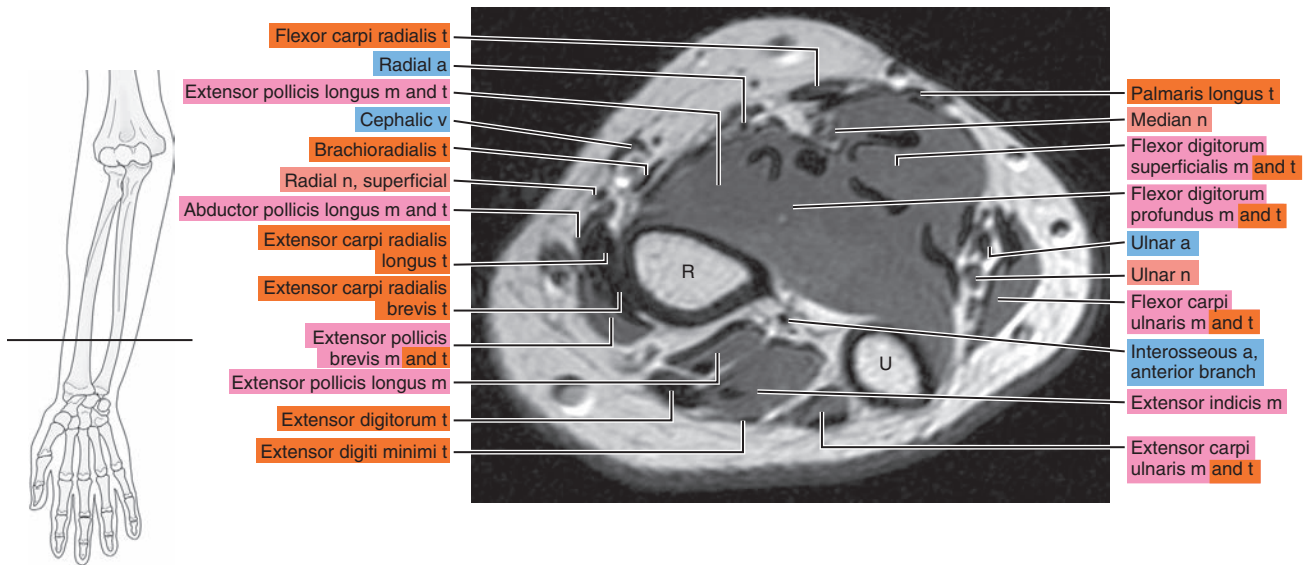




Figure 10.1.19

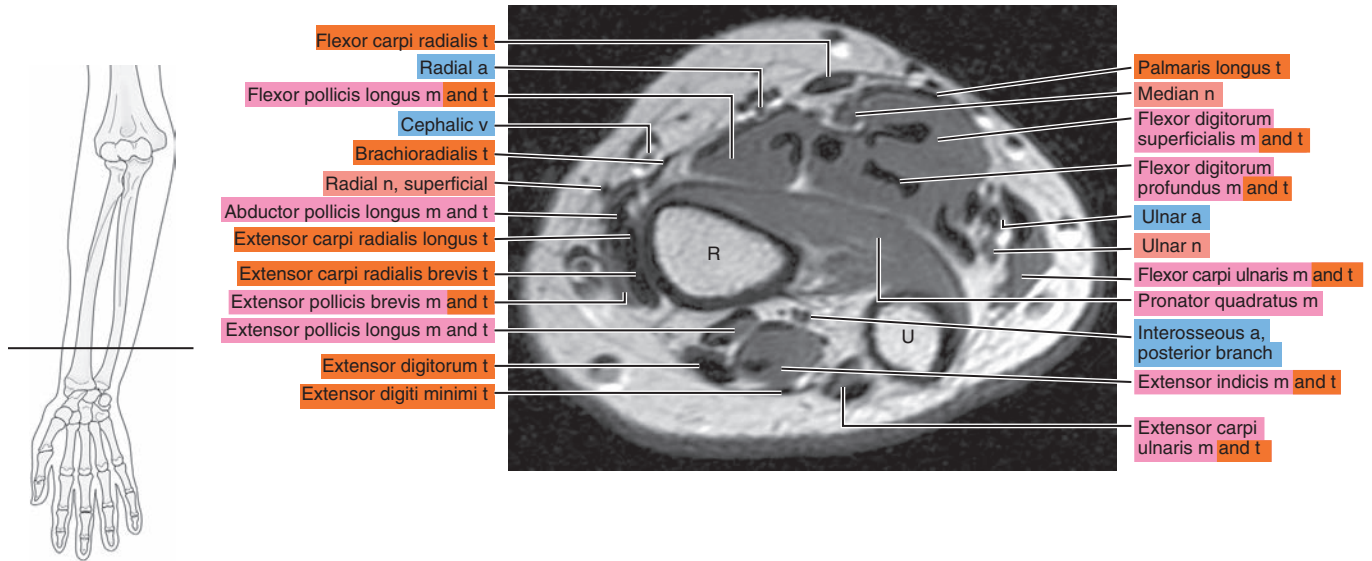
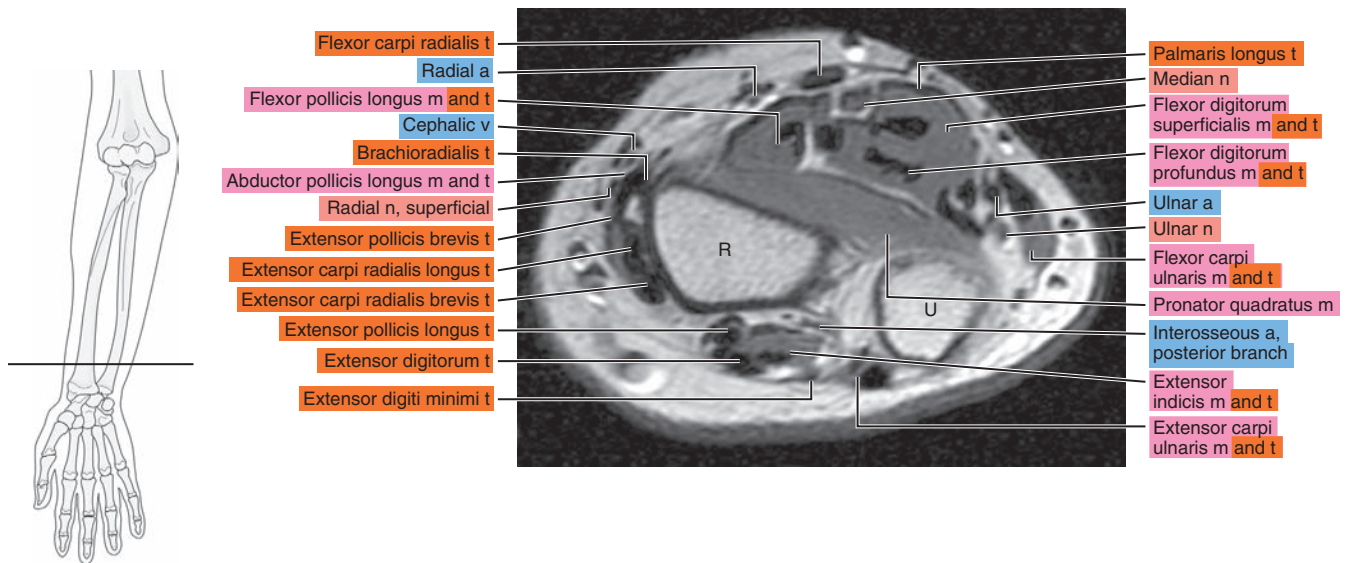


Figure 10.1.20





# SAGITTAL

Figure 10.2.1

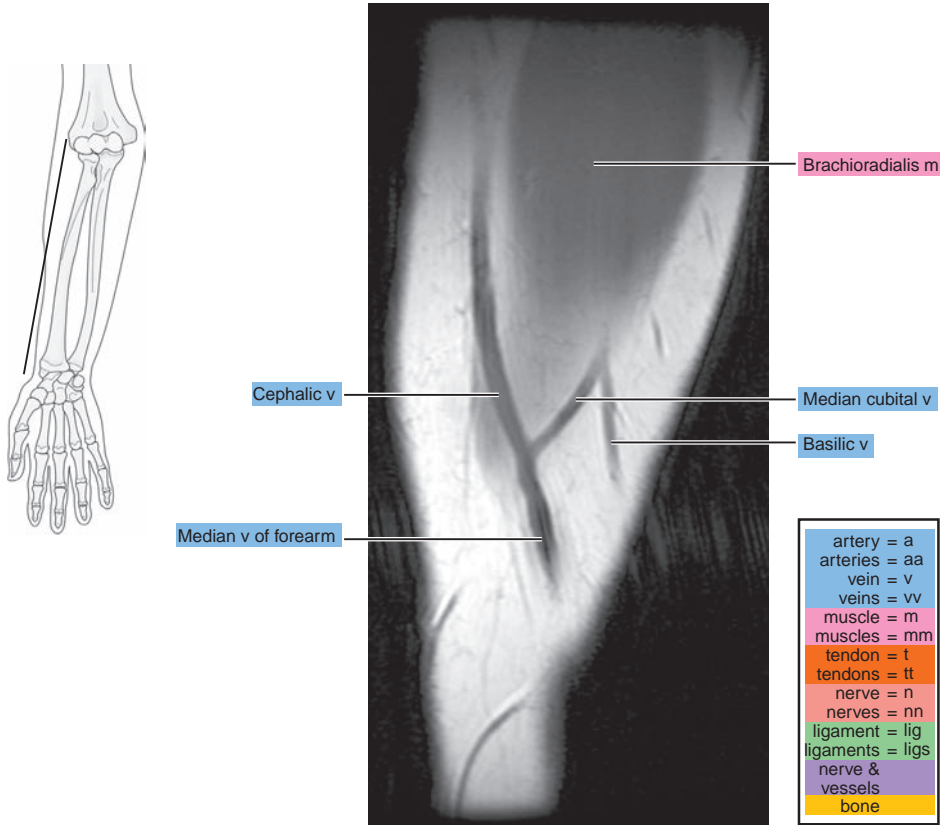


Figure 10.2.2

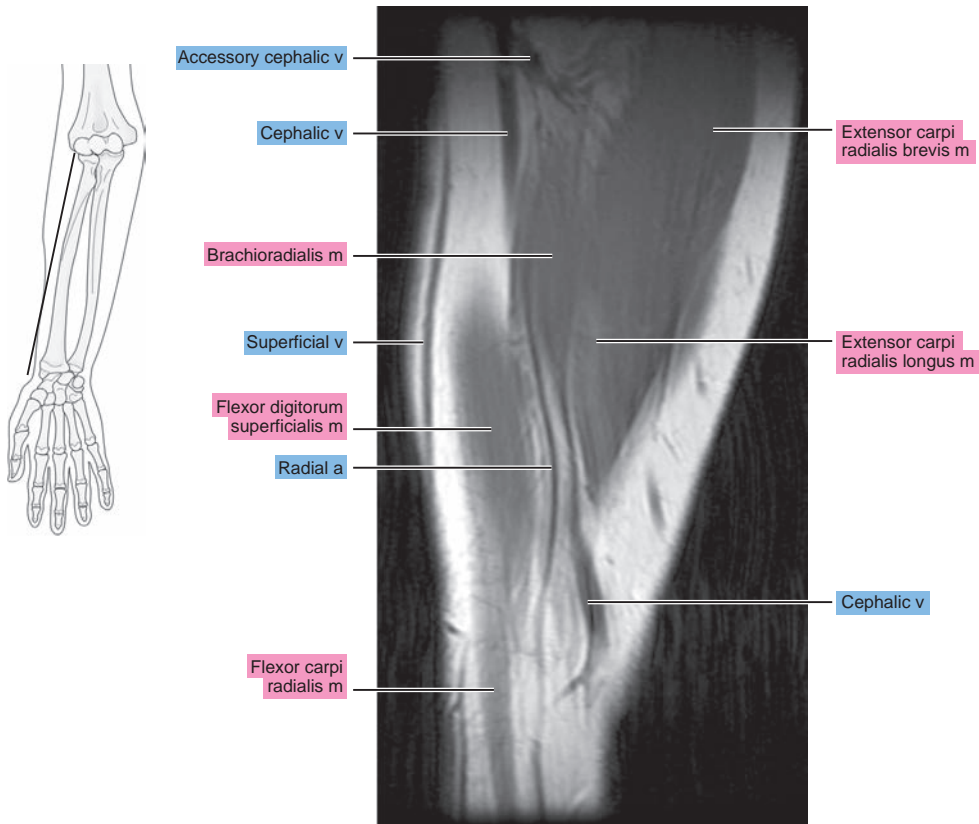


Figure 10.2.3

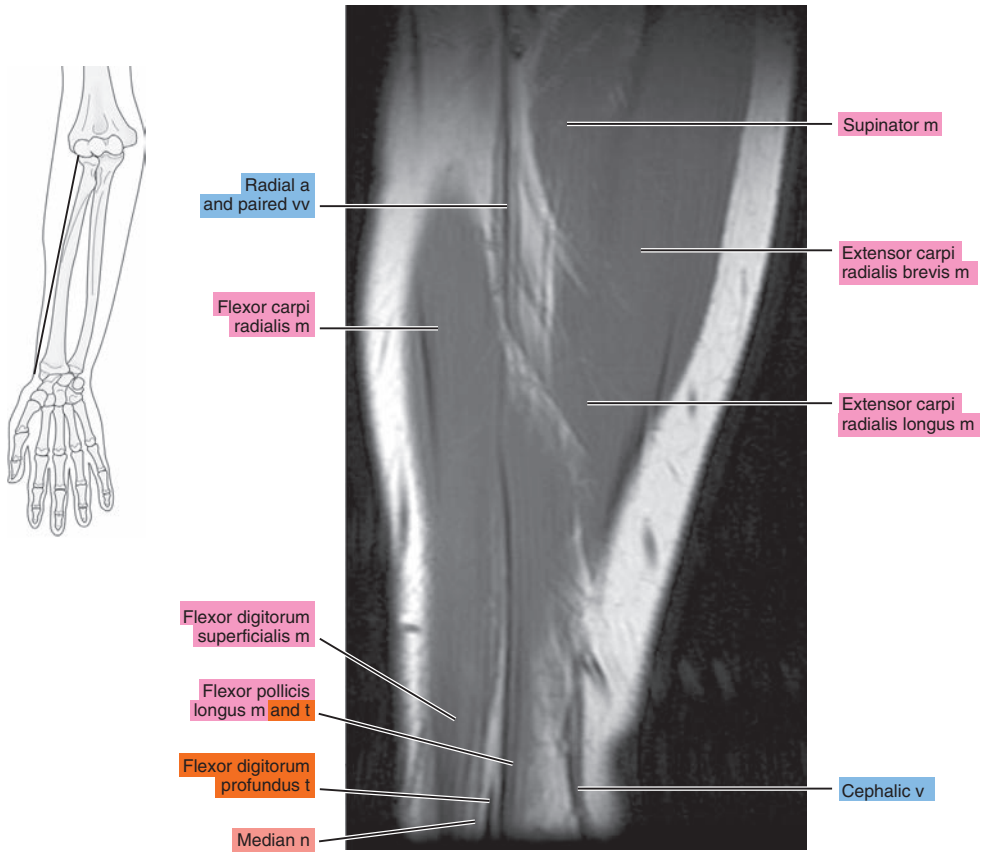


Figure 10.2.4

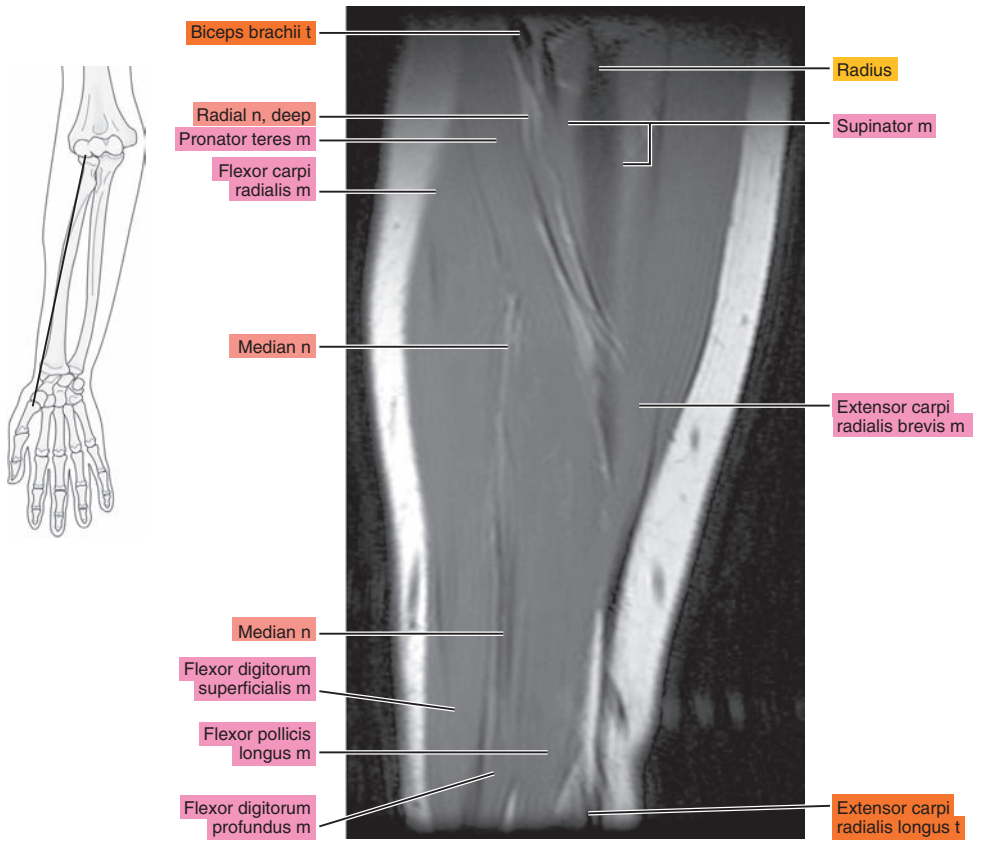


Figure 10.2.5

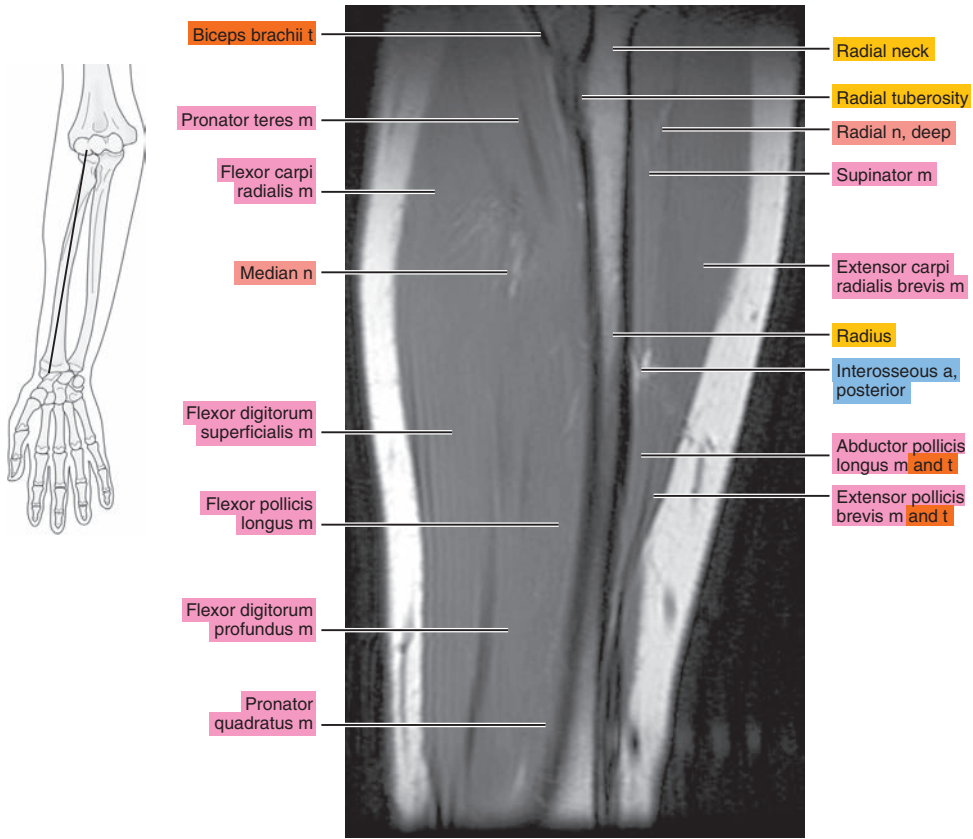


Figure 10.2.6

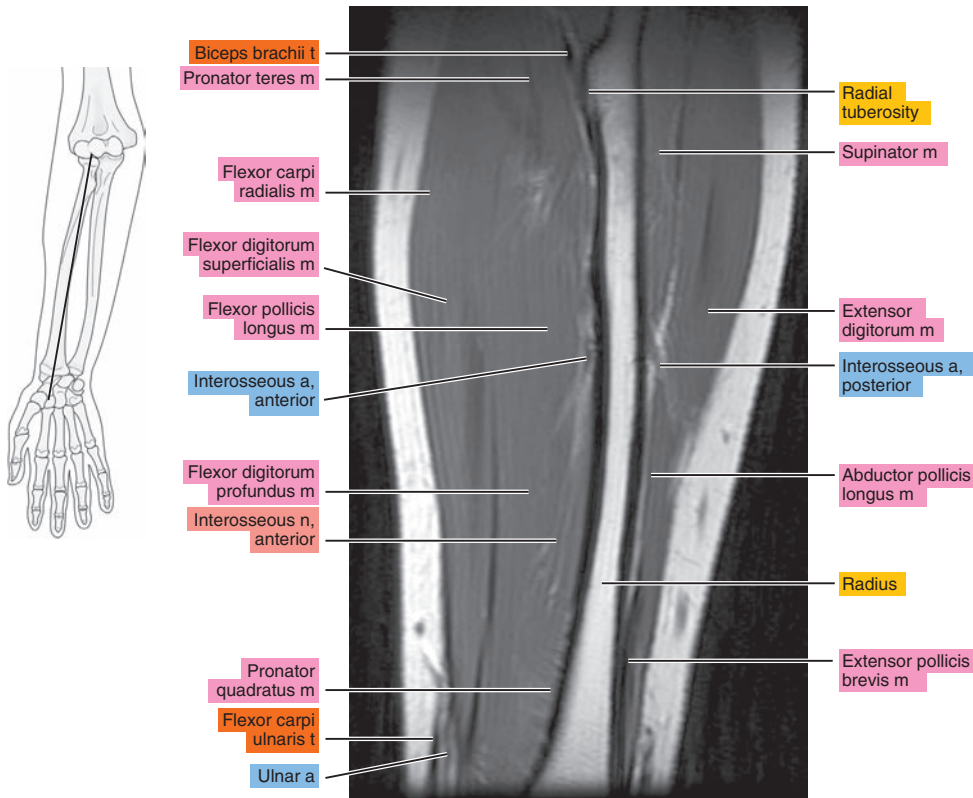


Figure 10.2.7

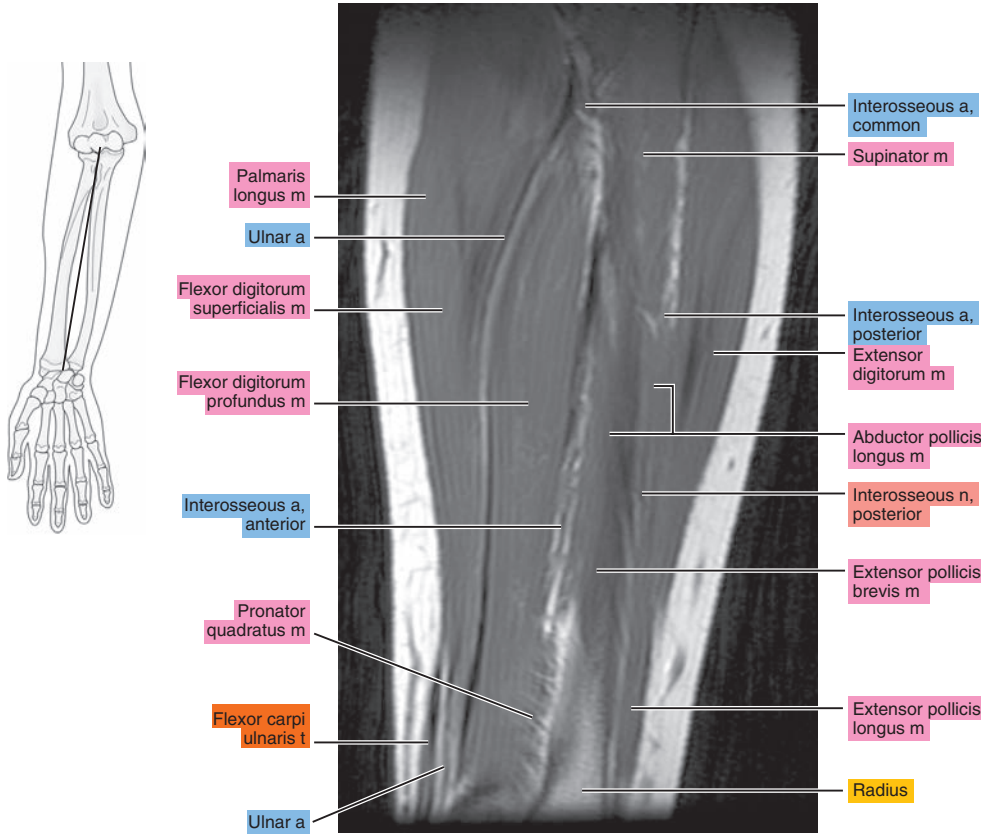


Figure 10.2.8

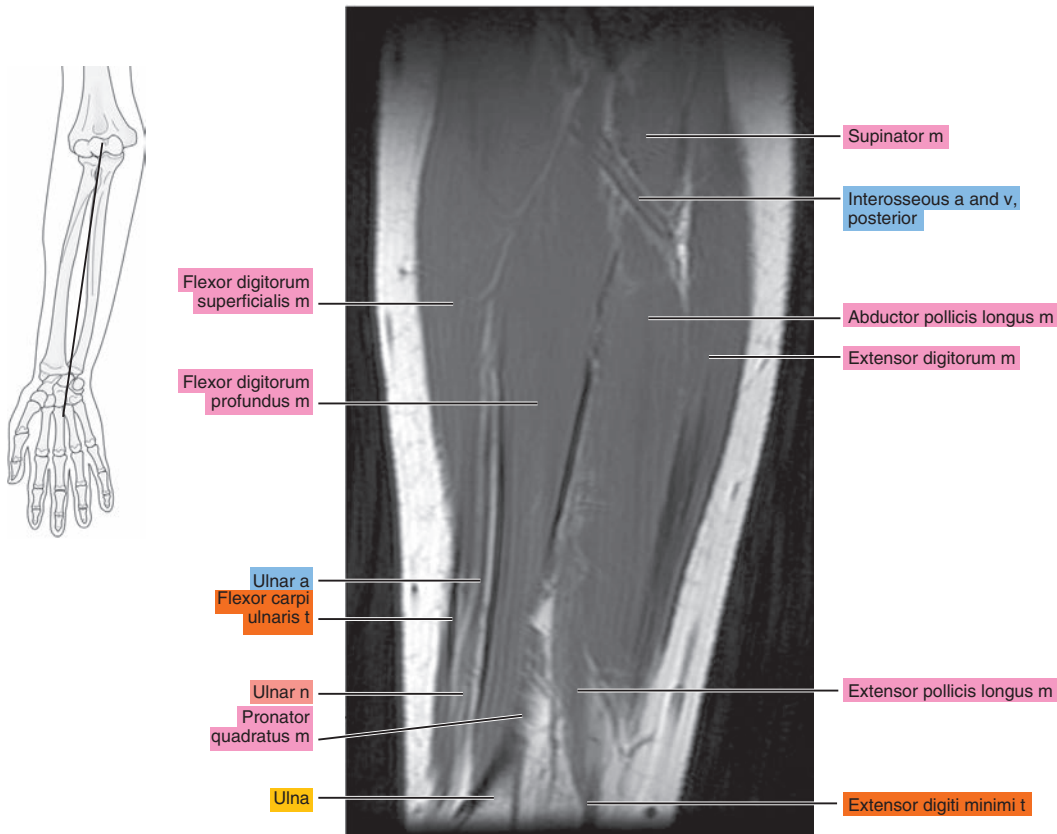




Figure 10.2.9

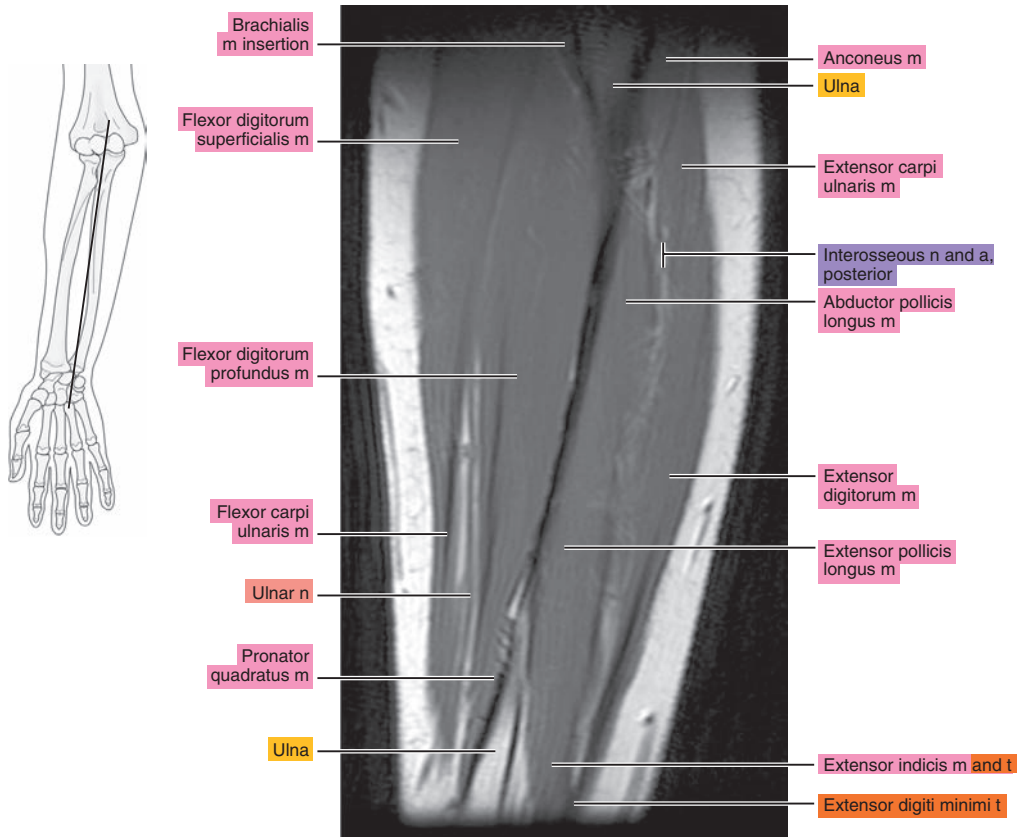


Figure 10.2.10

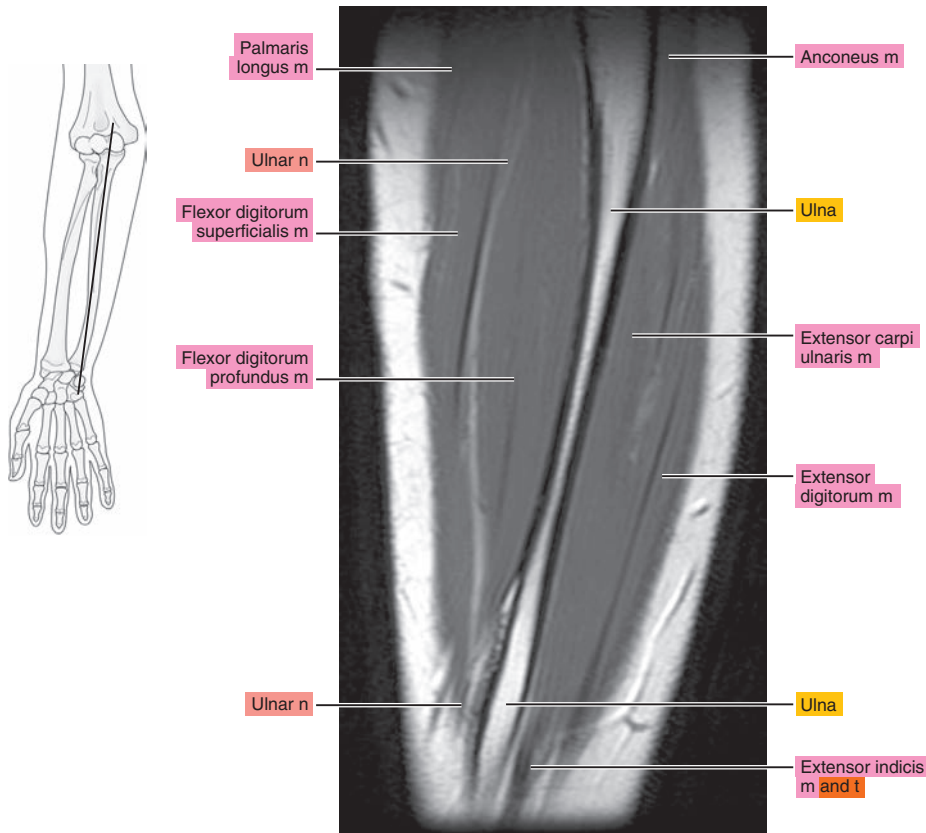


Figure 10.2.11

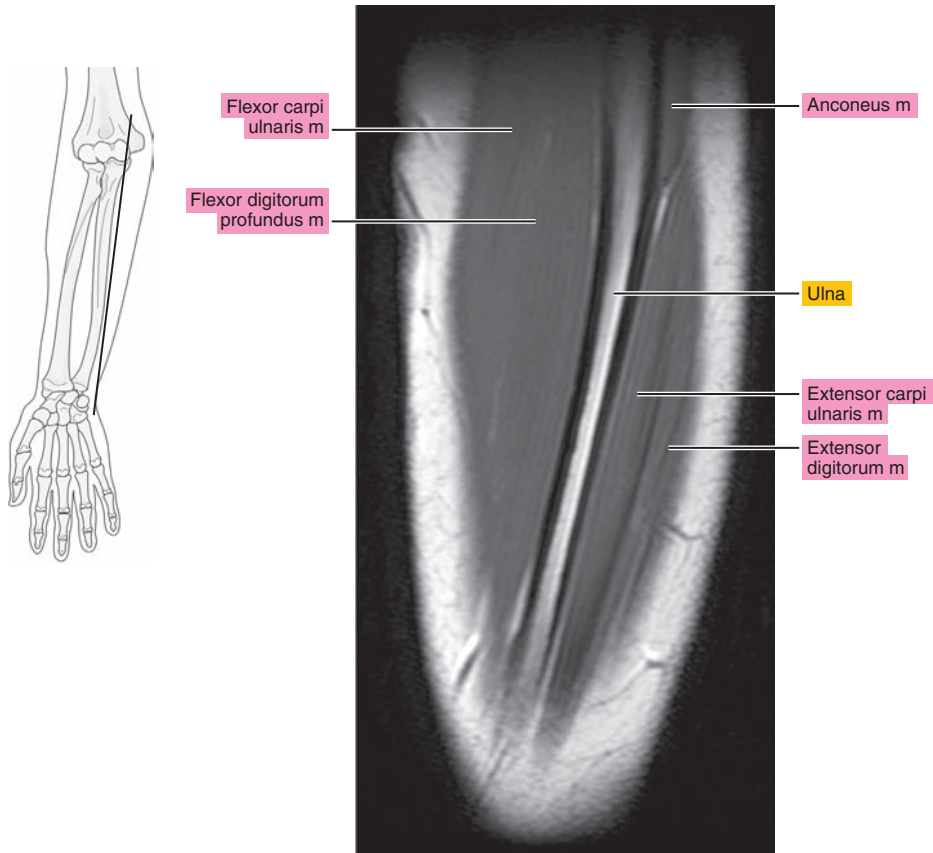
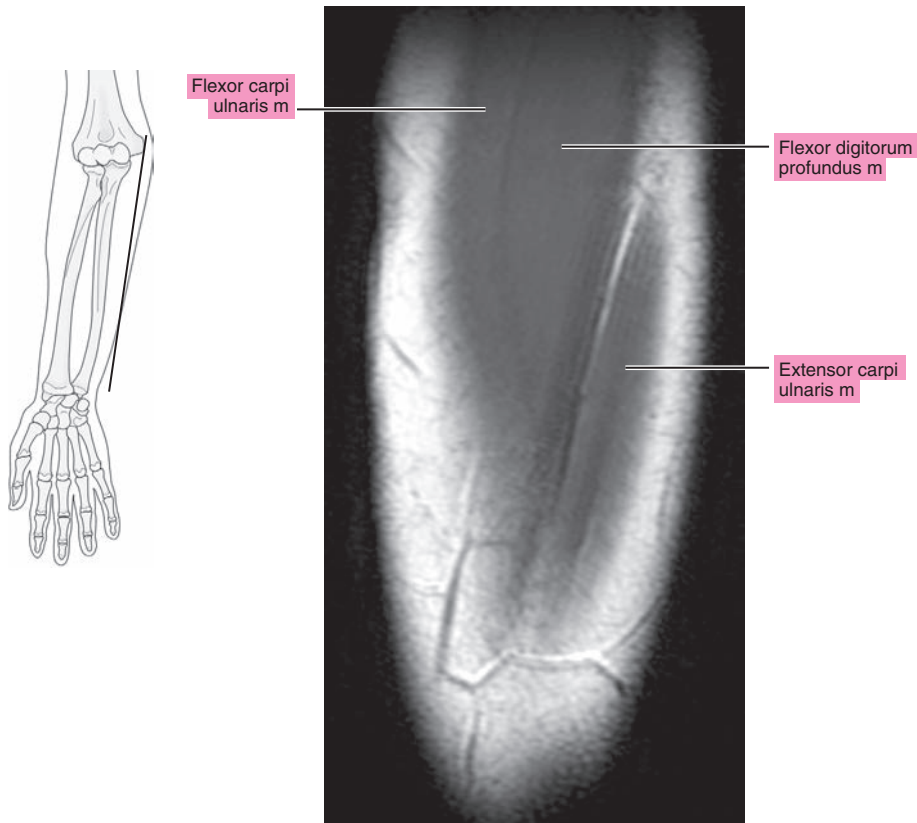


Figure 10.2.12



# CORONAL

Figure 10.3.1

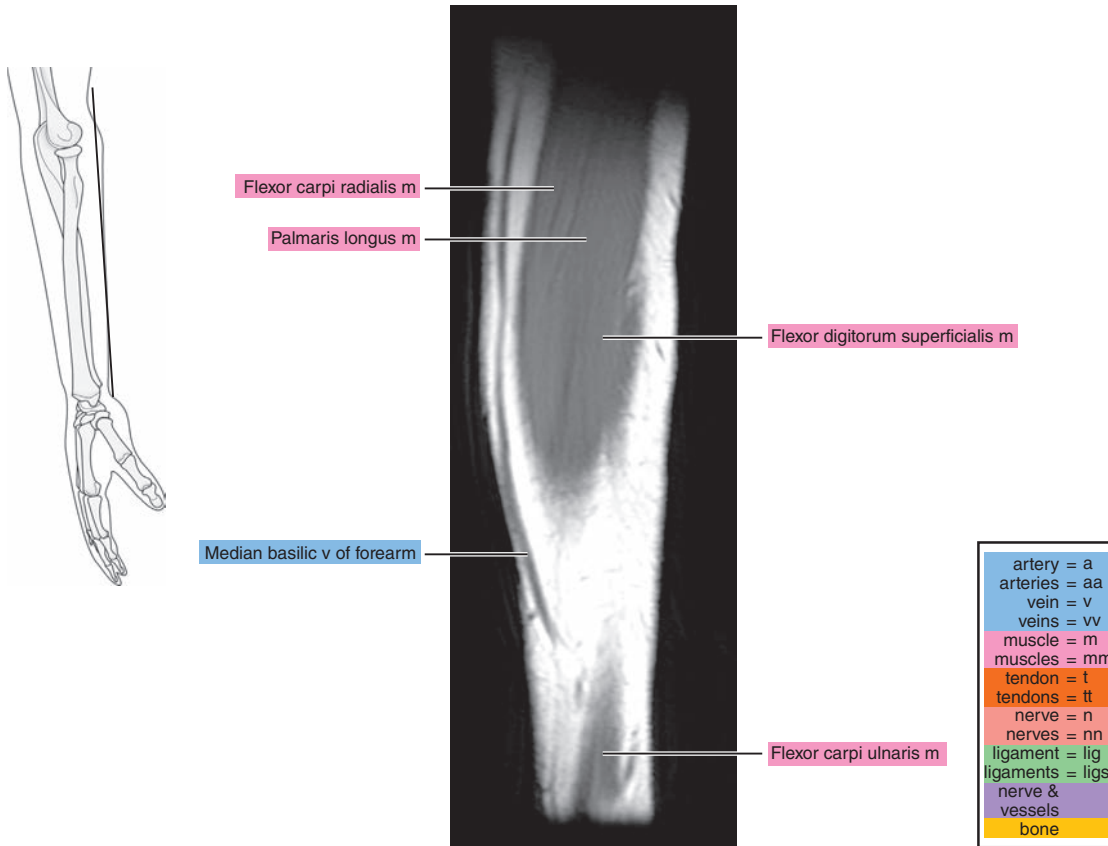


Figure 10.3.2

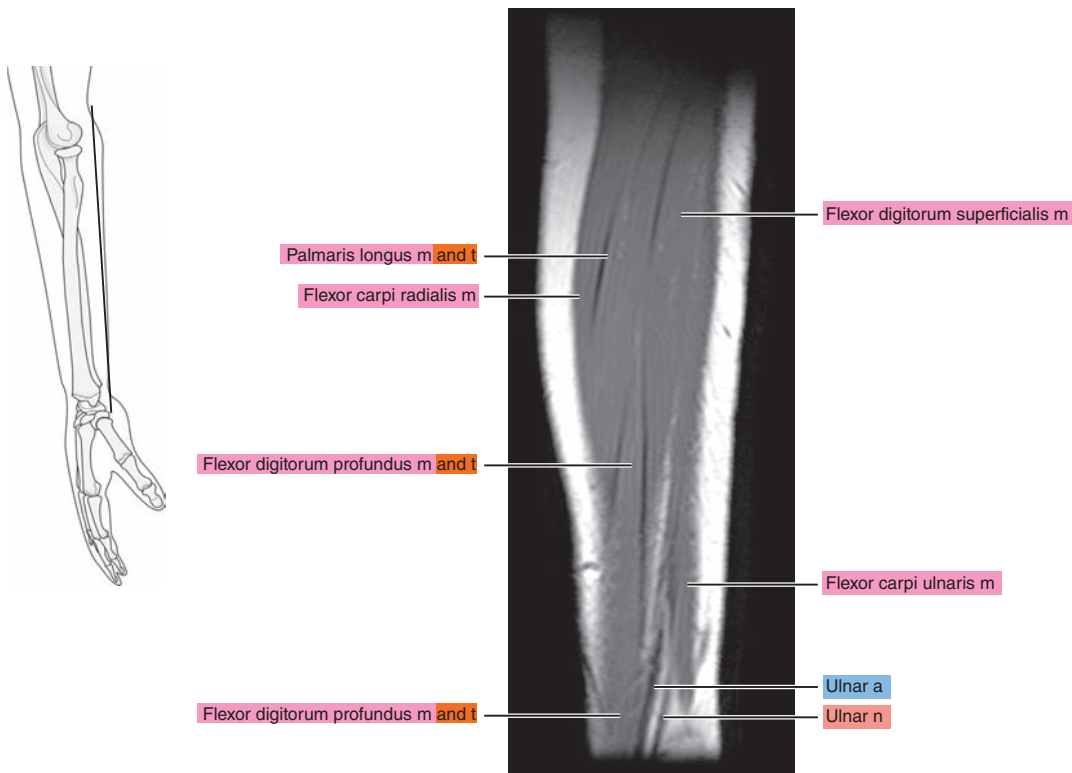


Figure 10.3.3

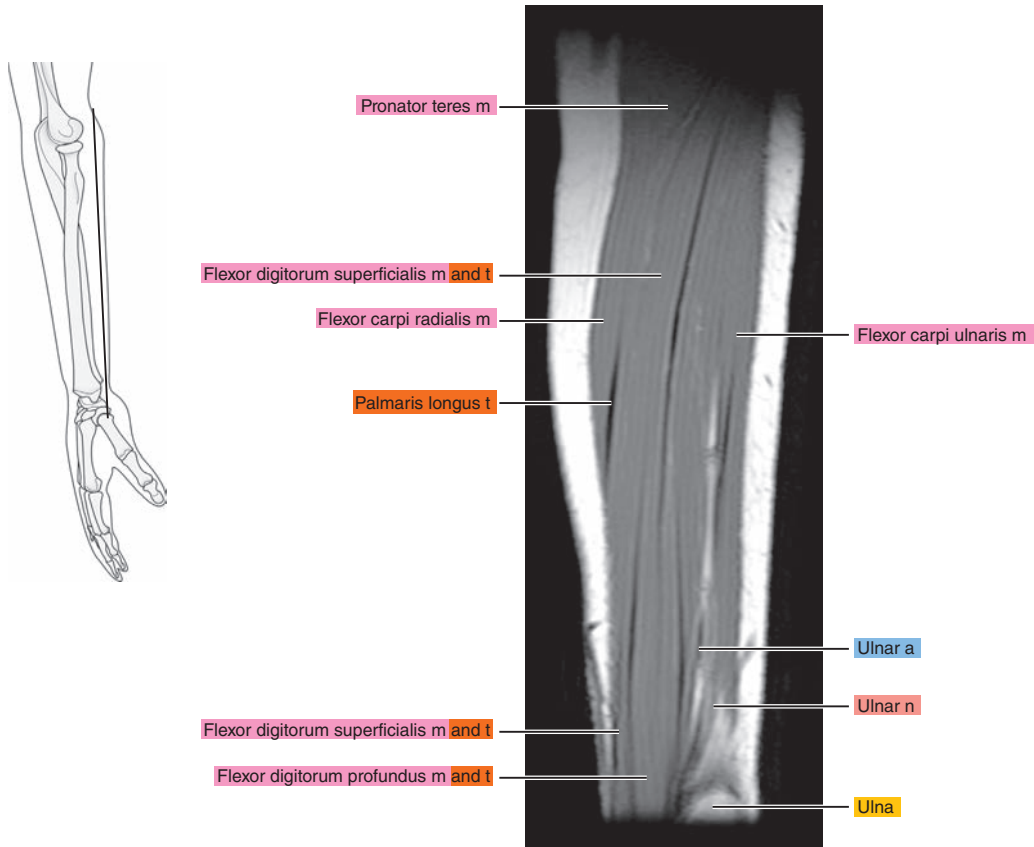


Figure 10.3.4

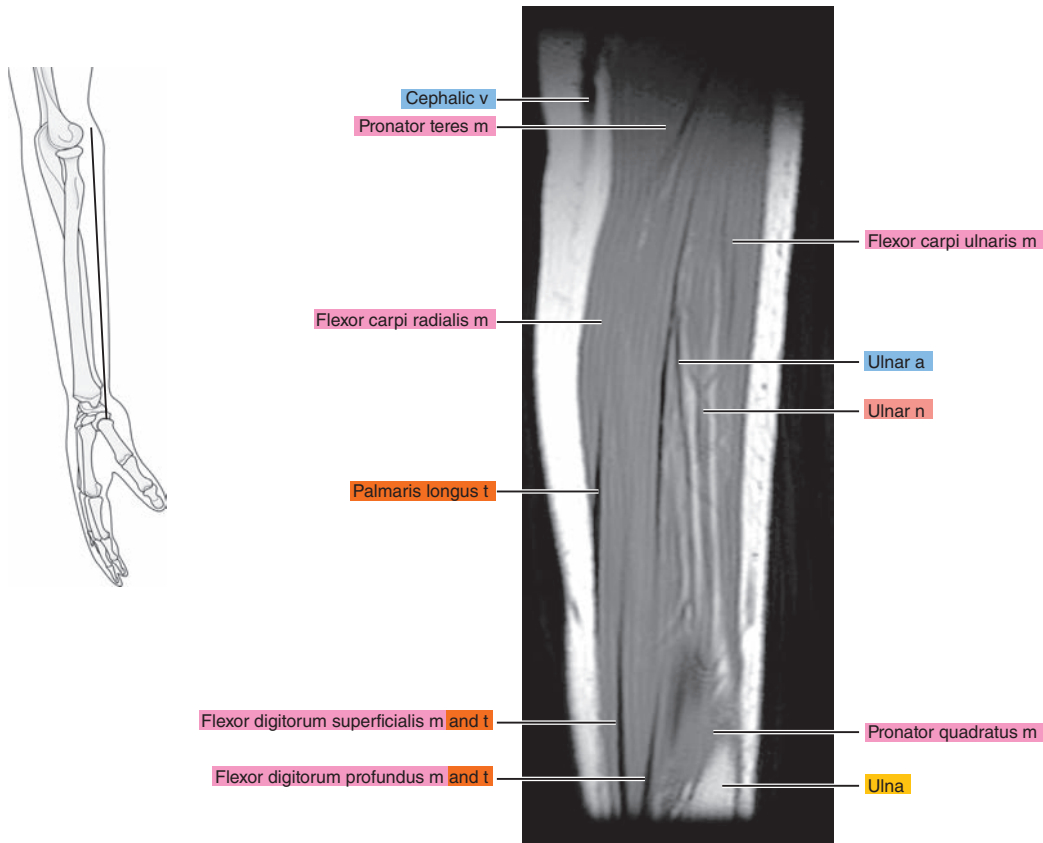




Figure 10.3.5

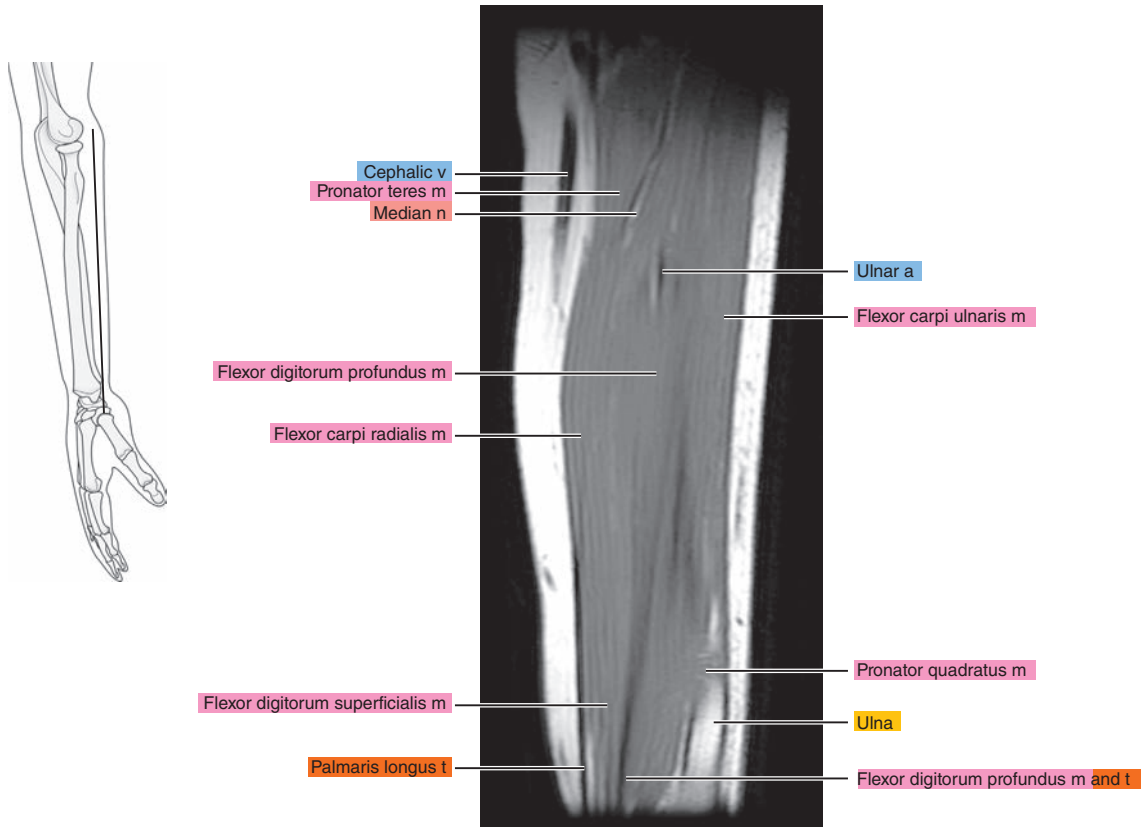


Figure 10.3.6

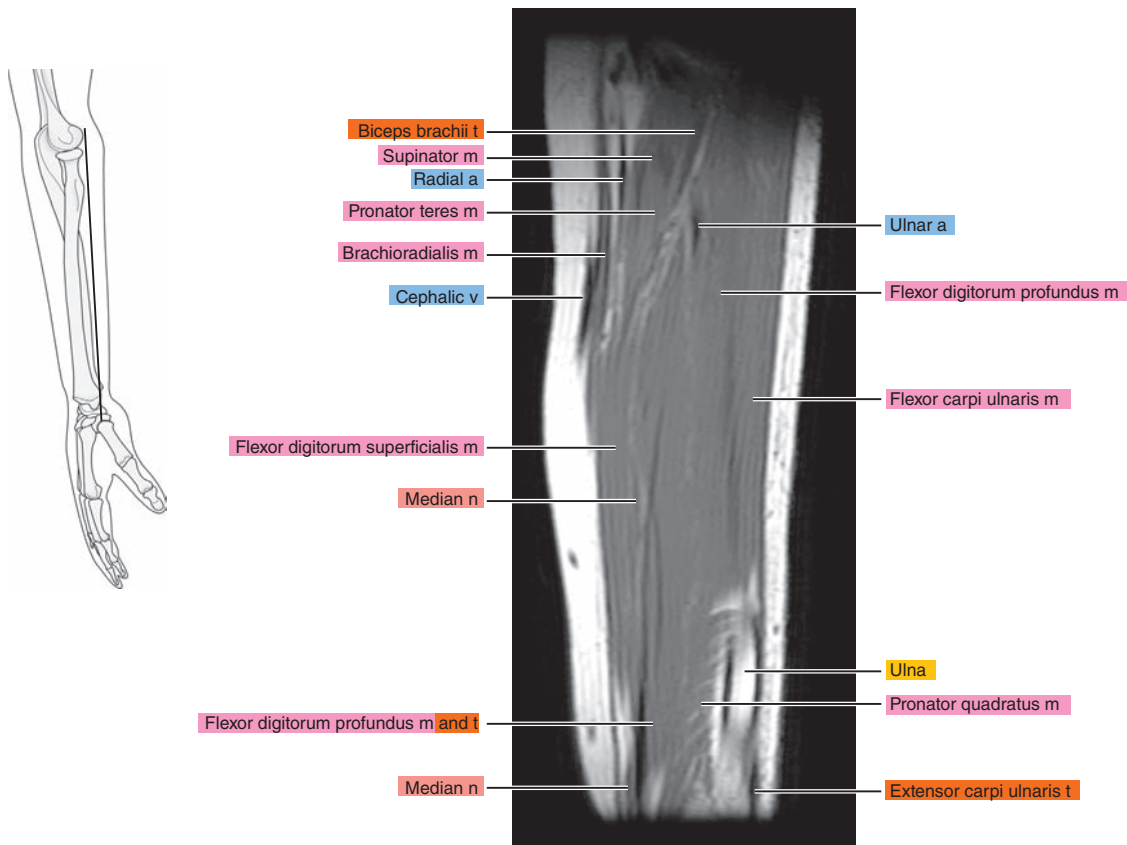


Figure 10.3.7

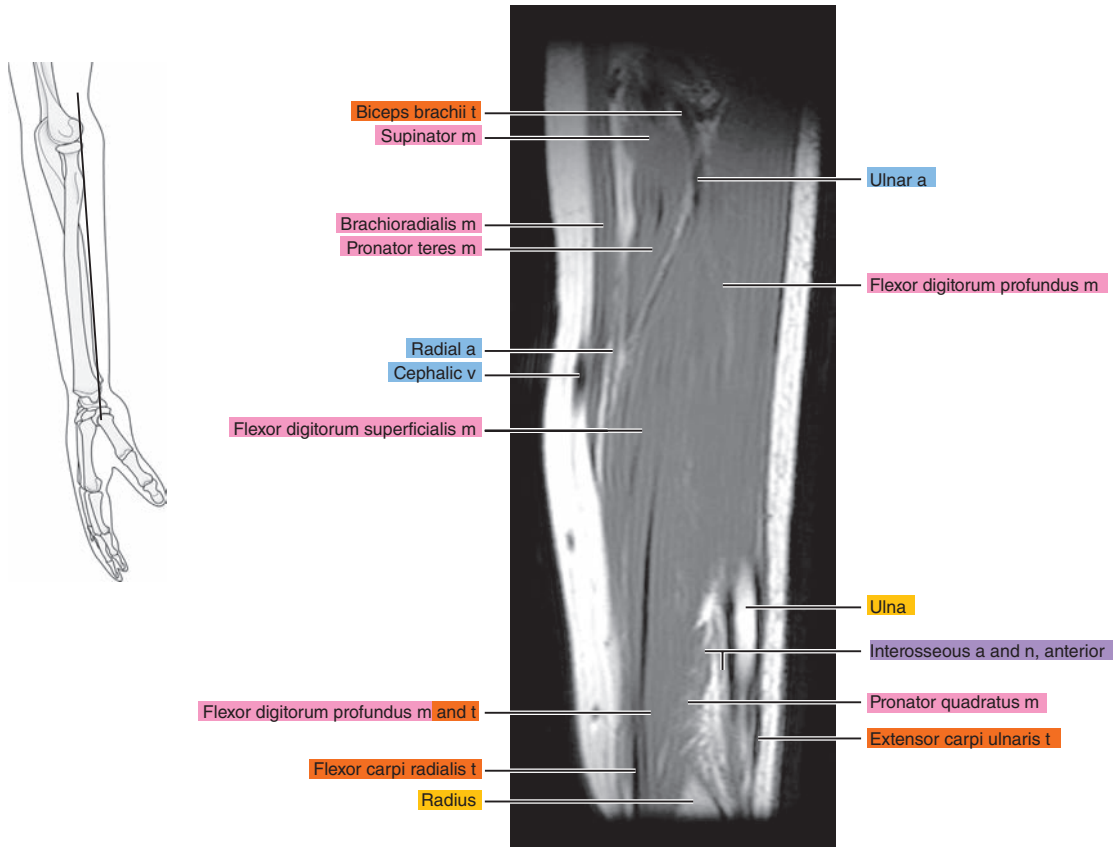


Figure 10.3.8

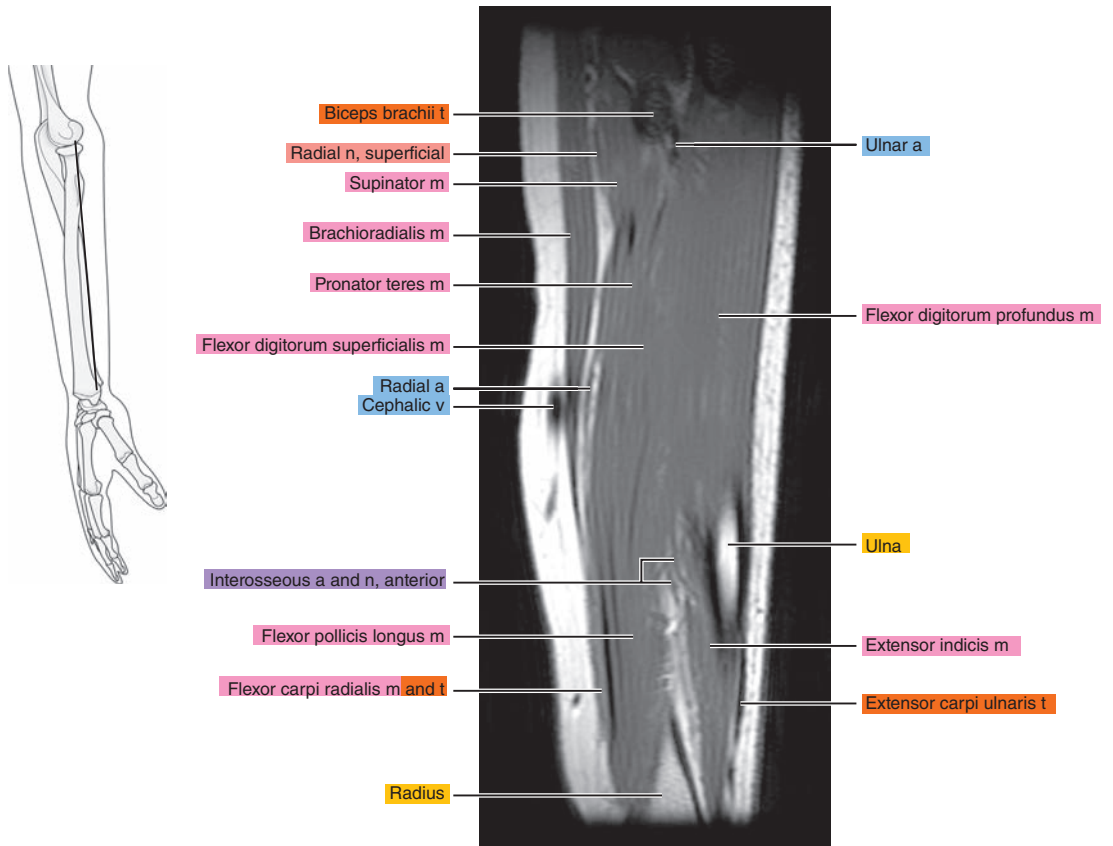


Figure 10.3.9

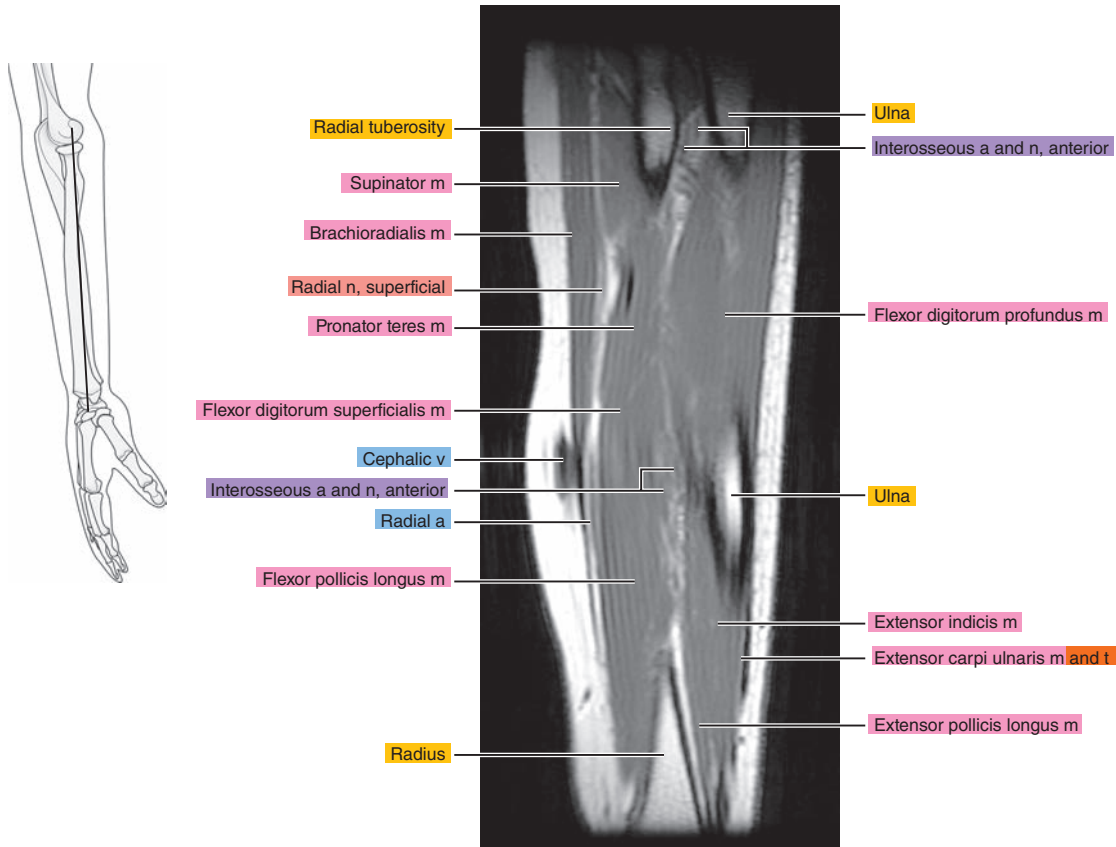


Figure 10.3.10

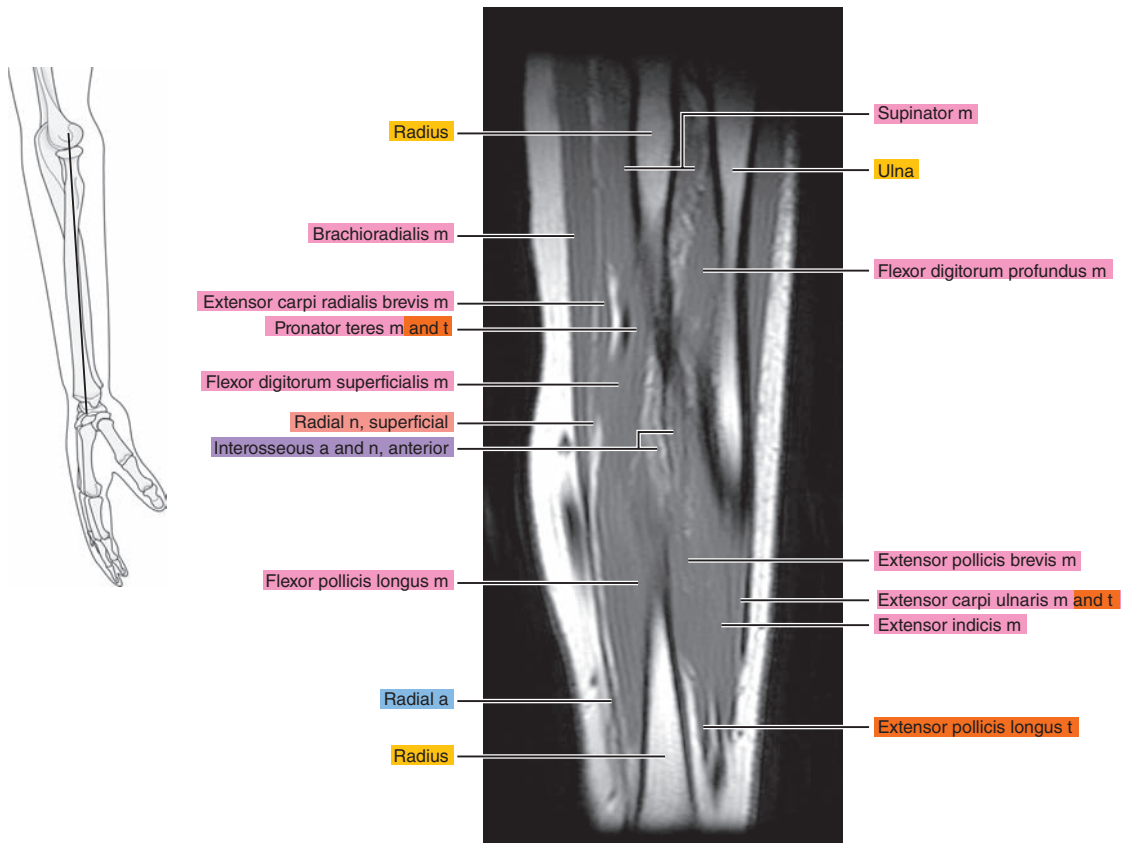


Figure 10.3.11

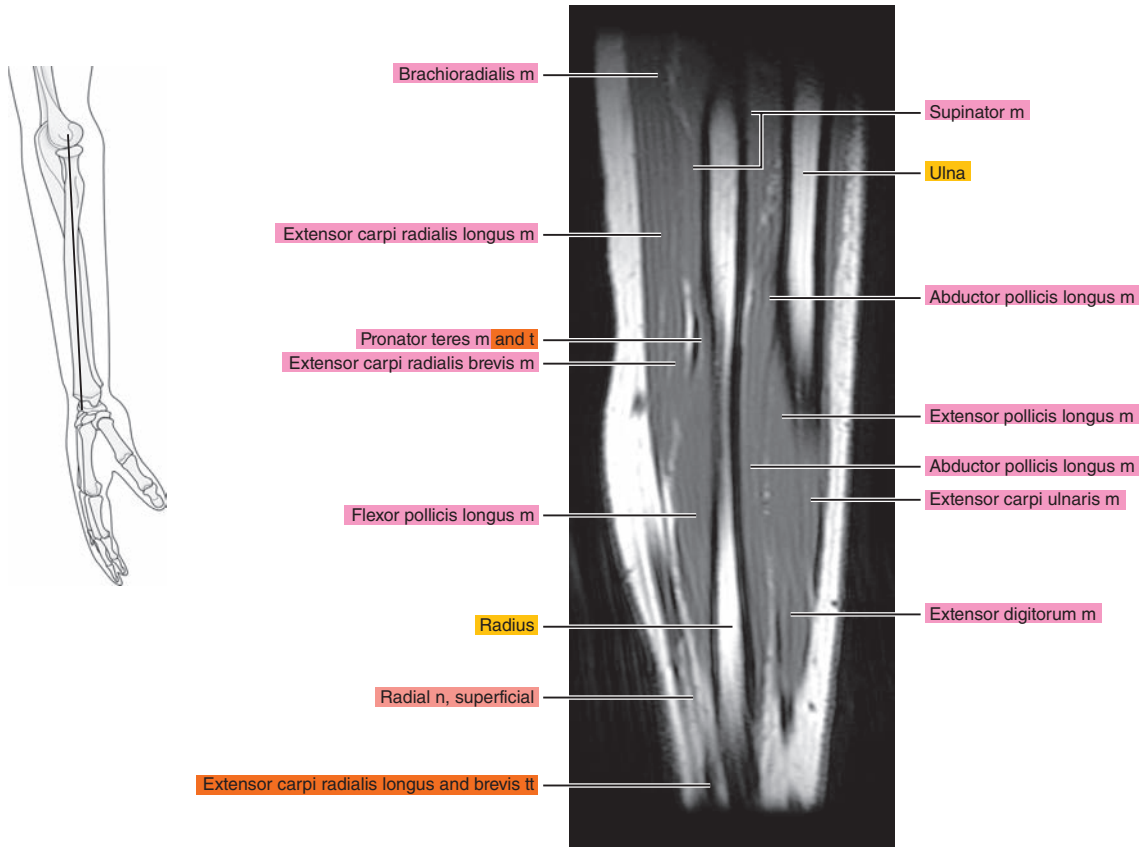


Figure 10.3.12

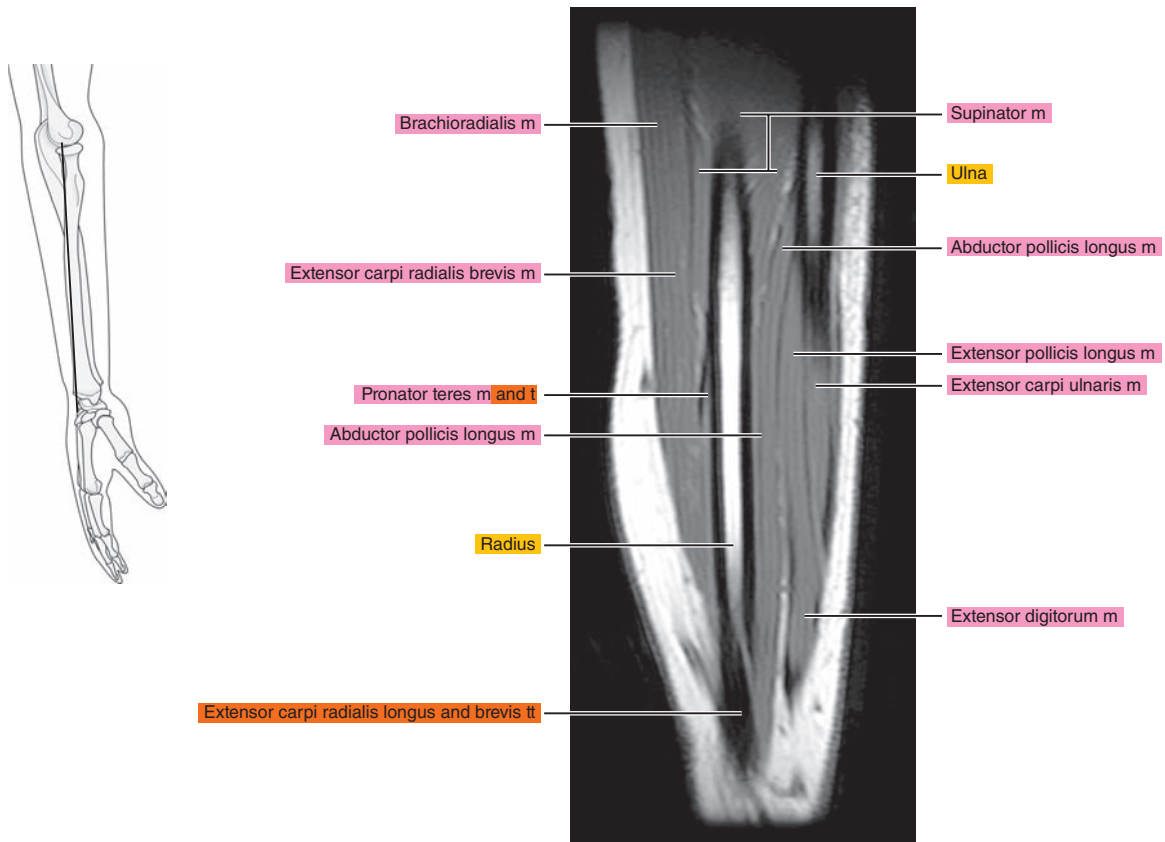




Figure 10.3.13

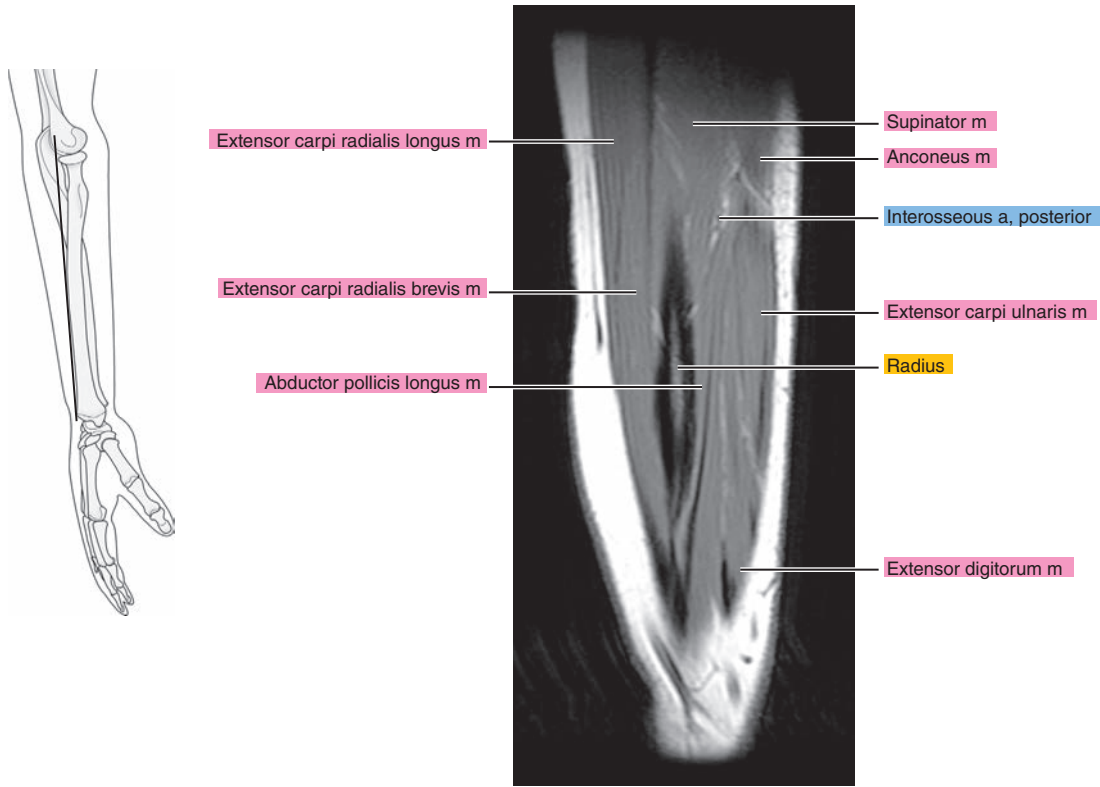


Figure 10.3.14

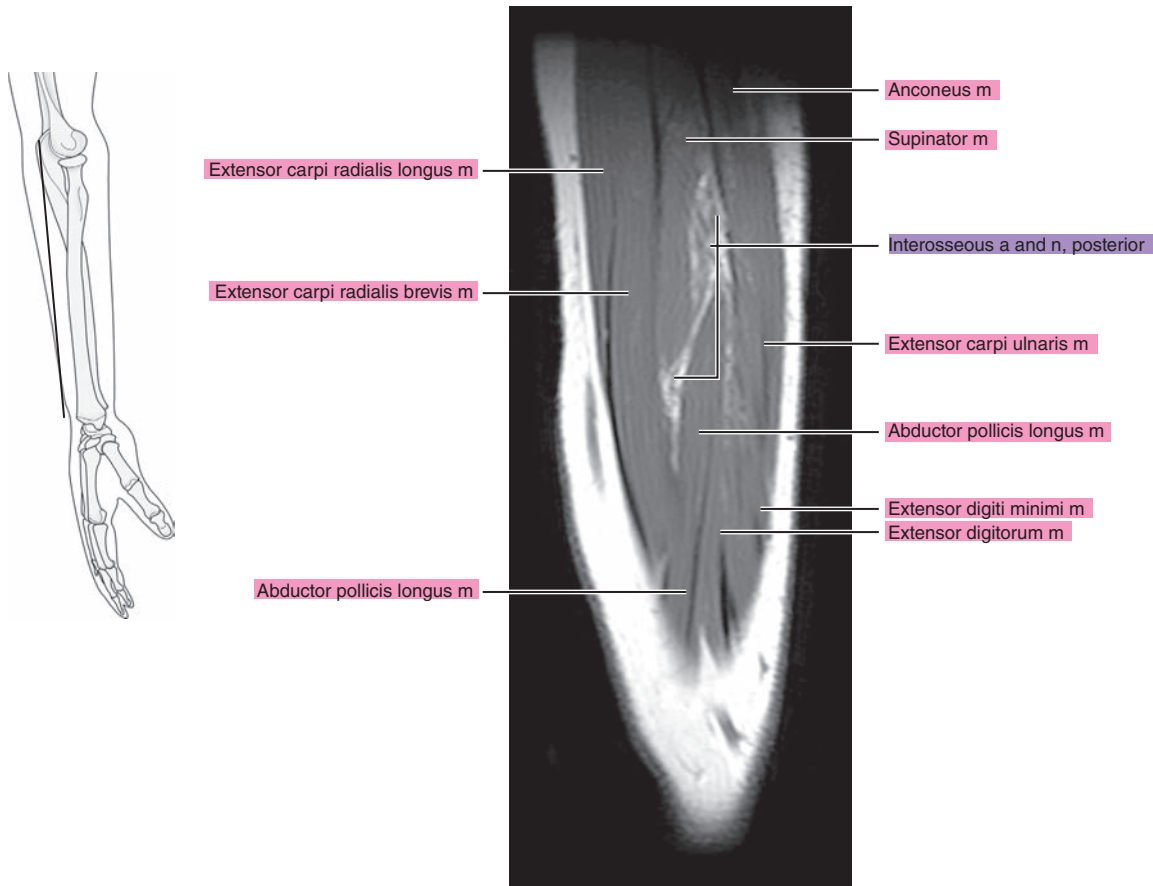


Figure 10.3.15

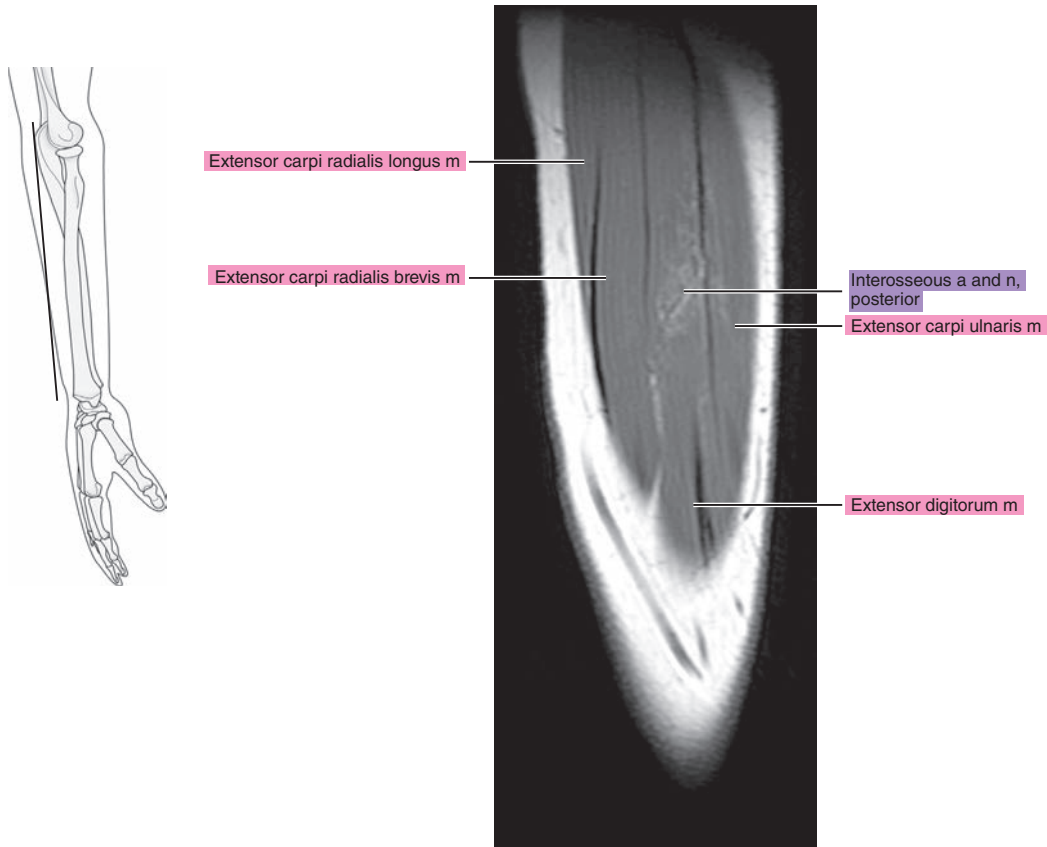
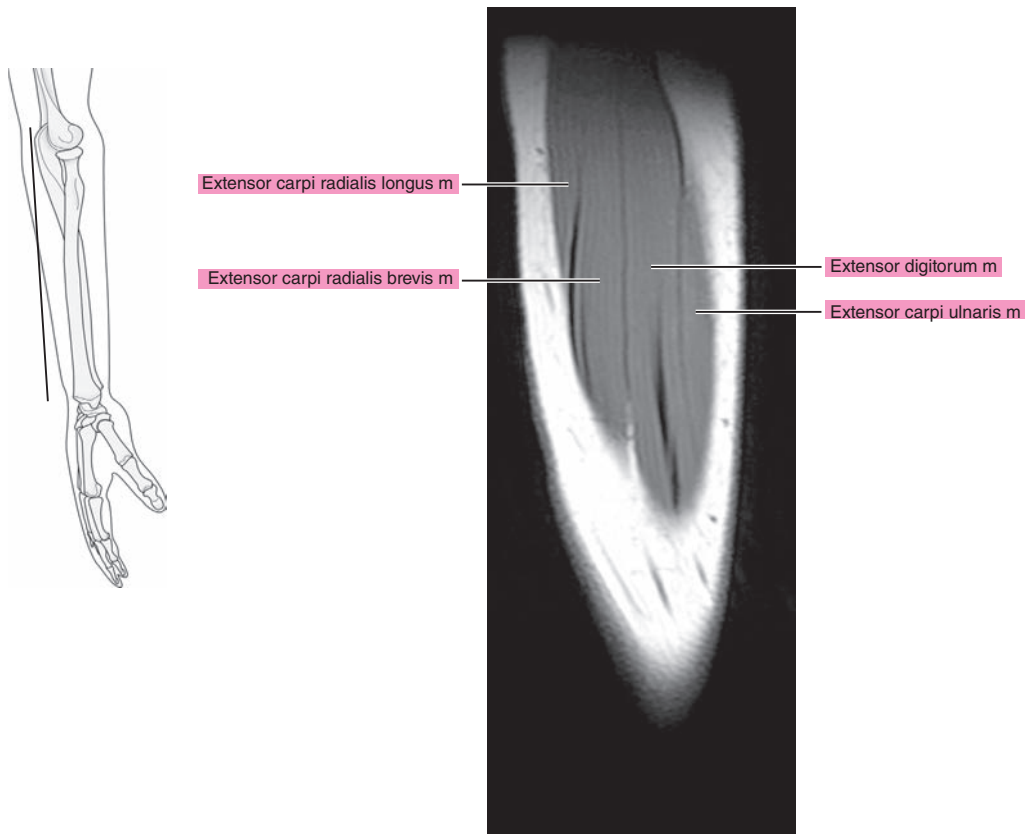


Figure 10.3.16



**Table 10-1. Muscles of the Forearm**

MUSCLE	ORIGIN	INSERTION	NERVE SUPPLY
<b>Anconeus</b>	Posterior surface of the lateral epicondyle and adjacent capsular ligament of the elbow	Onto the radial side of the olecranon and adjacent shaft of the ulna	Nerve to anconeus (C7, C8, and T1)
<b>Brachioradialis</b>	Upper two-thirds of the lateral epicondylar ridge of the humerus and the anterior surface of the lateral intermuscular septum	Lateral side of the base of the styloid process of the radius	Radial (C5, C6, and C7)
<b>Extensor carpi radialis longus</b>	Lower third of the lateral epicondylar ridge, lateral intermuscular septum, and extensor tendons from the lateral epicondyle	Lateral aspect of the base of the second metacarpal	Radial (C5, C6, and C7)
<b>Extensor carpi radialis brevis</b>	Common extensor tendon from the lateral epicondyle, intermuscular septa, and radial collateral ligament of the elbow joint	Dorsal aspect of the base of the third metacarpal	Radial or deep radial (posterior interosseus) (C7 and C8)
<b>Extensor digitorum</b>	Common extensor tendon	Dorsal digital fibrous expansion covering the dorsum of the proximal phalanx and sides of its base, base of the middle, and distal phalanges	Deep radial (posterior interosseus) (C7 and C8)
<b>Extensor digiti minimi</b>	Intermuscular septa, overlying fascia, and common extensor tendon	Base of the proximal phalanx of the little finger	Deep radial (posterior interosseus) (C7 and C8)
<b>Extensor carpi ulnaris</b>	Two heads: (1) distal dorsal aspect of the lateral epicondyle and (2) proximal three-fourths of the dorsal border of the ulna	Onto a tubercle at the base of the fifth metacarpal	Deep radial (posterior interosseus) (C7 and C8)
<b>Supinator</b>	Dorsal aspect of the lateral epicondyle, ulnar depression distal to the radial notch, and supinator crest	Lateral surface of the radius between the anterior and posterior oblique lines	Deep radial (posterior interosseus) (C5 and C6)
<b>Abductor pollicis longus</b>	Lateral edge of the proximal part of the middle third of the ulna, adjacent interosseous membrane, dorsal surface of the radius, and, occasionally, the intermuscular septa	Radial side of the ventral aspect of the base of the first metacarpal	Deep radial (posterior interosseus) (C7 and C8)
<b>Extensor pollicis brevis</b>	Distal end of the middle third of the radius in its dorsal surface, interosseous membrane, and, occasionally, the ulna	Base of the proximal phalanx of the thumb or into the capsule of the metacarpophalangeal joint	Deep radial (posterior interosseus) (C7 and C8)
<b>Extensor pollicis longus</b>	Middle third of the dorsal surface of the ulna adjacent to the interosseous membrane	Base of the distal phalanx of the thumb	Deep radial (posterior interosseus) (C7 and C8)
<b>Extensor indicis</b>	Proximal part of the distal third of the posterior surface of the ulna interosseous membrane	Dorsal aponeurosis on the ulnar side of the index finger, adjacent to the base of the proximal phalanx	Deep radial (posterior interosseus) (C7 and C8)

*continued*

**Table 10-1. Muscles of the Forearm—cont'd**

MUSCLE	ORIGIN	INSERTION	NERVE SUPPLY
<b>Pronator teres</b>	Two heads: (1) humeral head (superior half of the ventral surface of the medial epicondyle) and (2) ulnar head (medial border of the coronoid process)	Onto the middle third of the lateral surface of the radius	Median (C6 and C7)
<b>Flexor carpi radialis</b>	Medial epicondyle of the humerus	Base of the second metacarpal and, usually, base of the third metacarpal	Median (C6 and C7)
<b>Palmaris longus</b>	Medial epicondyle	Flexor retinaculum and palmar aponeurosis	Median (C7 and C8)
<b>Flexor carpi ulnaris</b>	Two heads: (1) medial epicondyle and (2) medial side of the olecranon, upper two-thirds of the dorsal border of the ulna	Primarily onto the pisiform	Ulnar (C7 and C8)
<b>Flexor digitorum superficialis</b>	Two heads: (1) ulnar (ventral surface of the medial epicondyle, ulnar collateral ligament, ulnar tuberosity, medial border of coronoid process) and (2) radial (anterior oblique line and ventral border below the radial oblique line)	Ventral surface of the shaft of the middle phalanx of each finger	Median (C7, C8, and T1)
<b>Flexor digitorum profundus</b>	Proximal three-fourths of the medial and anterior surface of the ulna and interosseous membrane	Bases of the distal phalanges of the second to fifth digits	Median, anterior interosseous branch (C8 and T1)
<b>Flexor pollicis longus</b>	Ventral surface of the radius, oblique line, and adjacent interosseous membrane	Base of the distal phalanx of the thumb	Median, anterior interosseous branch (C8 and T1)
<b>Pronator quadratus</b>	Medial side and ventral surface of the distal fourth of the ulna	Distal quarter of the ventral surface of the radius	Median, anterior interosseous branch (C8 and T1)



*Chapter*  
**11**

**MRI of the Wrist**

# AXIAL

Figure 11.1.1

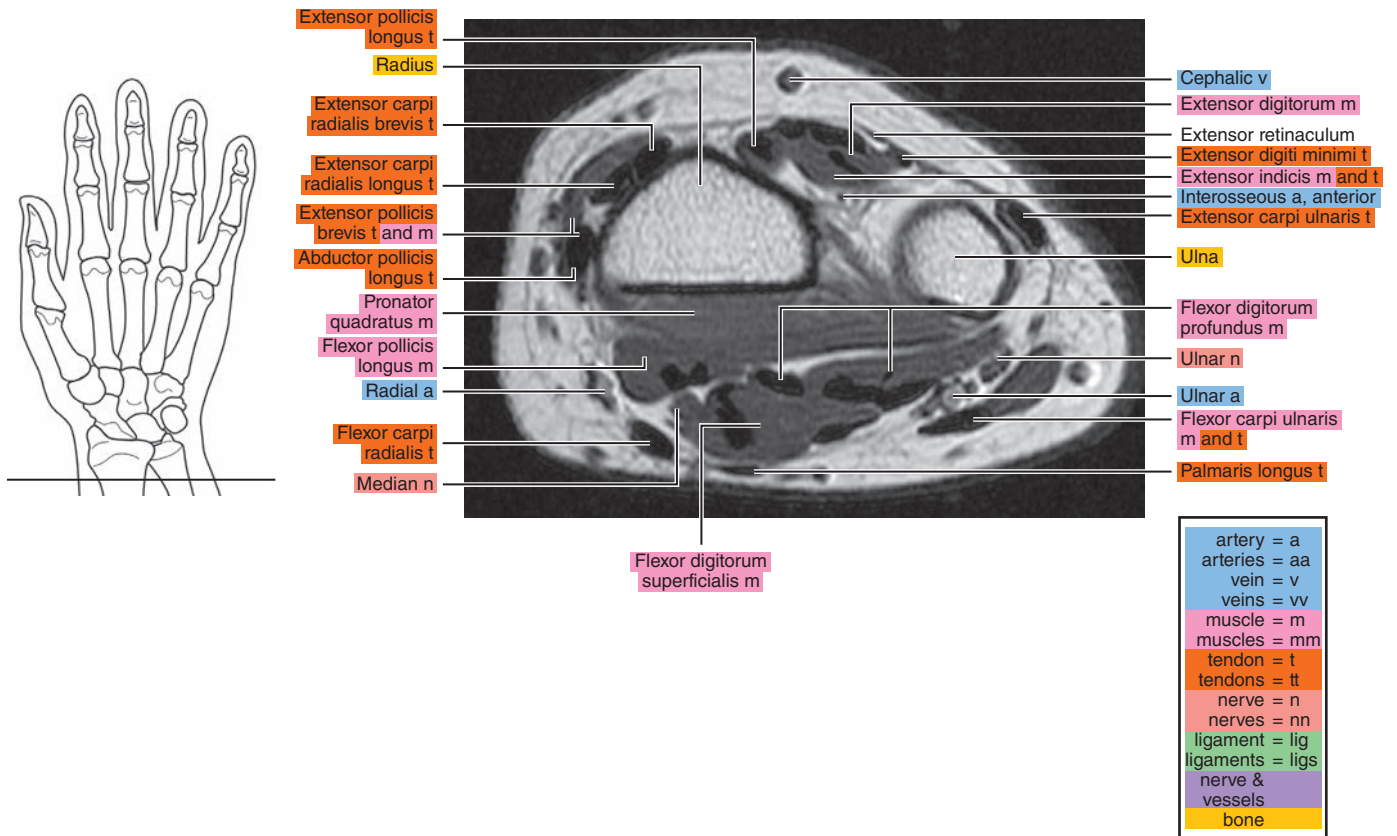


Figure 11.1.2

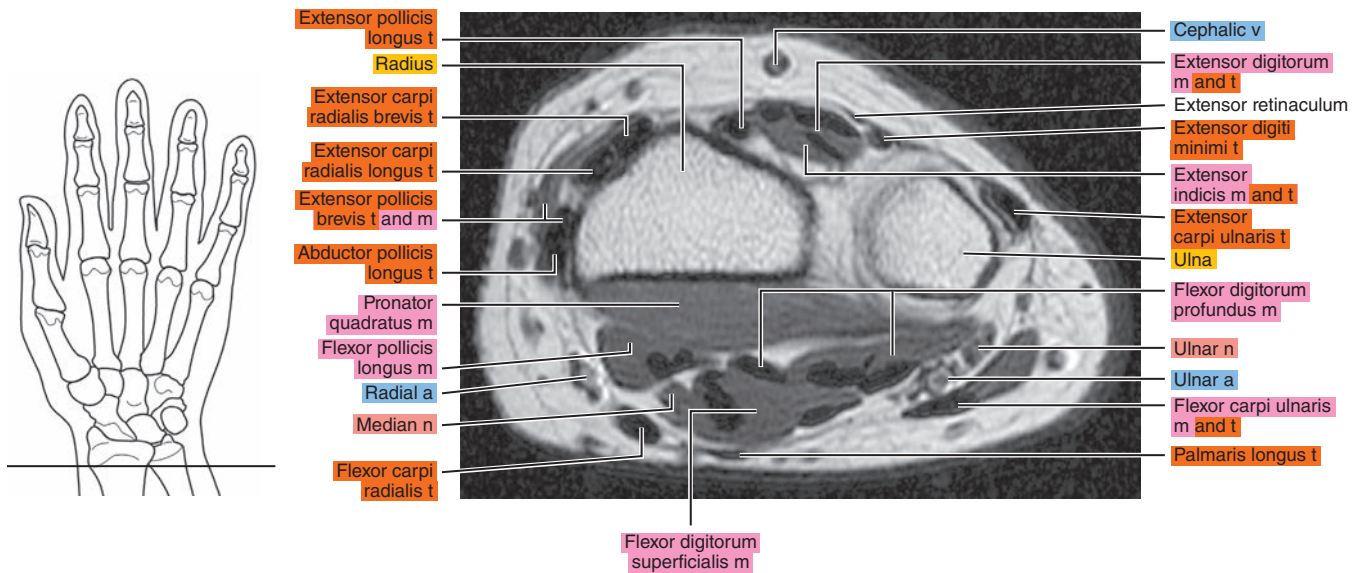


Figure 11.1.3

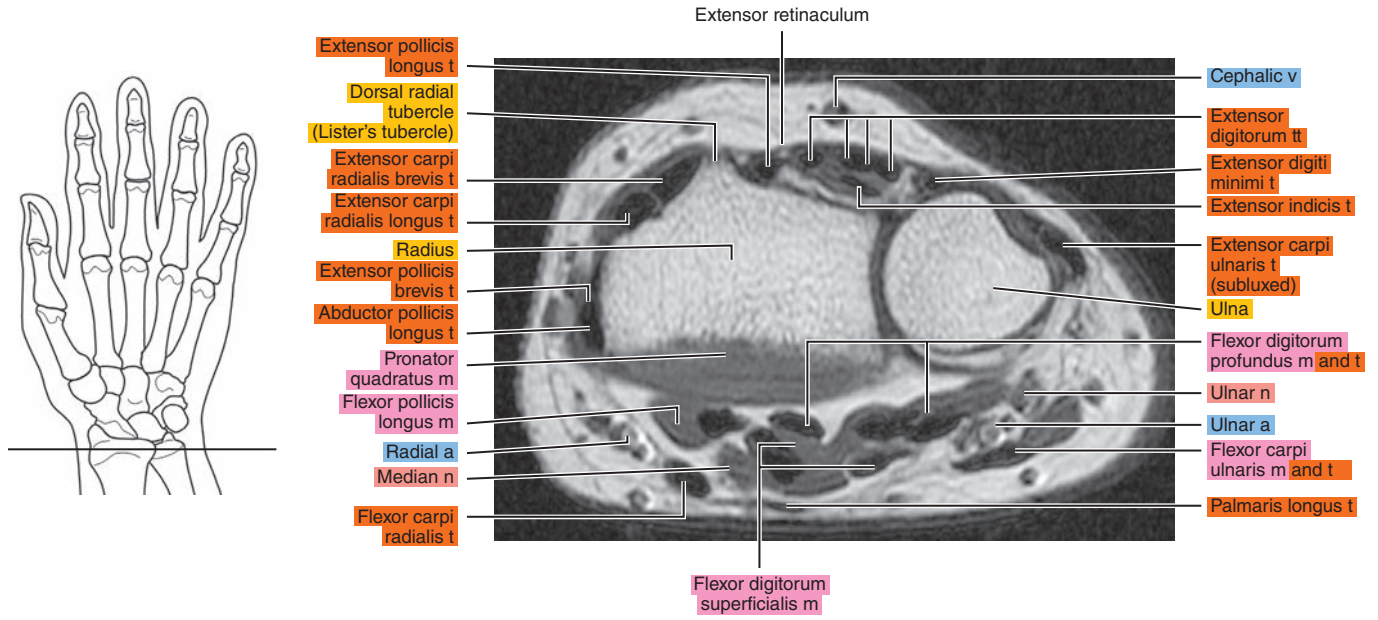


Figure 11.1.4

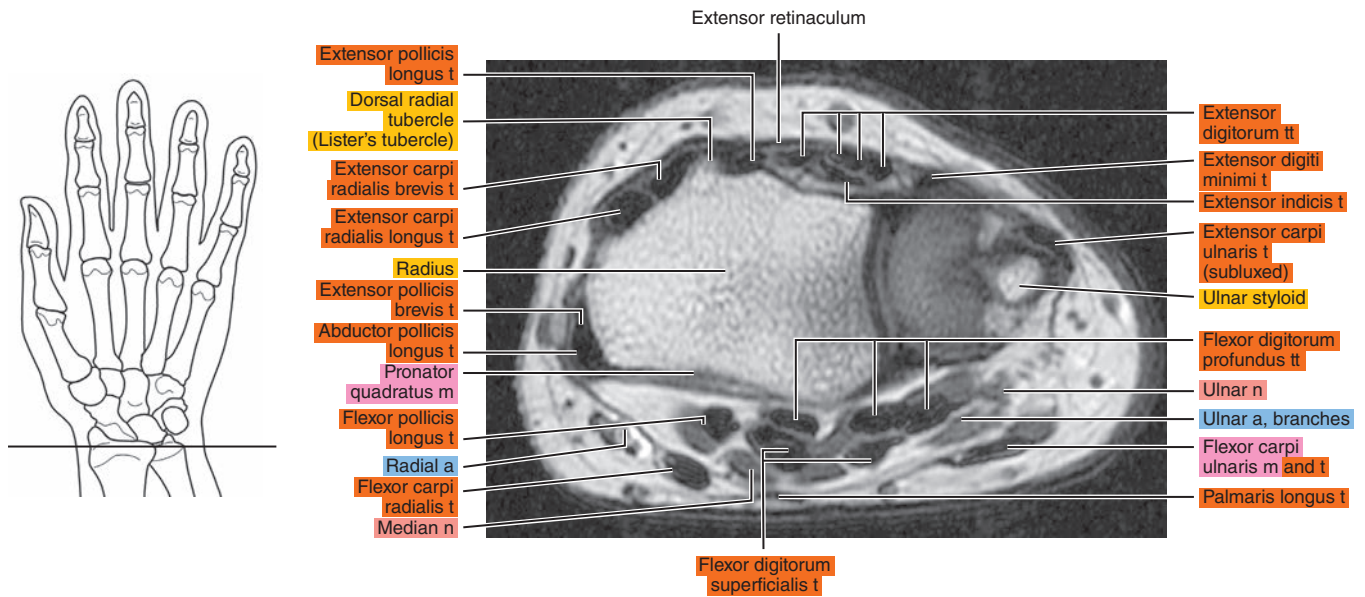


Figure 11.1.5

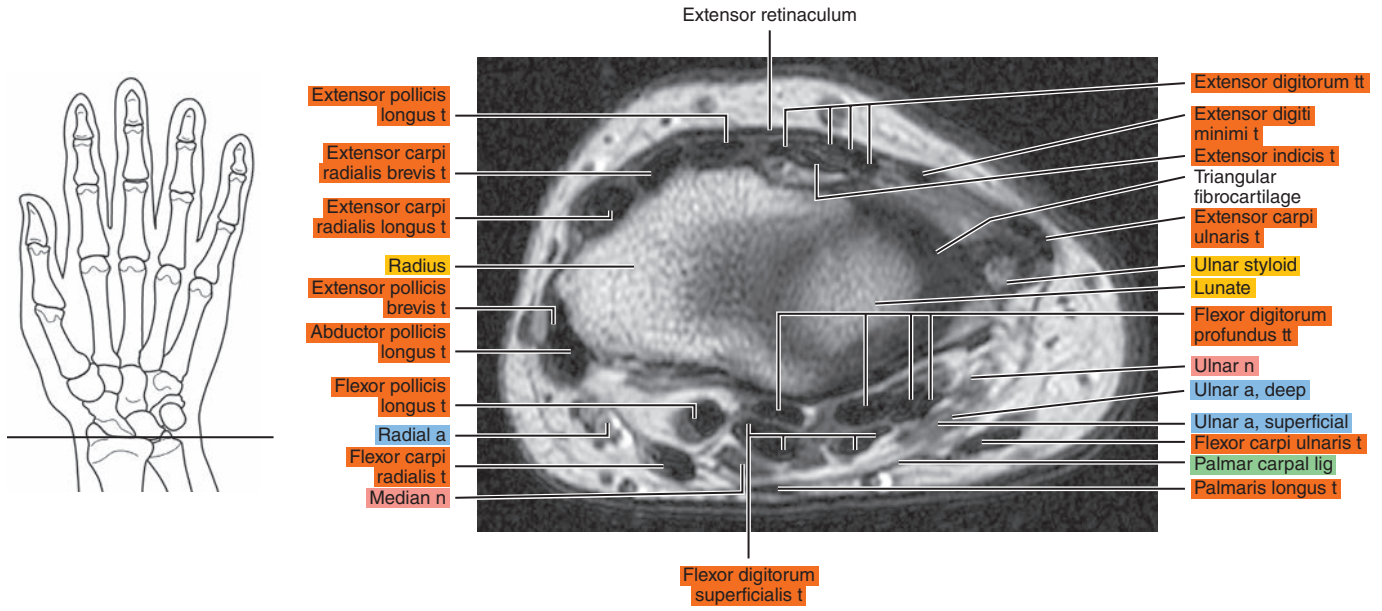


Figure 11.1.6

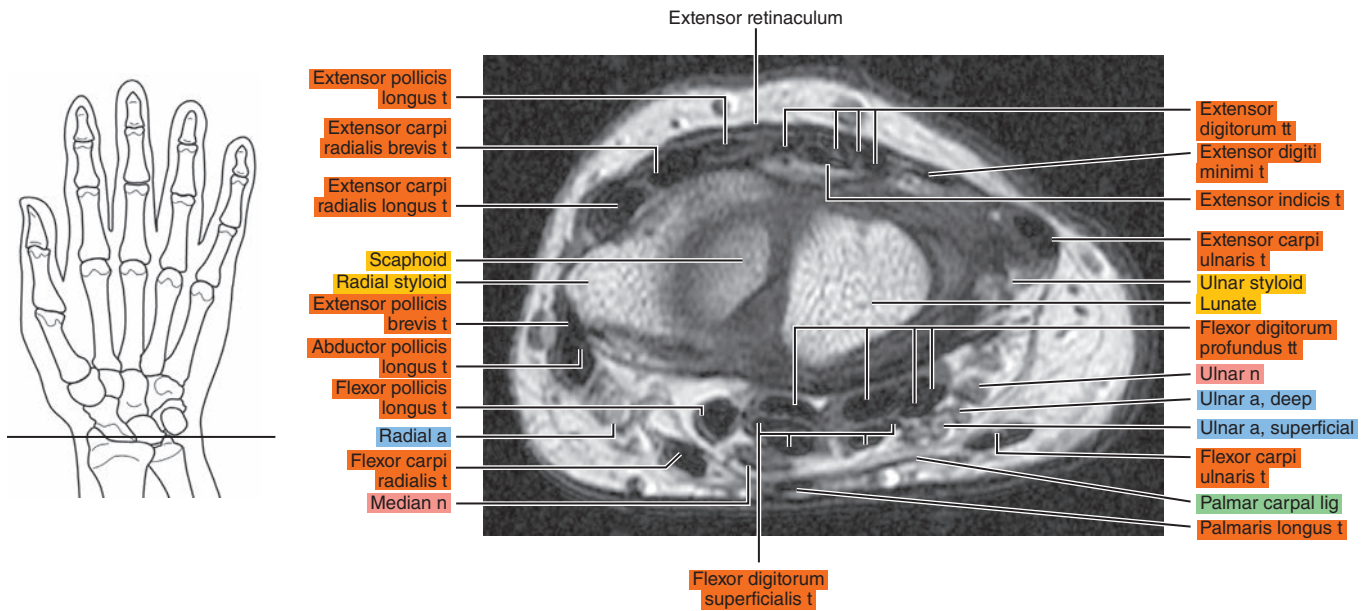




Figure 11.1.7

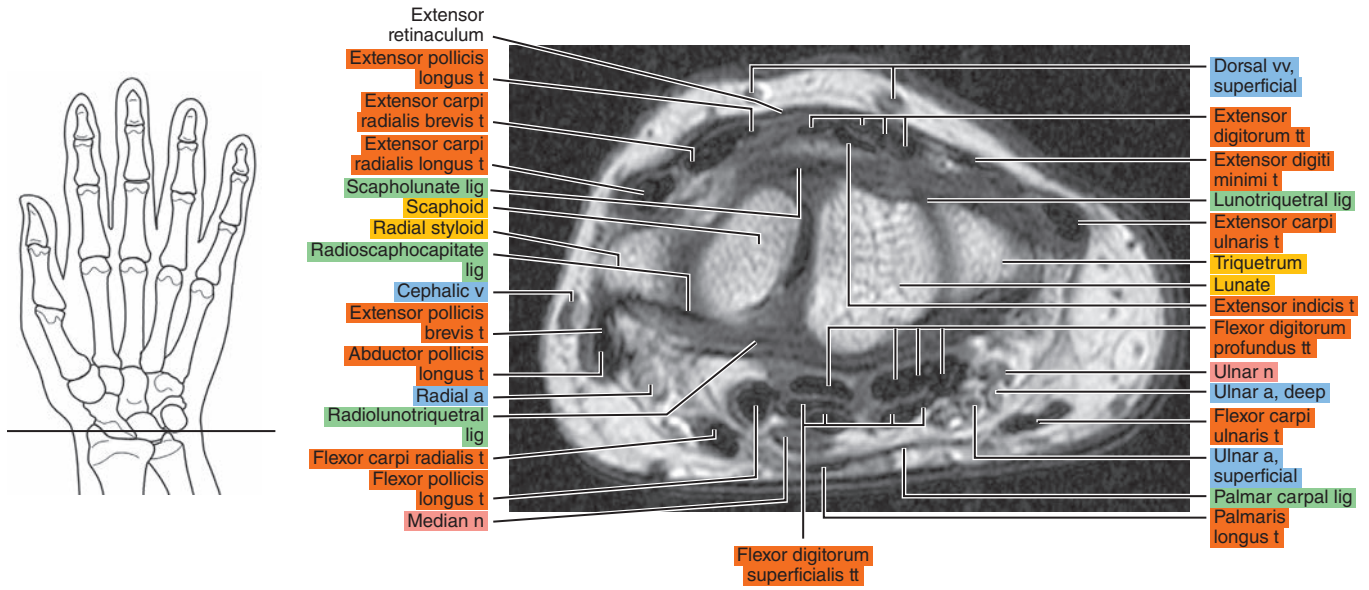


Figure 11.1.8

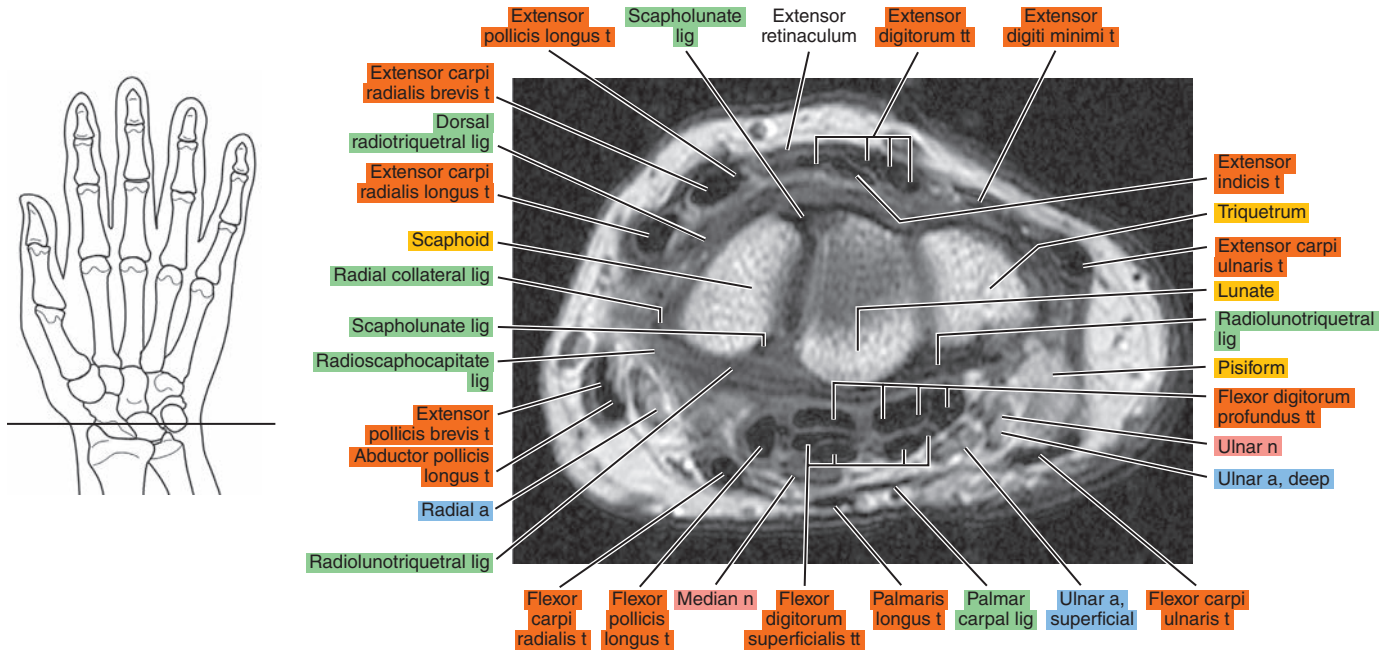


Figure 11.1.9

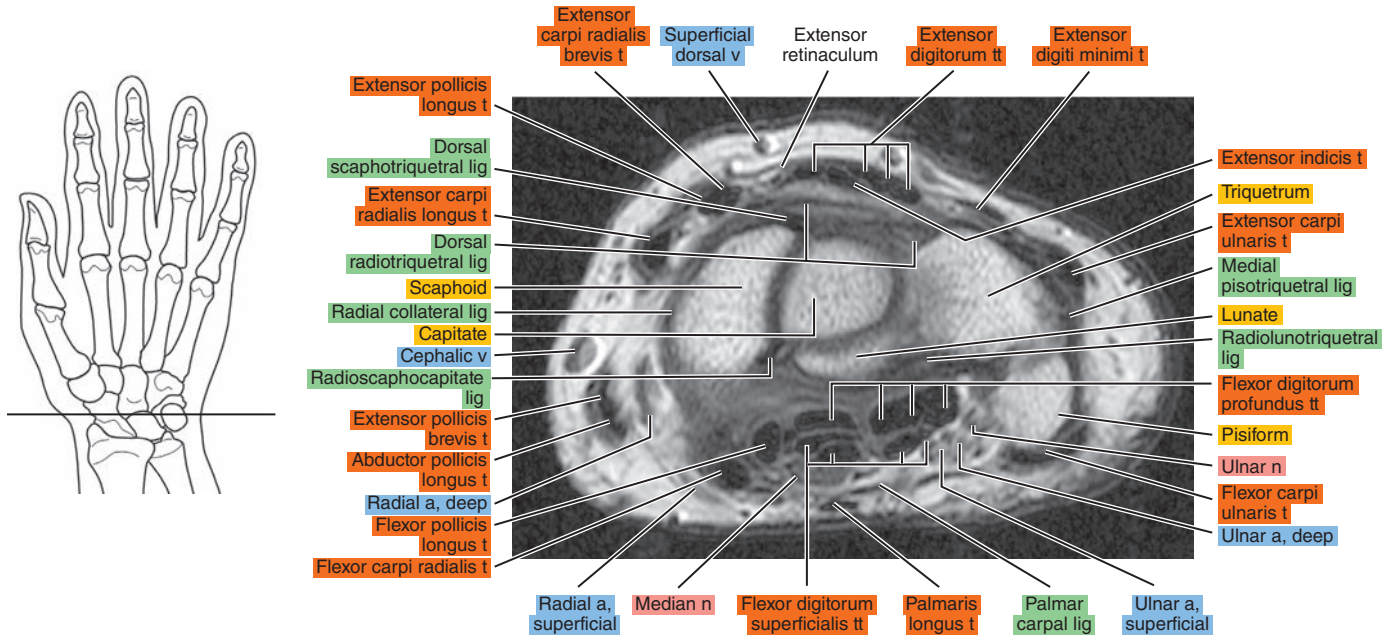


Figure 11.1.10

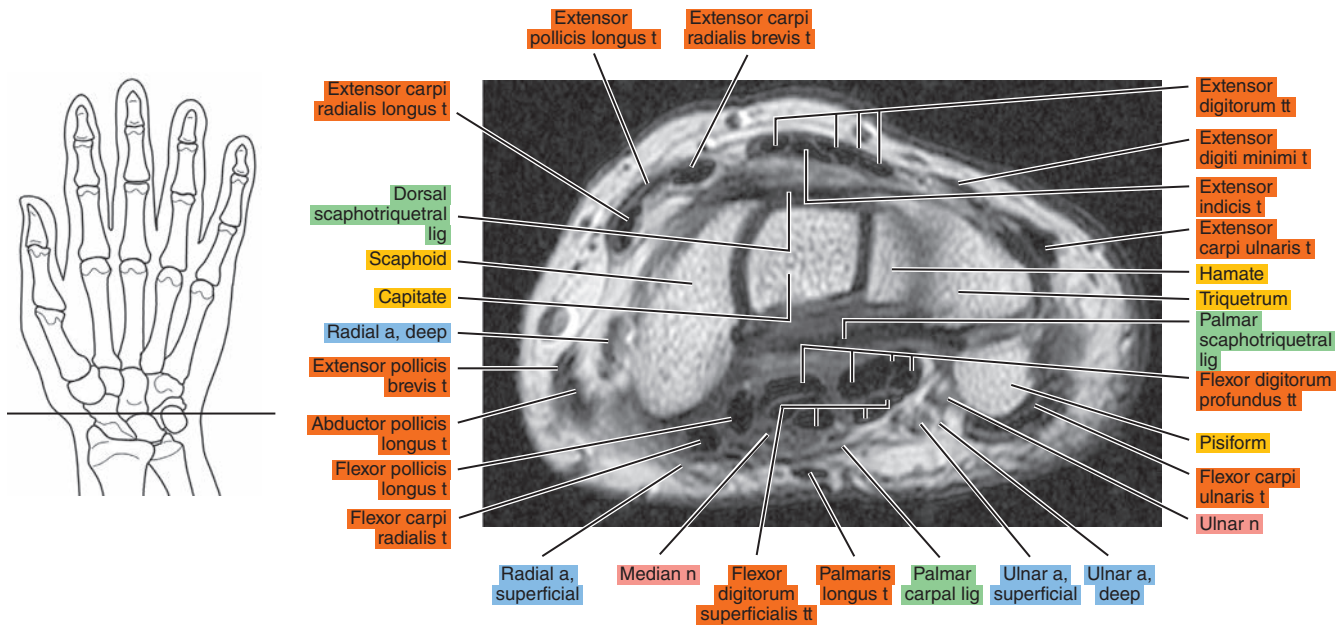


Figure 11.1.11

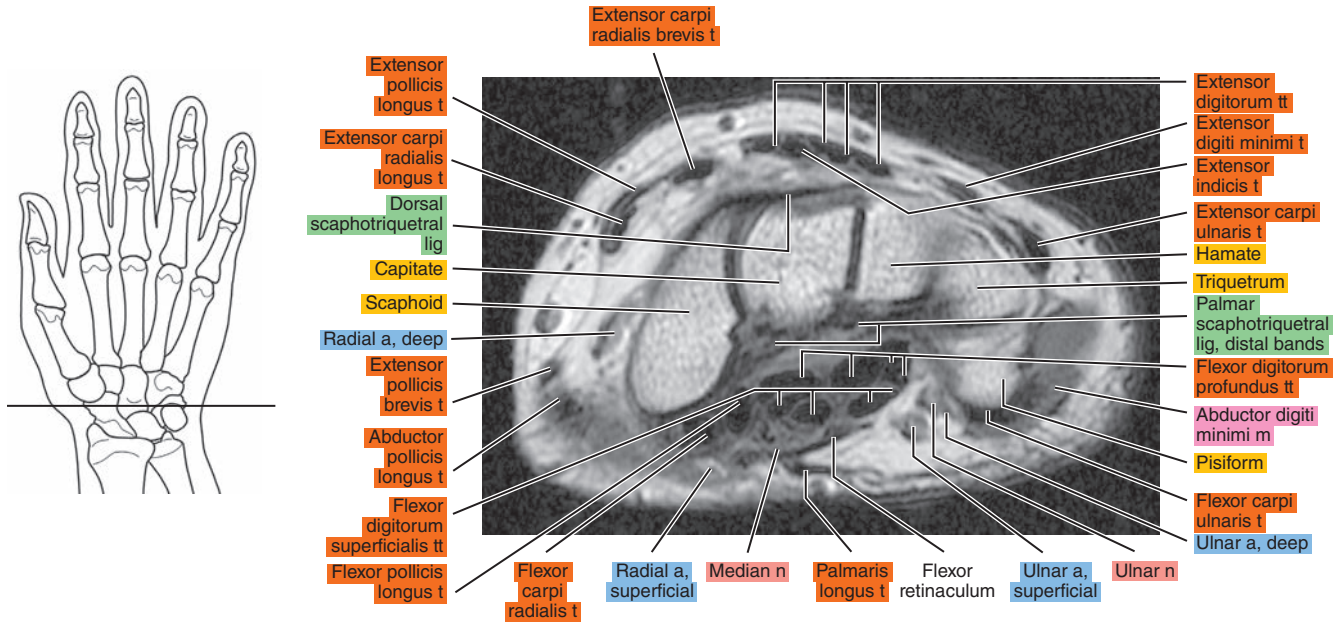


Figure 11.1.12

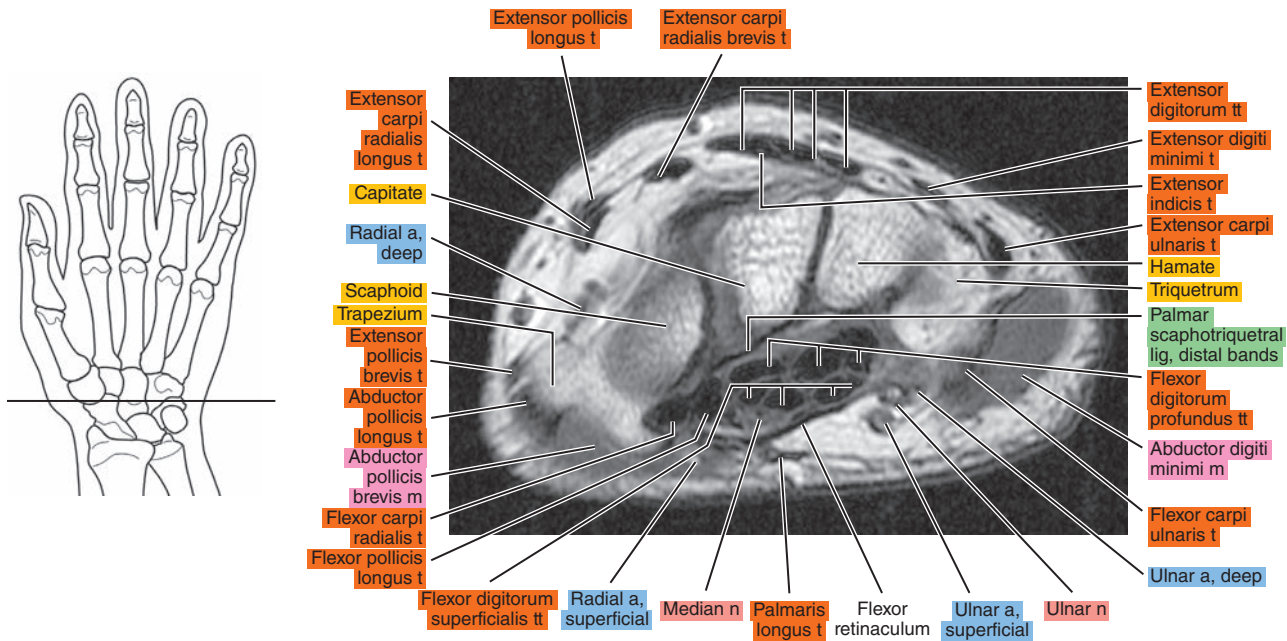




Figure 11.1.13

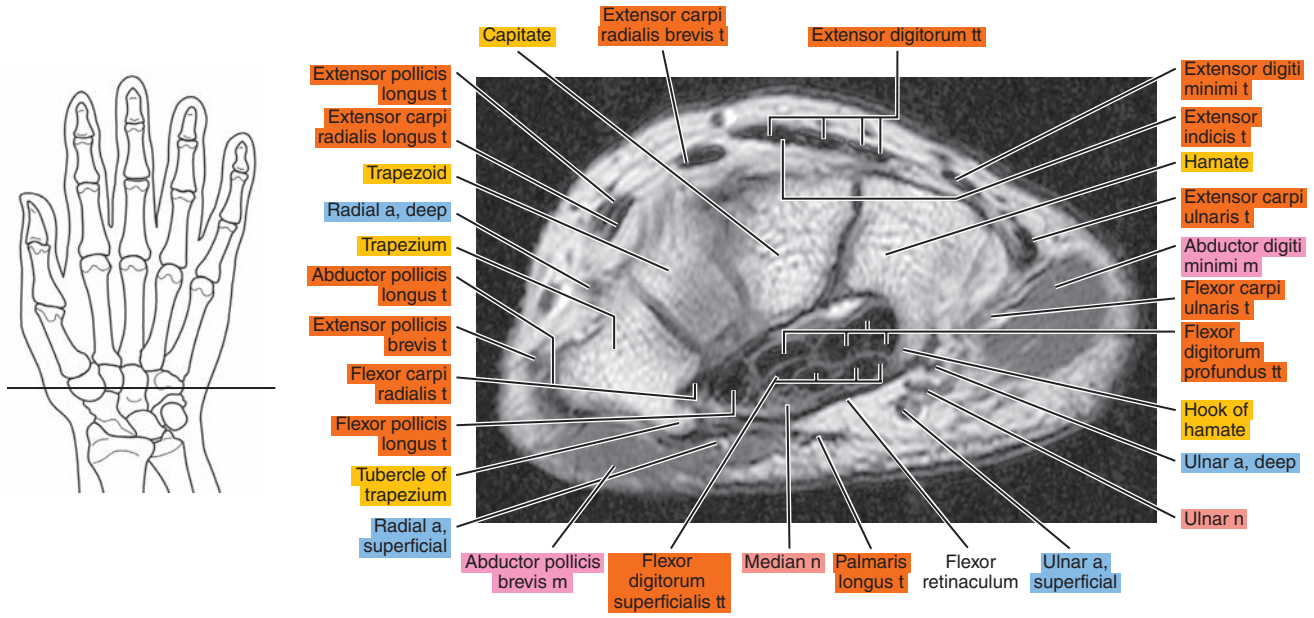


Figure 11.1.14

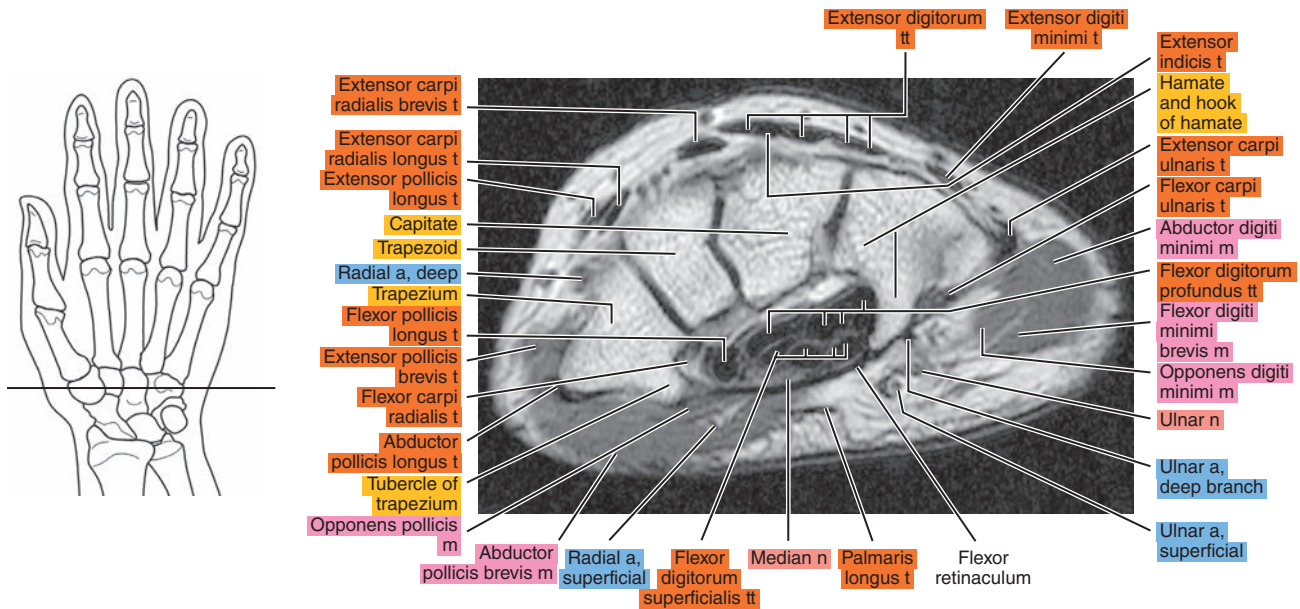




Figure 11.1.15

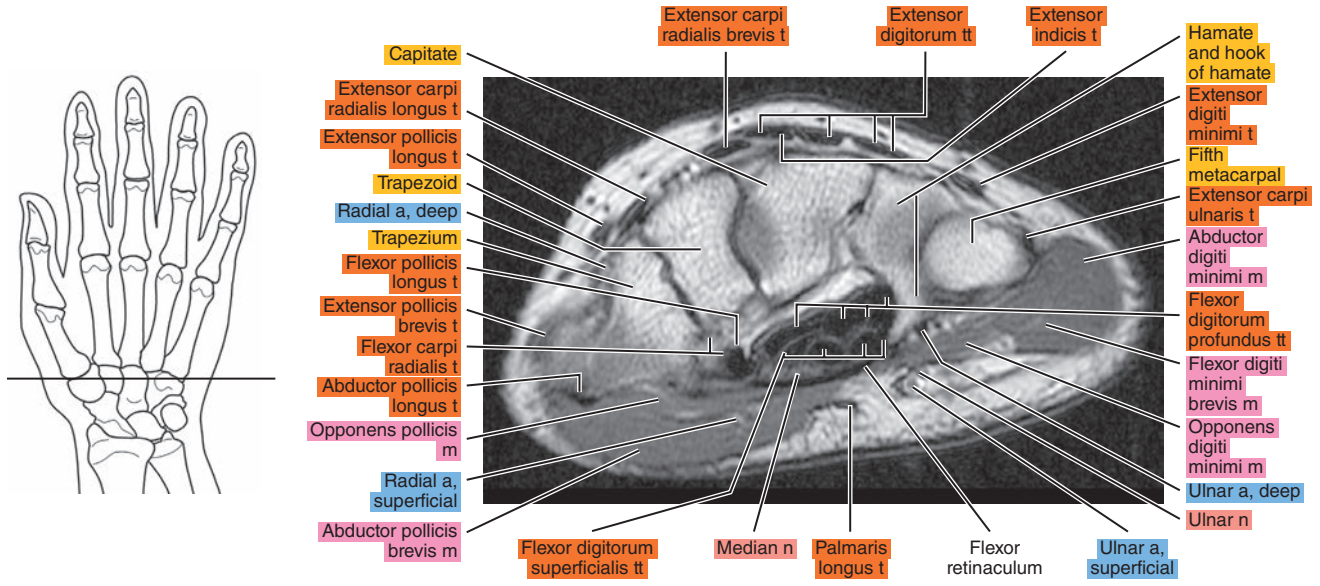


Figure 11.1.16

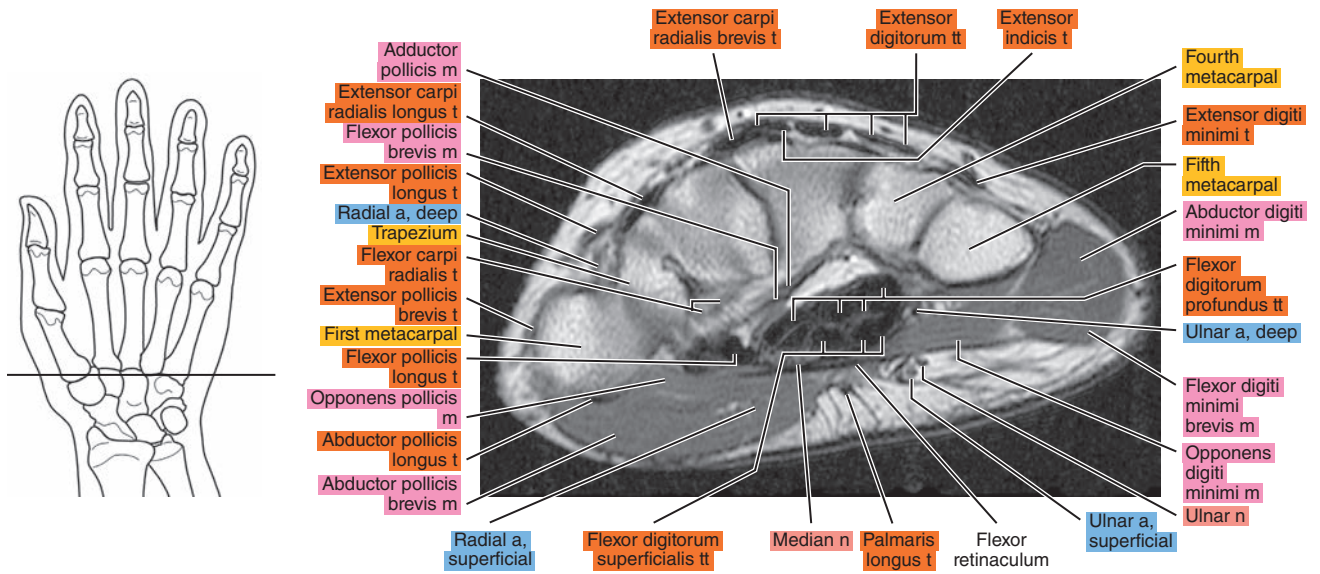


Figure 11.1.17

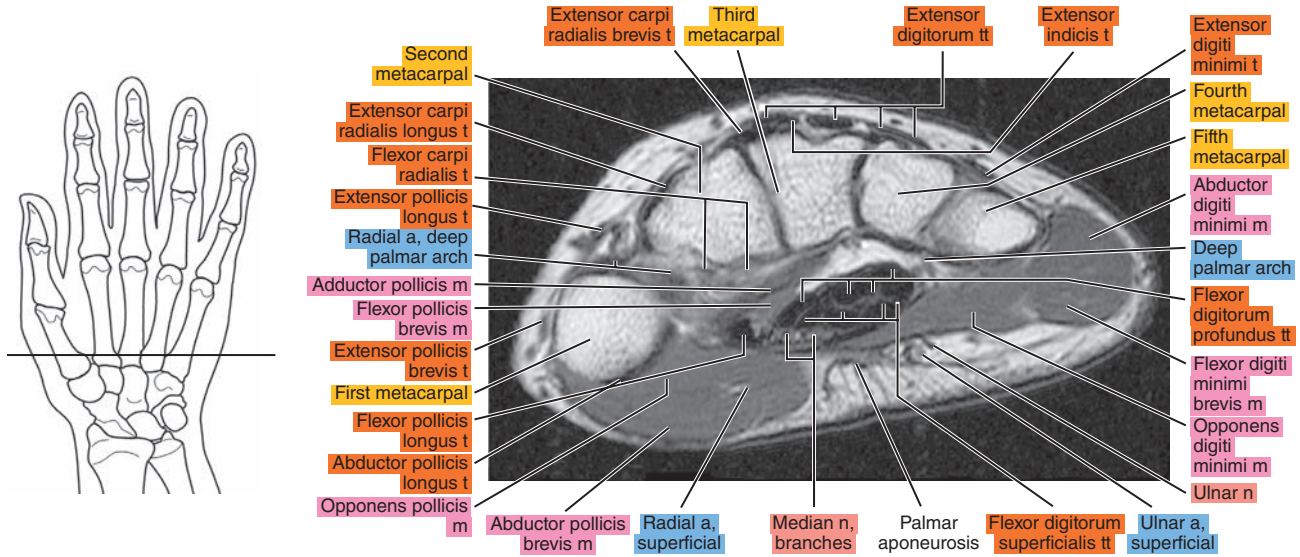
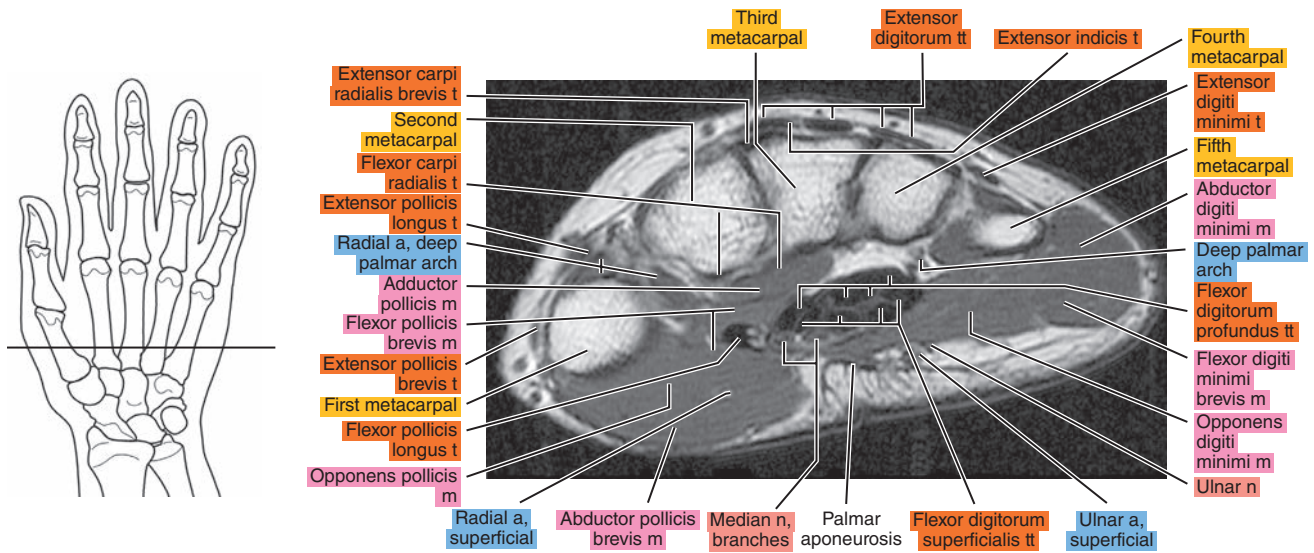


Figure 11.1.18



# SAGITTAL

Figure 11.2.1

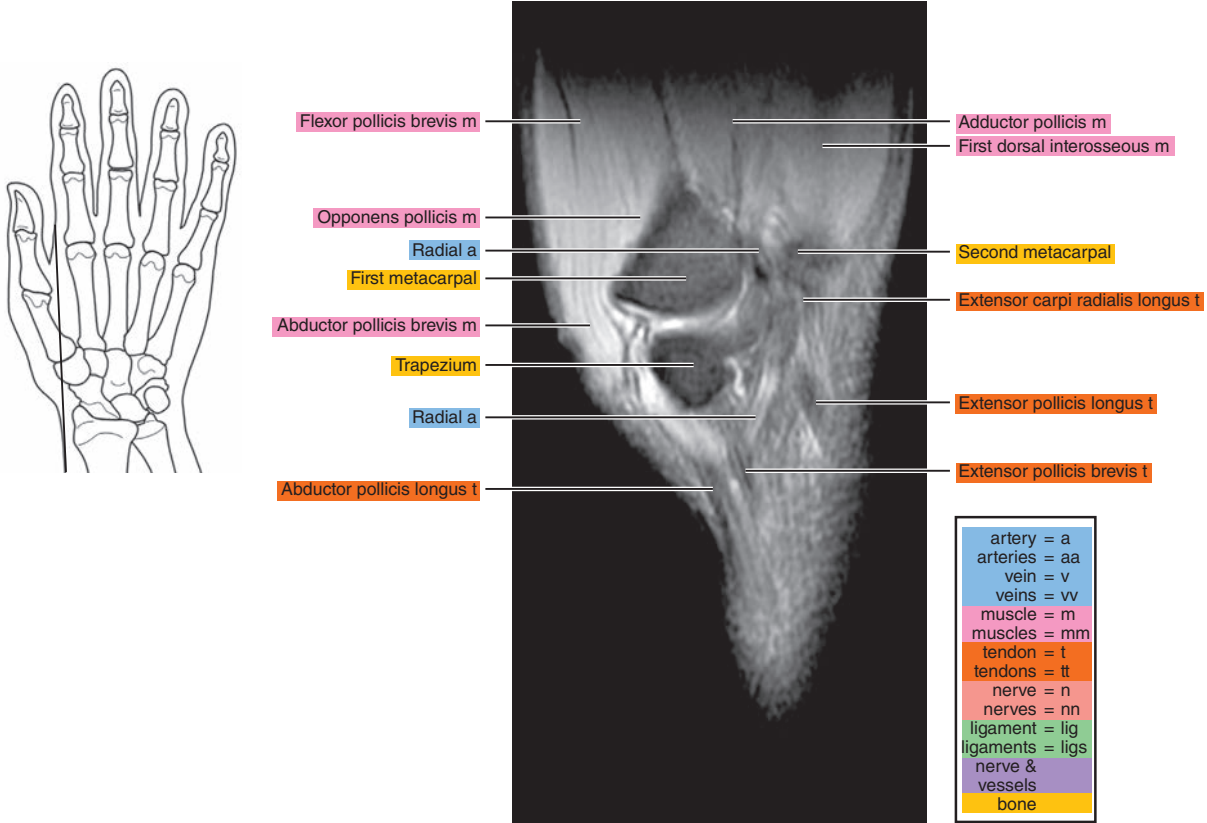


Figure 11.2.2

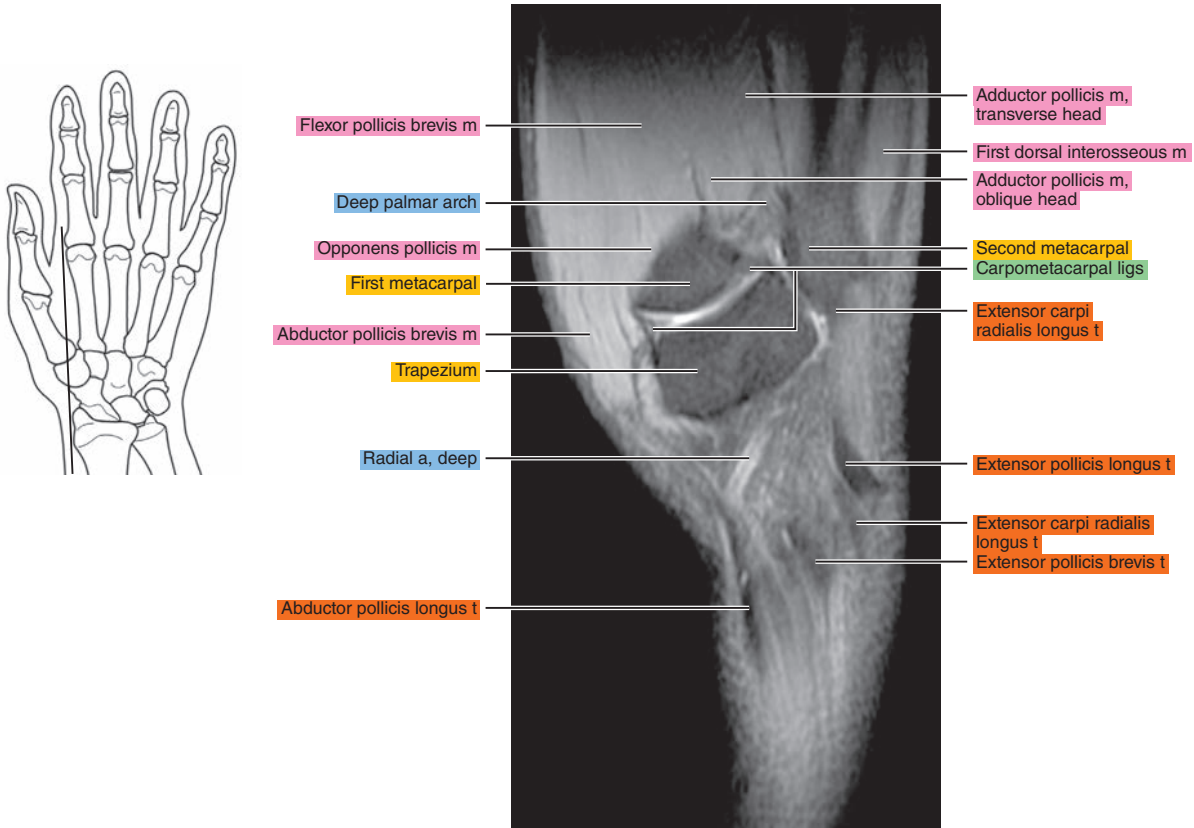




Figure 11.2.3

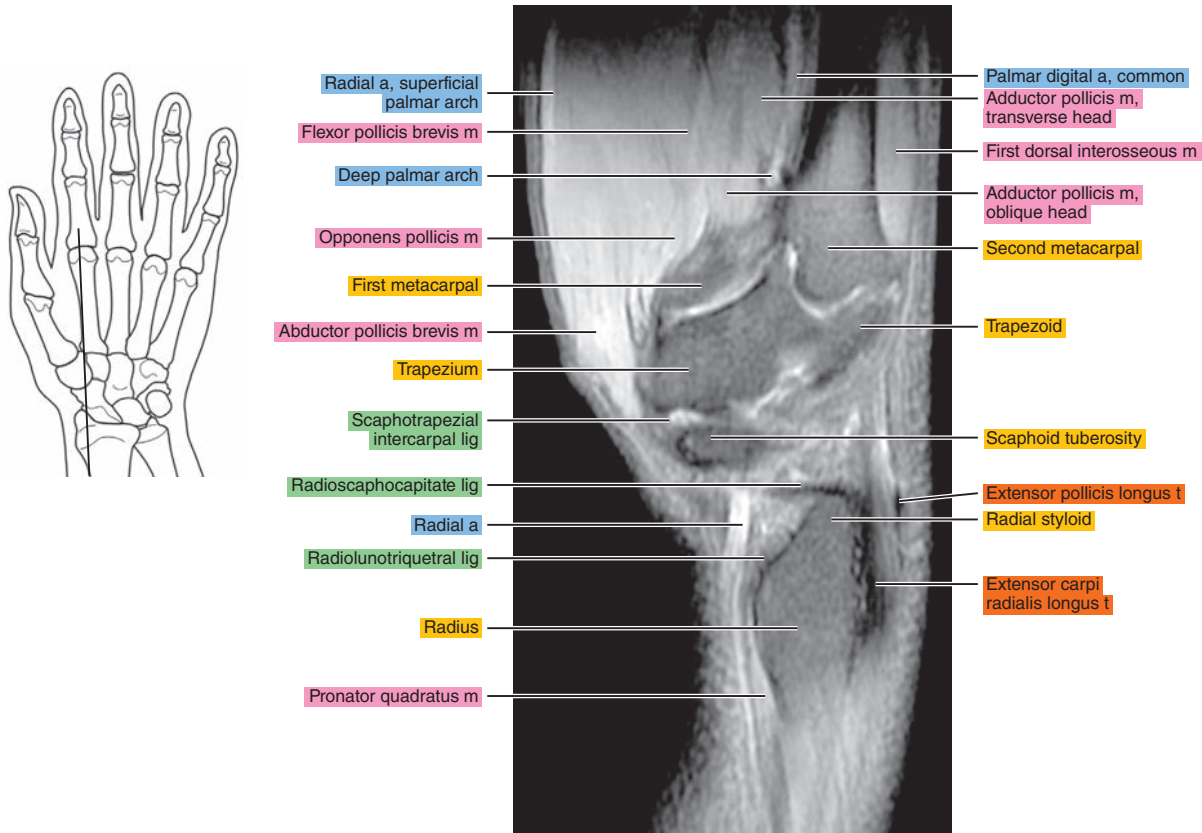


Figure 11.2.4

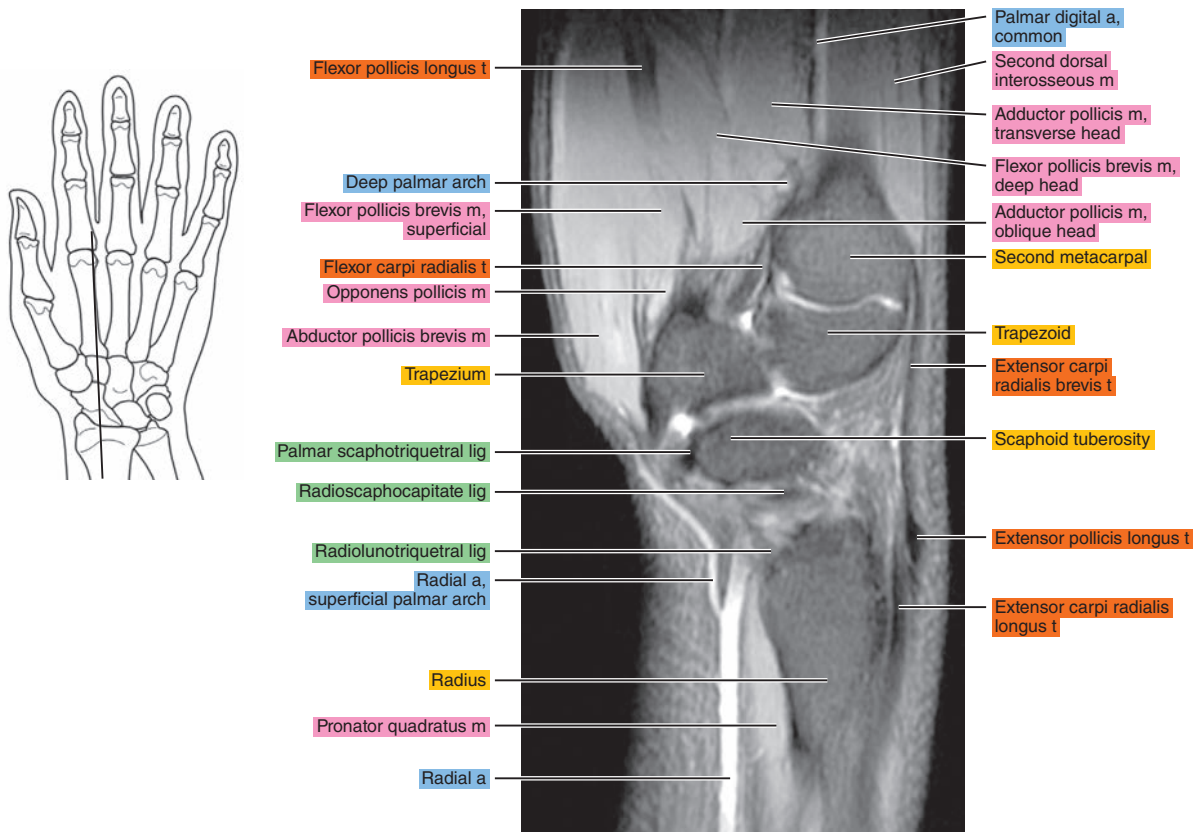




Figure 11.2.5

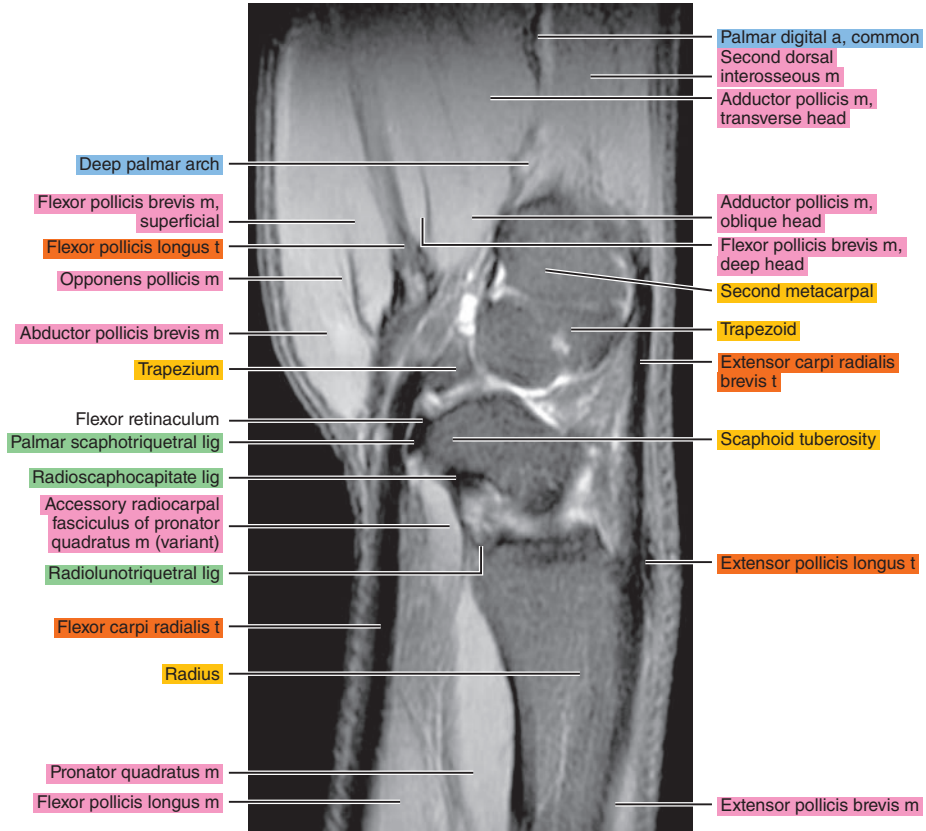
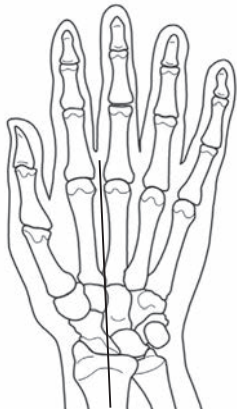

Figure 11.2.6

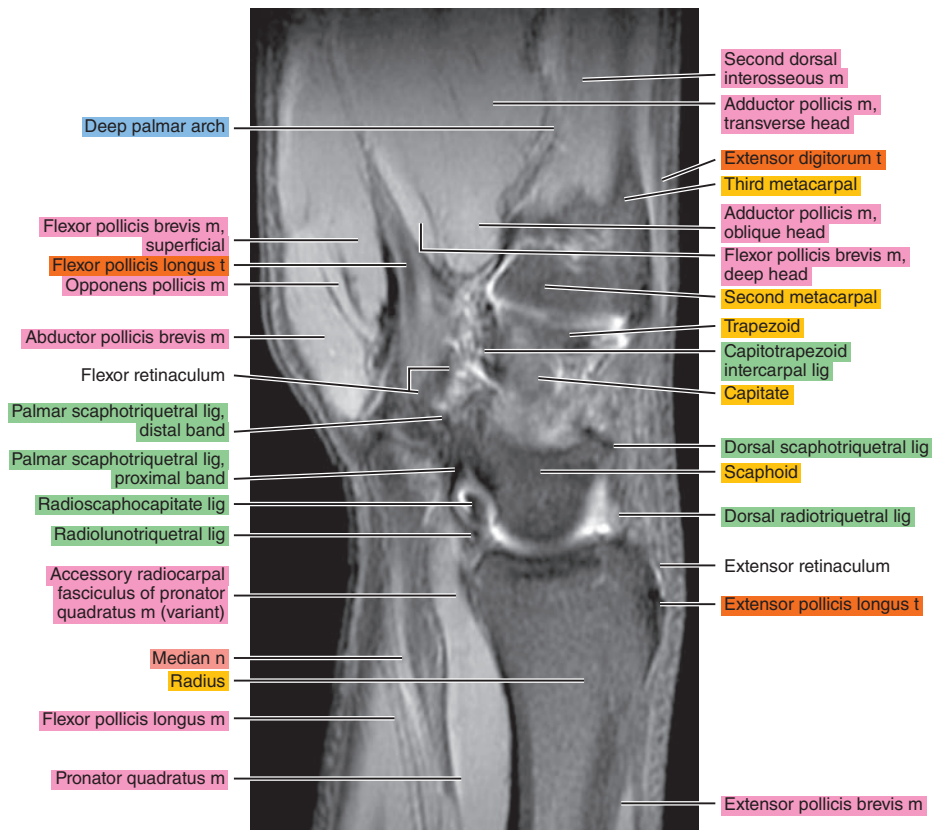
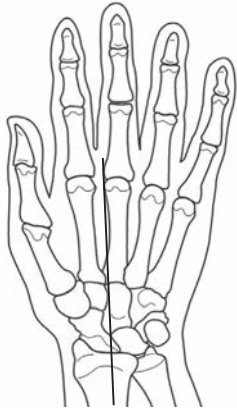

Figure 11.2.7

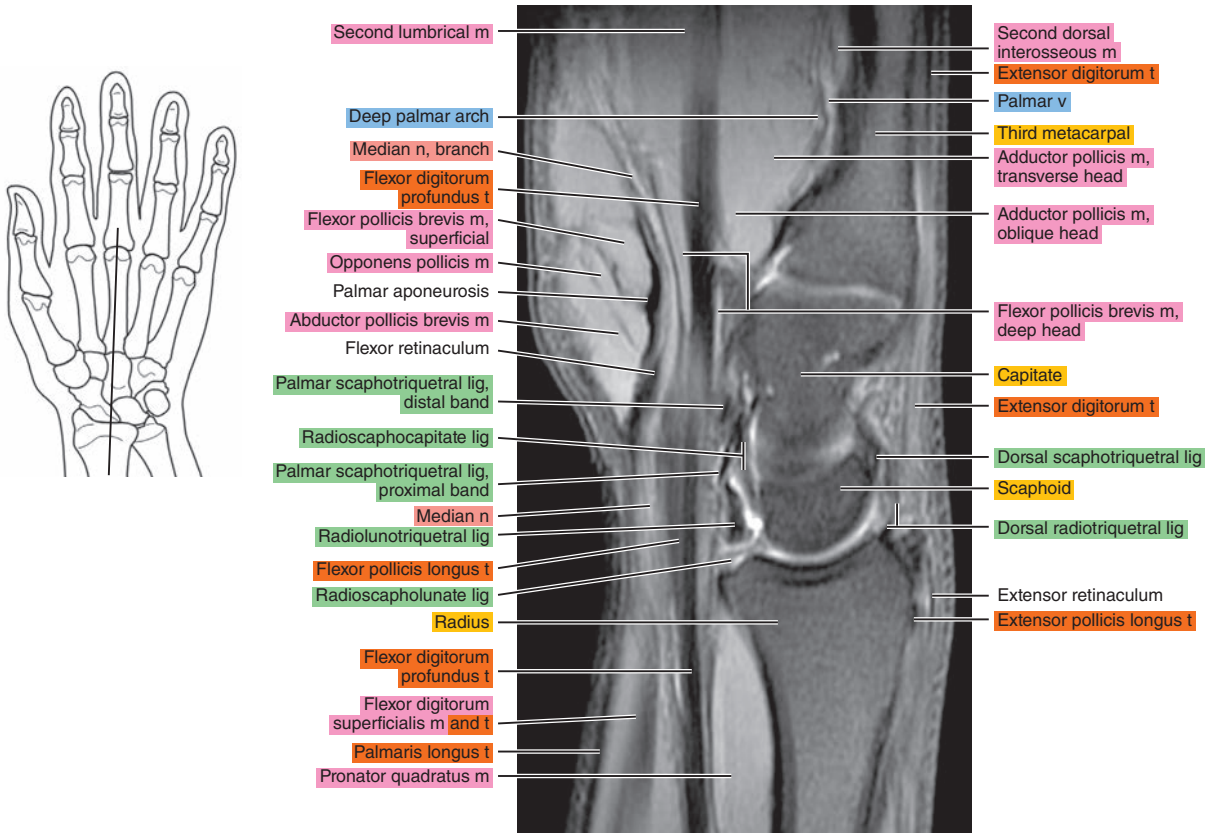


Figure 11.2.8

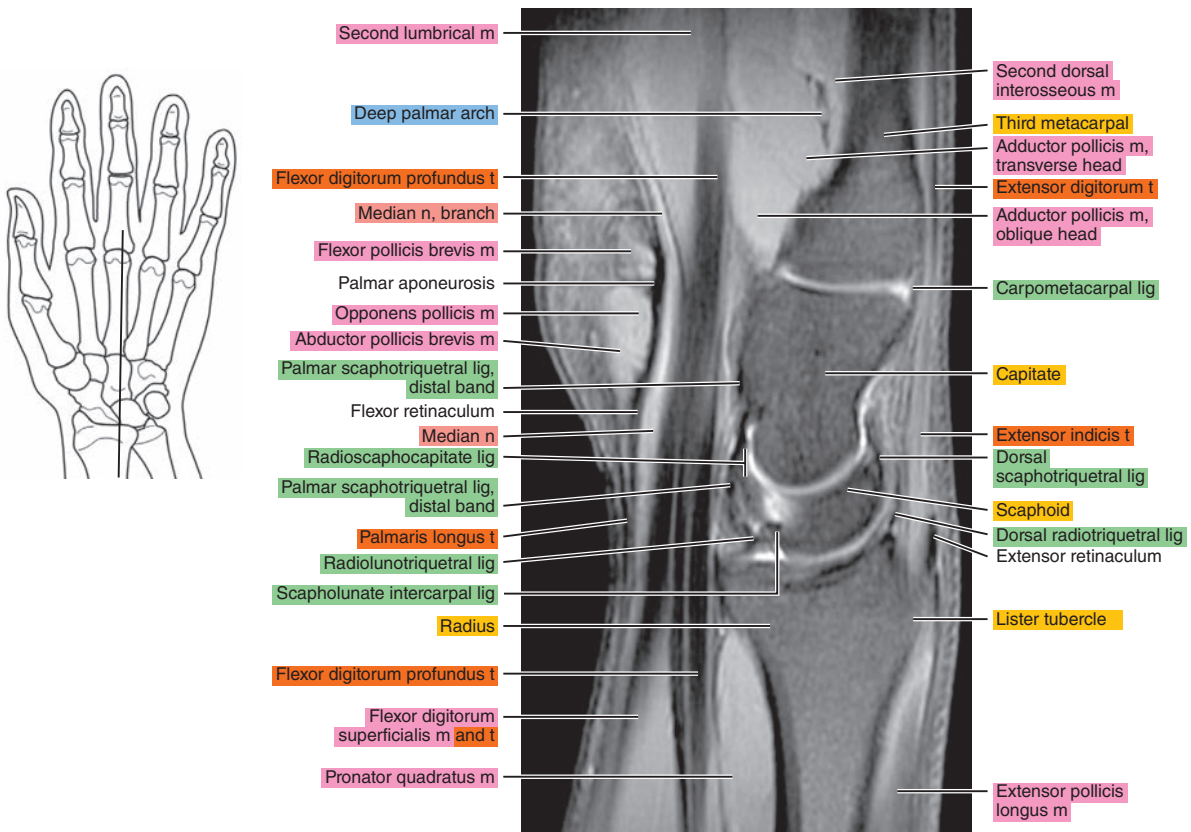


Figure 11.2.9

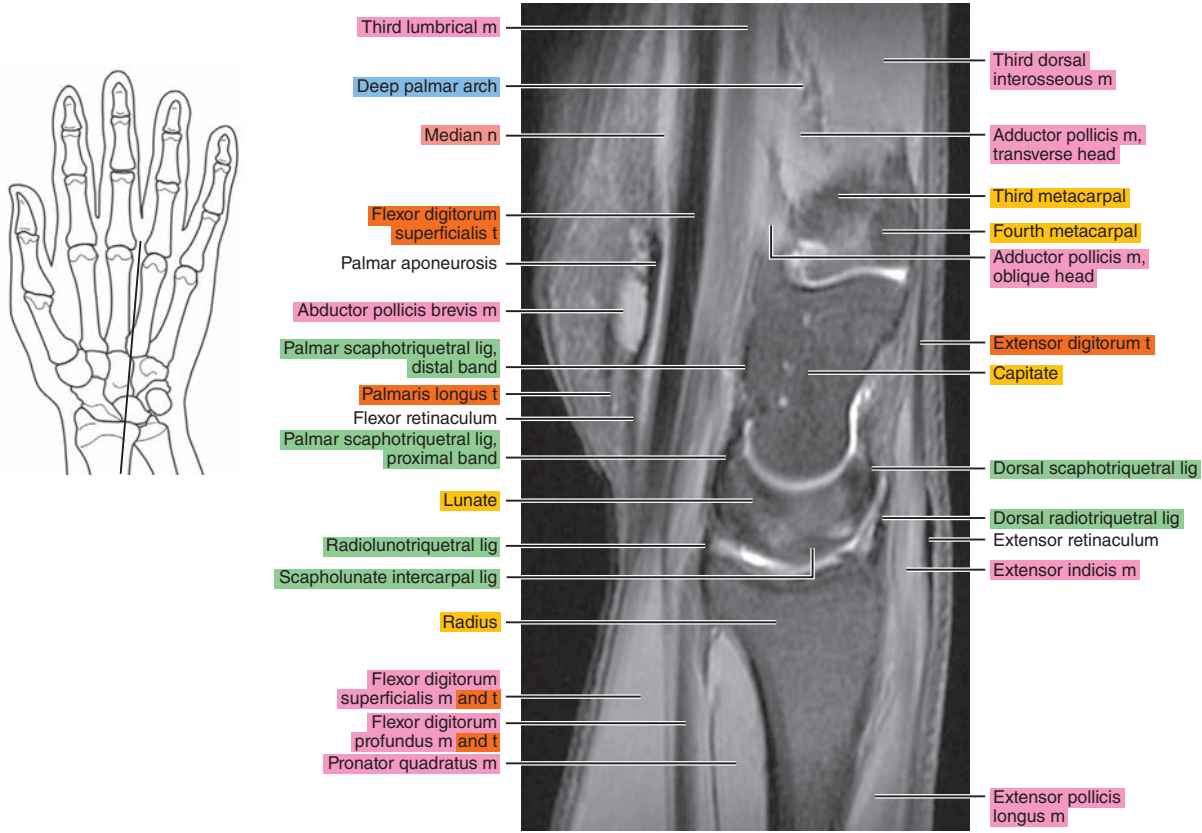


Figure 11.2.10

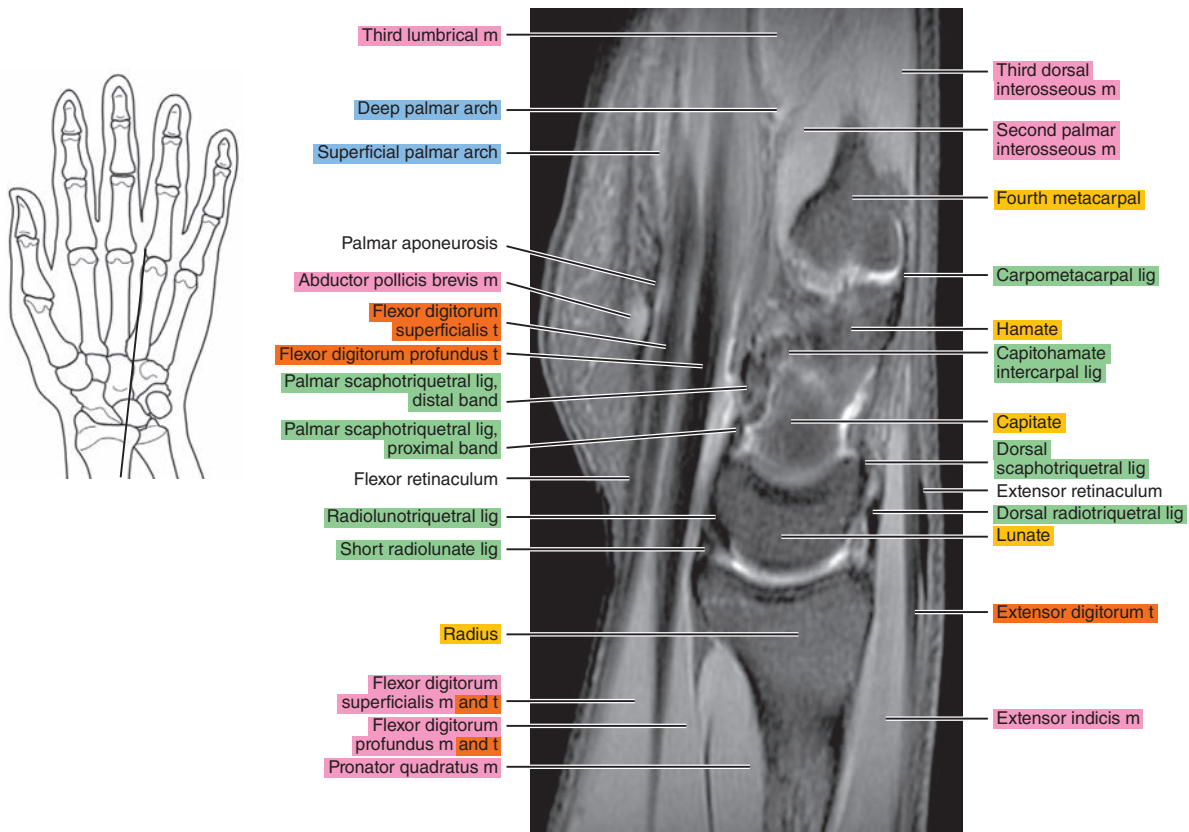




Figure 11.2.11

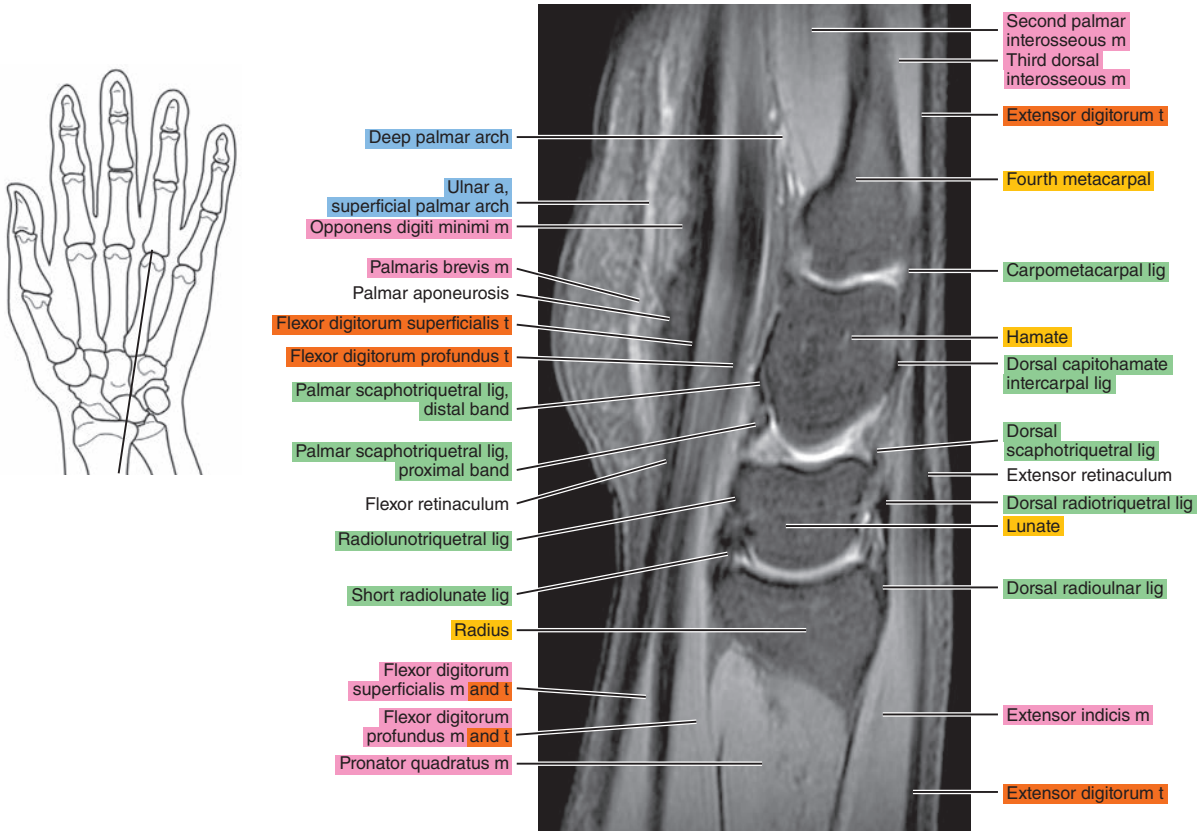


Figure 11.2.12

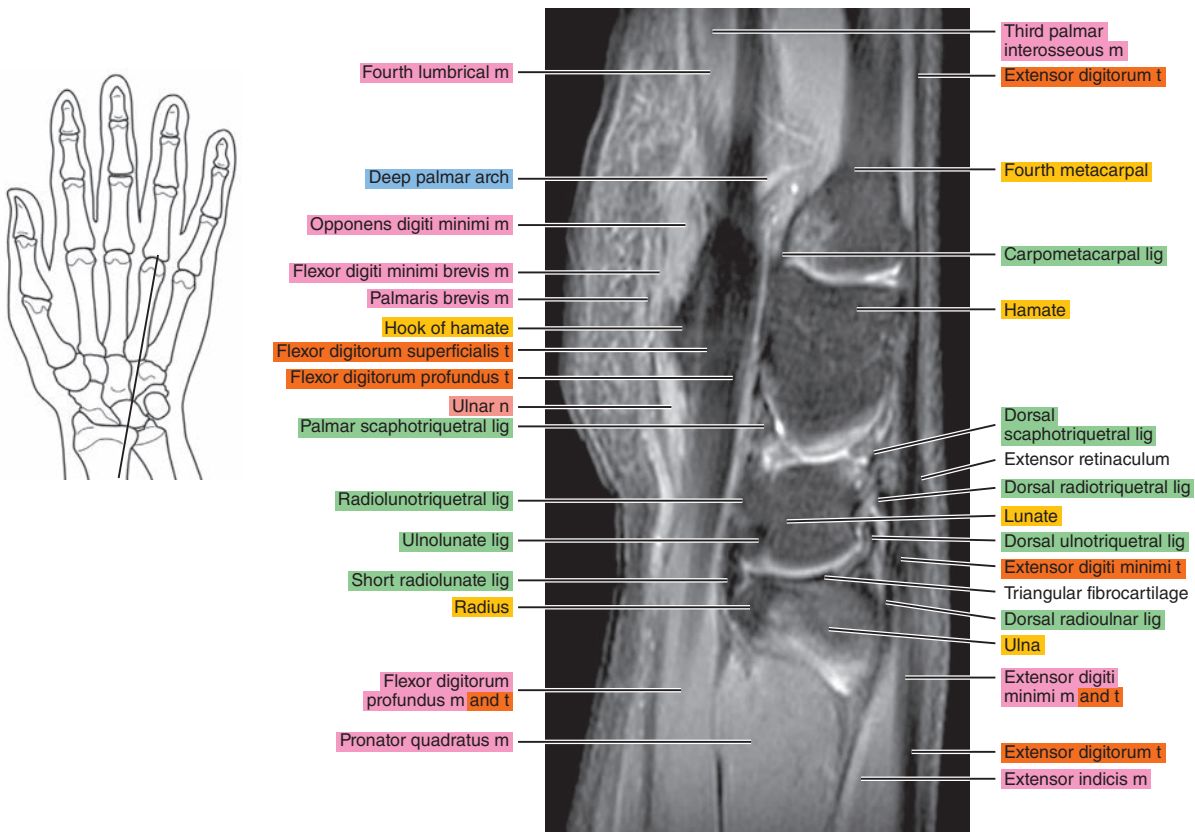




Figure 11.2.13

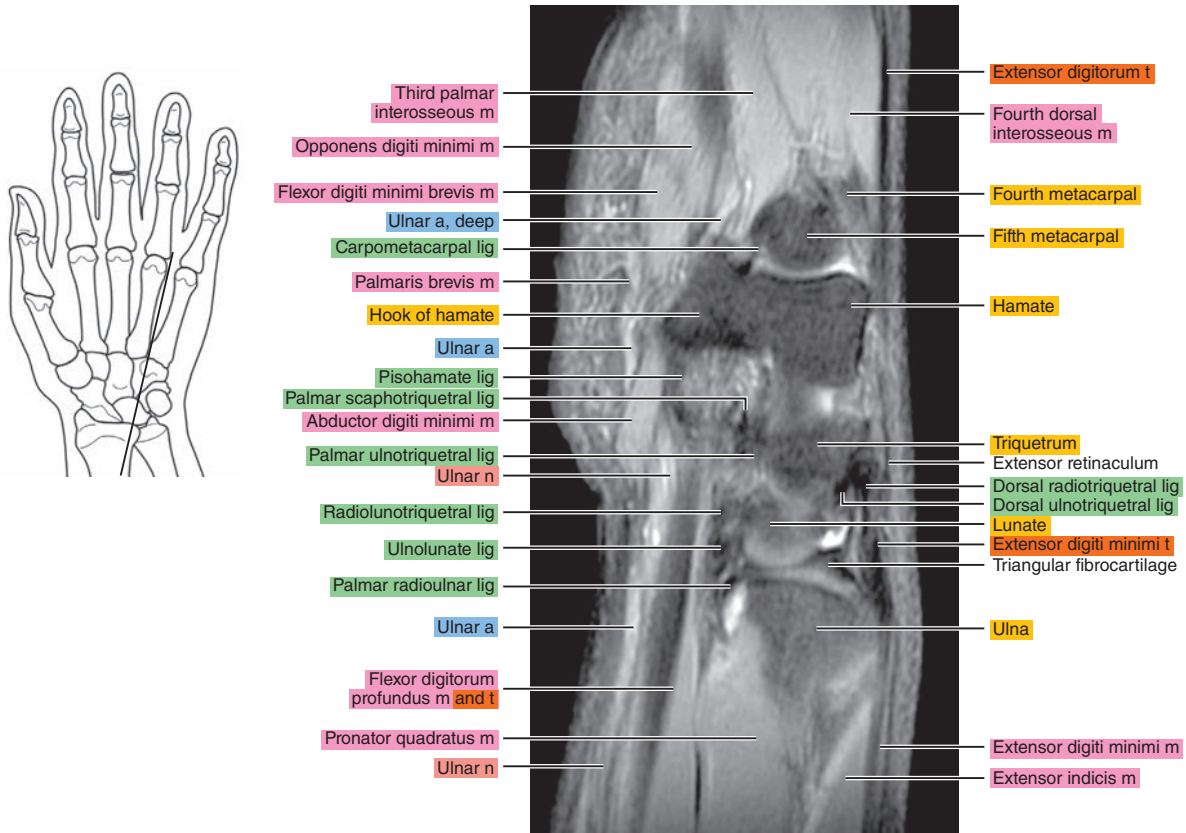


Figure 11.2.14

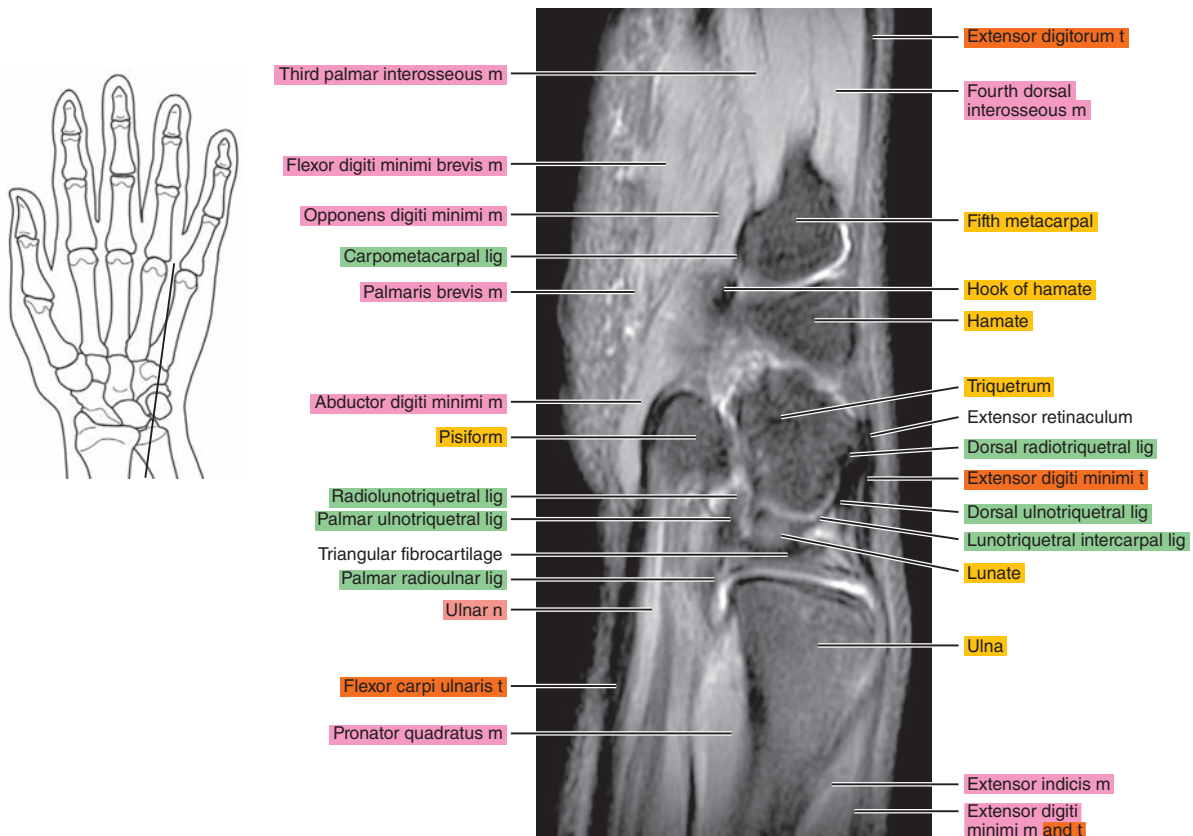


Figure 11.2.15

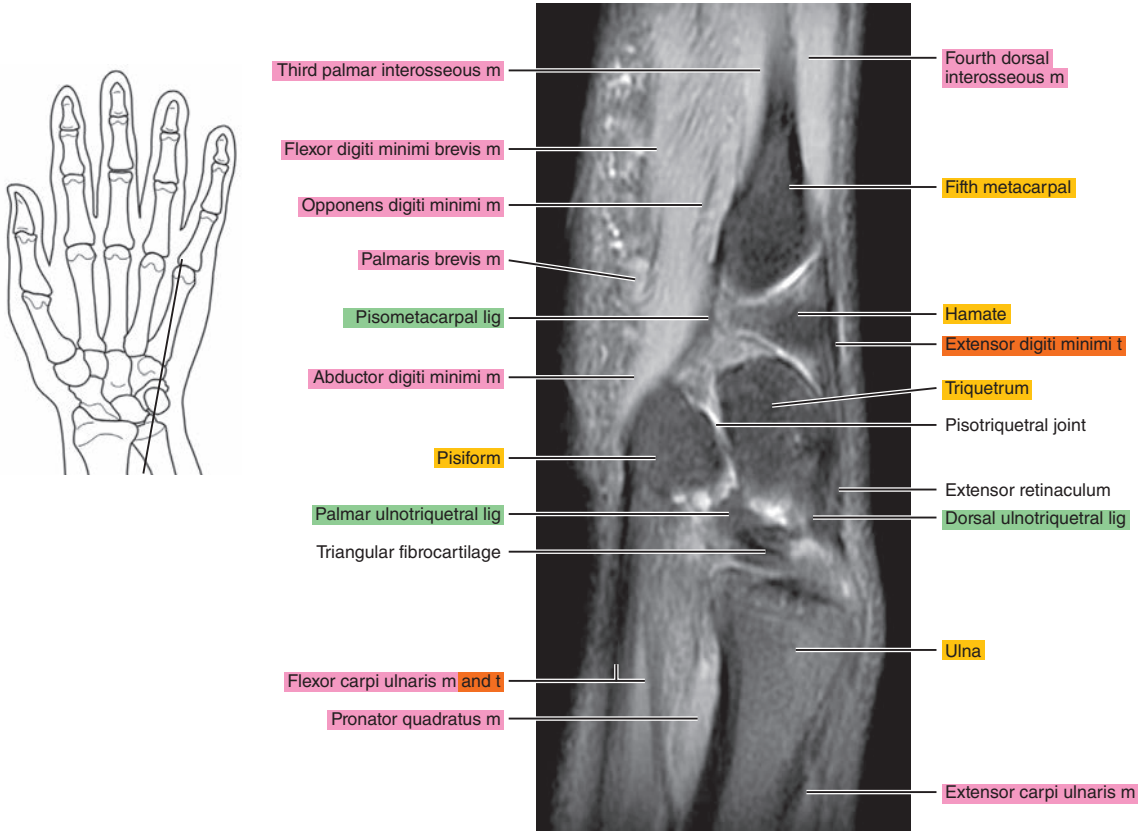


Figure 11.2.16

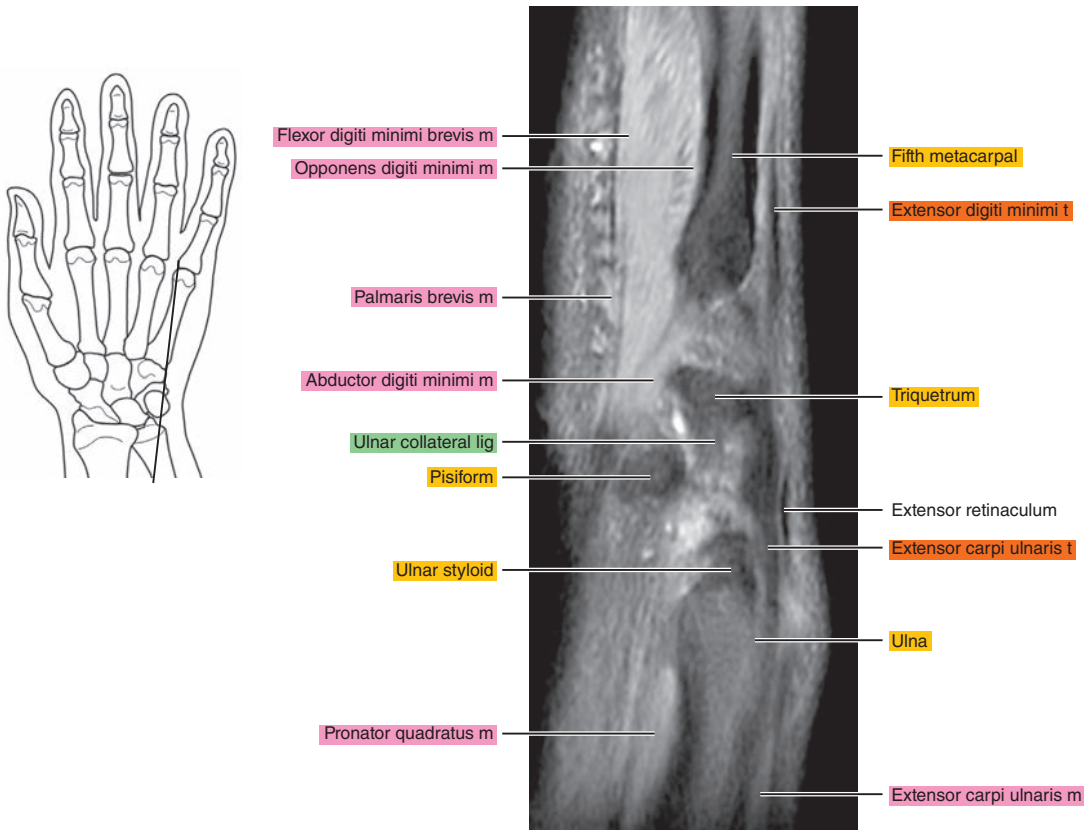
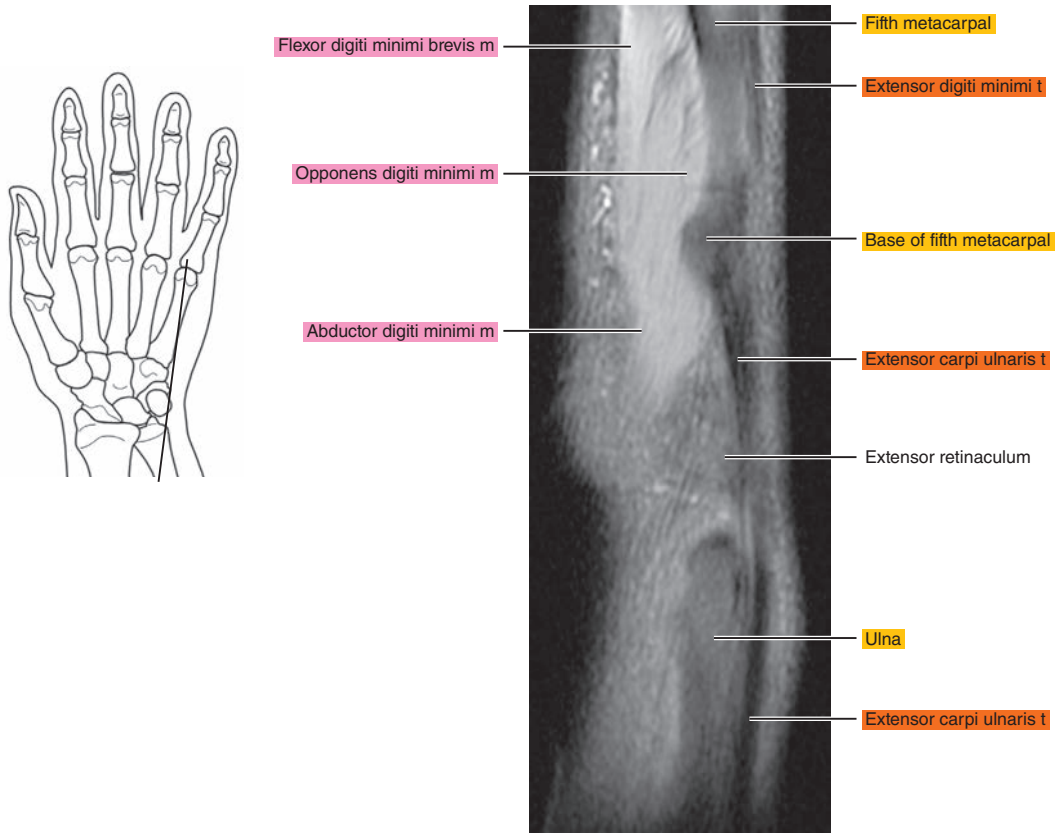


Figure 11.2.17



# CORONAL

Figure 11.3.1

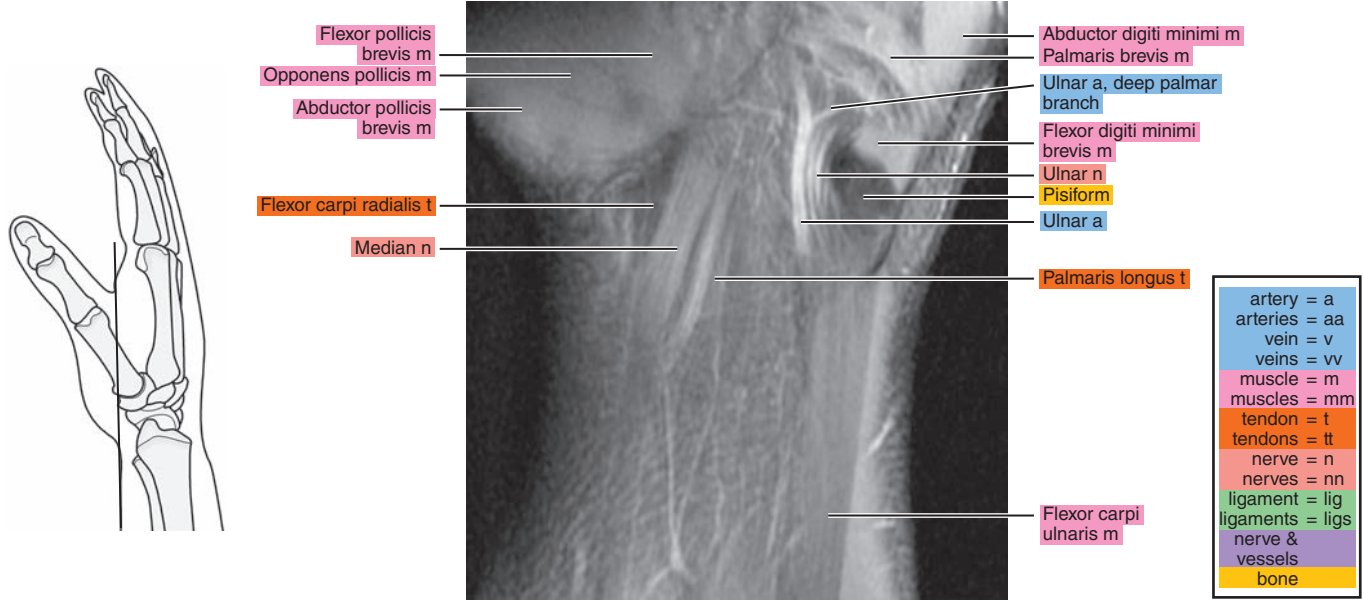


Figure 11.3.2

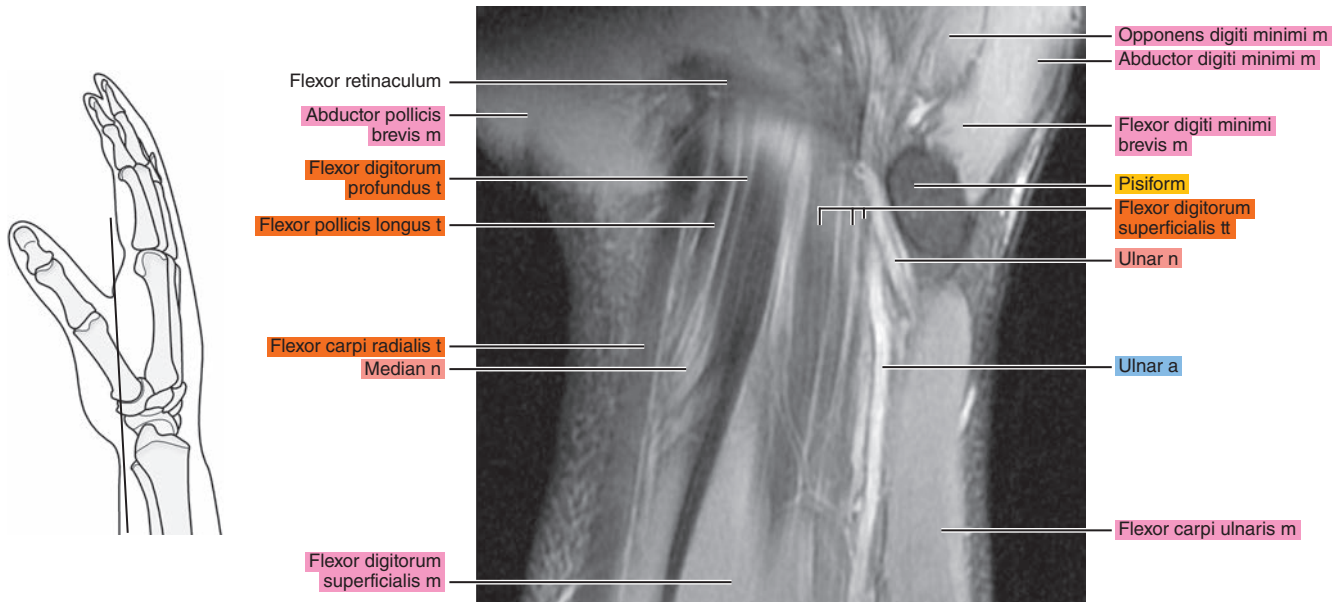




Figure 11.3.3

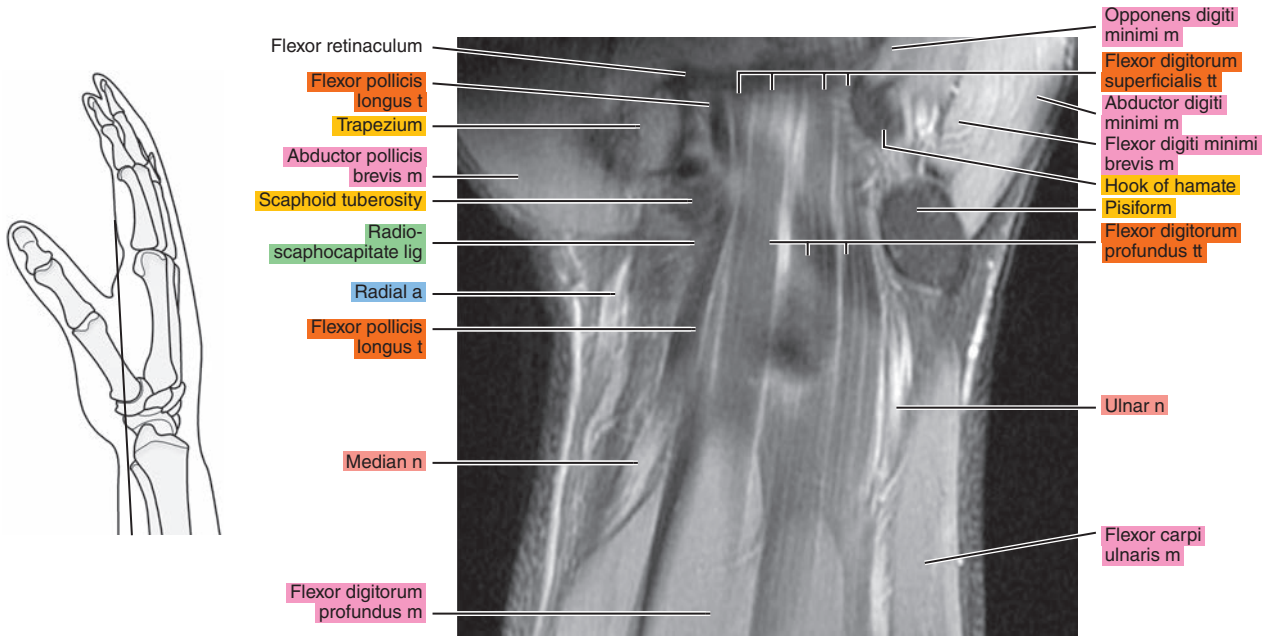


Figure 11.3.4

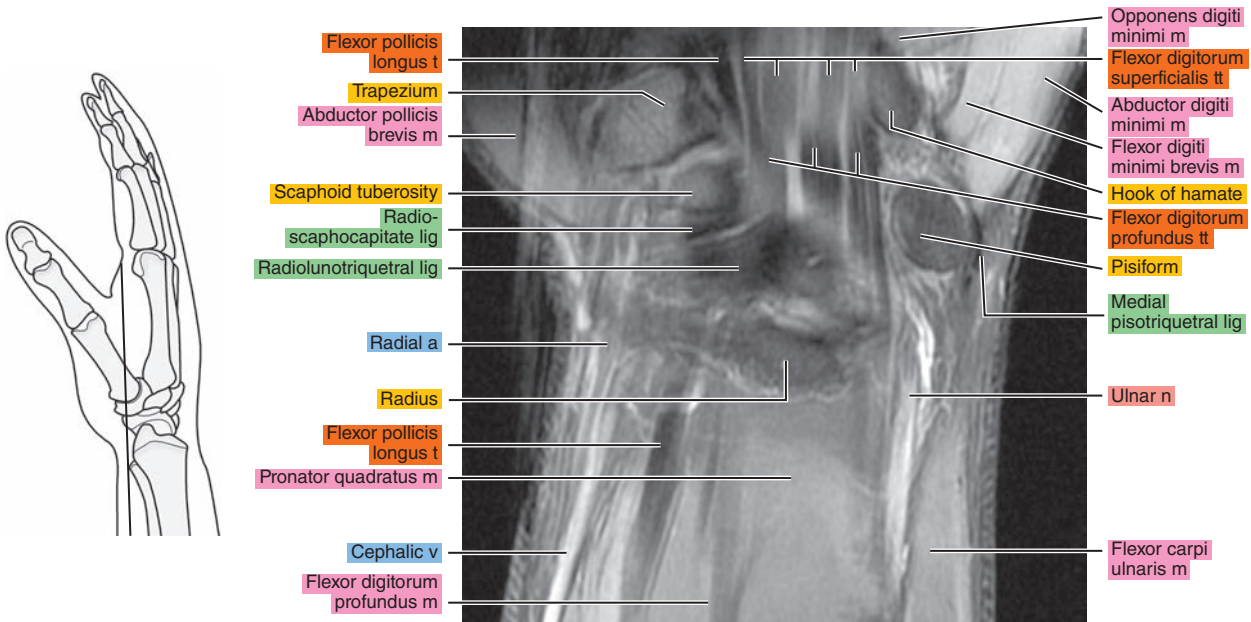


Figure 11.3.5

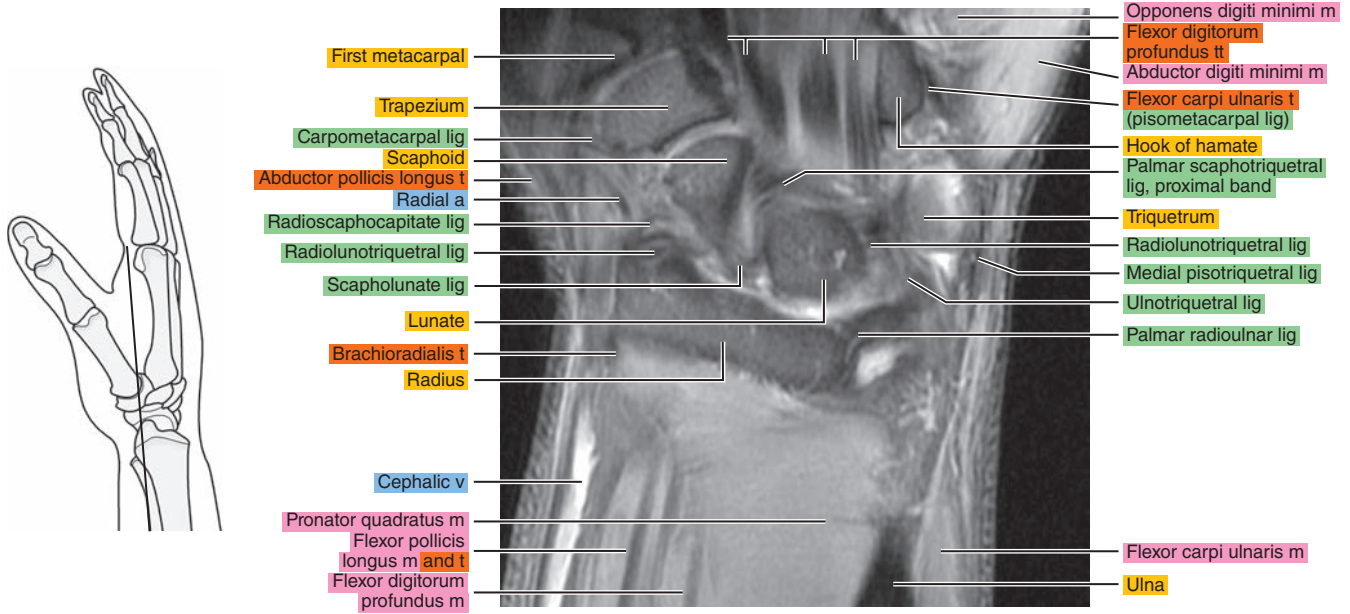


Figure 11.3.6

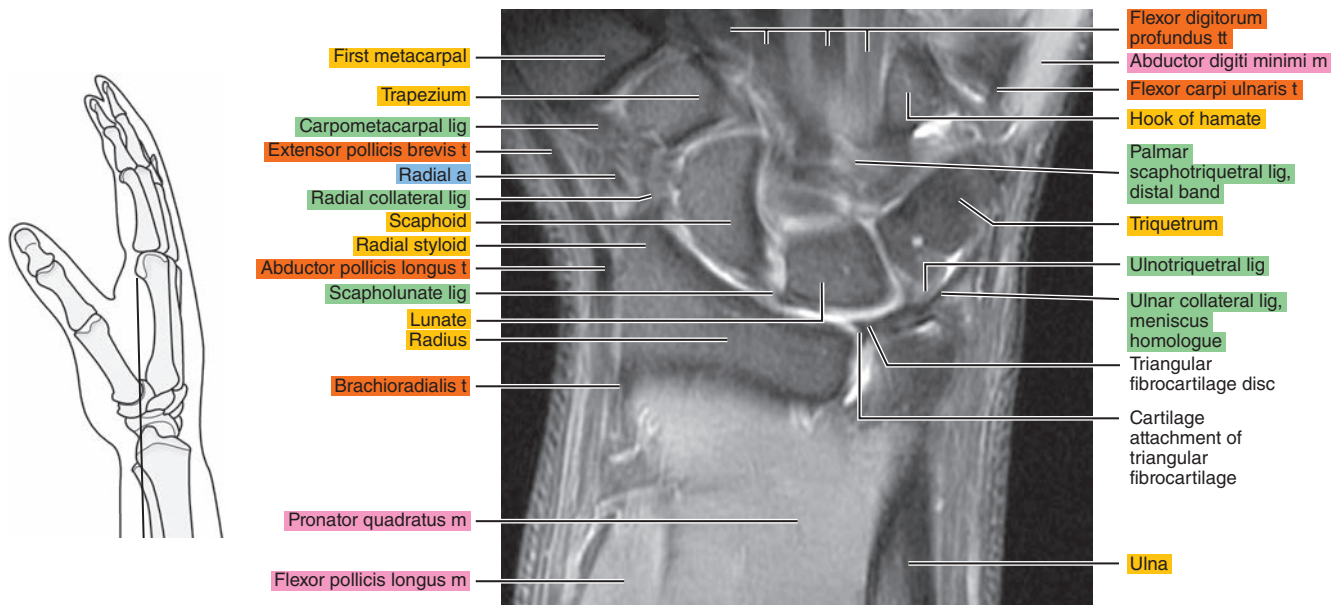


Figure 11.3.7

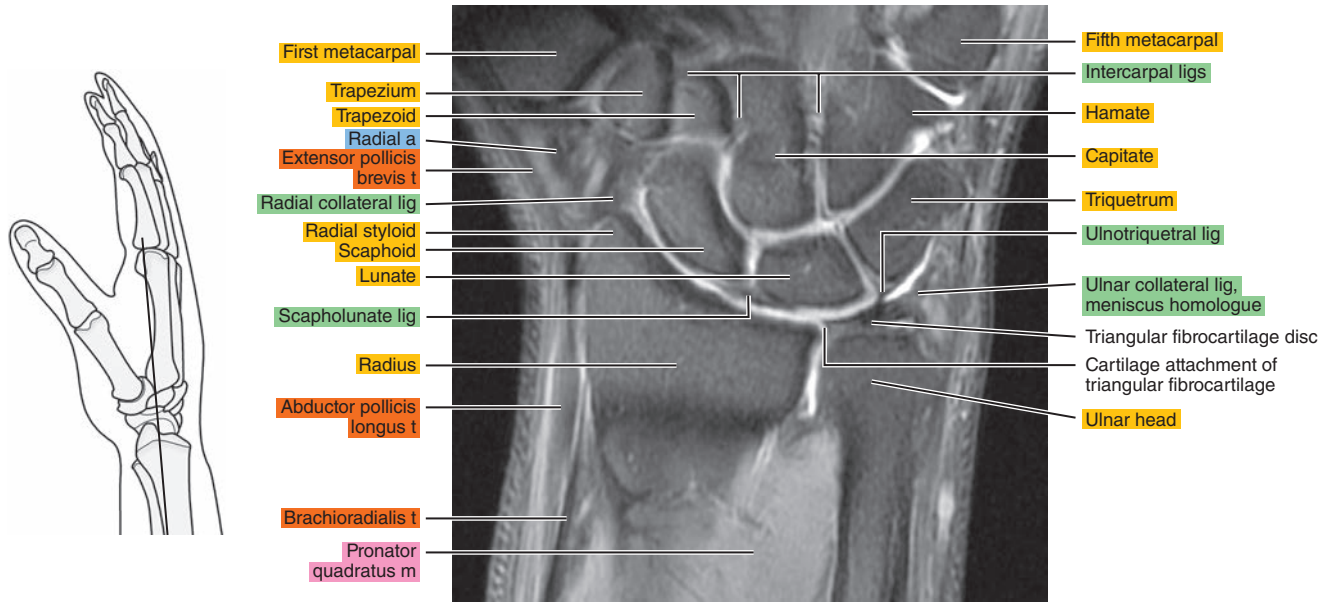


Figure 11.3.8

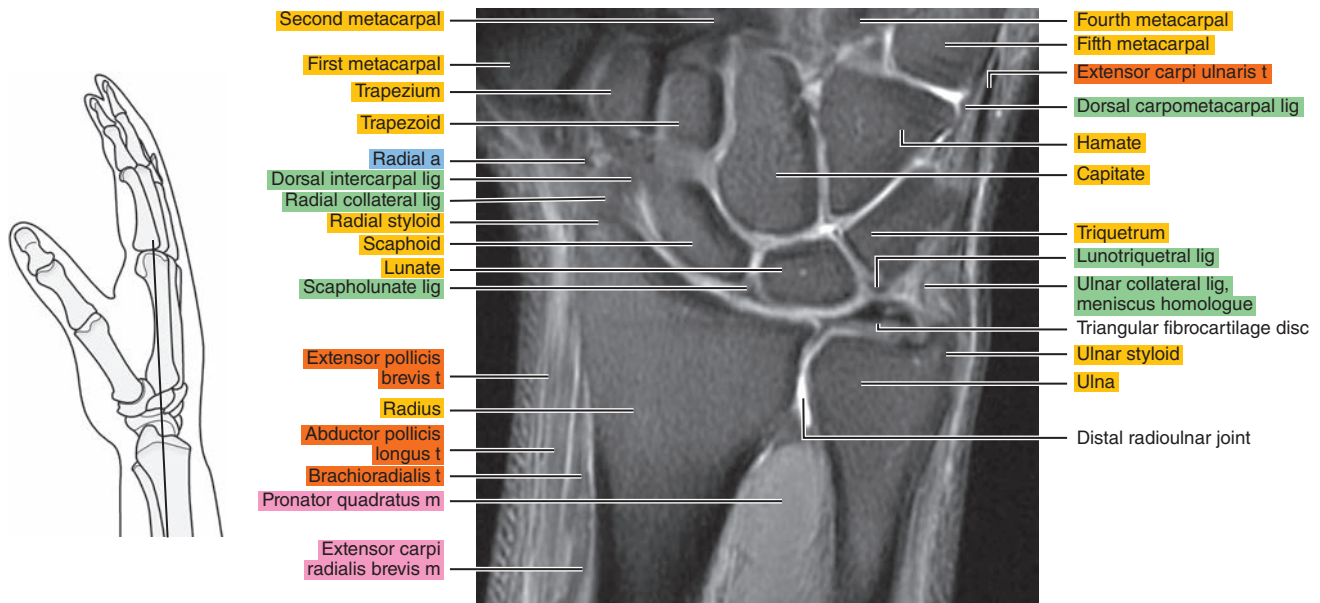


Figure 11.3.9

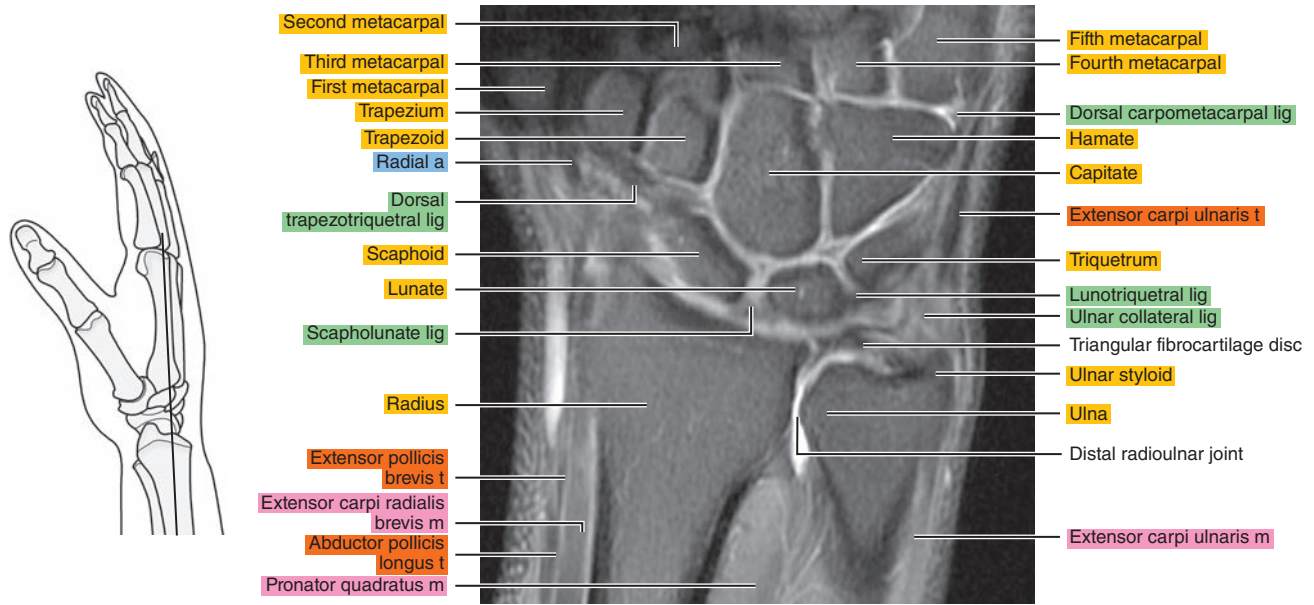


Figure 11.3.10

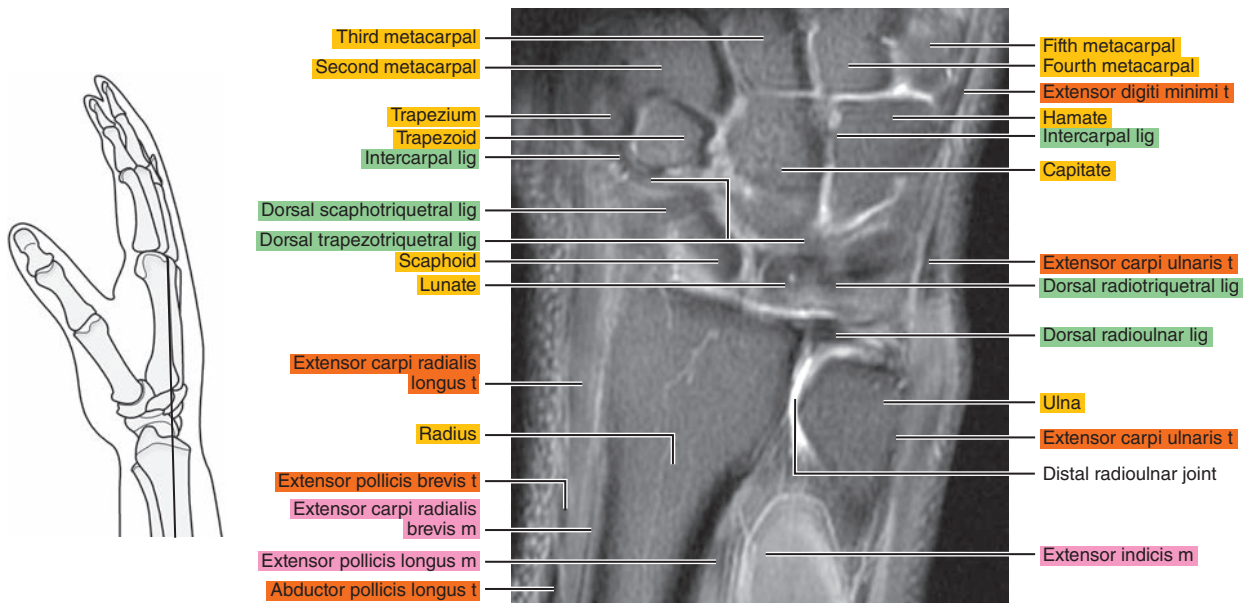




Figure 11.3.11

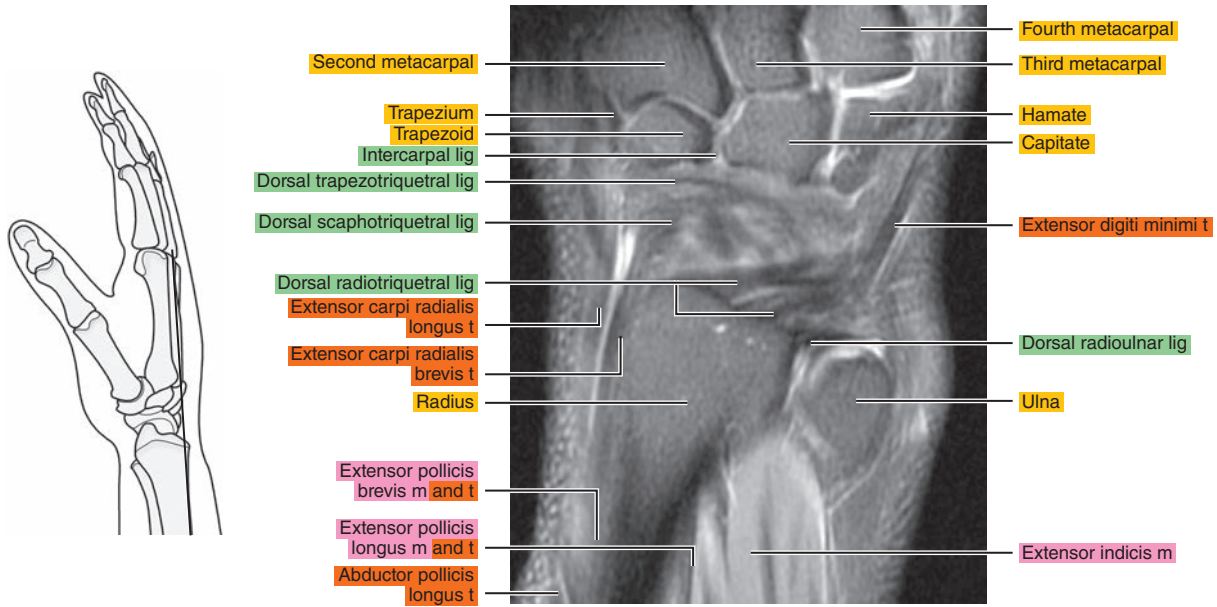


Figure 11.3.12

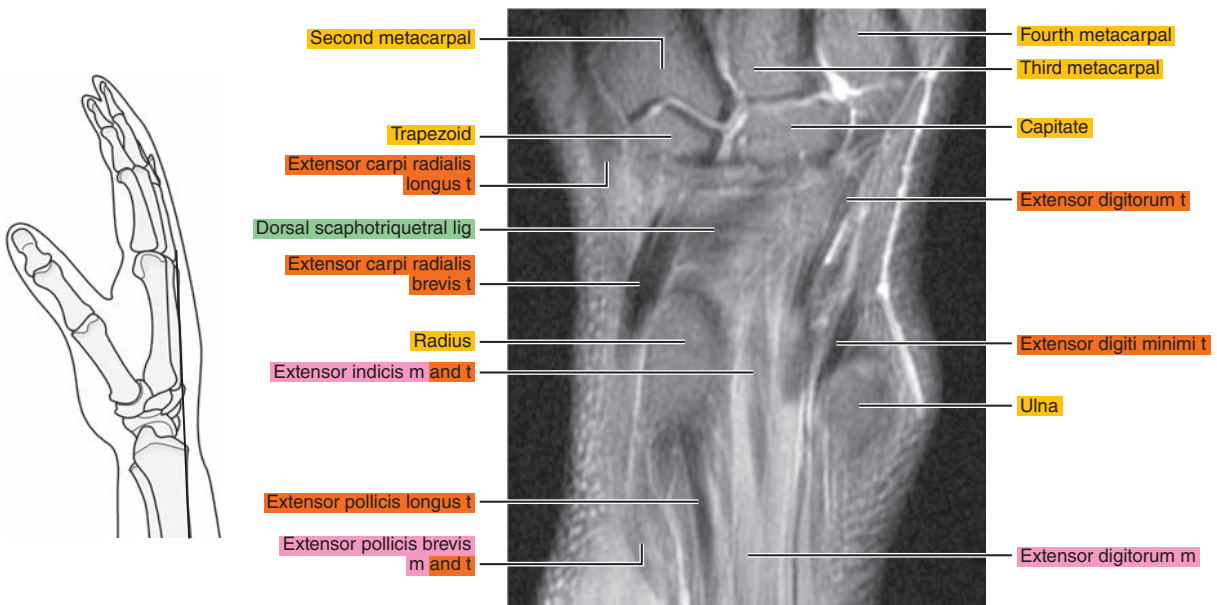
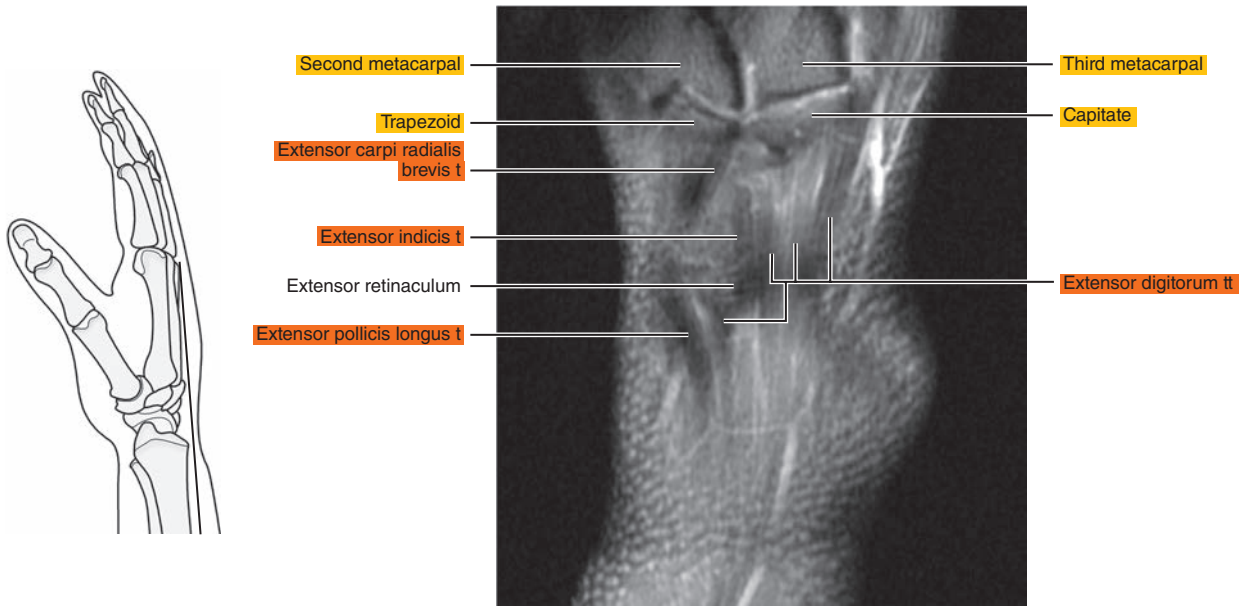


Figure 11.3.13



*Chapter*  
**12**

**MRI of the Hand**

# AXIAL

Figure 12.1.1

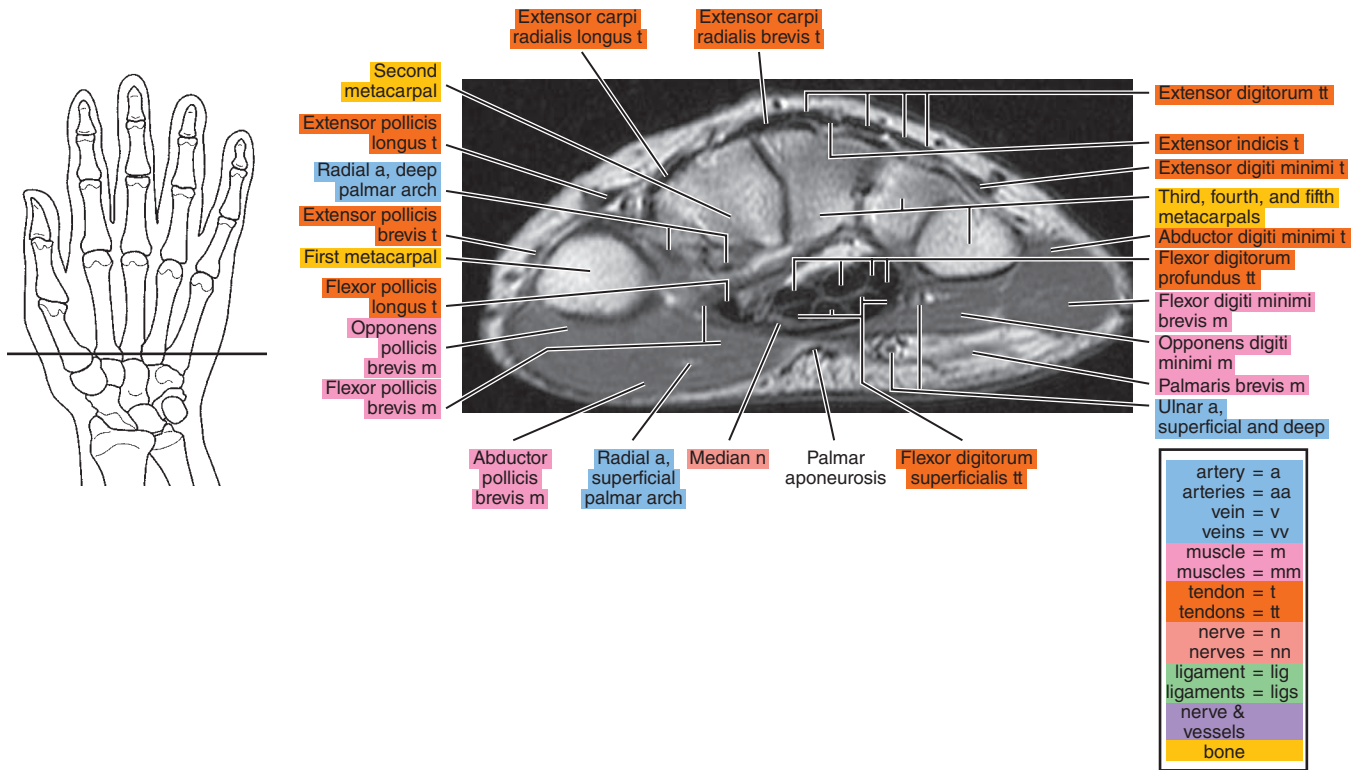


Figure 12.1.2

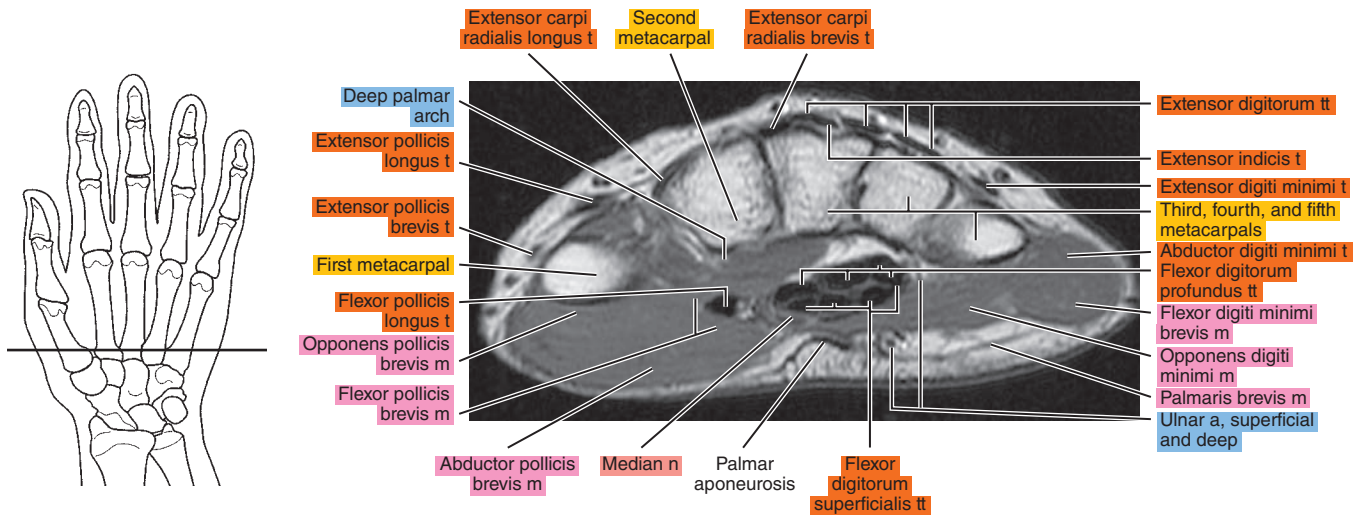




Figure 12.1.3

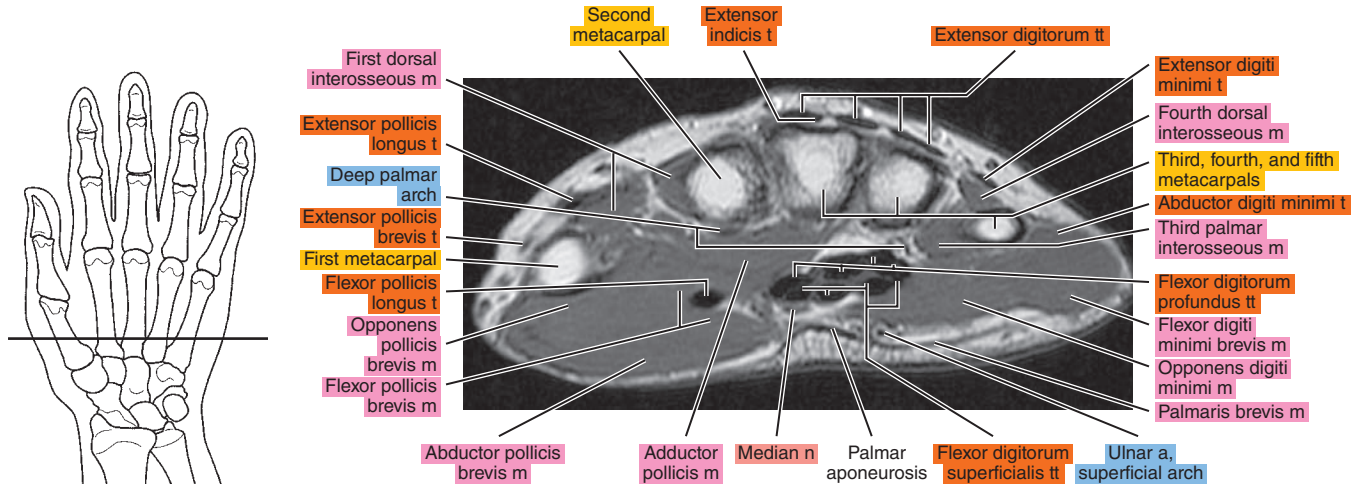


Figure 12.1.4

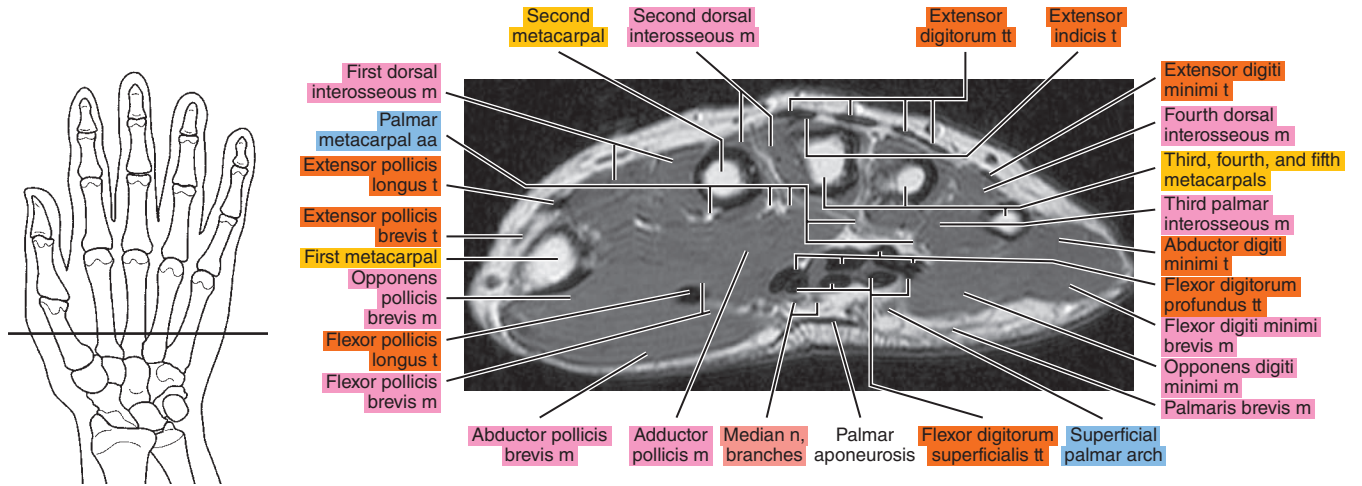


Figure 12.1.5

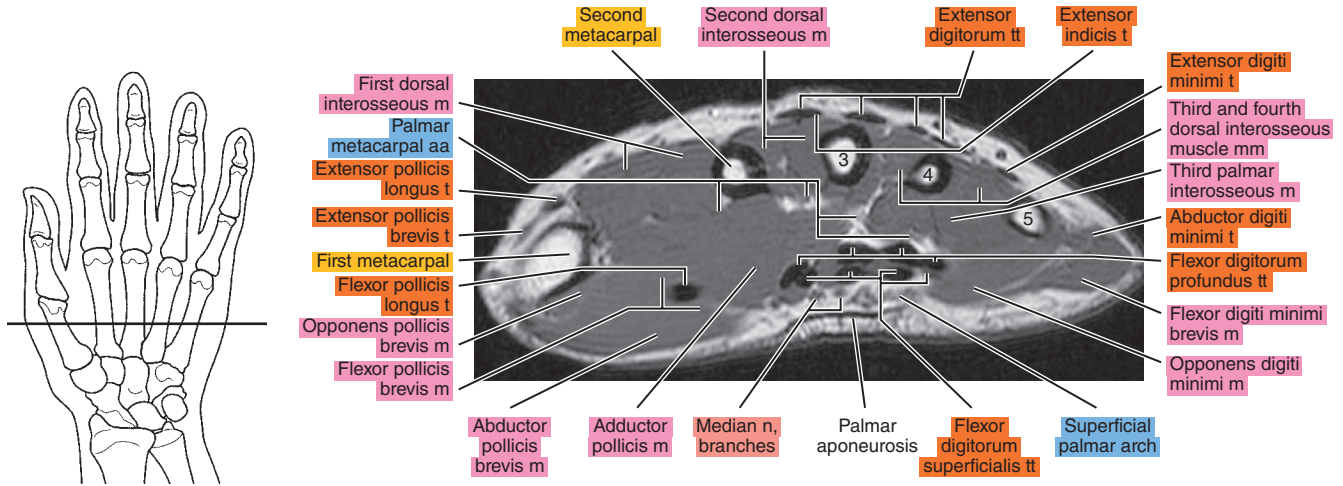


Figure 12.1.6

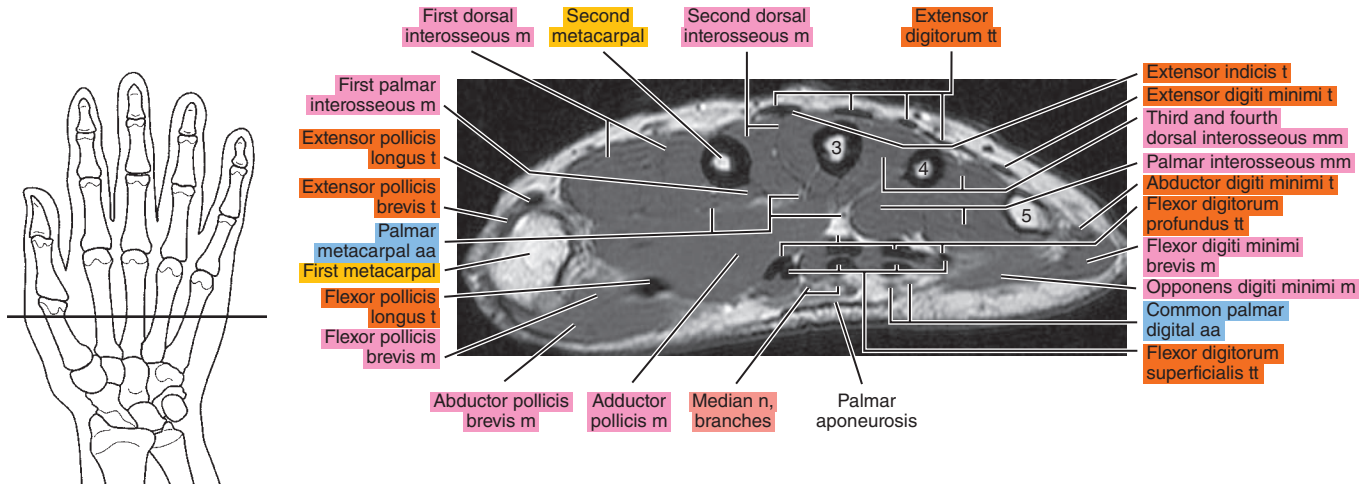


Figure 12.1.7

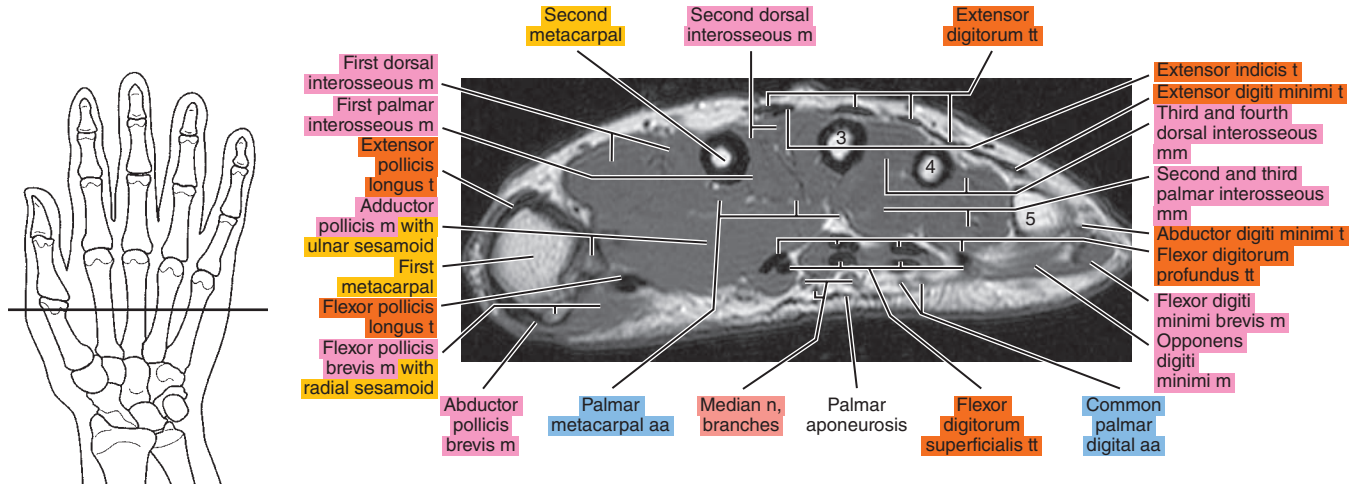


Figure 12.1.8

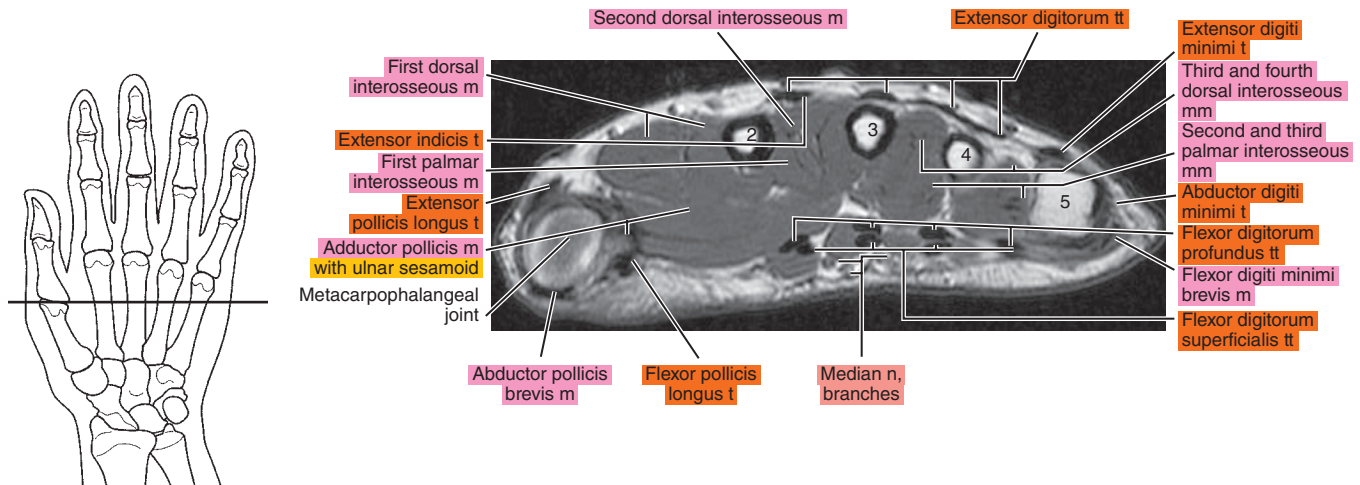


Figure 12.1.9

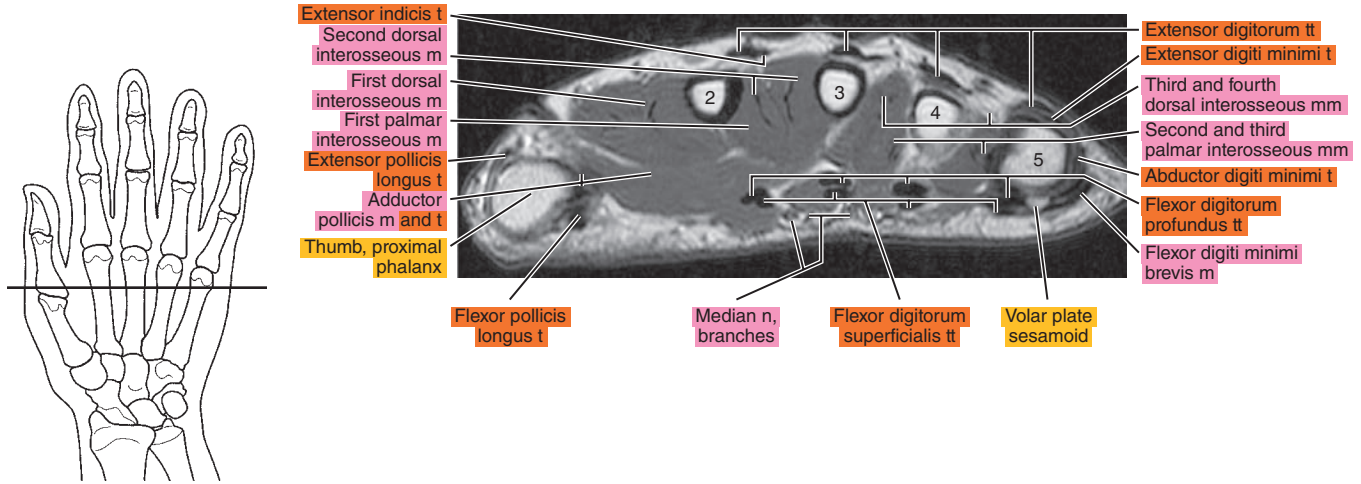


Figure 12.1.10

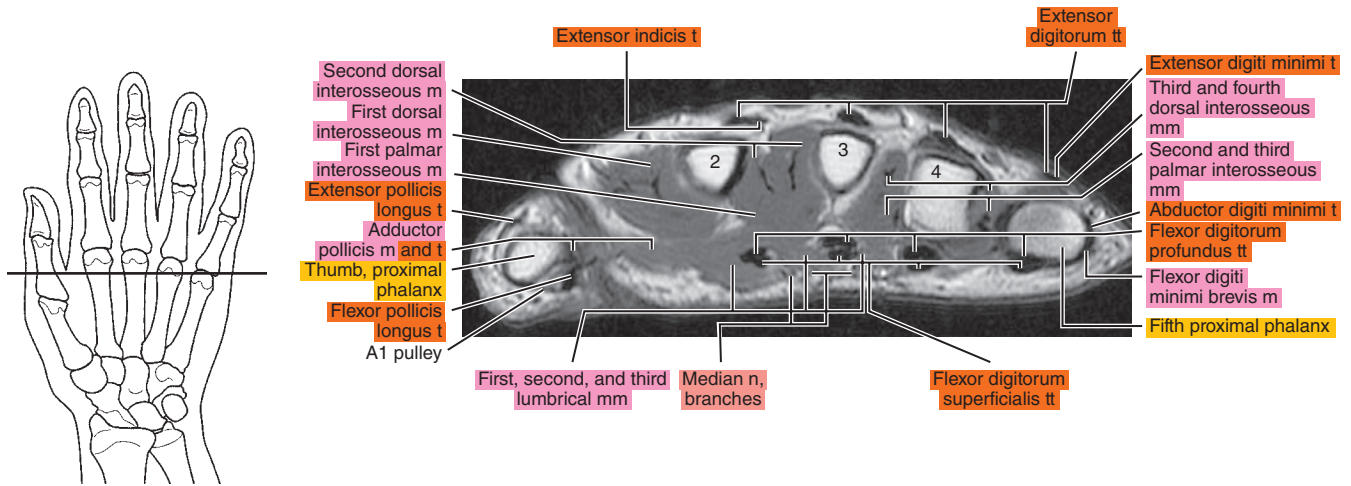




Figure 12.1.11

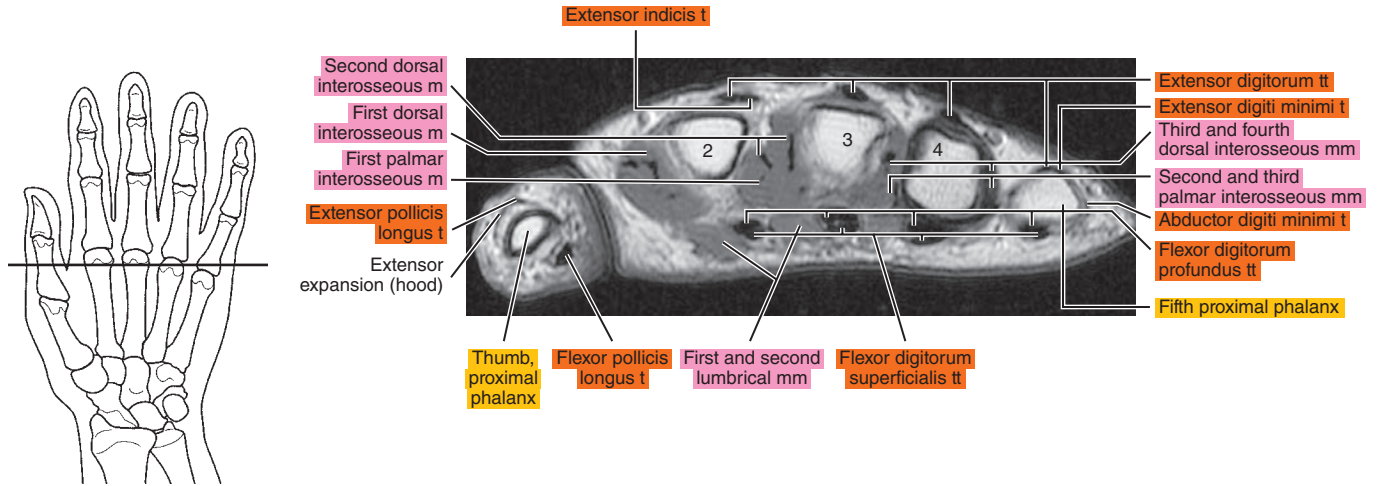


Figure 12.1.12

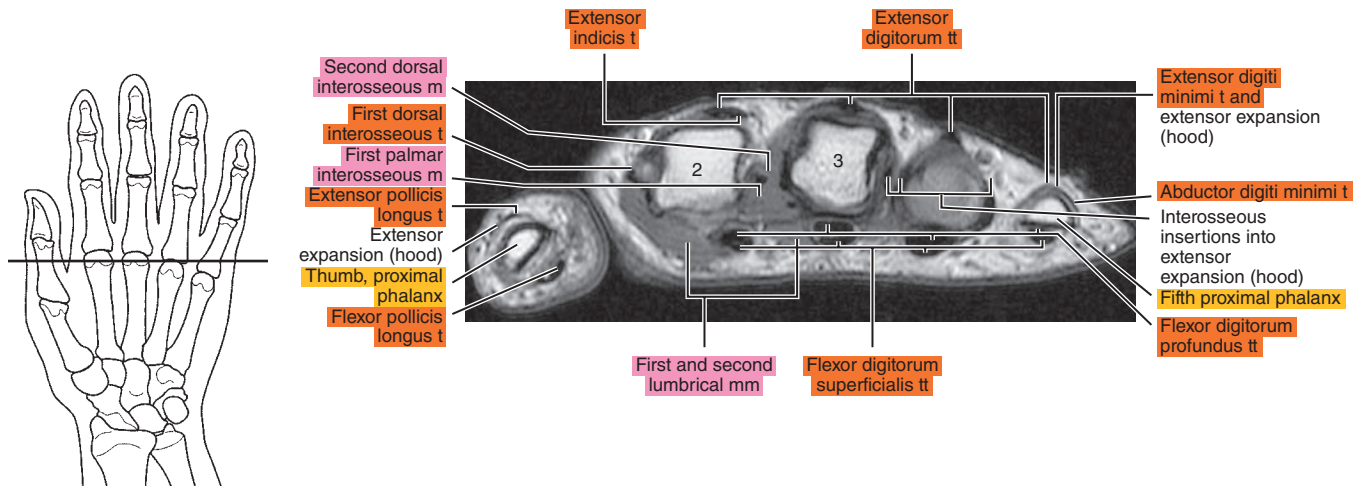


Figure 12.1.13

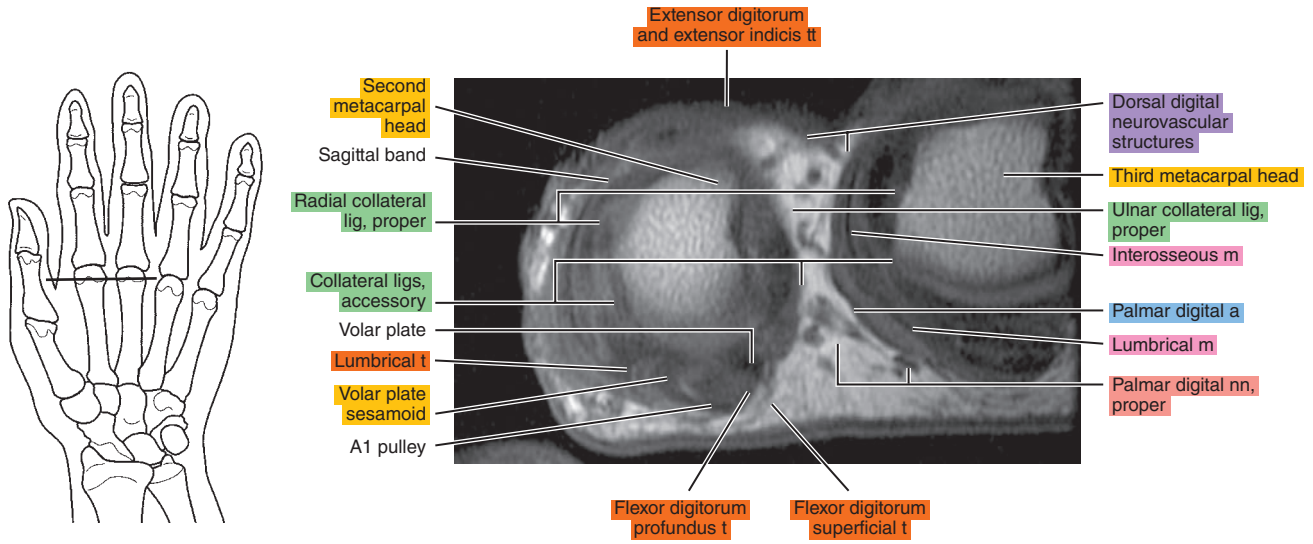
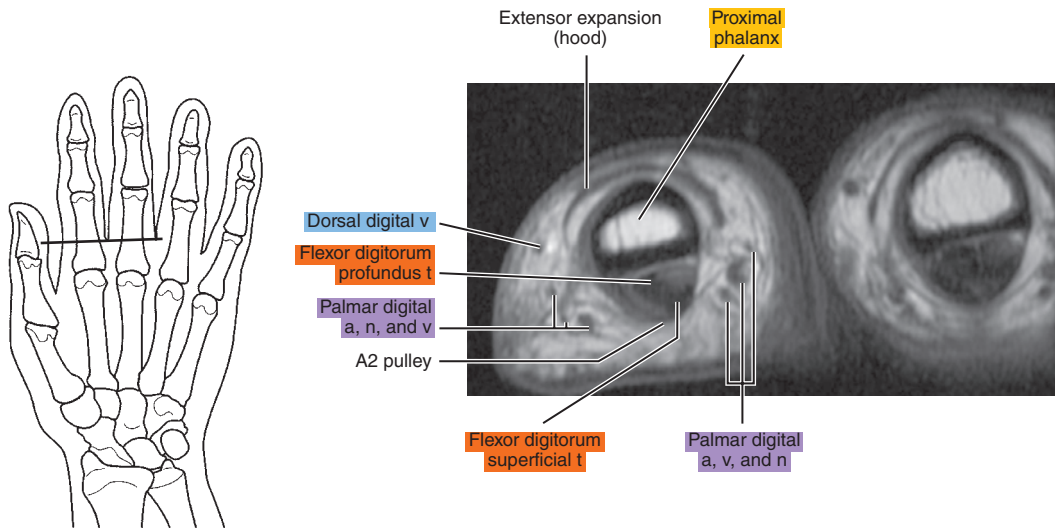
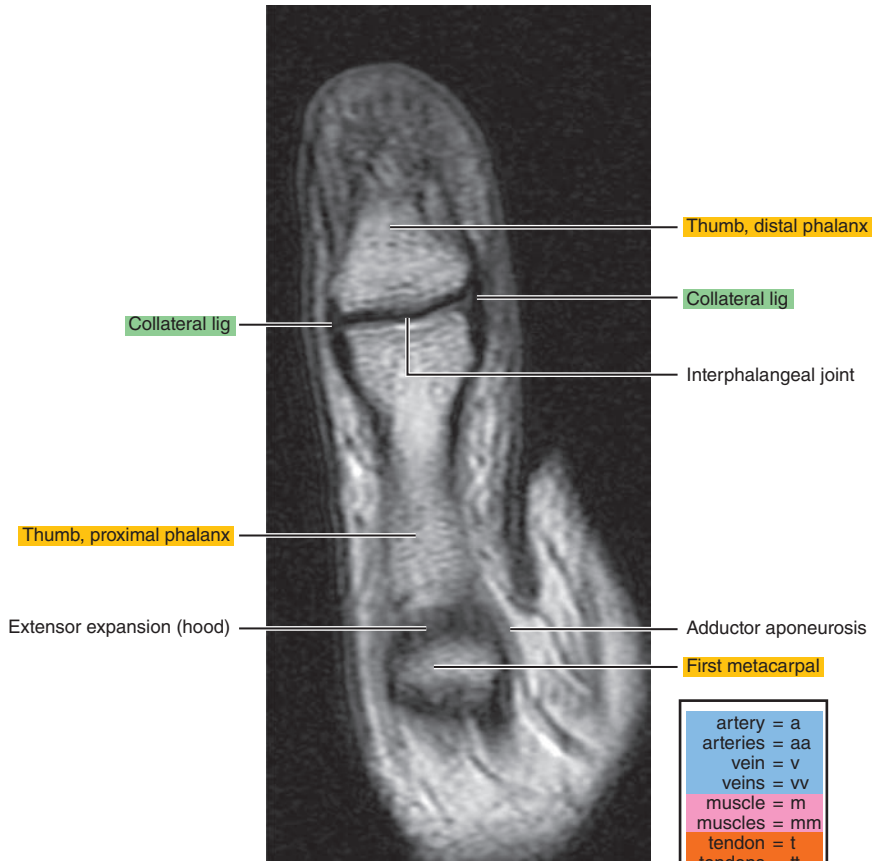
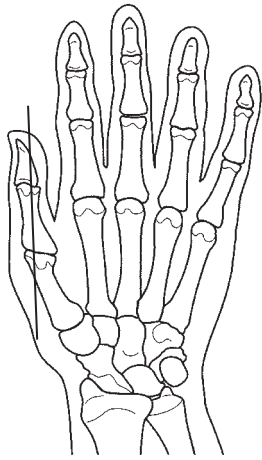


Figure 12.1.14



# SAGITTAL

Figure 12.2.1



artery = a
arteries = aa
vein = v
veins = vv
muscle = m
muscles = mm
tendon = t
tendons = tt
nerve = n
nerves = nn
ligament = lig
ligaments = ligs
nerve & vessels
bone

Figure 12.2.2

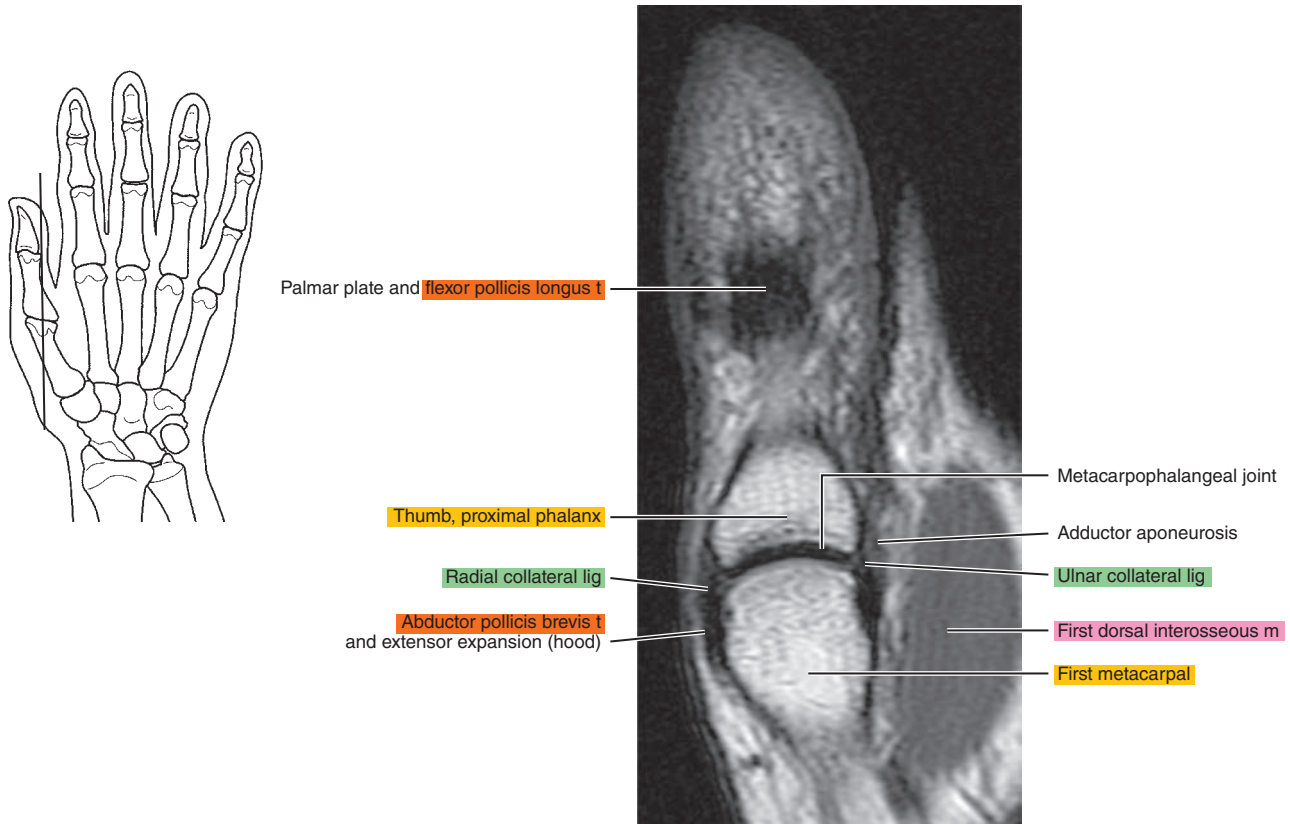


Figure 12.2.3

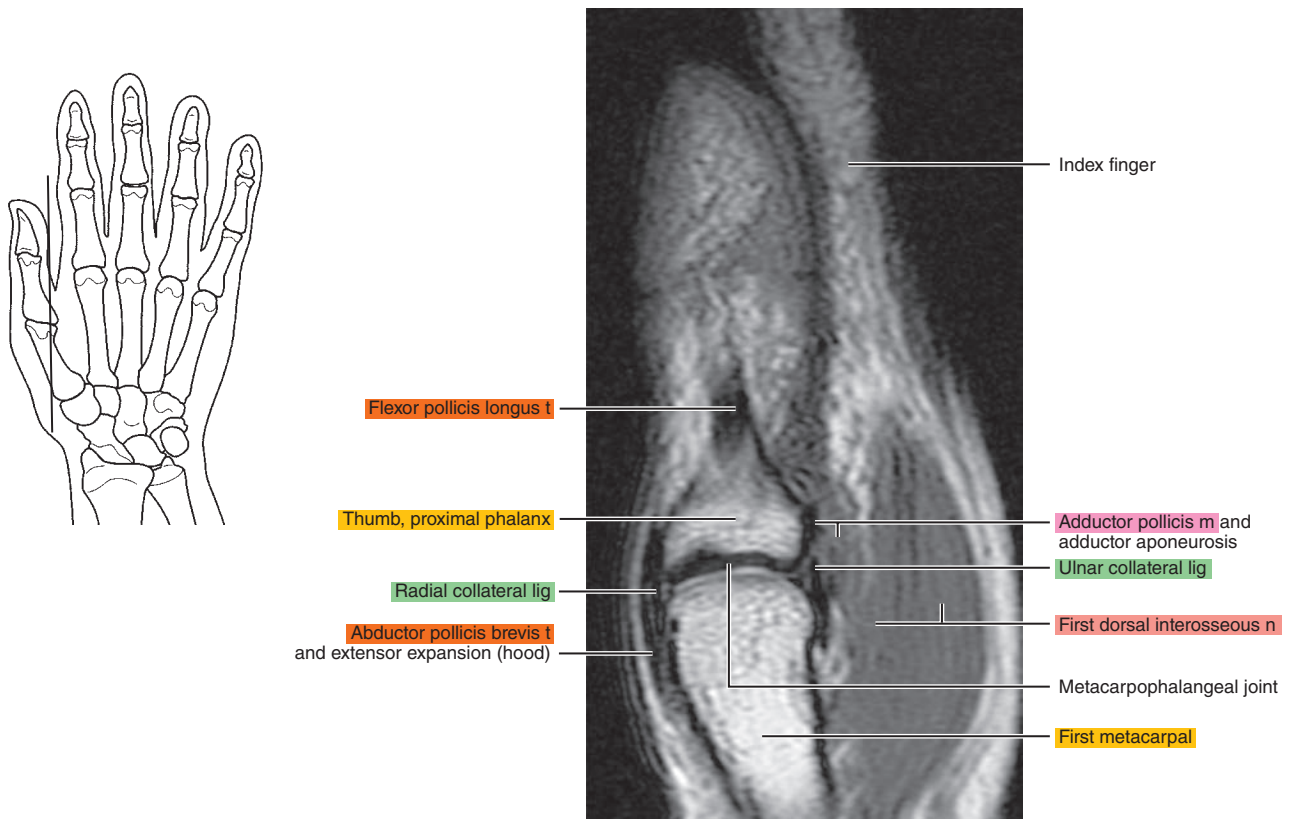




Figure 12.2.4

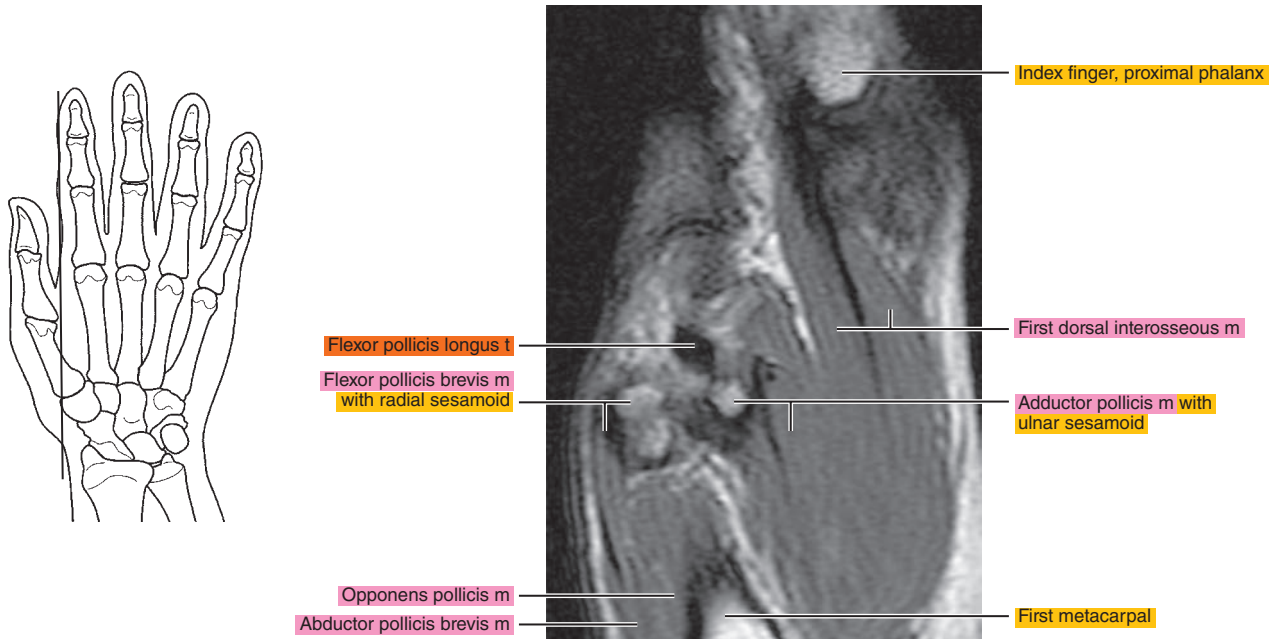


Figure 12.2.5

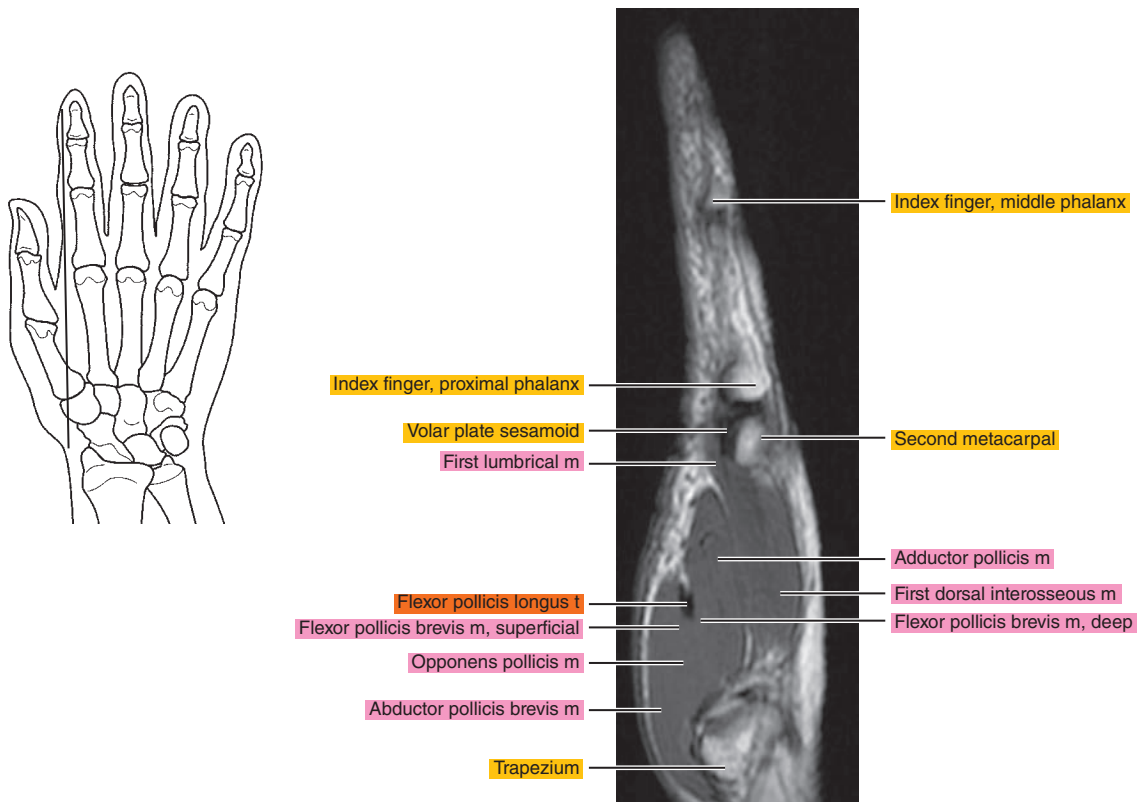


Figure 12.2.6

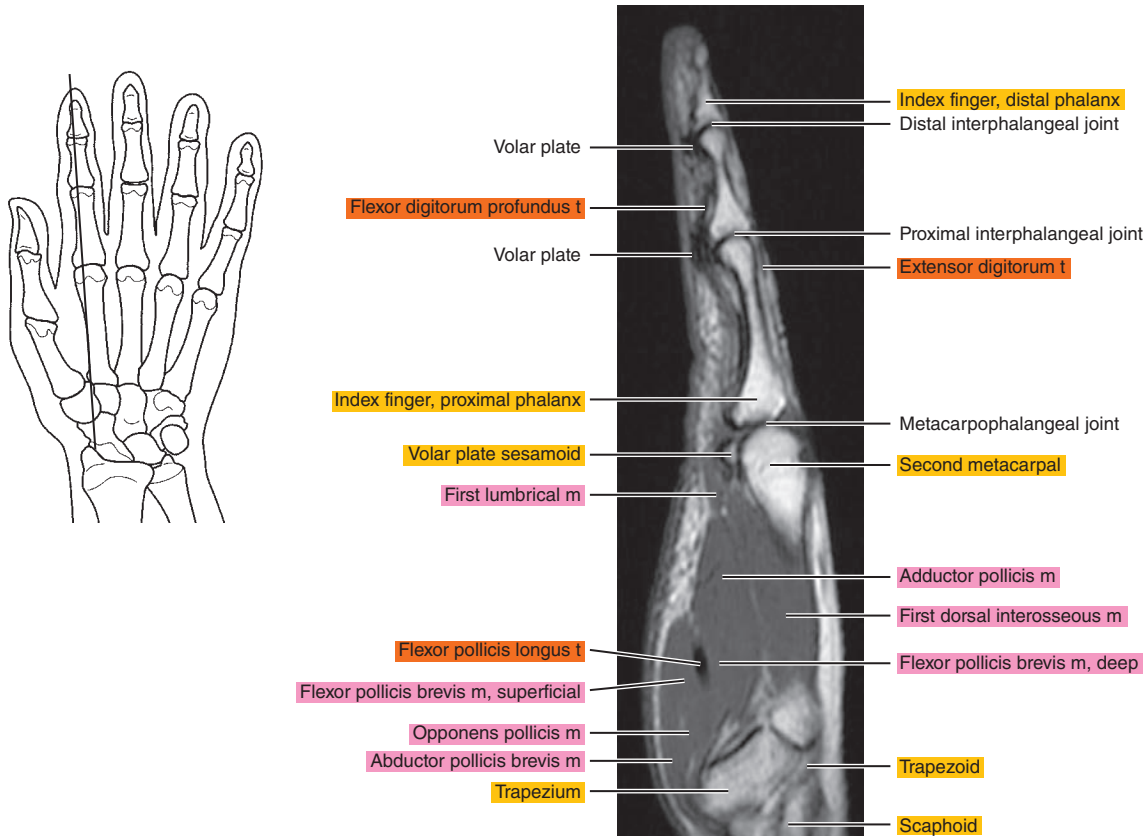


Figure 12.2.7

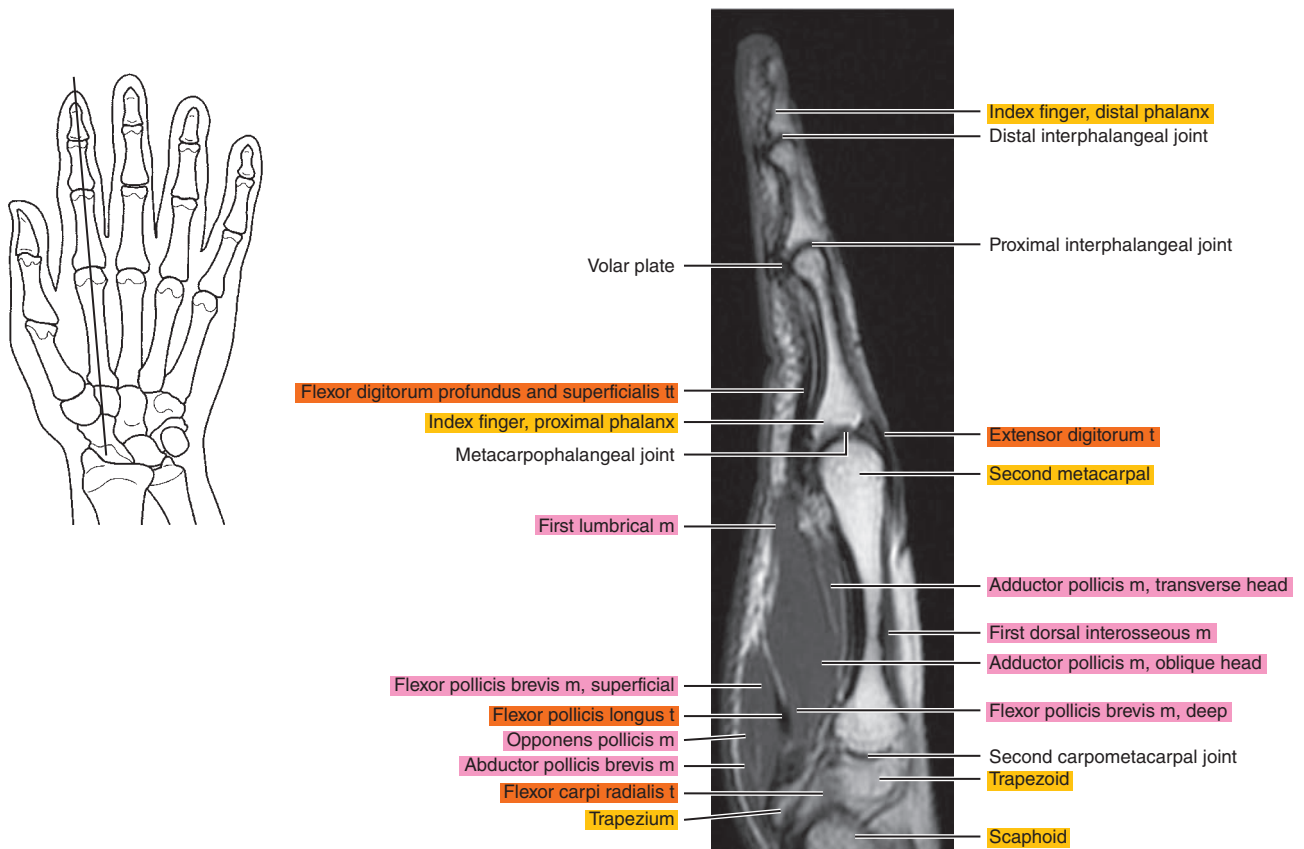


Figure 12.2.8

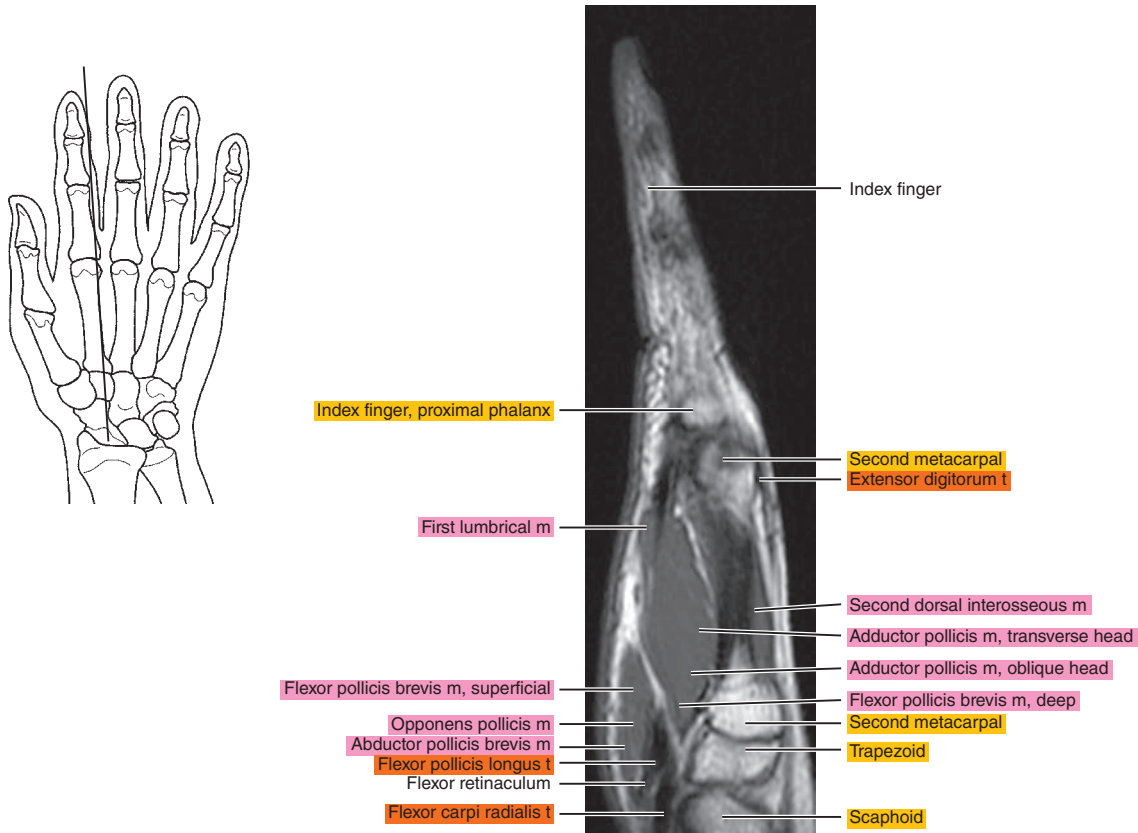


Figure 12.2.9

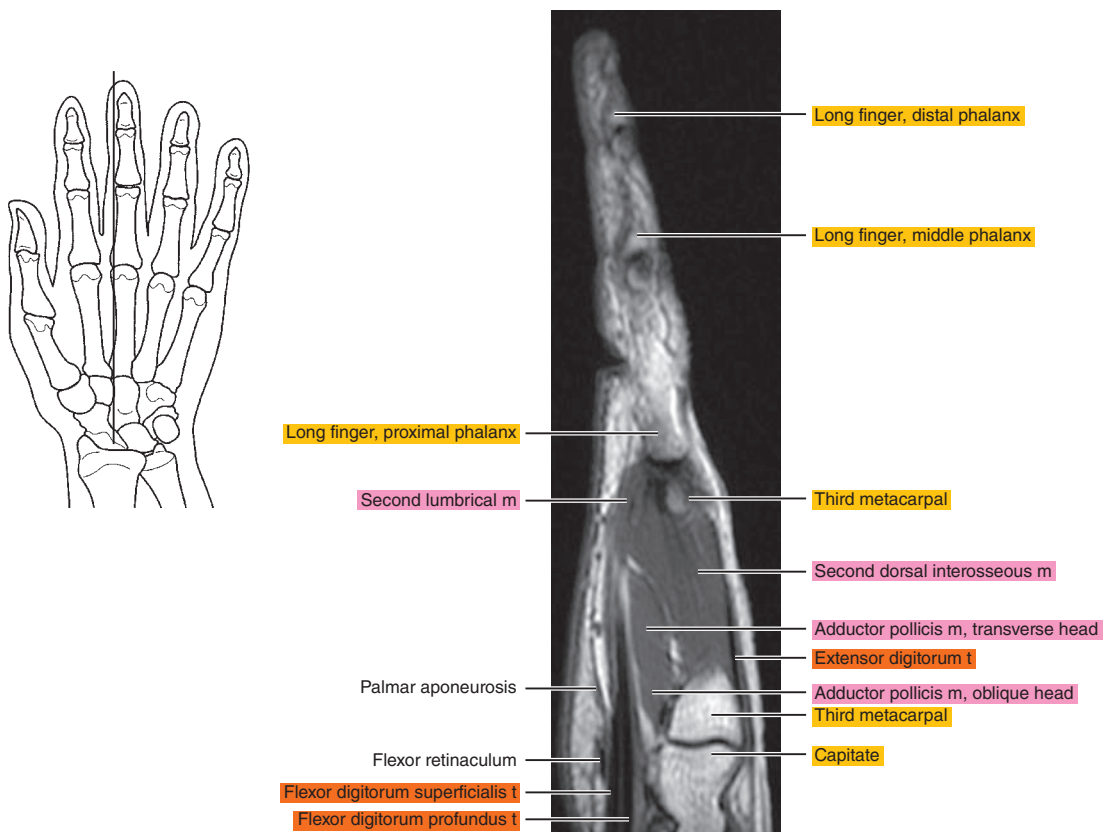


Figure 12.2.10

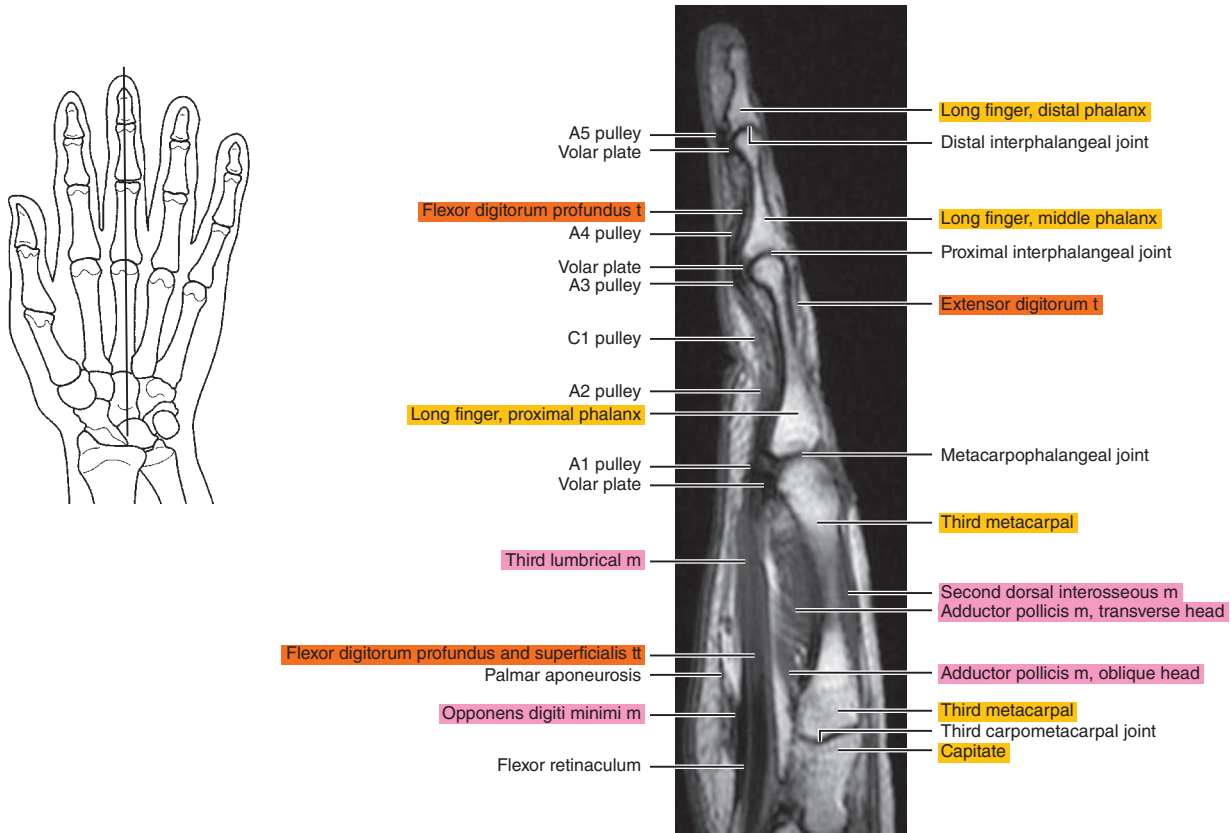


Figure 12.2.11

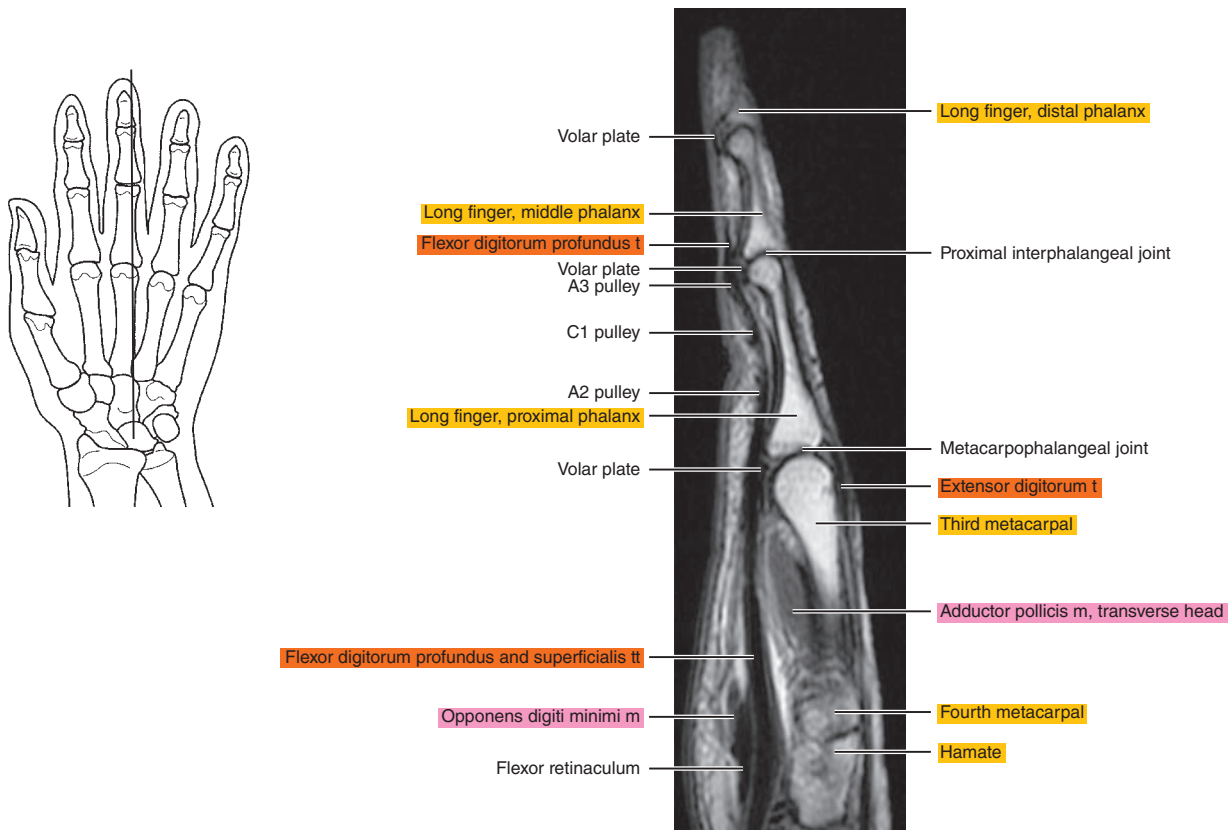




Figure 12.2.12

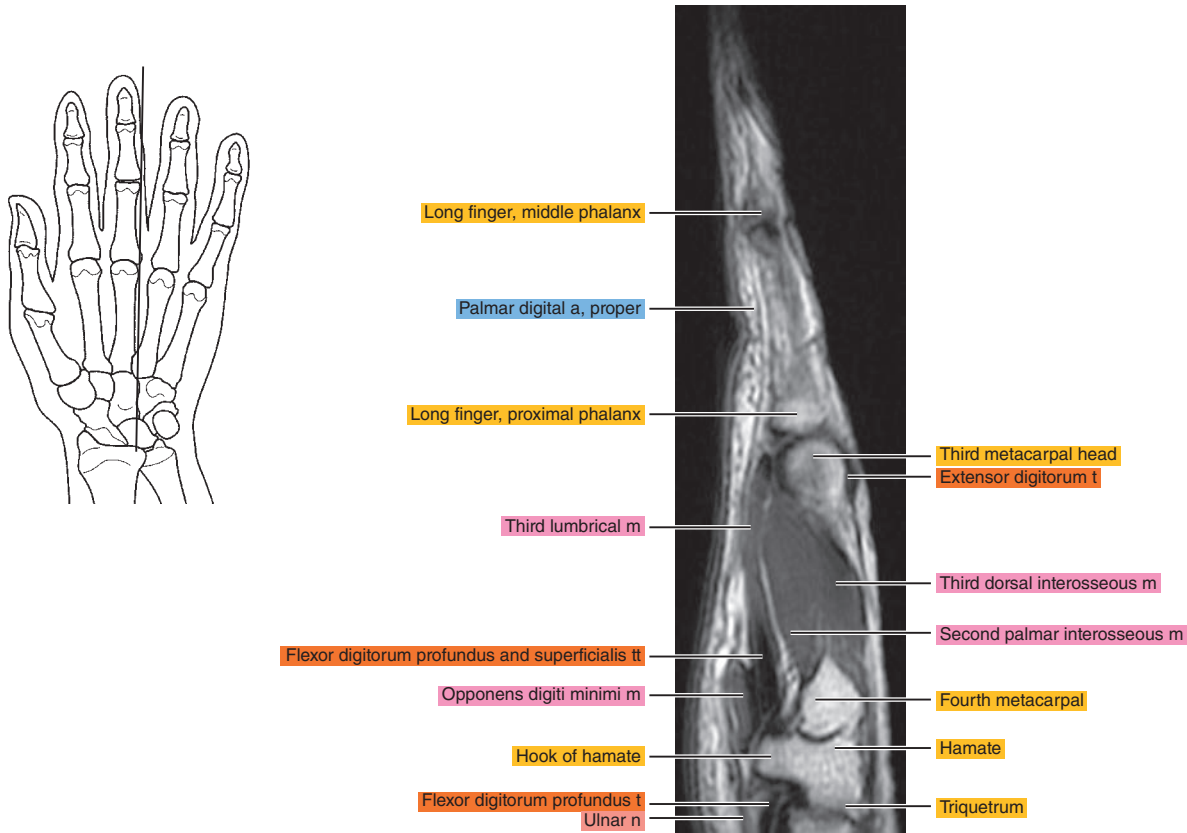


Figure 12.2.13

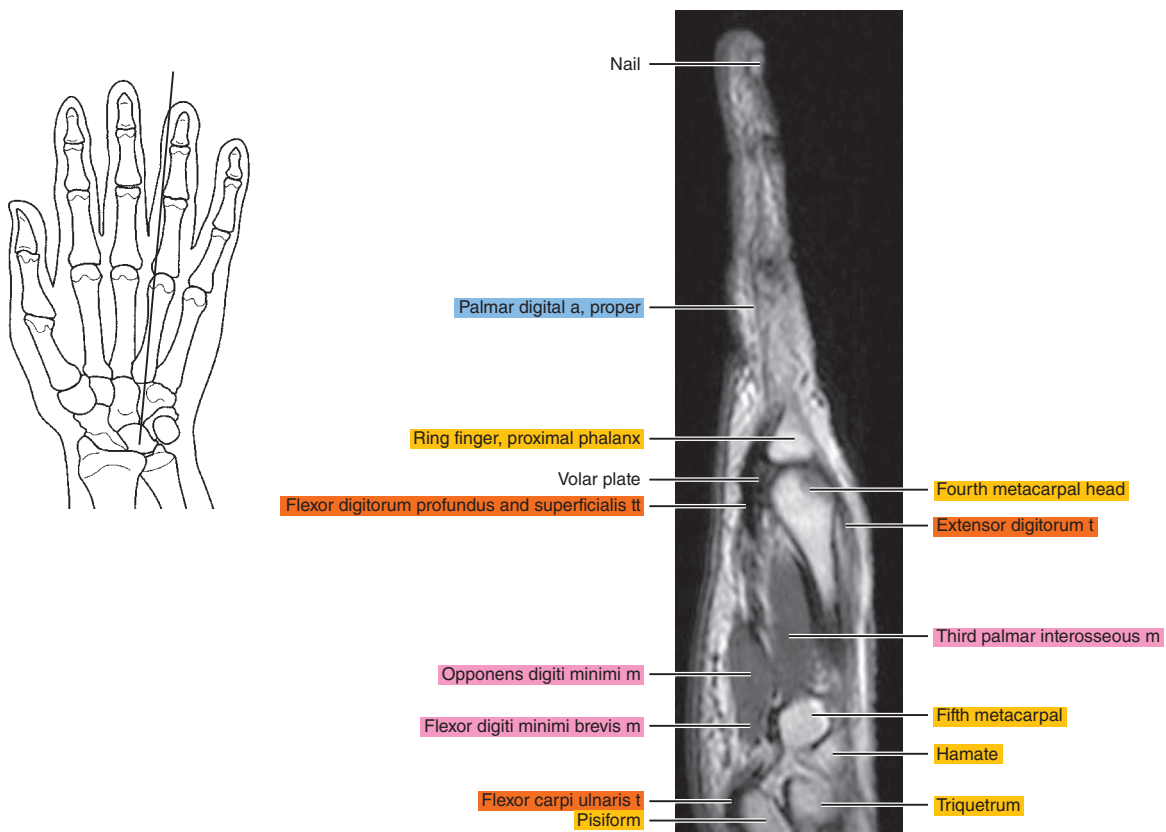


Figure 12.2.14

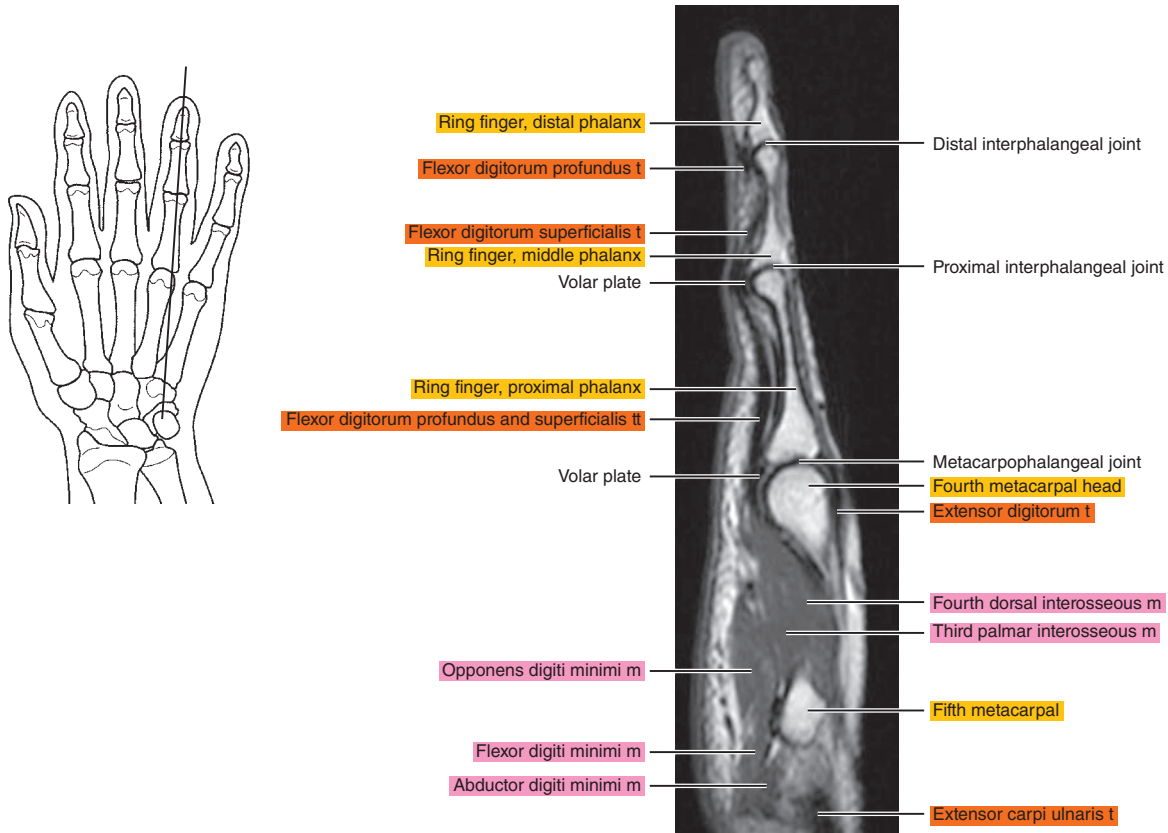


Figure 12.2.15

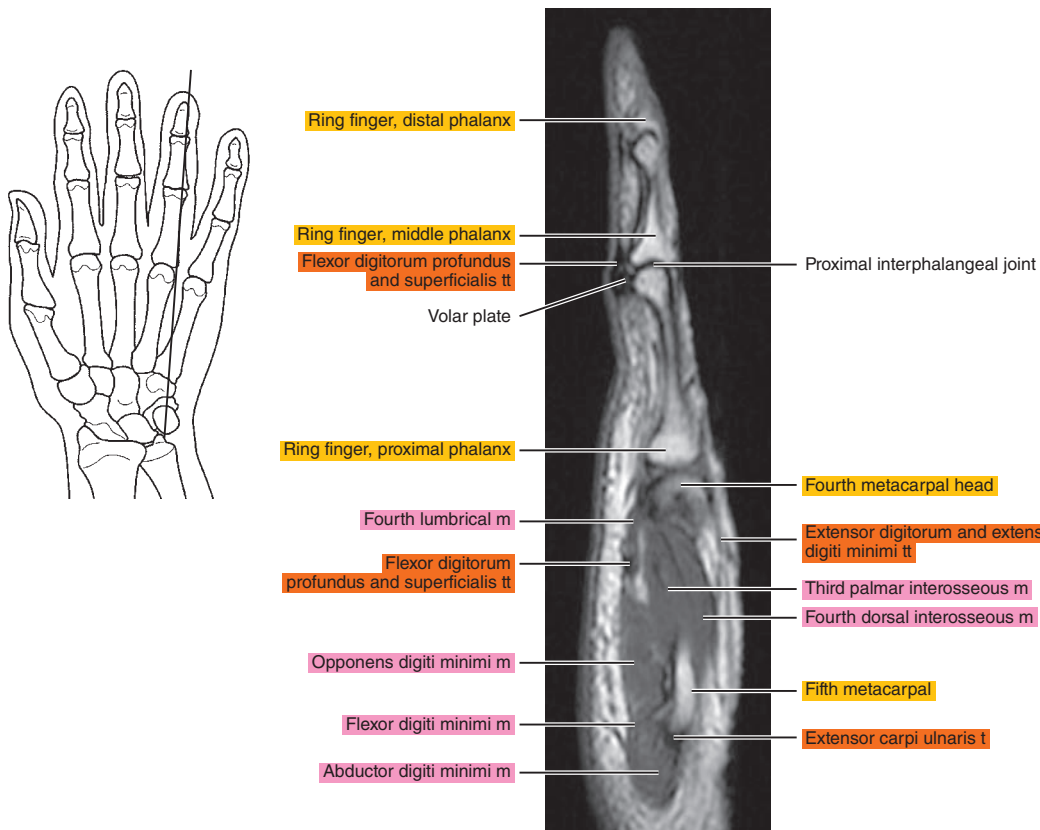


Figure 12.2.16

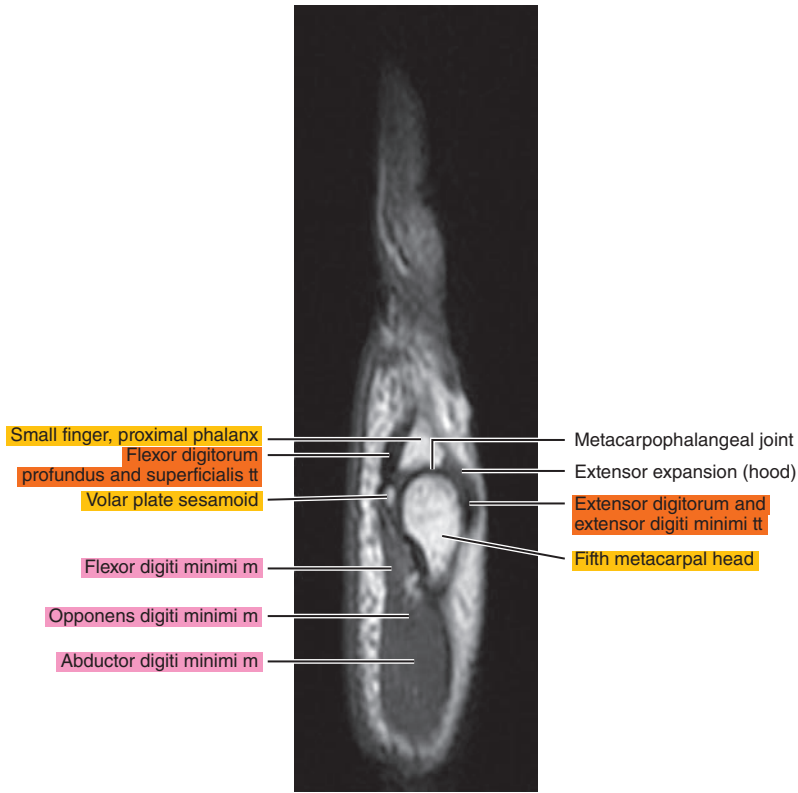
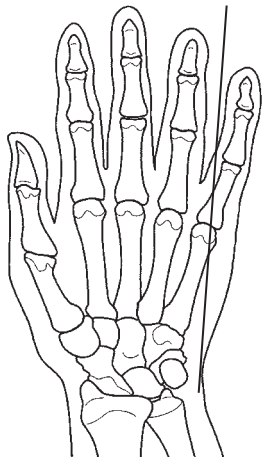


Figure 12.2.17

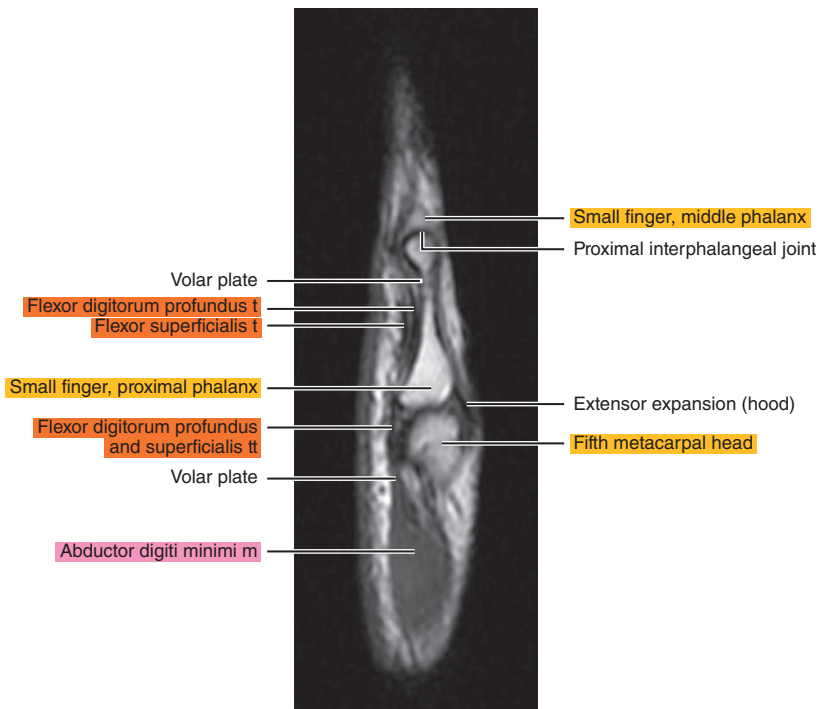
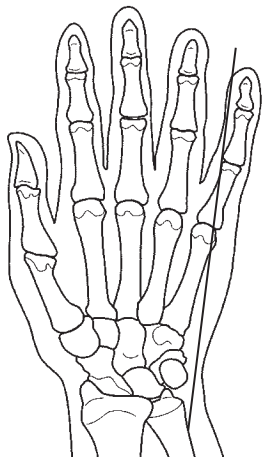
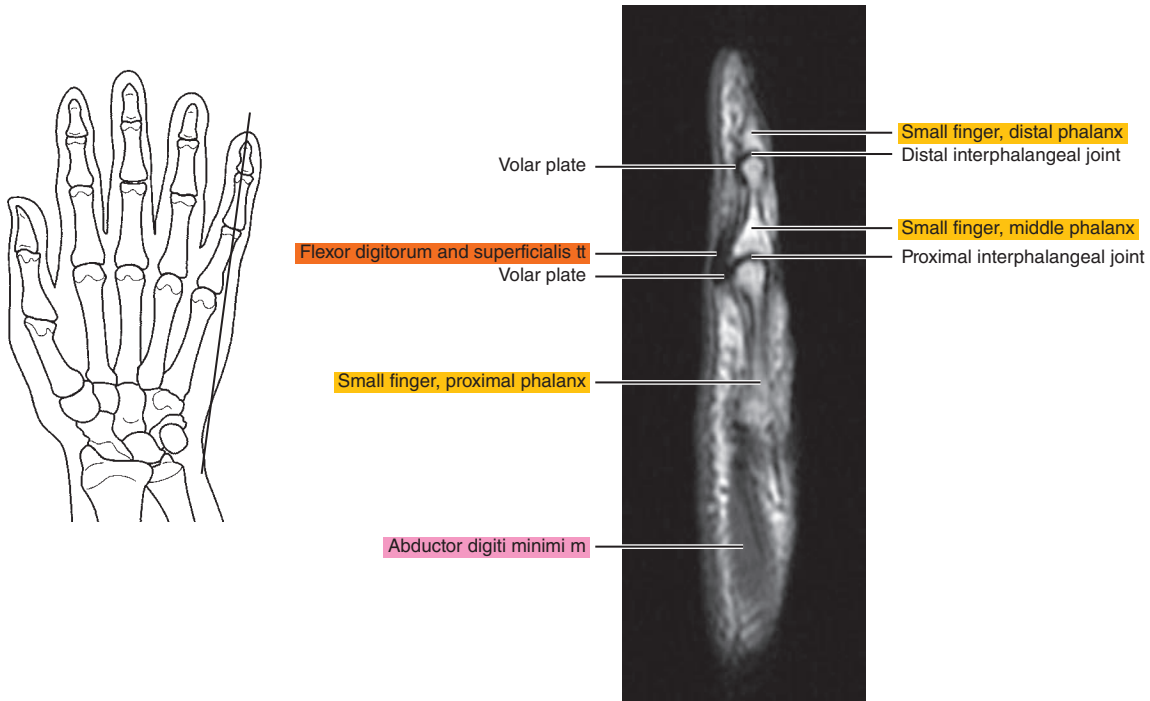


Figure 12.2.18





# CORONAL

Figure 12.3.1

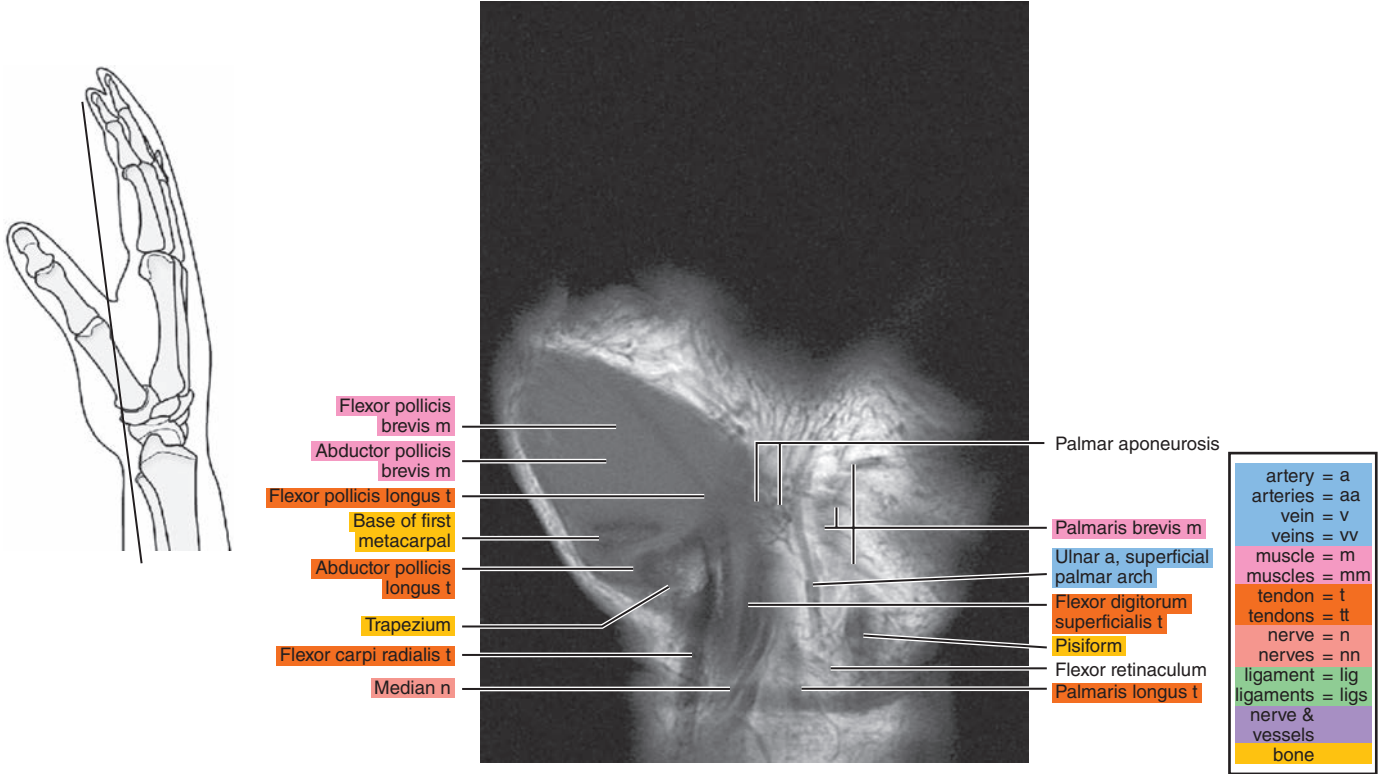


Figure 12.3.2

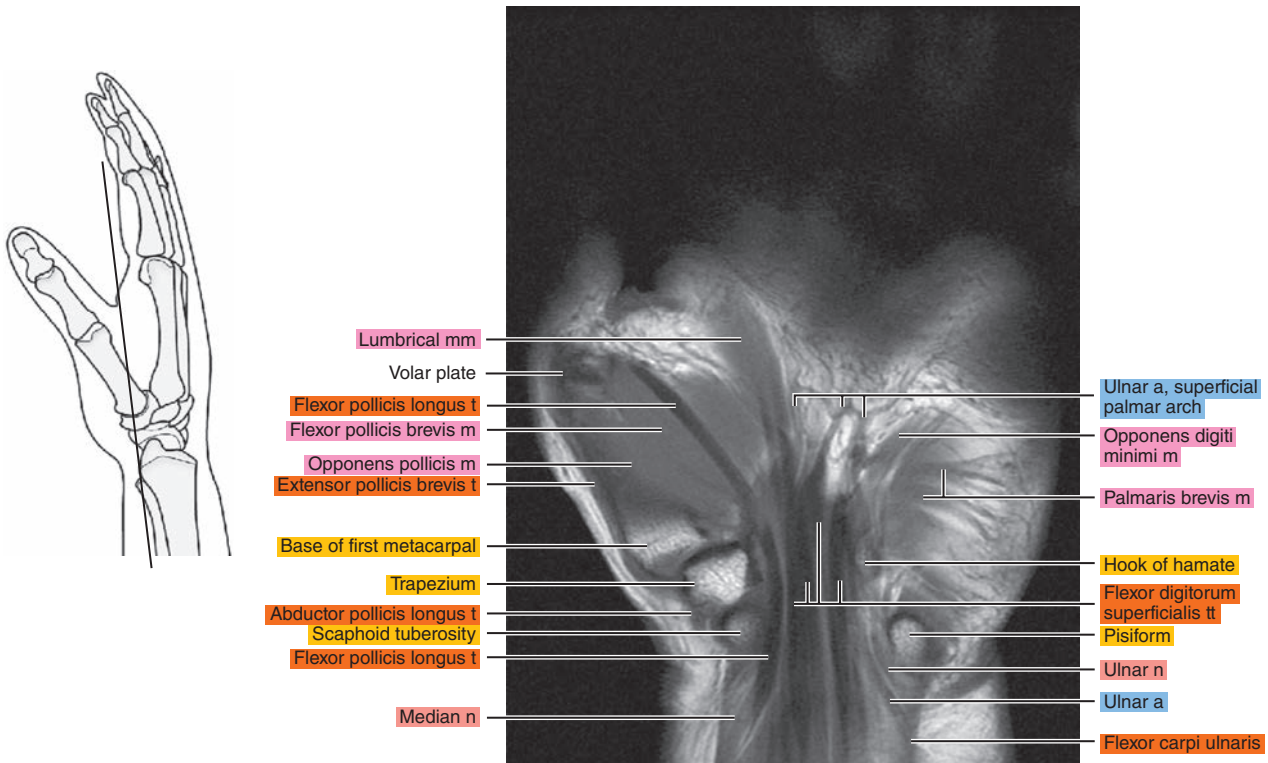


Figure 12.3.3

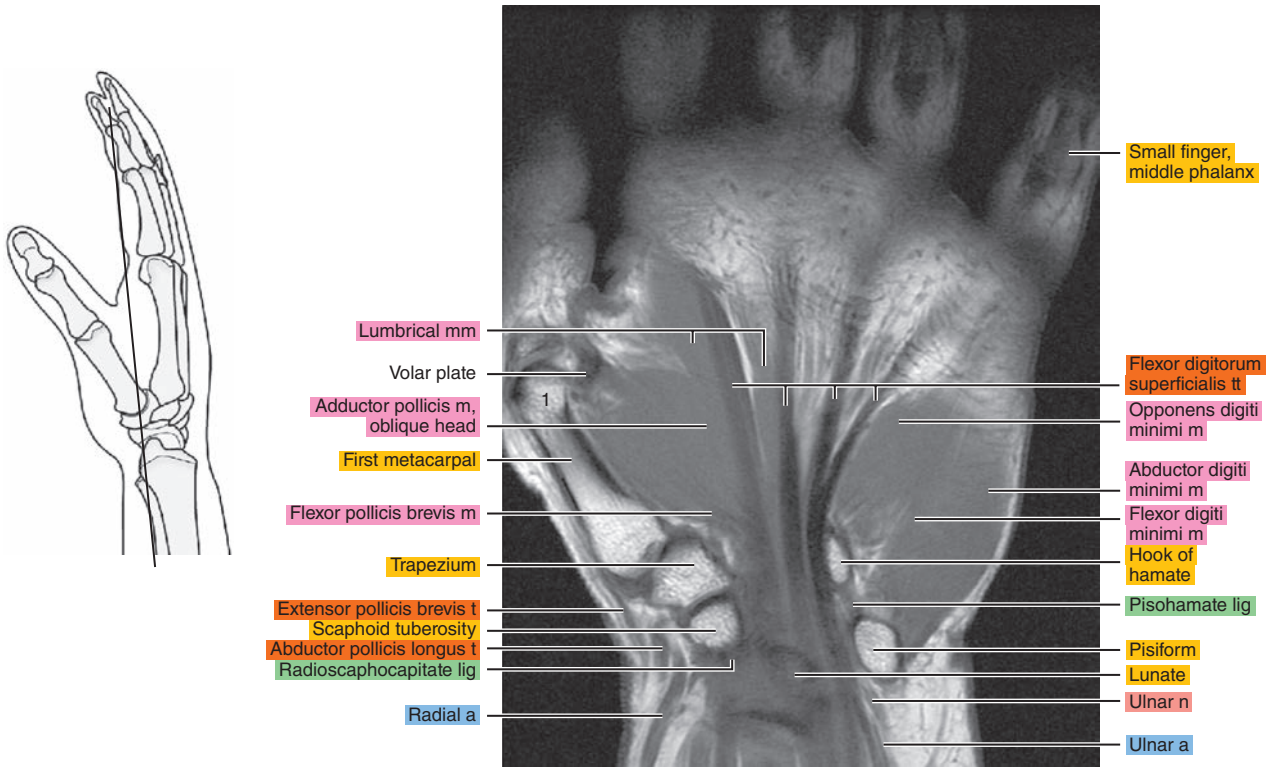


Figure 12.3.4

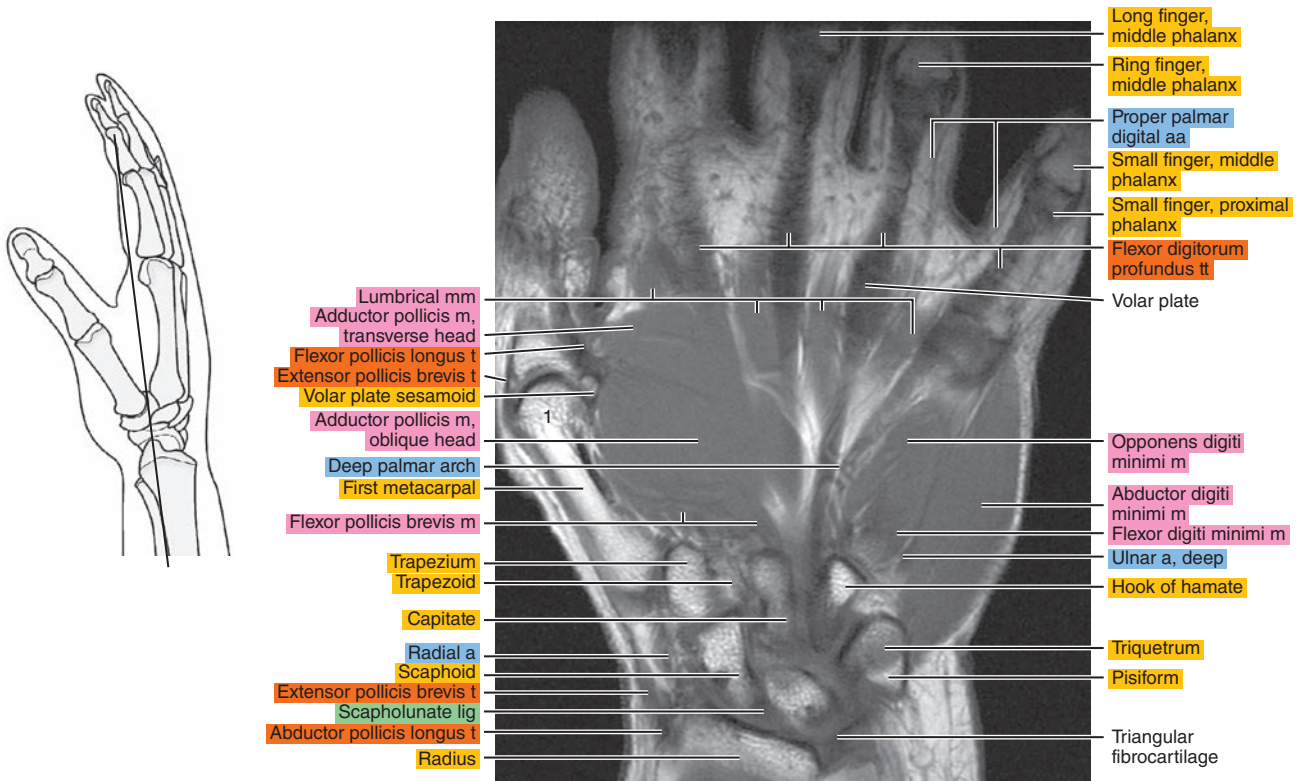


Figure 12.3.5

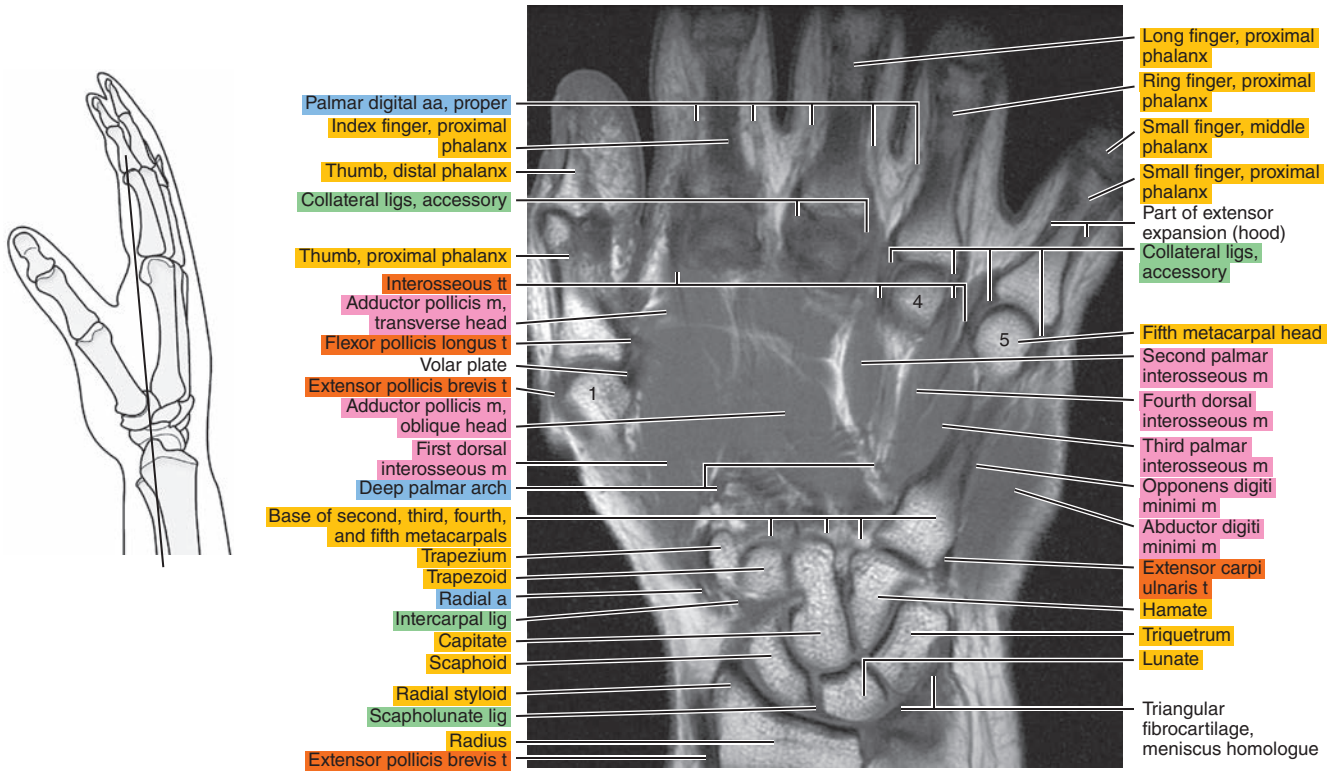


Figure 12.3.6

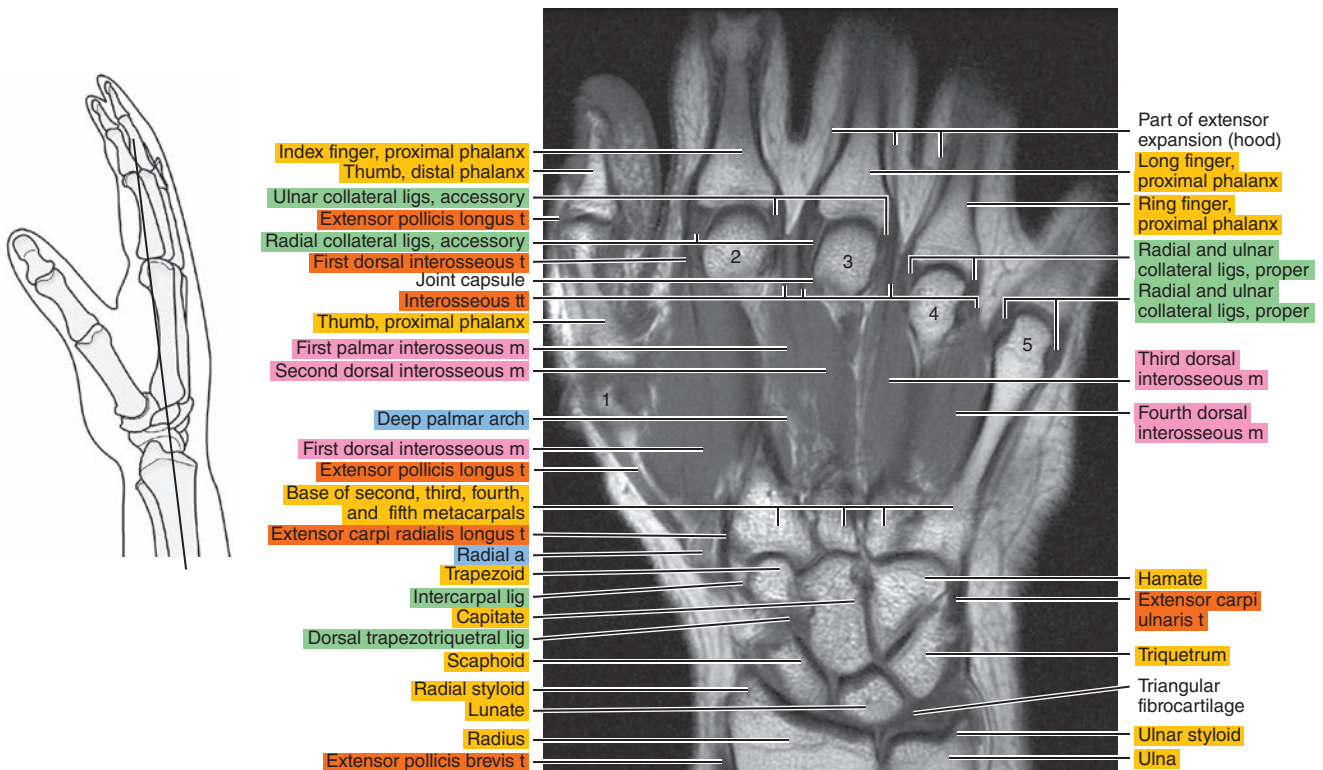




Figure 12.3.7

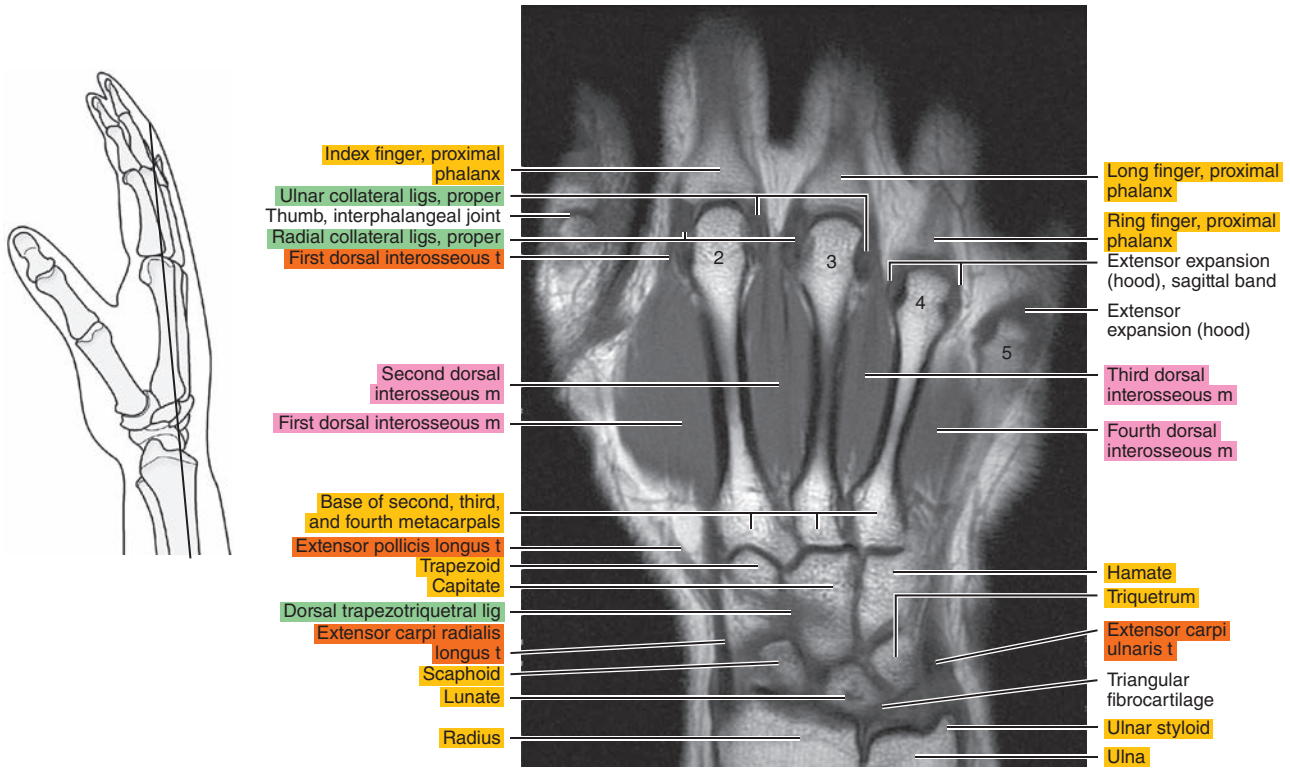


Figure 12.3.8

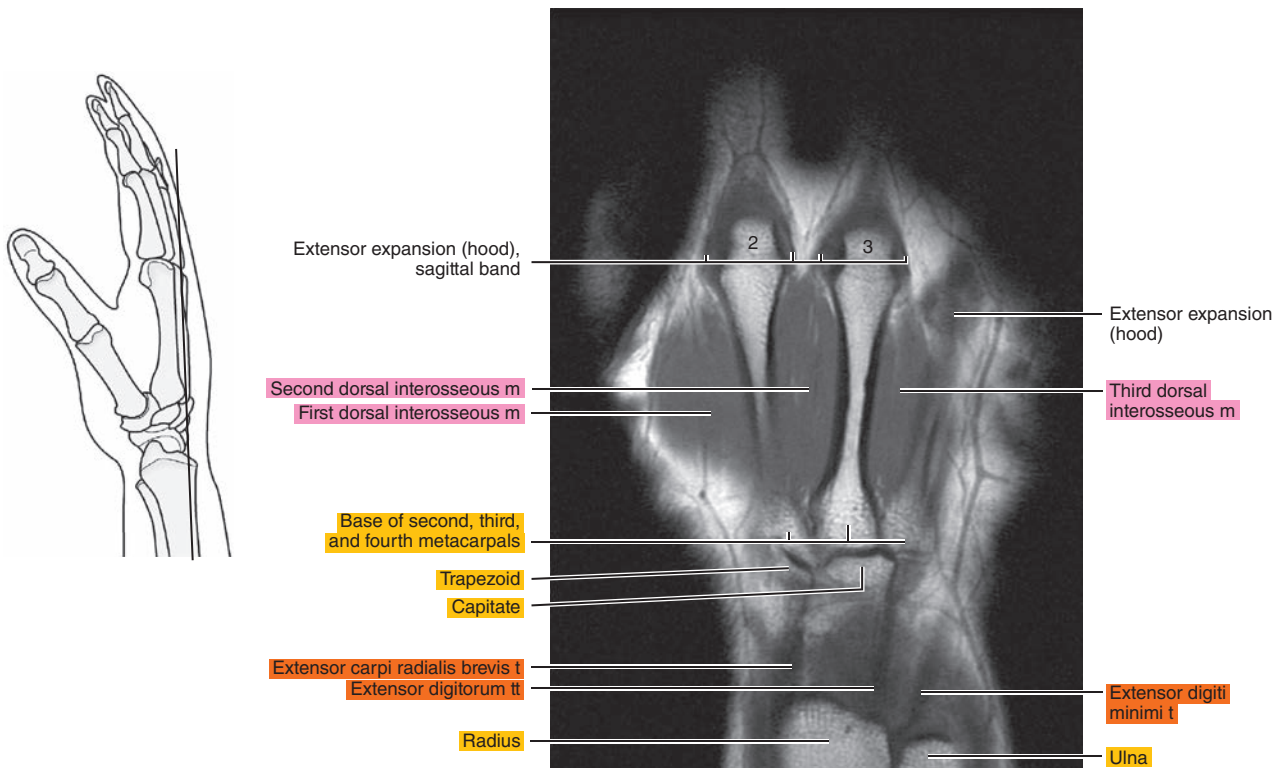
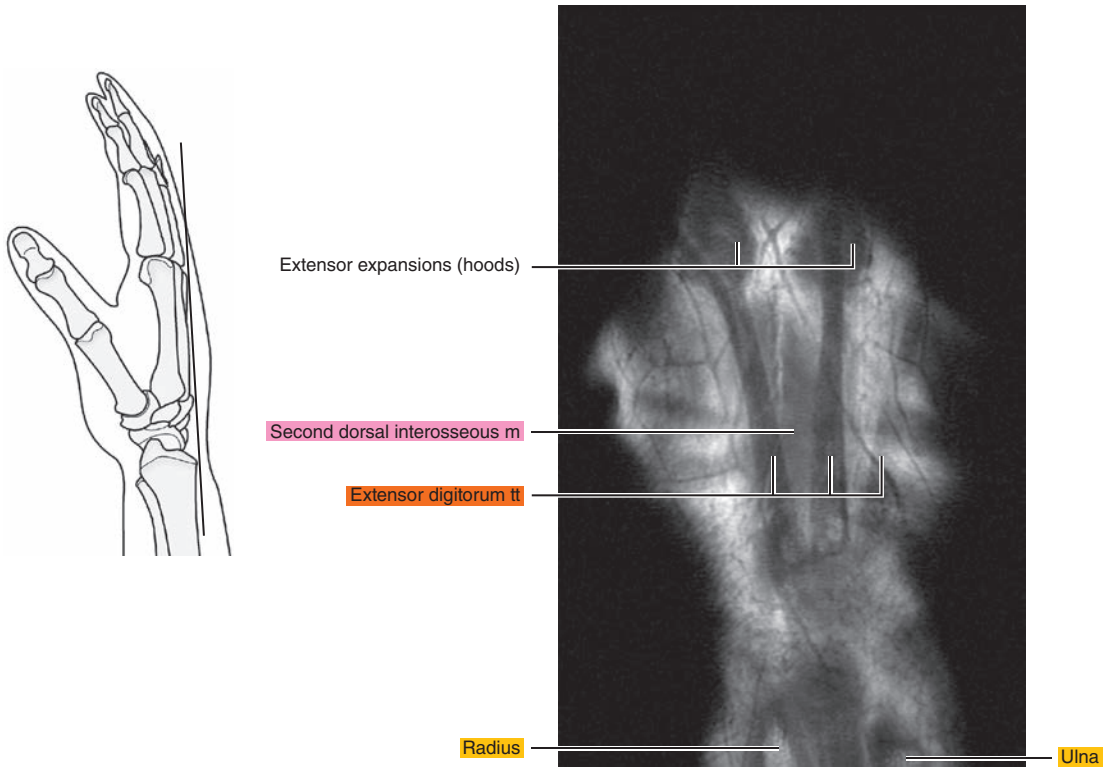




Figure 12.3.9



**Table 12-1. Muscles of the Hand**

MUSCLE	ORIGIN	INSERTION	NERVE SUPPLY
<b>Palmaris brevis</b>	Ulnar border of the palmar aponeurosis.	Deep surface of the skin along the ulnar border of the palm.	Superficial branch of ulnar (C8 and T1)
<b>Abductor pollicis brevis</b>	Palmar surface of the flexor retinaculum, trapezium, and, occasionally, scaphoid.	Radial side of the base of the proximal phalanx of the thumb.	Recurrent branch of median (C8 and T1)
<b>Opponens pollicis</b>	Palmar surface of the flexor retinaculum and tubercle of the trapezium.	Lateral part of the palmar surface of the shaft of the first metacarpal.	Recurrent branch of median (C8 and T1)
<b>Flexor pollicis brevis</b>	Superficial head: trapezium, adjacent part of the flexor retinaculum, and tendon sheath of the flexor carpi radialis; deep head: trapezoid and capitate.	Superficial head: lateral side of the palmar aspect of the base of the proximal phalanx; deep head: into a tendon of the superficial head.	Recurrent branch of median and deep branch of ulnar (C8 and T1)
<b>Adductor pollicis brevis</b>	Carpal head: flexor retinaculum, capitate, bases of the second and third metacarpals; metacarpal head: palmar ridges of the third metacarpal and capsules of the second, third, and fourth metacarpophalangeal articulations.	Ulnar side of the palmar aspect of the base of the proximal phalanx of the thumb.	Recurrent branch of median (C8 and T1)
<b>Abductor digiti minimi</b>	Distal half of the pisiform, pisohamate ligament, tendon of the flexor carpi ulnaris, and, frequently, the flexor retinaculum.	Two tendons: (1) the ulnar side of the base of the proximal phalanx of the little finger and (2) the aponeurosis of the extensor tendon of the little finger.	Deep palmar division of ulnar (C8 and T1)
<b>Flexor digiti minimi brevis</b>	Hook of the hamate and adjacent parts of the flexor retinaculum.	Ulnar side of the base of the proximal phalanx of the little finger.	Superficial or deep palmar branch of ulnar (C8 and T1)
<b>Opponens digiti minimi</b>	Distal border of the hook of the hamate and adjacent flexor retinaculum.	Medial surface of the body and particularly onto the head of the fifth metacarpal.	Deep palmar branch of ulnar (C8 and T1)
<b>Lumbrical</b>	Two lateral lumbricals: radial and palmar sides of the first and second tendons of the flexor digitorum profundus; two medial lumbricals: adjacent side of the second and third tendons, and the third and fourth tendons of the flexor digitorum profundus.	Into the radial border of the tendon of the extensor digitorum on the dorsal aspect of the proximal phalanx.	Median, lateral two or three lumbricals; ulnar, deep palmar branch, medial one or two lumbricals (C8 and T1)
<b>Interosseous</b>	Palmar interosseous: anterior border of the shaft of the first, second, fourth, and fifth metacarpals. The first arises near the base and the others arise from three-fourths of the shaft of the bone. Dorsal interosseous: adjacent sides of the metacarpal bones in each metacarpal interspace.	Into the expansion on the axial side of the corresponding digit. The first palmar interosseous is described frequently as a division of the flexor brevis or adductor pollicis. The first dorsal interosseous usually inserts onto the proximal phalanx. The other three insert into the extensor expansion and proximal phalanx.	Deep palmar branch of ulnar (C8 and T1)

*Chapter*  
**13**

**MRI of the Cervical Spine**

# AXIAL

Figure 13.1.1

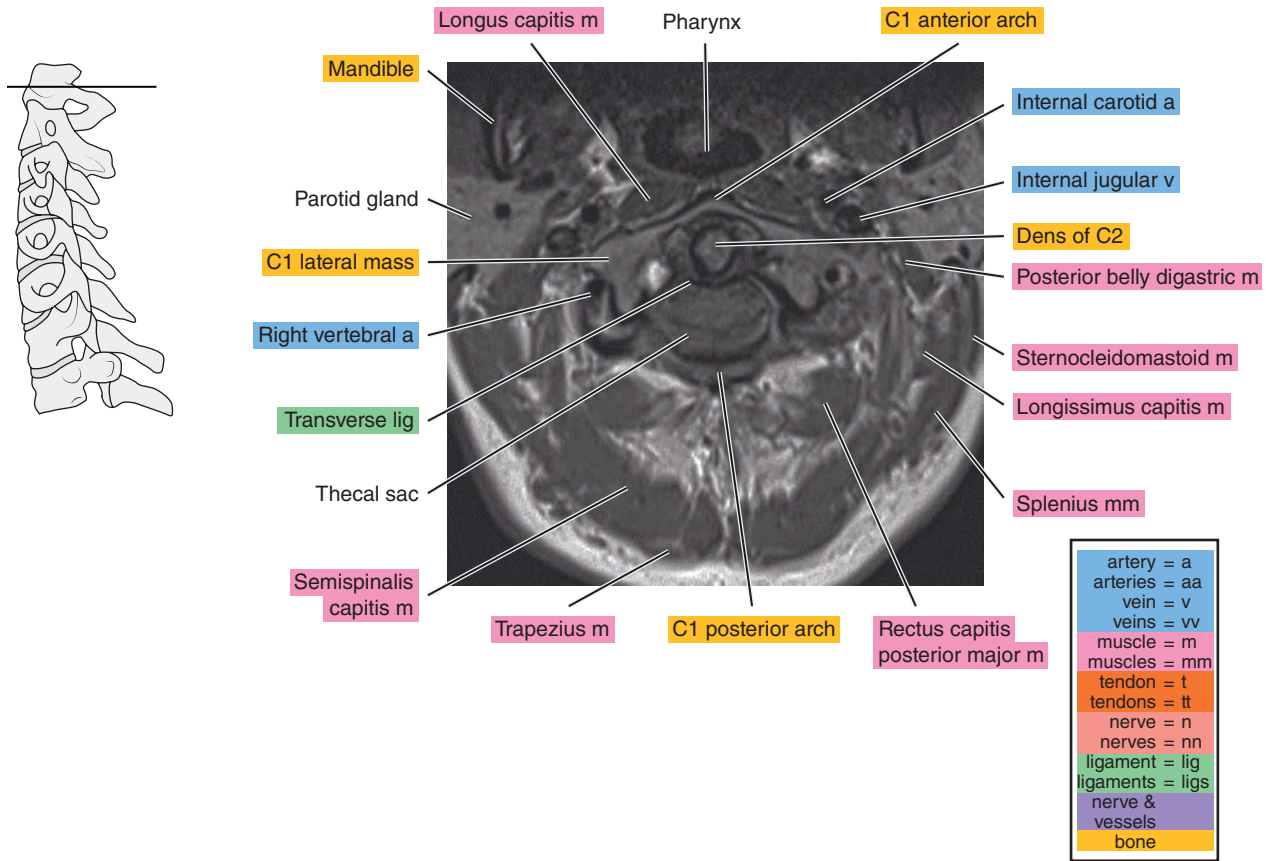


Figure 13.1.2

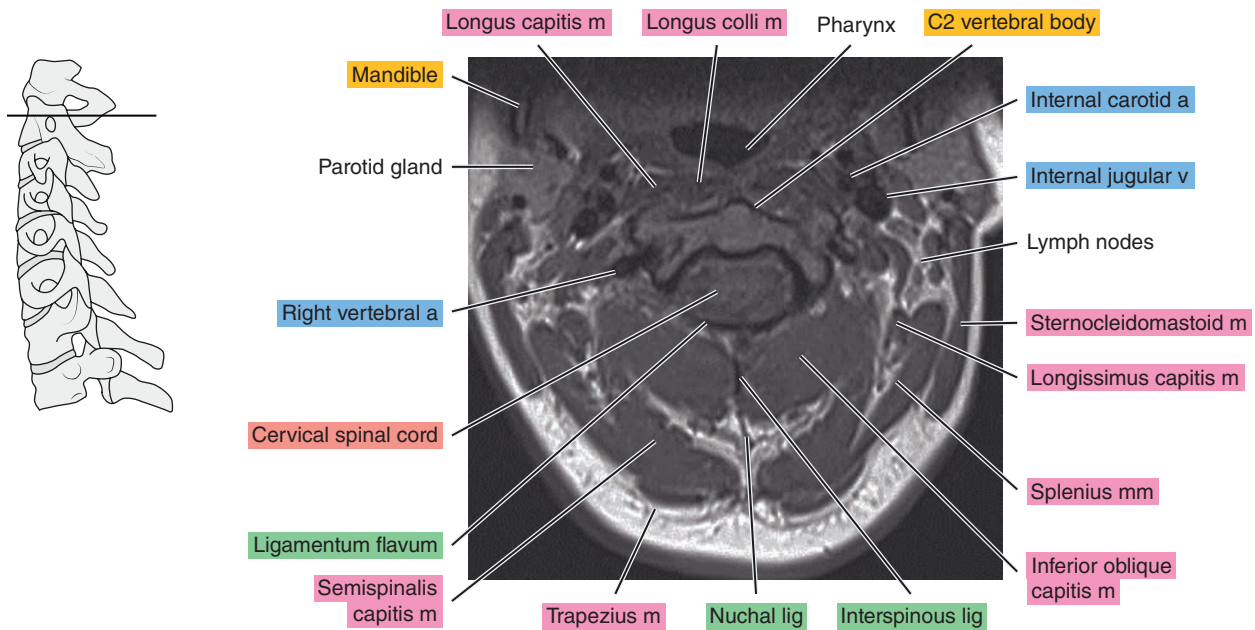




Figure 13.1.3

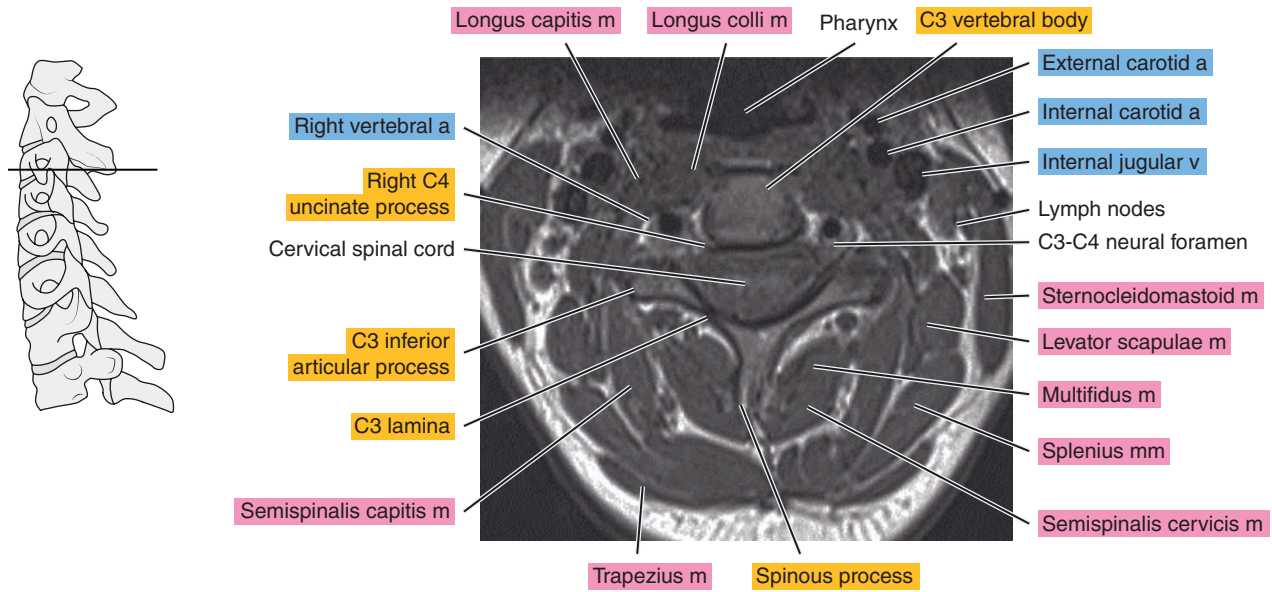


Figure 13.1.4

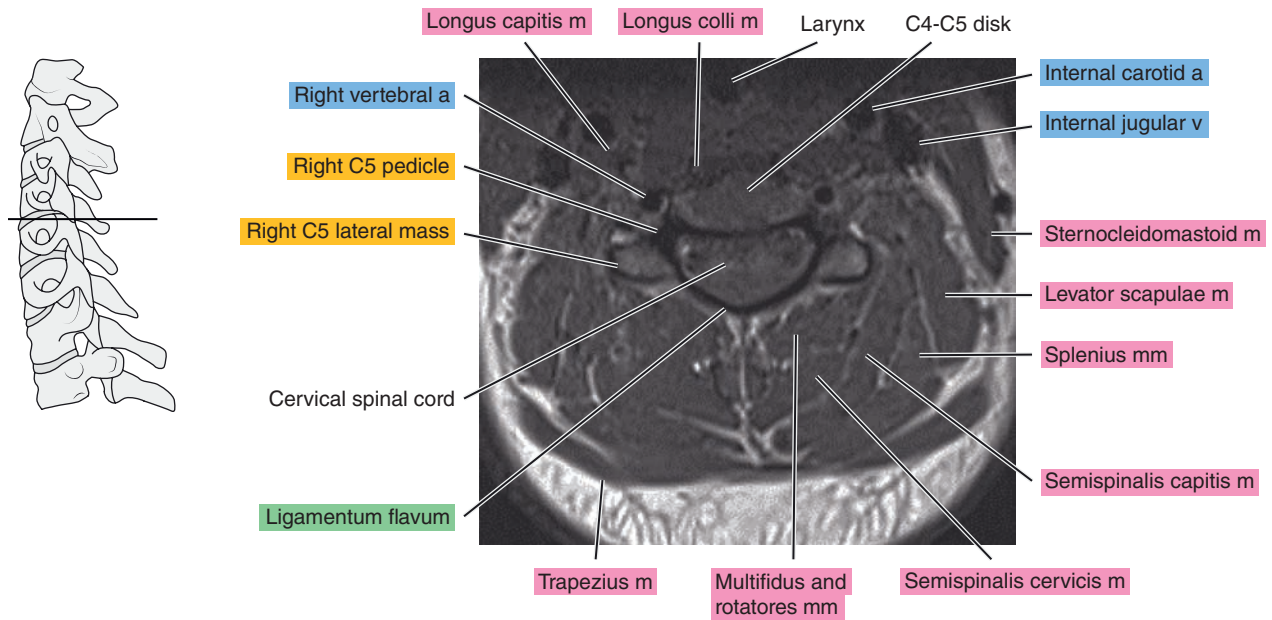


Figure 13.1.5

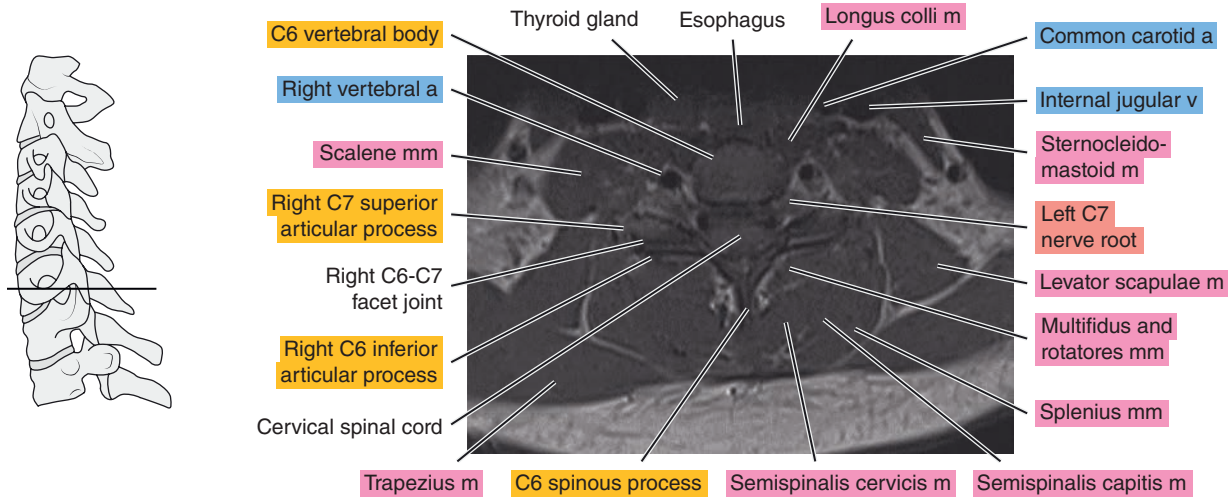
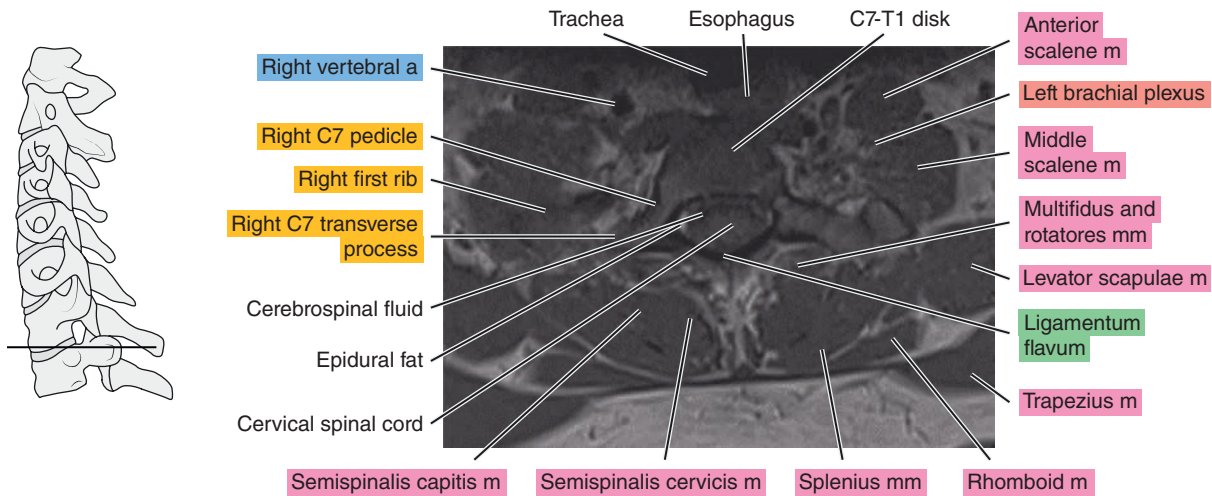


Figure 13.1.6



# SAGITTAL

Figure 13.2.1

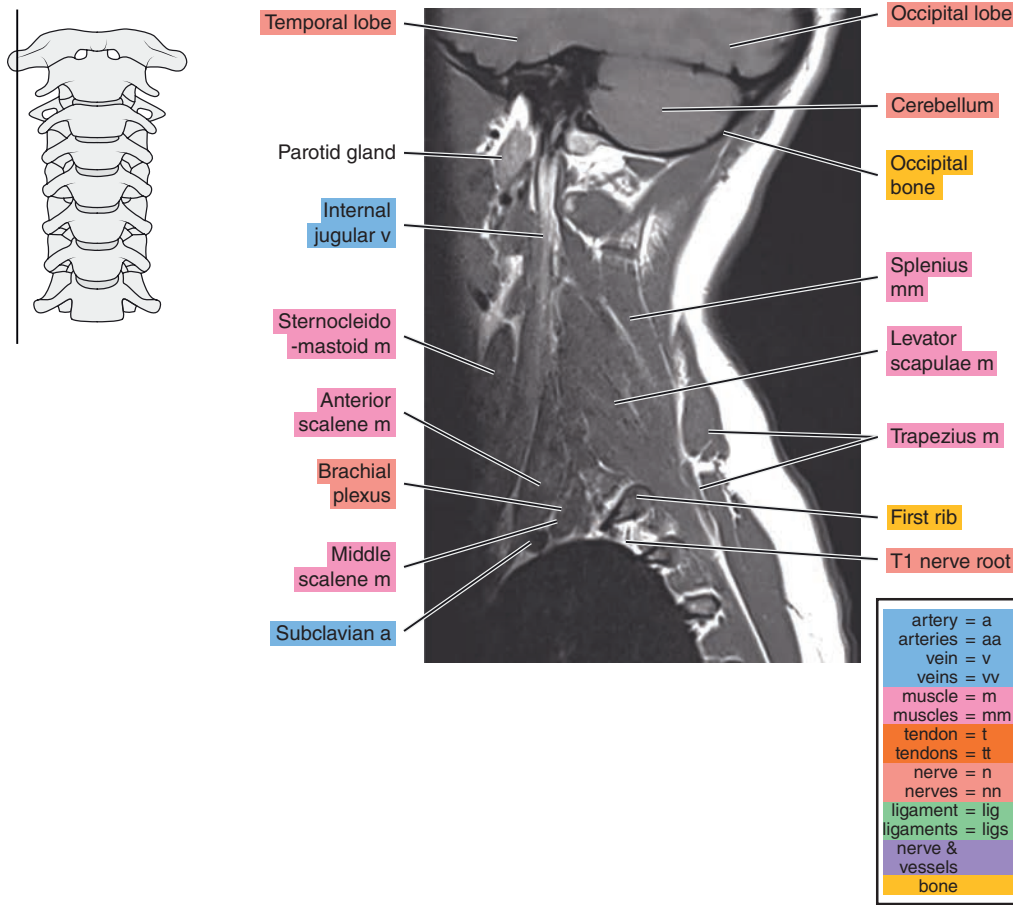


Figure 13.2.2

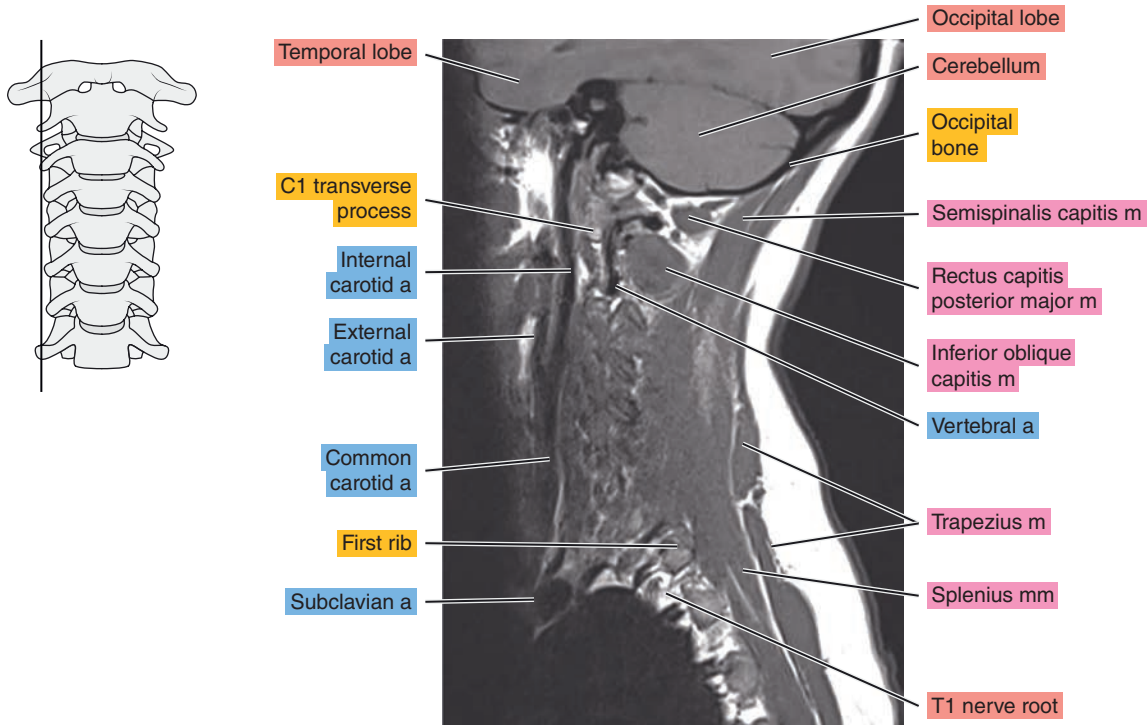


Figure 13.2.3

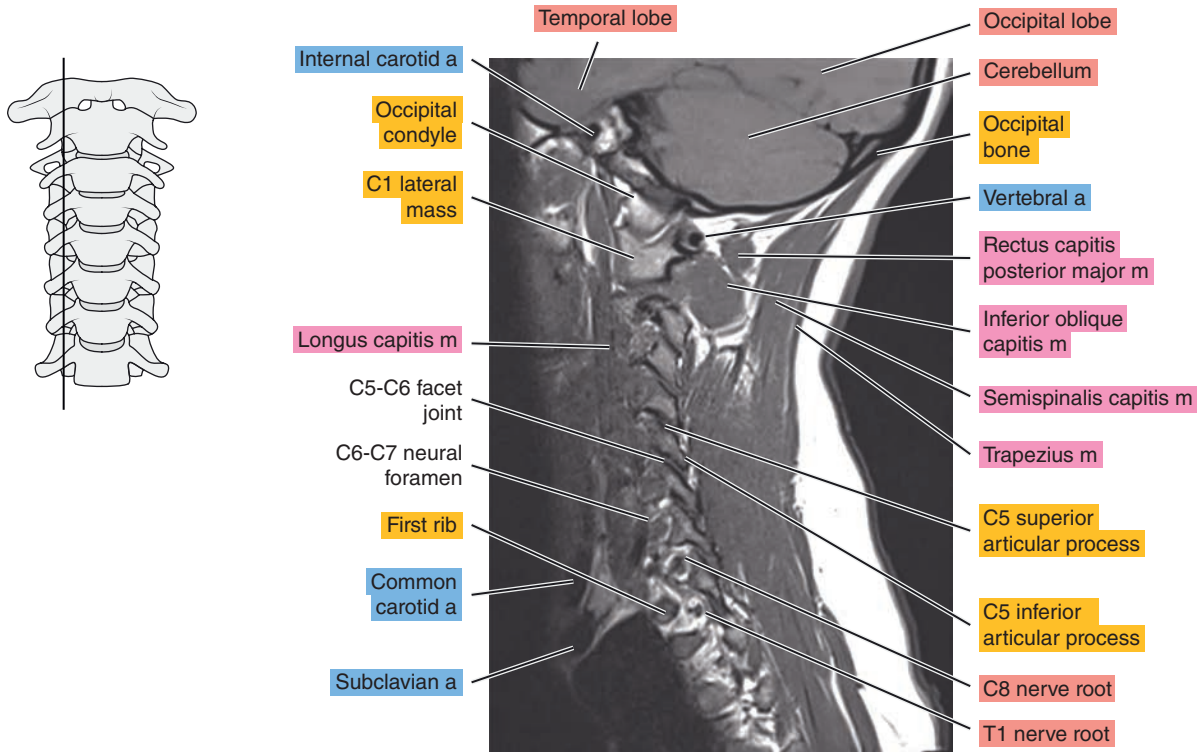


Figure 13.2.4

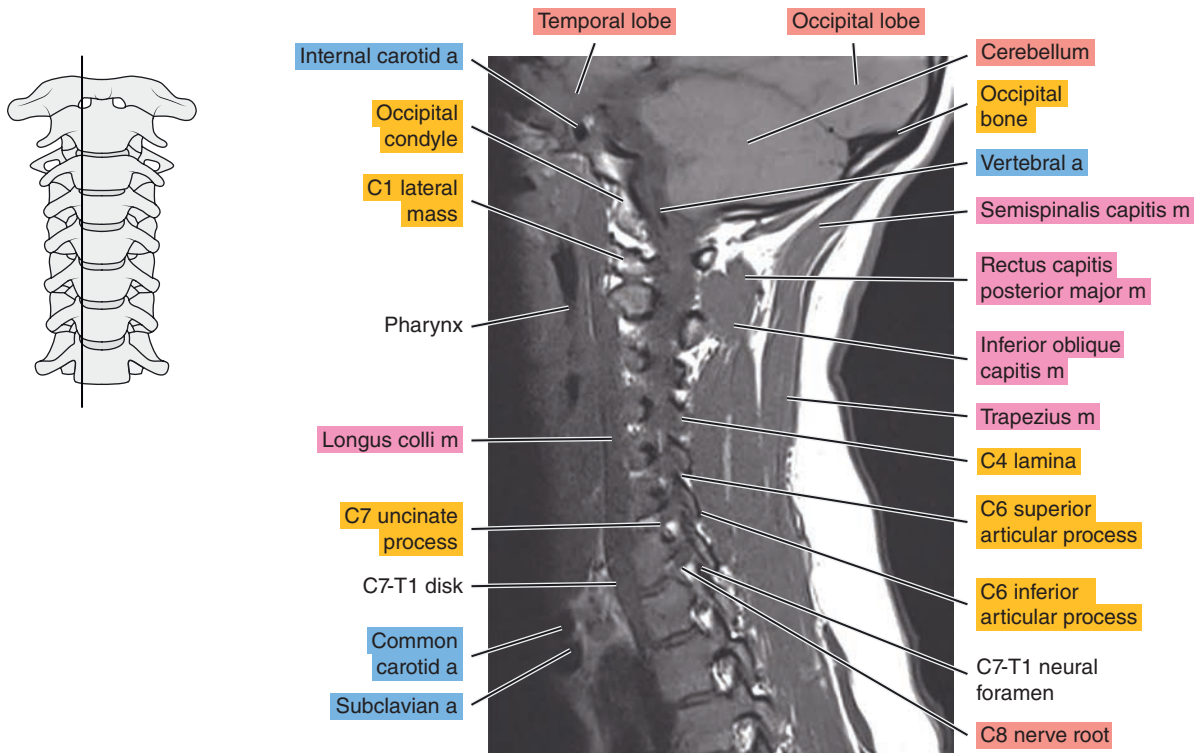
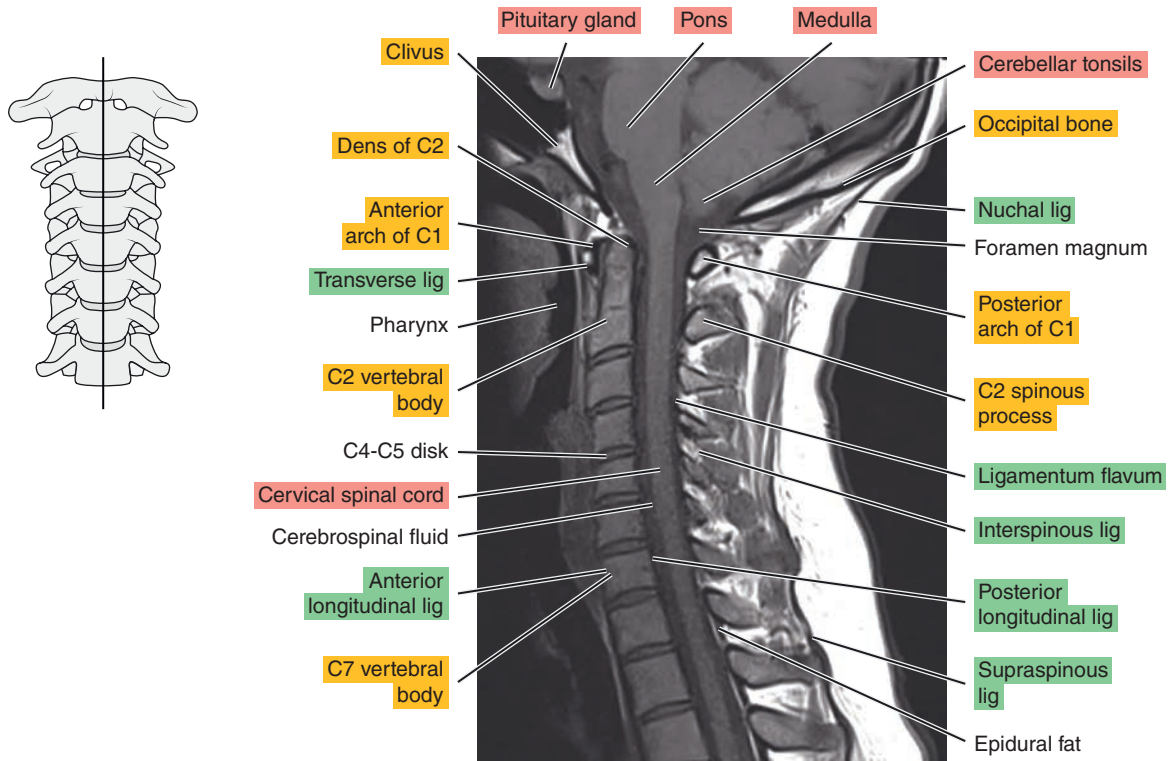


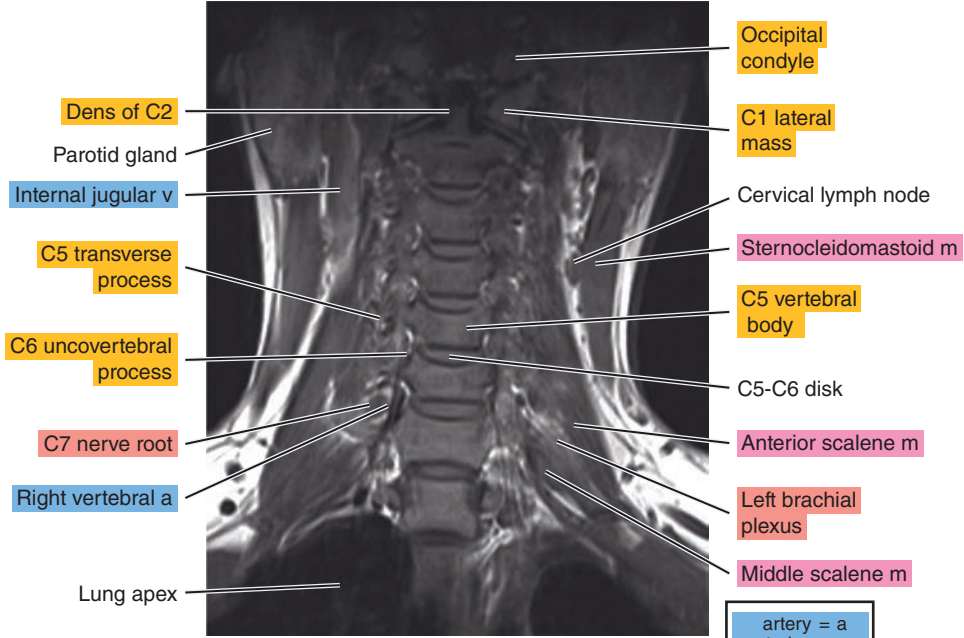
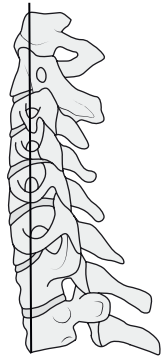


Figure 13.2.5



# CORONAL

Figure 13.3.1



artery = a
arteries = aa
vein = v
veins = vv
muscle = m
muscles = mm
tendon = t
tendons = tt
nerve = n
nerves = nn
ligament = lig
ligaments = ligs
nerve & vessels
bone

Figure 13.3.2

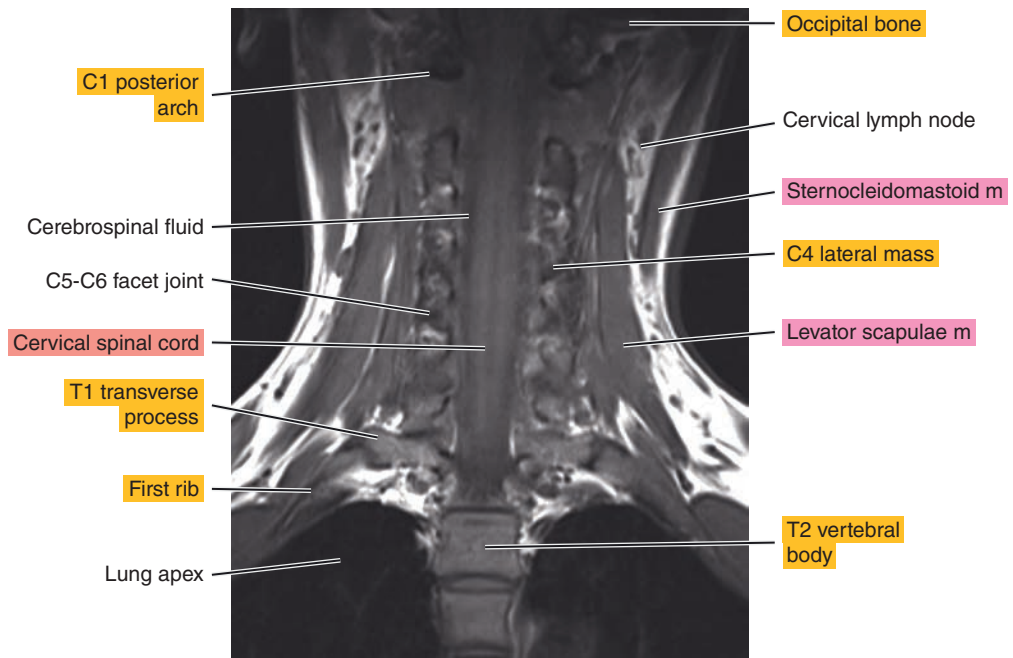
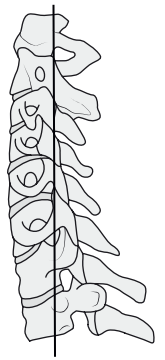

Figure 13.3.3

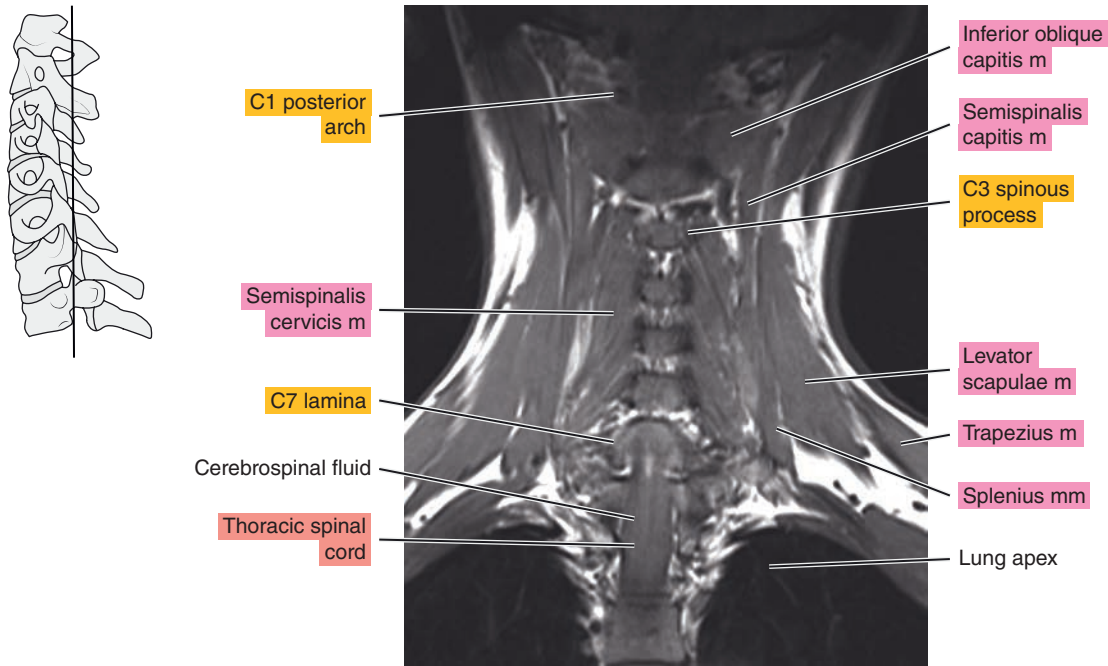
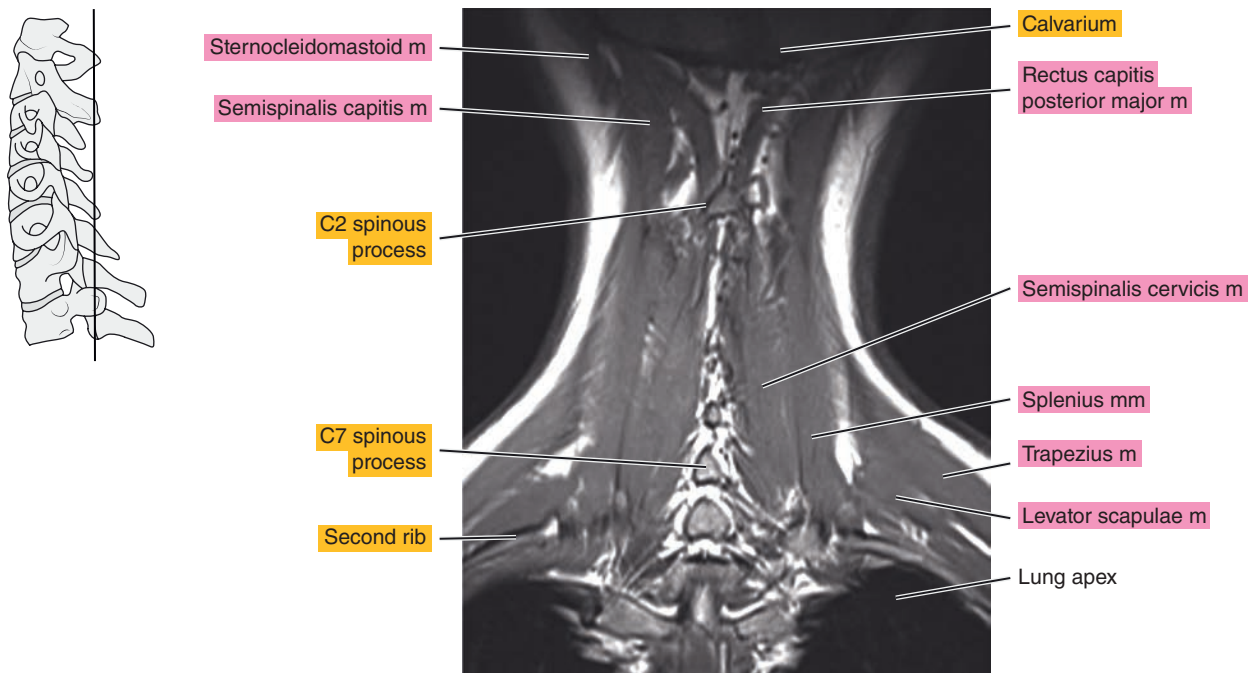


Figure 13.3.4



*Chapter*  
**14**

**MRI of the Thoracic Spine**



# AXIAL

Figure 14.1.1

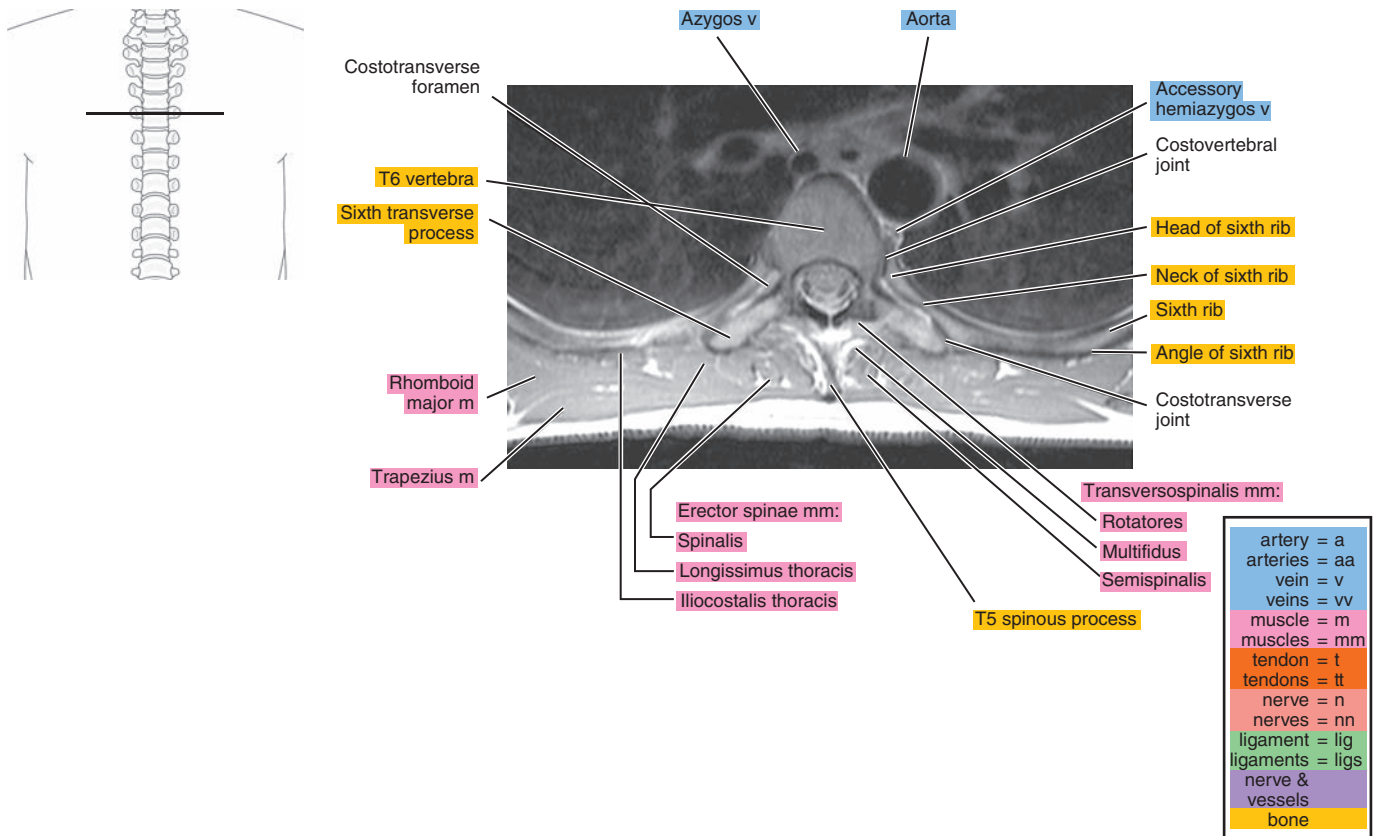


Figure 14.1.2

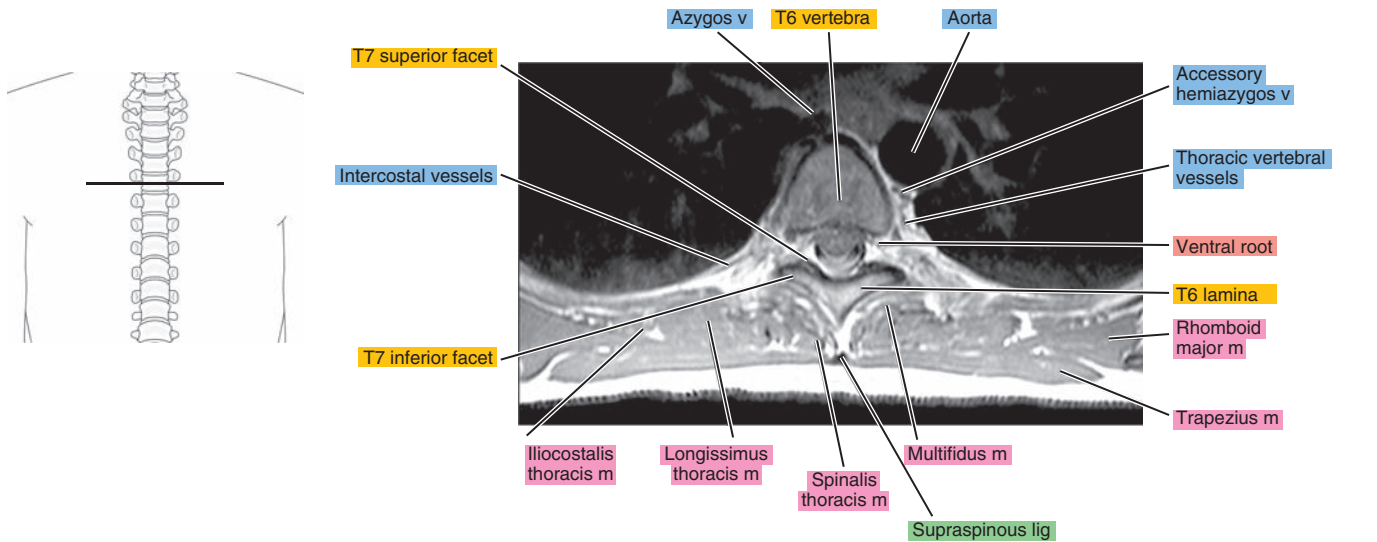


Figure 14.1.3

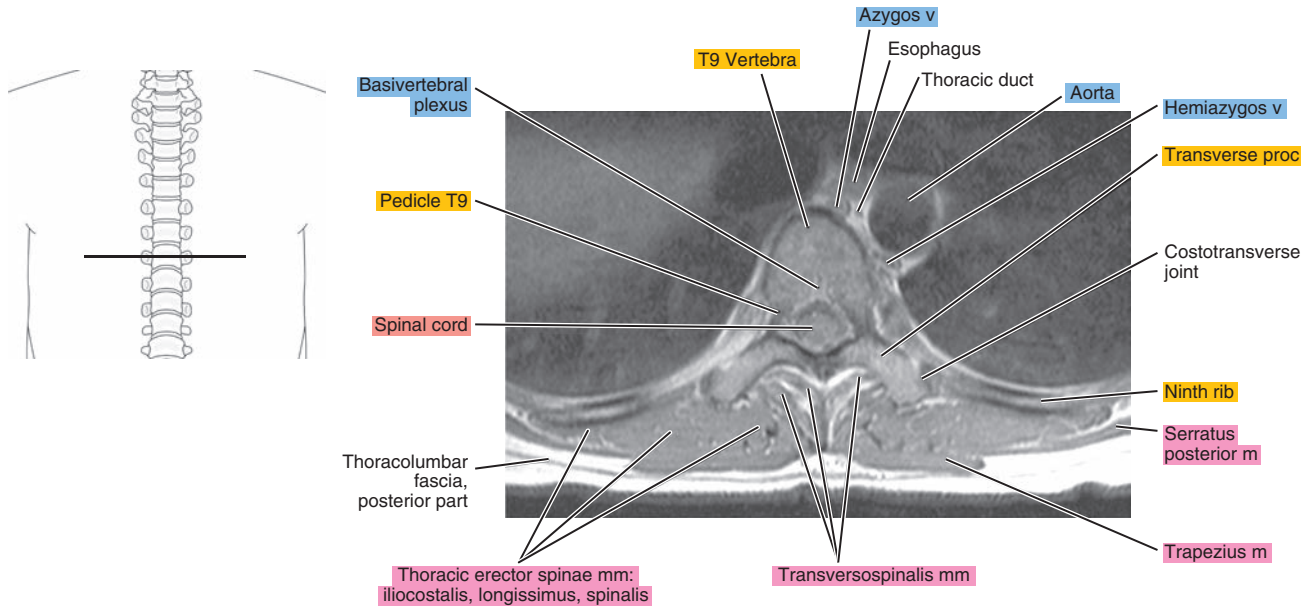
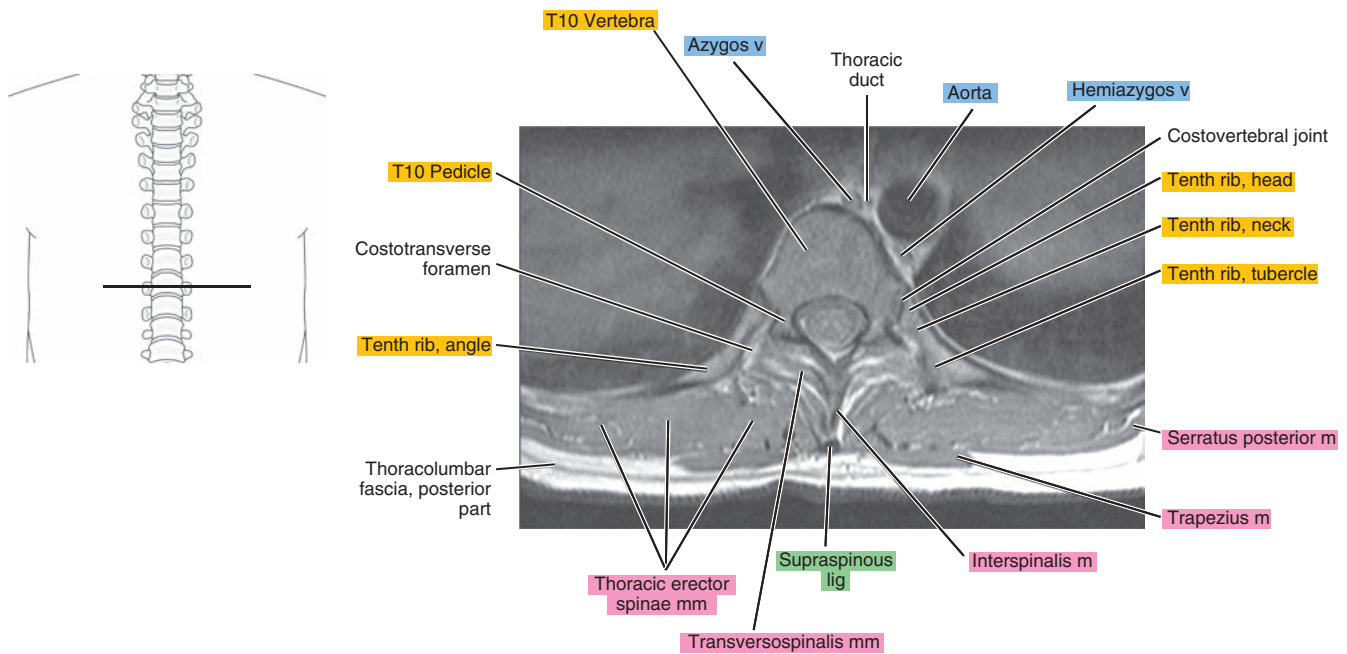


Figure 14.1.4



# SAGITTAL

Figure 14.2.1

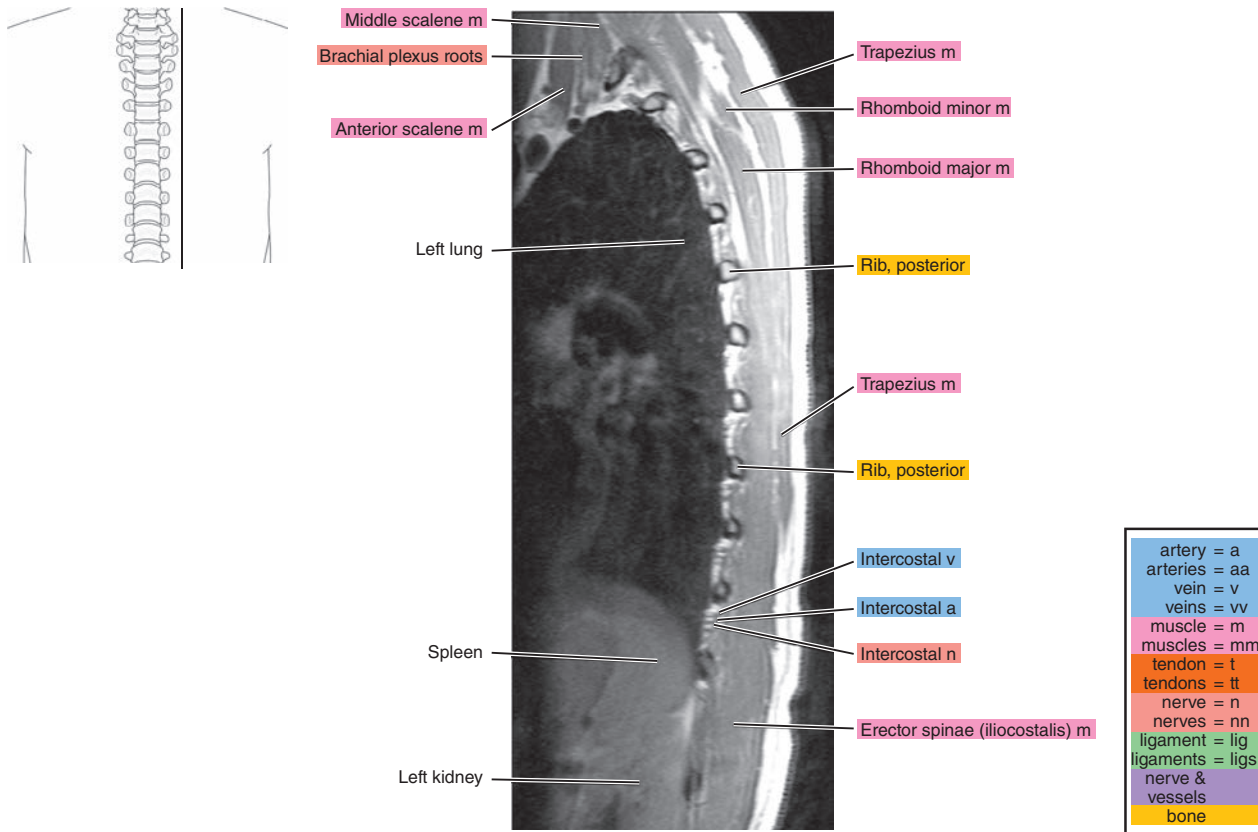


Figure 14.2.2

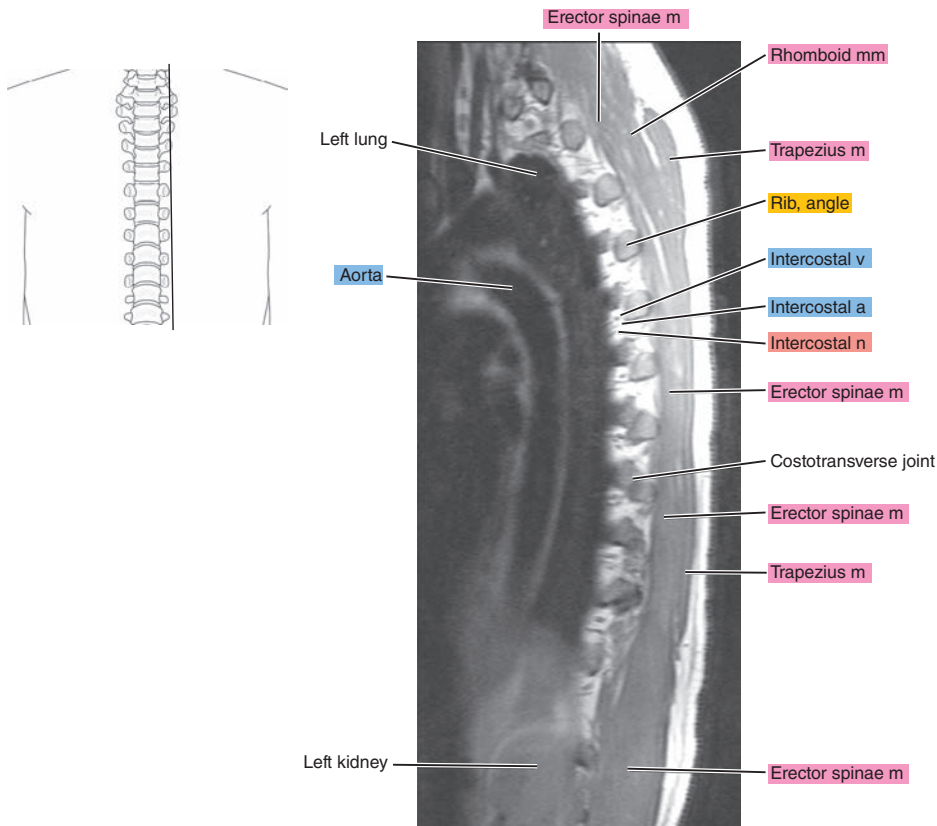


Figure 14.2.3

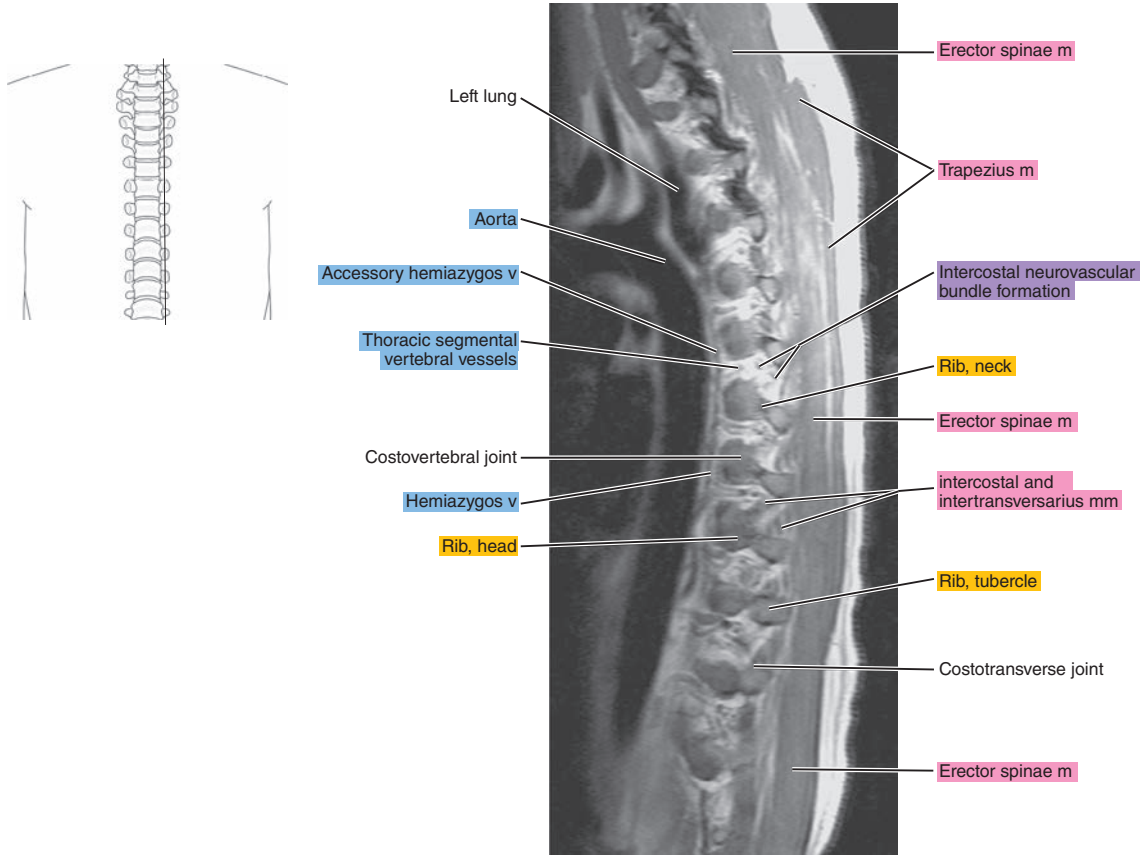


Figure 14.2.4

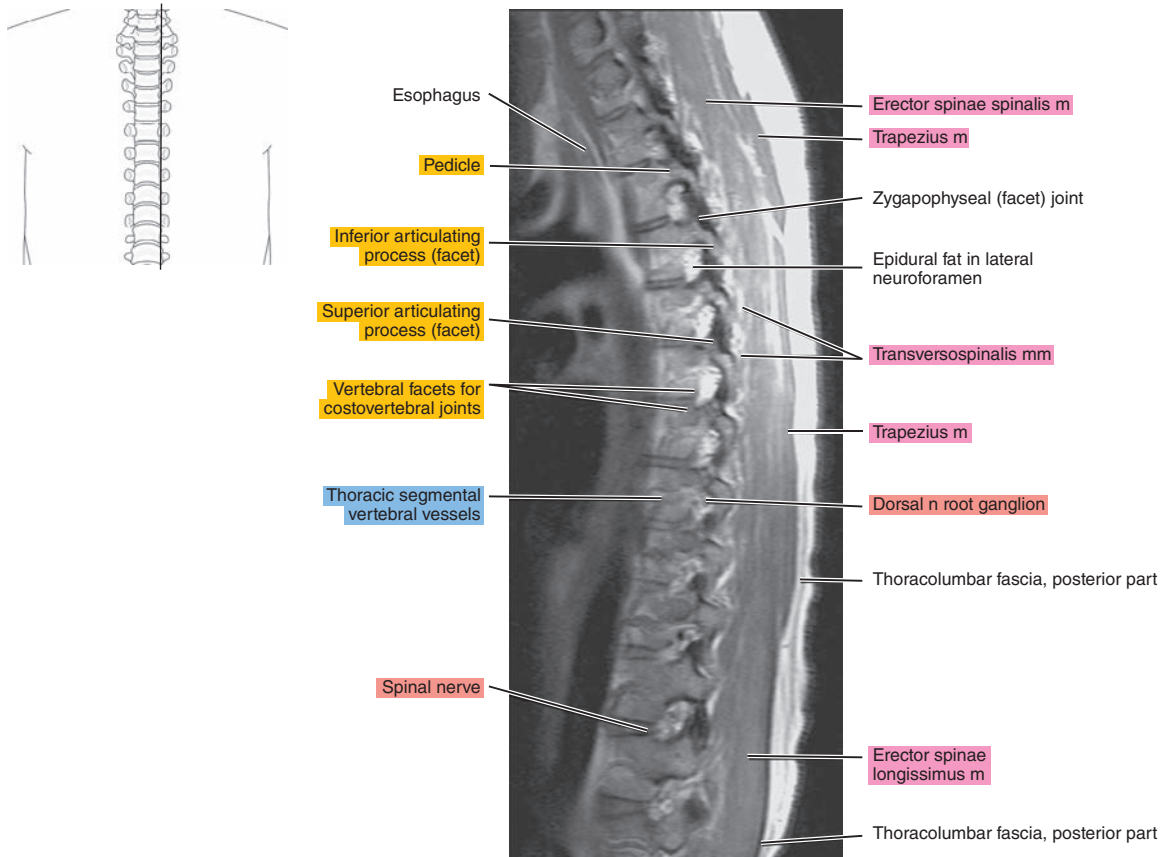




Figure 14.2.5

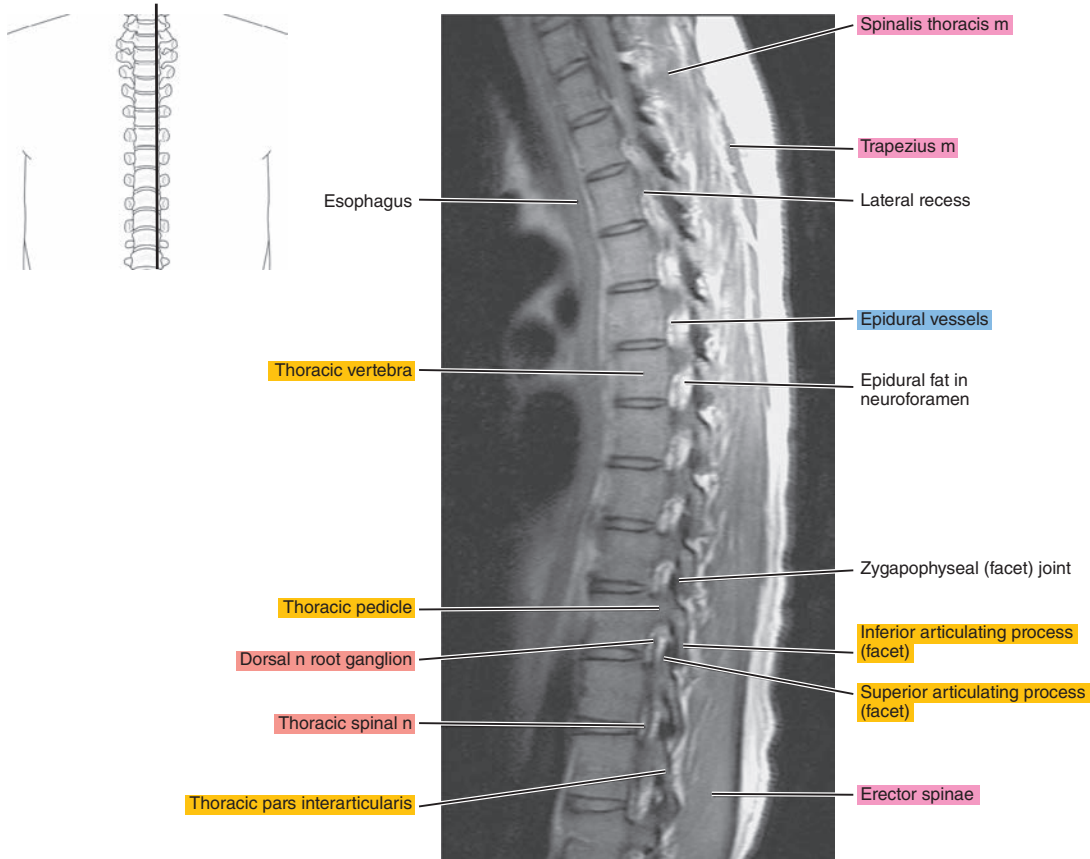
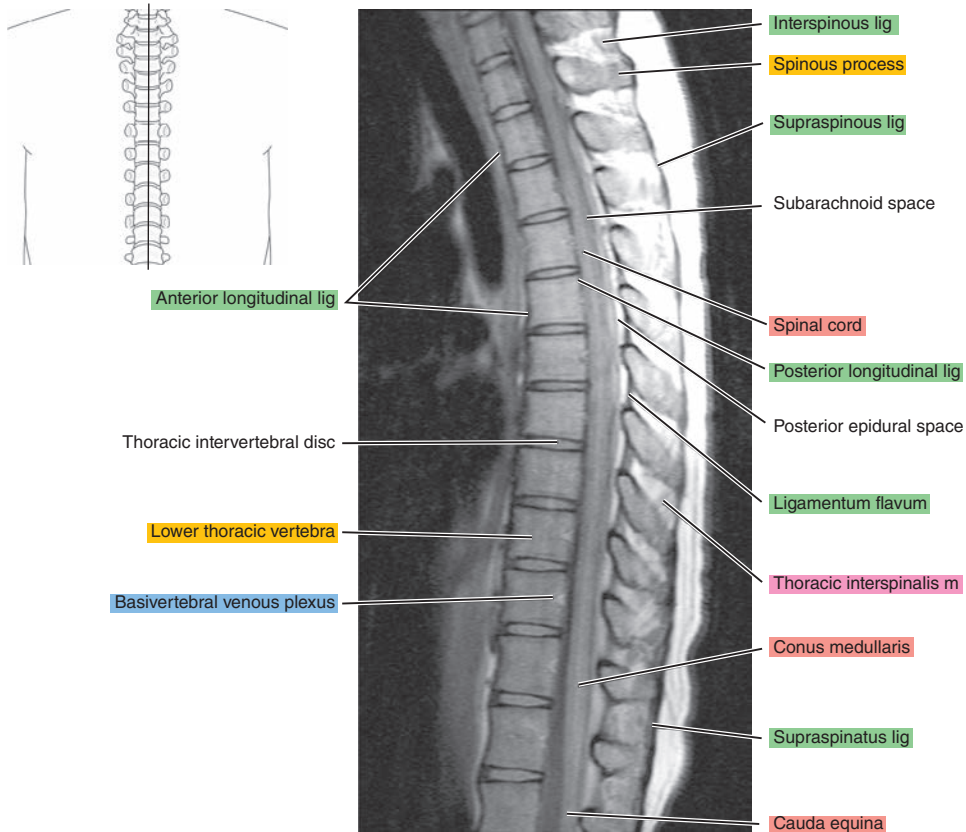


Figure 14.2.6



# CORONAL

Figure 14.3.1

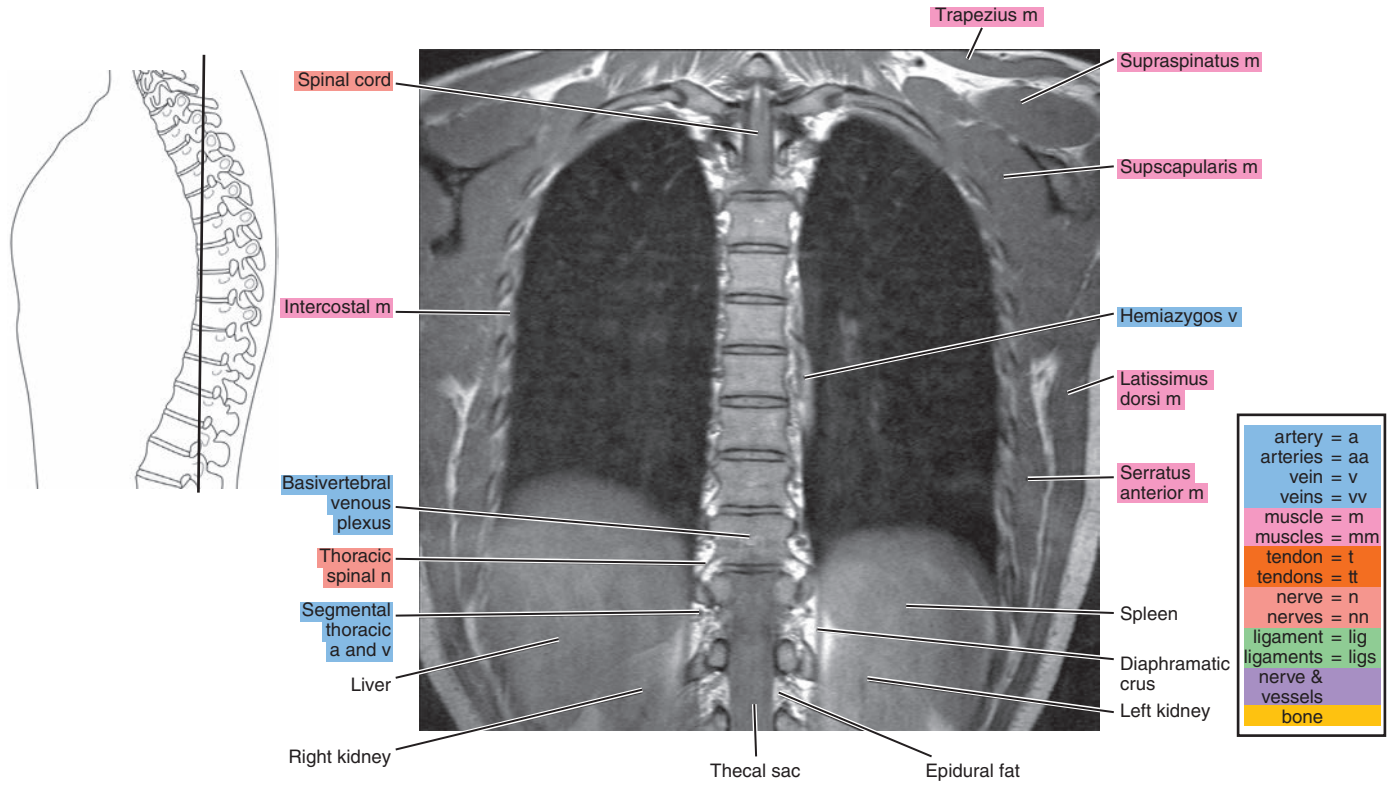


Figure 14.3.2

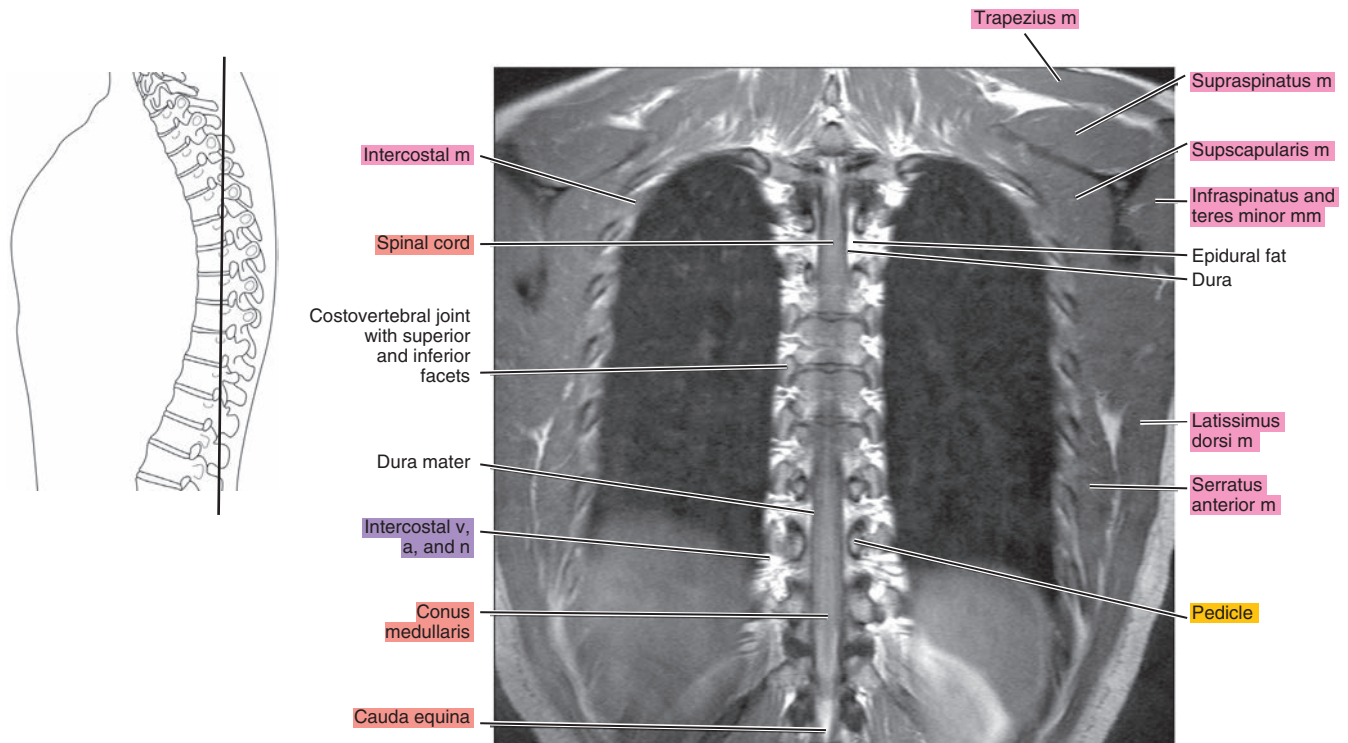


Figure 14.3.3

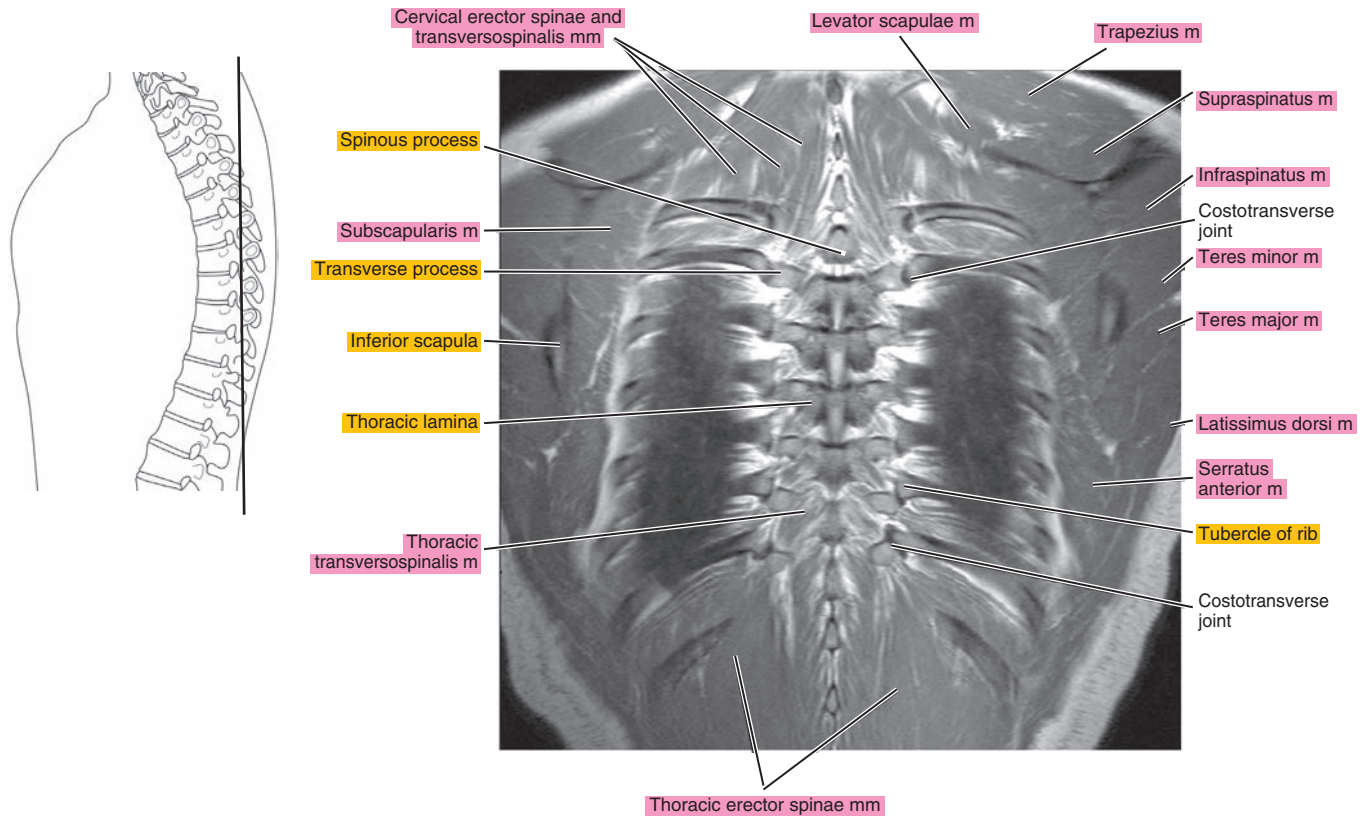


Figure 14.3.4

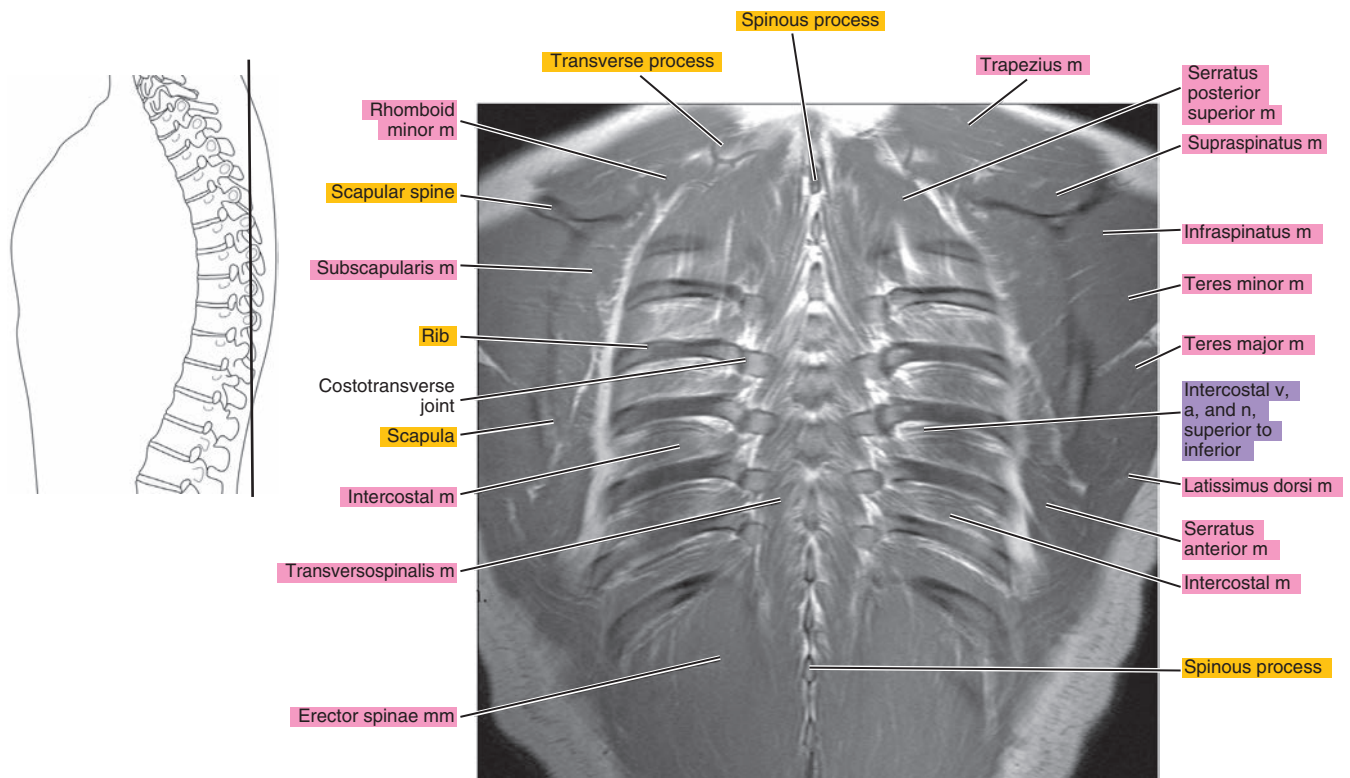




Figure 14.3.5

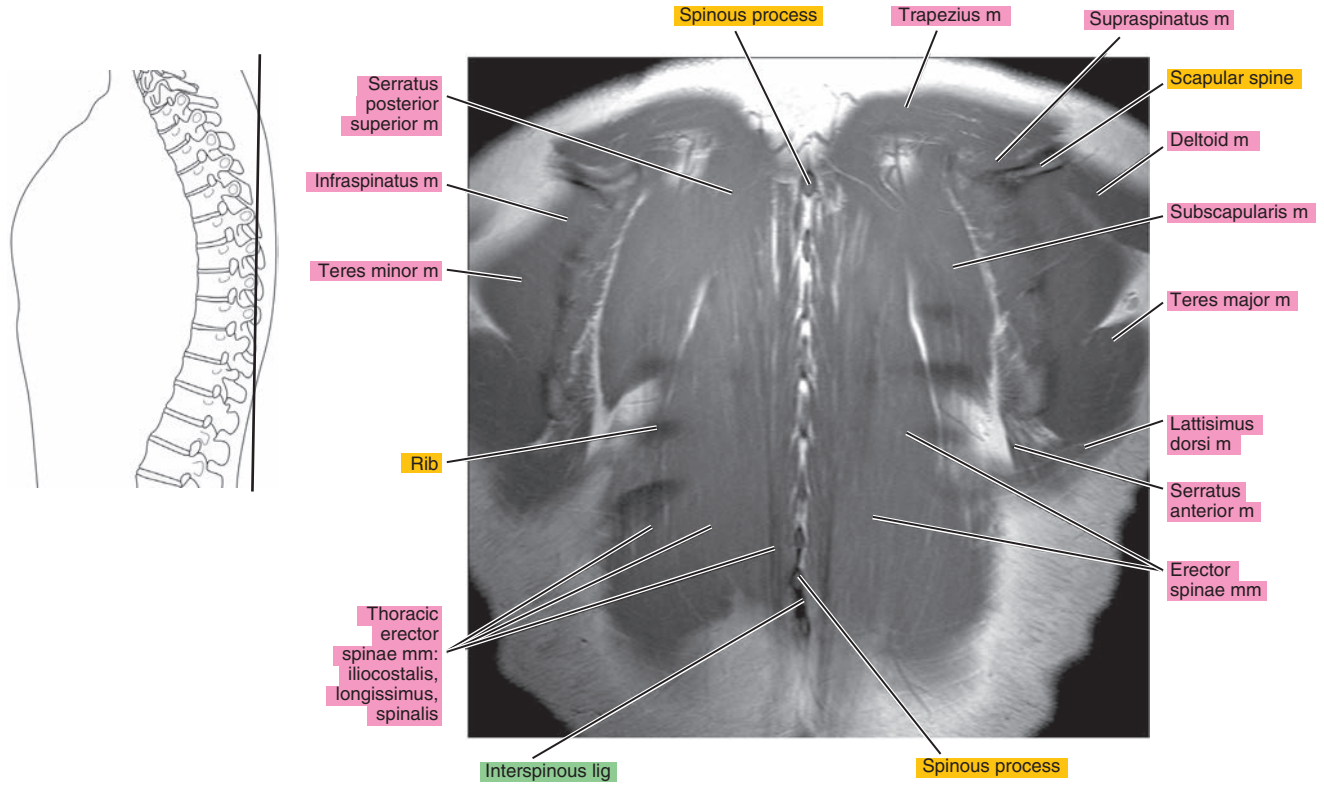


Figure 14.3.6

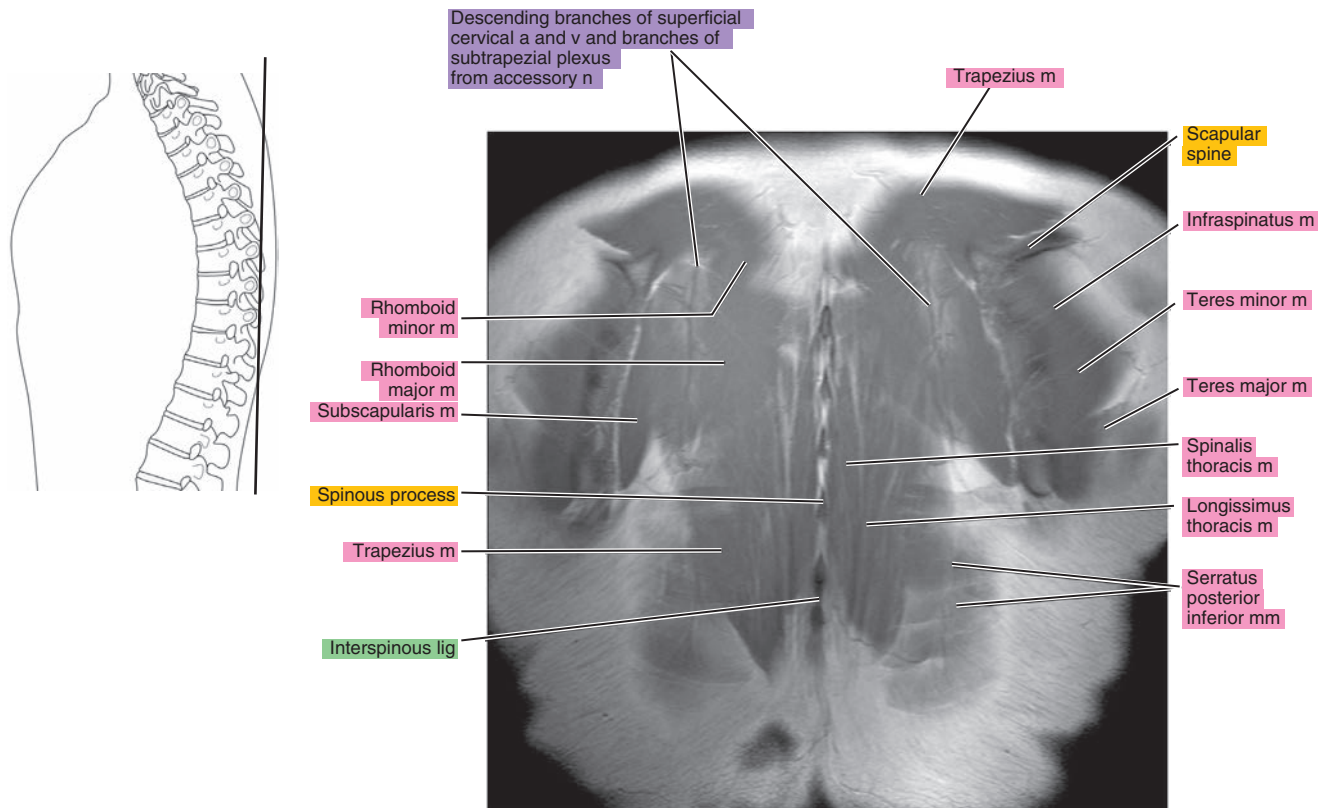
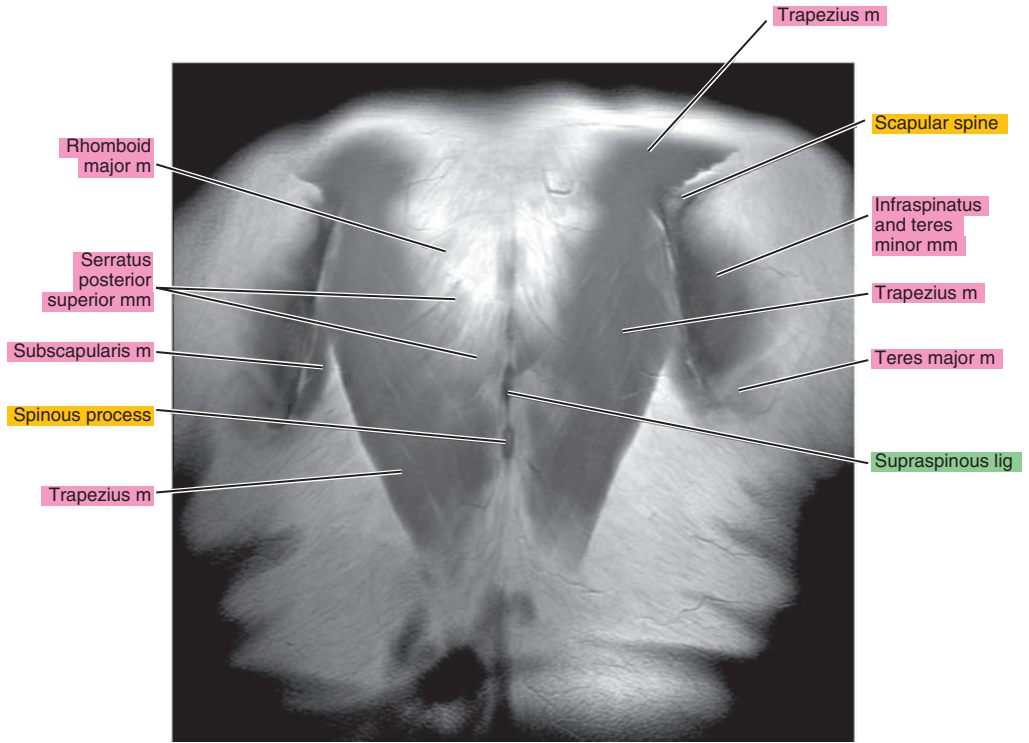
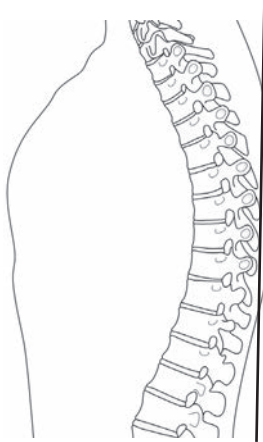




Figure 14.3.7



**Table 14-1. Muscles of the Back**

MUSCLE	ORIGIN	INSERTION	NERVE SUPPLY
<b>Trapezius</b>	Medial third of the superior nuchal line, external occipital protuberance, ligamentum nuchae, spinous processes of the seventh cervical and thoracic vertebrae, and corresponding supraspinous ligaments	Lateral third of the posterior surface of the clavicle, medial side of the acromion, and upper border of the spine of the scapula	Accessory and cervical plexus
<b>Rhomboides major</b>	Spinous processes and corresponding supraspinous ligaments of the first four thoracic vertebrae	Medial border of the scapula below the scapular spine	Dorsal scapular
<b>Rhomboides minor</b>	Spinous processes of the sixth and seventh cervical vertebrae	Medial margin of the scapula above the scapular spine	Dorsal scapular
<b>Levator scapulae</b>	Posterior tubercles of the transverse processes of the four upper cervical vertebrae	Superior angle of the scapula	Dorsal scapular
<b>Serratus posterior superior</b>	From spinous processes of the two lower cervical and two upper thoracic vertebrae	Onto the lateral side of the angles of the second to fifth ribs	First to fourth intercostal
<b>Serratus posterior inferior</b>	With latissimus dorsi, from the spinous processes of the two lower thoracic and two upper lumbar vertebrae	Onto the lower borders of the last four ribs	Ninth to 12th intercostal
<b>Serratus anterior</b>	From the center of the lateral aspect of the first eight or nine ribs	Superior and inferior angles and intervening medial margin of the scapula	Long thoracic from brachial plexus
<b>Deltoid</b>	Lateral third of the clavicle, lateral border of the acromion process, and lower border of the scapular spine	Lateral margin of the proximal half of the humeral shaft	Axillary from fifth and sixth cervical nerves through brachial plexus
<b>Latissimus dorsi</b>	Spinous processes of the lower five or six thoracic and lumbar vertebrae, median ridge of the sacrum, and outer lip of the iliac crest	With teres major, onto the medial border of the bicipital groove of the humerus	Thoracodorsal
<b>Infraspinatus</b>	Infraspinous fossa of the scapula	Middle facet of the greater tuberosity of the humerus	Suprascapular from fifth to sixth cervical
<b>Supraspinatus</b>	Supraspinous fossa of the scapula	Greater tuberosity of the humerus	Suprascapular from fifth to sixth cervical
<b>Teres major</b>	Inferior angle and lower third of the border of the scapula	Medial border of the bicipital groove of the humerus	Lower subscapular from fifth and sixth cervical
<b>Teres minor</b>	Upper two-thirds of the lateral border of the scapula	Lower facet of the greater tuberosity of the humerus	Axillary from fifth and sixth cervical
<b>Spinalis capitis</b>	Rarely a separate muscle; it arises with the semispinalis capitis from the upper thoracic spinous process	Inserts with the semispinalis capitis on the occiput	Branches of the dorsal primary divisions of the spinal nerves

**Table 14-1. Muscles of the Back**

MUSCLE	ORIGIN	INSERTION	NERVE SUPPLY
<b>Spinalis cervicis</b>	Spinous processes of the sixth and seventh cervical vertebrae	Spinous processes of the axis and the third cervical vertebra	Dorsal branches of cervical
<b>Spinalis thoracis</b>	Spinous processes of the upper lumbar and two lower thoracic vertebrae	Spinous processes of the middle and upper thoracic vertebrae	Dorsal branches of thoracic and upper lumbar
<b>Iliocostalis cervicis</b>	Angles of the upper six ribs	Transverse processes of the middle cervical vertebrae	Dorsal branches of upper thoracic
<b>Iliocostalis thoracis</b>	Medial side of the angles of the lower six ribs	Angles of the upper six ribs	Dorsal branches of thoracic
<b>Iliocostalis lumborum</b>	With erector spinae, from the sacrum, ilium, and spines of the lumbar vertebrae	Angles of the lower six ribs	Dorsal branches of thoracic and lumbar nerves
<b>Longissimus capitis</b>	From the transverse processes of the upper thoracic and transverse and articular processes of the lower and middle cervical vertebrae	Onto the mastoid process	Dorsal branches of cervical
<b>Longissimus cervicis</b>	Transverse processes of the upper thoracic vertebrae	Transverse processes of the middle and upper cervical vertebrae	Dorsal branches of lower cervical and upper thoracic
<b>Longissimus thoracis</b>	With the iliocostalis and from the transverse processes of the lower thoracic vertebrae	By lateral slips onto most or all of the ribs between the angles and the tubercles and onto the tips of the transverse processes of the upper lumbar vertebrae, and by medial slips into the accessory processes of the upper lumbar and transverse processes of the thoracic vertebrae	Dorsal branches of thoracic and lumbar
<b>Splenius capitis</b>	From the ligamentum nuchae of the last four cervical vertebrae and the supraspinous ligament of first and second thoracic vertebrae	Lateral half of the superior nuchal line and mastoid process	Dorsal branches of second to sixth cervical
<b>Splenius cervicis</b>	From the supraspinous ligament and the spinous processes of the third to fifth thoracic vertebrae	Posterior tubercles of the transverse processes of the first and second (sometimes third) cervical vertebrae	Dorsal branches of fourth to eighth cervical
<b>Semispinalis capitis</b>	Transverse processes of the five or six upper thoracic and articular processes of the four lower cervical vertebrae	Occipital bone between the superior and inferior nuchal lines	Dorsal branches of cervical
<b>Semispinalis cervicis</b>	Transverse processes of the second to fifth thoracic vertebrae	Spinous processes of the axis and the third to fifth cervical vertebrae	Dorsal branches of cervical and thoracic
<b>Semispinalis thoracis</b>	Transverse processes of the fifth to 11th thoracic vertebrae	Spinous processes of the first four thoracic and fifth and seventh cervical vertebrae	Dorsal branches of cervical and thoracic

*continued*

**Table 14-1. Muscles of the Back—cont'd**

MUSCLE	ORIGIN	INSERTION	NERVE SUPPLY
<b>Multifidus</b>	From the sacrum, the sacroiliac ligament, mammillary processes of the lumbar vertebrae, transverse processes of the thoracic vertebrae, and articular processes of the last four cervical vertebrae	Onto the spinous processes of all the vertebrae, up to and including the axis	Dorsal branches of spinal
<b>Rotatores</b>	Primarily developed in the thoracic region from the transverse processes of the vertebrae	Into the root of the spinous processes of the next two or three vertebrae above	Dorsal branches of spinal
<b>Interspinales cervicis</b>	Tubercle of the spinous process of the cervical vertebrae	Tubercle of the spinous process of the next superior vertebra	Dorsal branches of cervical
<b>Interspinales thoracis</b>	Often poorly developed or absent between the spinous processes of the thoracic vertebrae	Spinous processes of thoracic vertebrae	Dorsal branches of thoracic
<b>Interspinales lumborum</b>	Superior margin of the lumbar spinous processes	Inferior margin of the next superior spinous process	Dorsal branches of lumbar
<b>Intertransversarii anteriores cervicis</b>	Anterior tubercle of the cervical transverse process	Anterior tubercle of the next superior transverse process	Ventral branch of cervical
<b>Intertransversarii laterales lumborum</b>	Transverse processes of the lumbar vertebrae	Next superior transverse process	Ventral branches of lumbar
<b>Intertransversarii thoracis</b>	Transverse processes of the thoracic vertebrae	Next superior transverse process	Dorsal branches of thoracic



*Chapter*  
**15**

**MRI of the Lumbar Spine**

# AXIAL

Figure 15.1.1

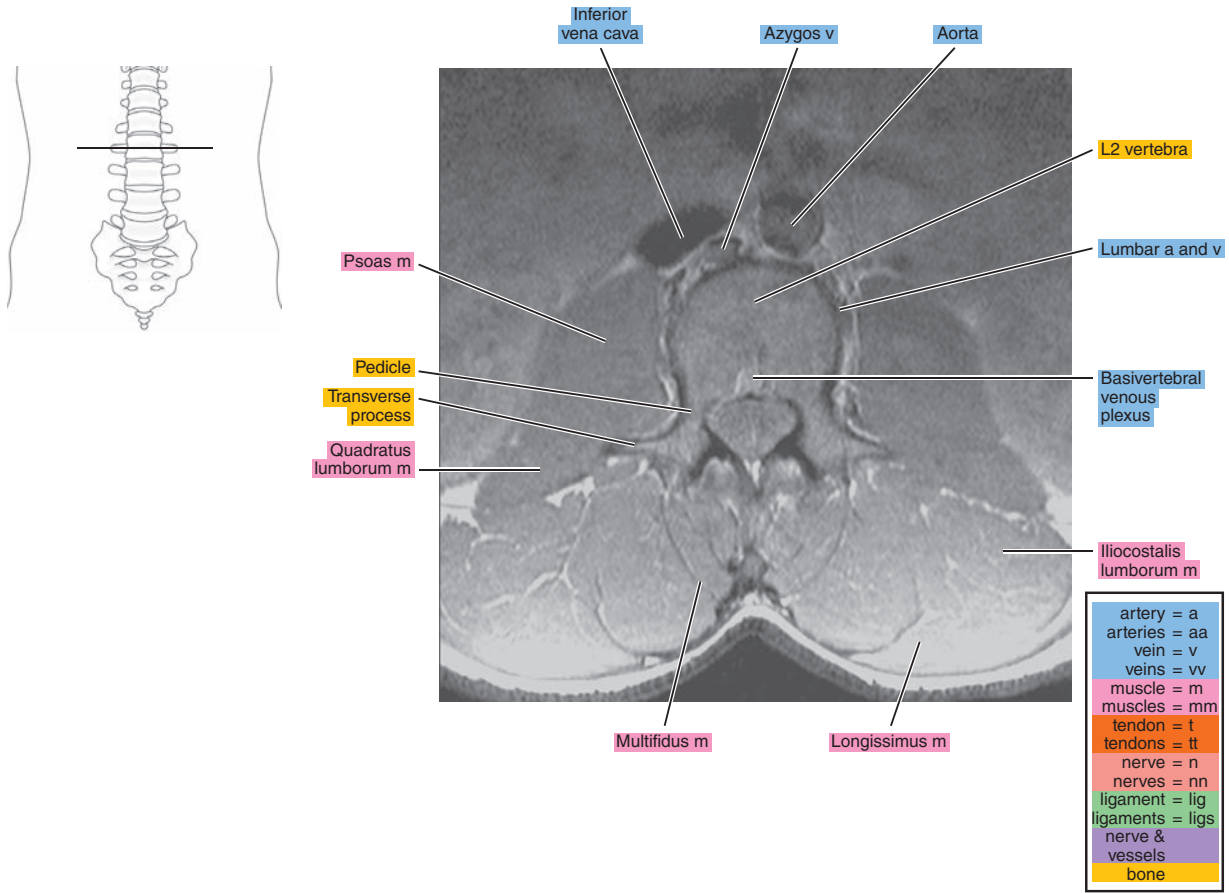


Figure 15.1.2

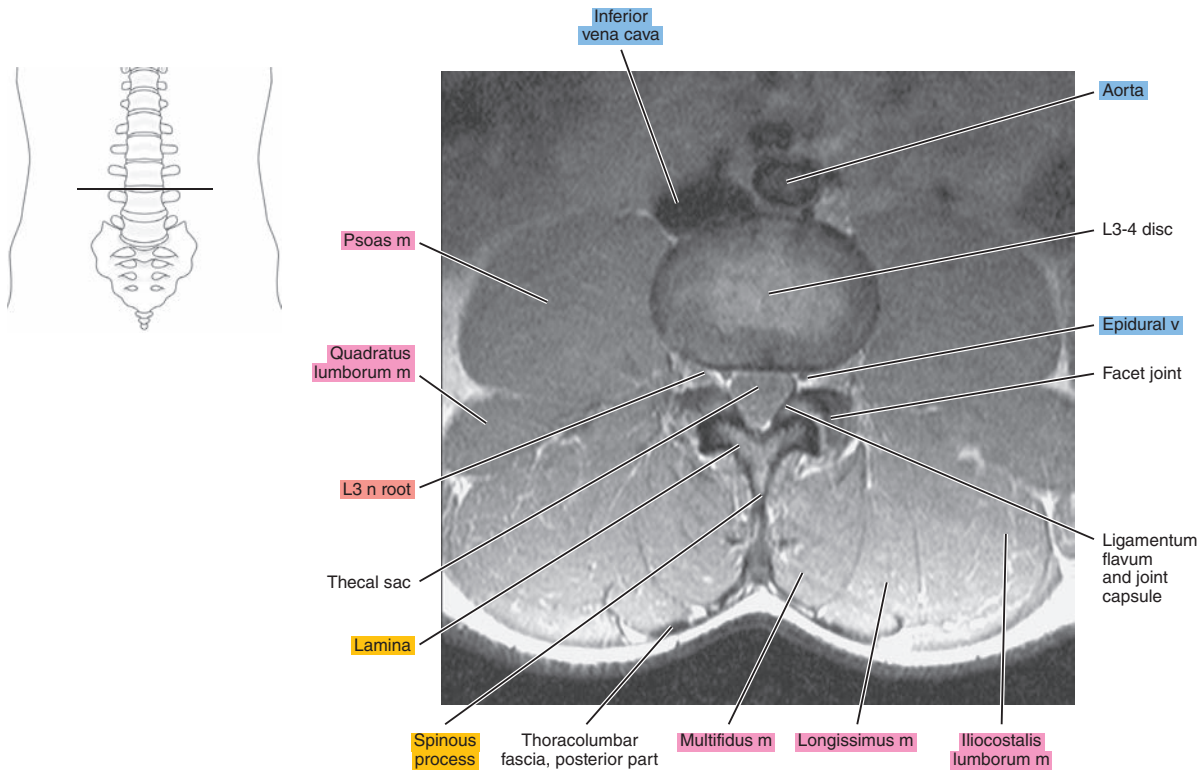


Figure 15.1.3

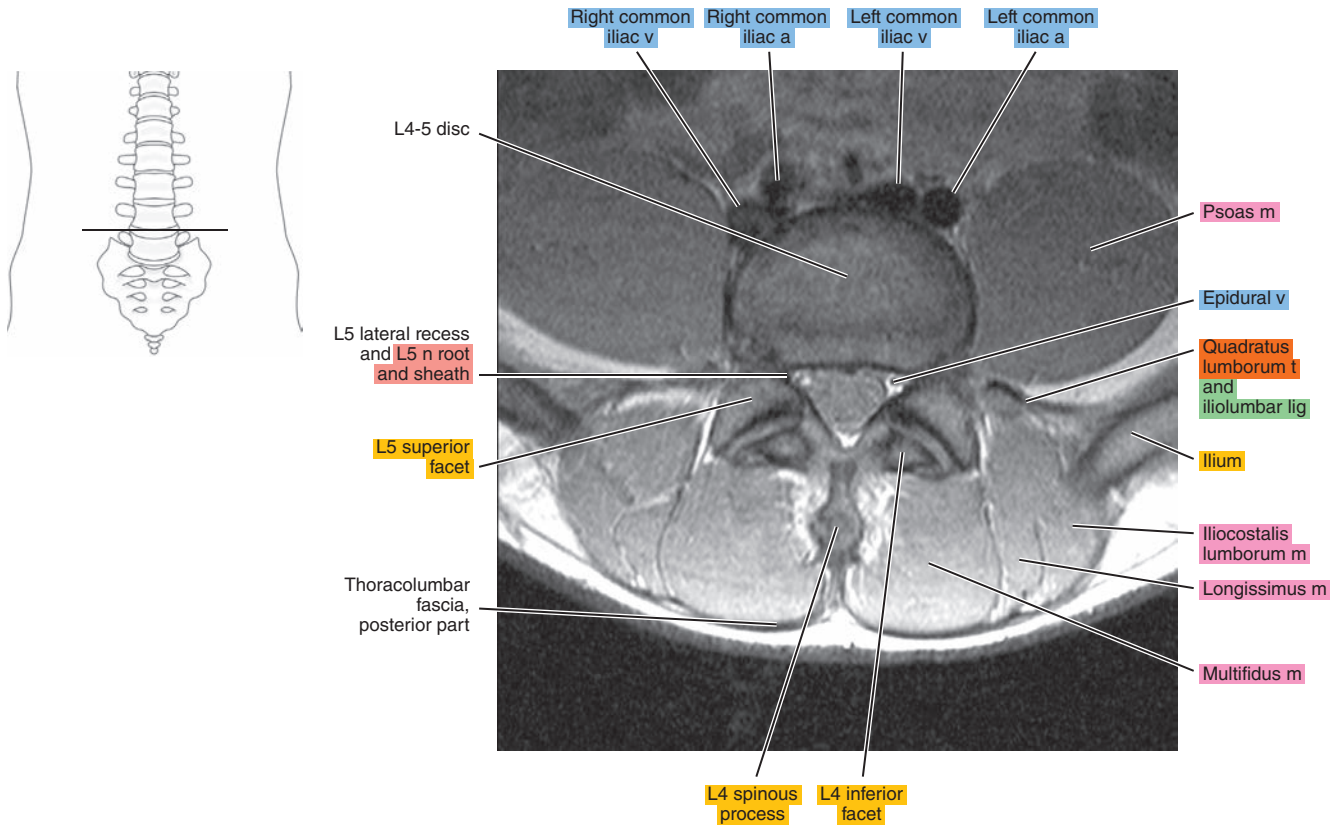


Figure 15.1.4

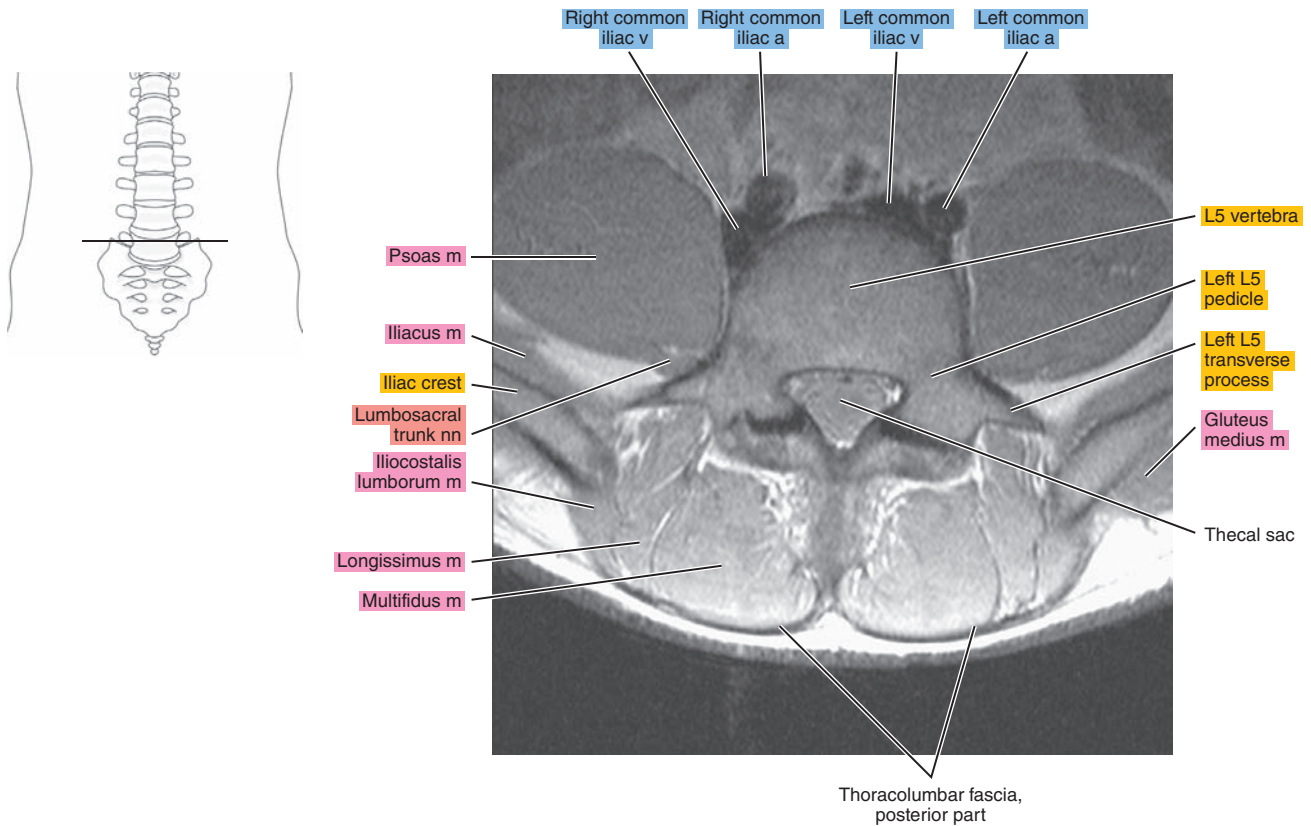


Figure 15.1.5

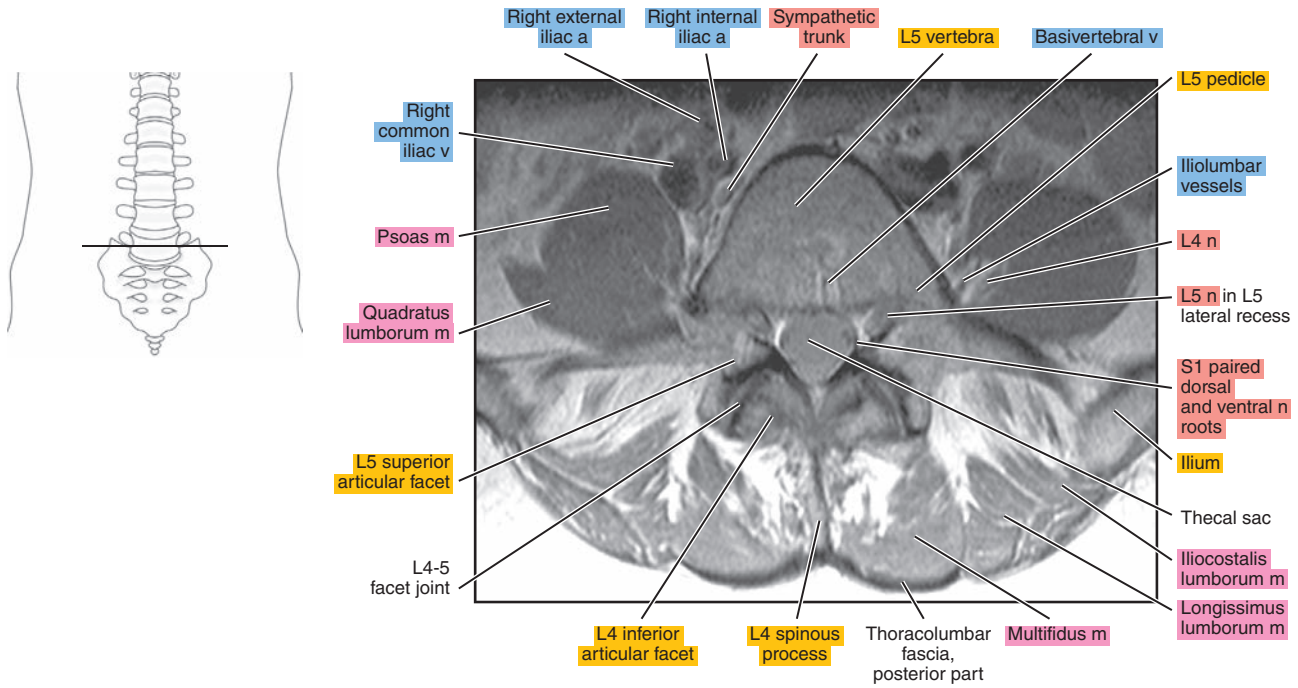


Figure 15.1.6

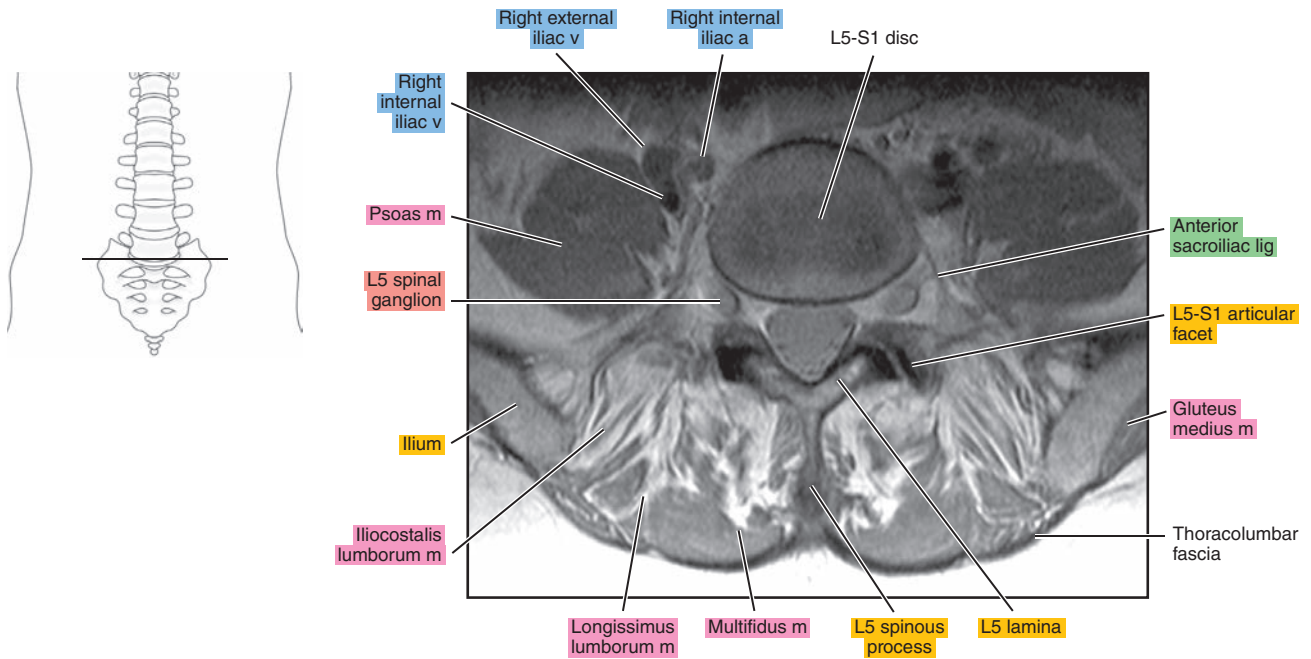




Figure 15.1.7

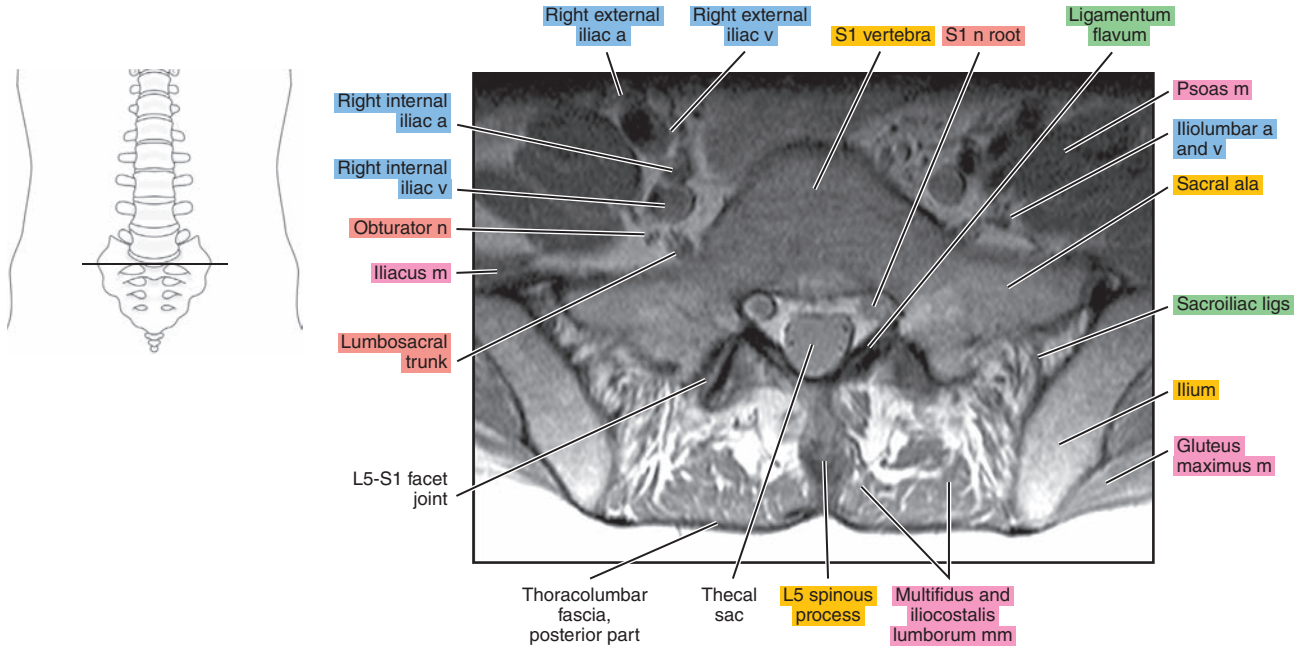
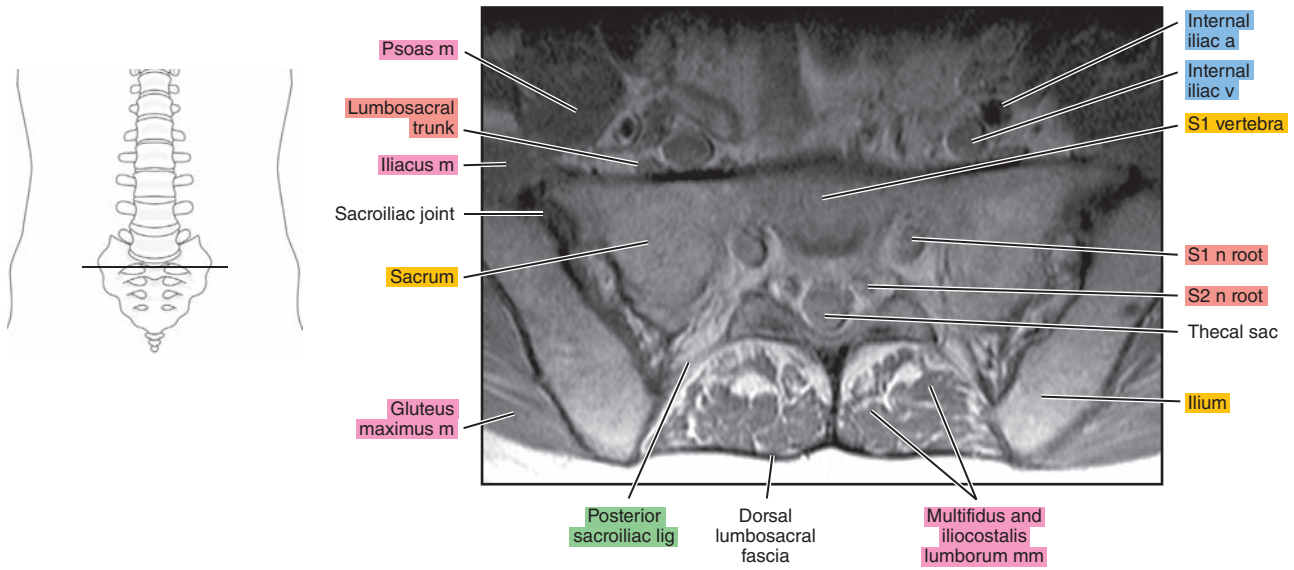


Figure 15.1.8



# SAGITTAL

Figure 15.2.1

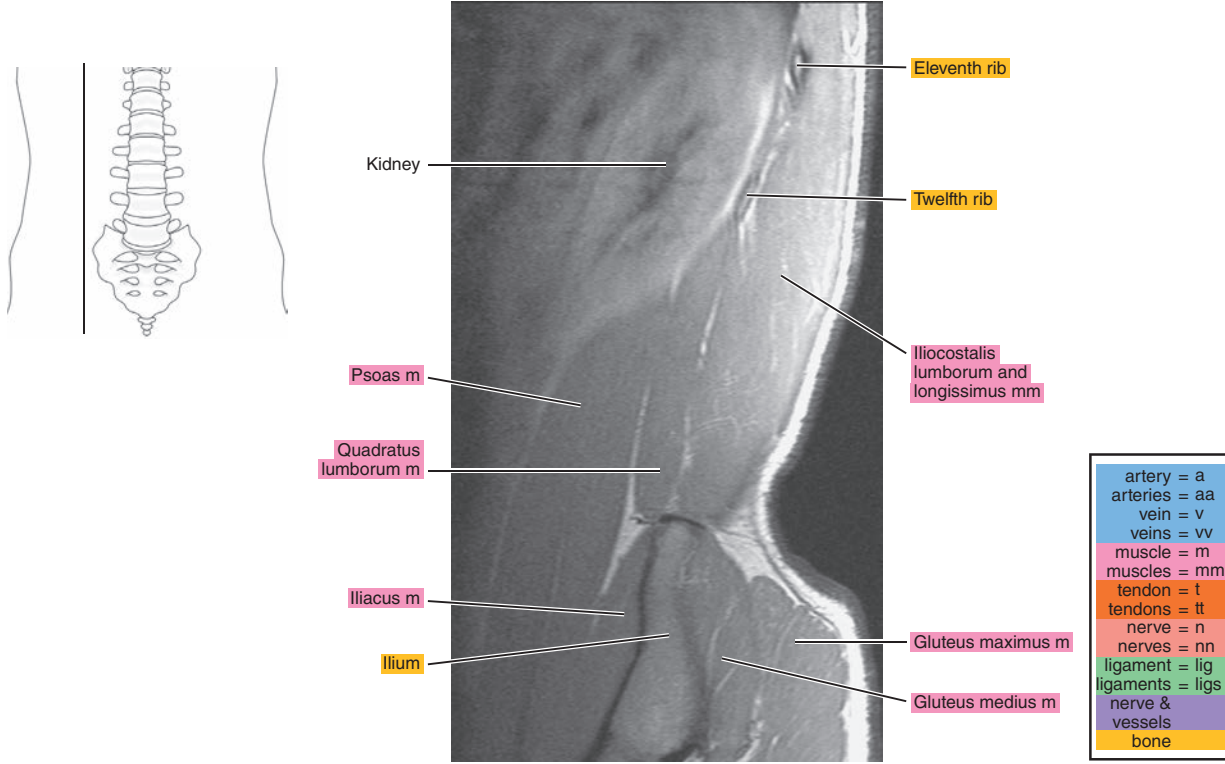


Figure 15.2.2

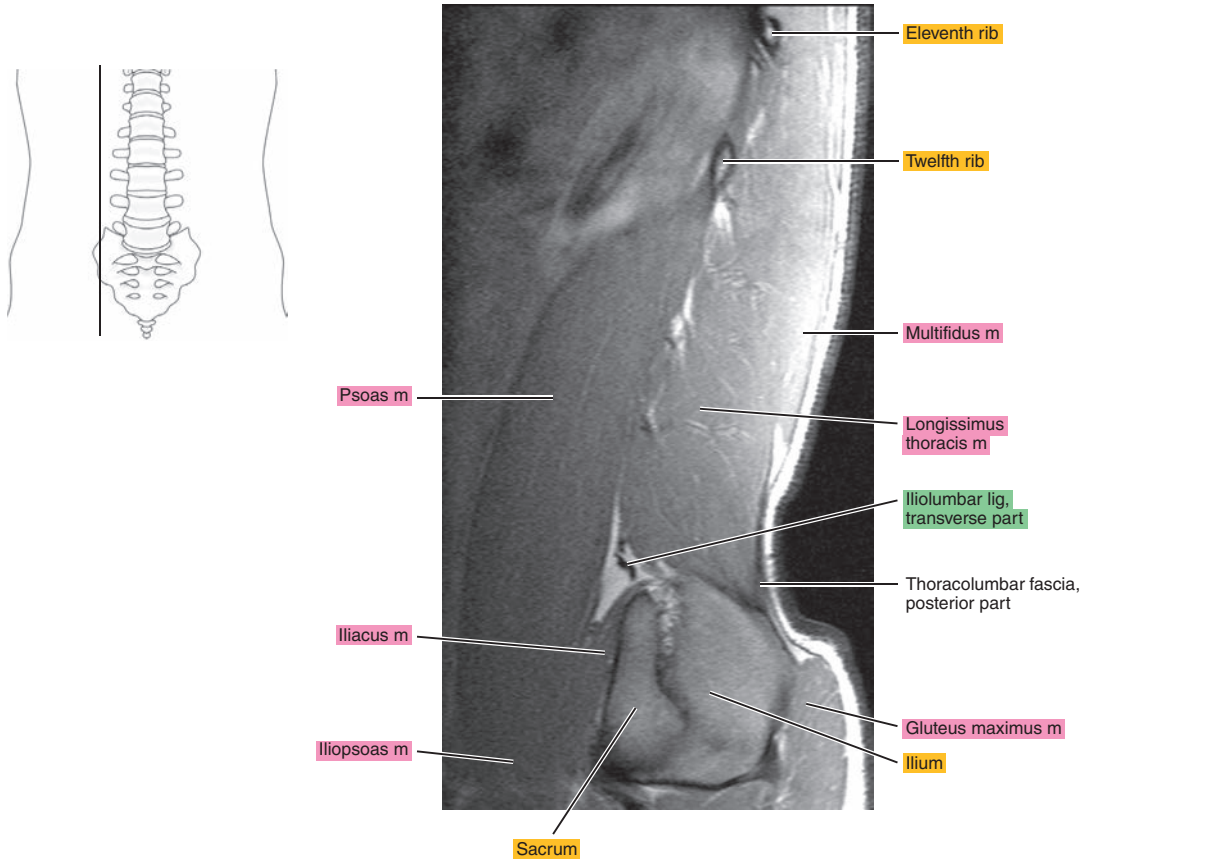


Figure 15.2.3

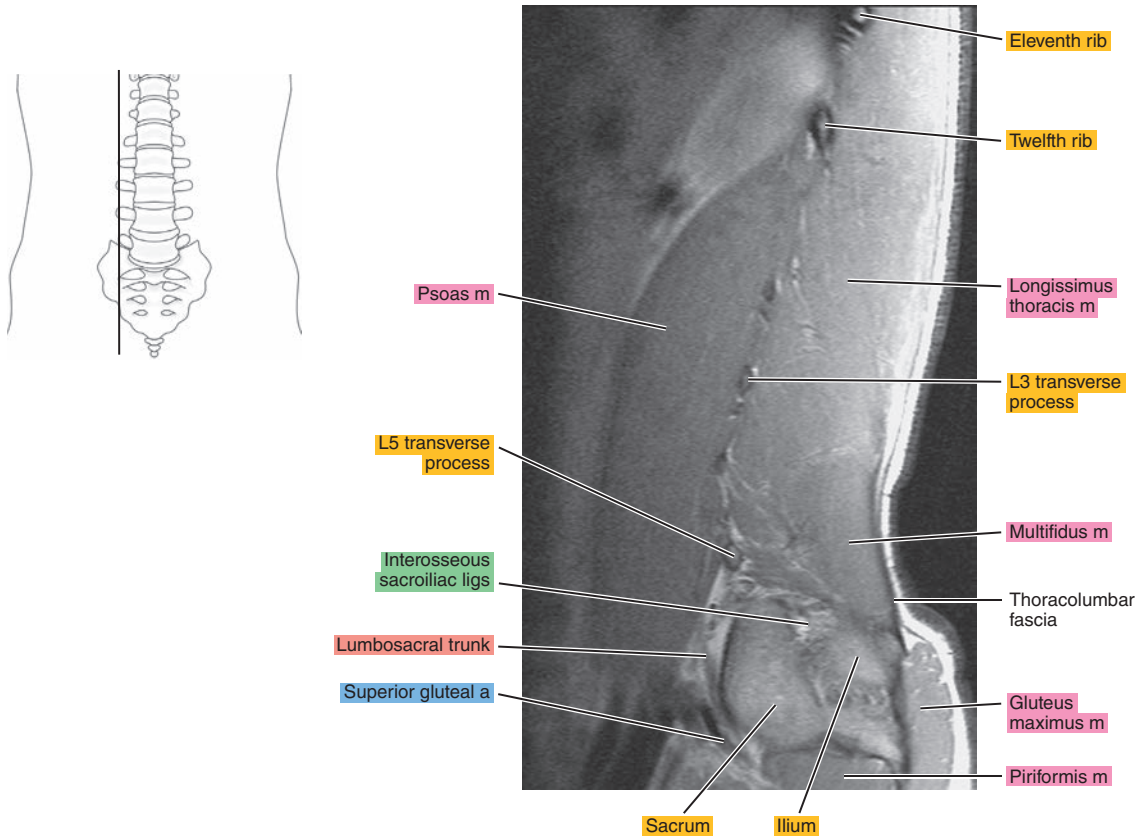


Figure 15.2.4

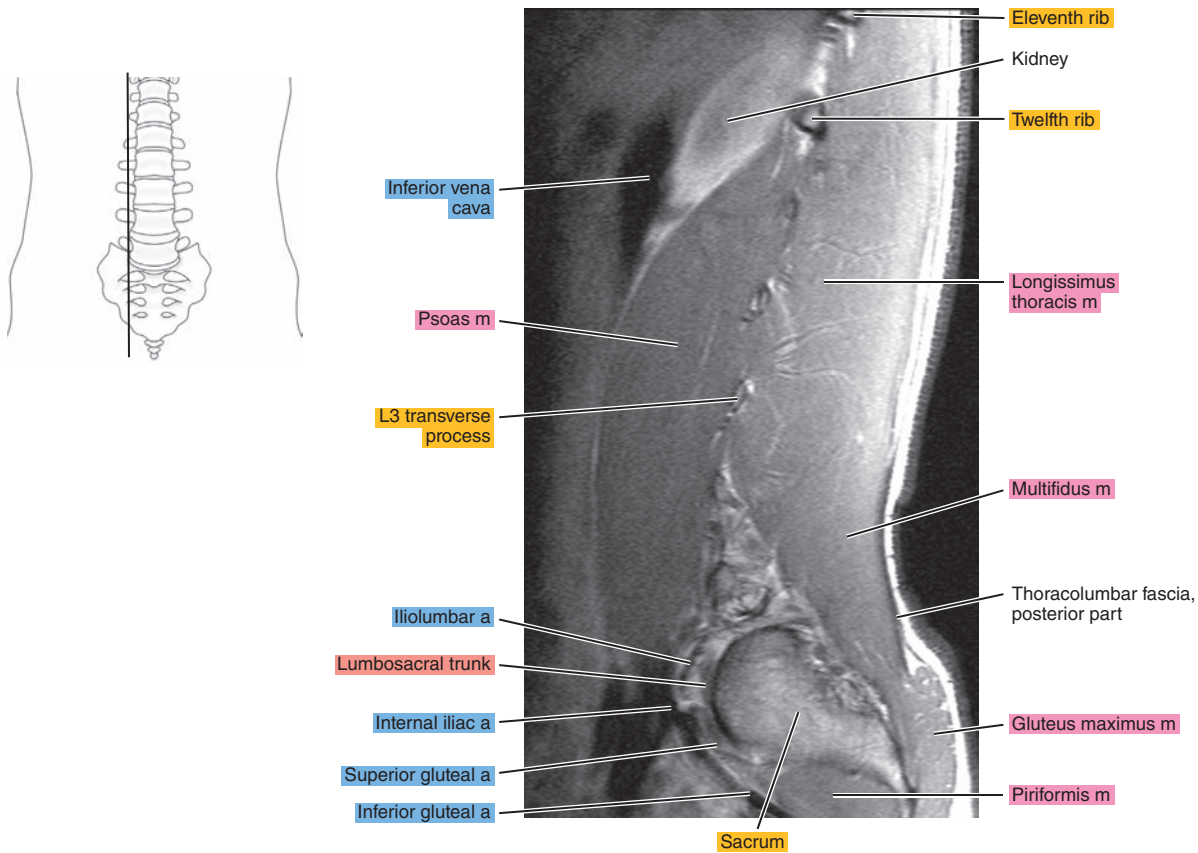


Figure 15.2.5

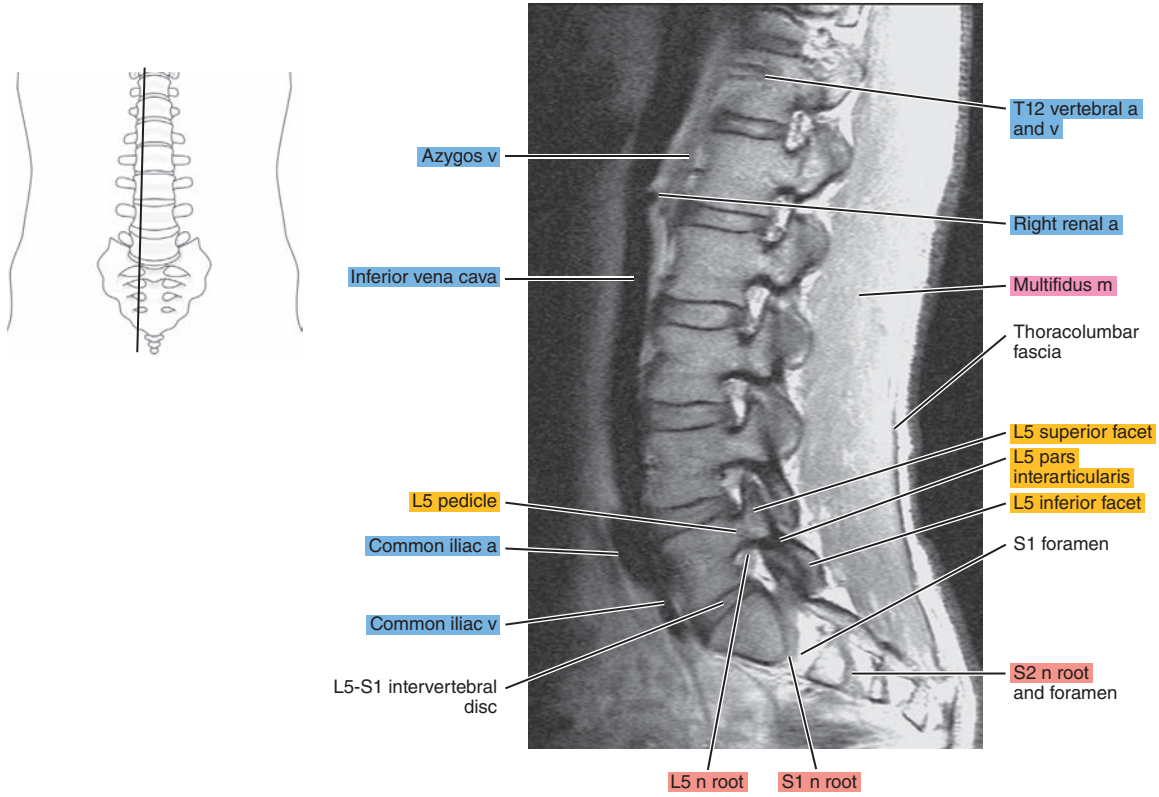
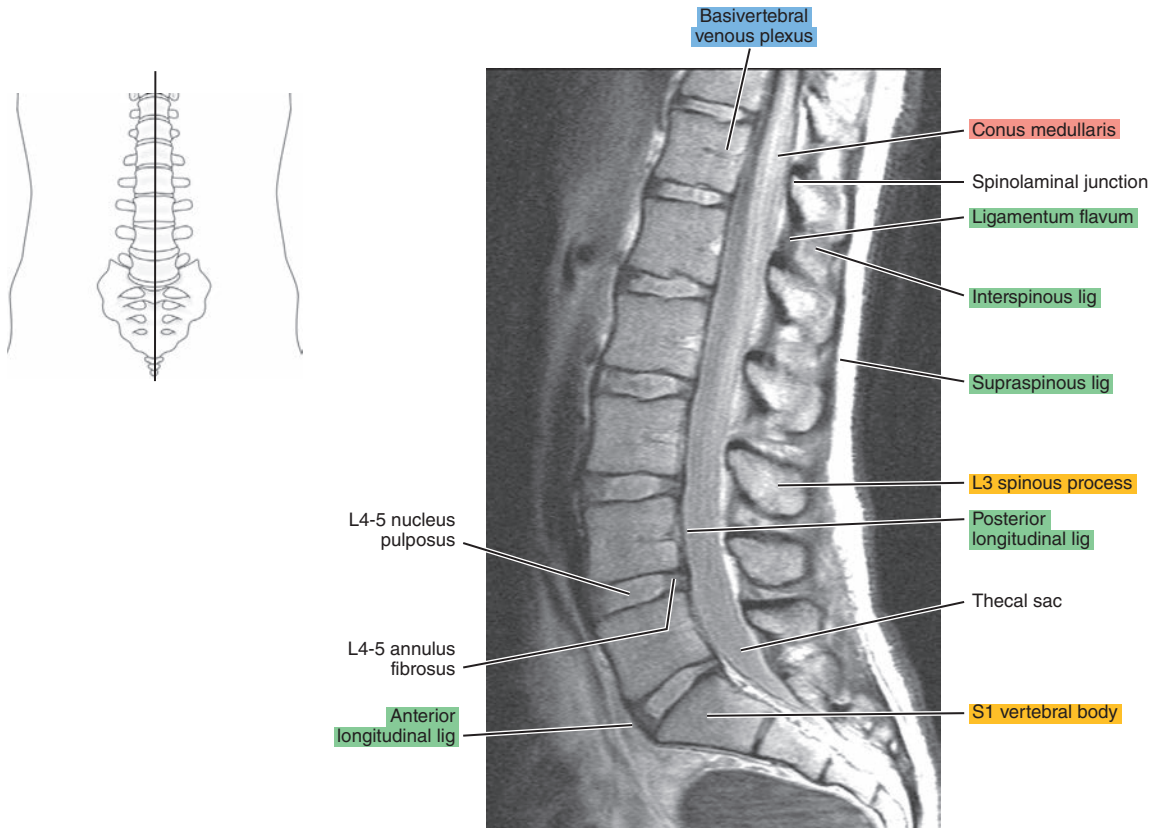


Figure 15.2.6





# CORONAL

Figure 15.3.1

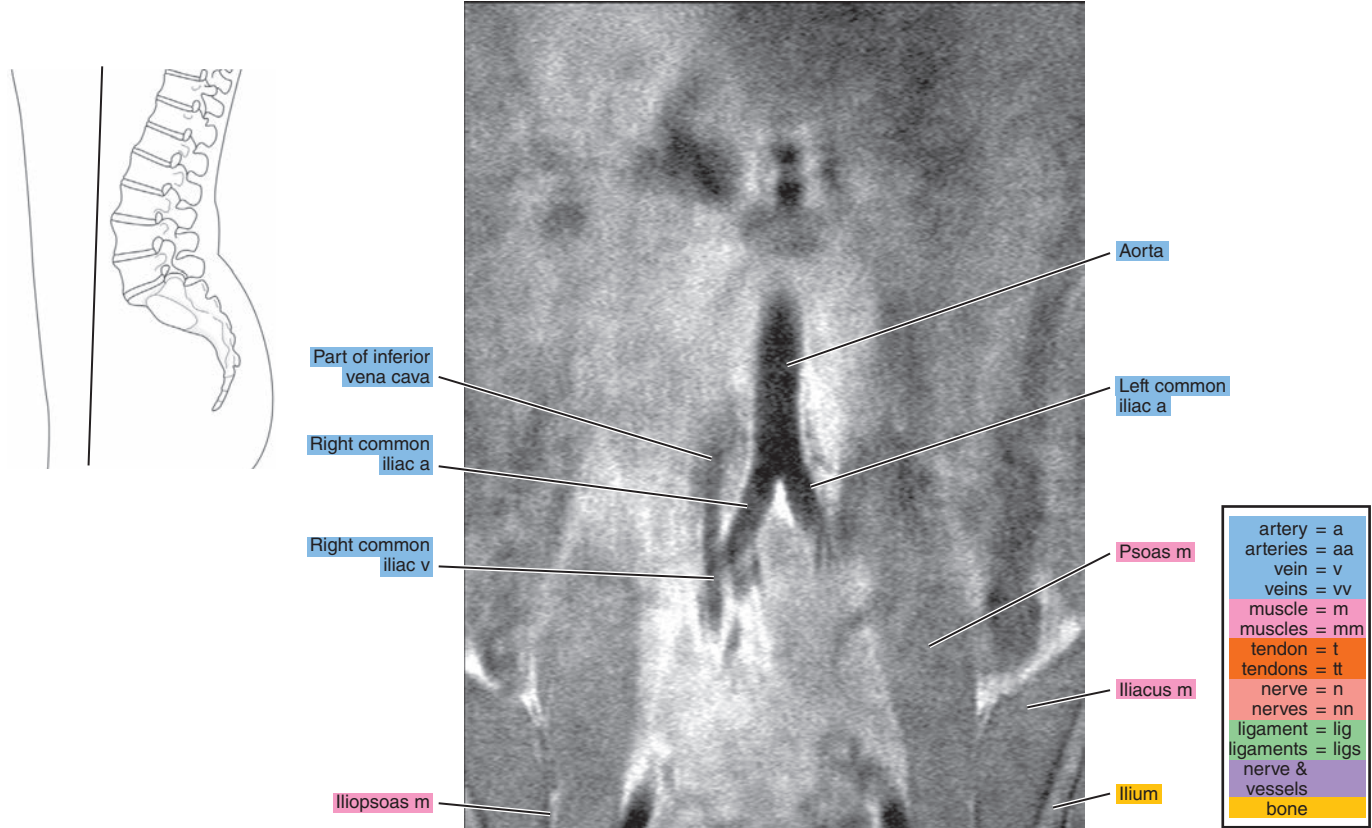


Figure 15.3.2

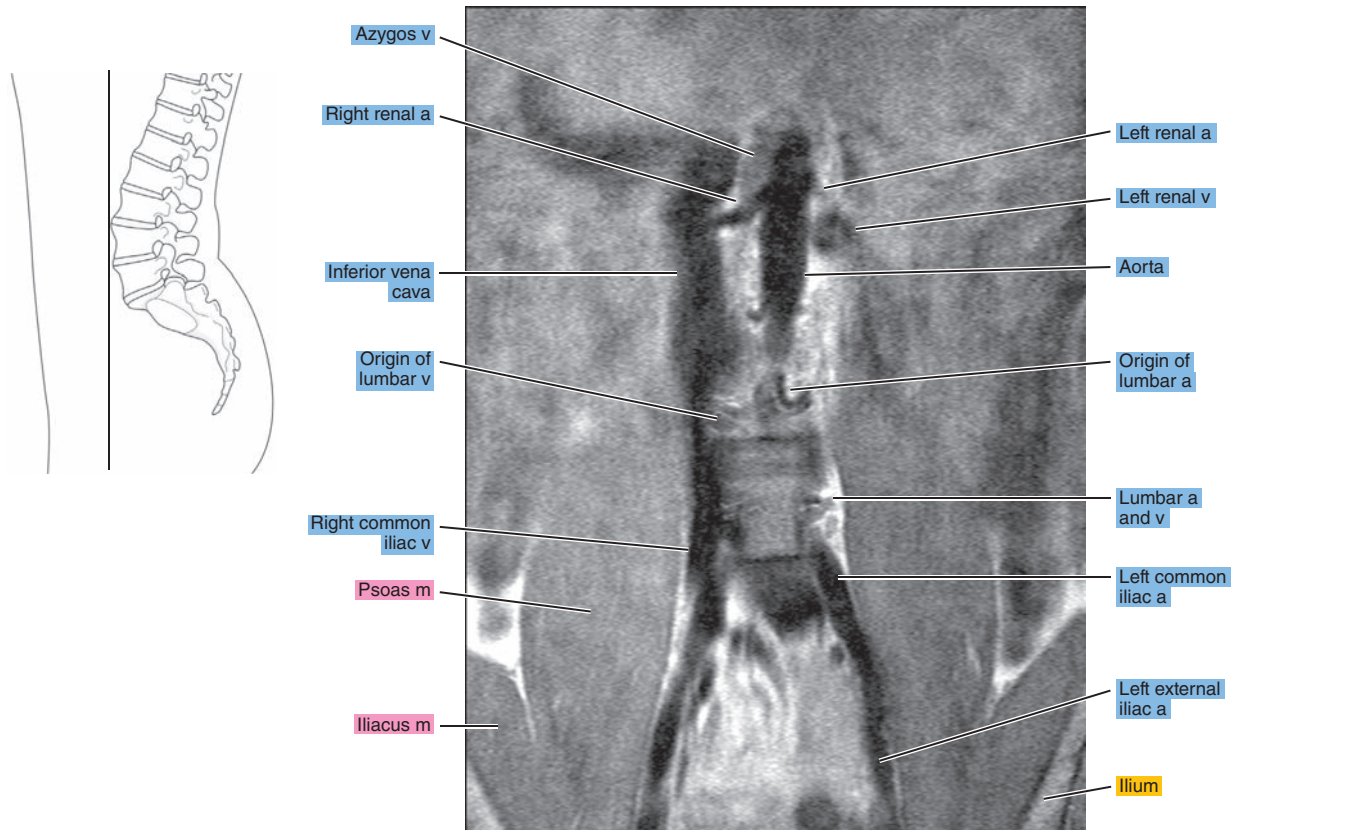


Figure 15.3.3

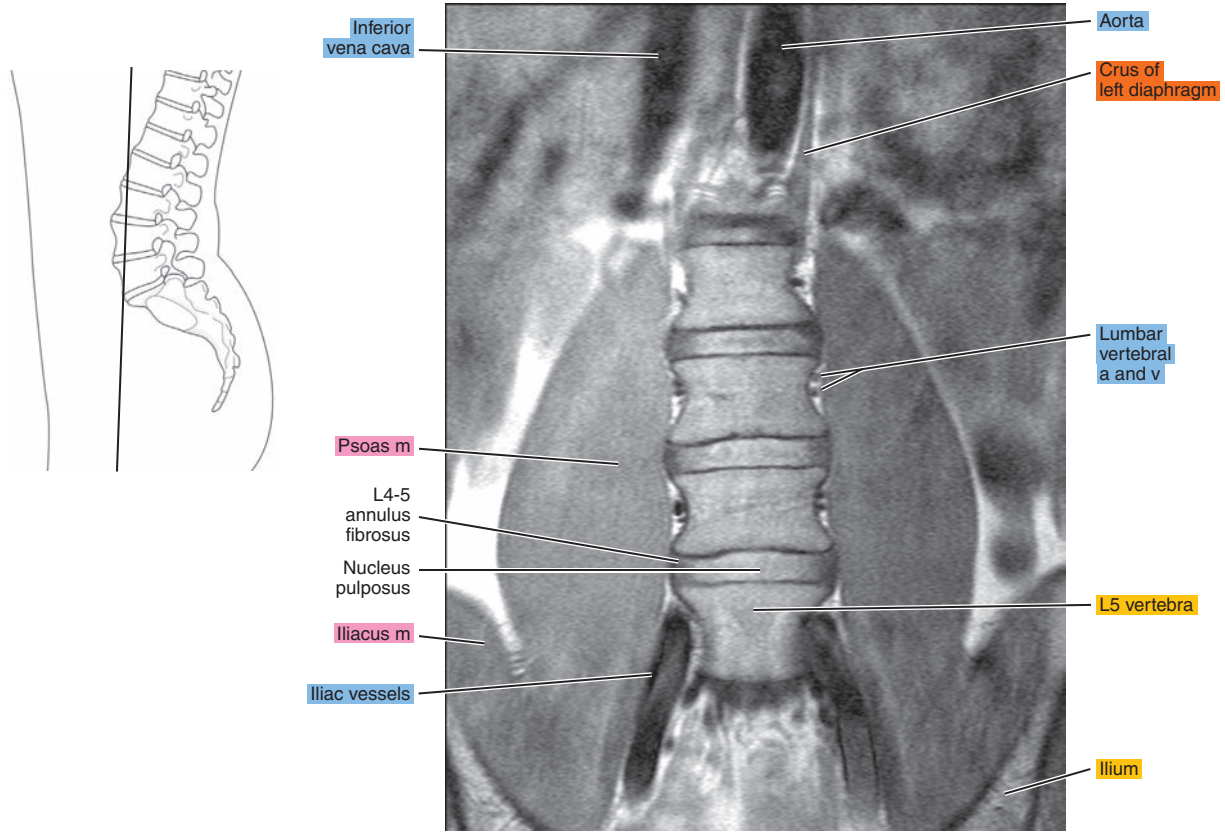


Figure 15.3.4

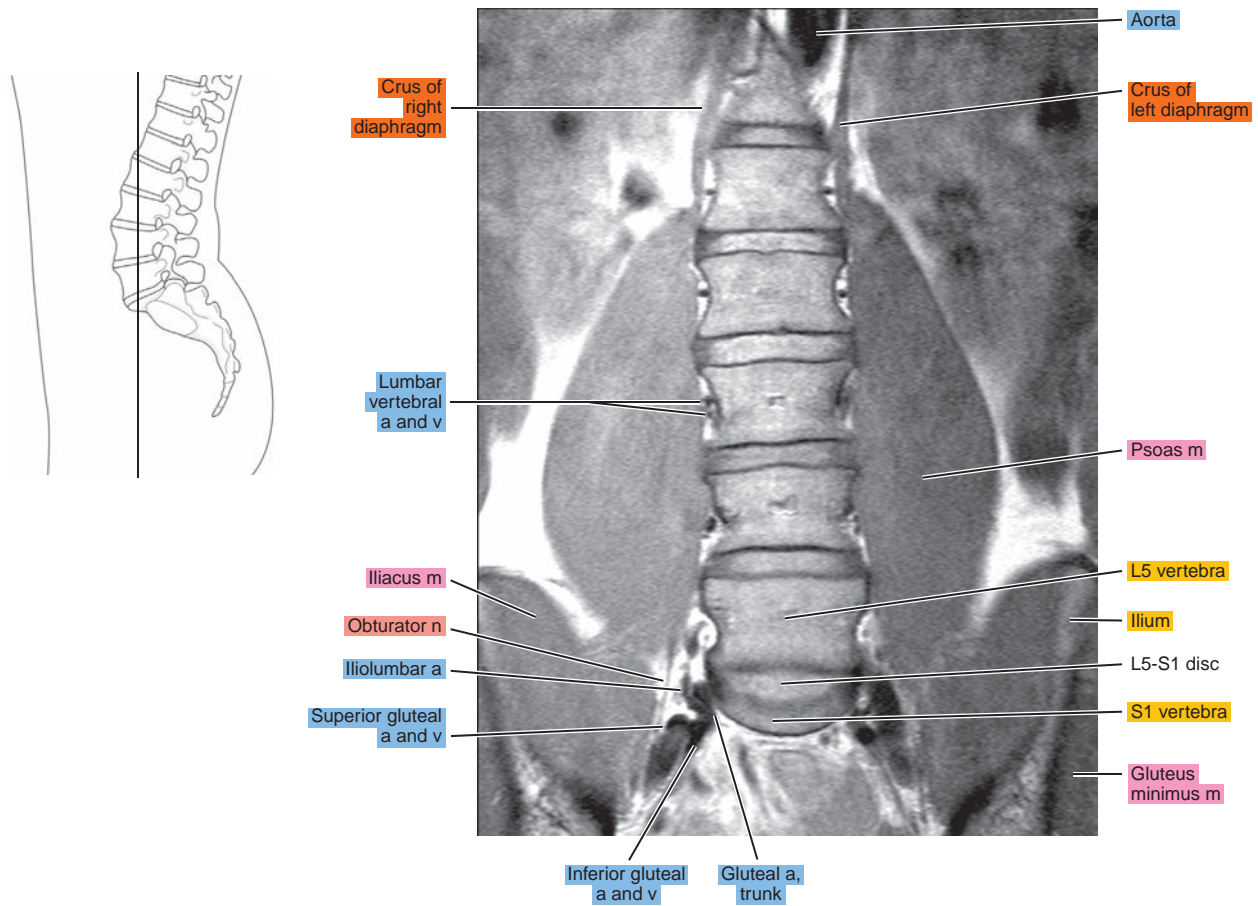




Figure 15.3.5

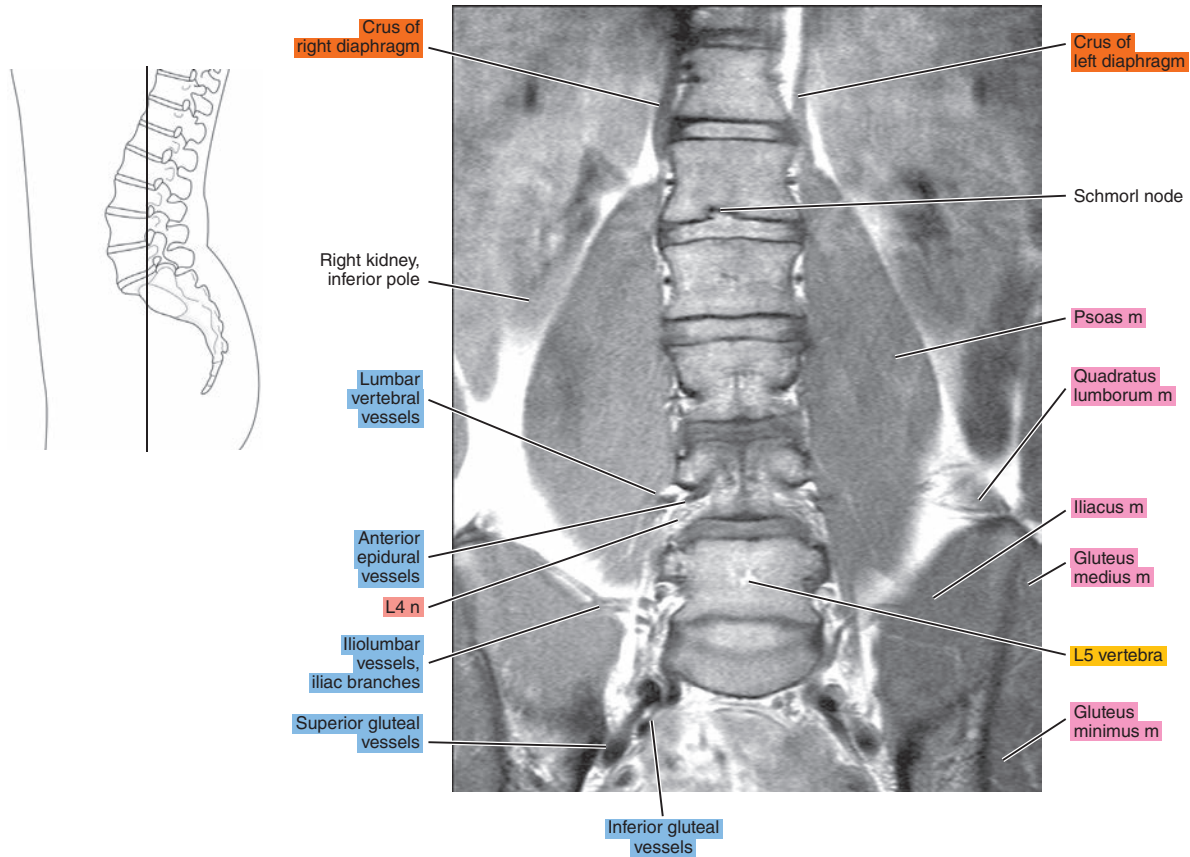


Figure 15.3.6

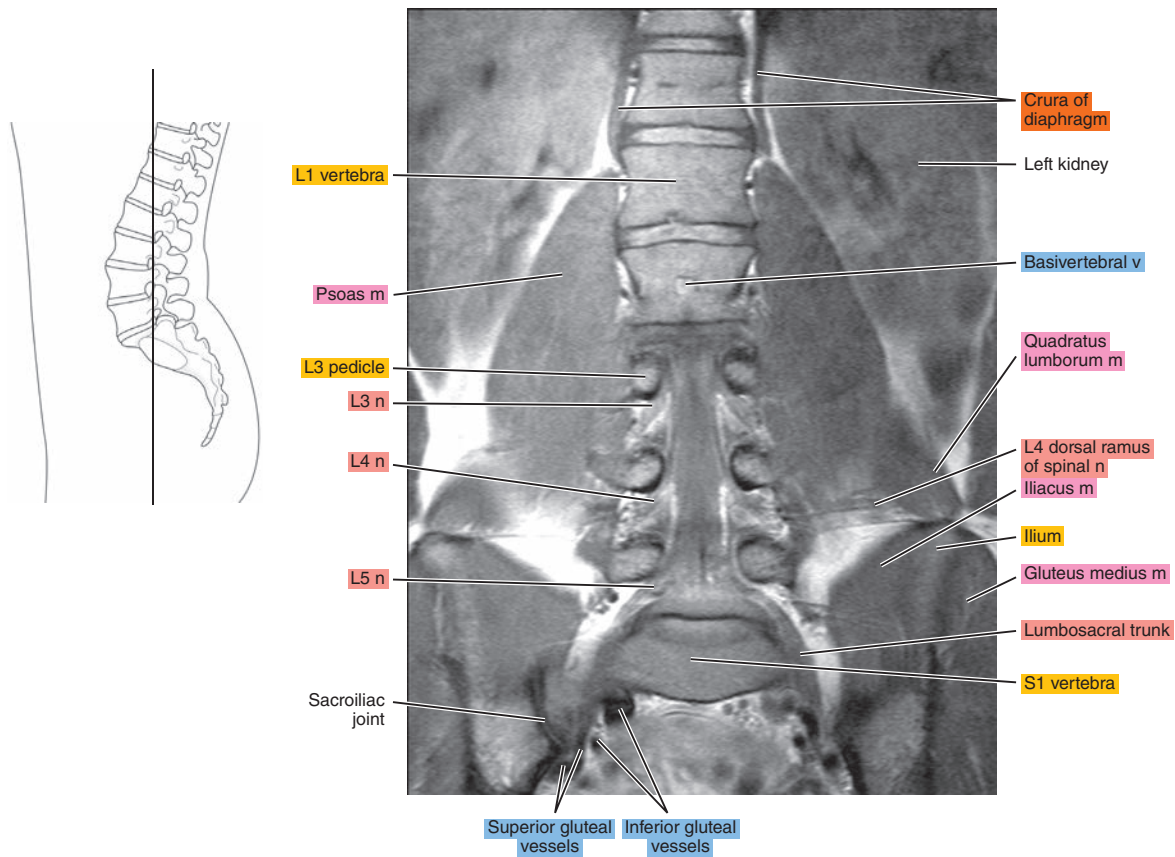


Figure 15.3.7

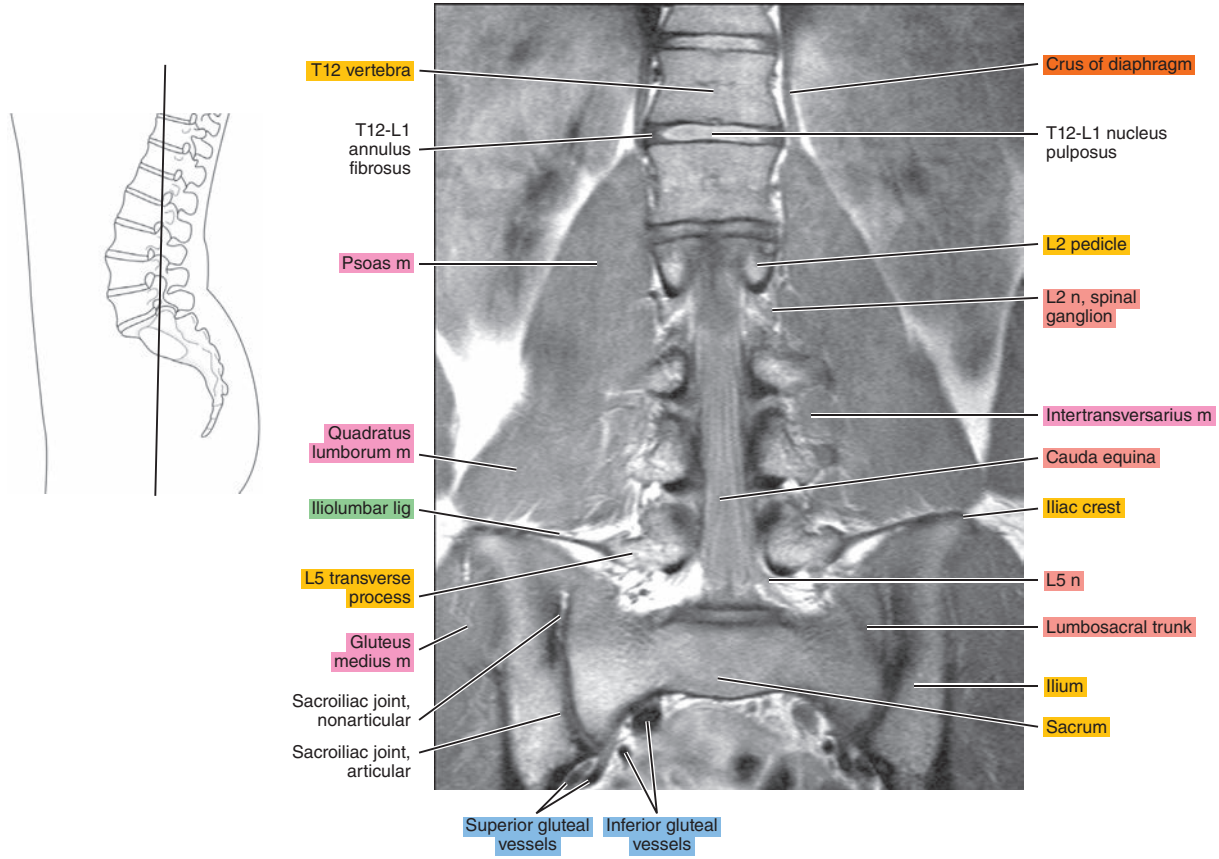


Figure 15.3.8

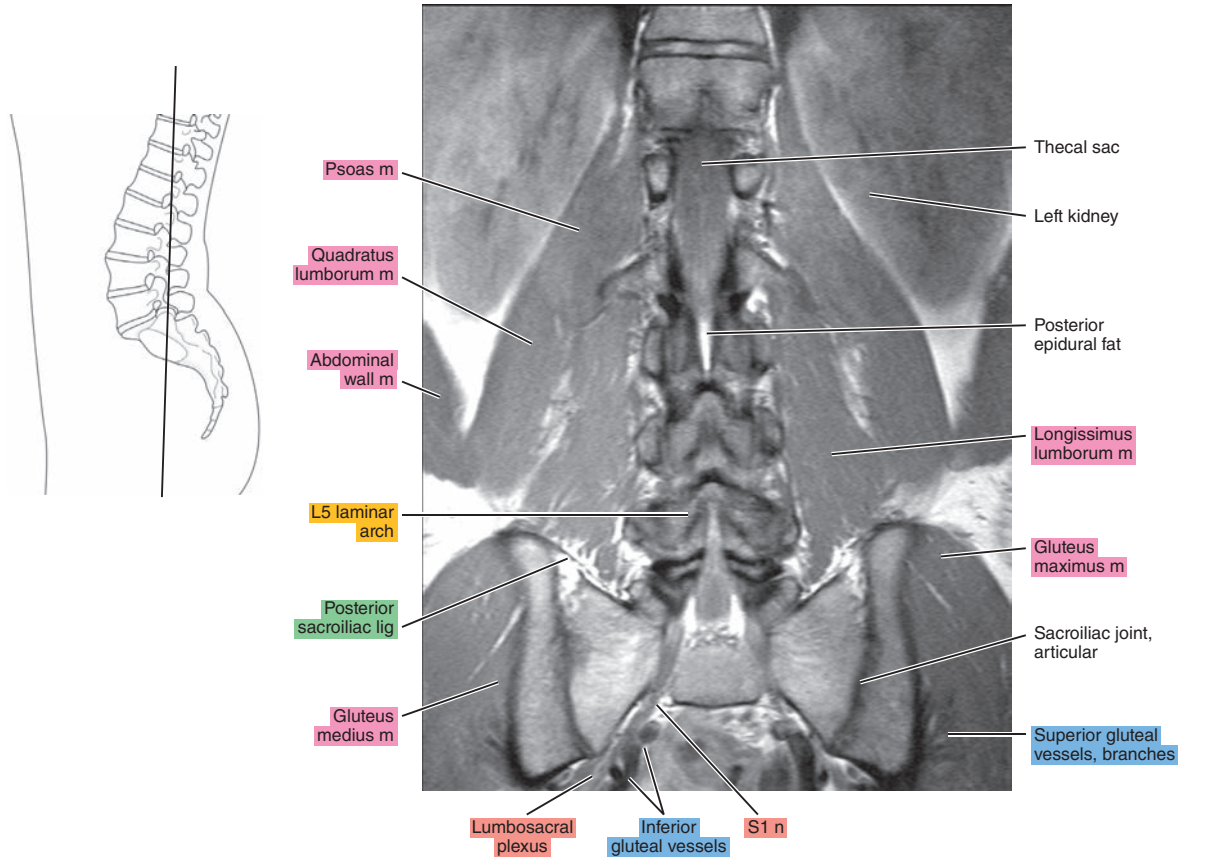




Figure 15.3.9

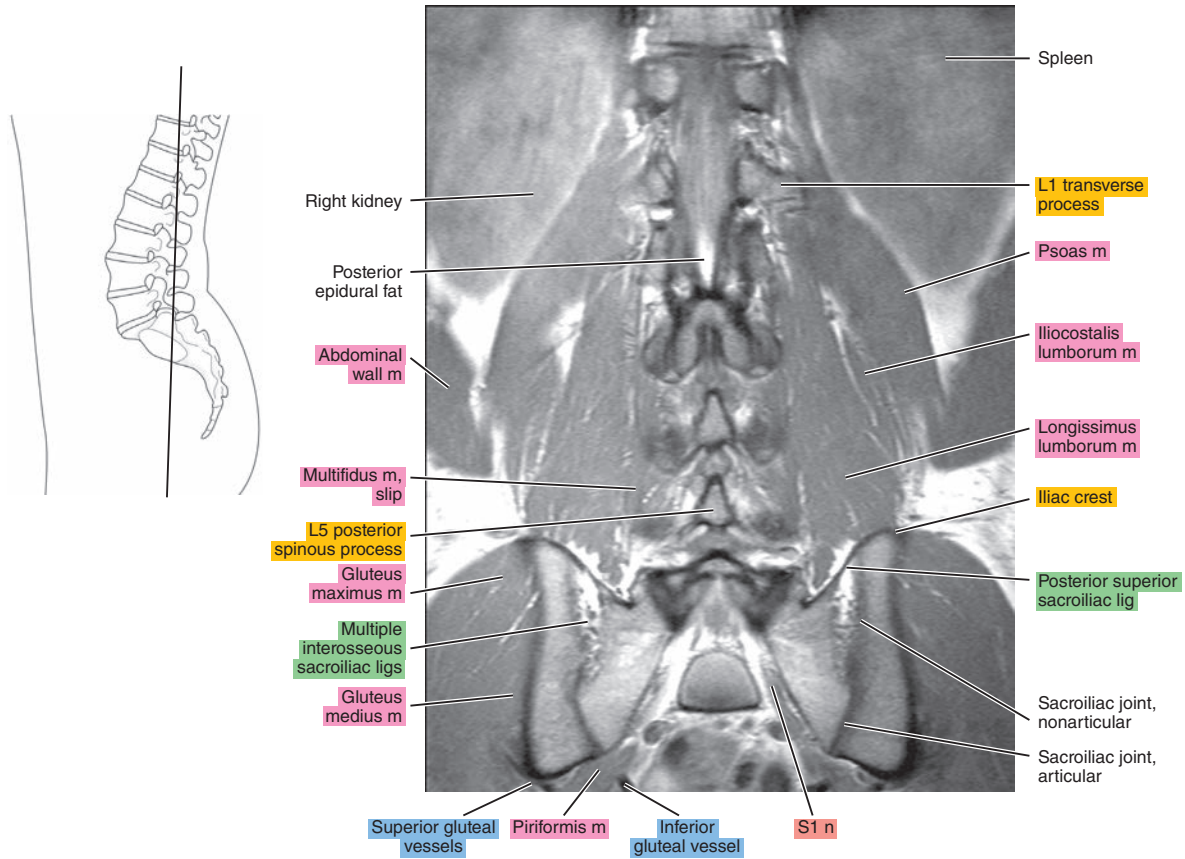


Figure 15.3.10

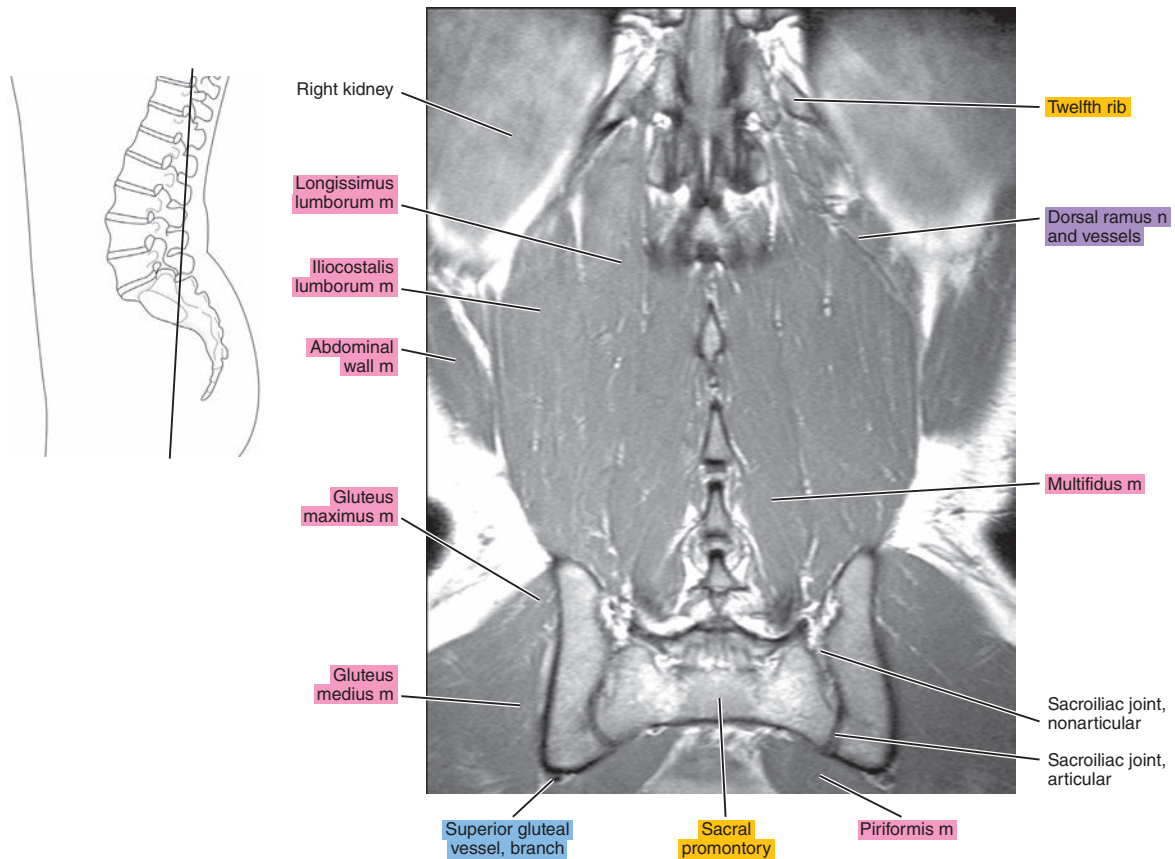
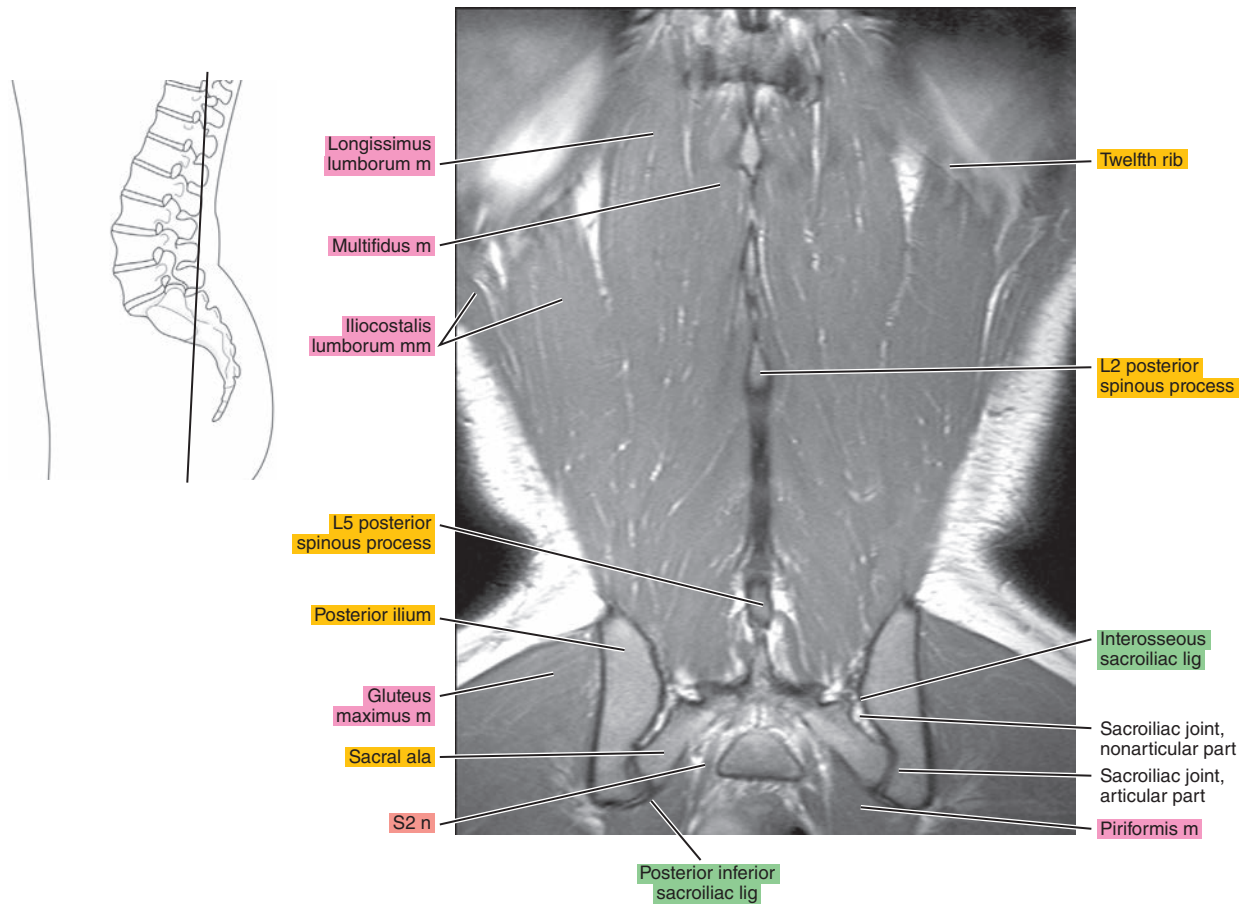


Figure 15.3.11



*Chapter*  
**16**

**CT of the Abdomen**

# AXIAL

Figure 16.1.1

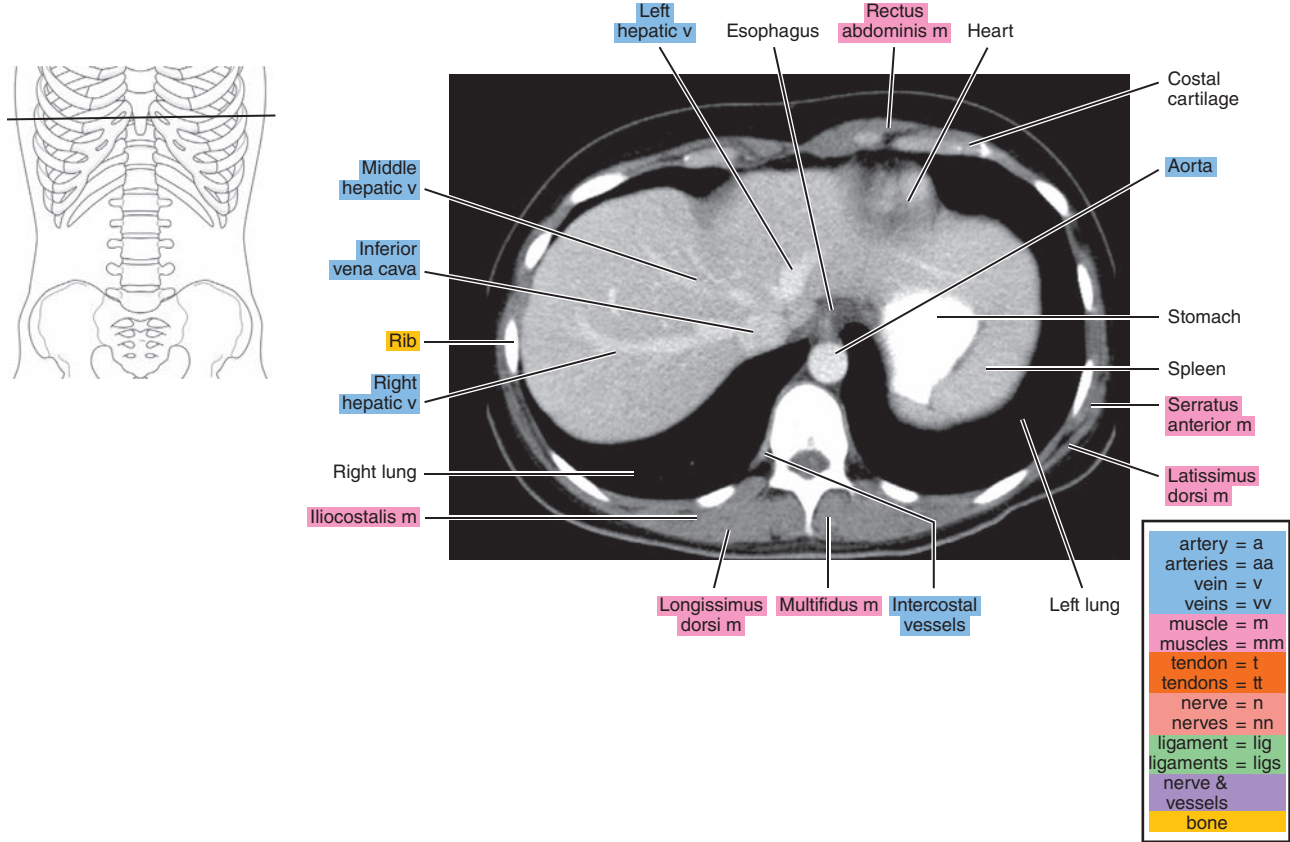


Figure 16.1.2

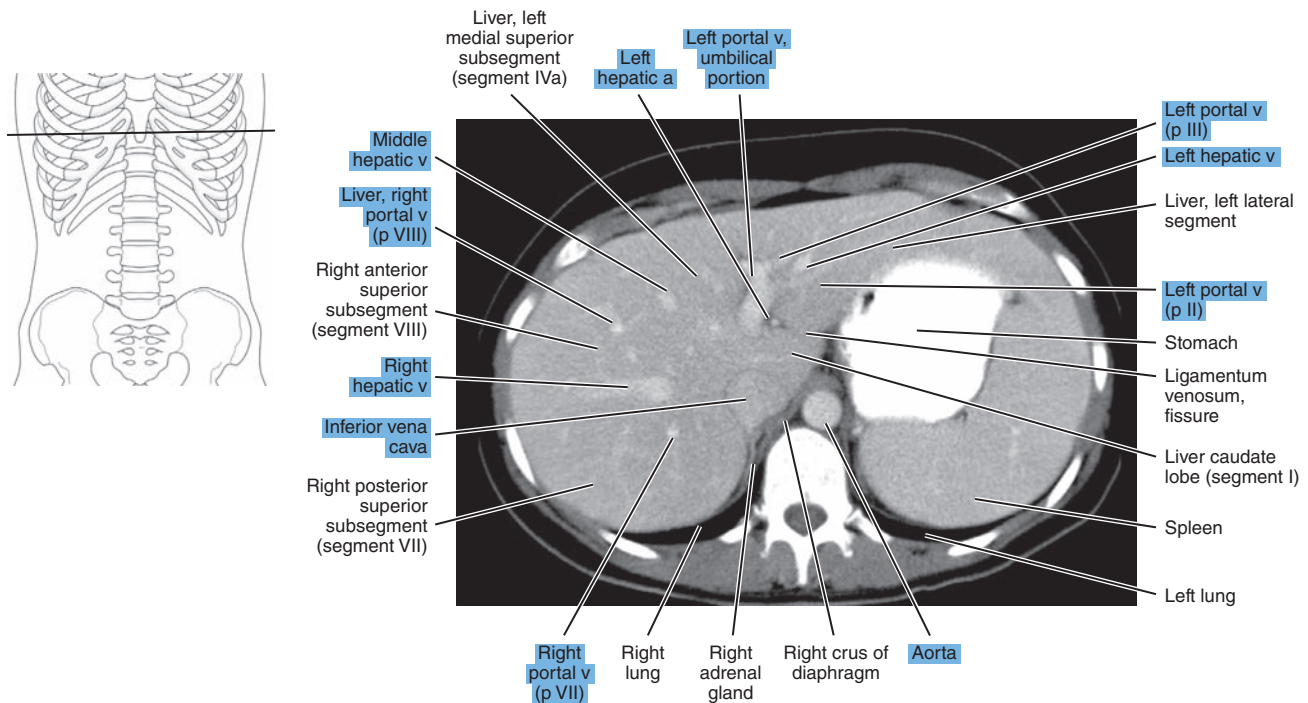




Figure 16.1.3

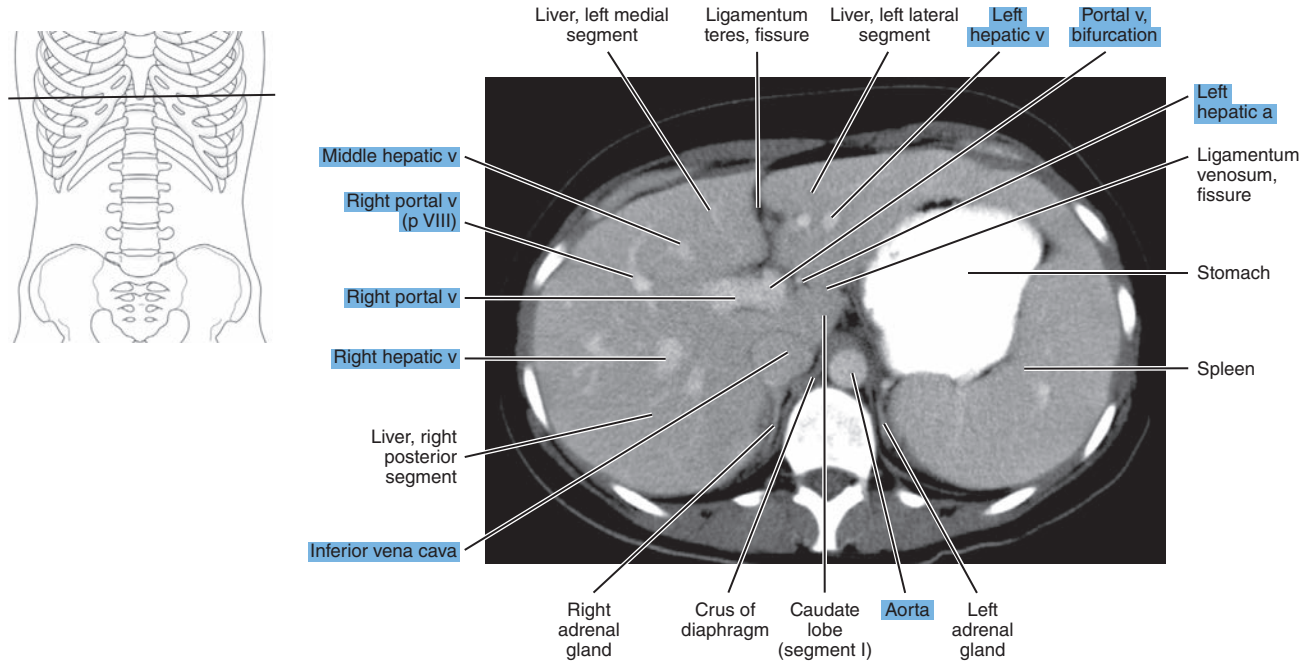


Figure 16.1.4

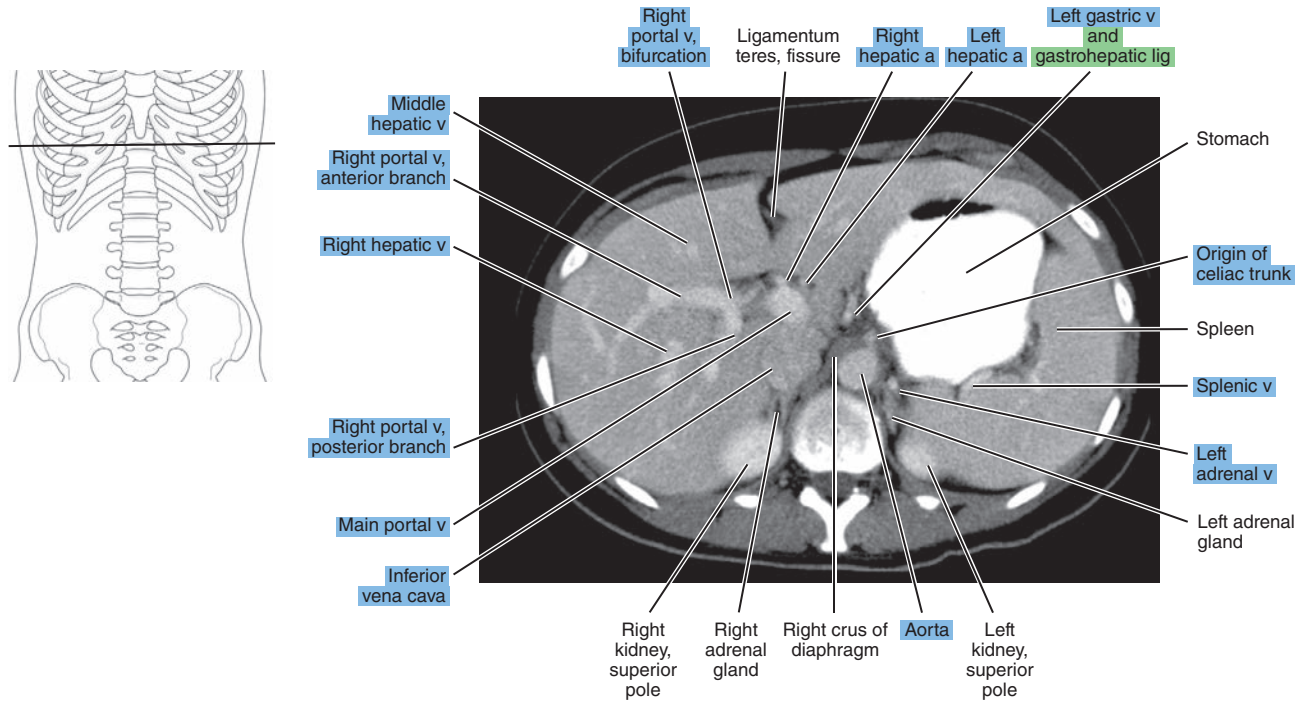


Figure 16.1.5

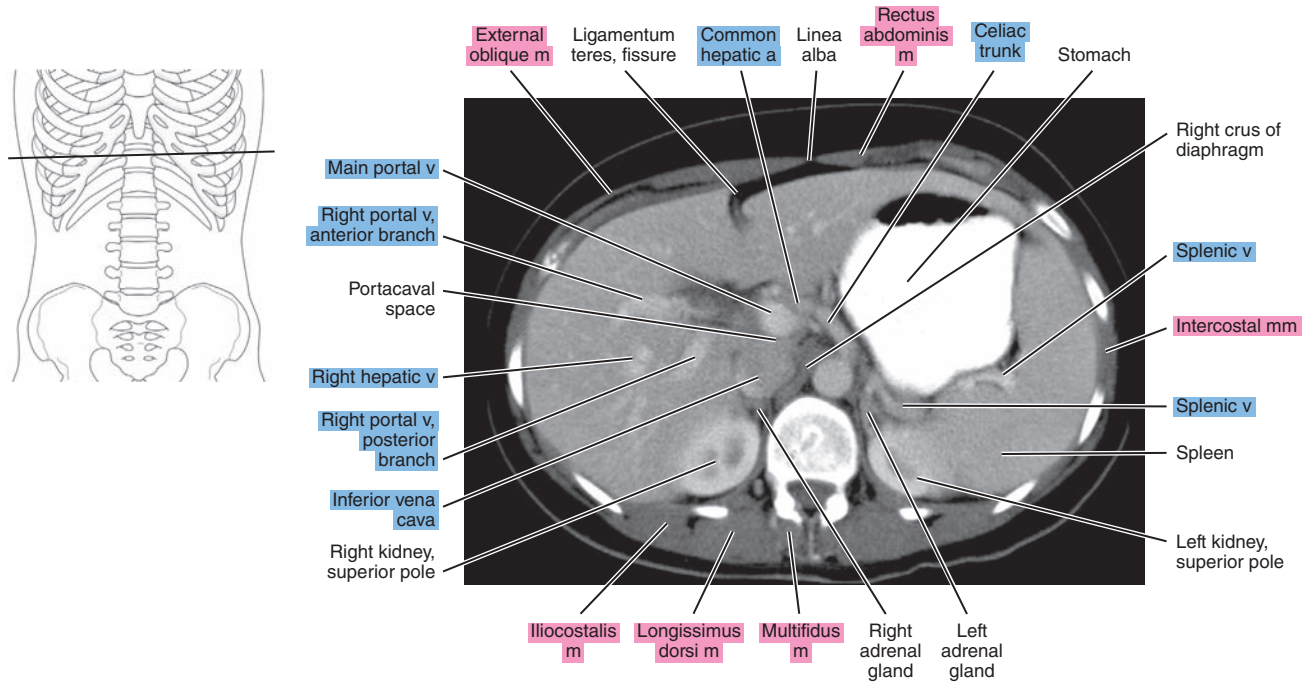


Figure 16.1.6

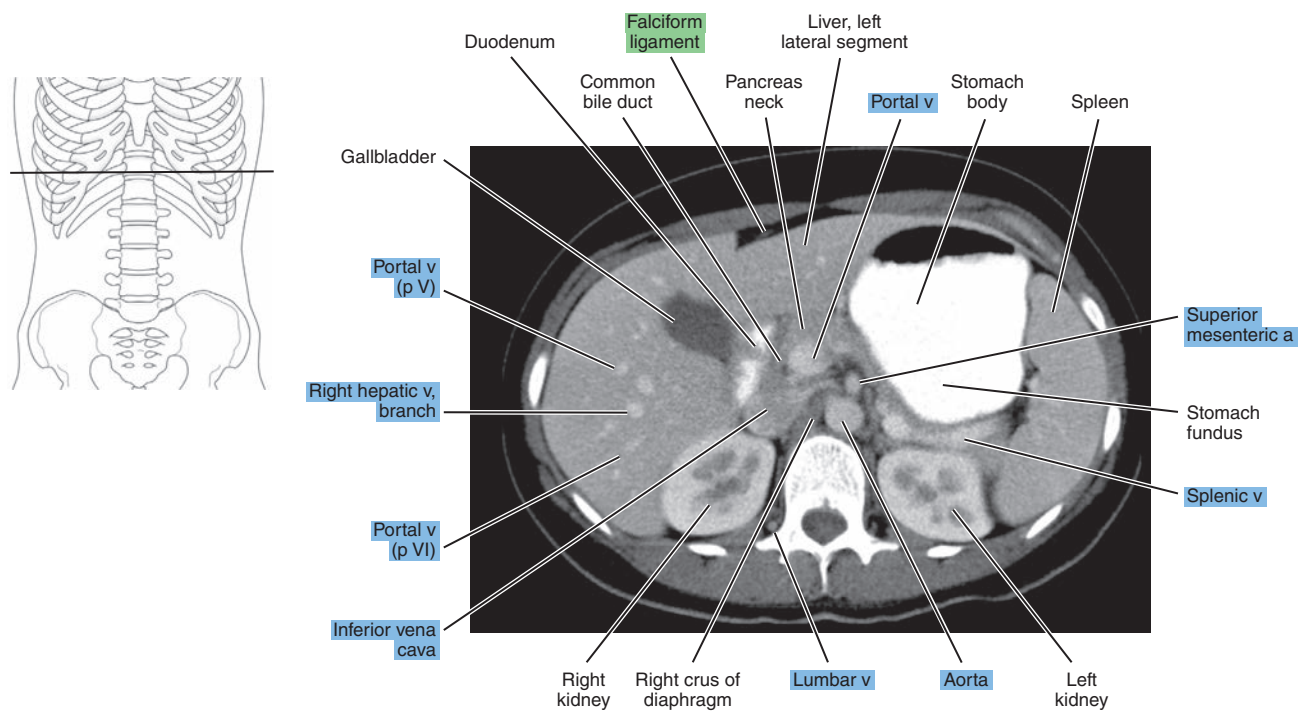


Figure 16.1.7

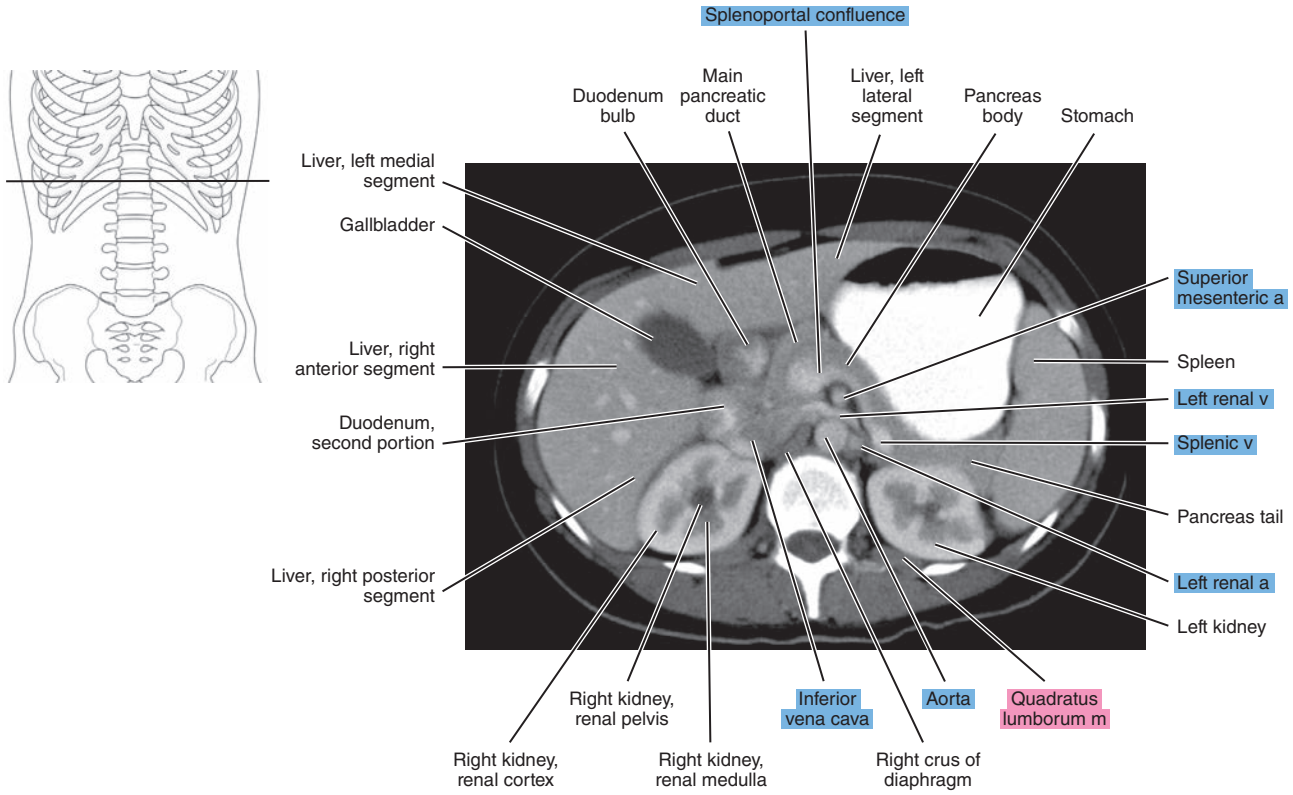


Figure 16.1.8

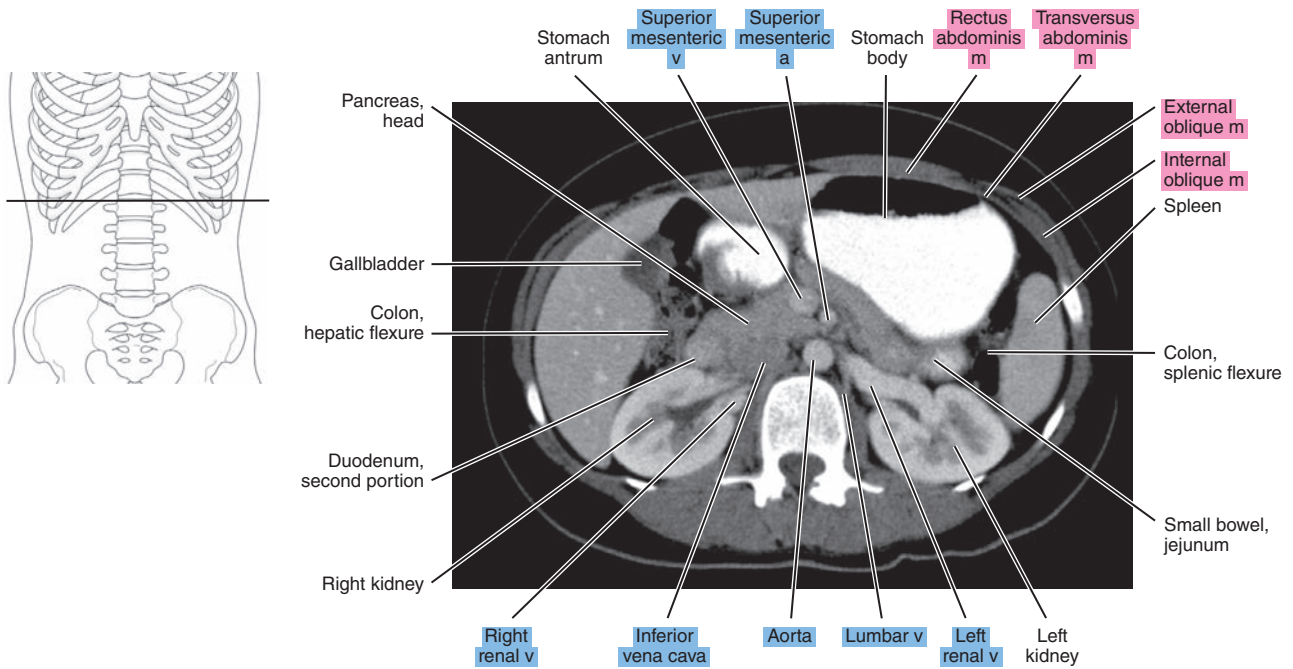




Figure 16.1.9

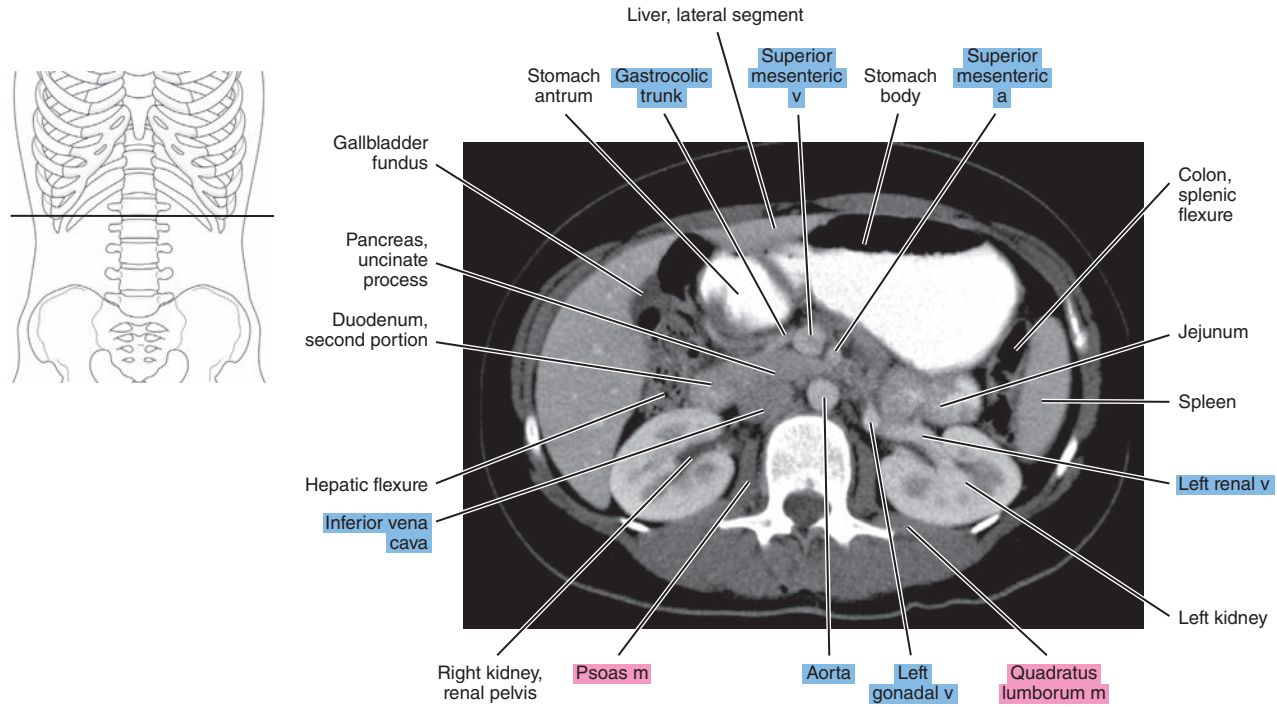


Figure 16.1.10

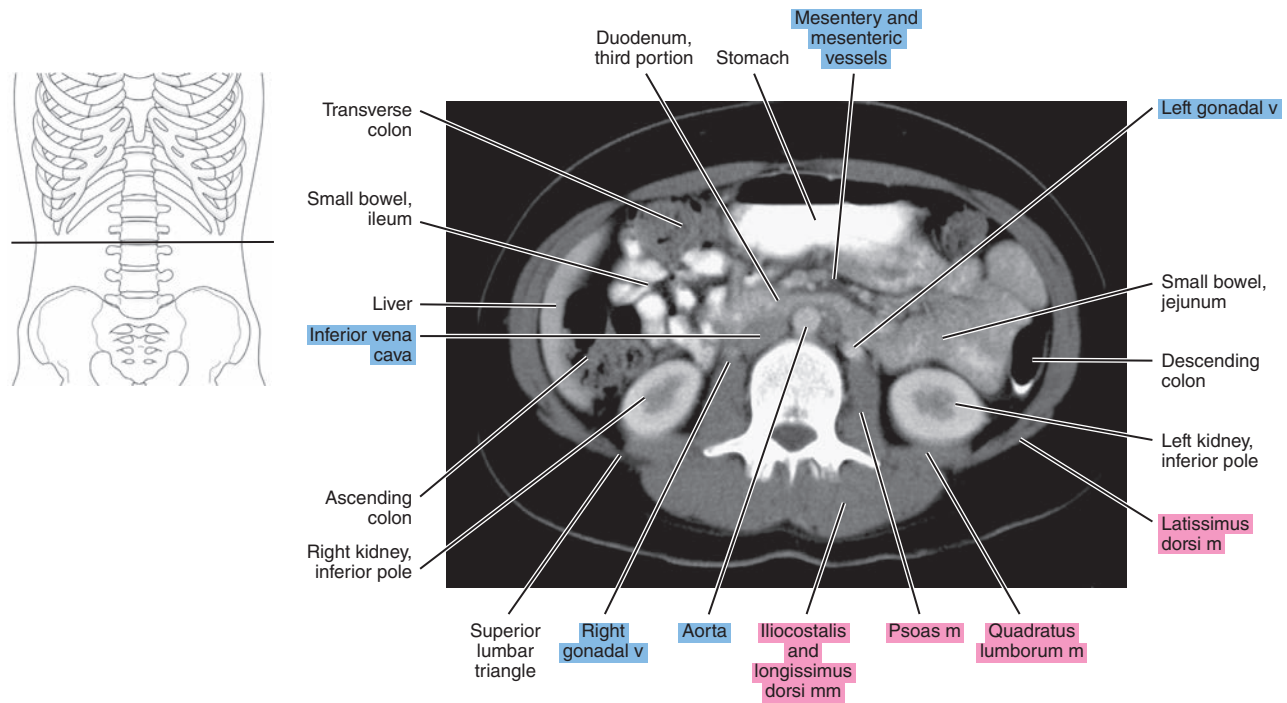




Figure 16.1.11

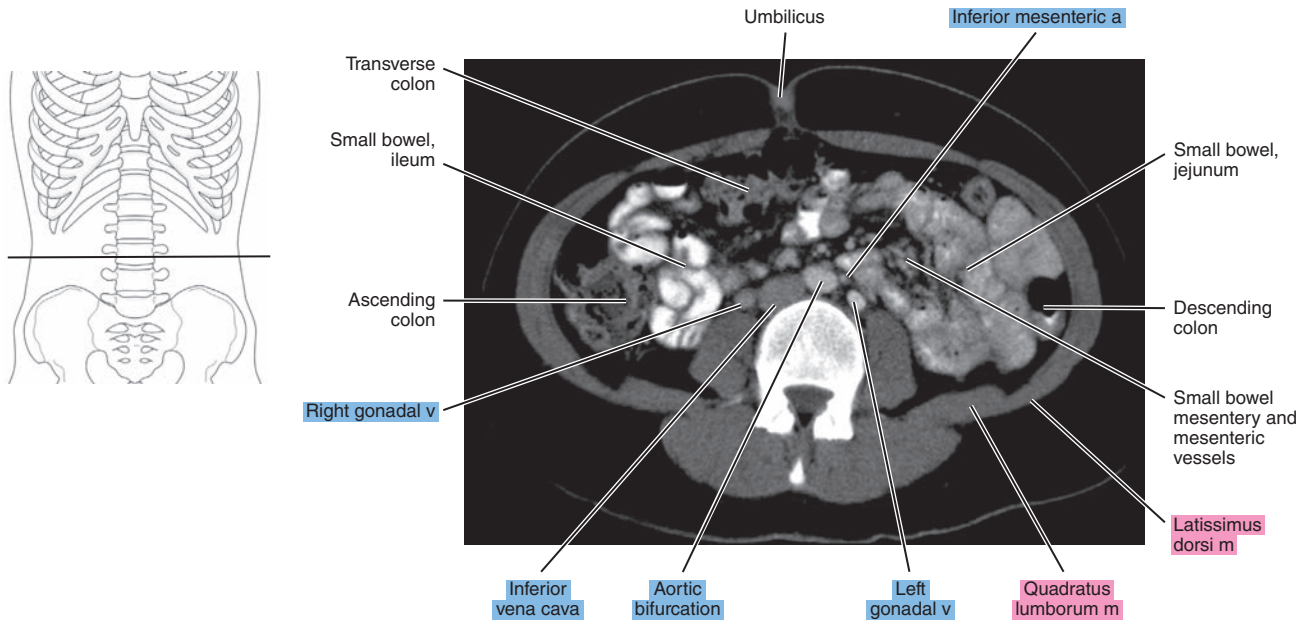
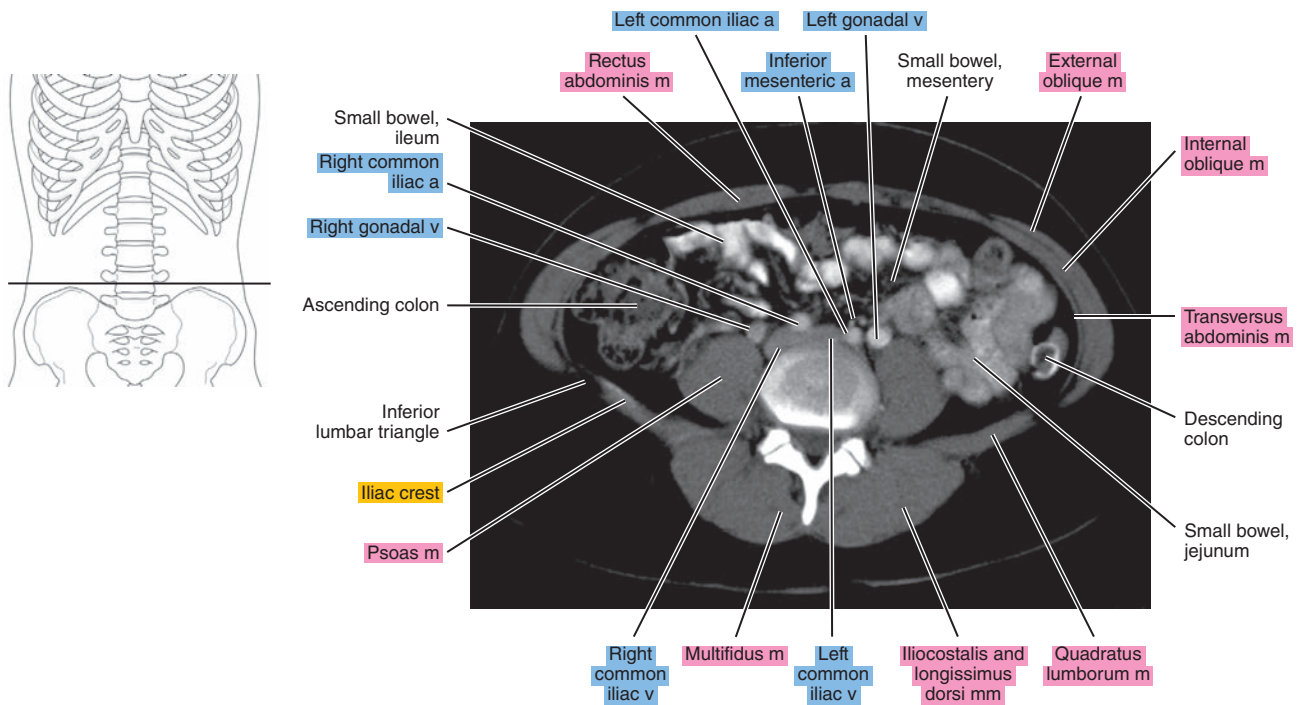


Figure 16.1.12



# SAGITTAL

Figure 16.2.1

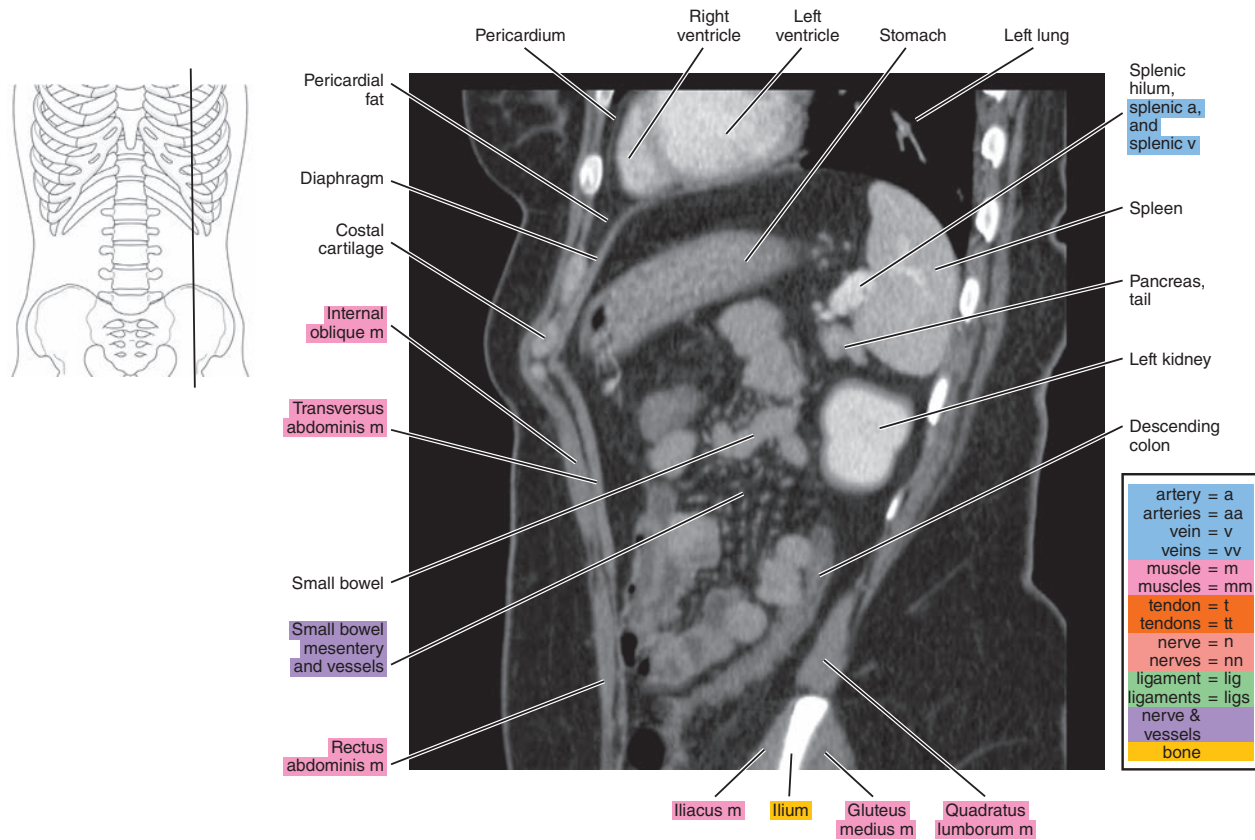


Figure 16.2.2

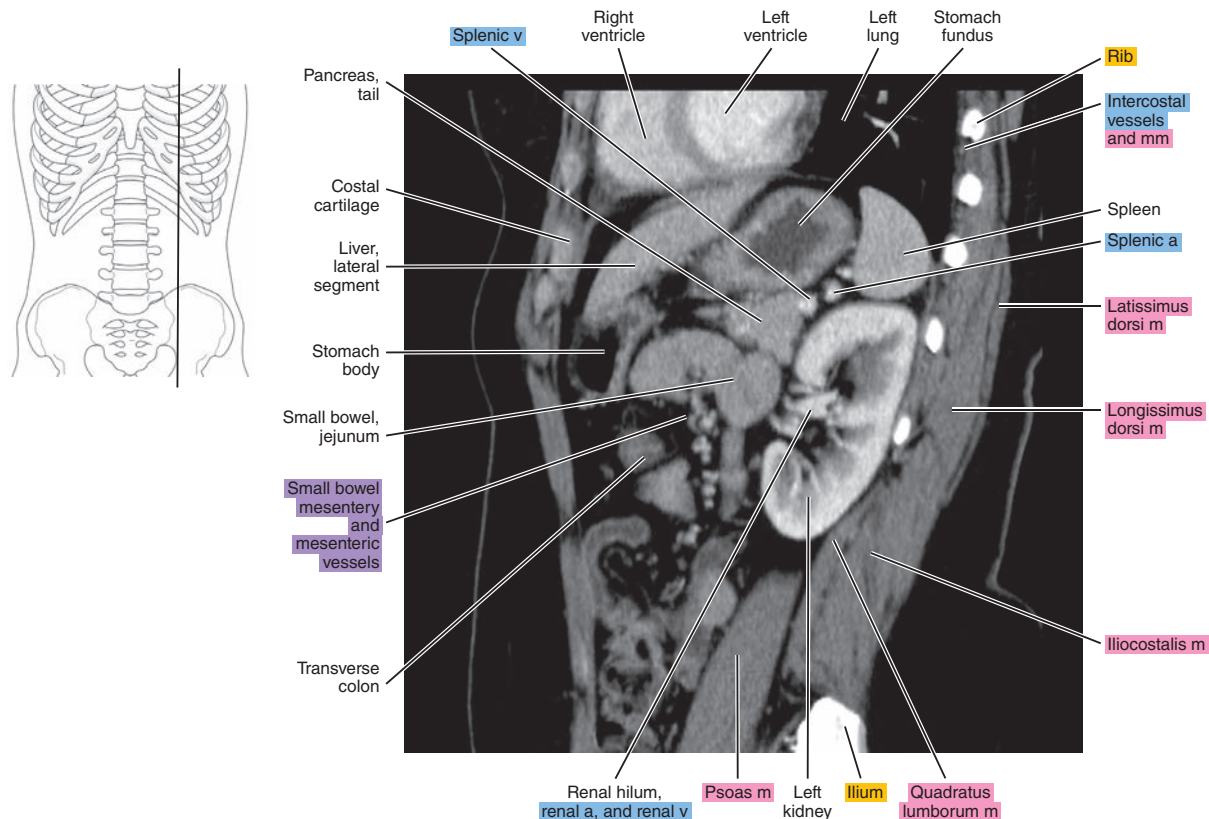


Figure 16.2.3

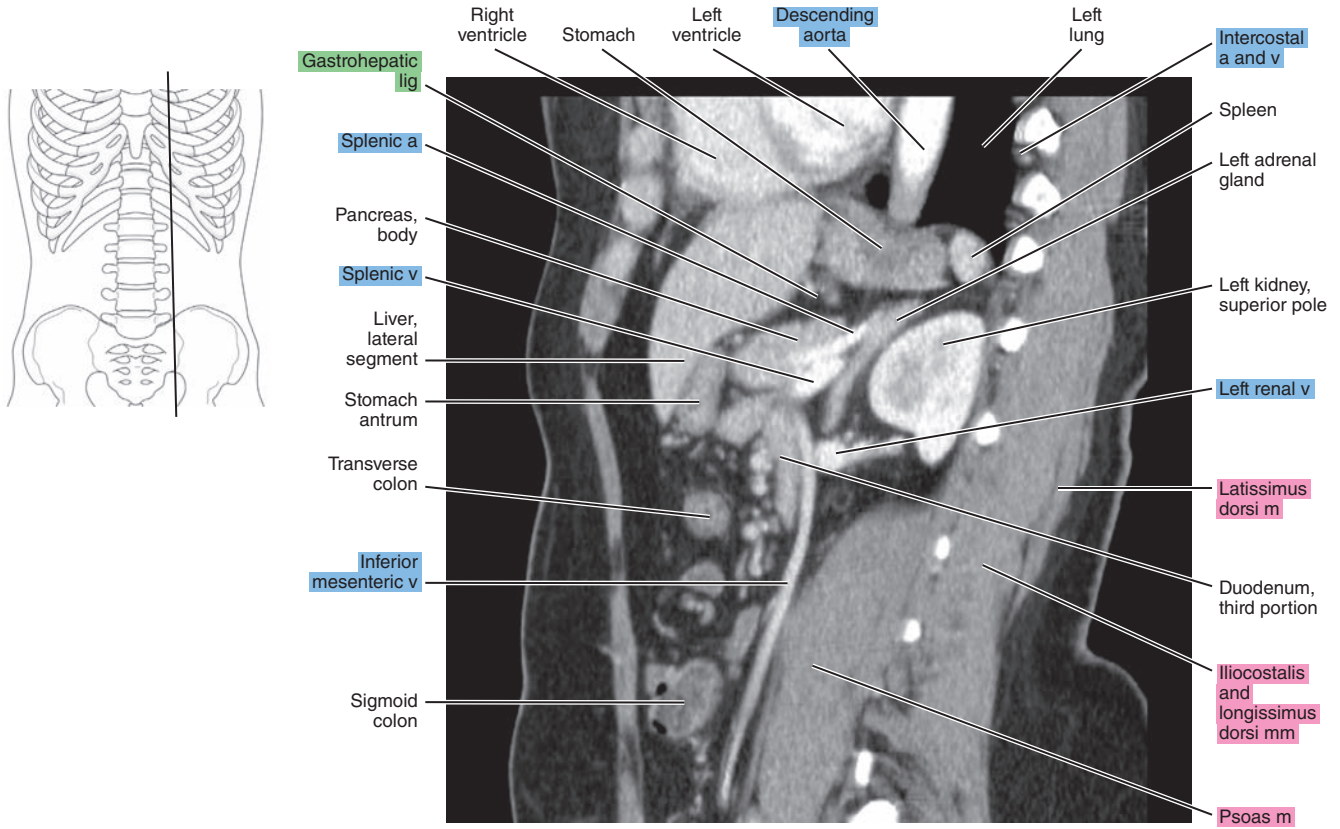


Figure 16.2.4

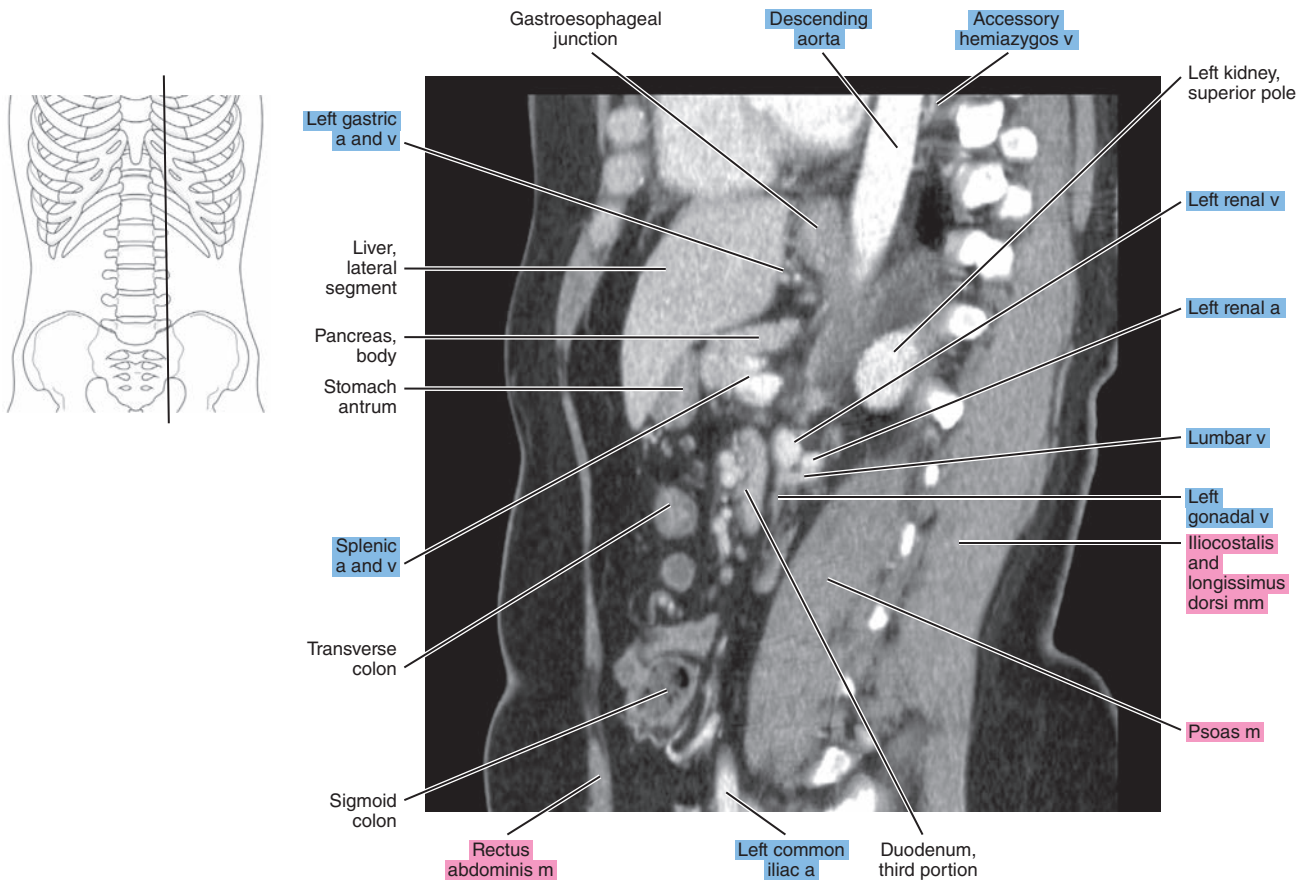




Figure 16.2.5

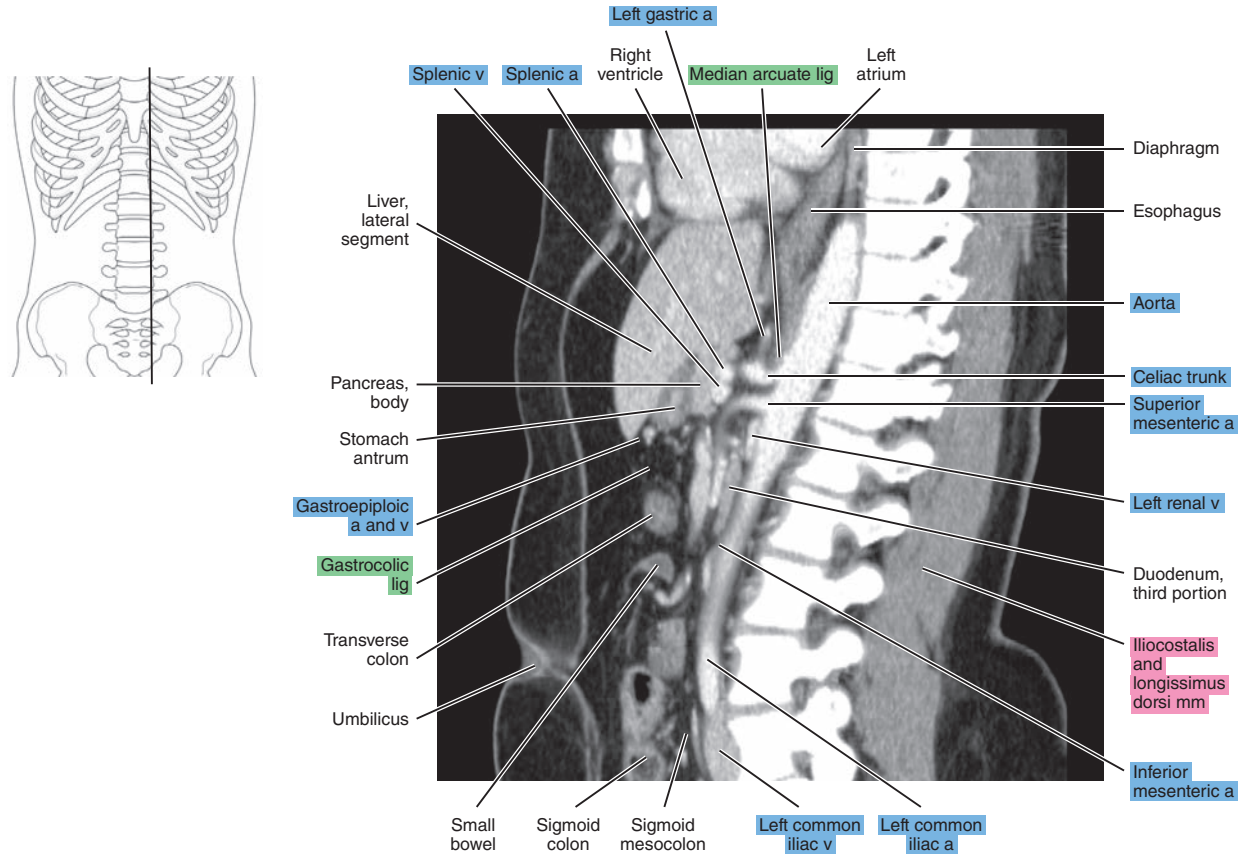


Figure 16.2.6

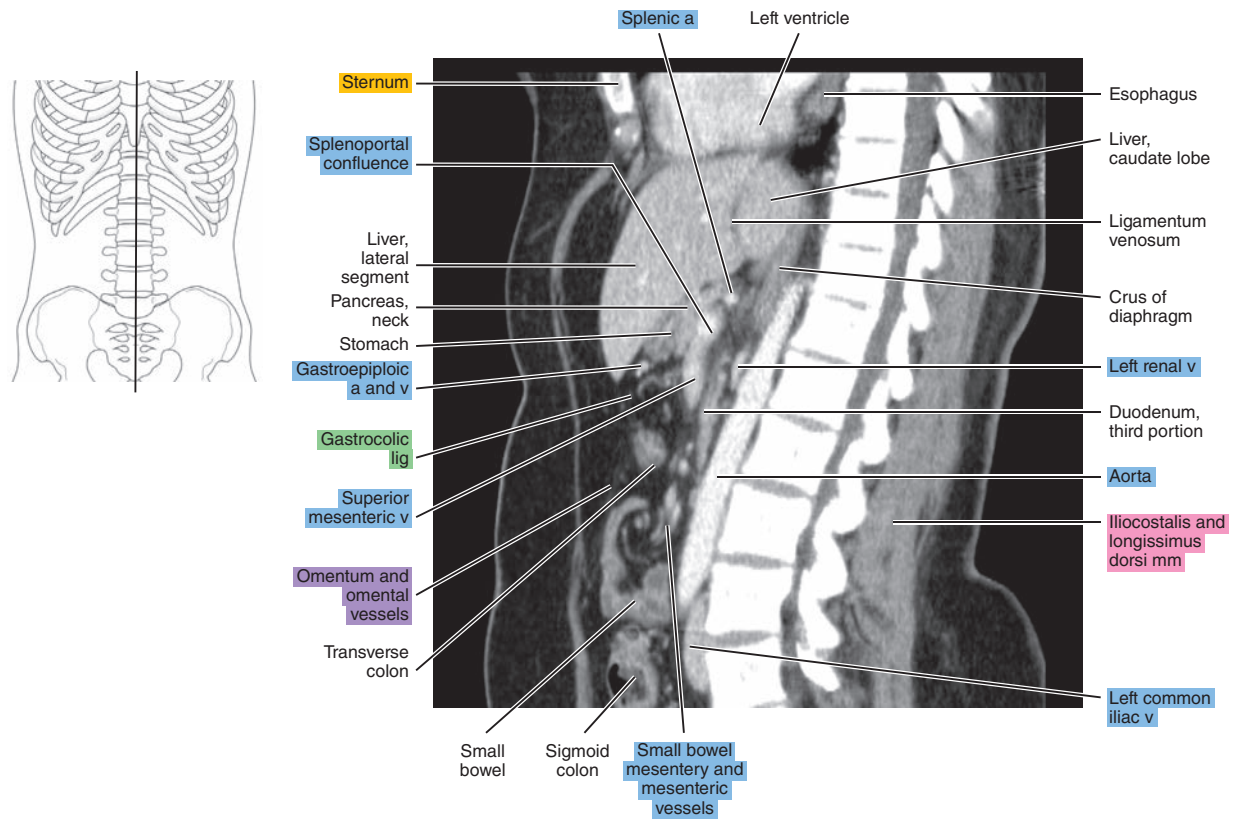




Figure 16.2.7

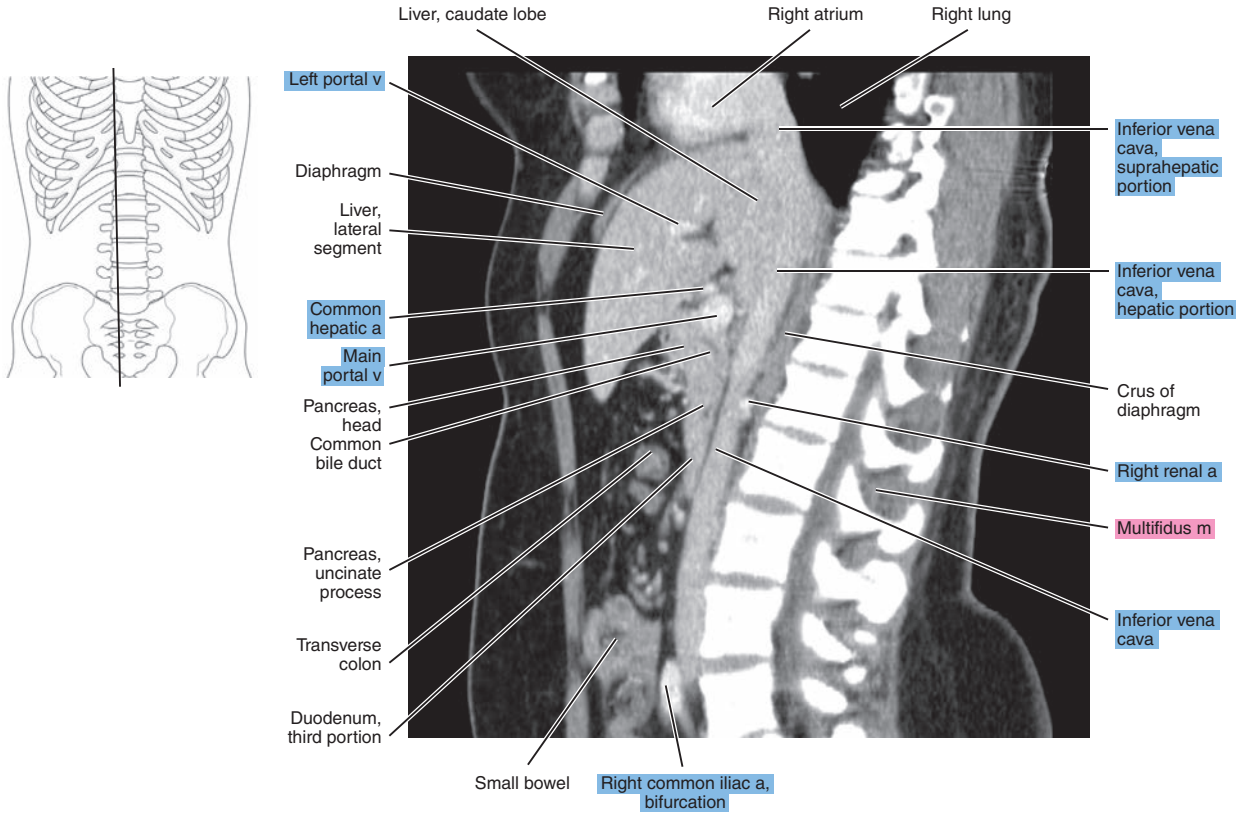


Figure 16.2.8

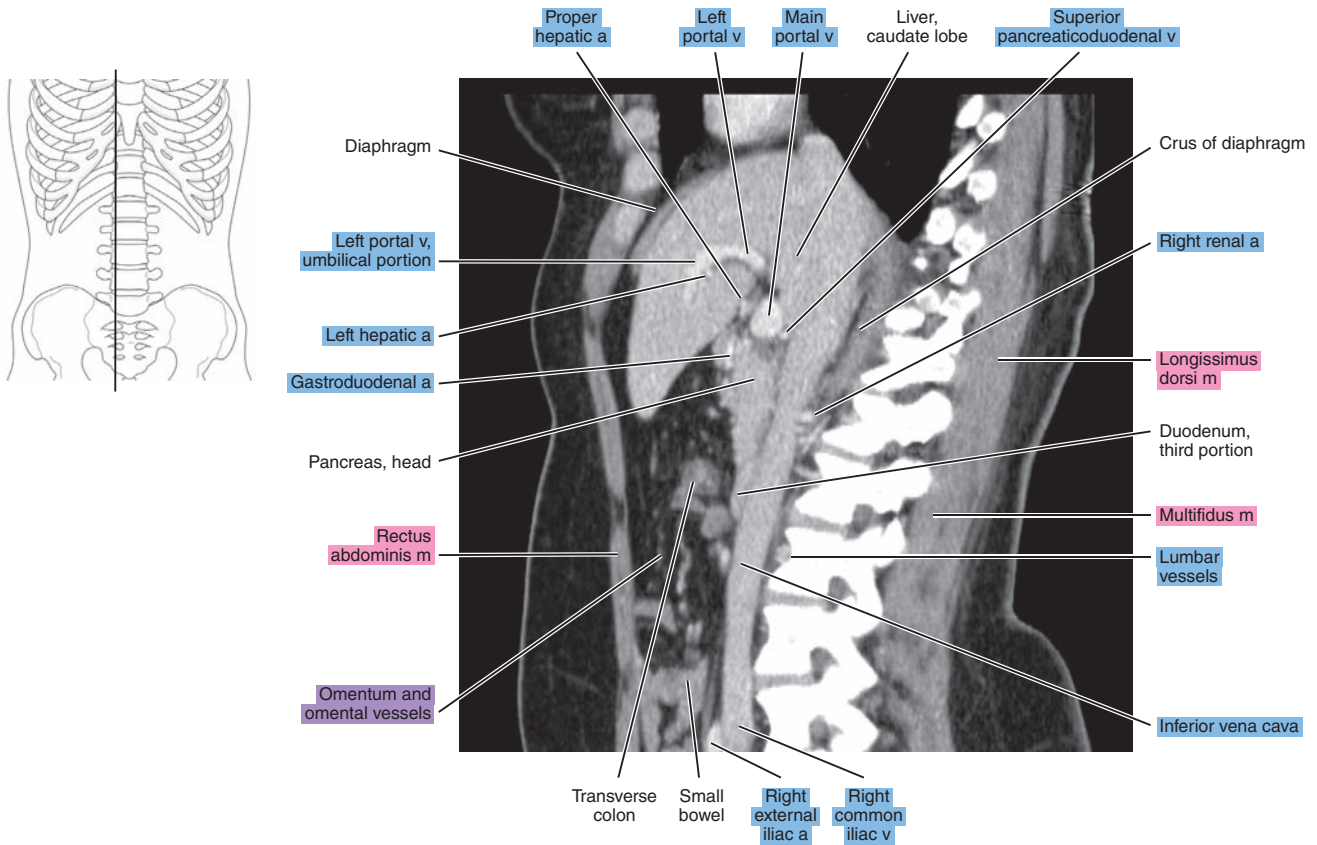


Figure 16.2.9

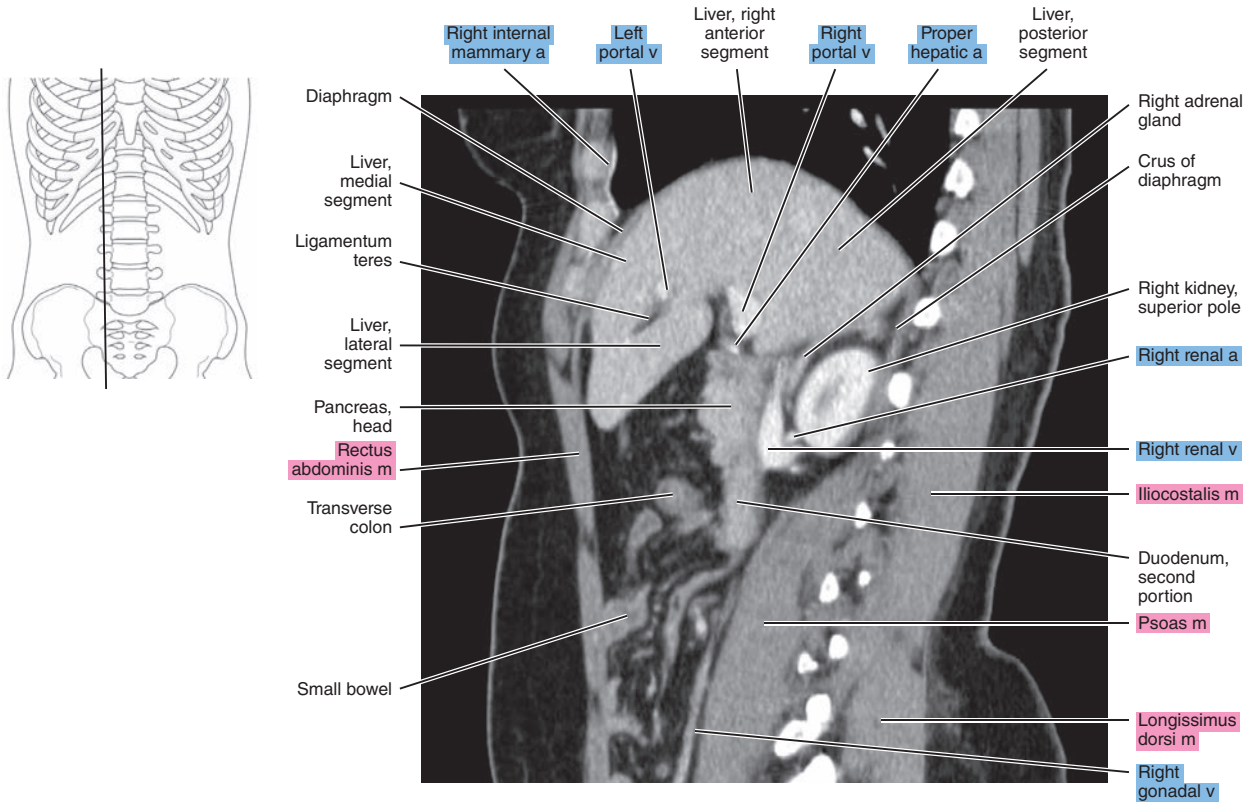


Figure 16.2.10

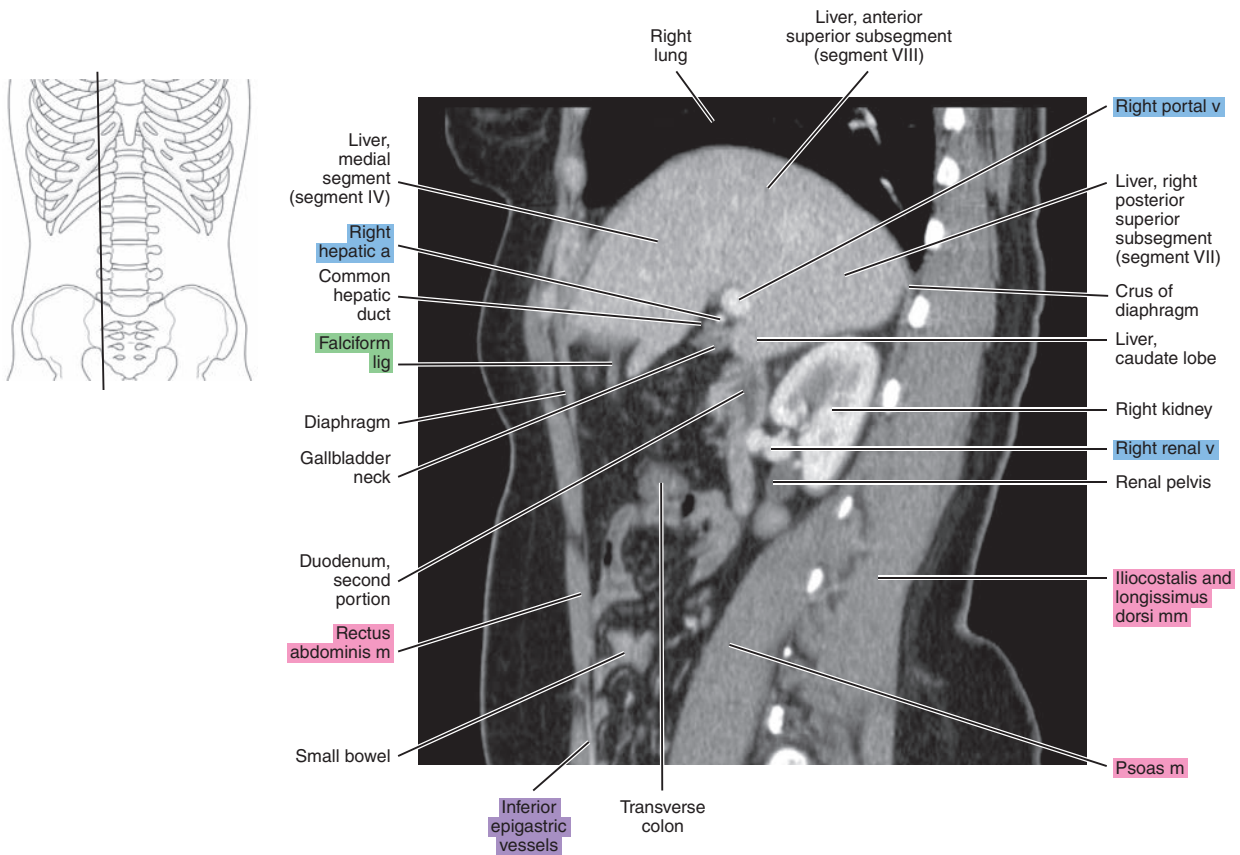


Figure 16.2.11

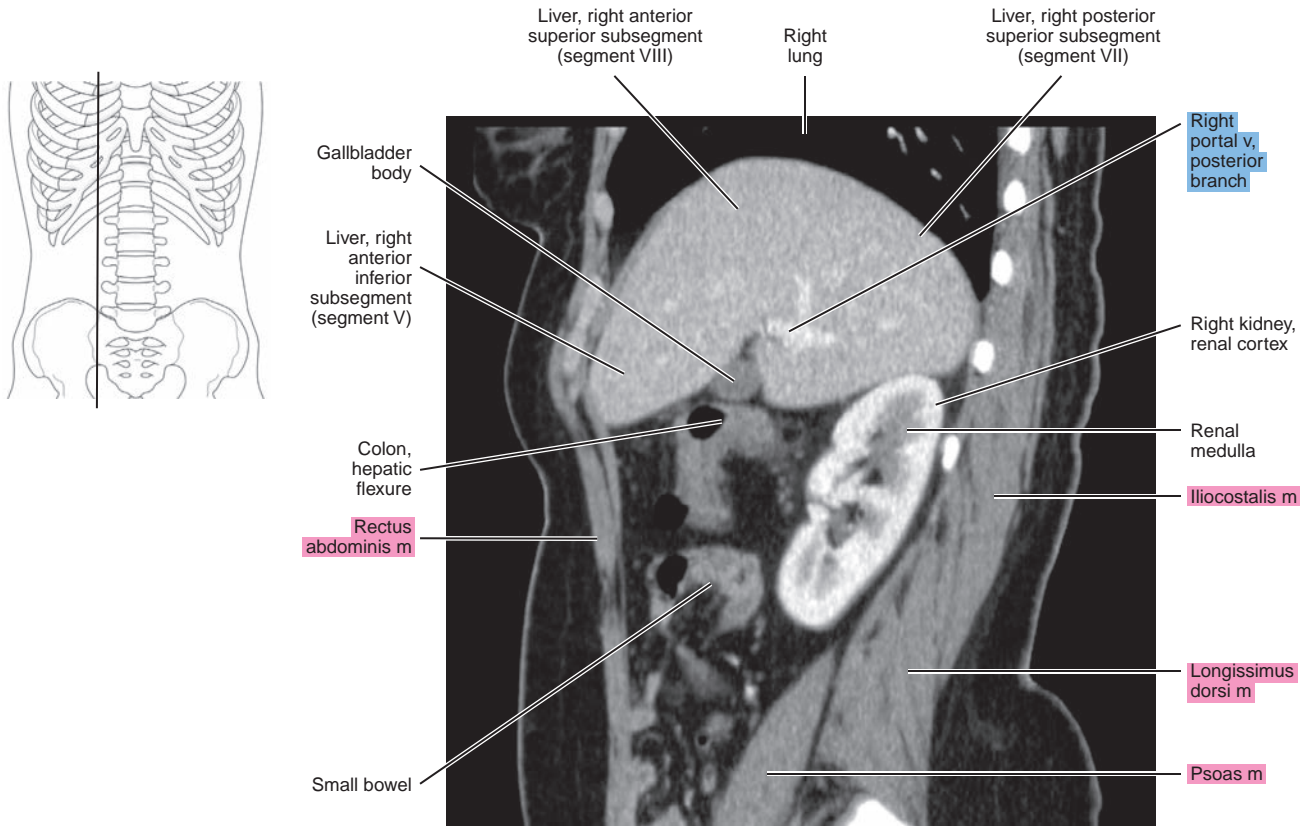
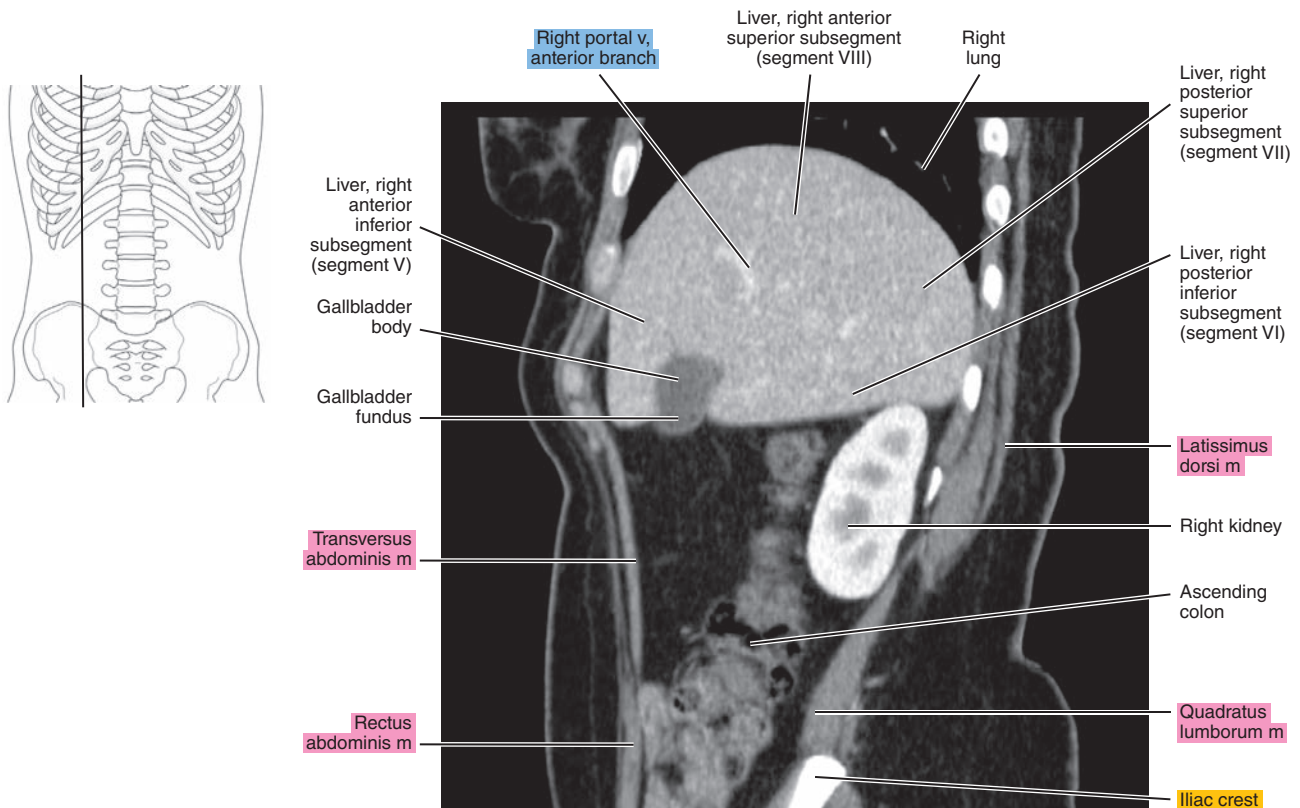


Figure 16.2.12





# CORONAL

Figure 16.3.1

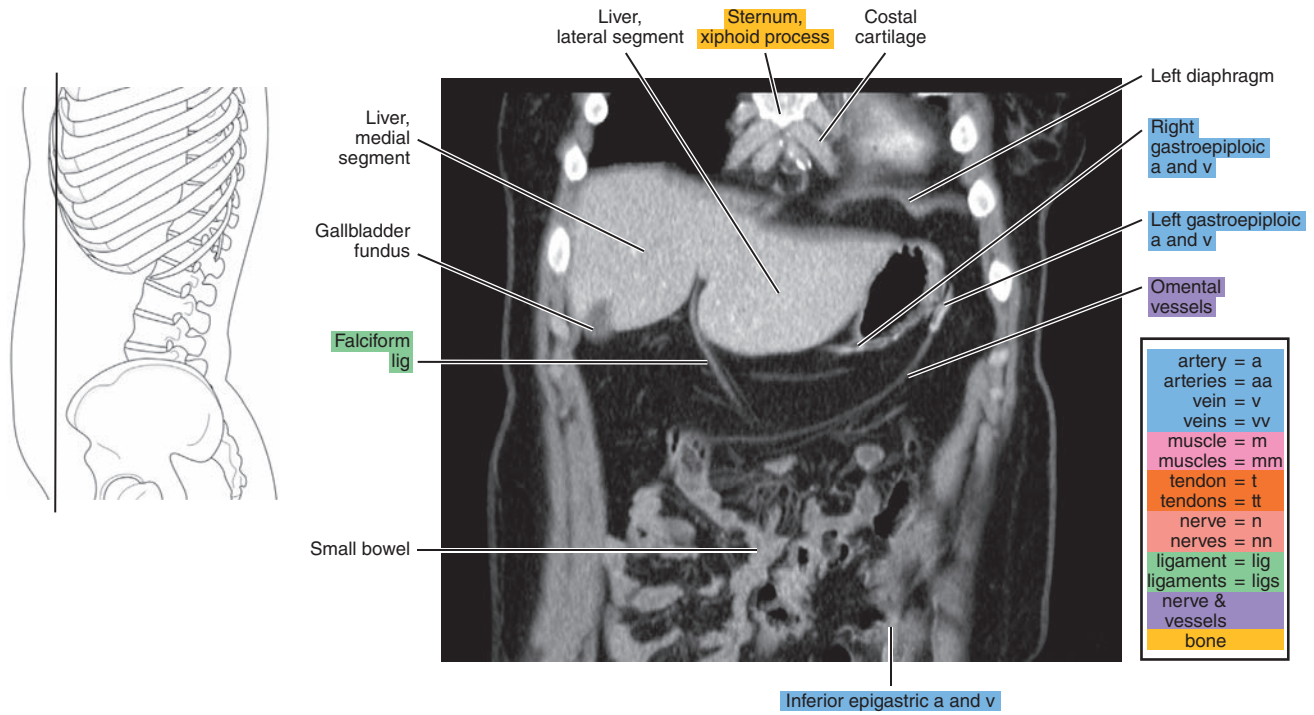


Figure 16.3.2

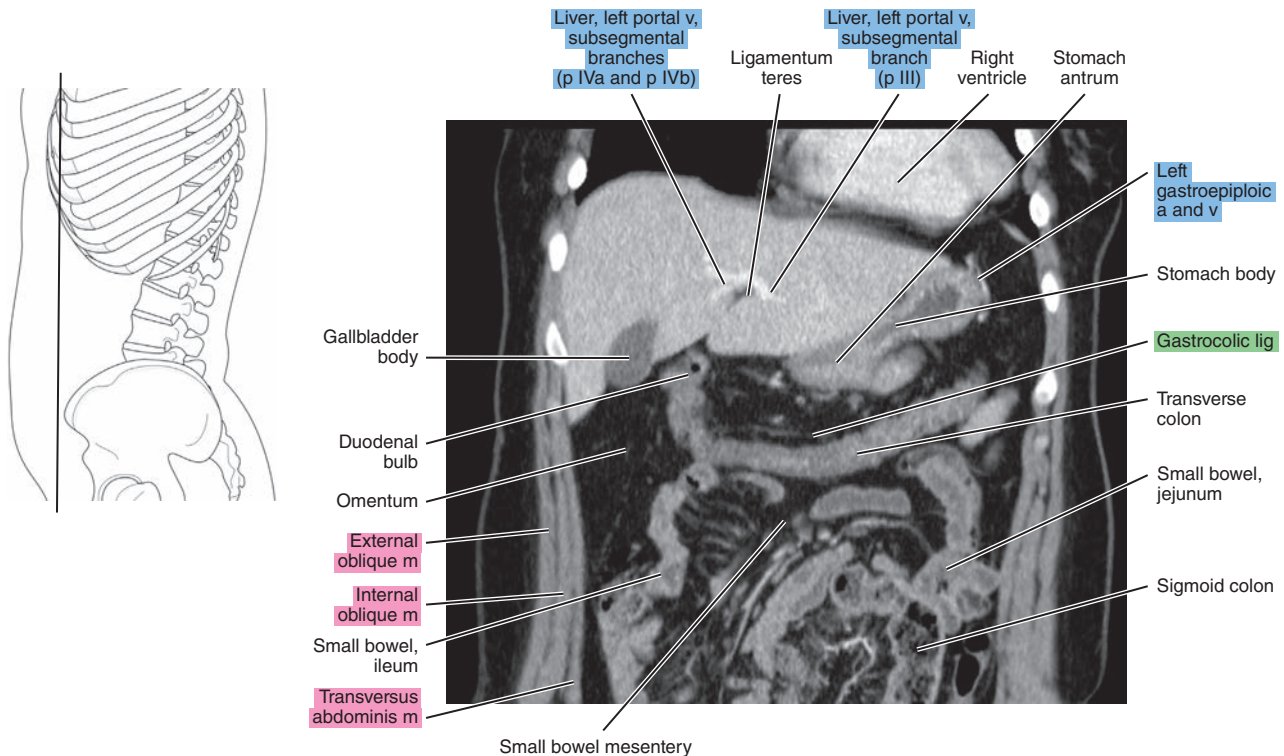




Figure 16.3.3

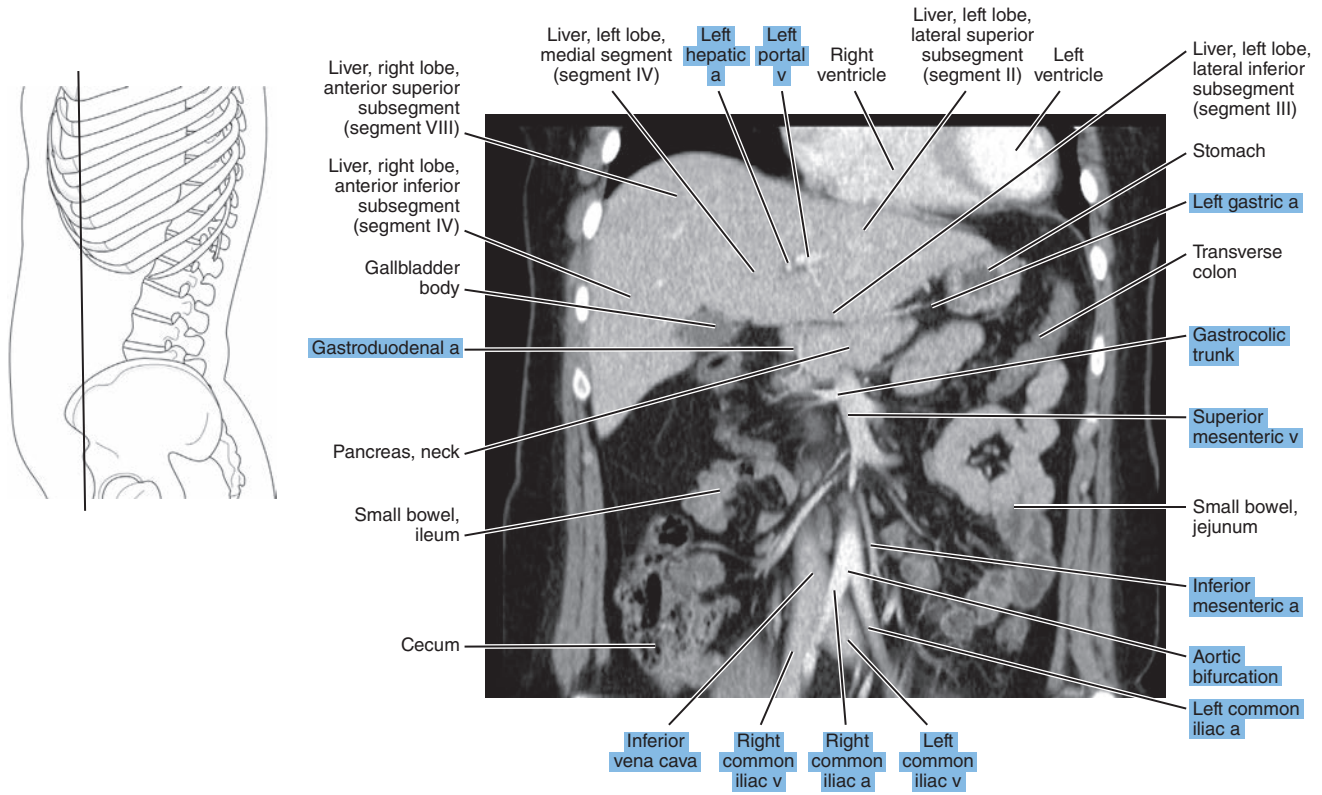


Figure 16.3.4

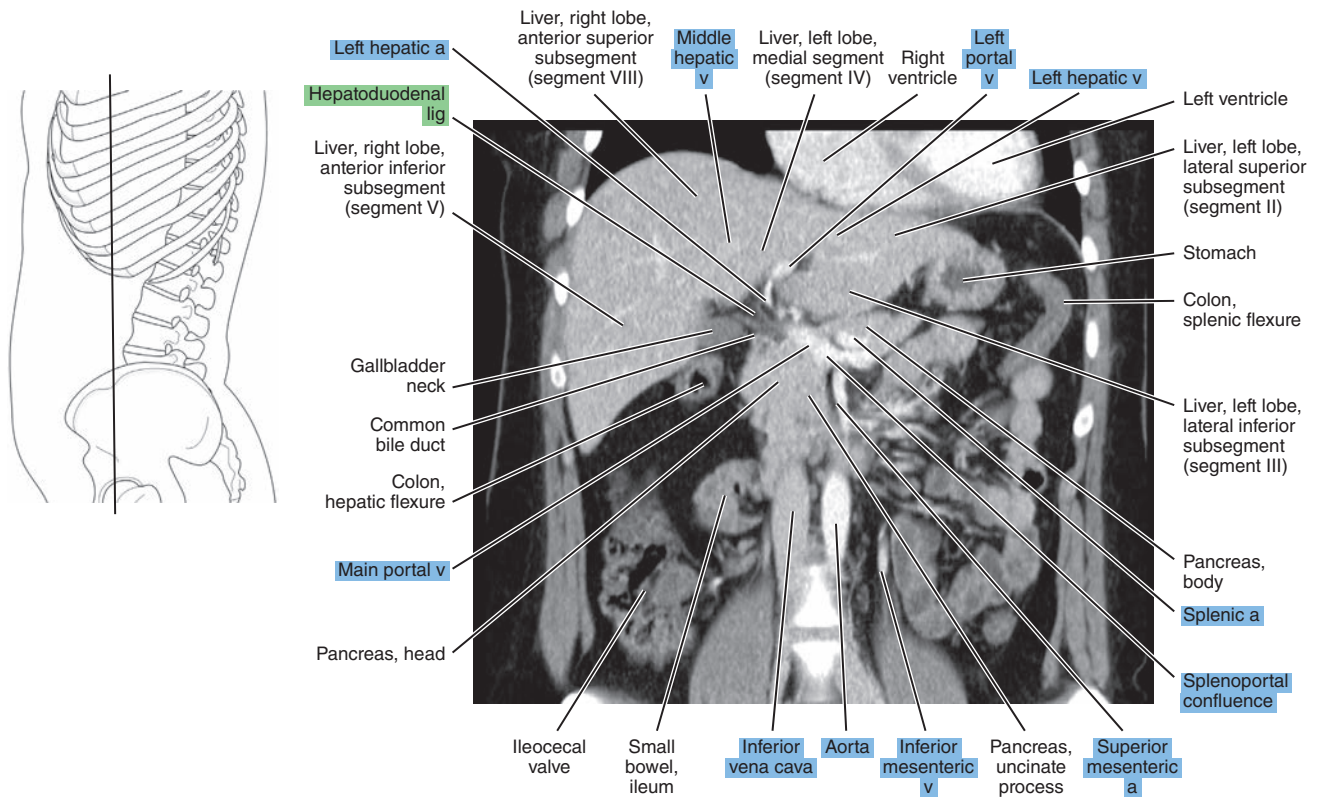


Figure 16.3.5

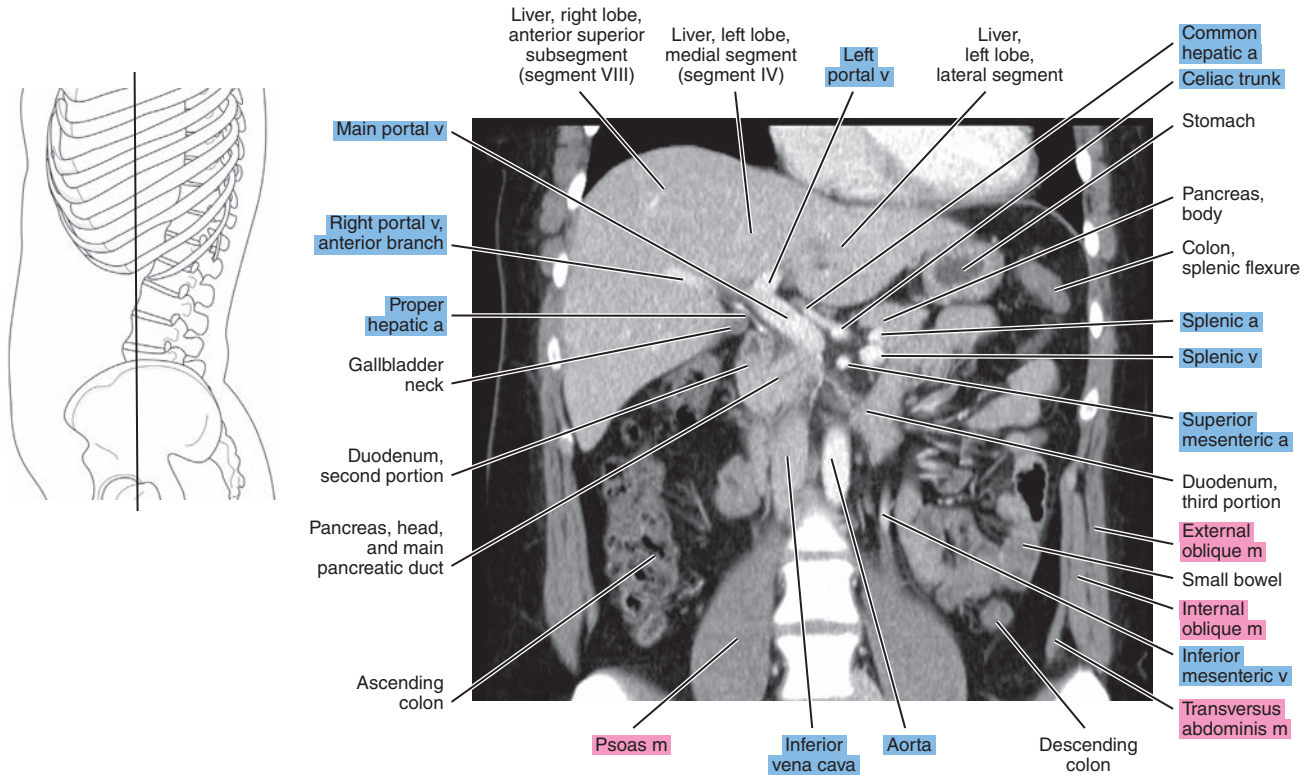


Figure 16.3.6

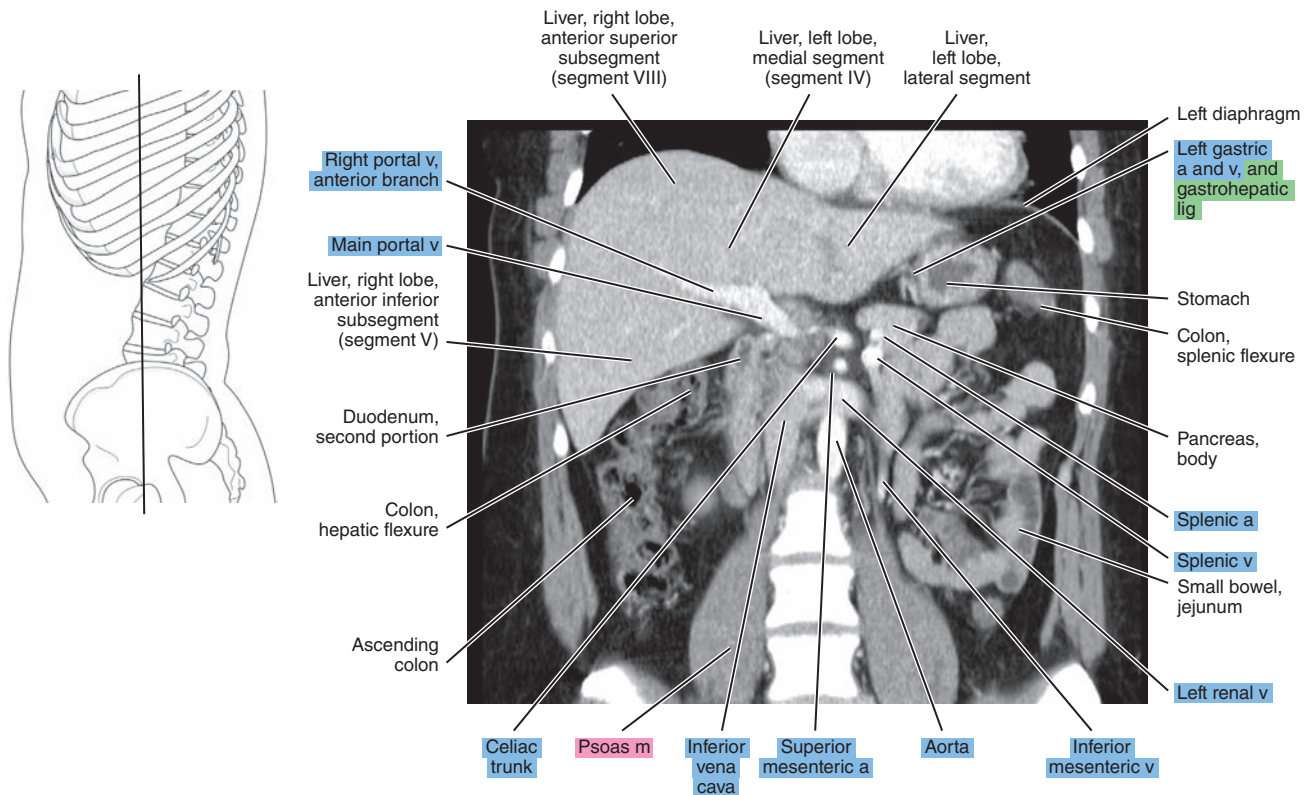




Figure 16.3.7

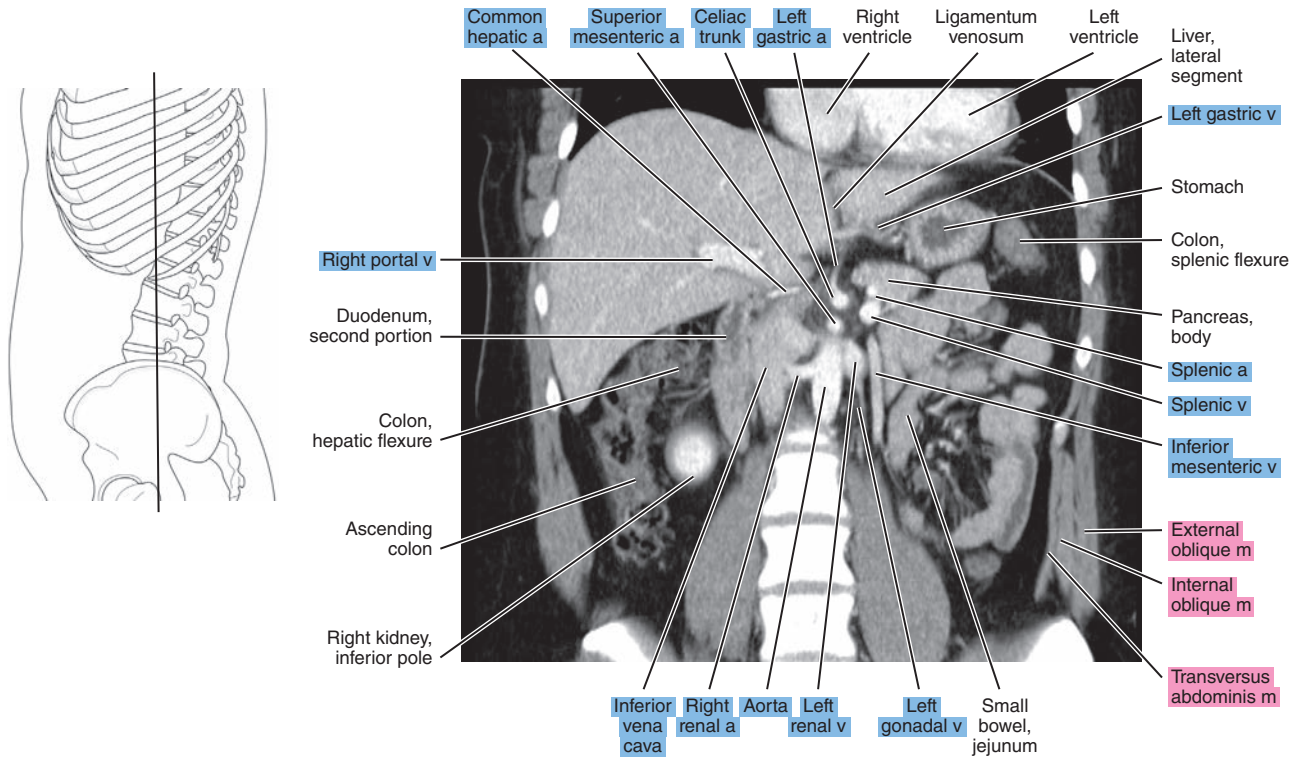


Figure 16.3.8

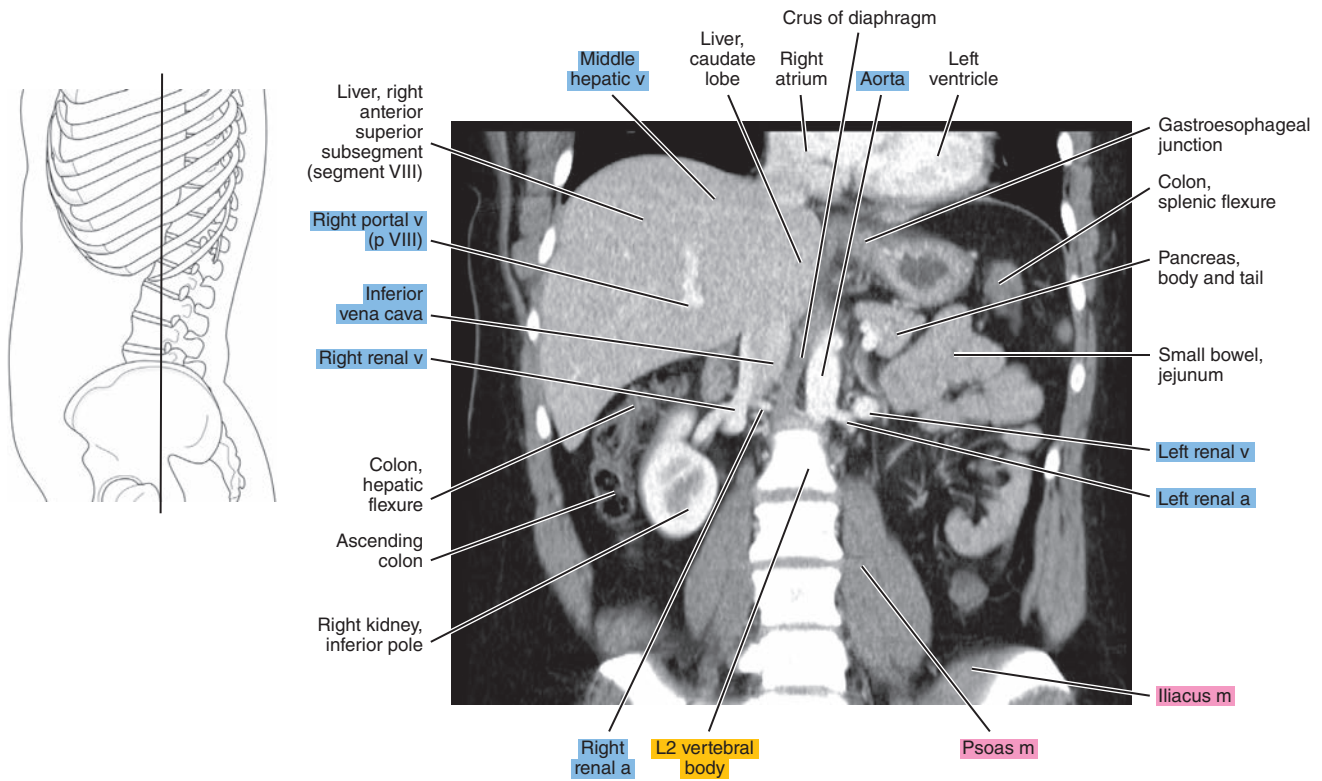


Figure 16.3.9

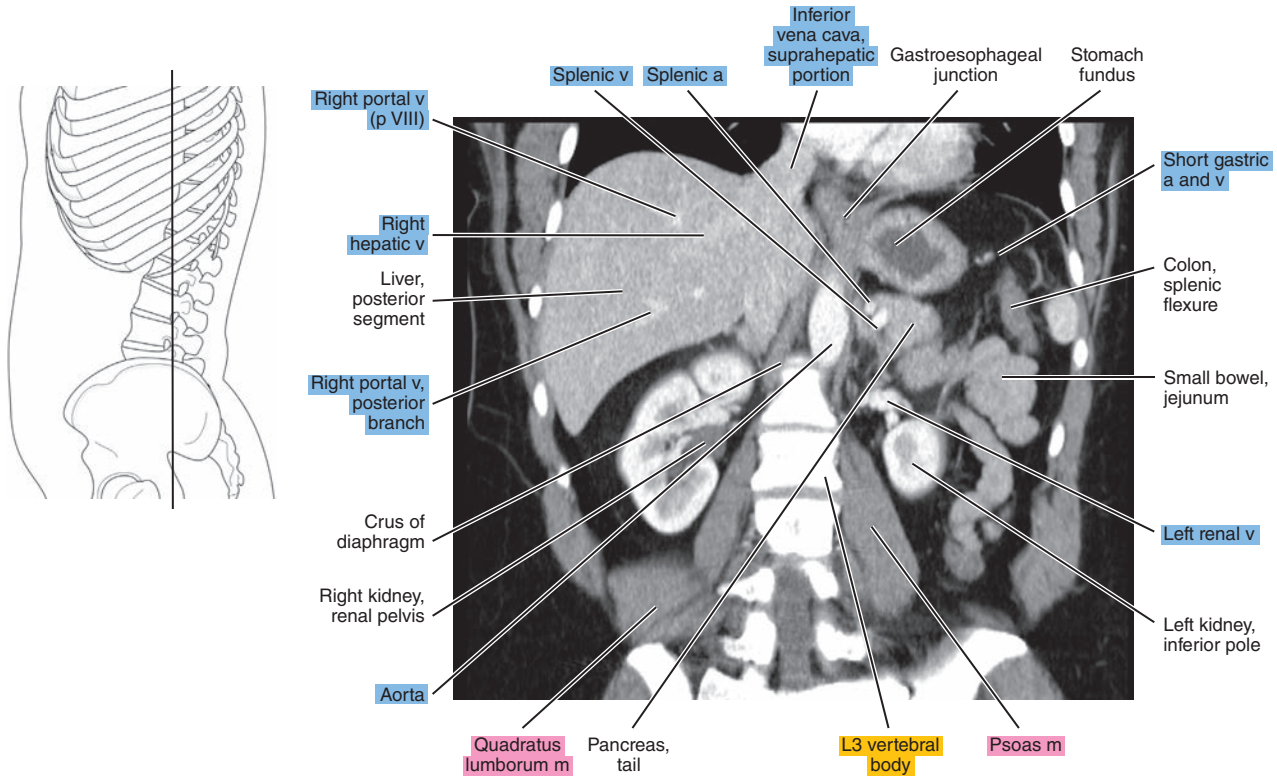


Figure 16.3.10

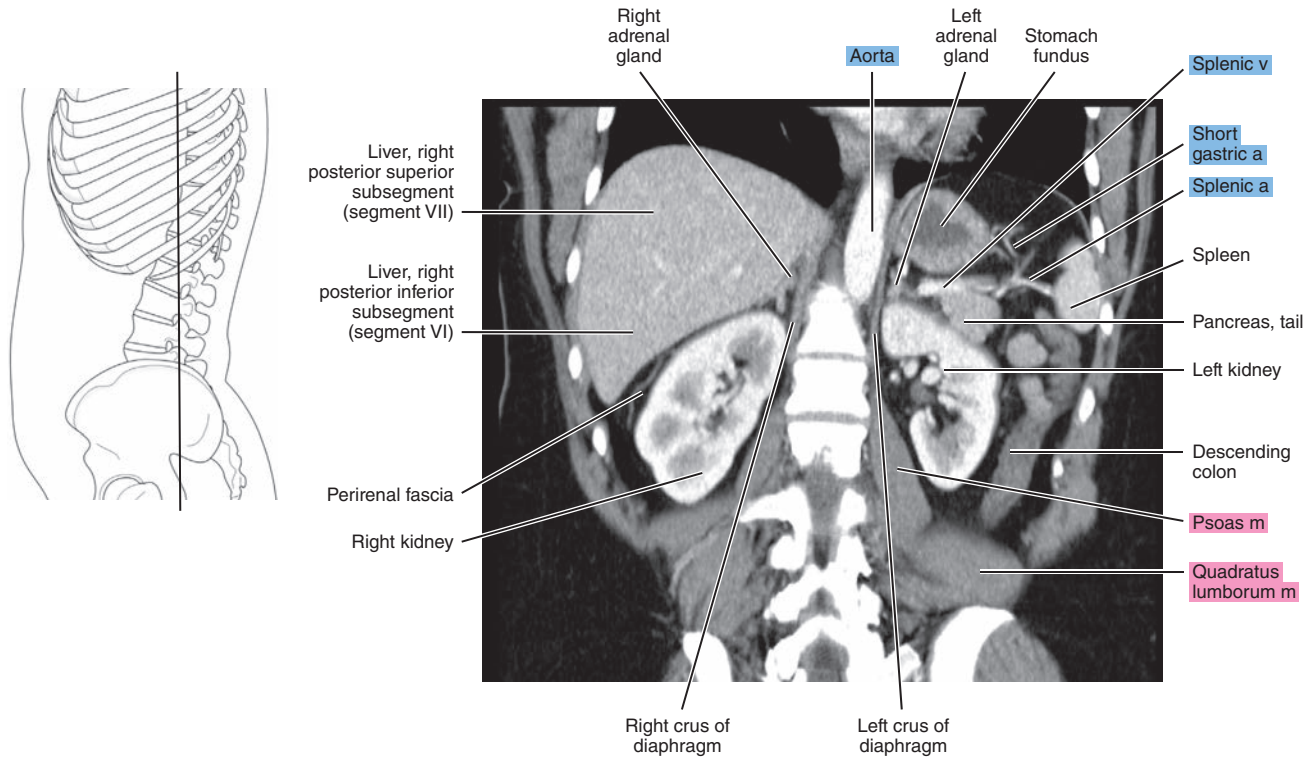




Figure 16.3.11

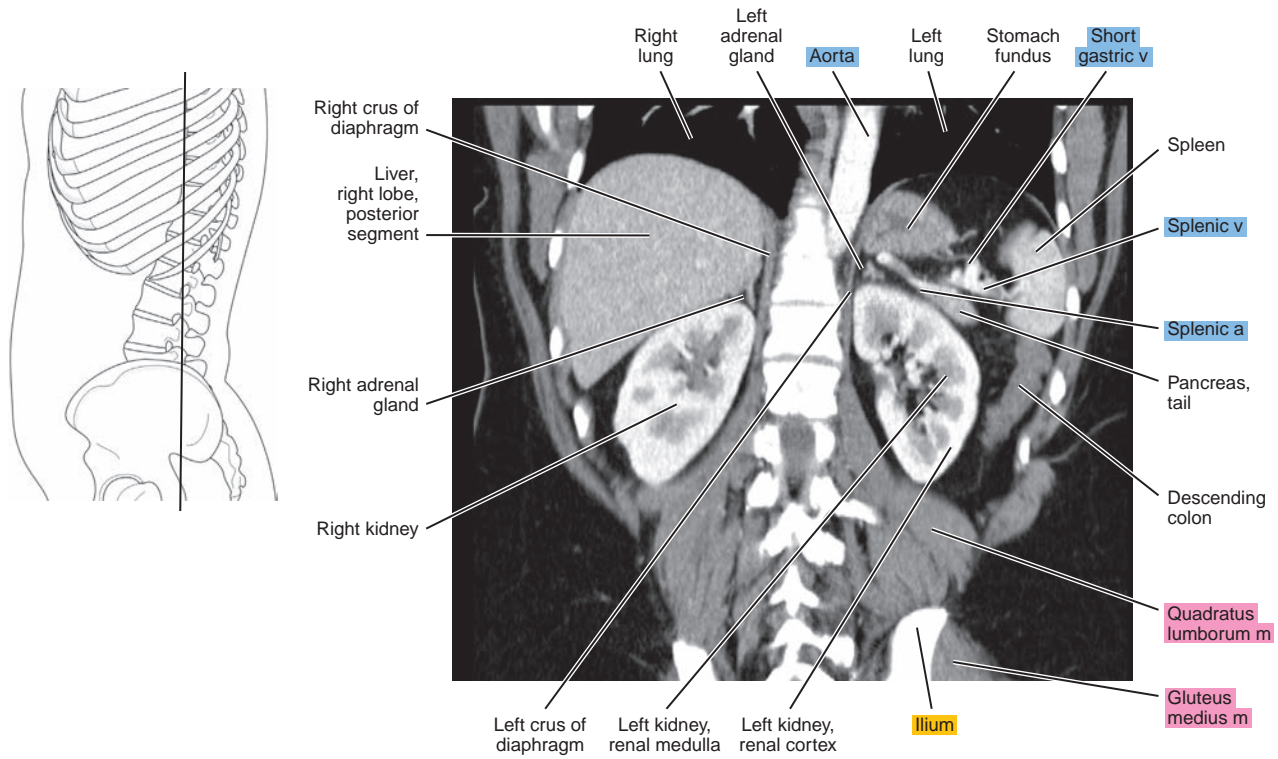
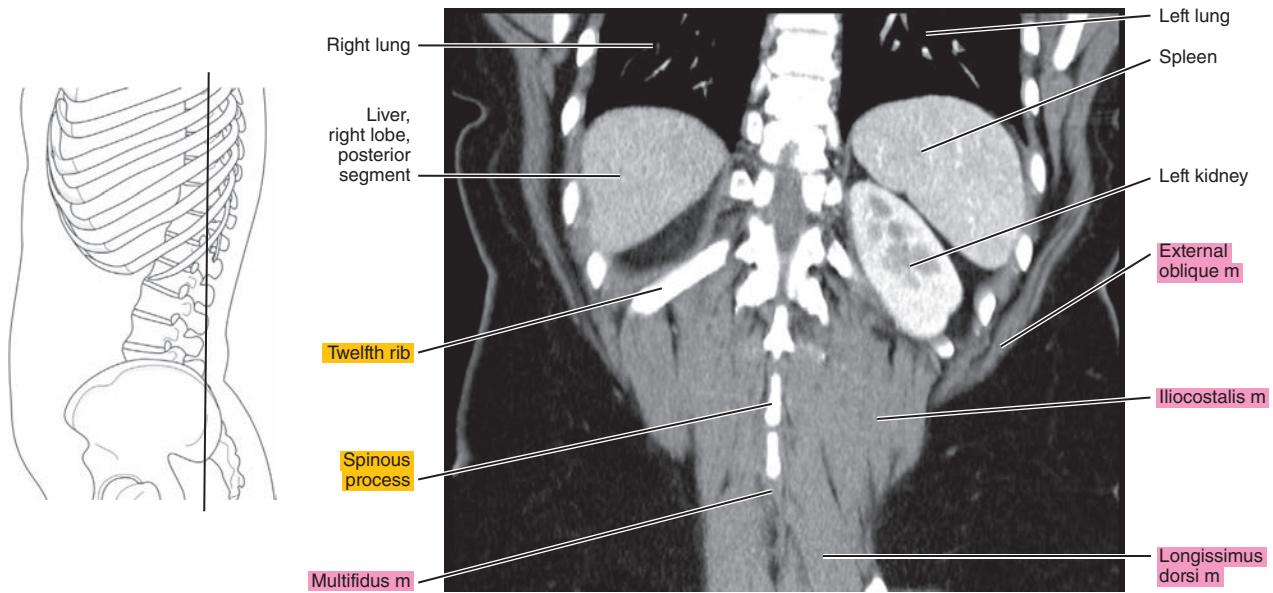


Figure 16.3.12



**Table 16-1. Muscles of the Abdominal Wall**

<b>MUSCLE</b>	<b>ORIGIN</b>	<b>INSERTION</b>	<b>NERVE SUPPLY</b>
<b>Rectus abdominis</b>	Crest and symphysis of the pubis	Xiphoid process and fifth to seventh costal cartilages	Branches of the lower thoracic
<b>External oblique (obliquus externus abdominis)</b>	Fifth to 12th ribs	Anterior half of the iliac crest, inguinal ligament, and anterior layer of the sheath of the rectus abdominis	Ventral branches of the lower thoracic
<b>Internal oblique (obliquus internus abdominis)</b>	Tenth to 12th ribs and sheath of the rectus abdominis; some fibers from the inguinal ligament terminate in the falx inguinalis	Iliac fascia deep to the lateral part of the inguinal ligament, the anterior half of the iliac crest, and the lumbar fascia	Lower thoracic
<b>Transversus abdominis</b>	Seventh to 12th costal cartilages, lumbar fascia, iliac crest, and inguinal ligament	Xiphoid cartilage and linea alba and through the falx inguinalis, pubic tubercle, and pecten pubis	Lower thoracic

*Chapter*  
**17**

**MRI of the Abdomen**

# AXIAL

Figure 17.1.1

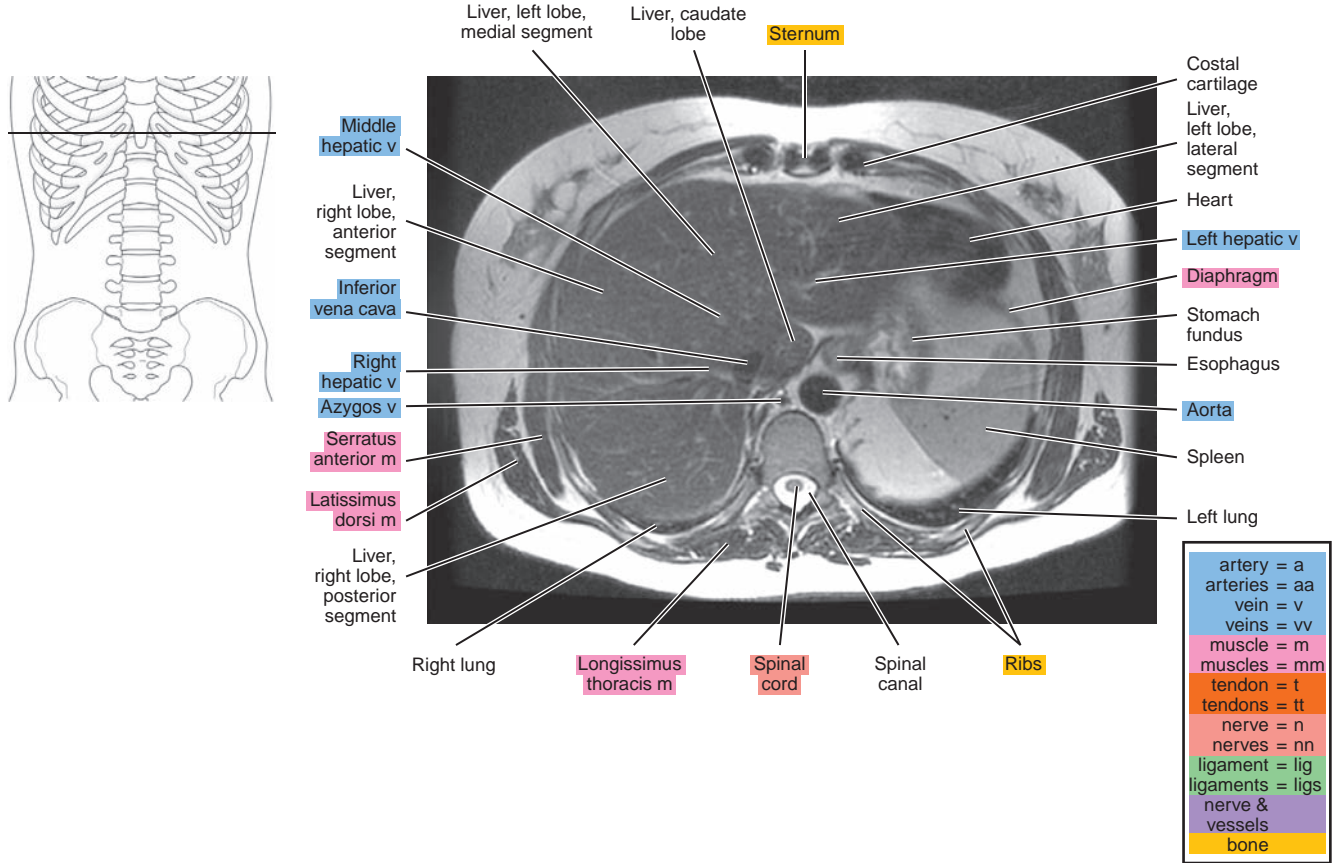


Figure 17.1.2

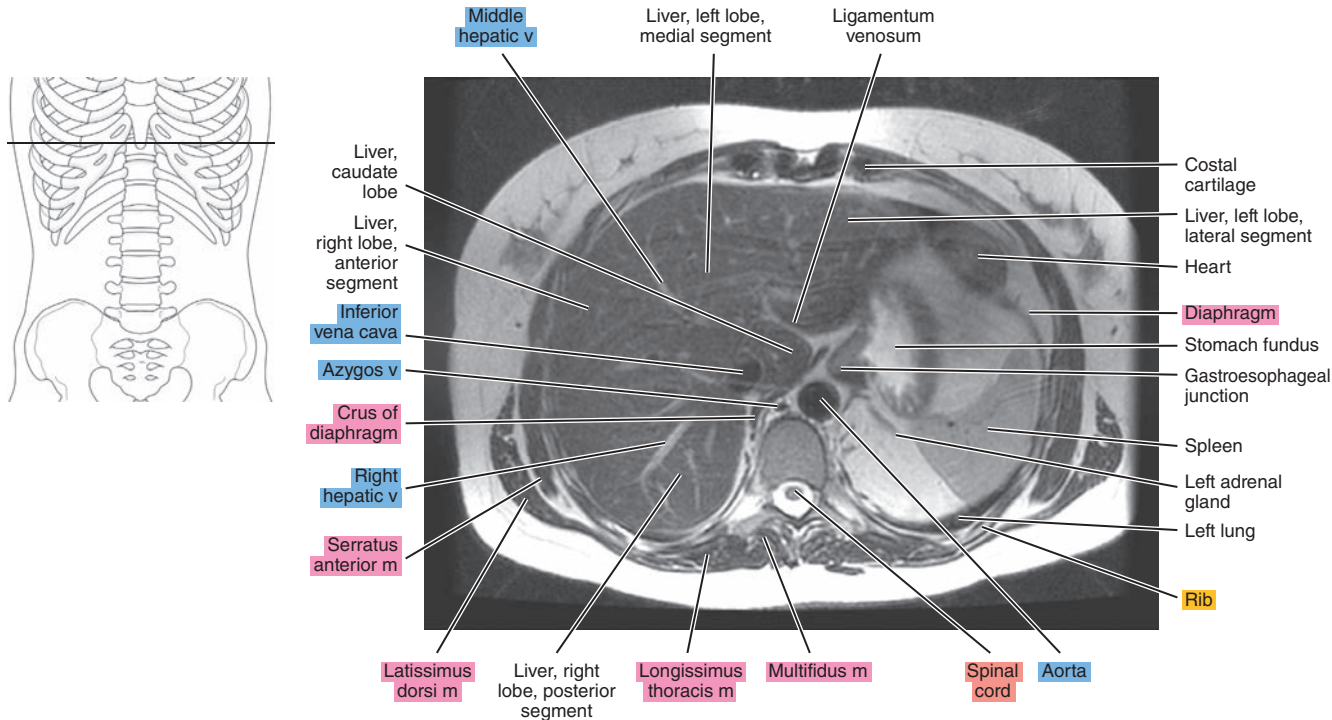




Figure 17.1.3

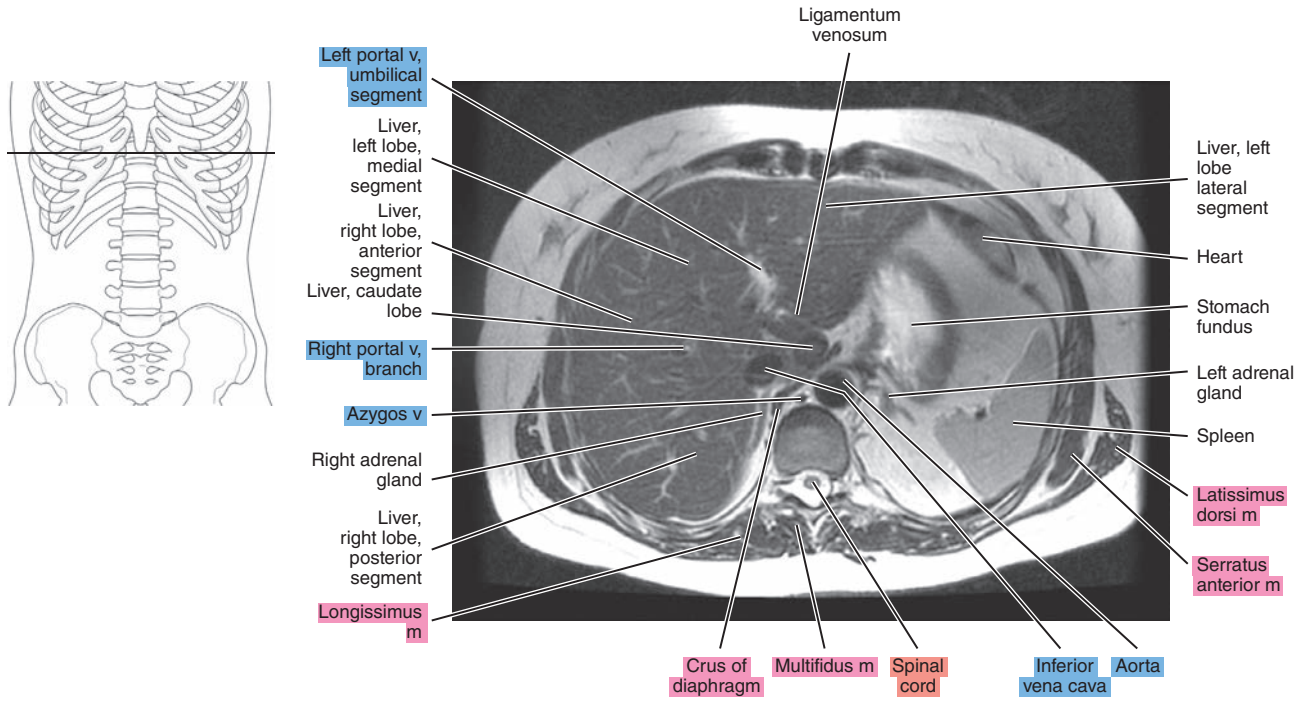


Figure 17.1.4

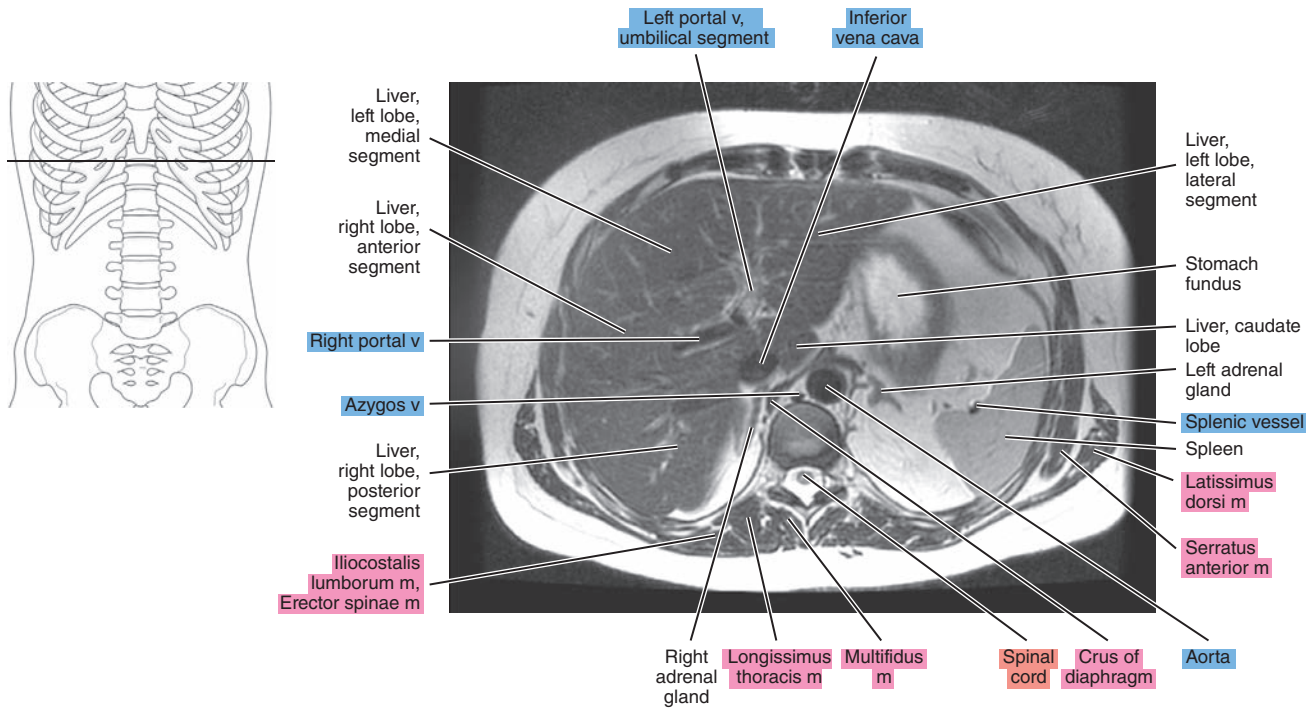


Figure 17.1.5

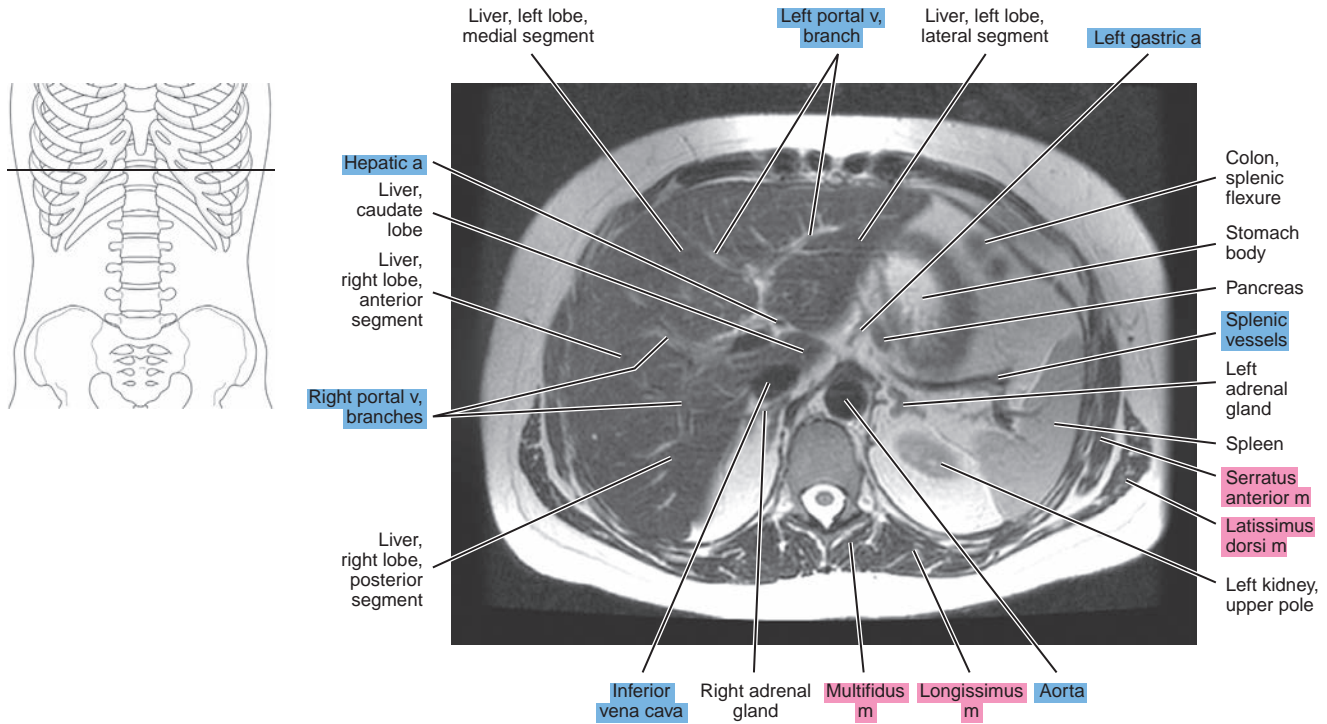


Figure 17.1.6

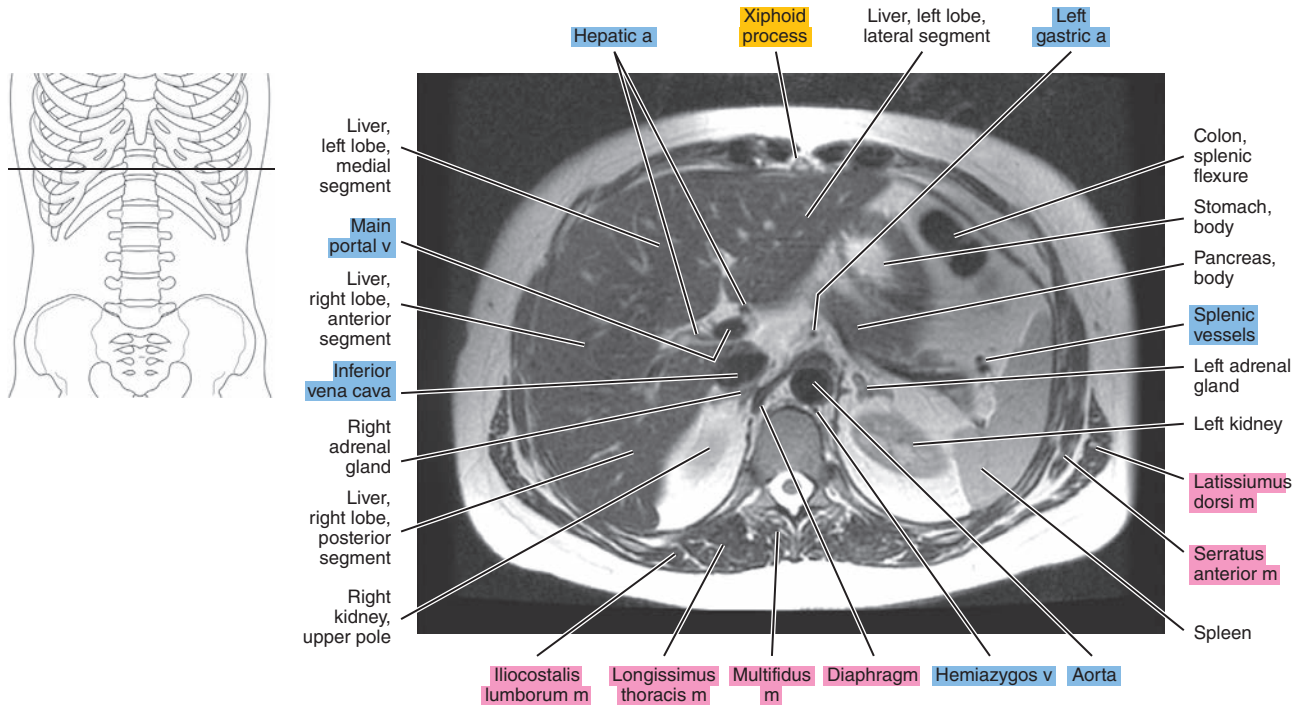




Figure 17.1.7

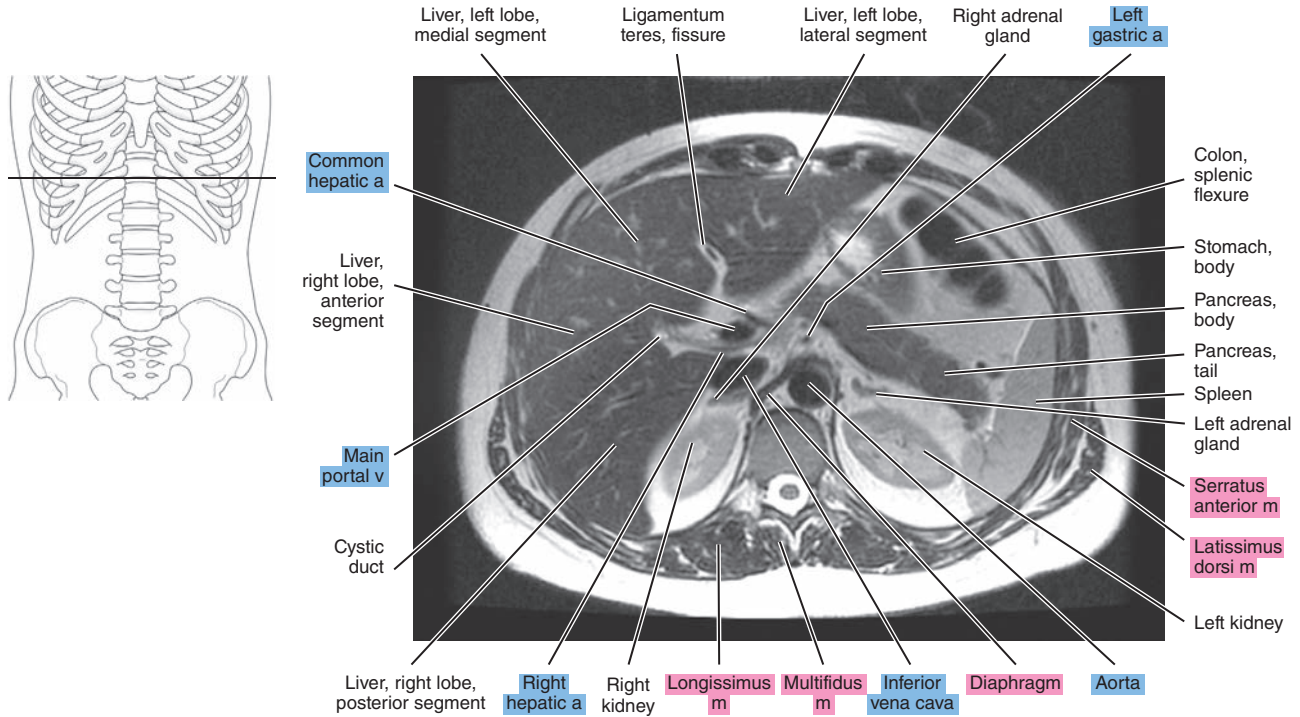


Figure 17.1.8

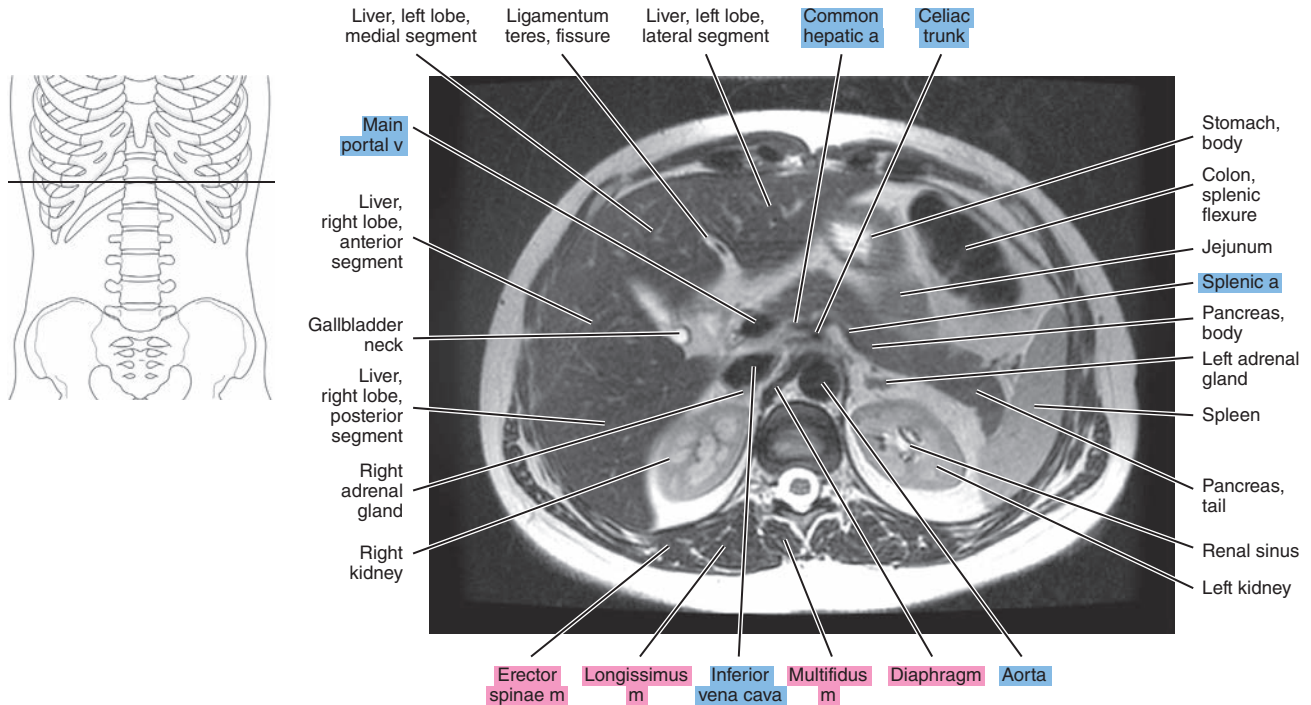


Figure 17.1.9

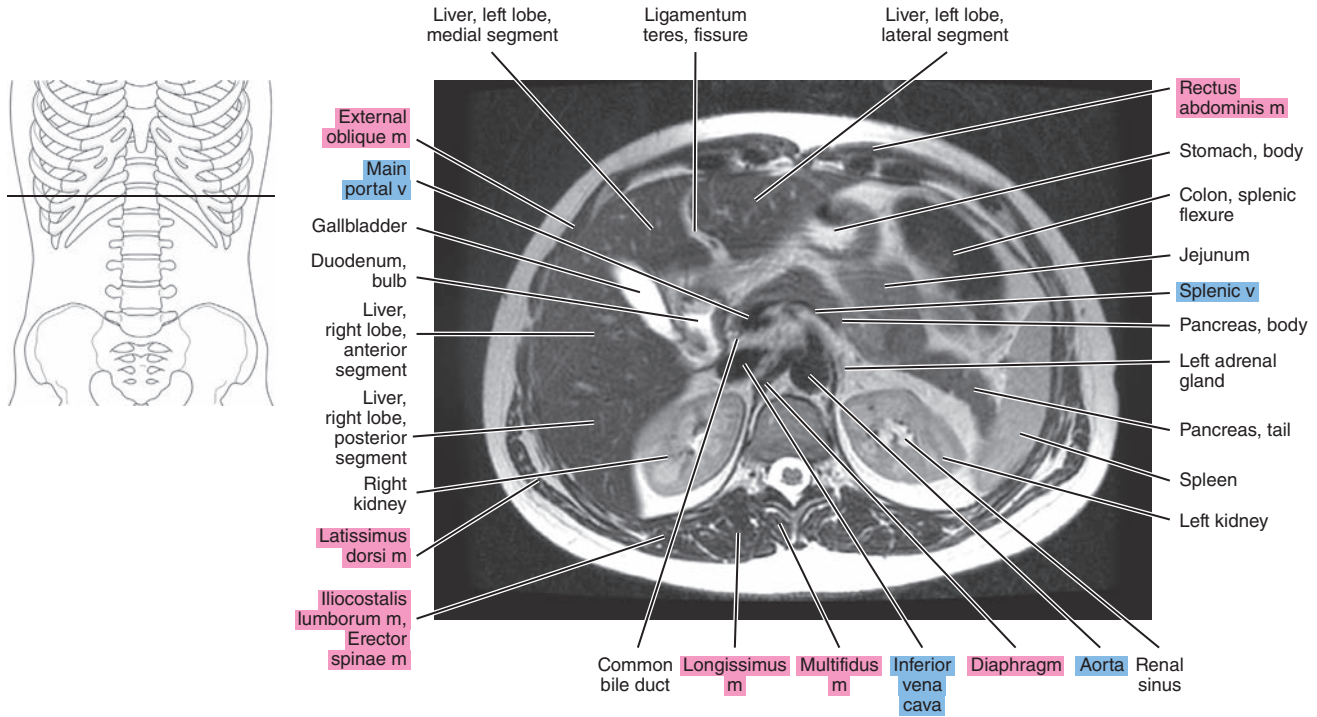


Figure 17.1.10

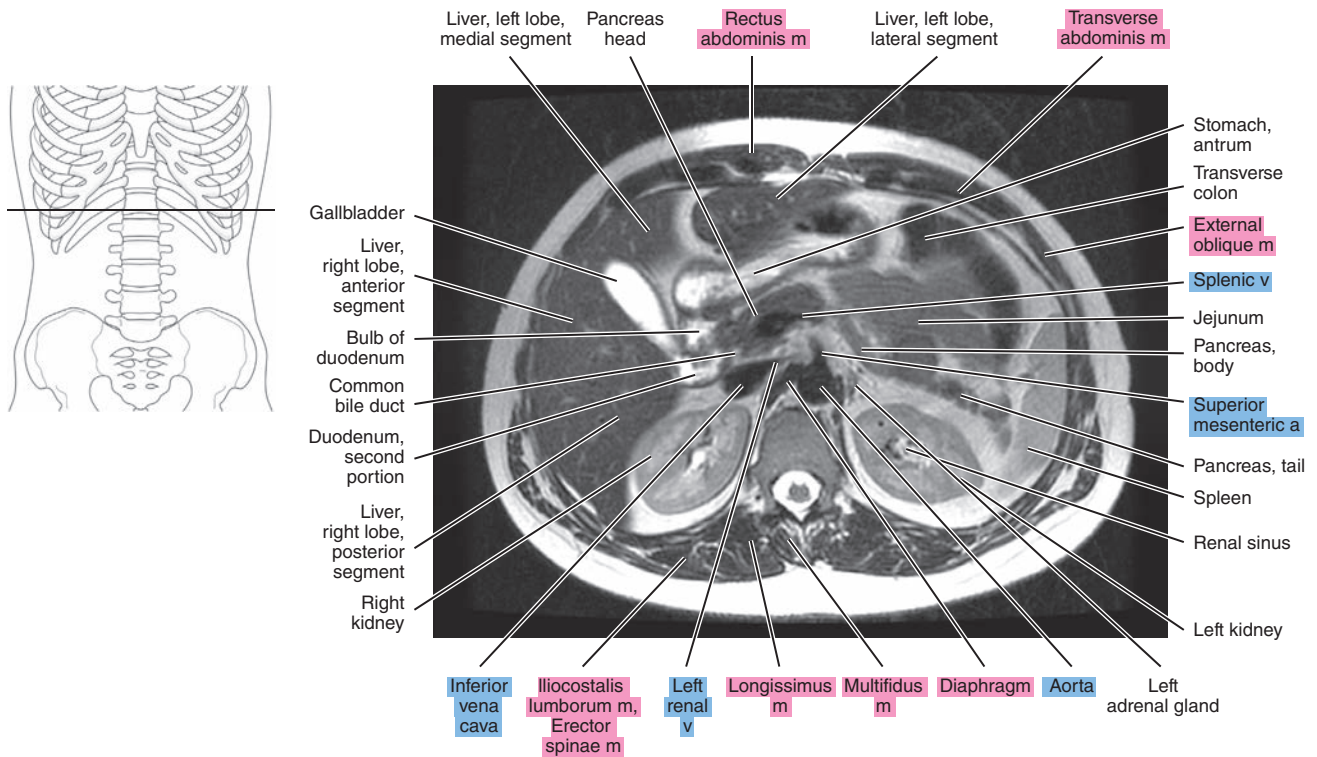




Figure 17.1.11

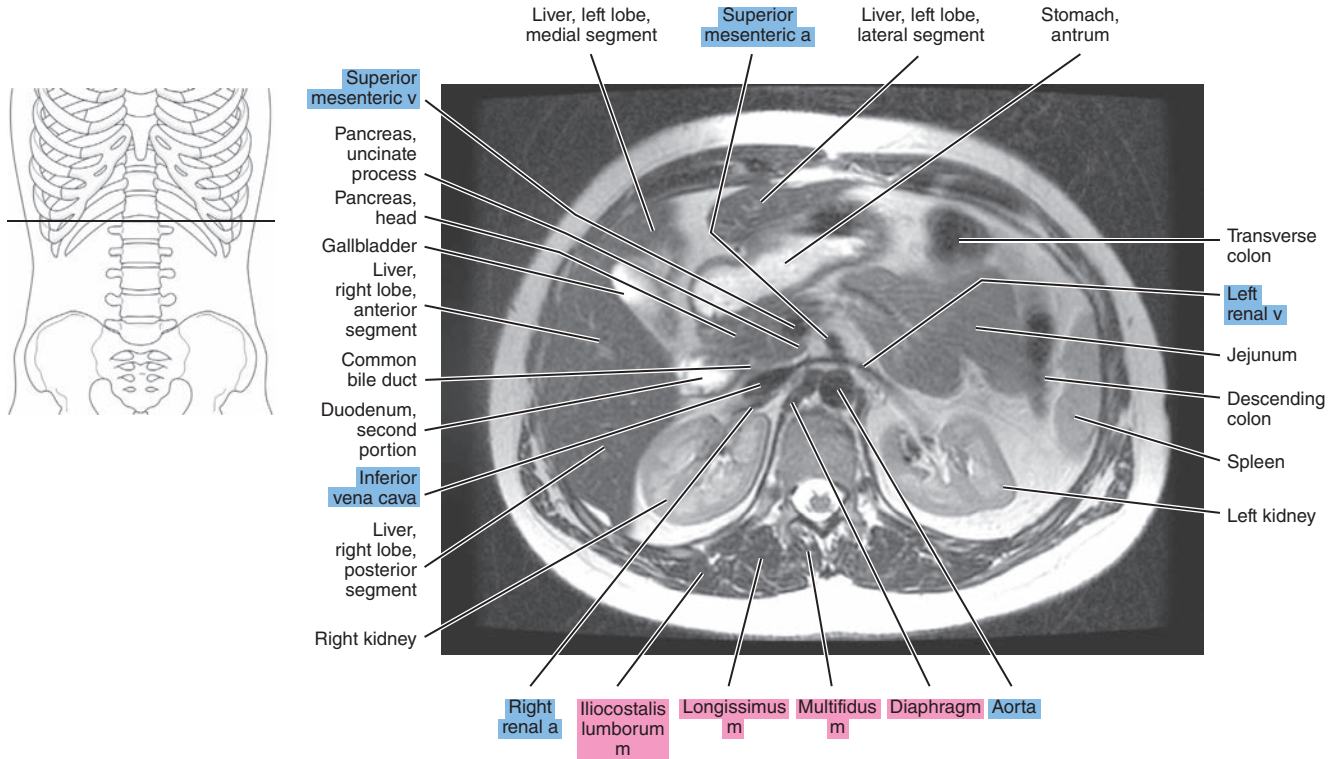


Figure 17.1.12

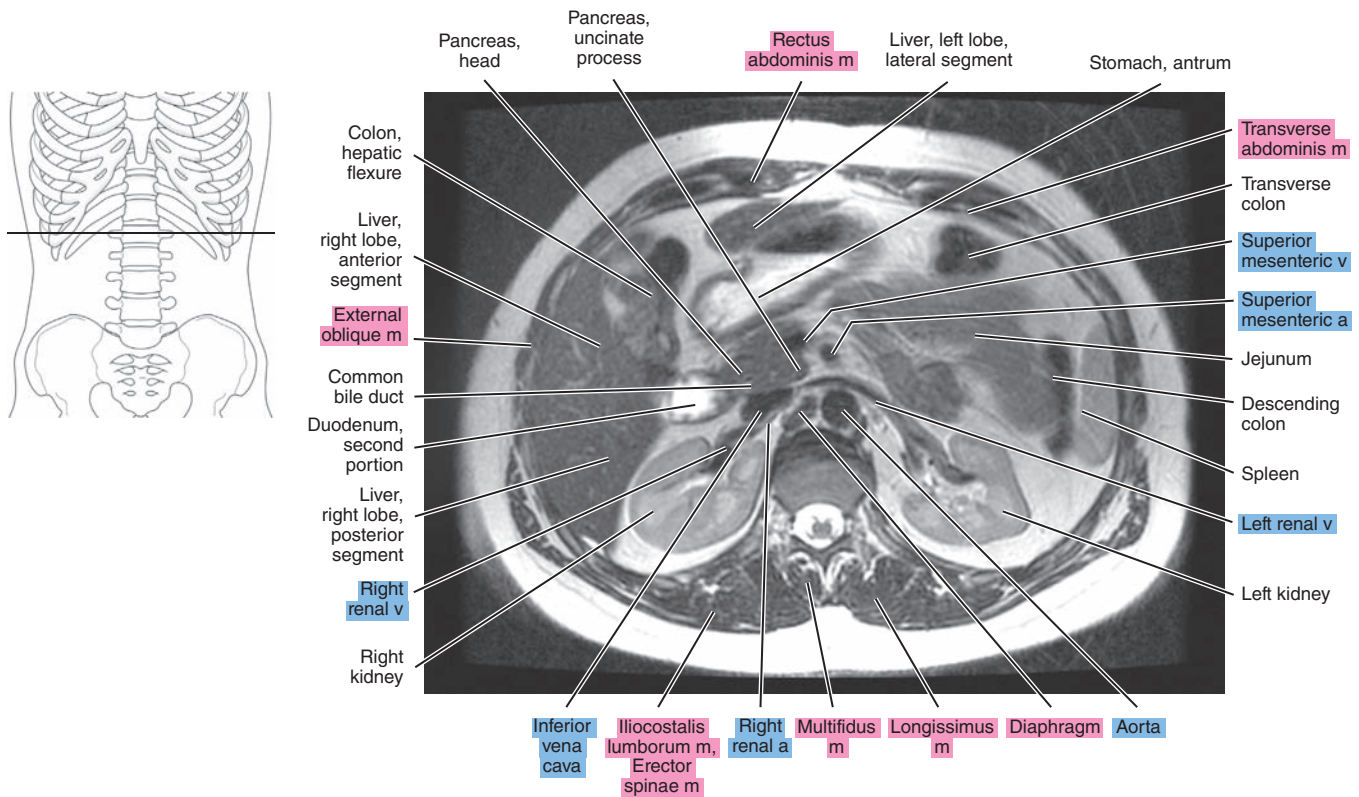


Figure 17.1.13

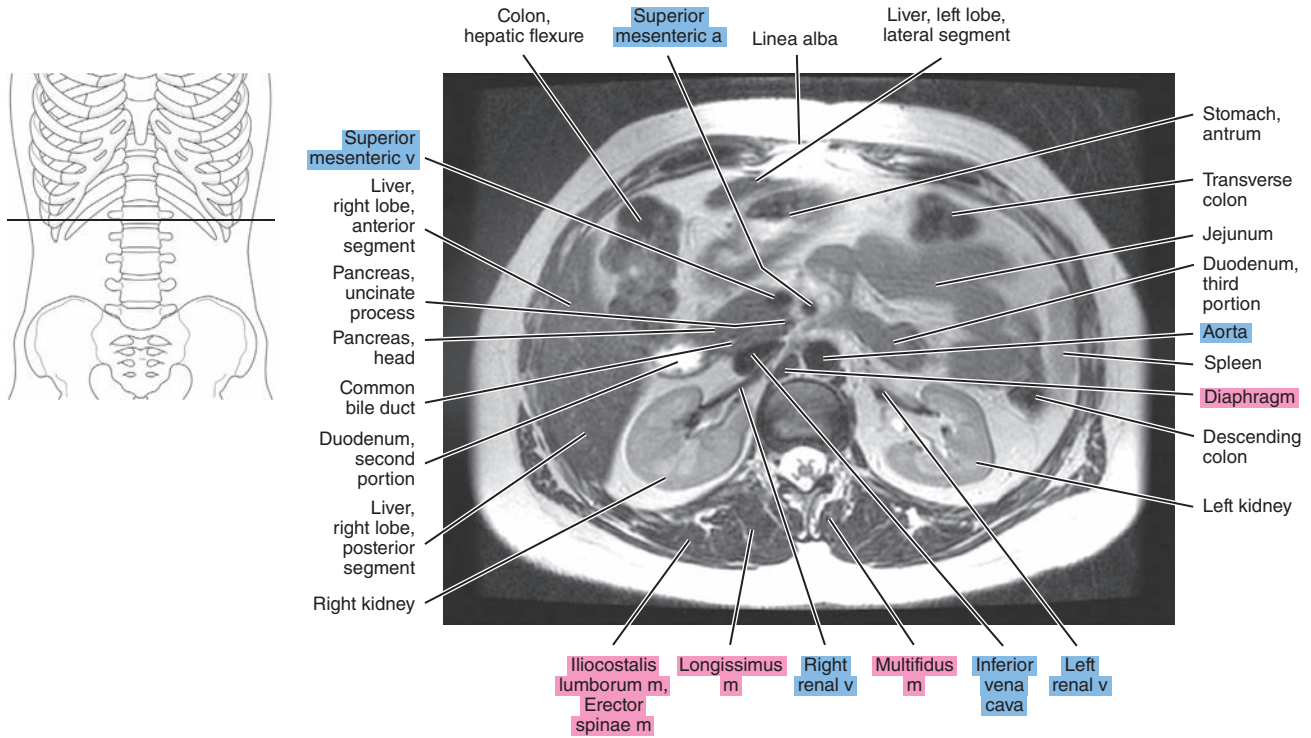


Figure 17.1.14

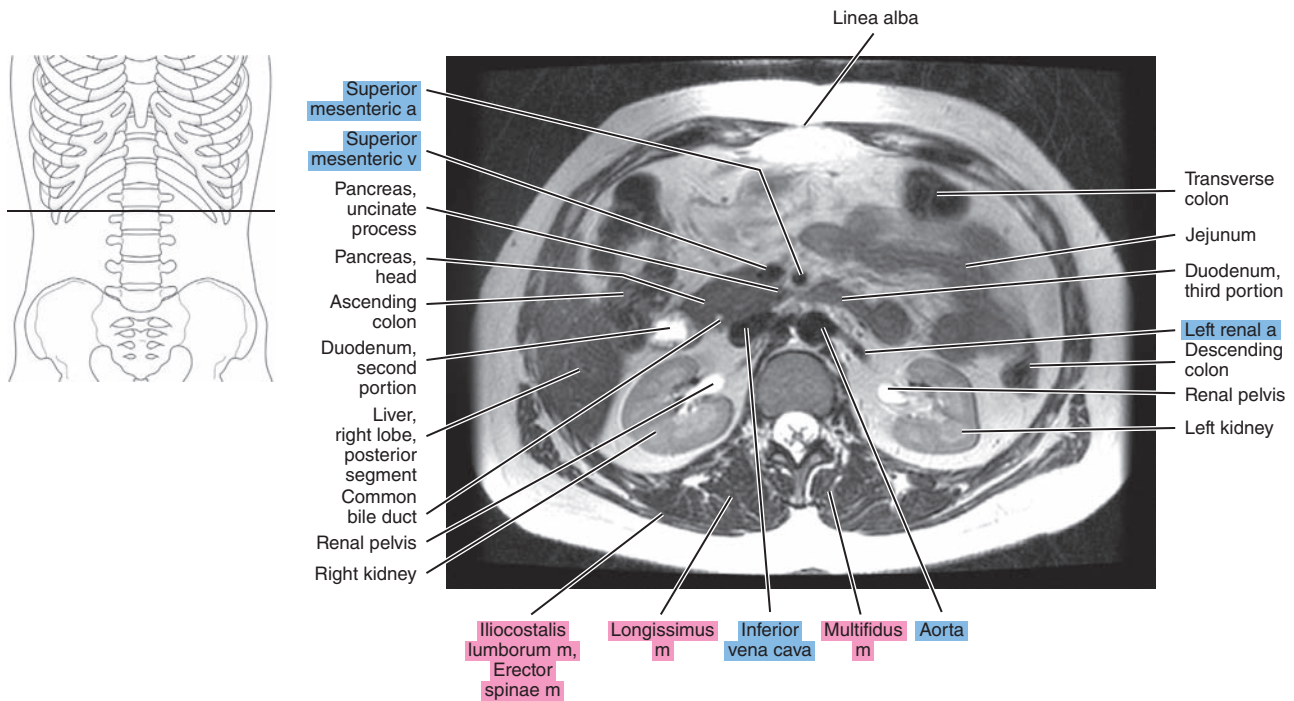




Figure 17.1.15

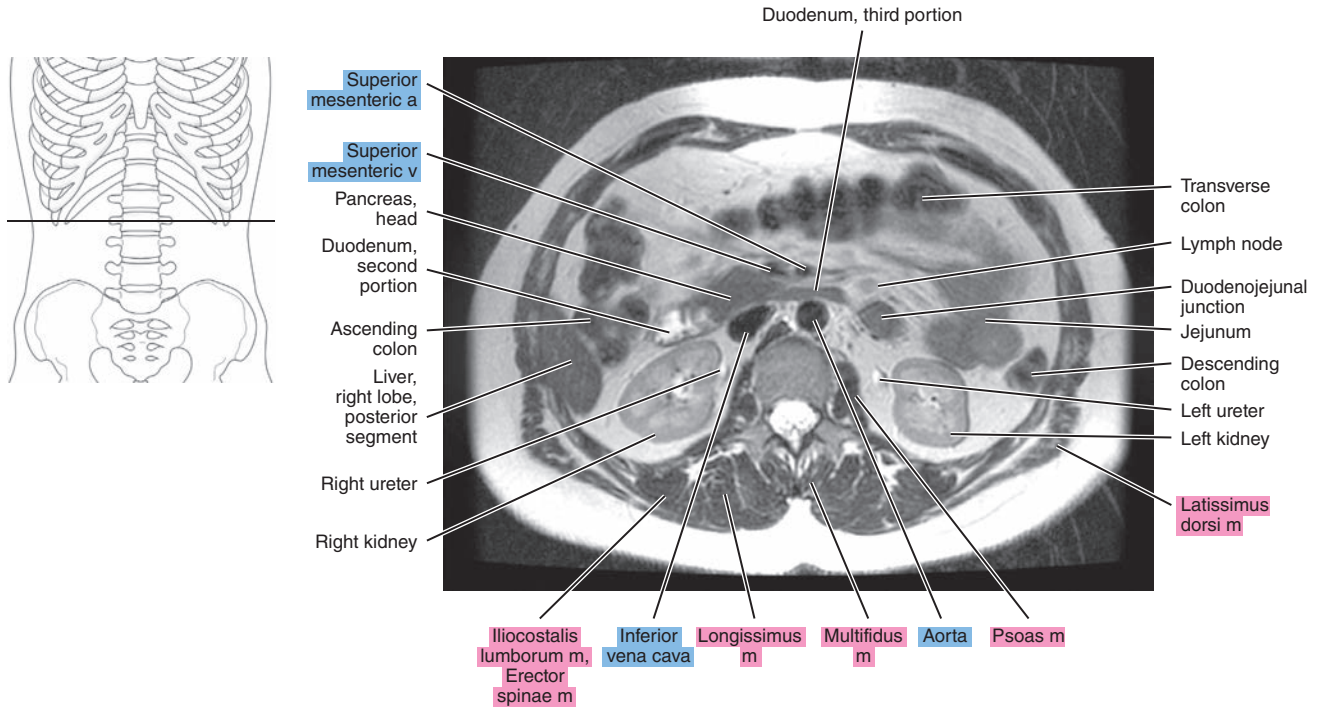
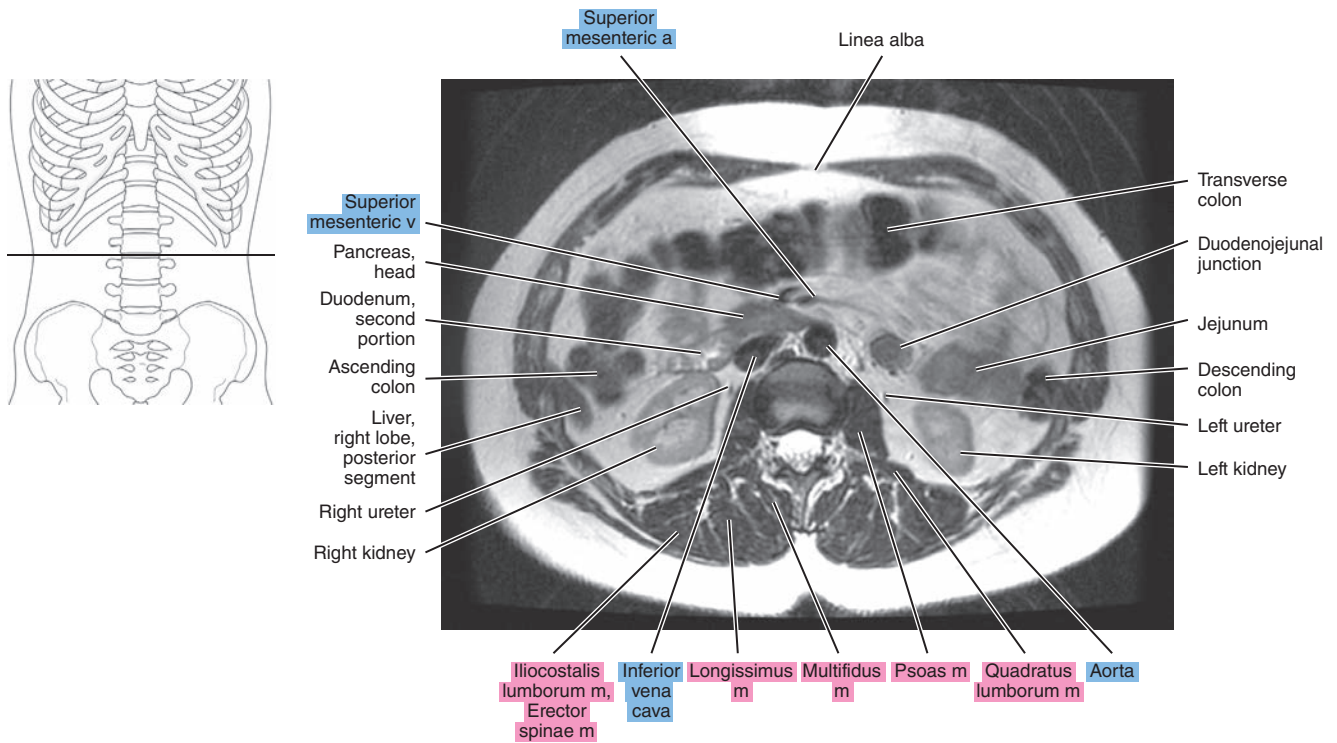


Figure 17.1.16



# SAGITTAL

Figure 17.2.1

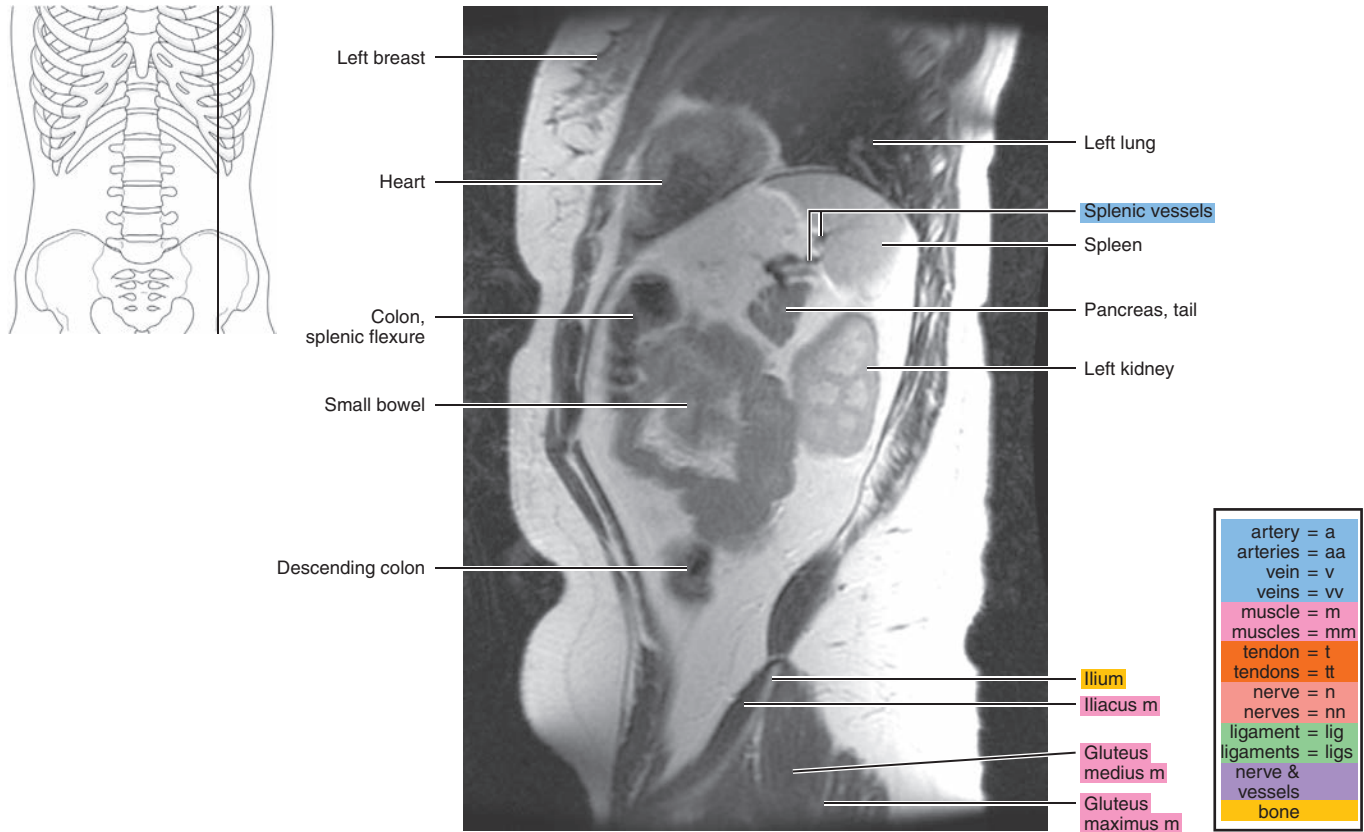


Figure 17.2.2

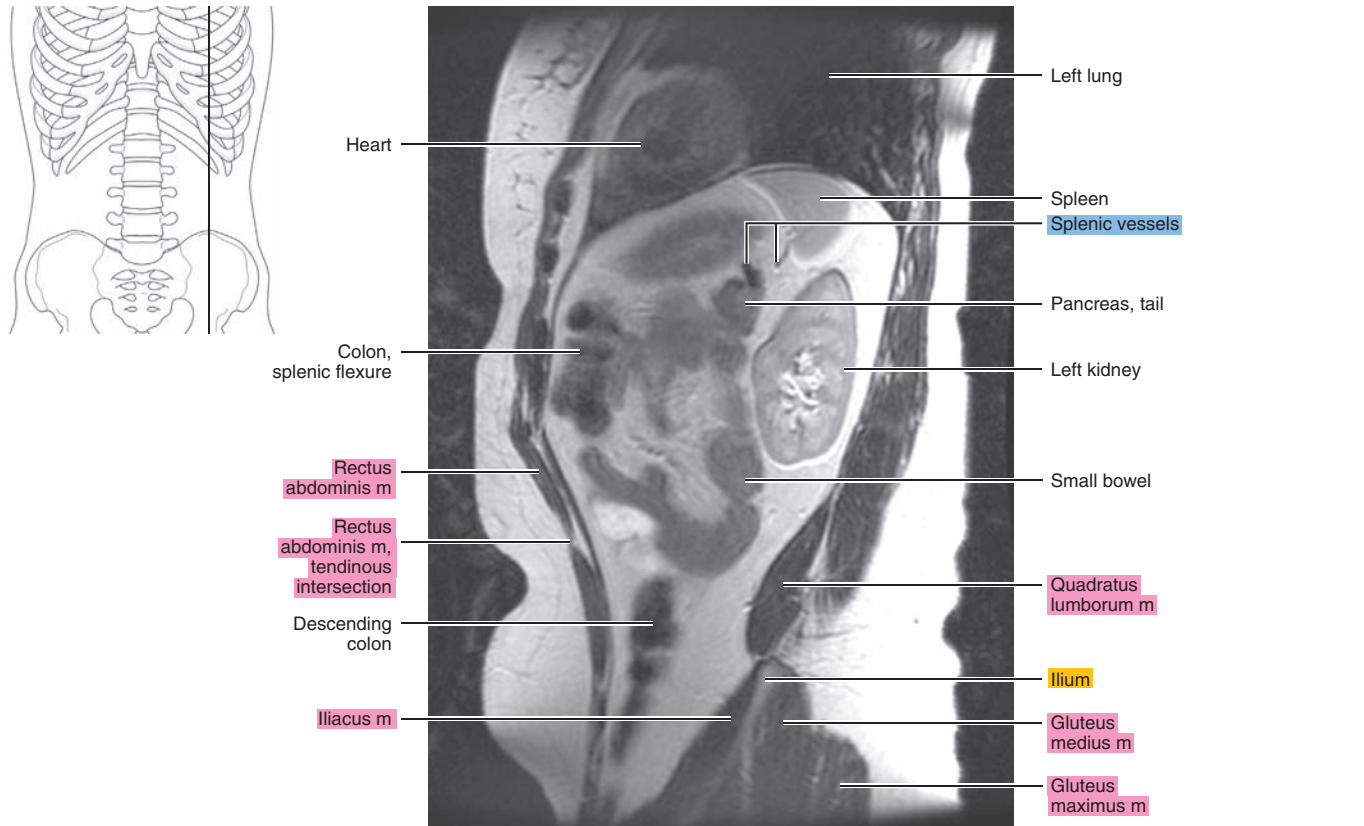




Figure 17.2.3

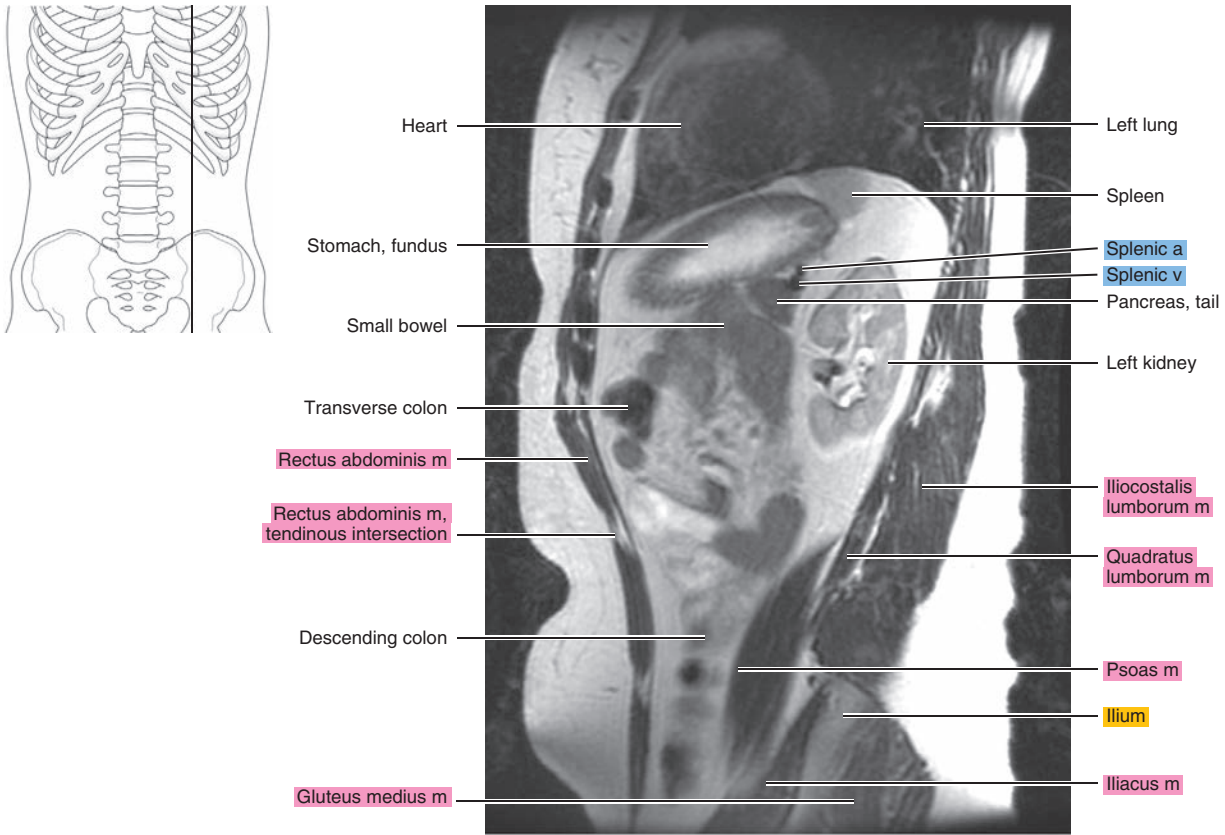


Figure 17.2.4

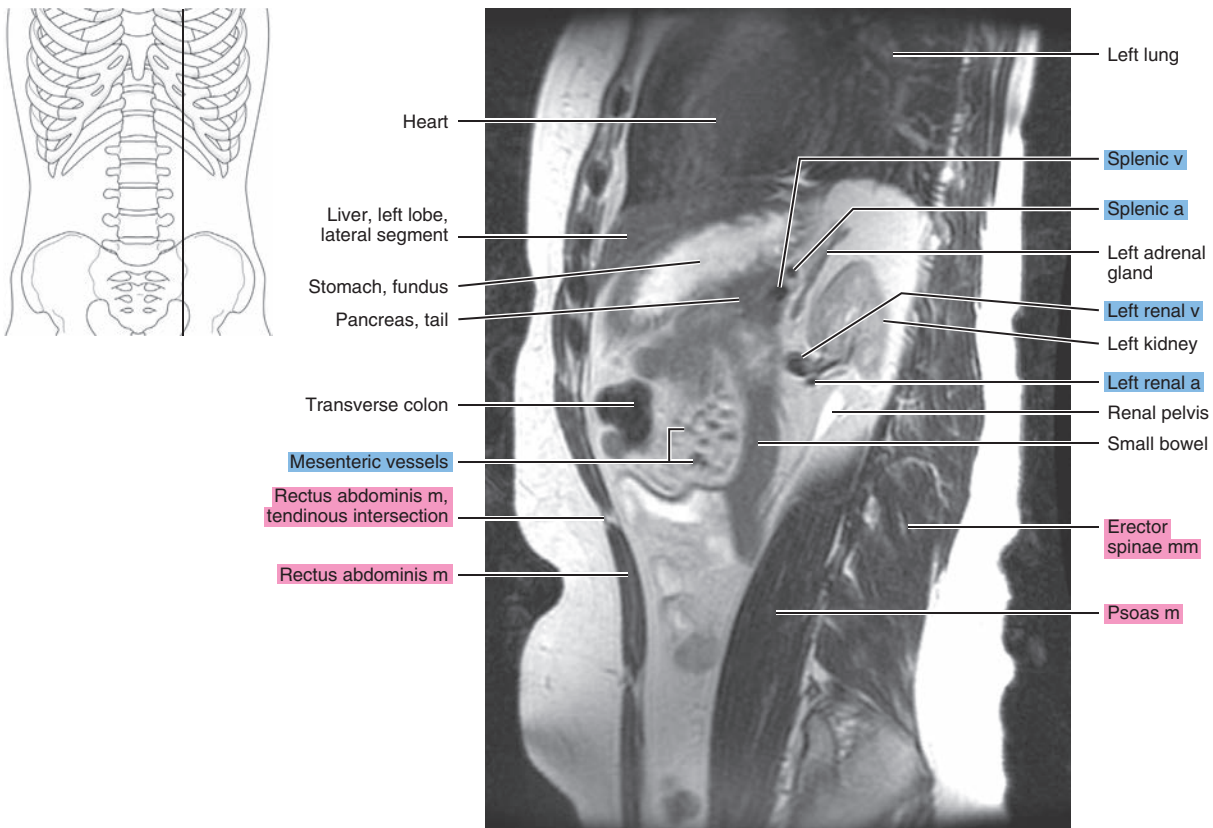


Figure 17.2.5

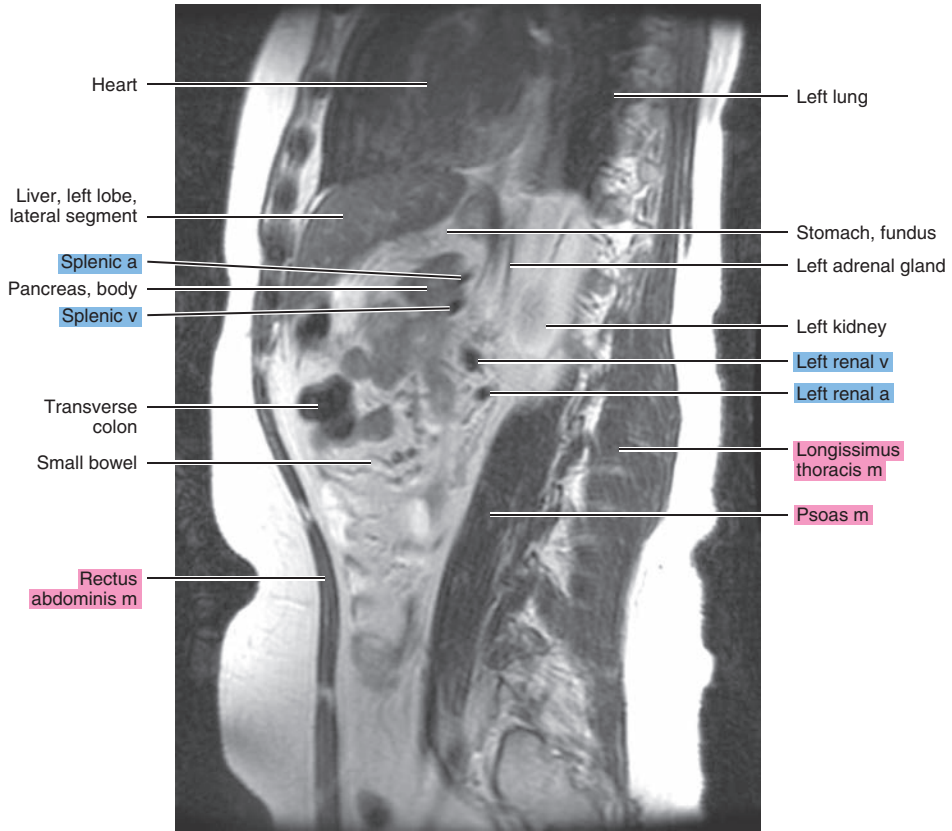
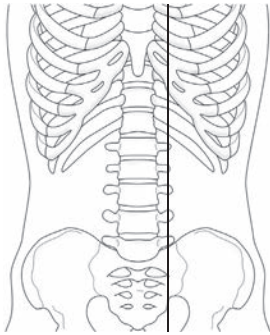


Figure 17.2.6

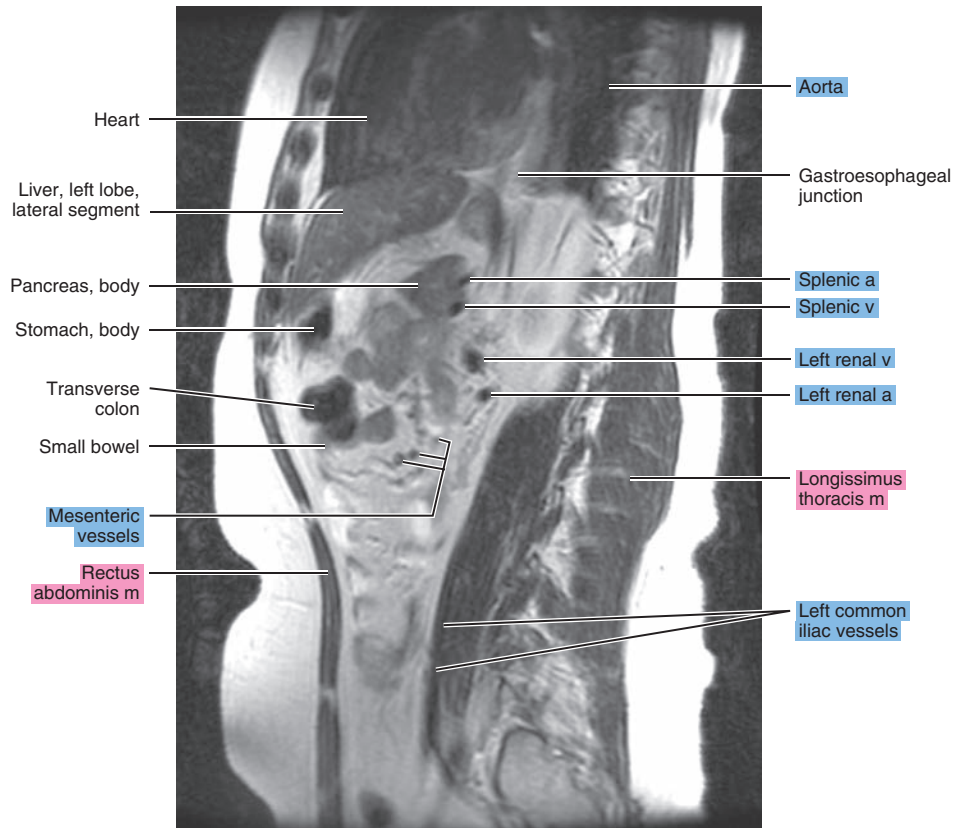
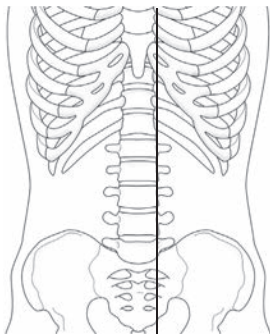


Figure 17.2.7

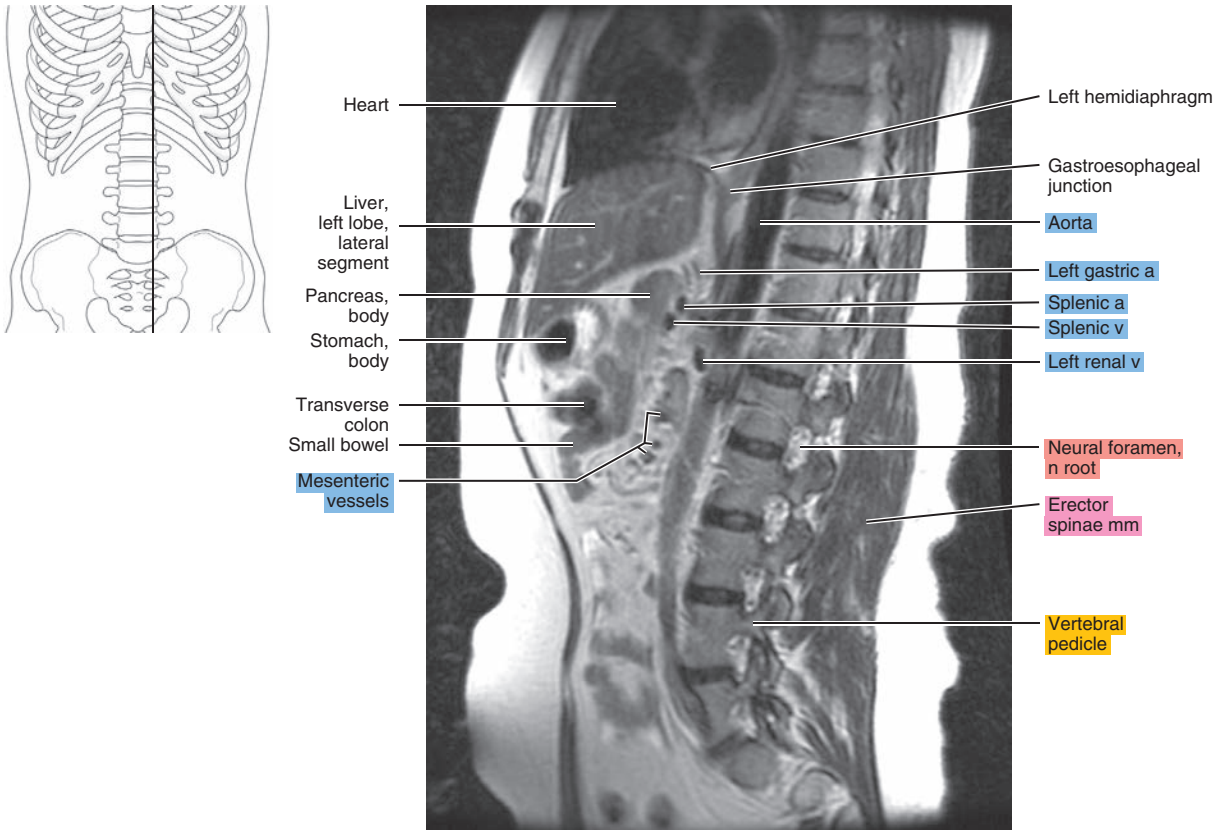


Figure 17.2.8

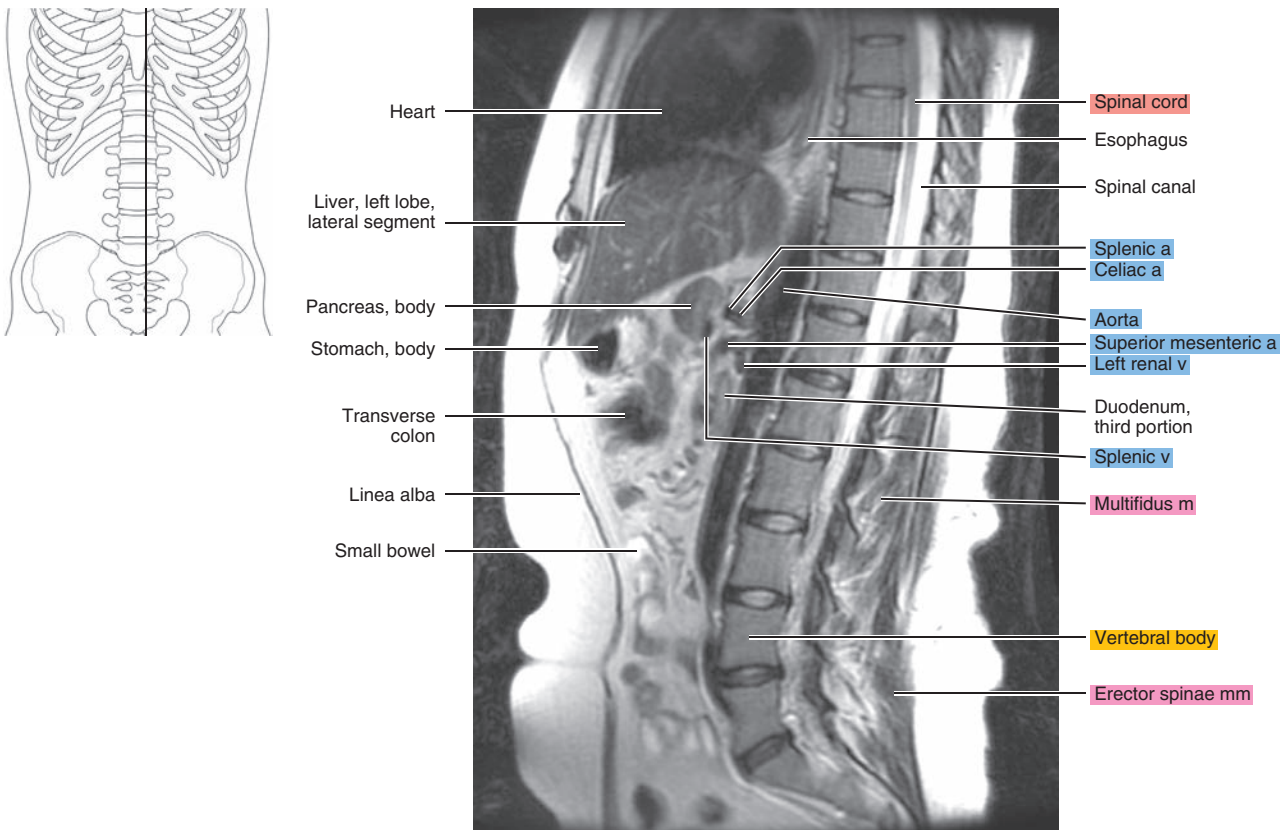




Figure 17.2.9

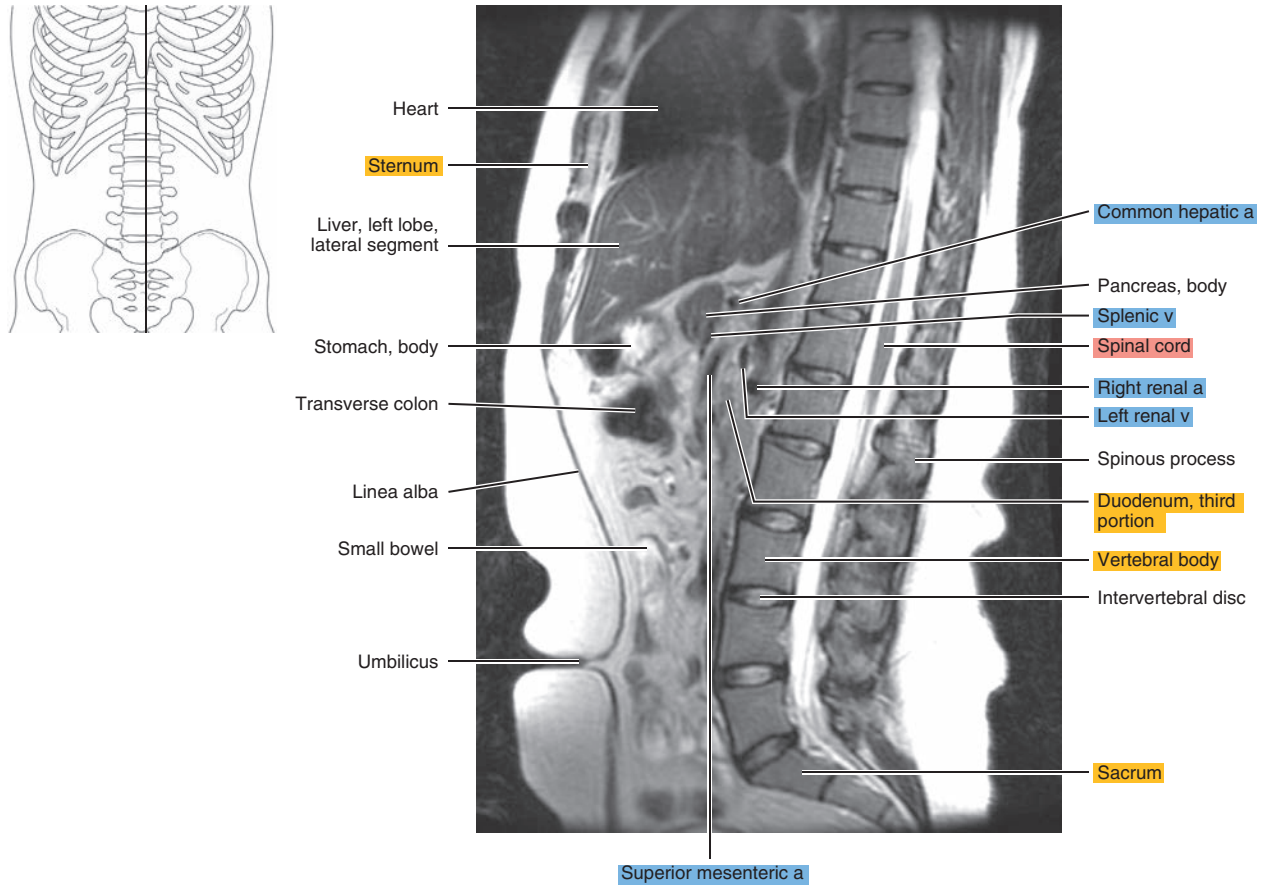


Figure 17.2.10

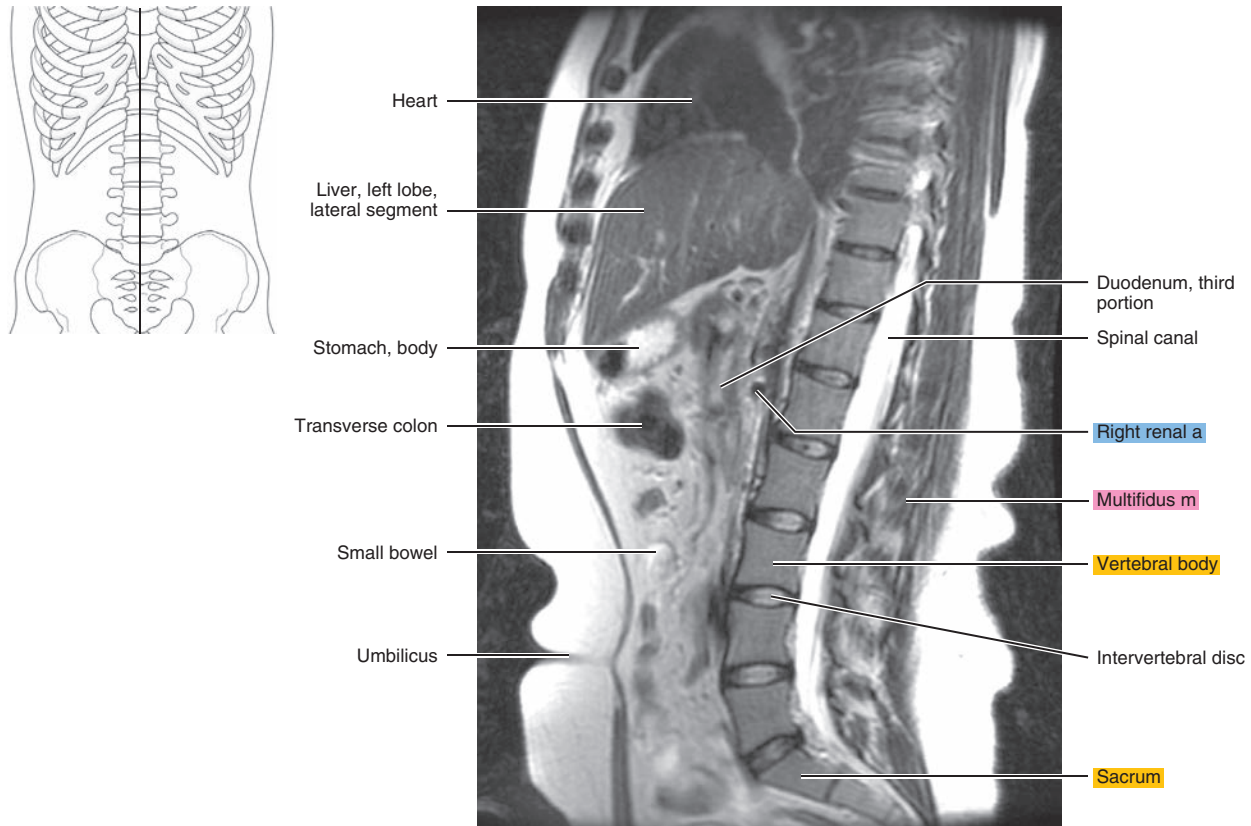




Figure 17.2.11

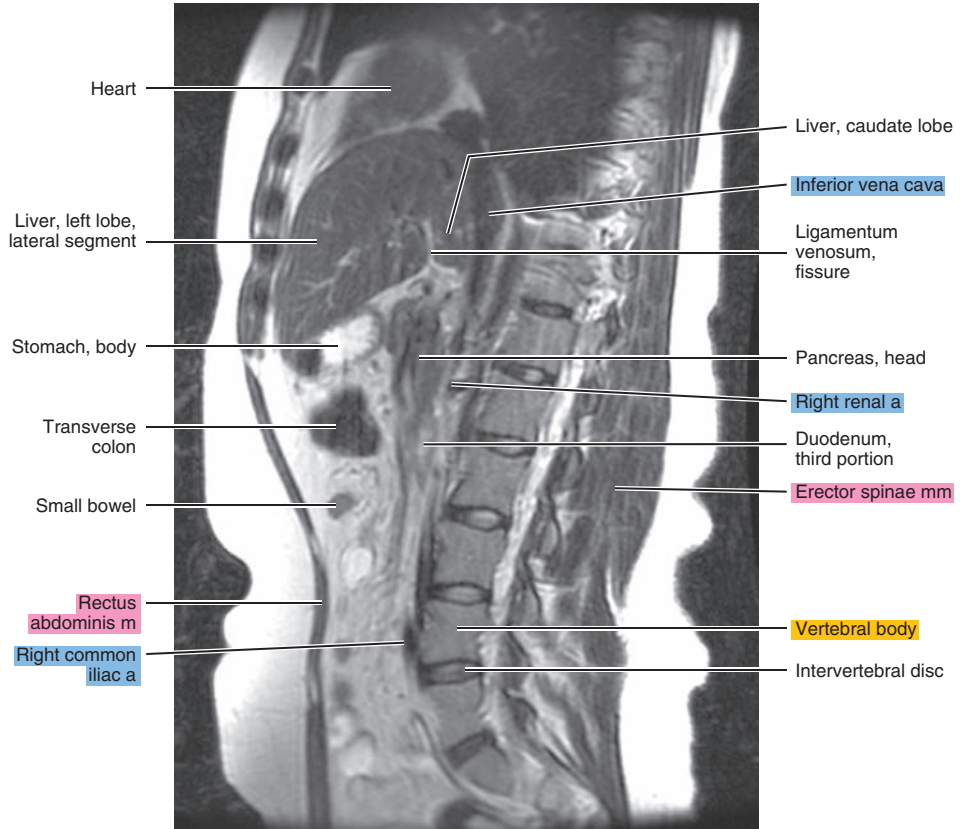
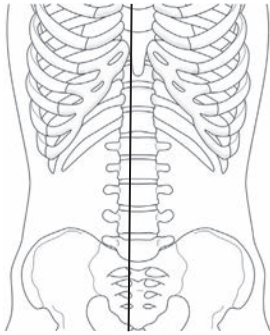


Figure 17.2.12

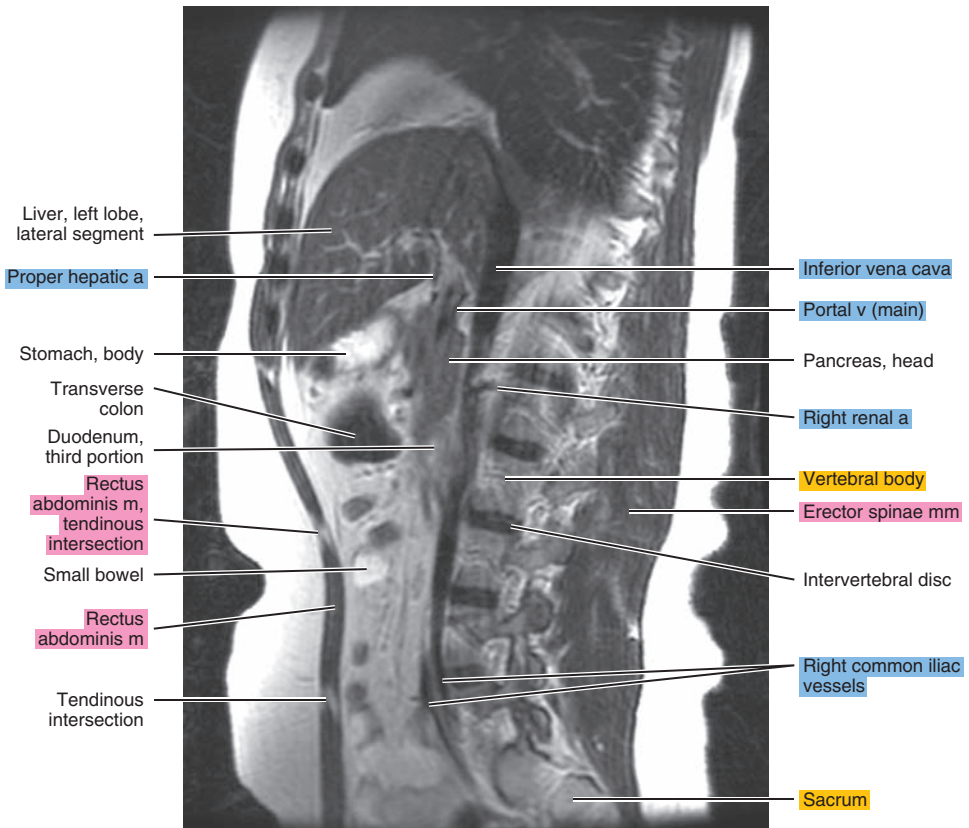
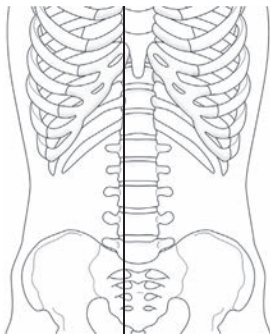


Figure 17.2.13

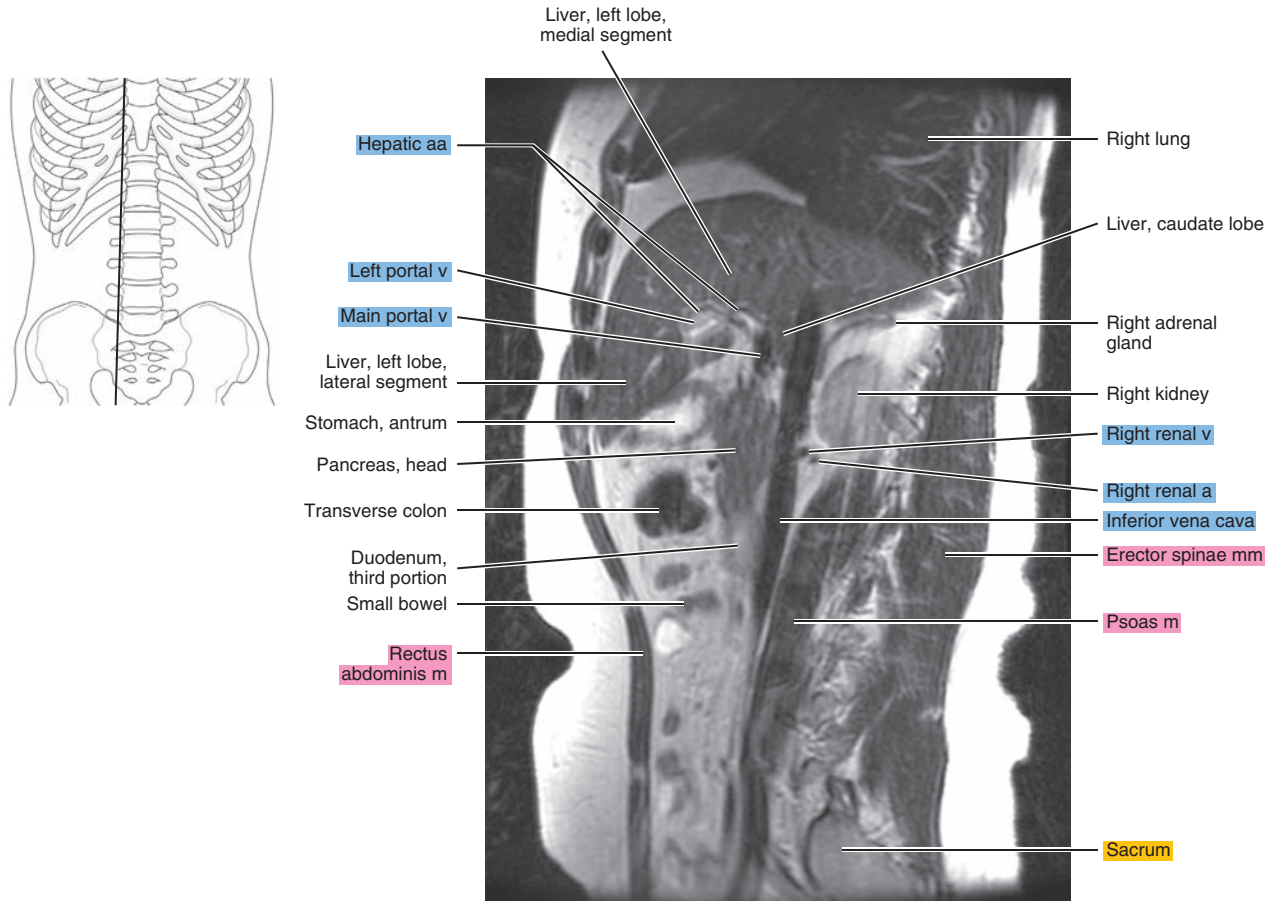


Figure 17.2.14

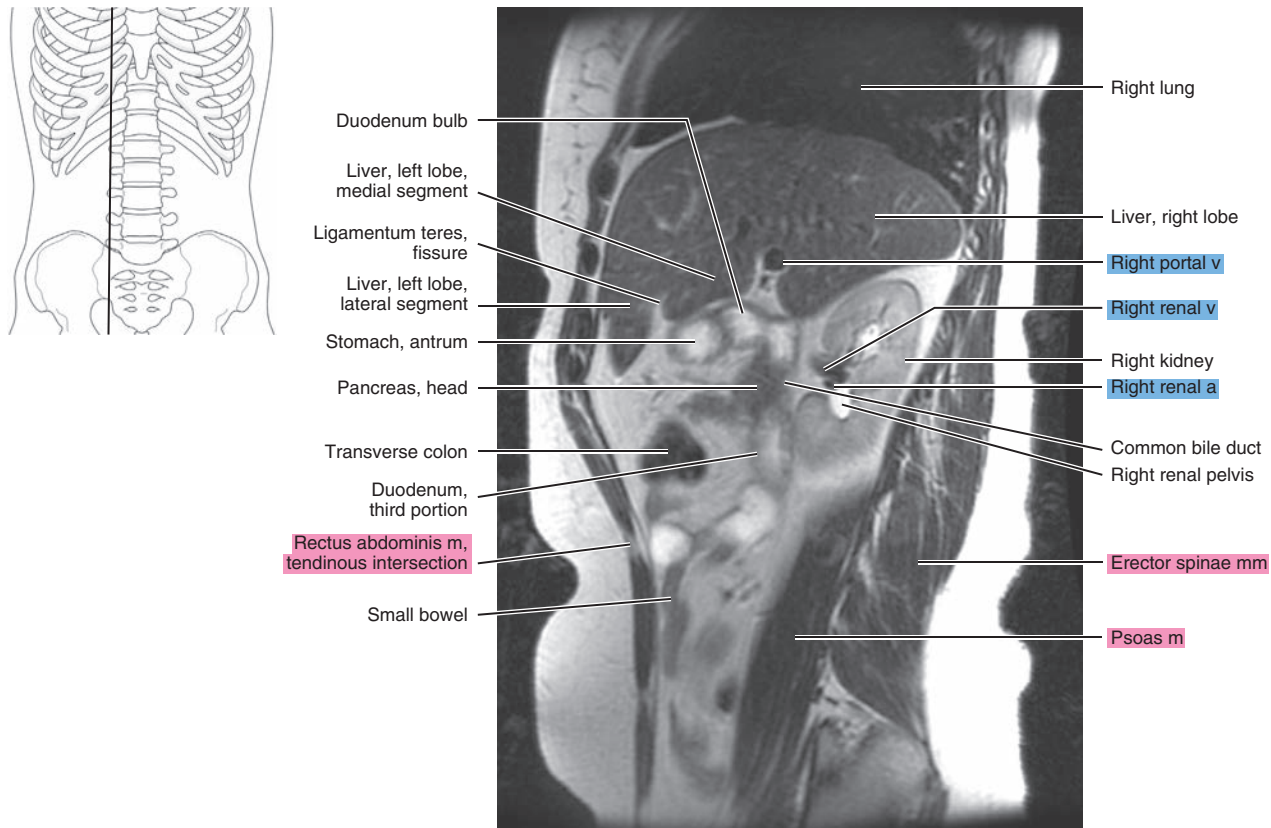

Figure 17.2.15

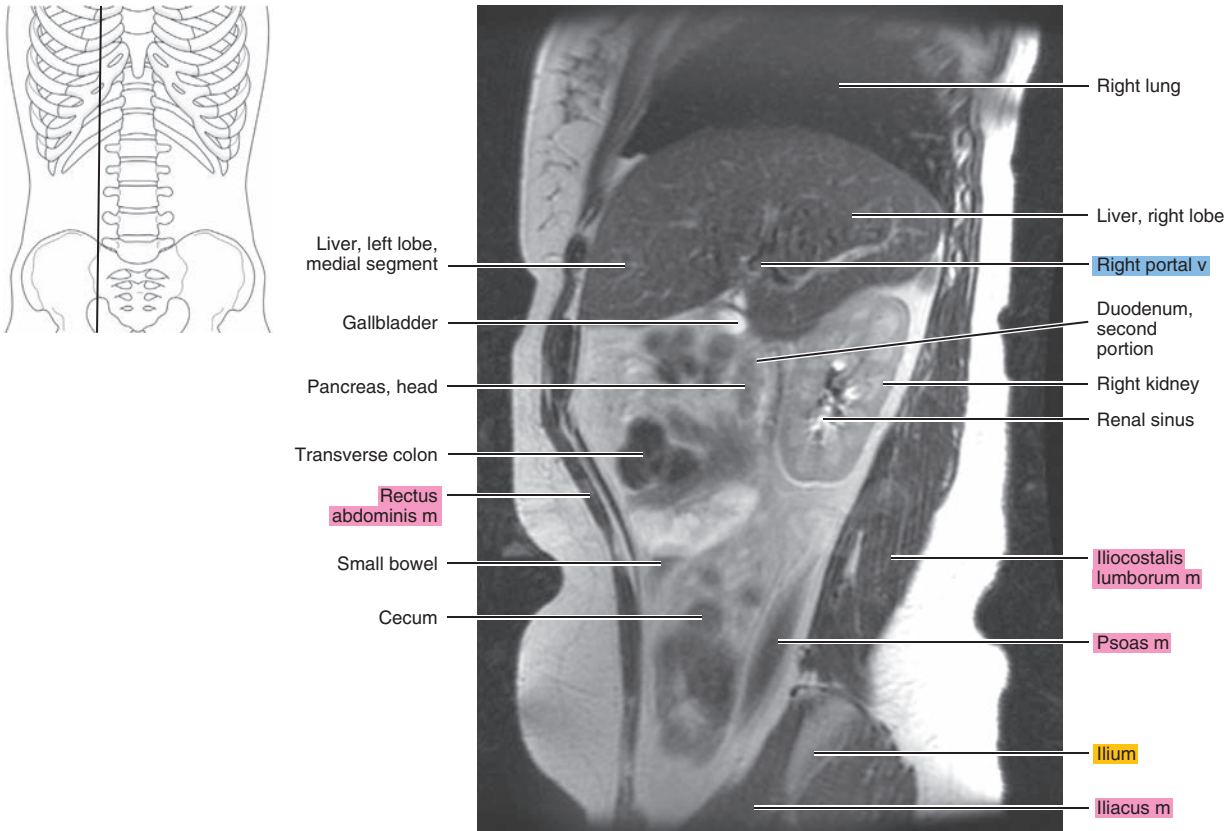
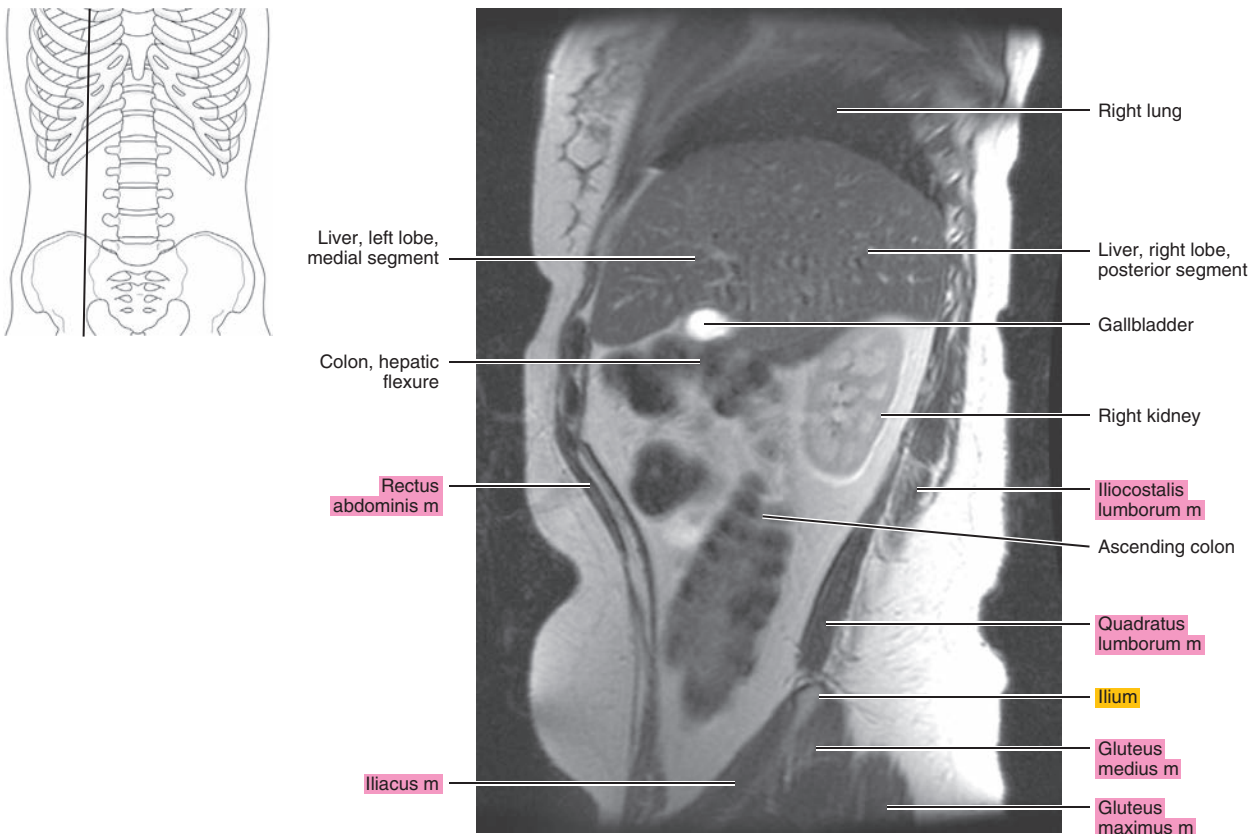


Figure 17.2.16





# CORONAL

Figure 17.3.1

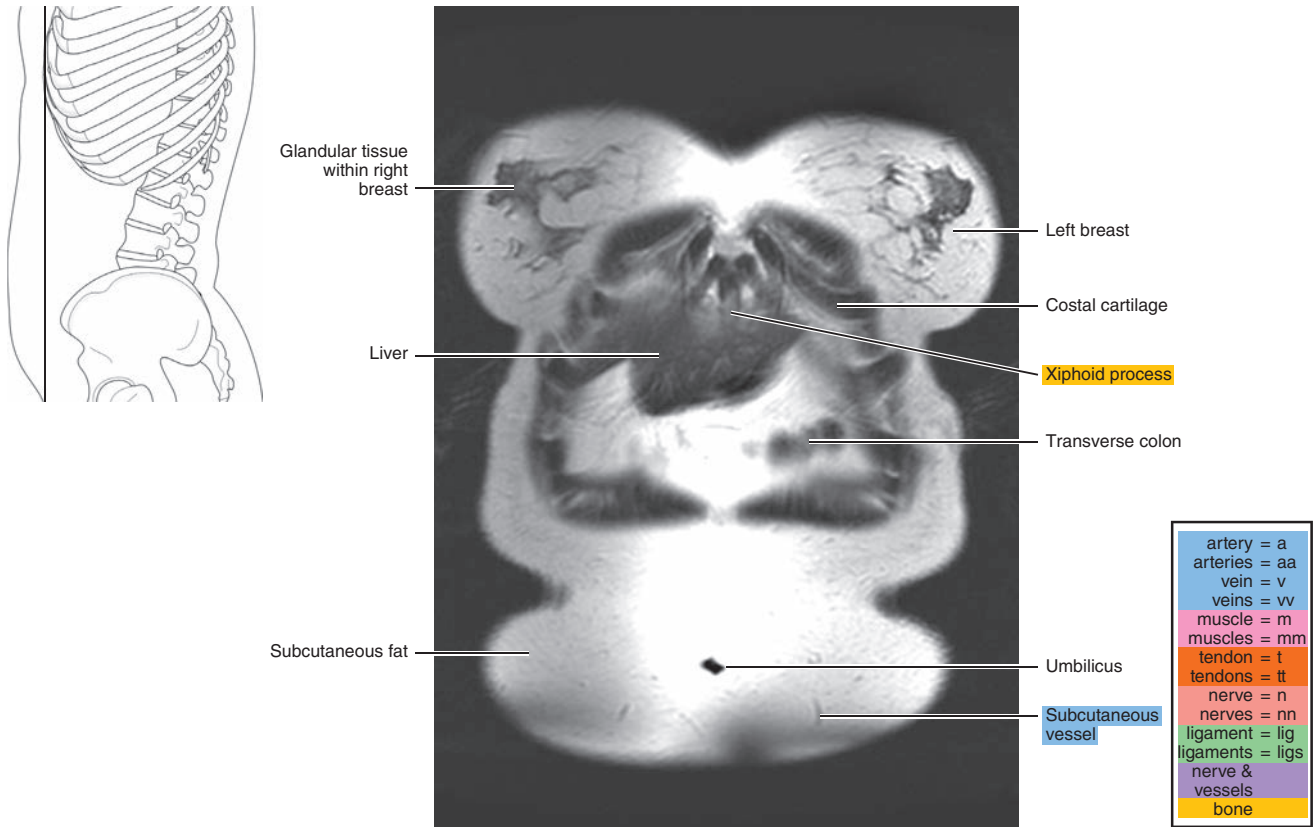


Figure 17.3.2

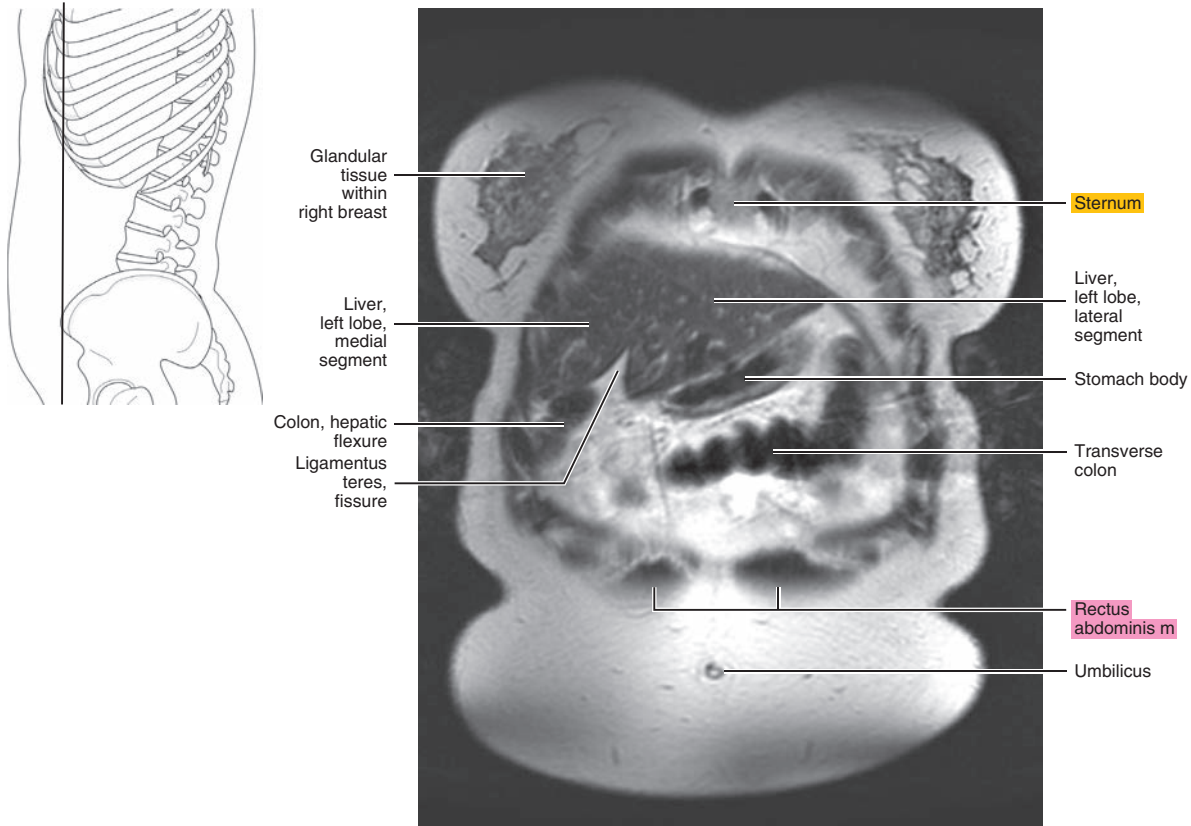




Figure 17.3.3

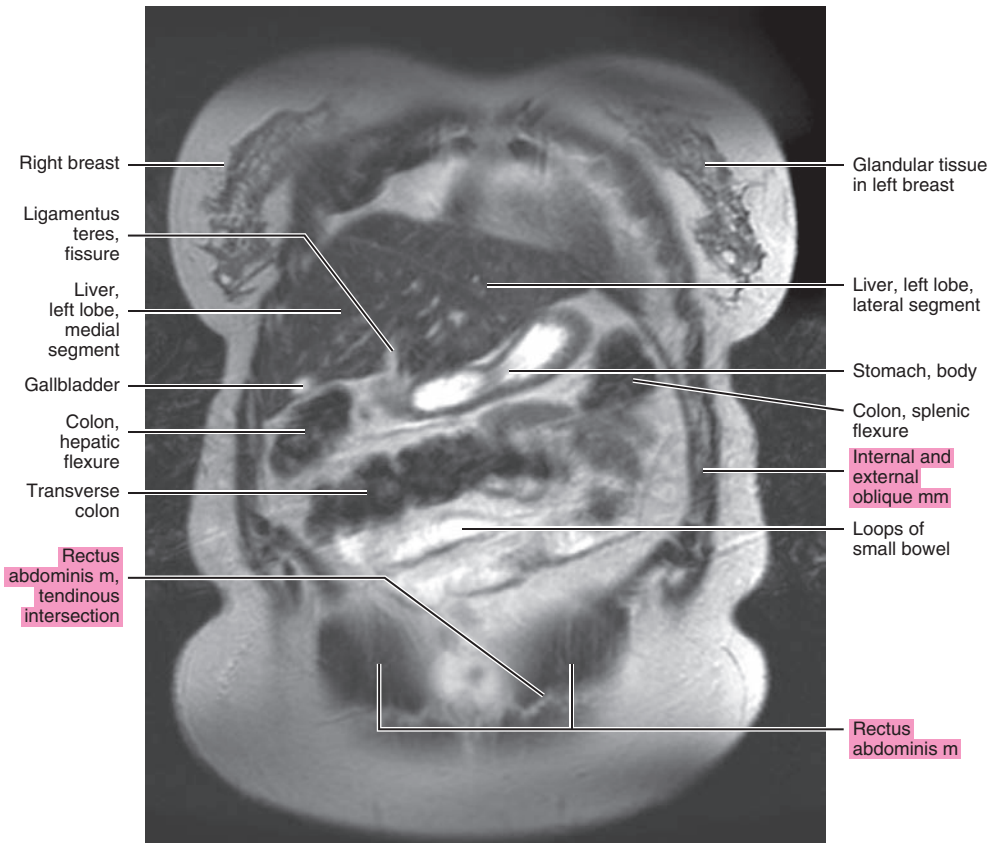
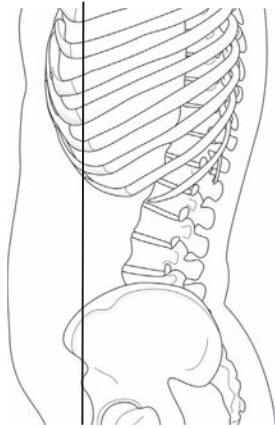


Figure 17.3.4

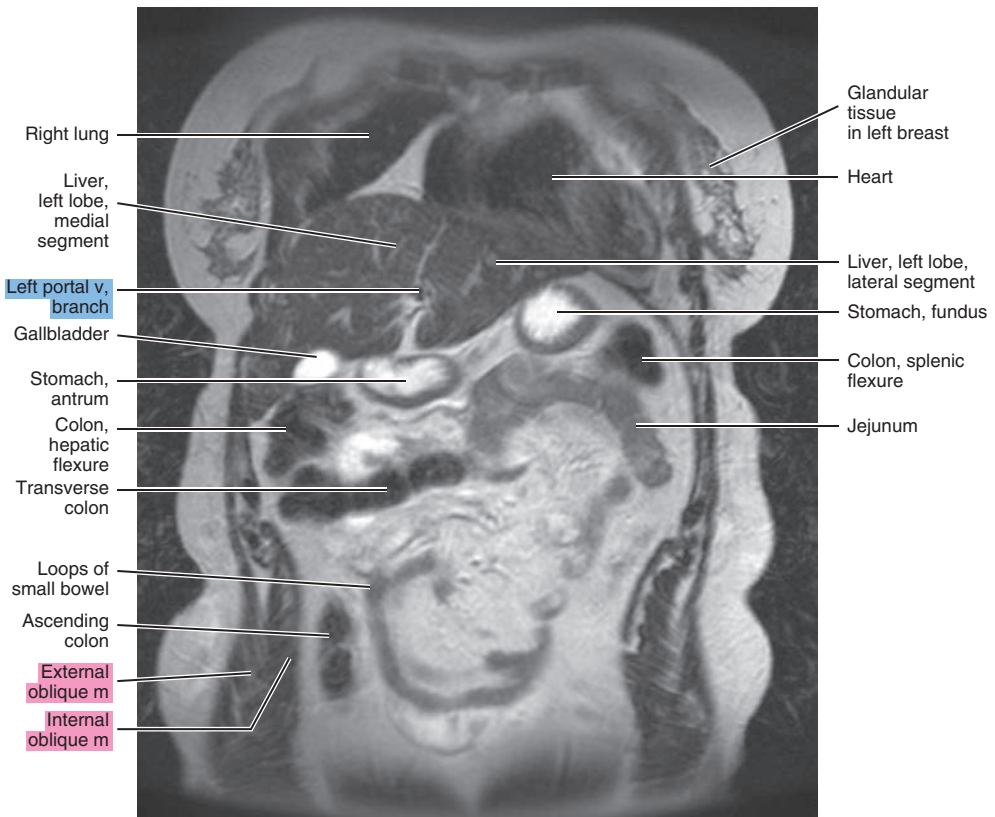
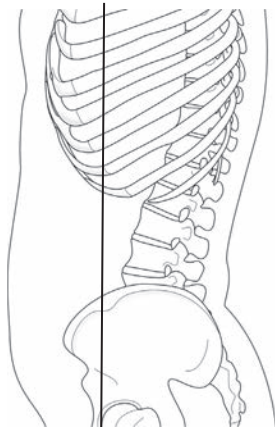


Figure 17.3.5

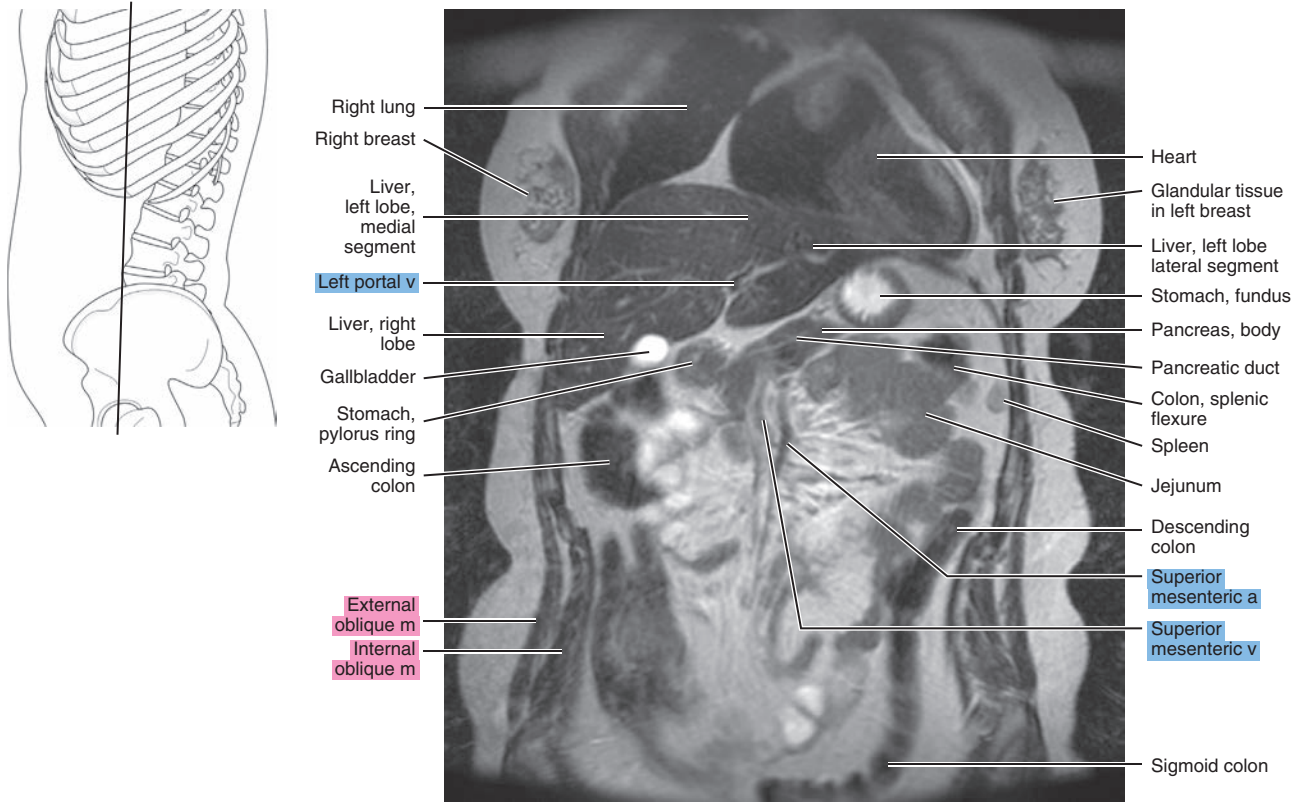


Figure 17.3.6

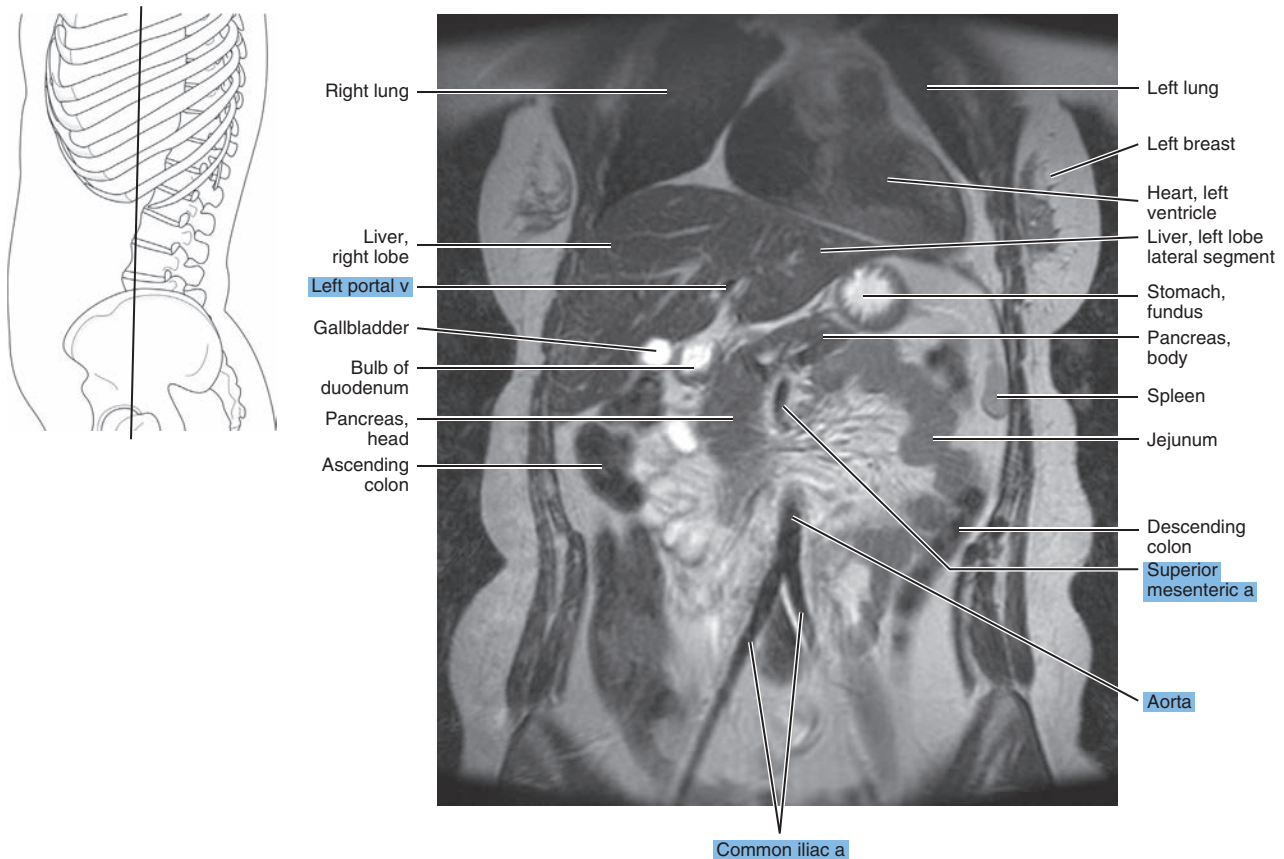


Figure 17.3.7

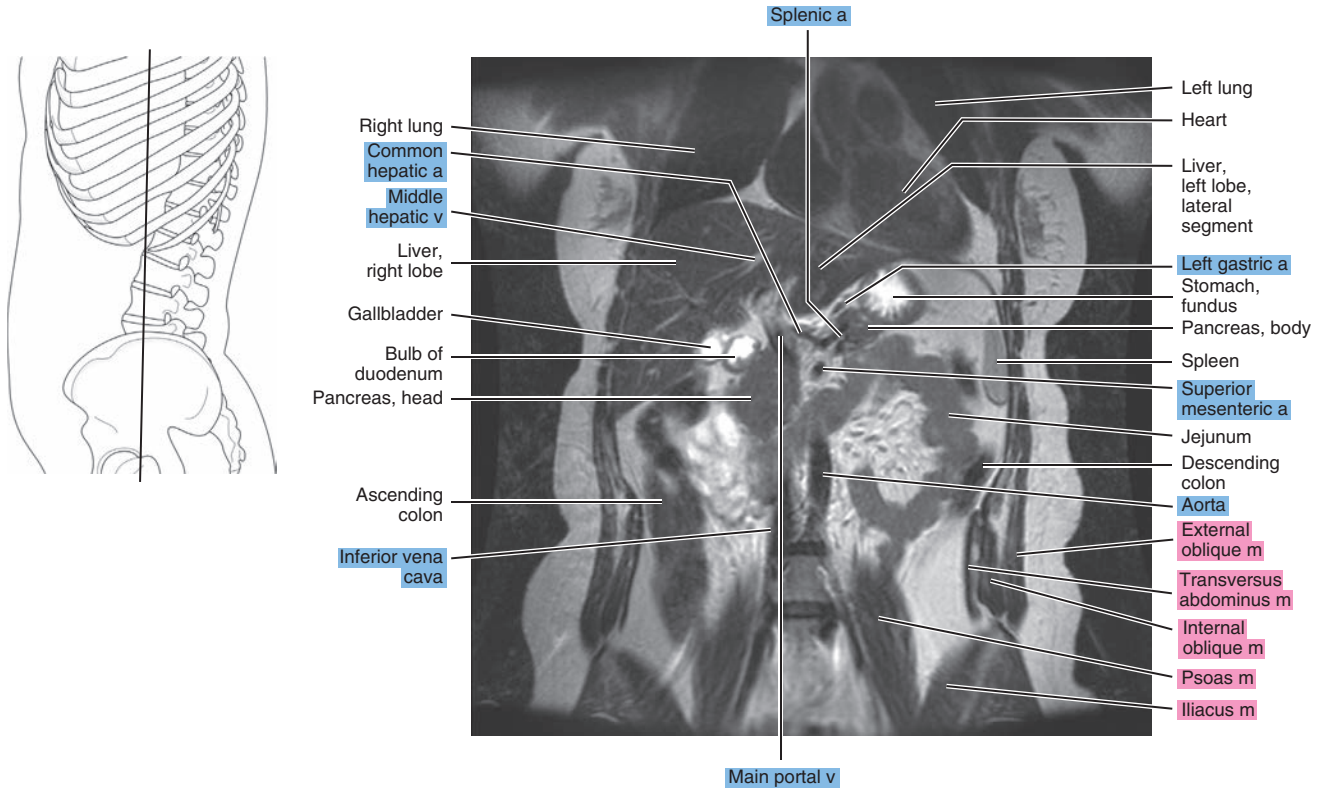


Figure 17.3.8

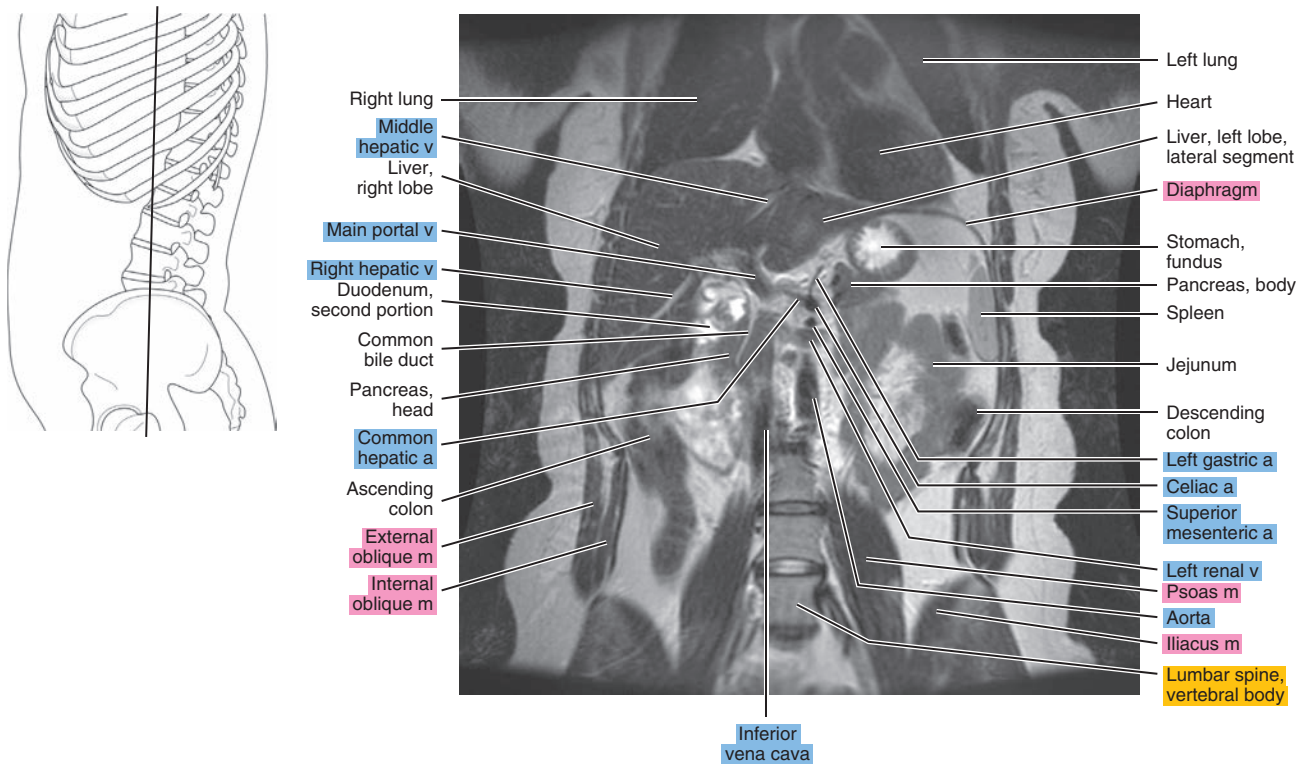




Figure 17.3.9

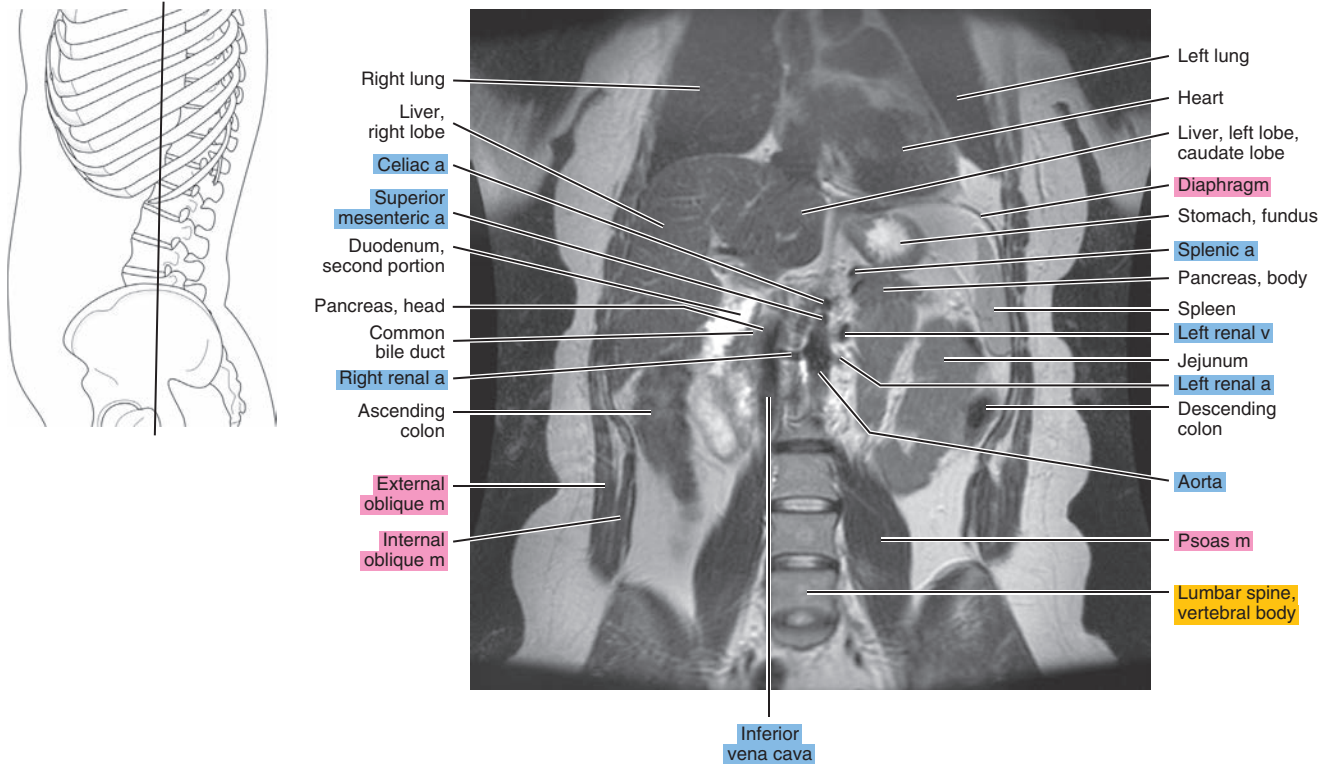


Figure 17.3.10

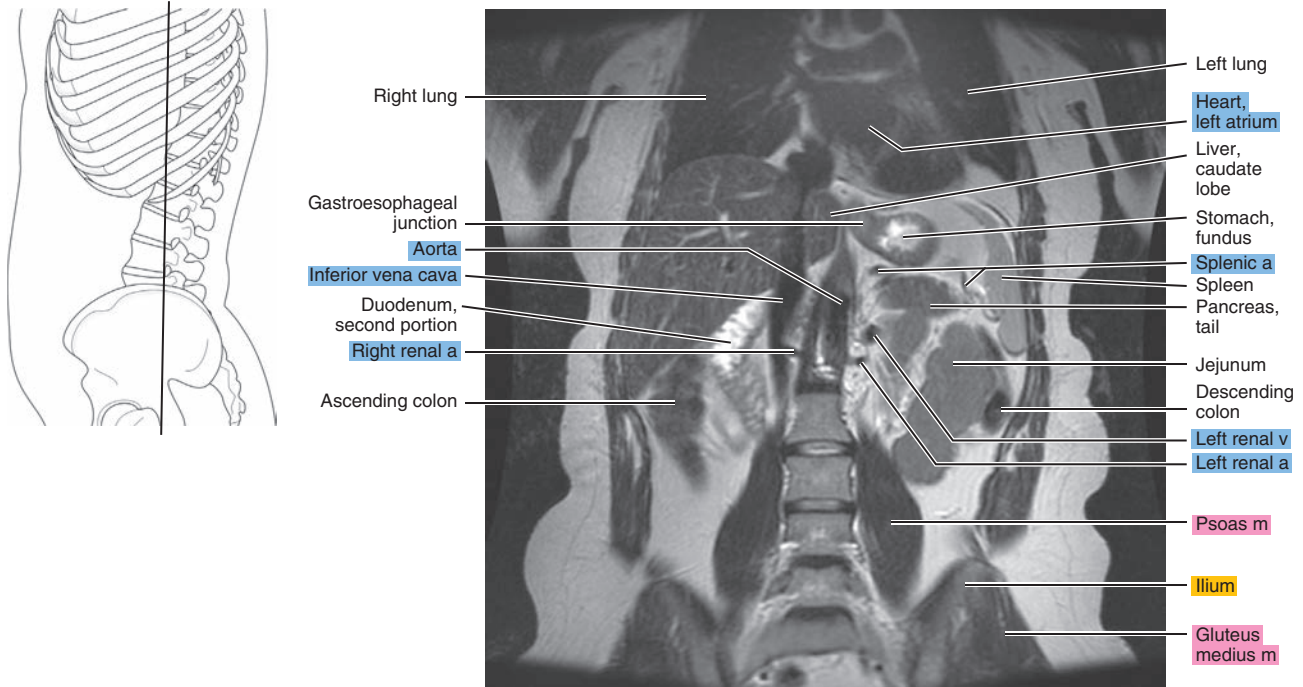




Figure 17.3.11

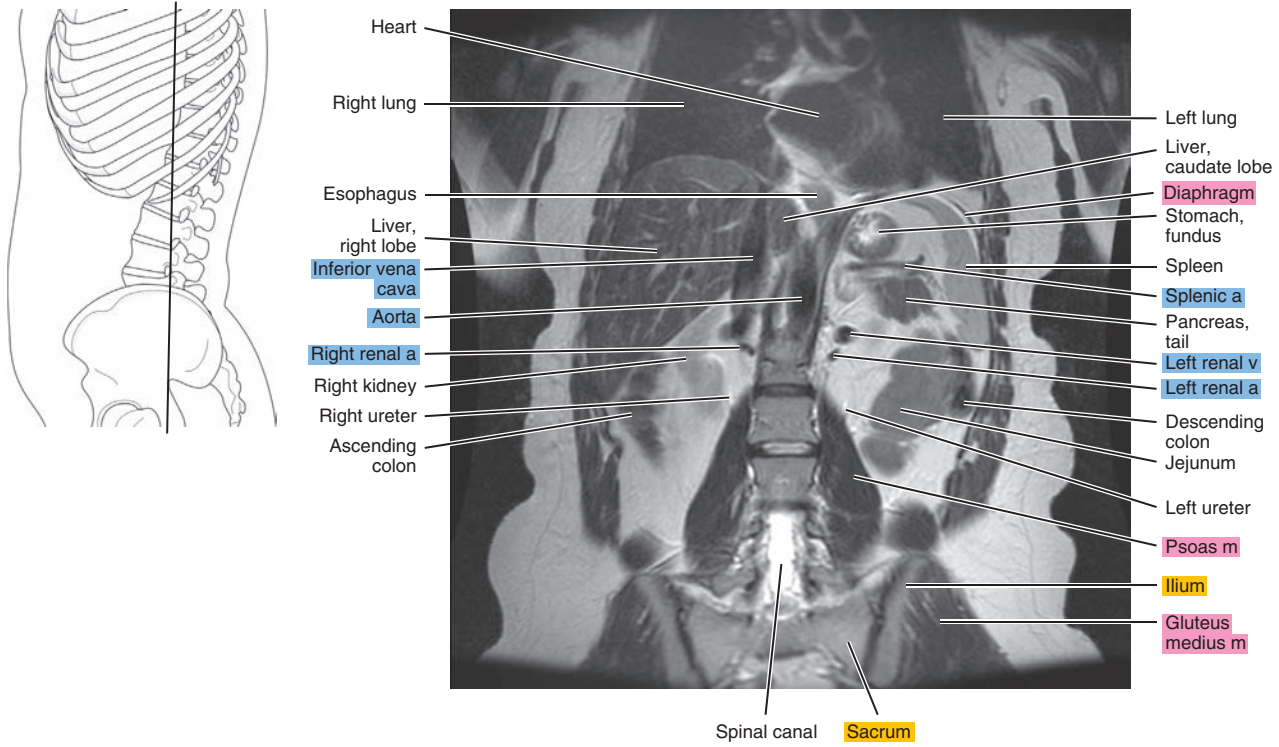


Figure 17.3.12

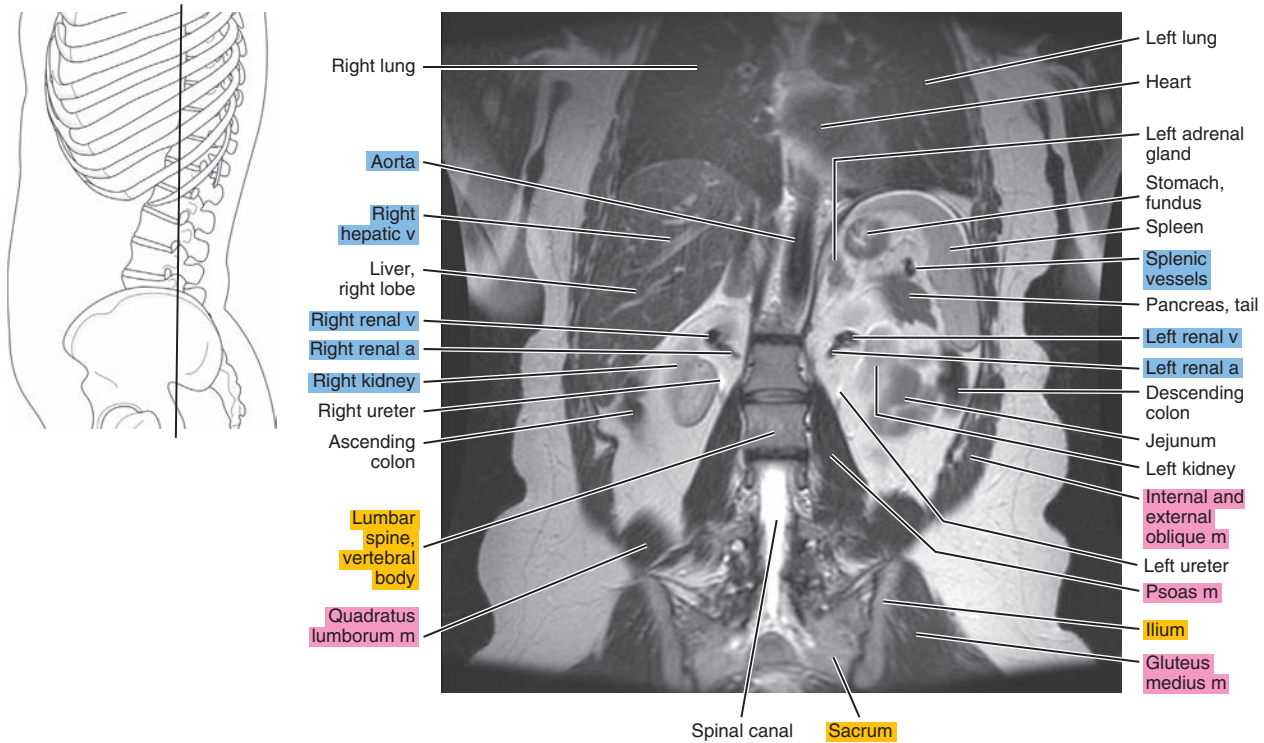


Figure 17.3.13

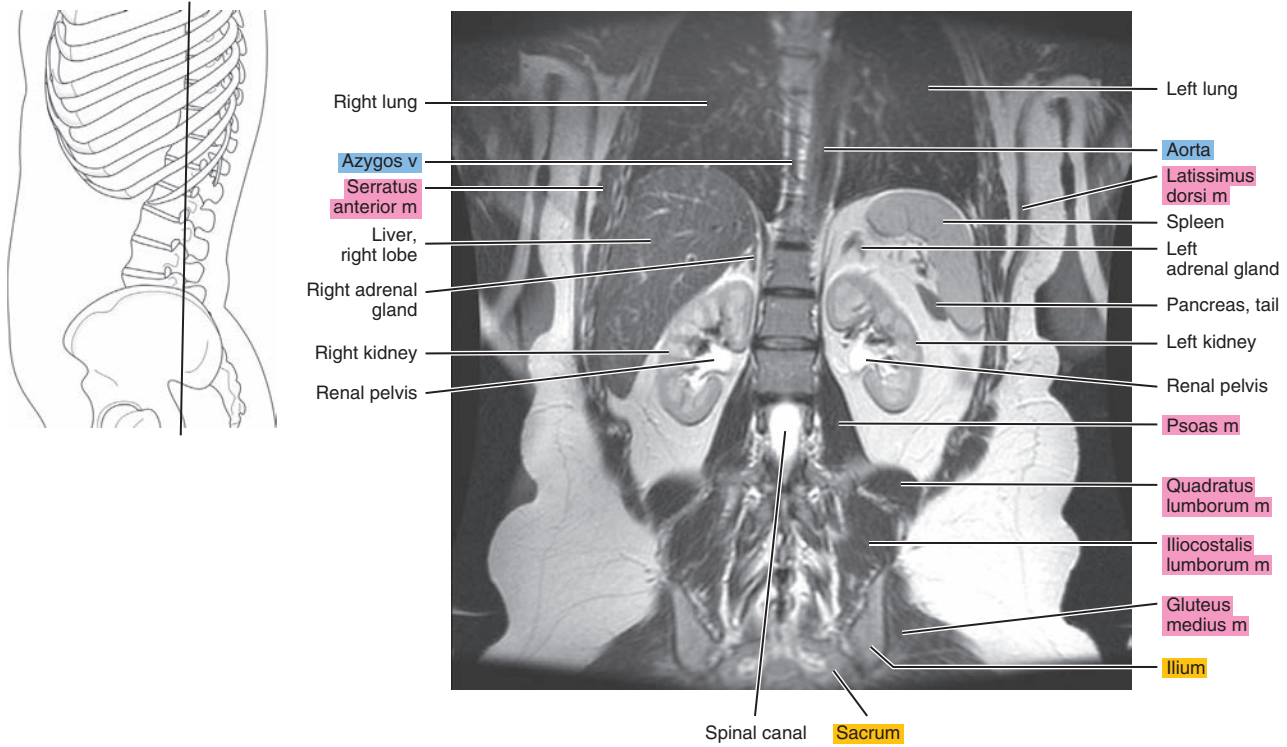


Figure 17.3.14

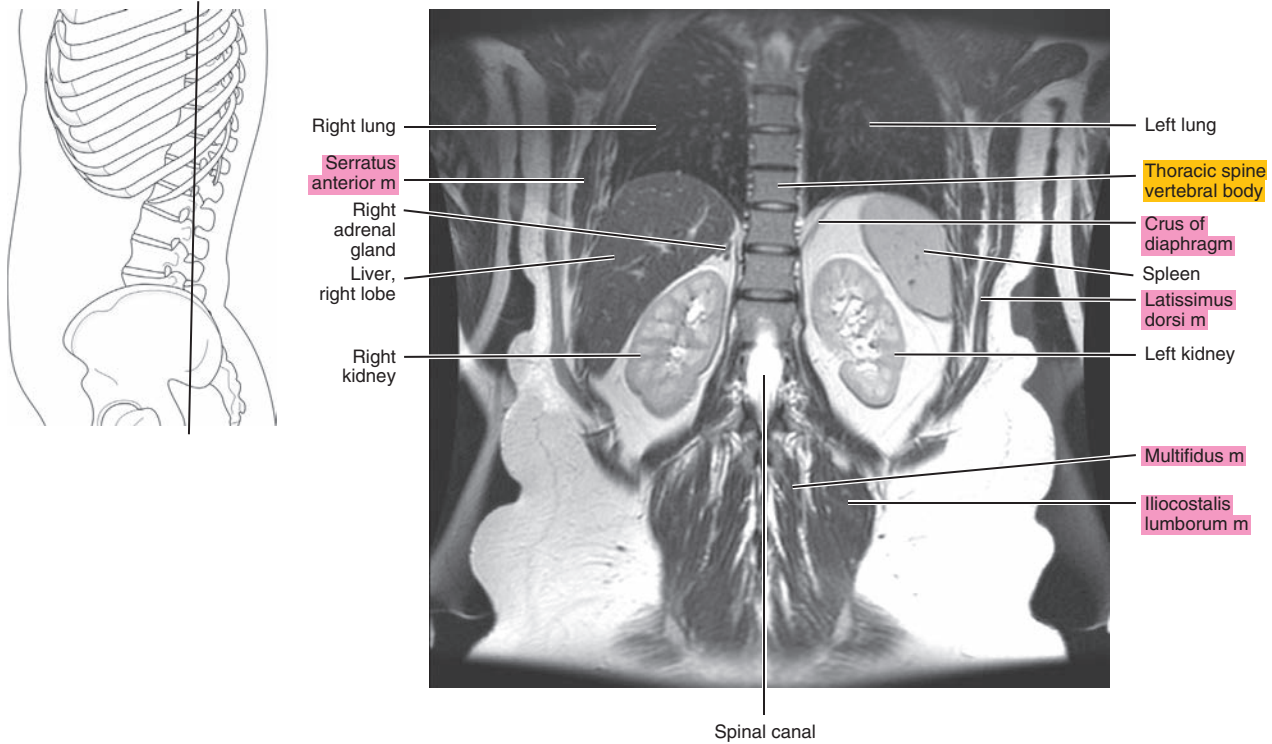


Figure 17.3.15

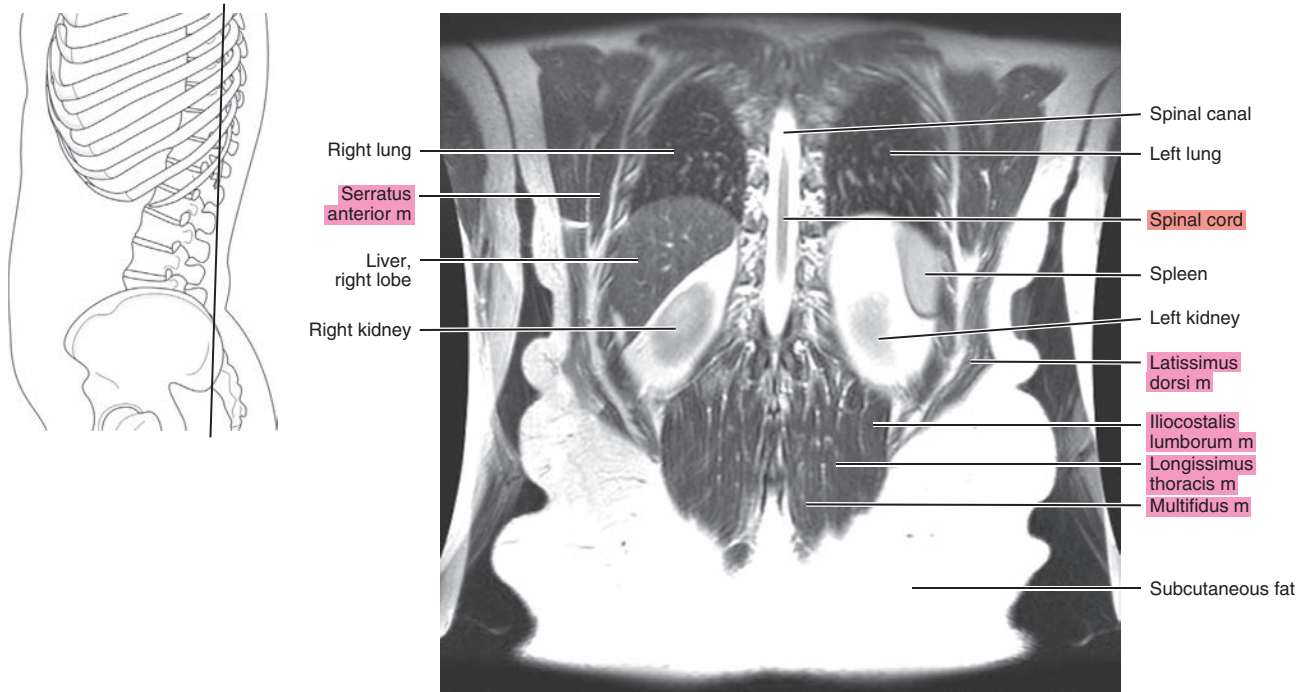
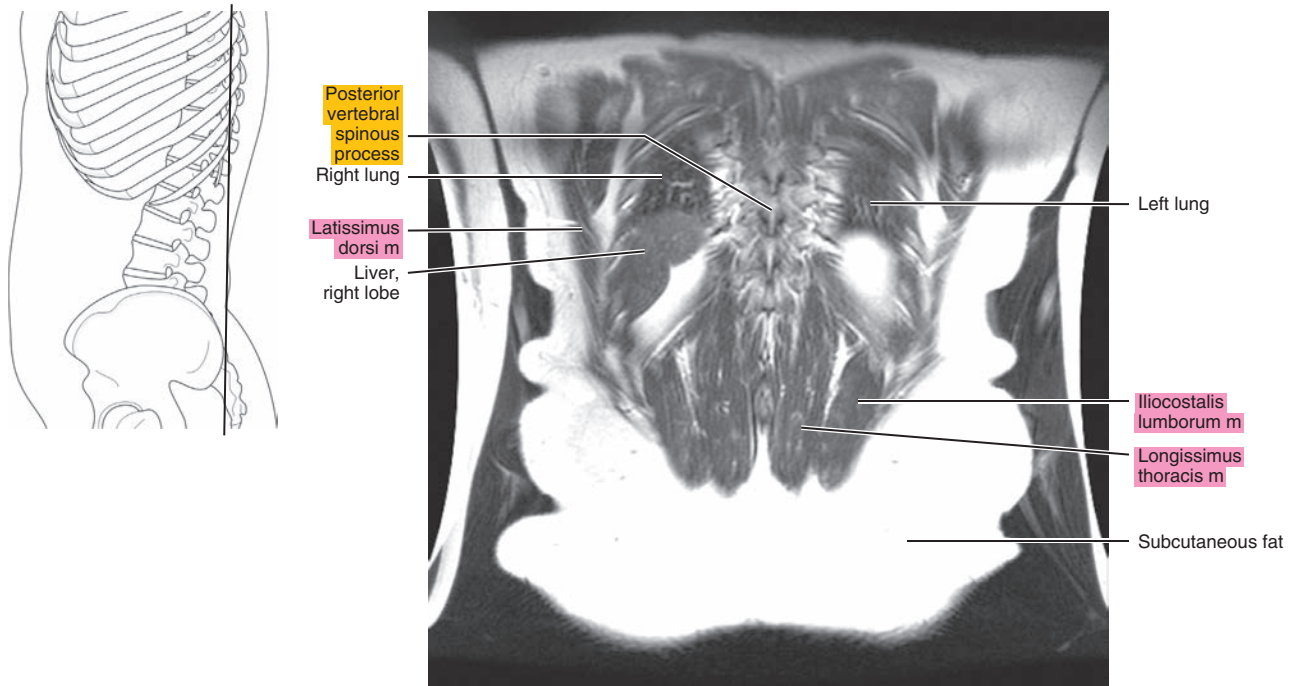


Figure 17.3.16





*Chapter*  
**18**

**MRI of the Hip**



# AXIAL

Figure 18.1.1

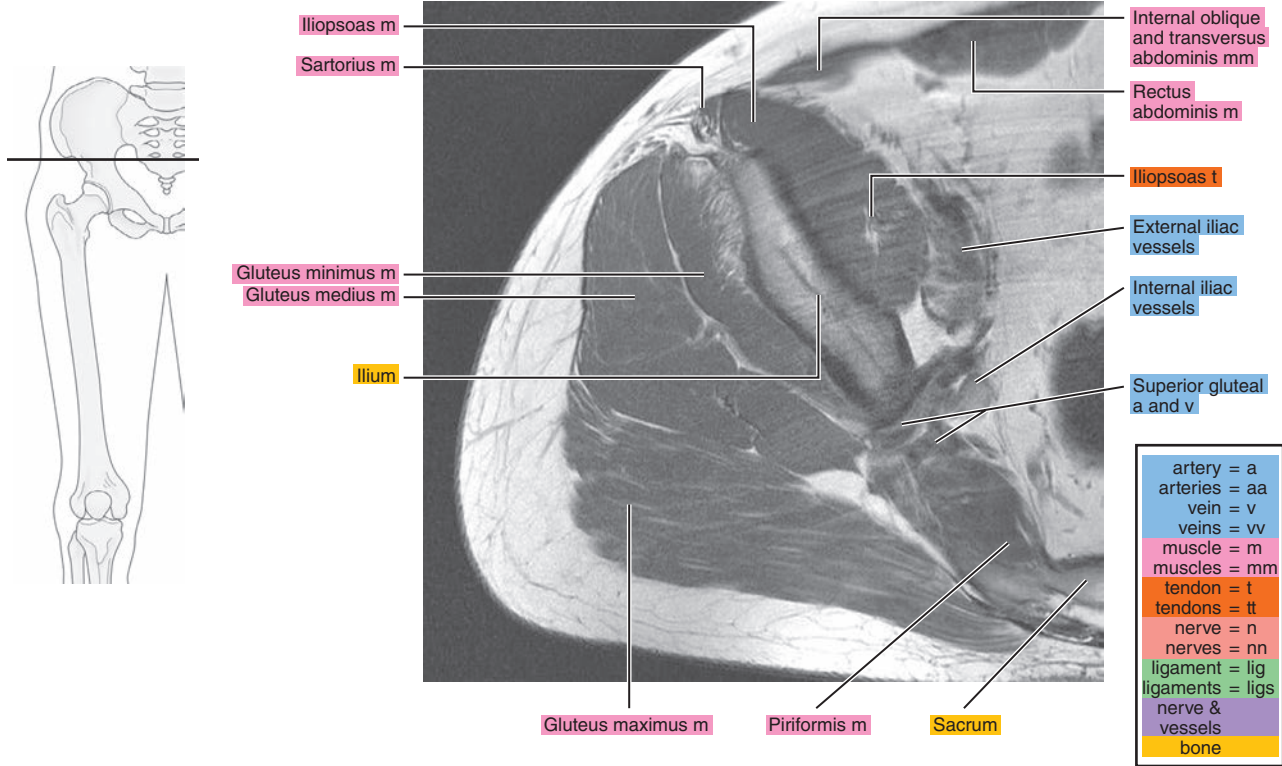


Figure 18.1.2

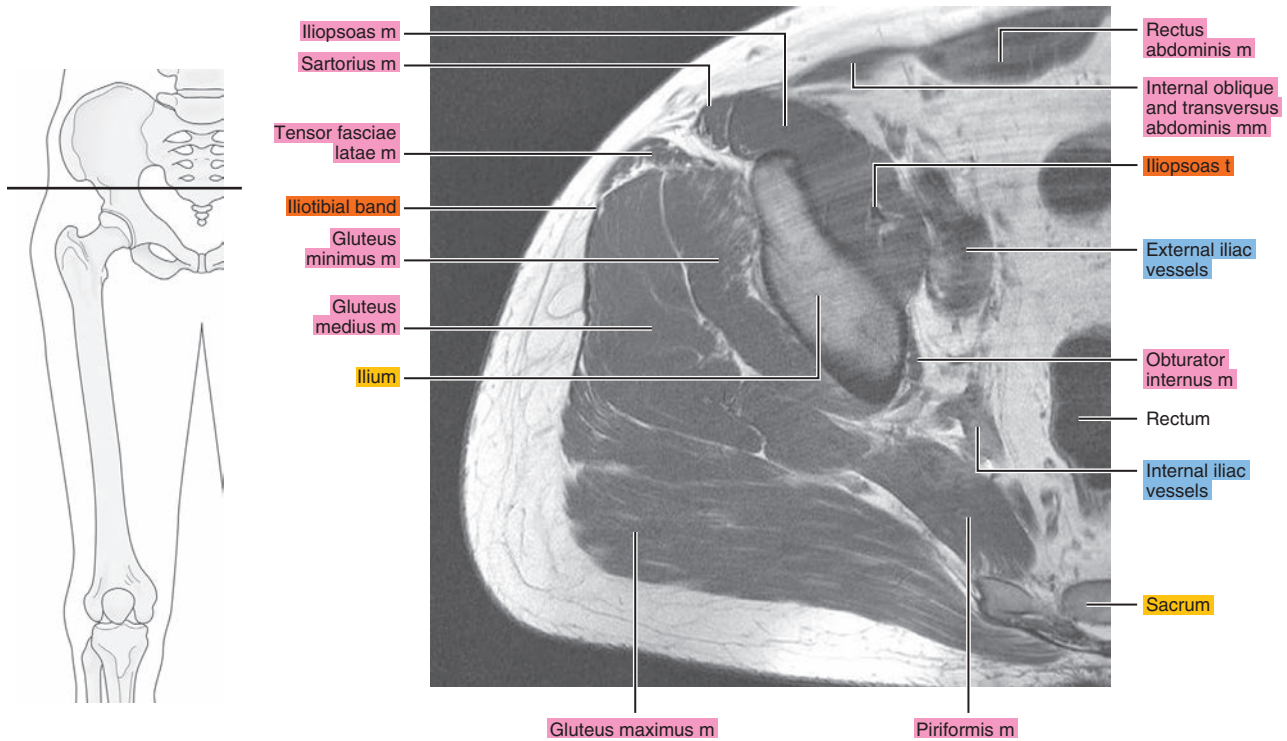


Figure 18.1.3

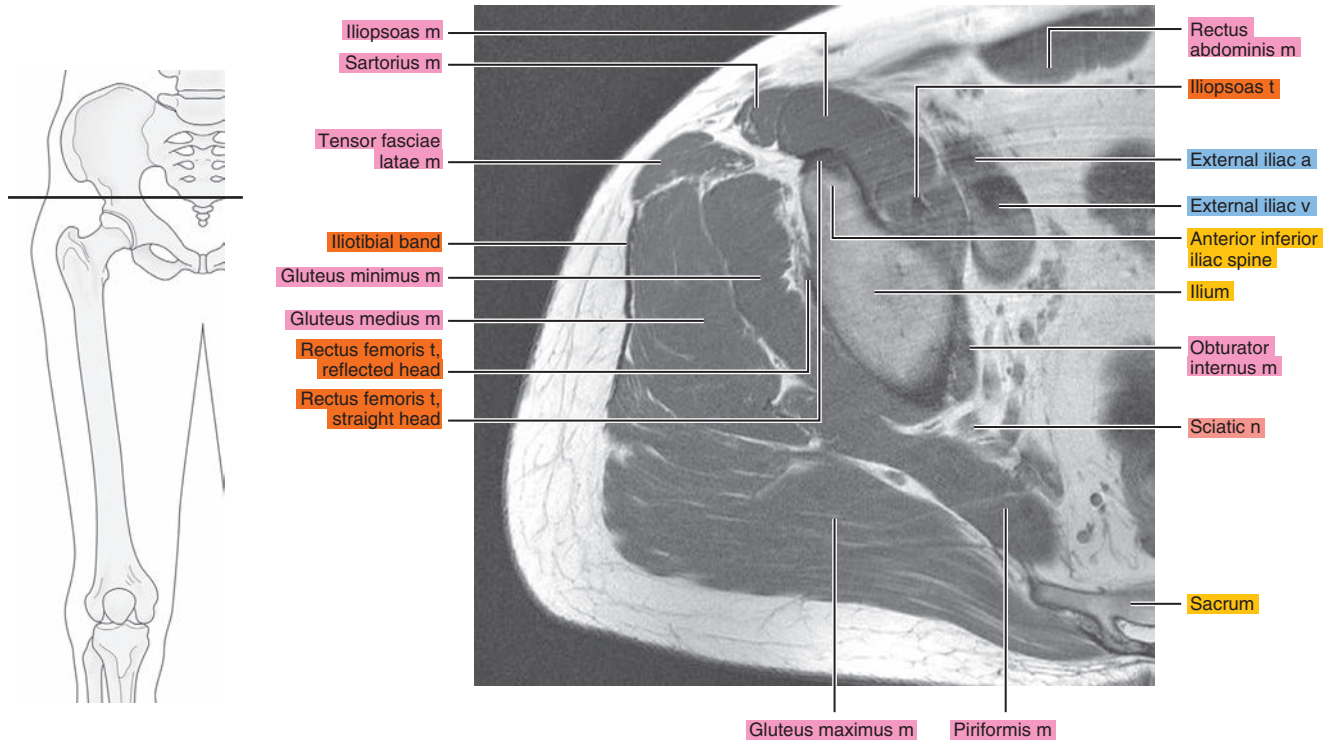


Figure 18.1.4

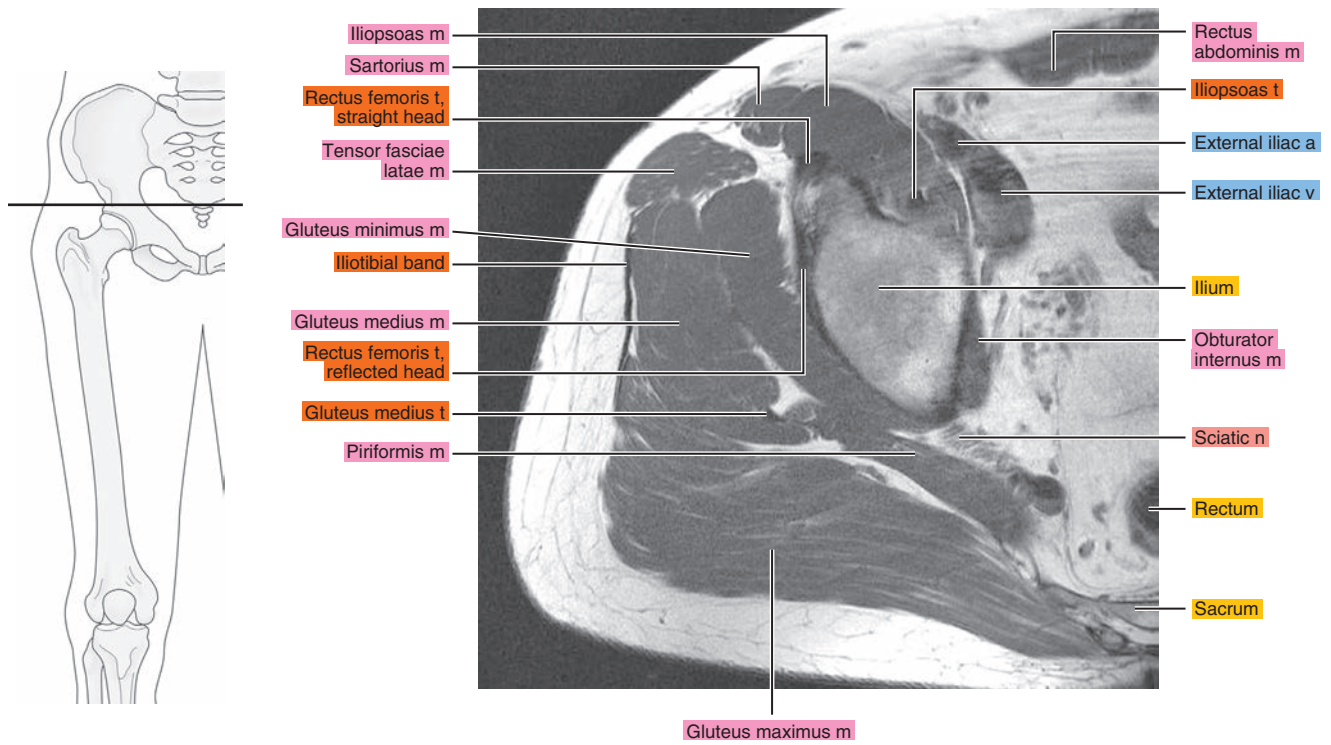


Figure 18.1.5

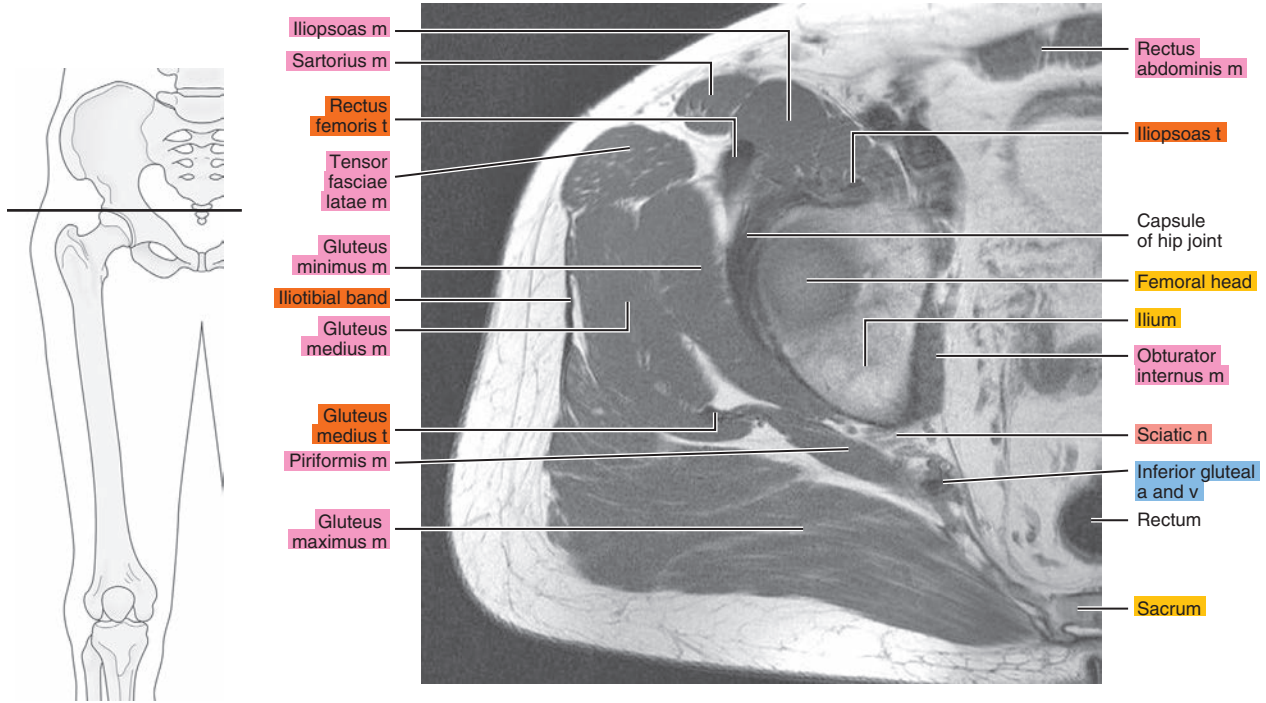


Figure 18.1.6

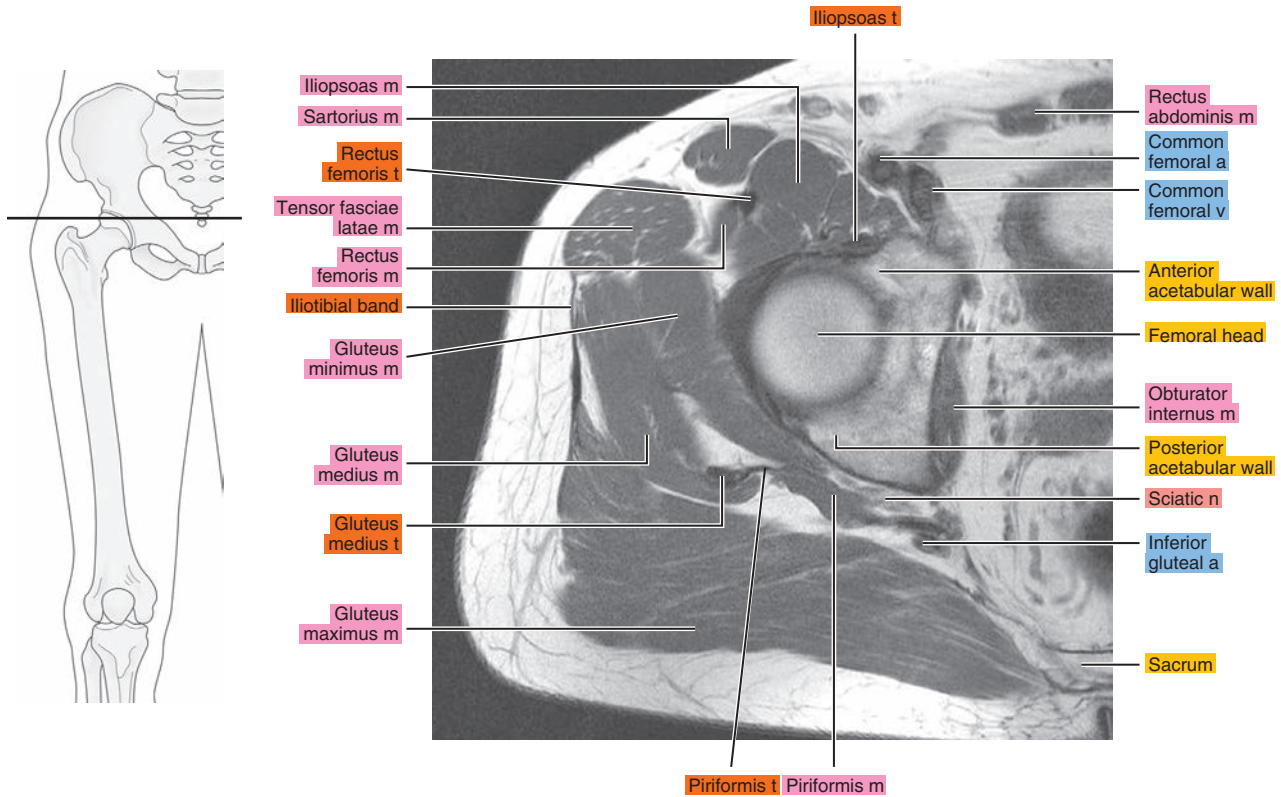




Figure 18.1.7

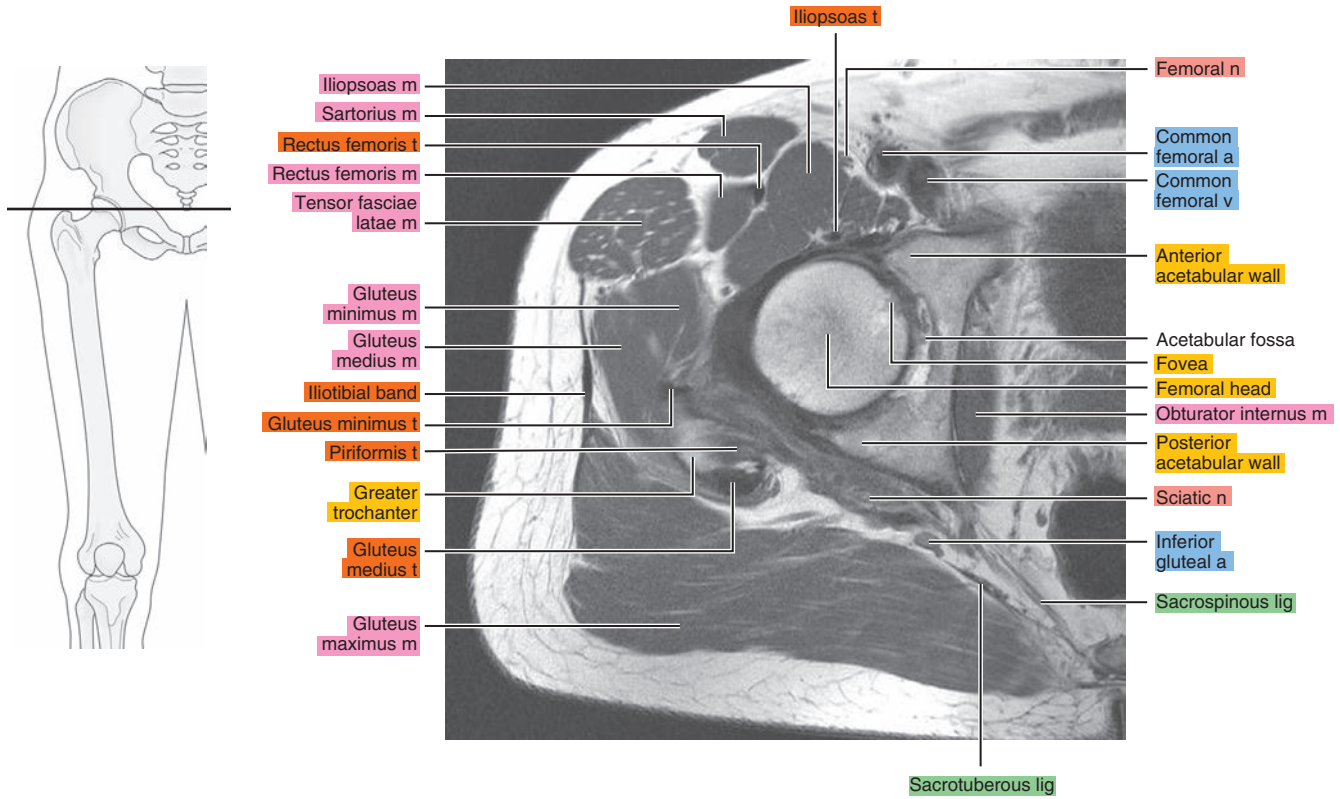


Figure 18.1.8

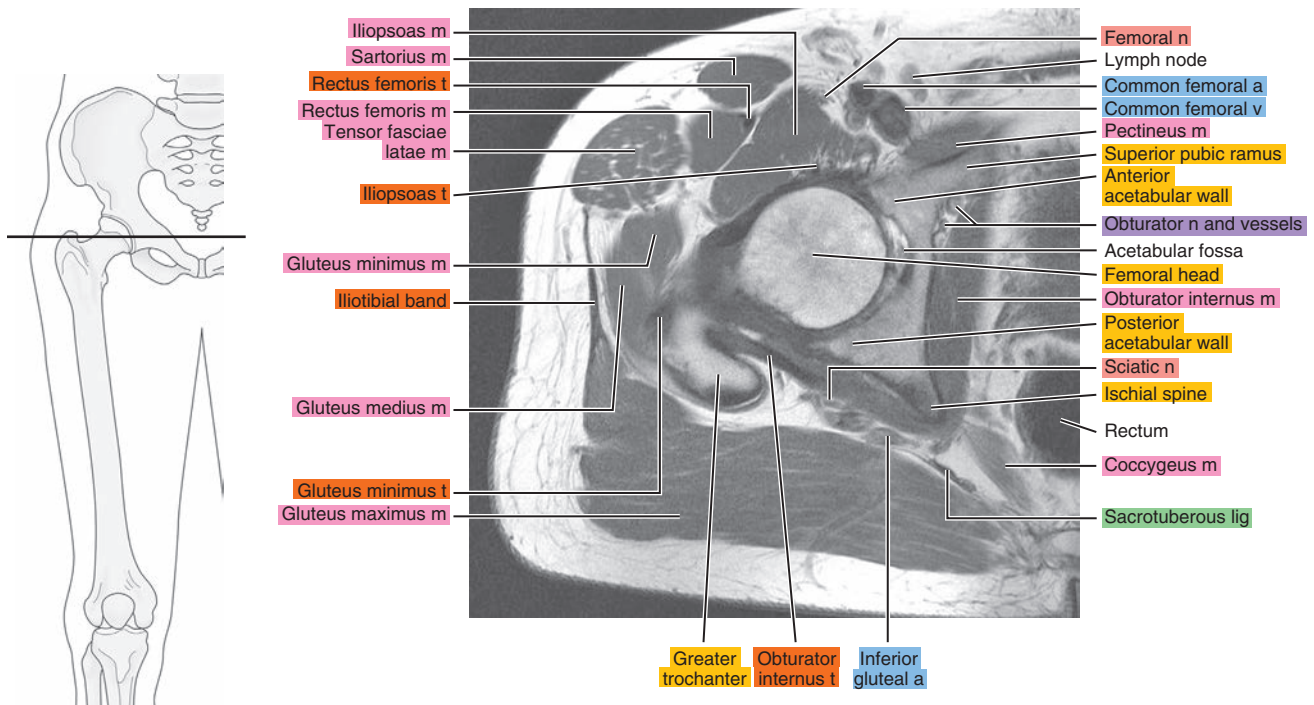




Figure 18.1.9

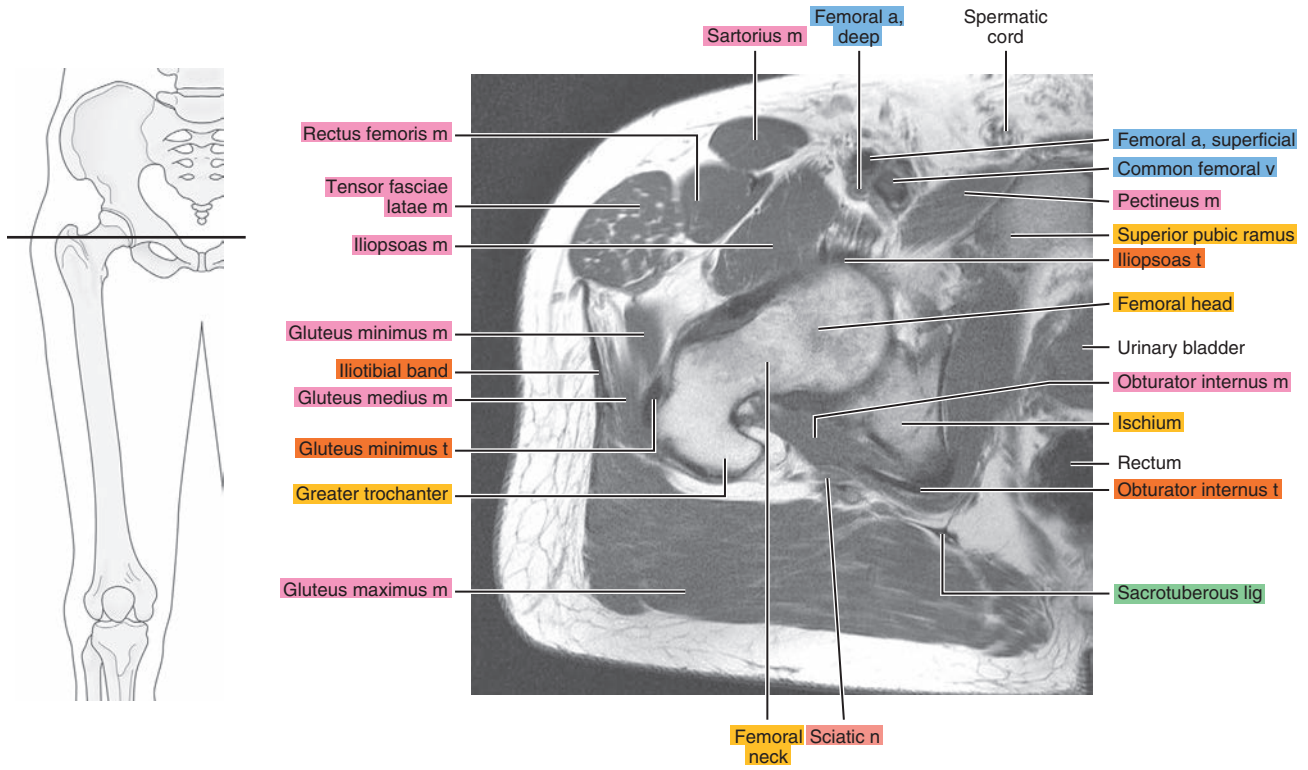


Figure 18.1.10

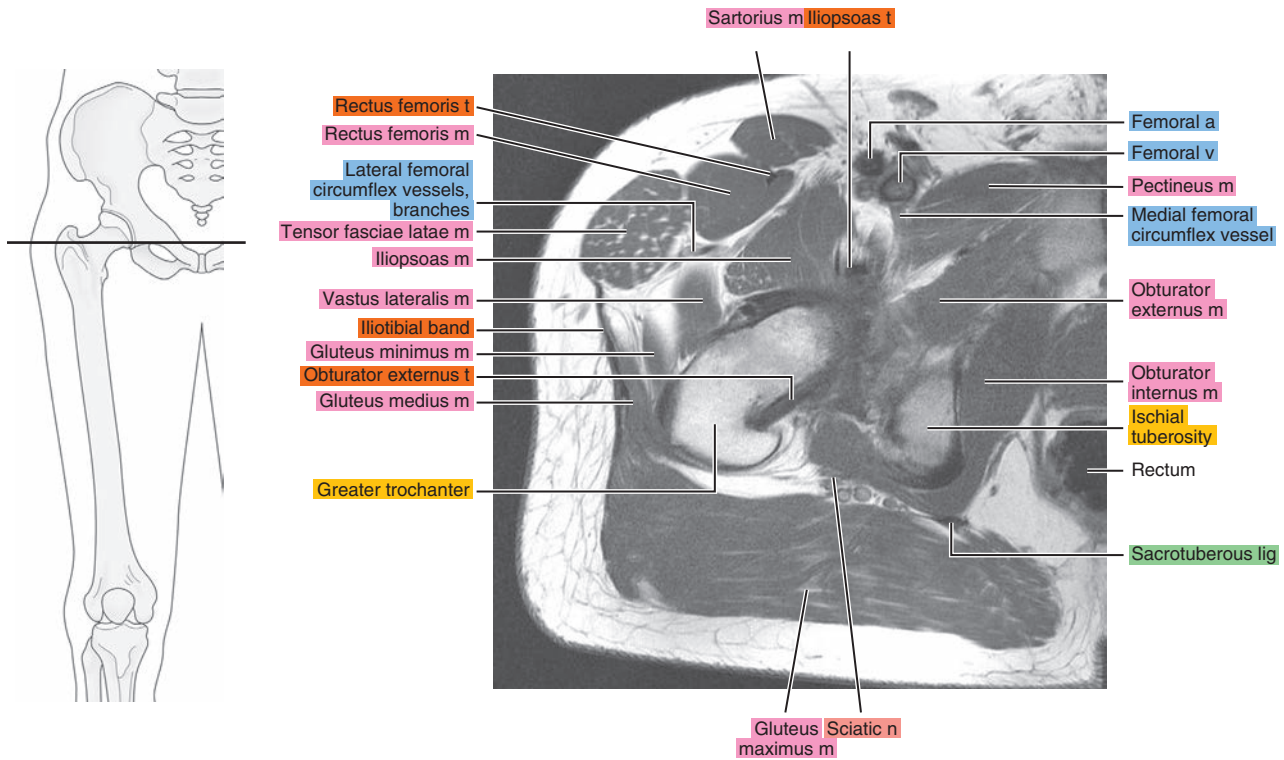


Figure 18.1.11

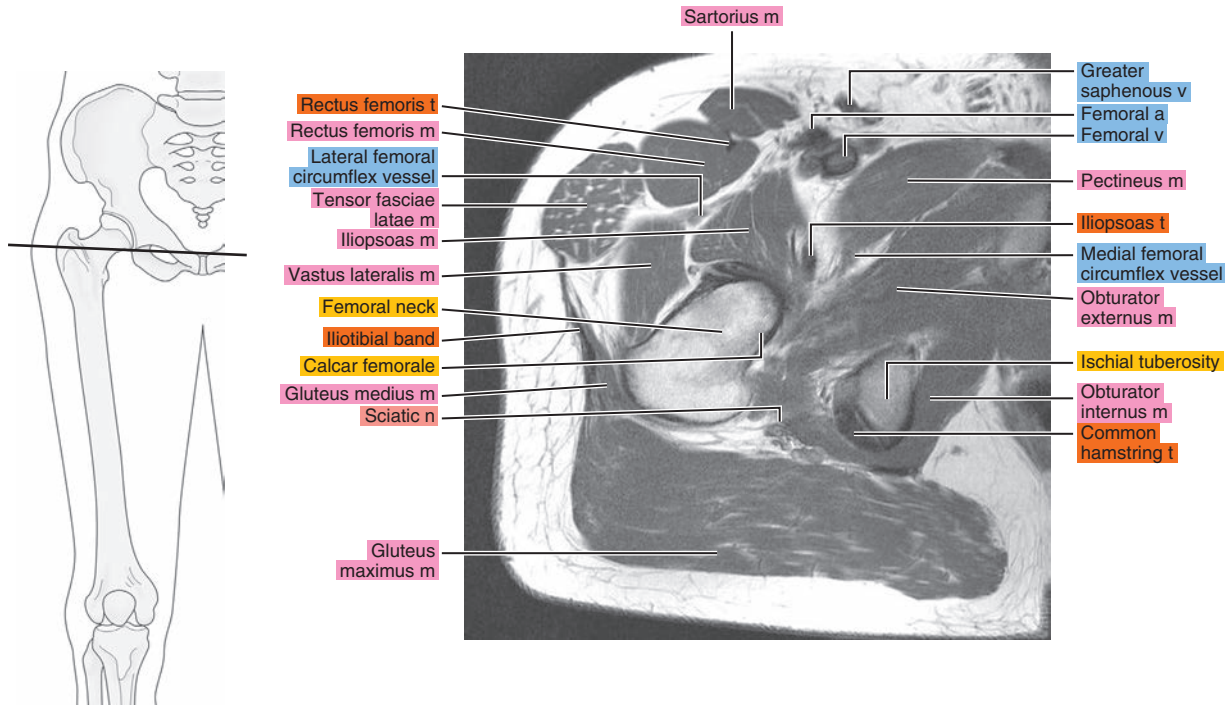


Figure 18.1.12

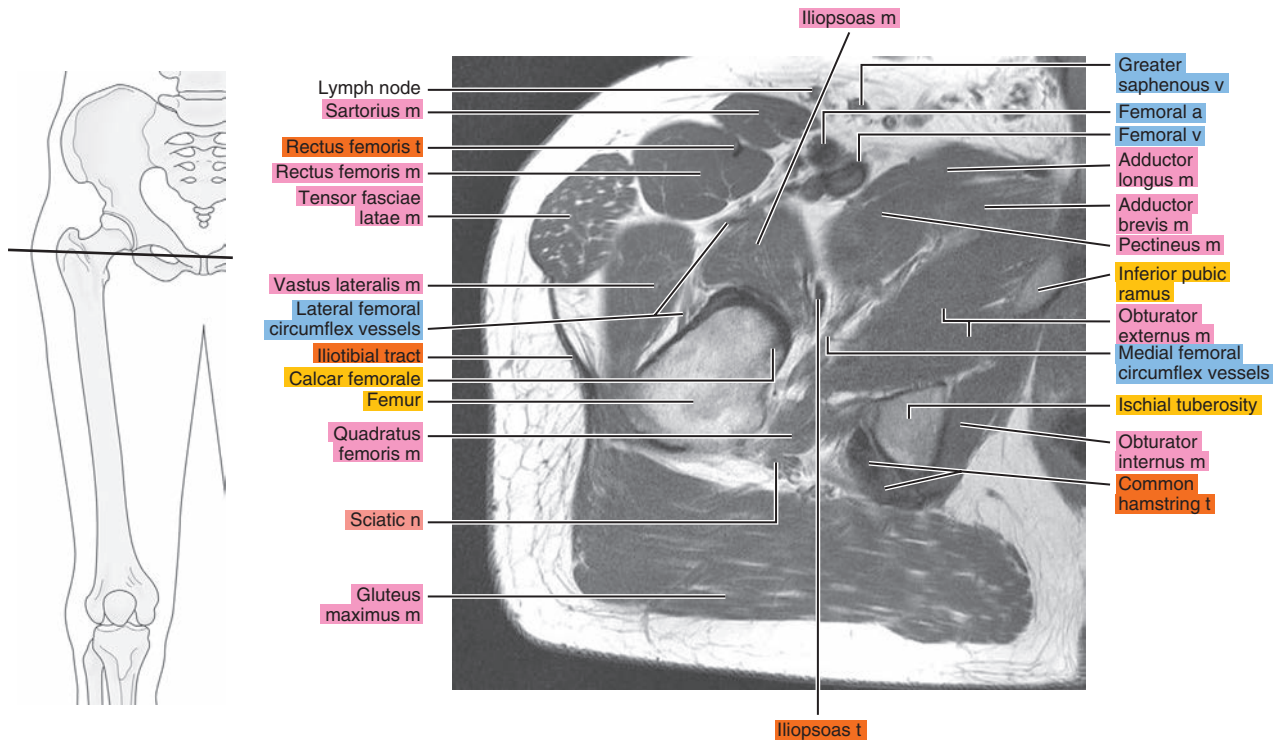


Figure 18.1.13

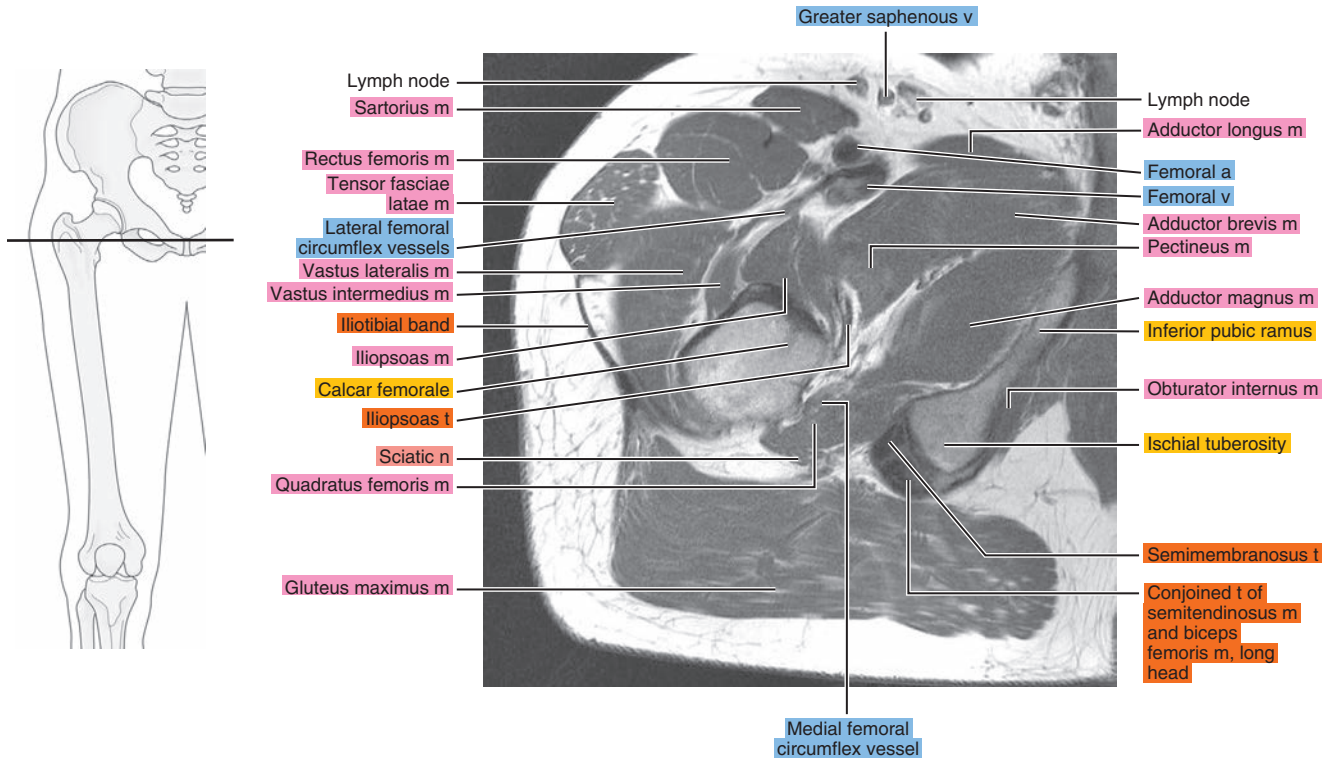


Figure 18.1.14

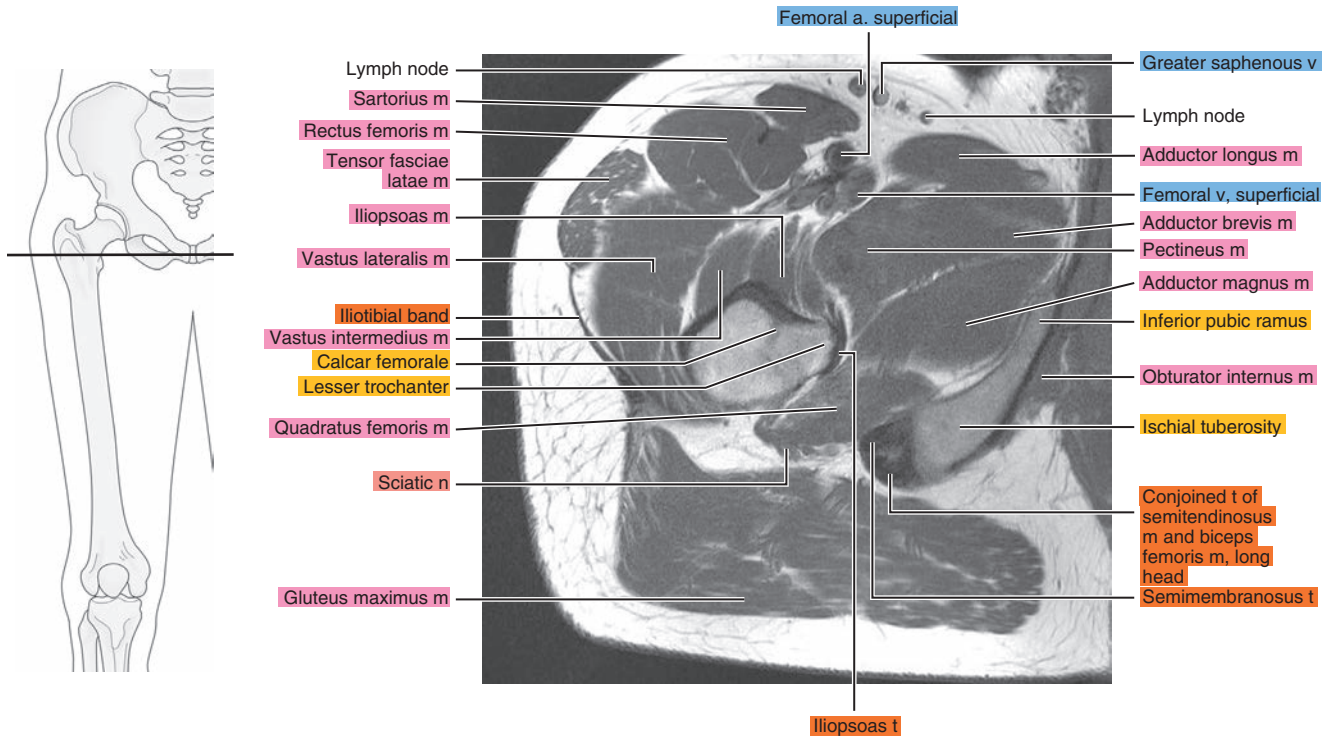




Figure 18.1.15

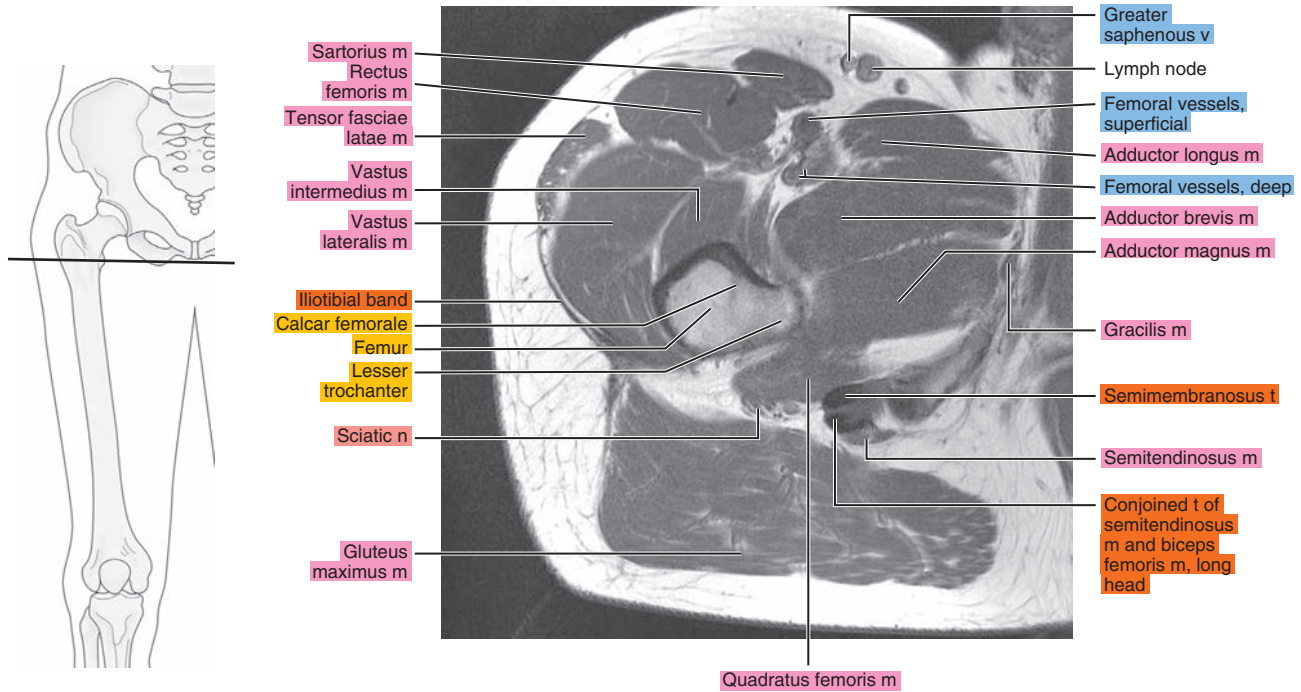


Figure 18.1.16

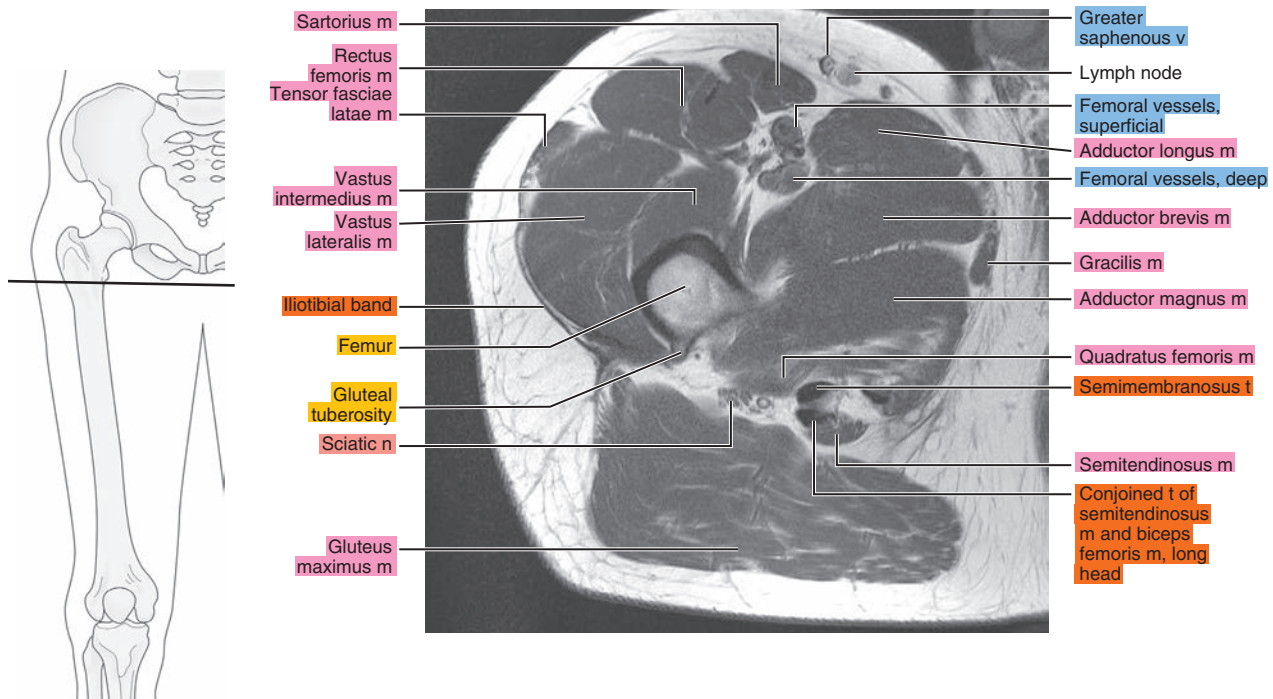




Figure 18.1.17

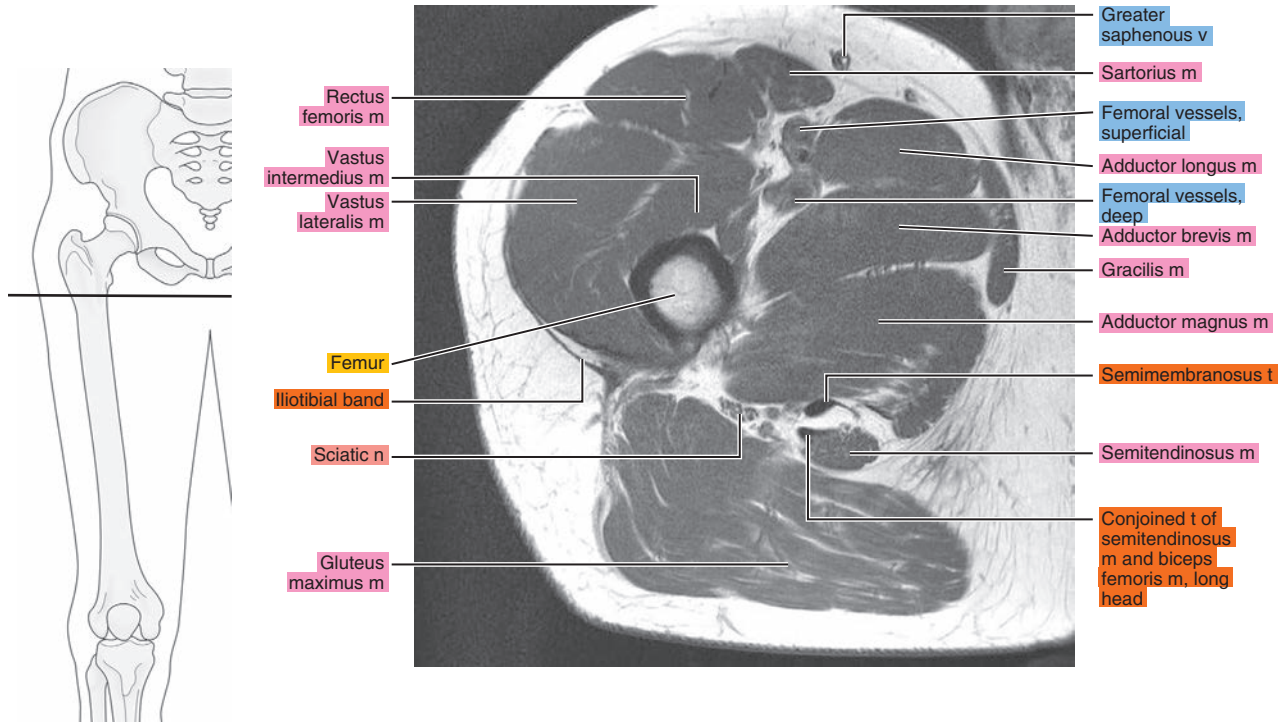
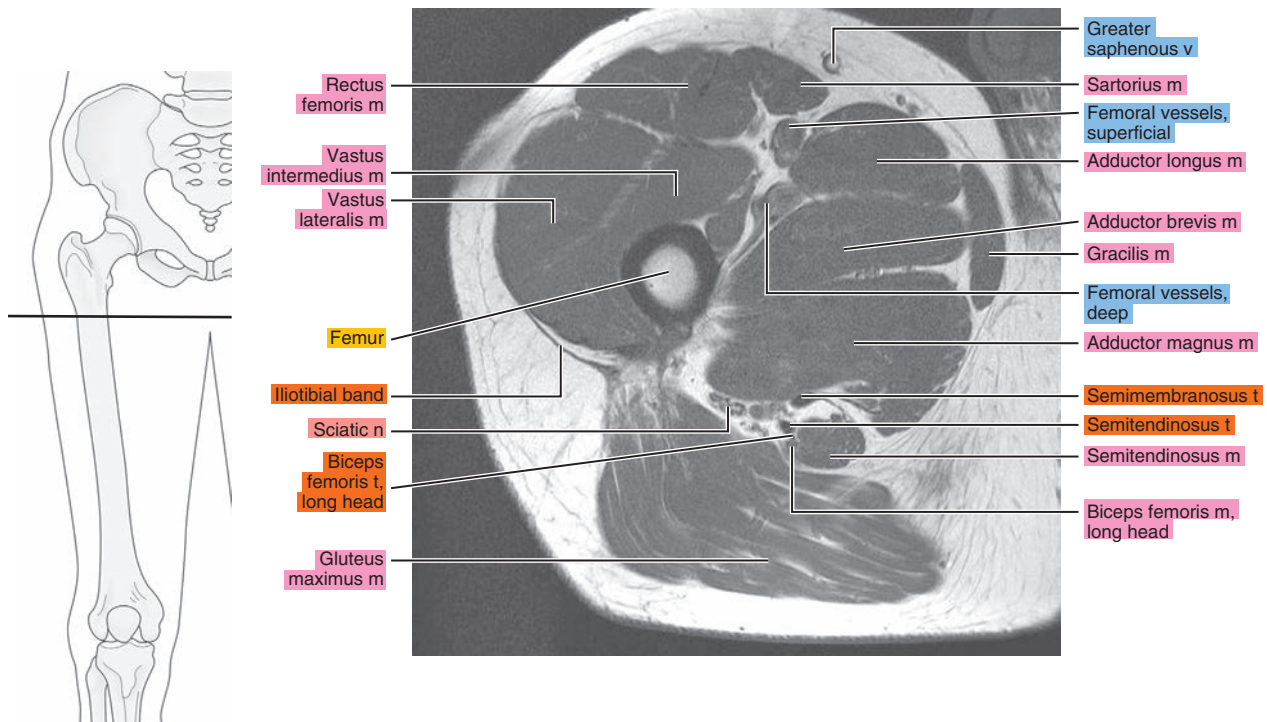


Figure 18.1.18



# SAGITTAL

Figure 18.2.1

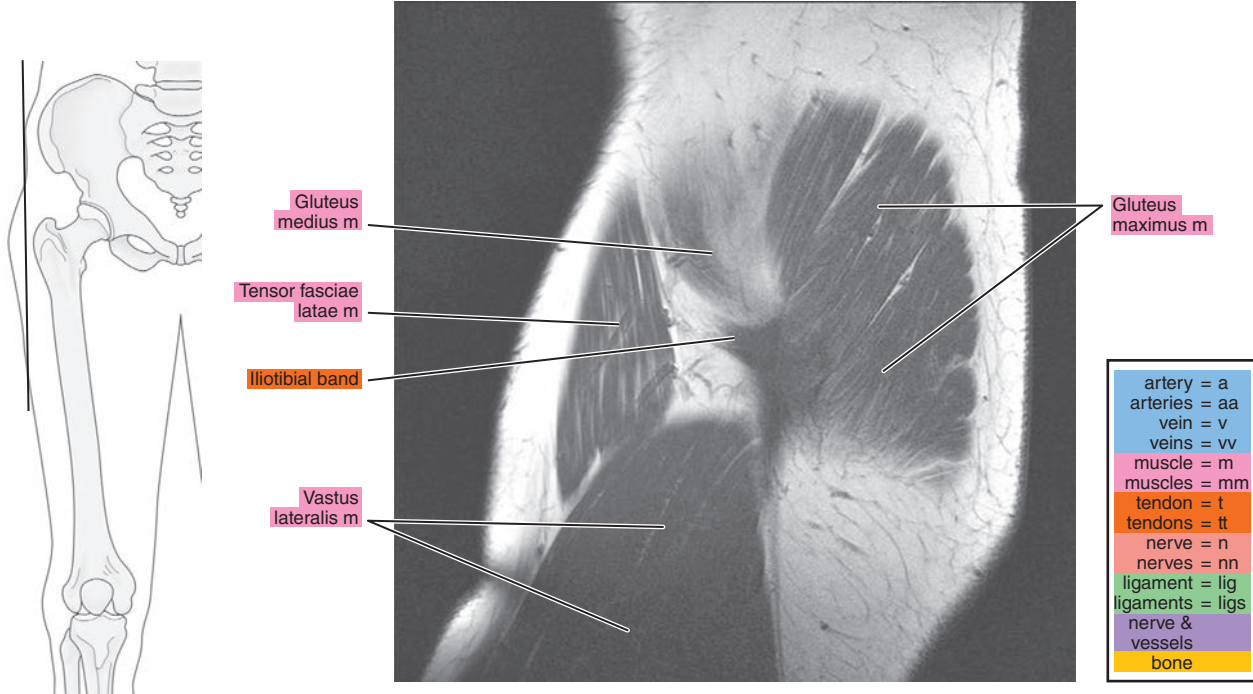


Figure 18.2.2

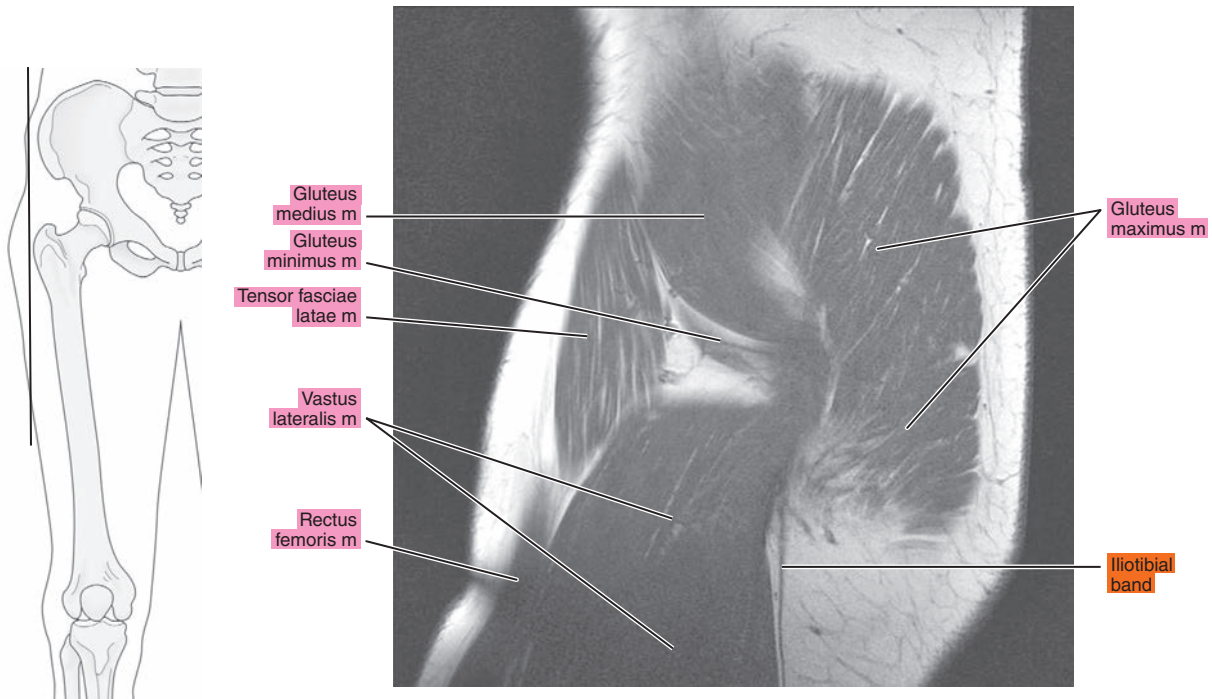


Figure 18.2.3

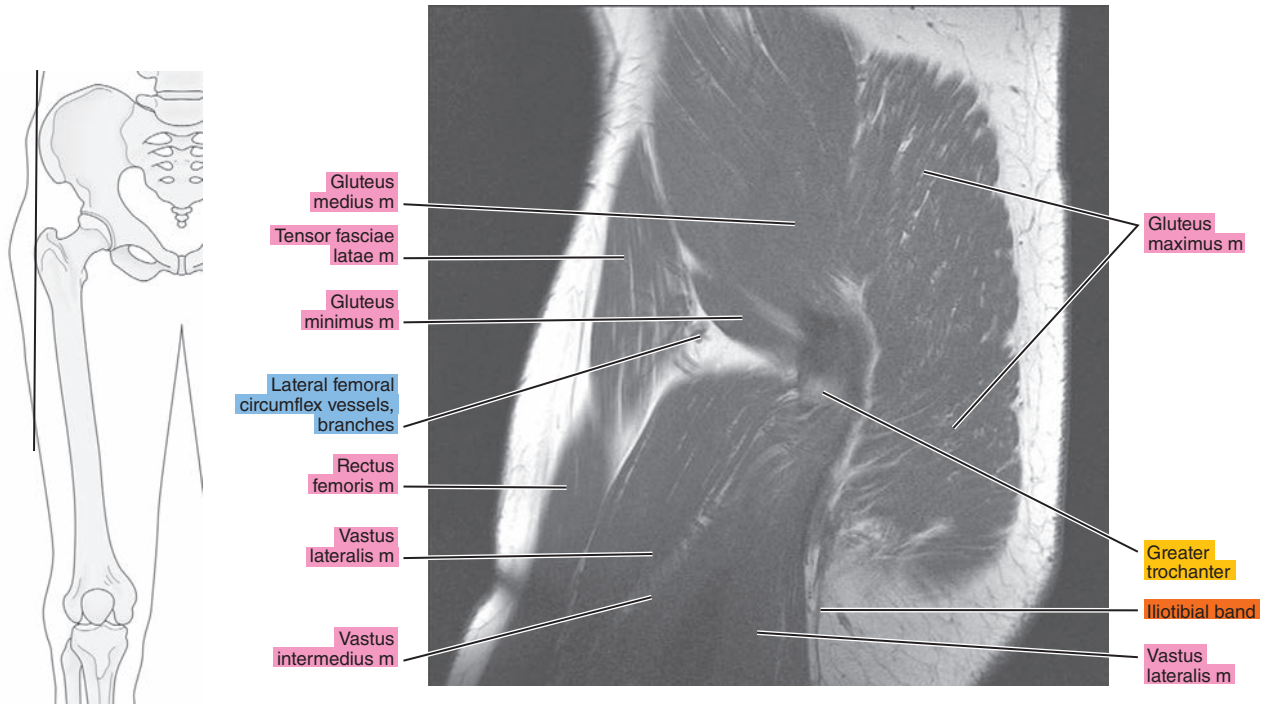


Figure 18.2.4

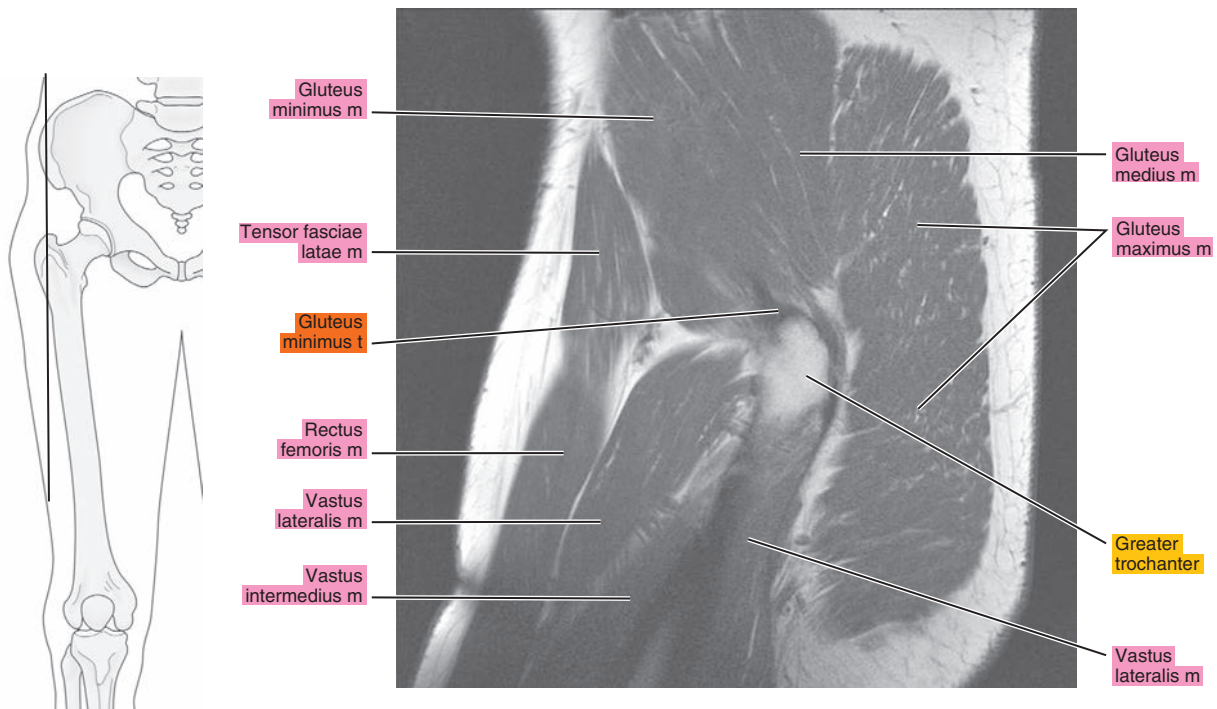




Figure 18.2.5

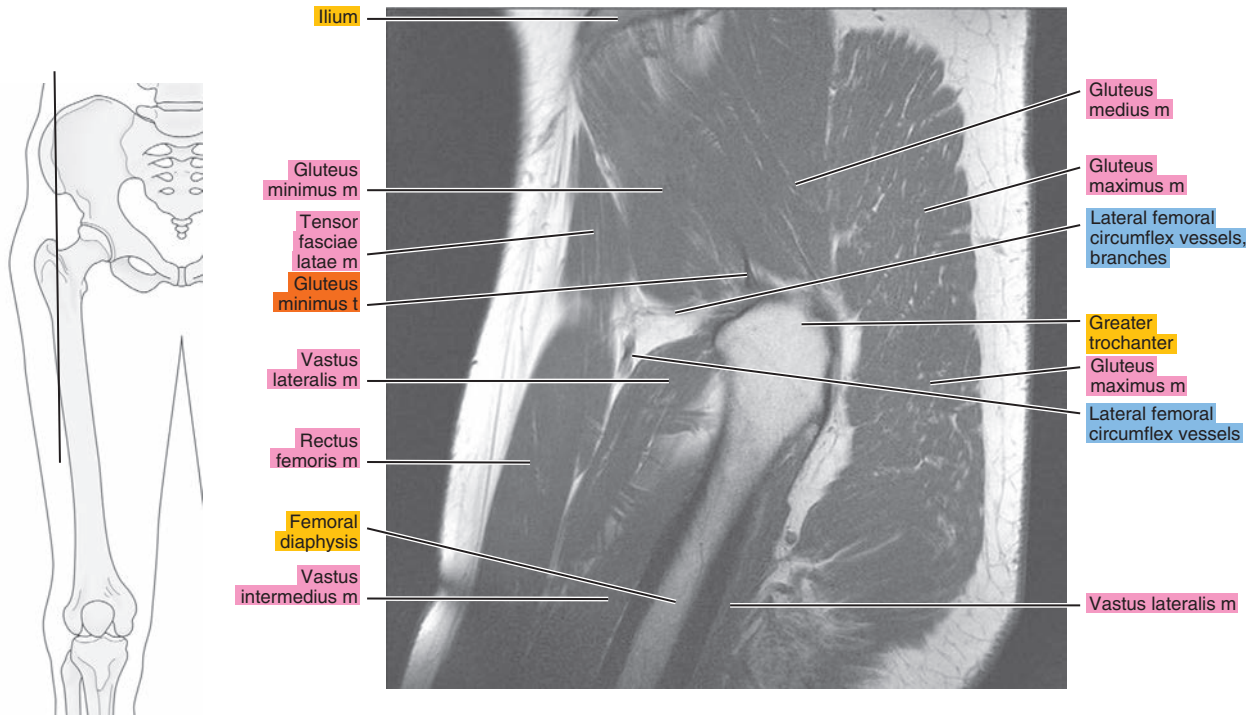


Figure 18.2.6

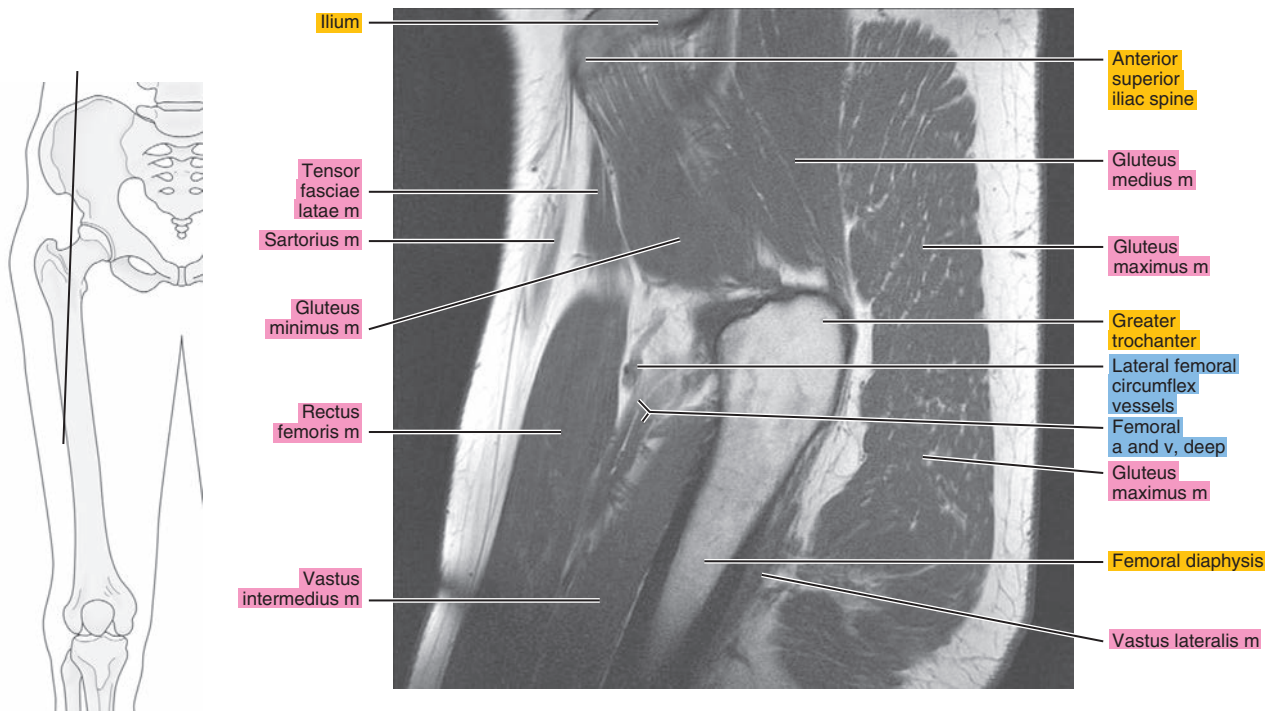




Figure 18.2.7

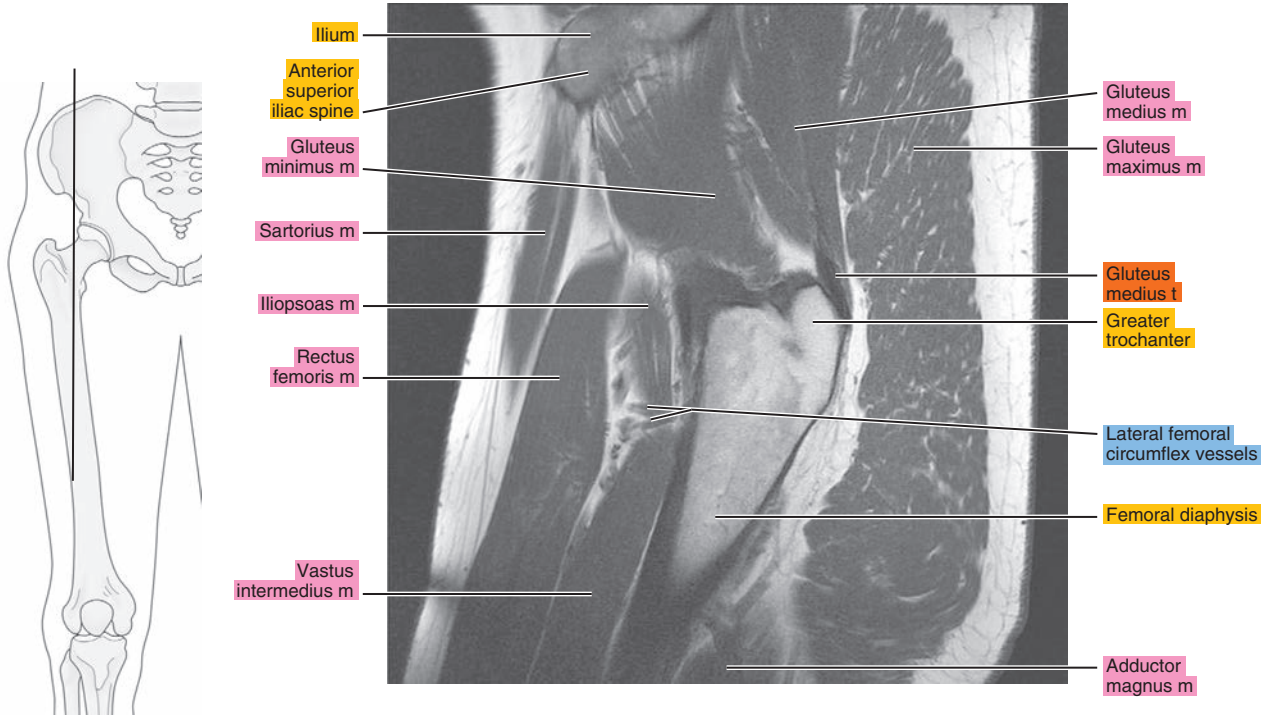


Figure 18.2.8

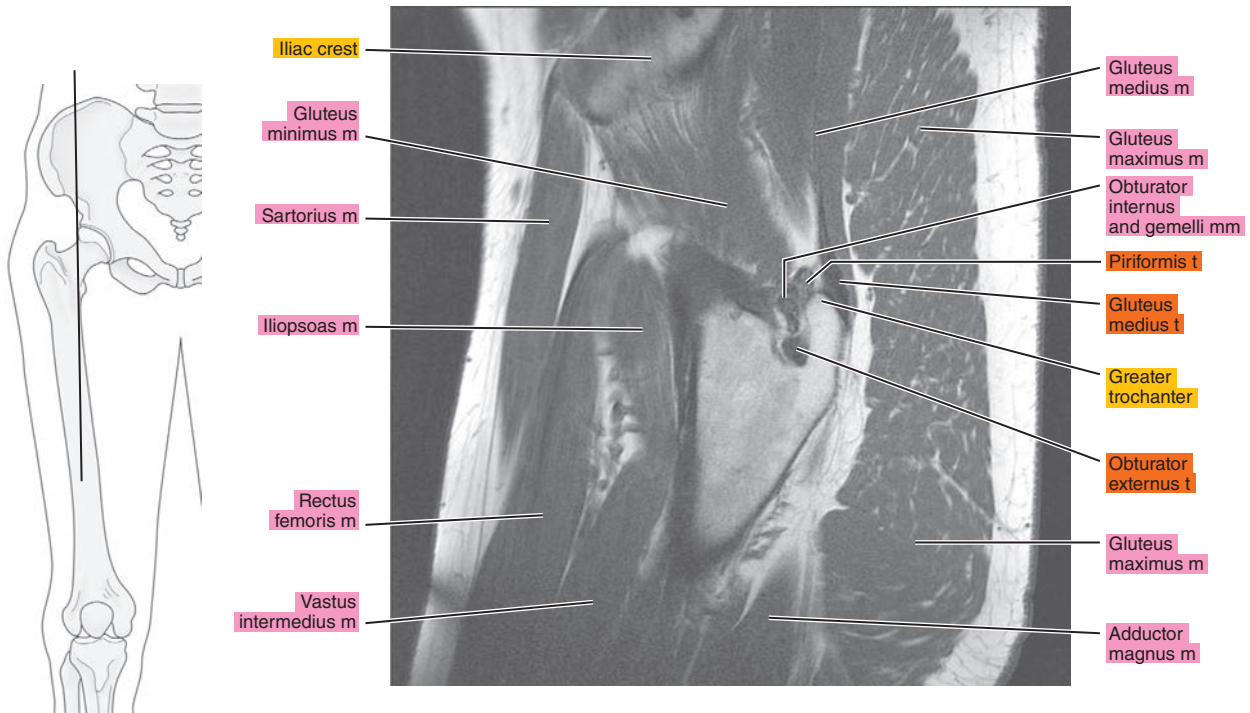


Figure 18.2.9

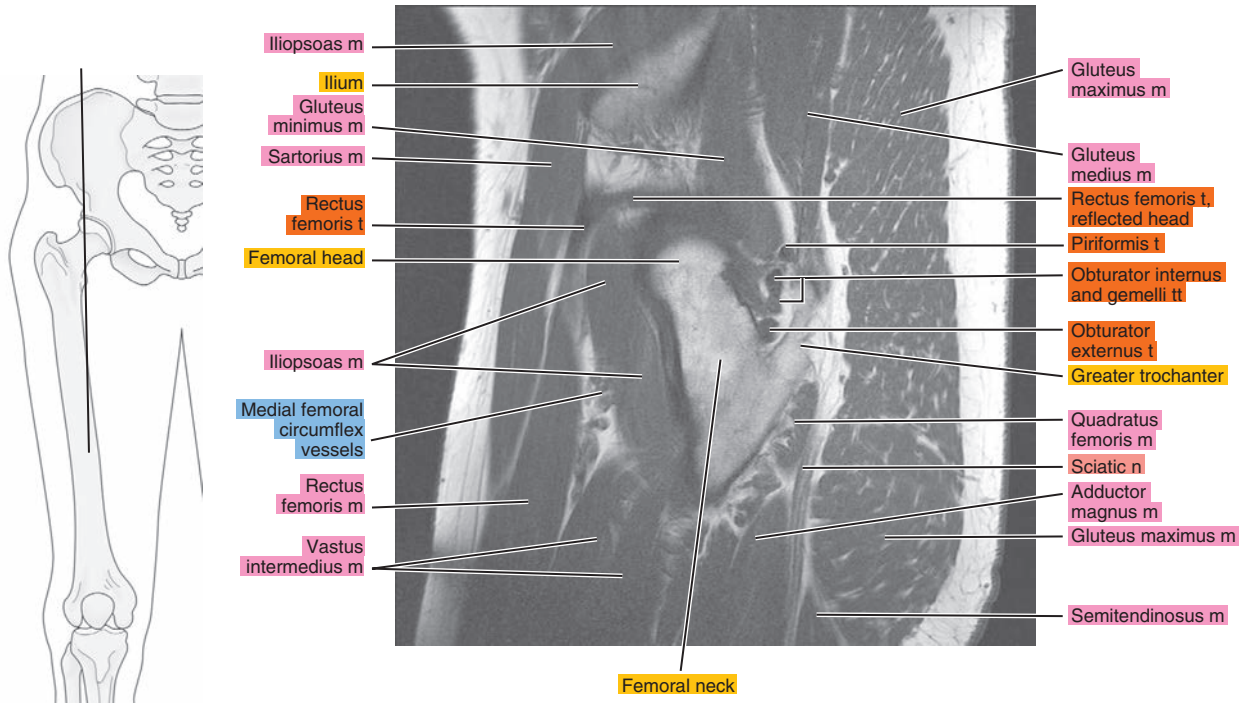


Figure 18.2.10

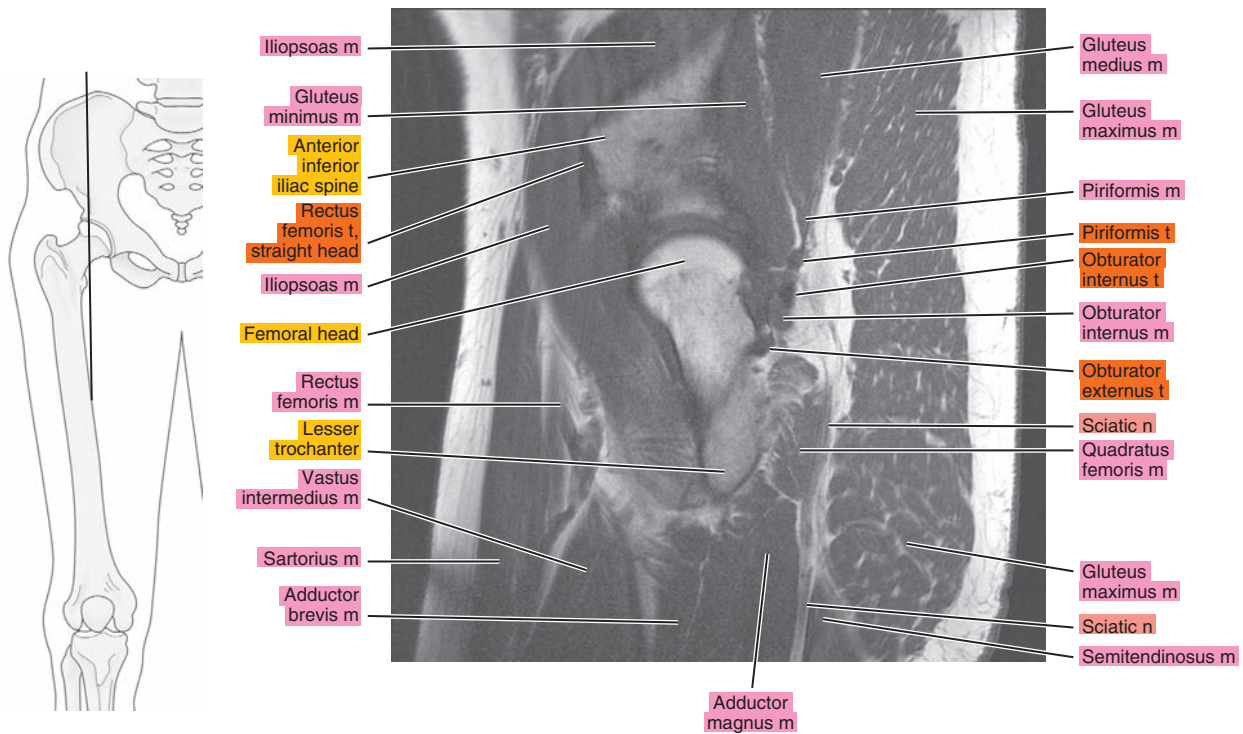


Figure 18.2.11

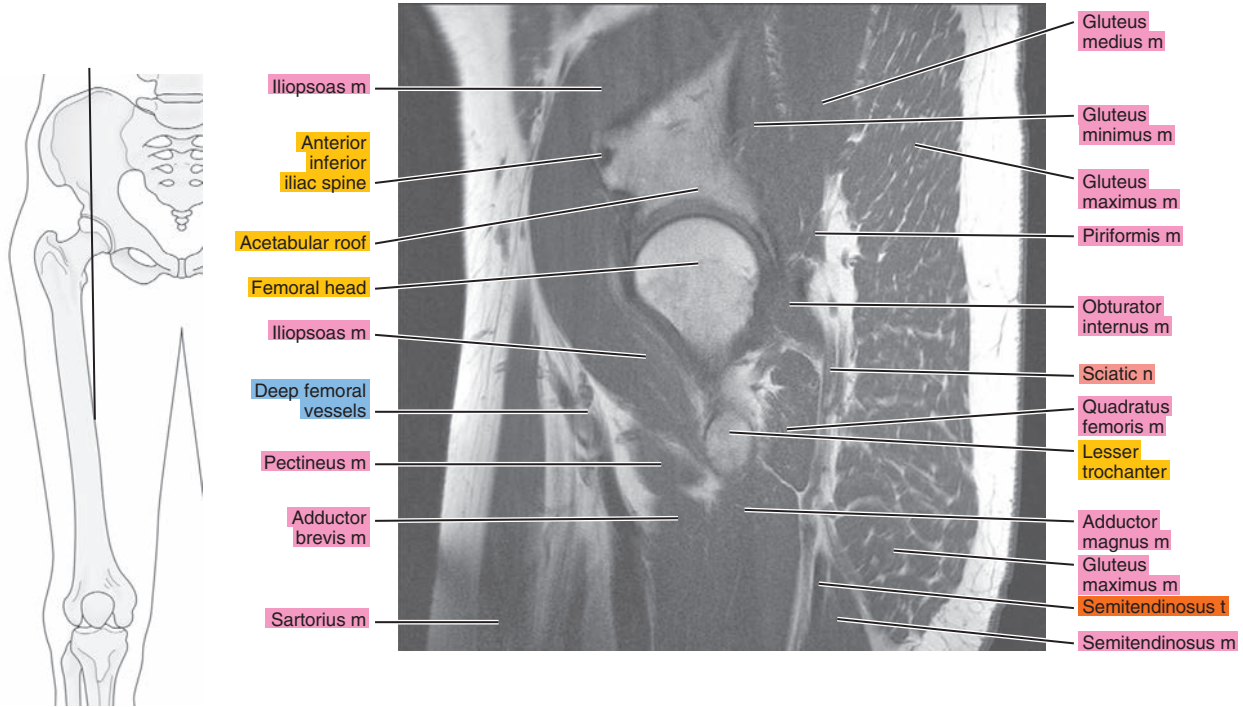

Figure 18.2.12

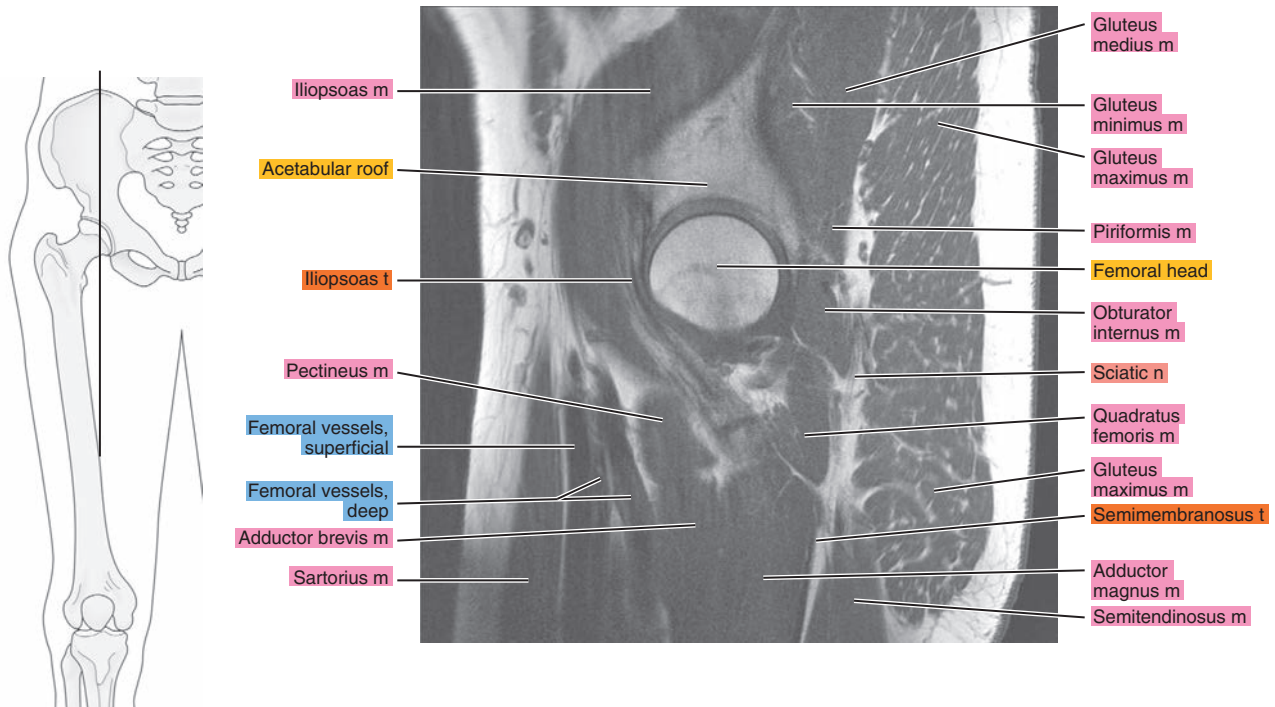




Figure 18.2.13

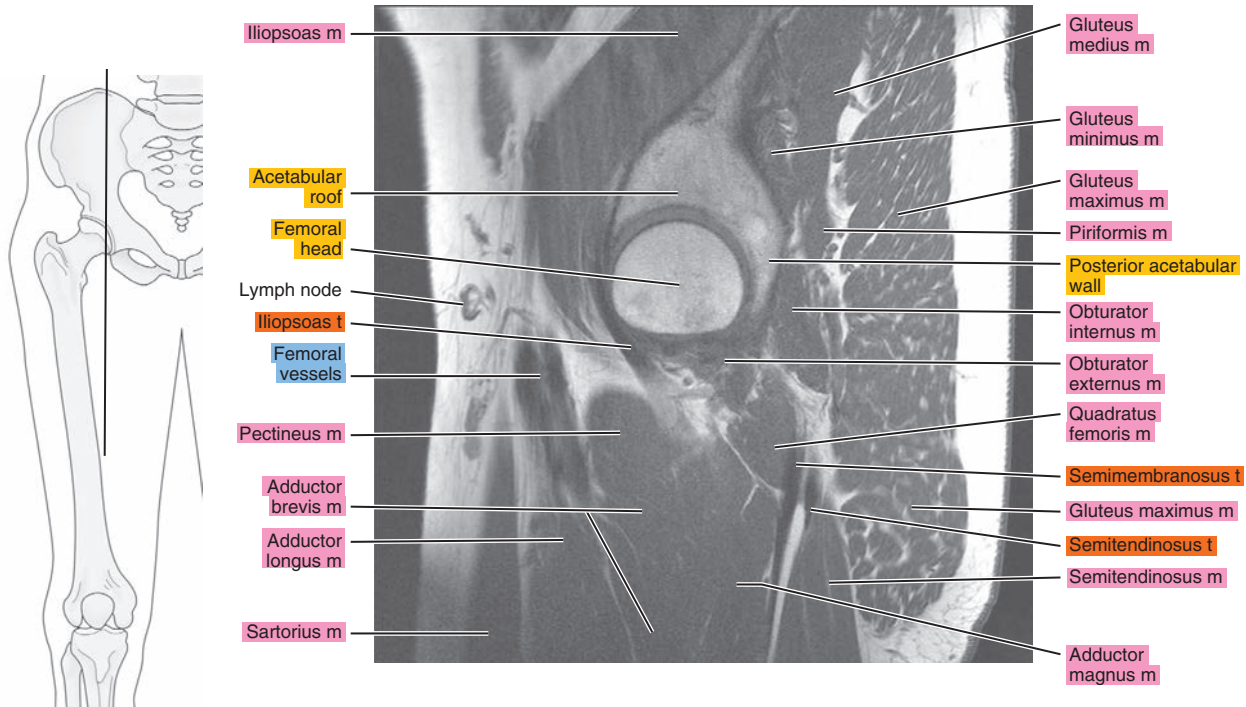


Figure 18.2.14

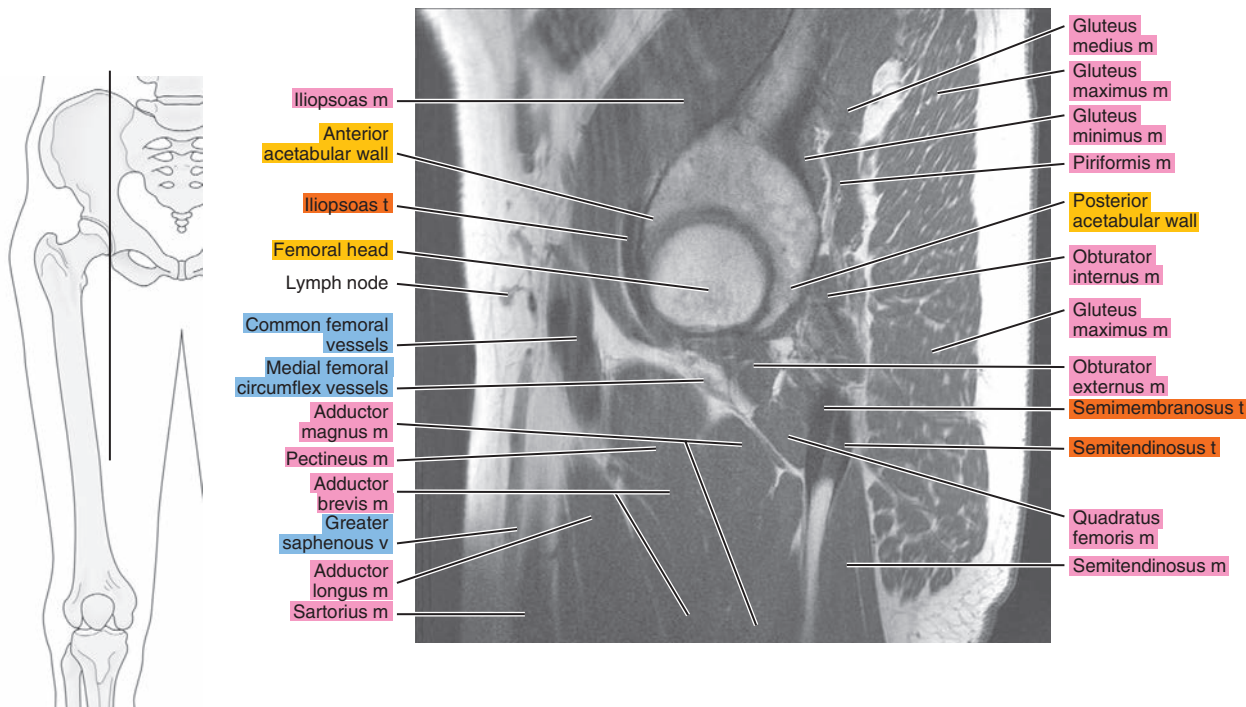




Figure 18.2.15

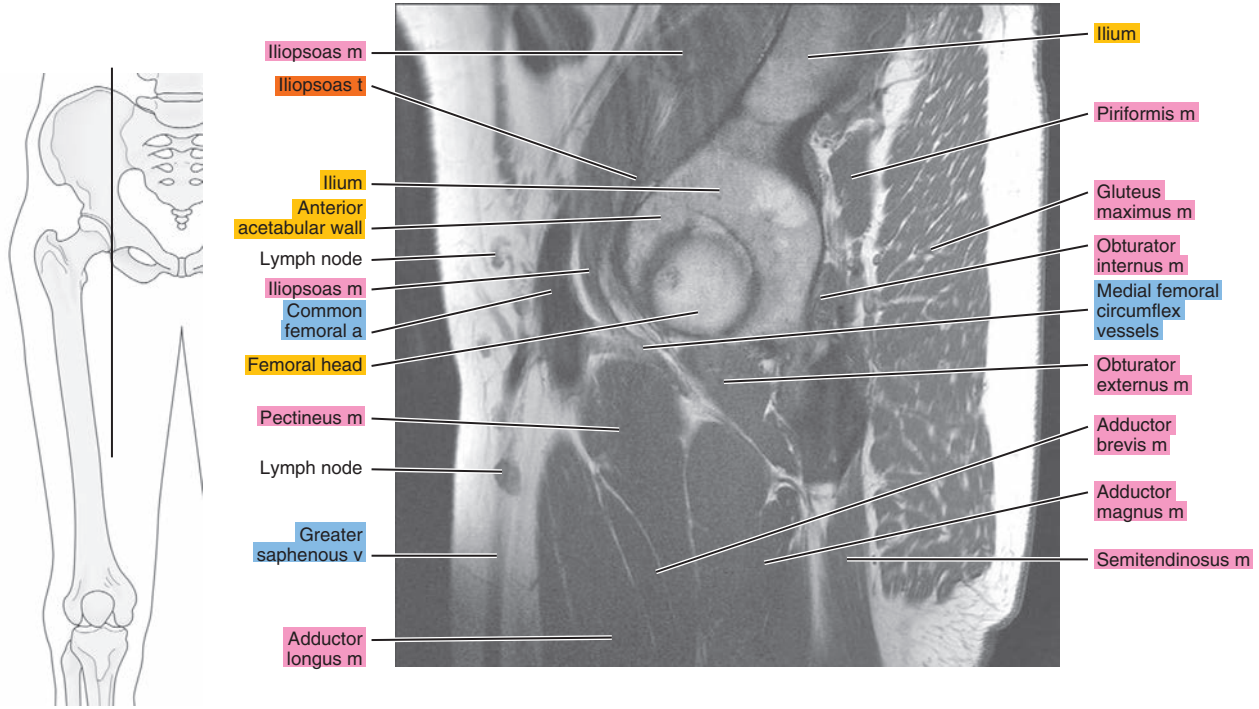


Figure 18.2.16

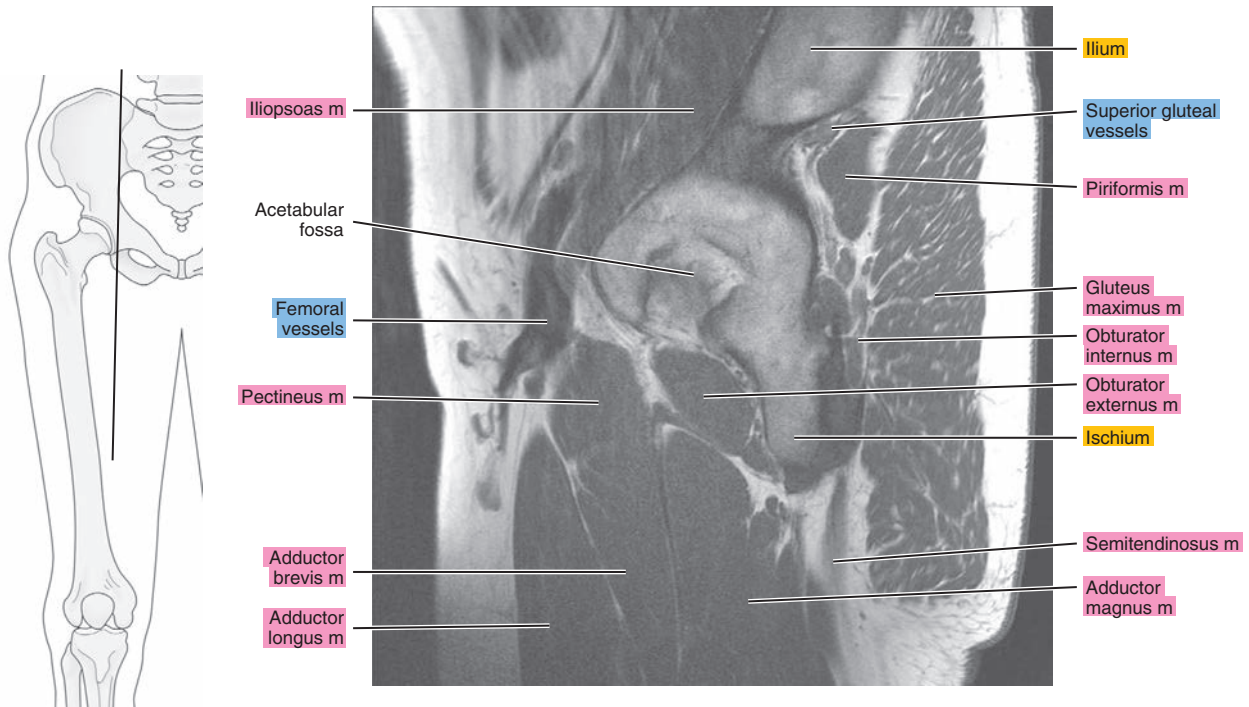


Figure 18.2.17

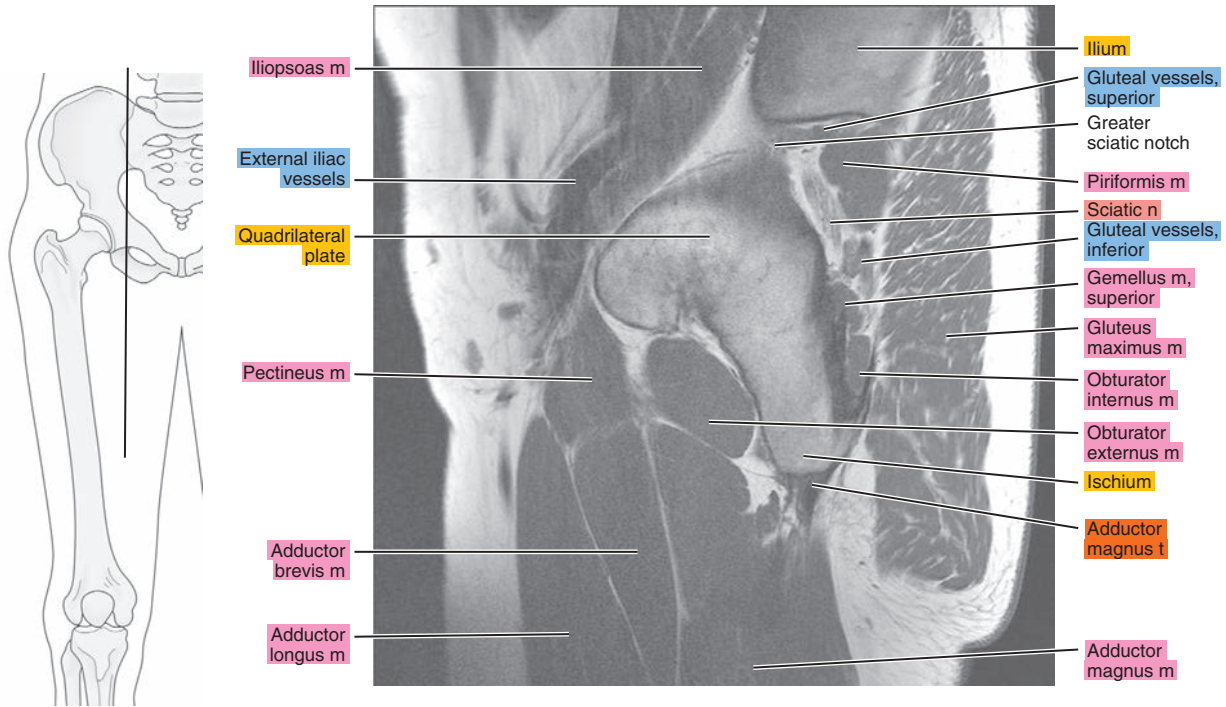


Figure 18.2.18

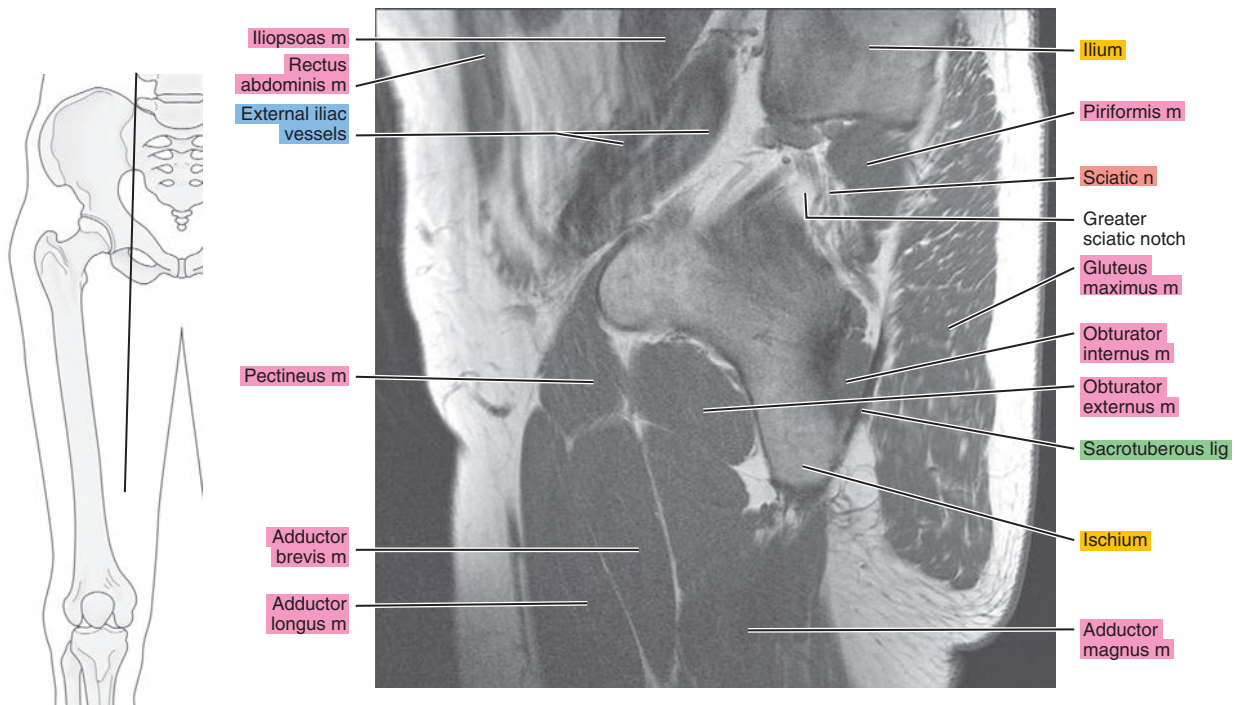
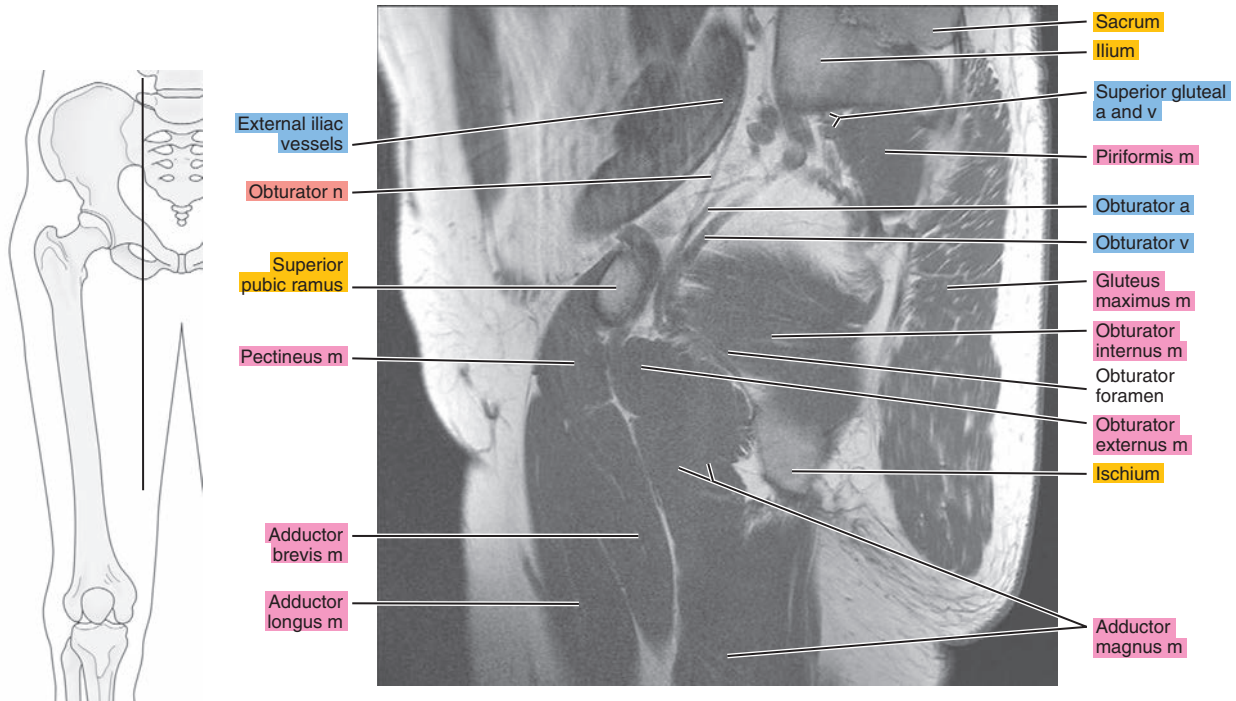


Figure 18.2.19





# CORONAL

Figure 18.3.1

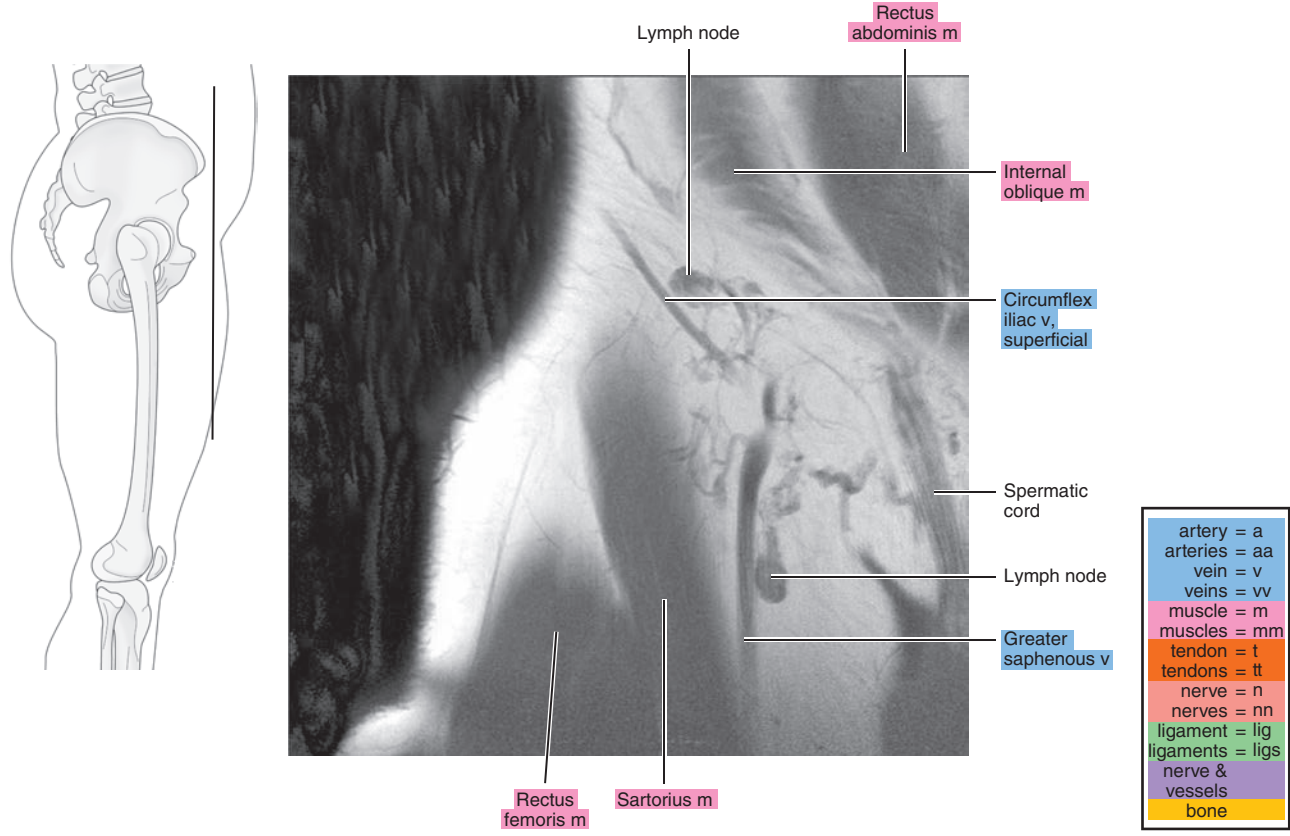


Figure 18.3.2

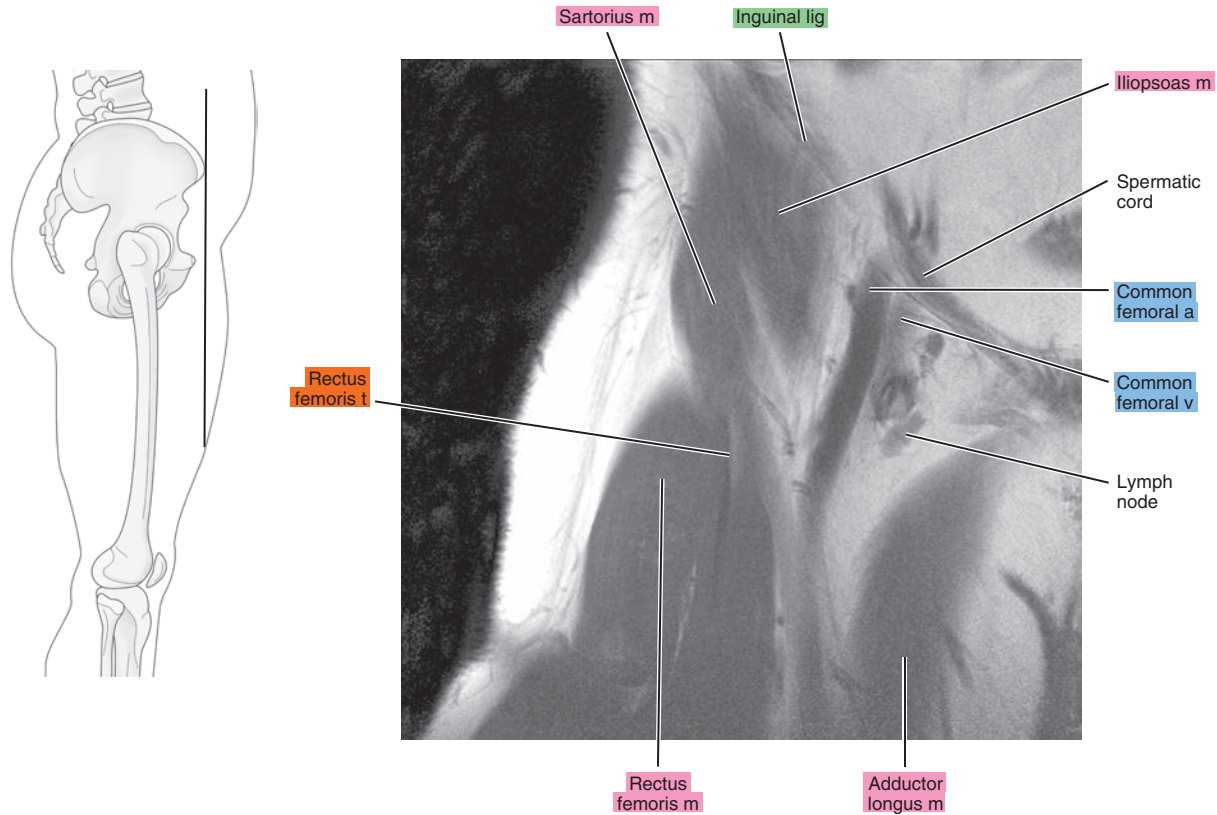




Figure 18.3.3

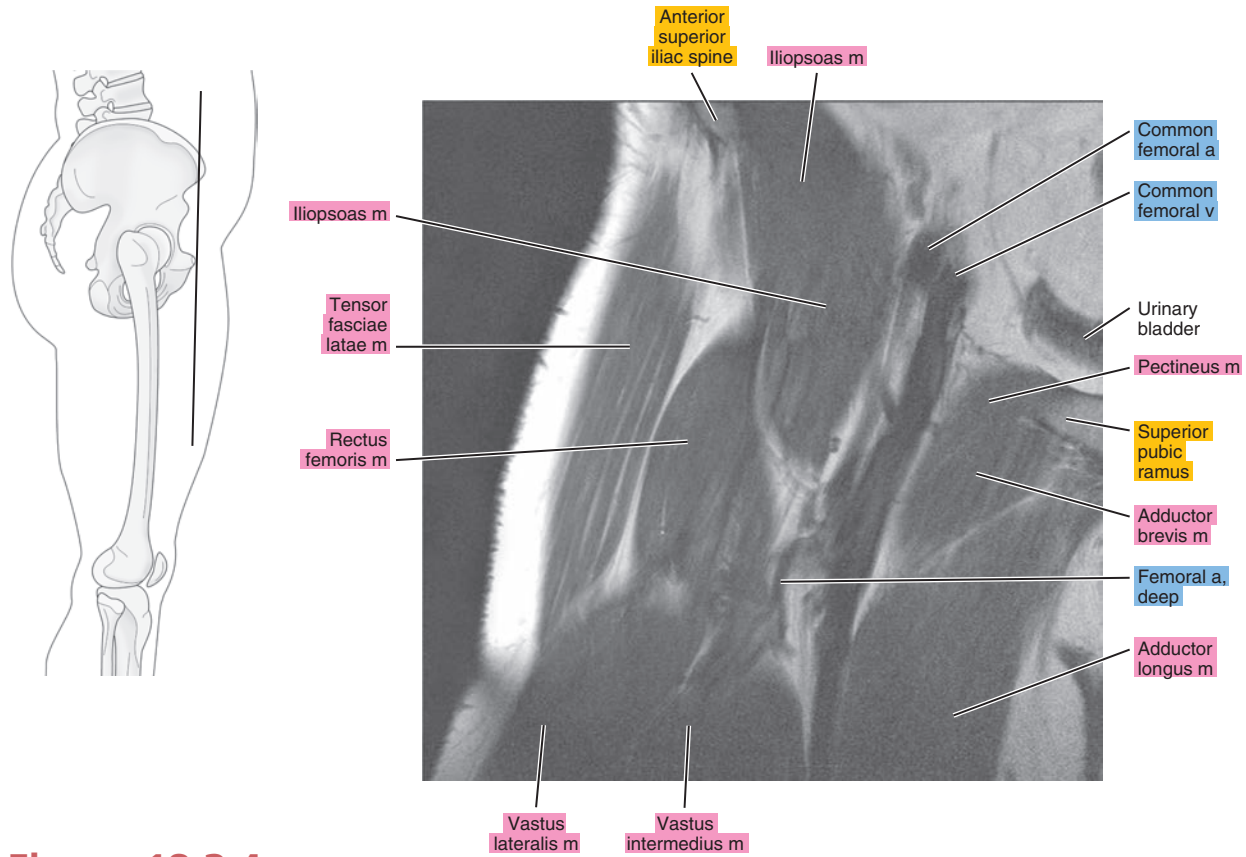


Figure 18.3.4

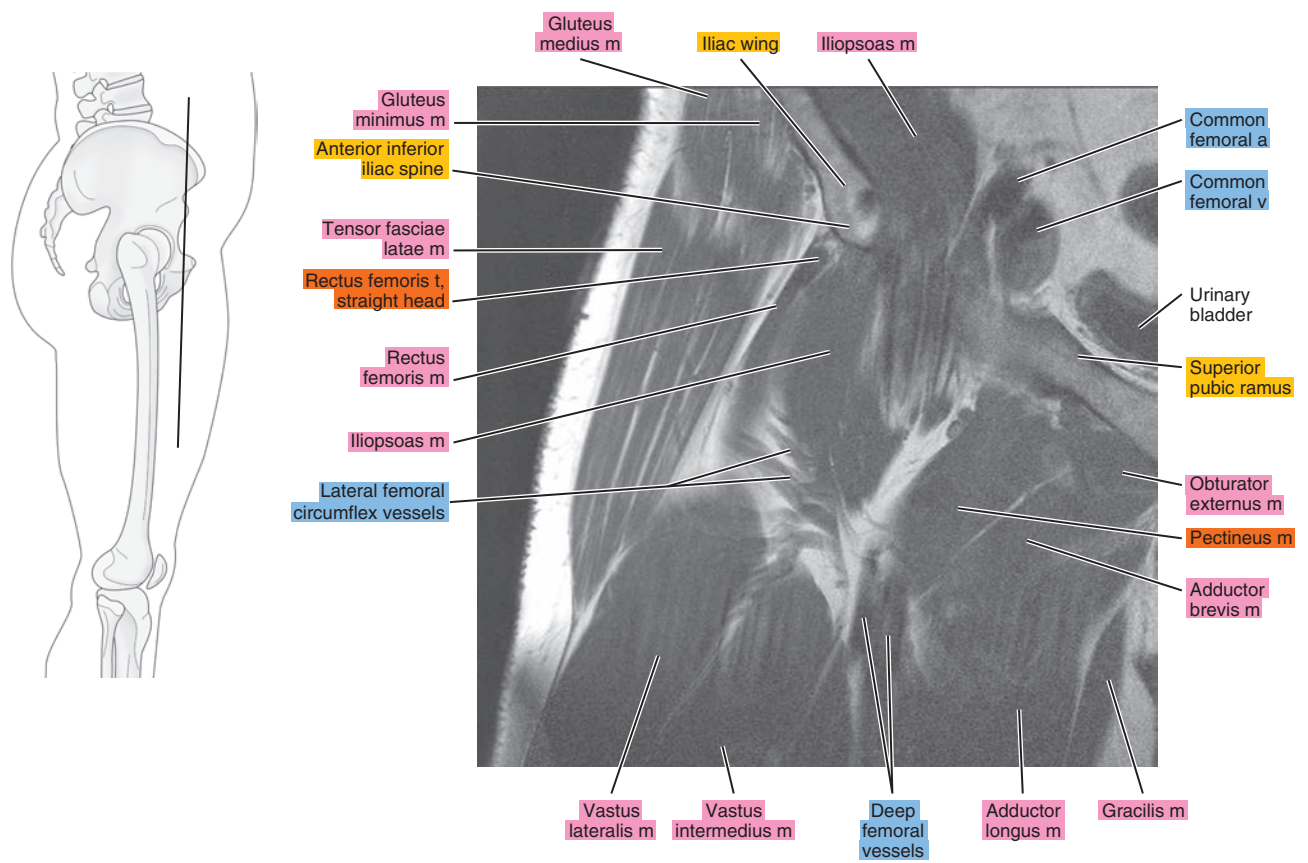


Figure 18.3.5

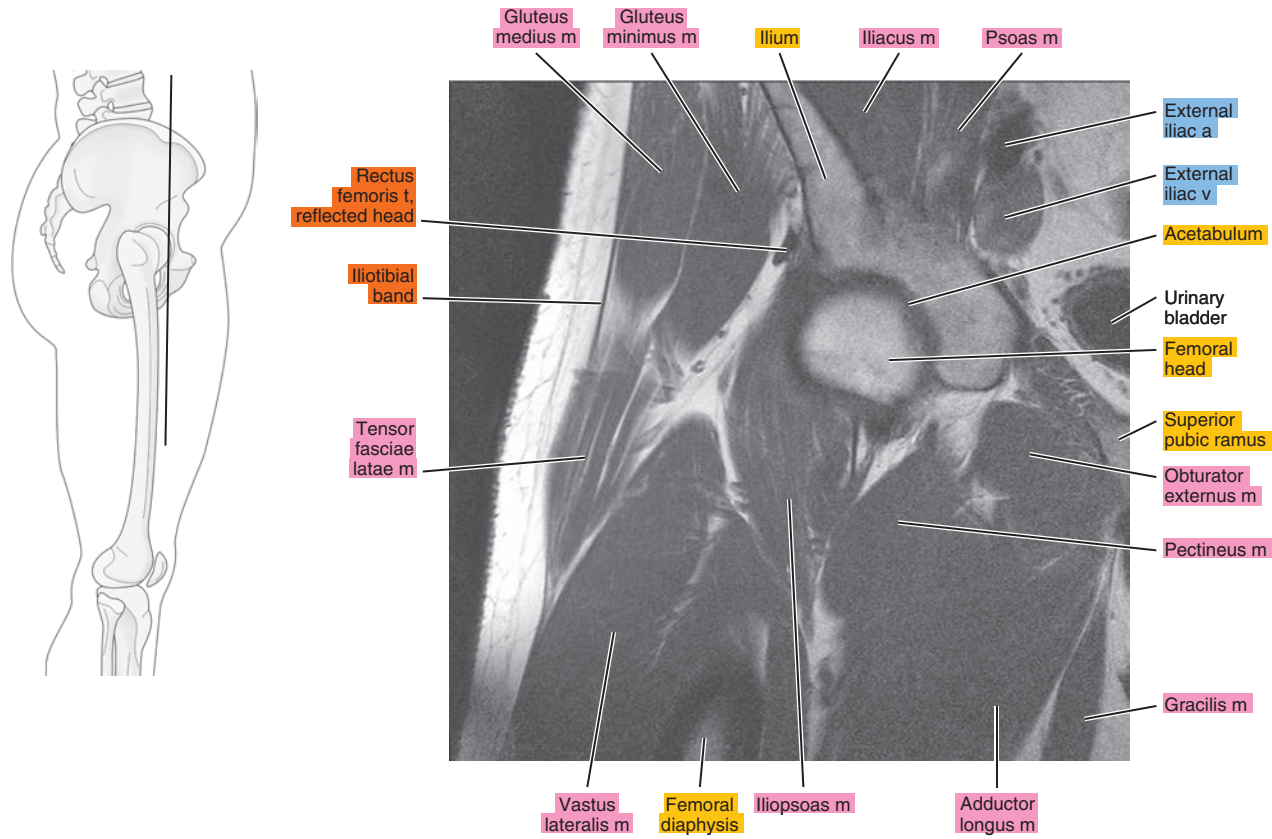


Figure 18.3.6

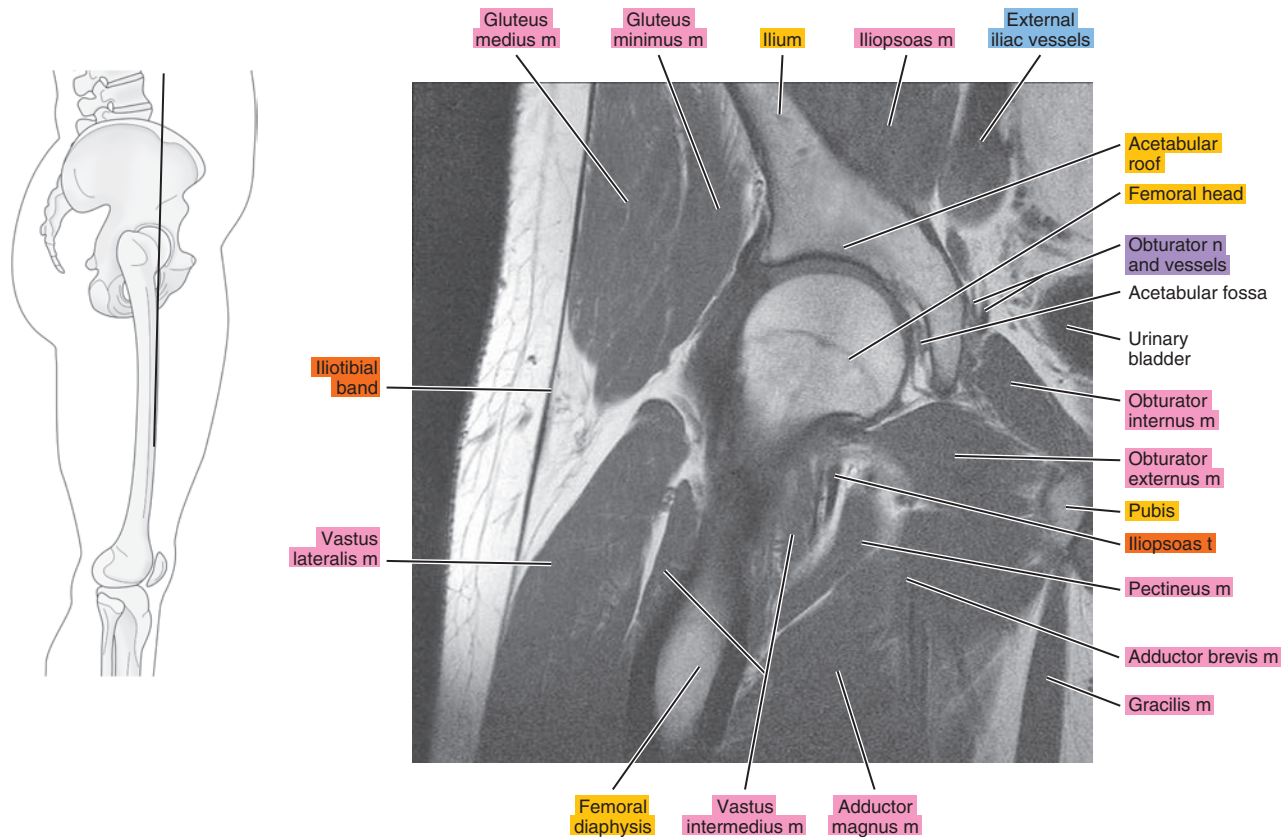




Figure 18.3.7

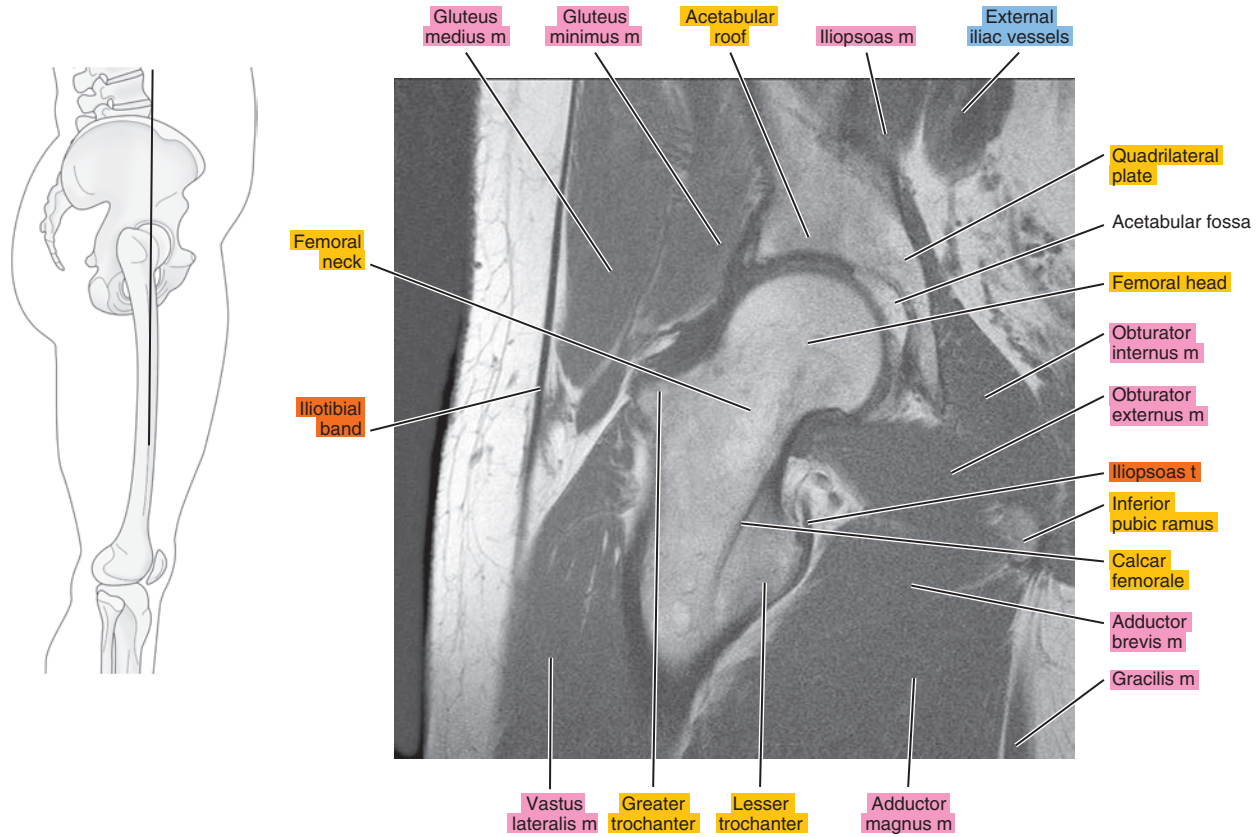


Figure 18.3.8

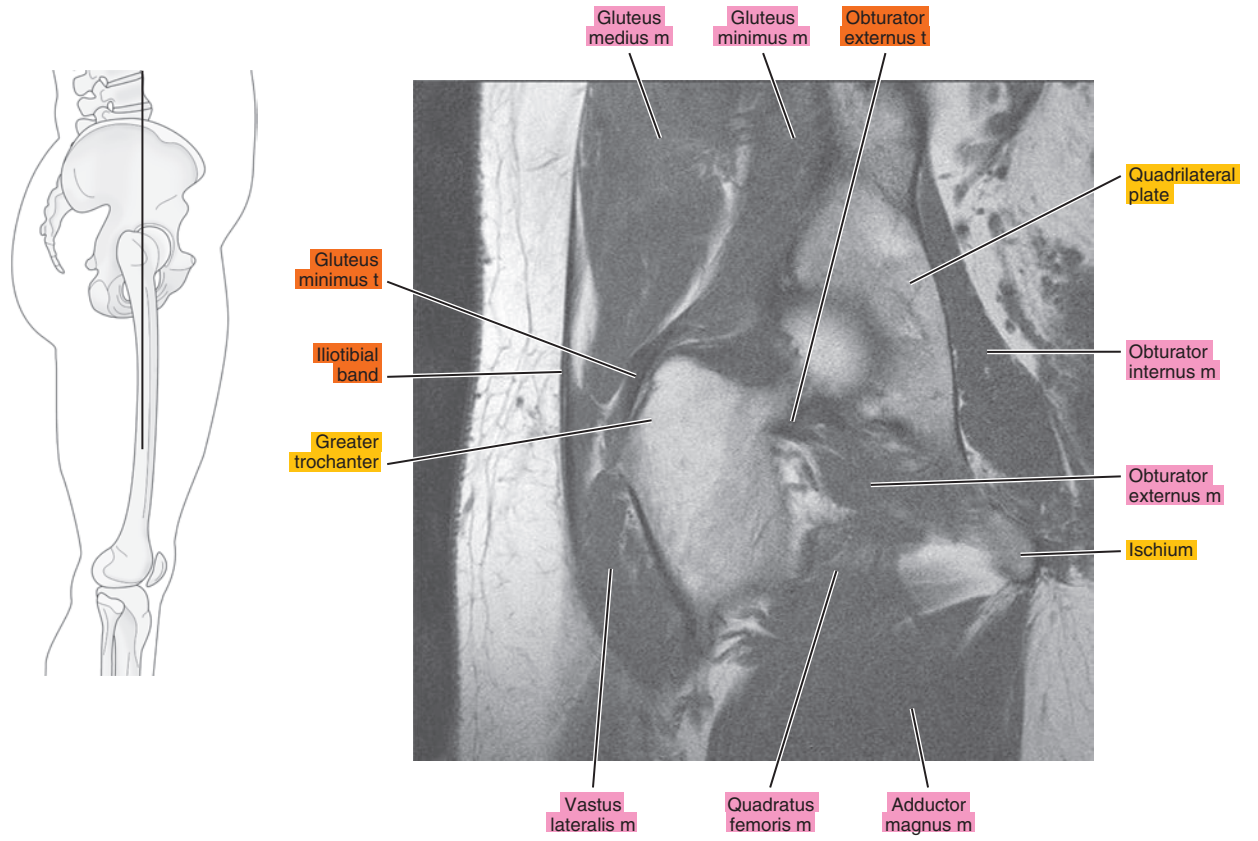


Figure 18.3.9

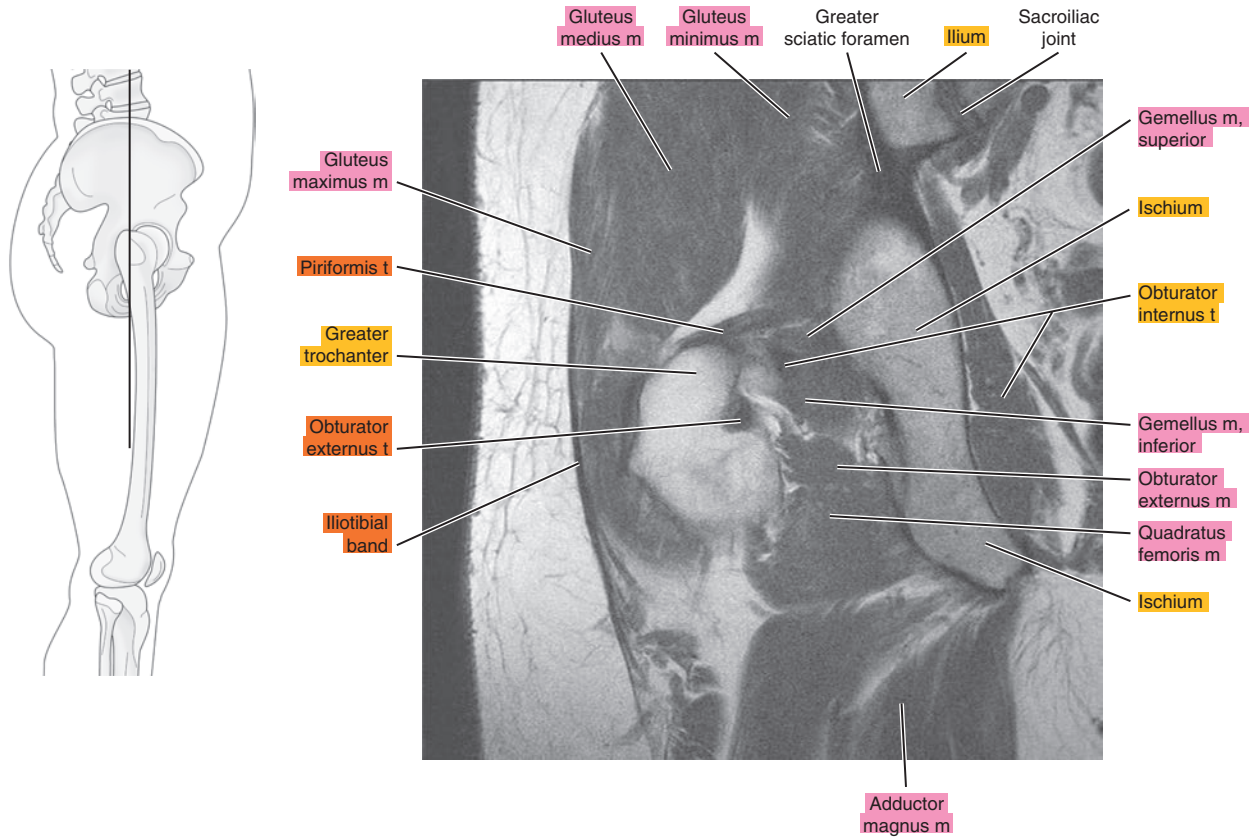


Figure 18.3.10

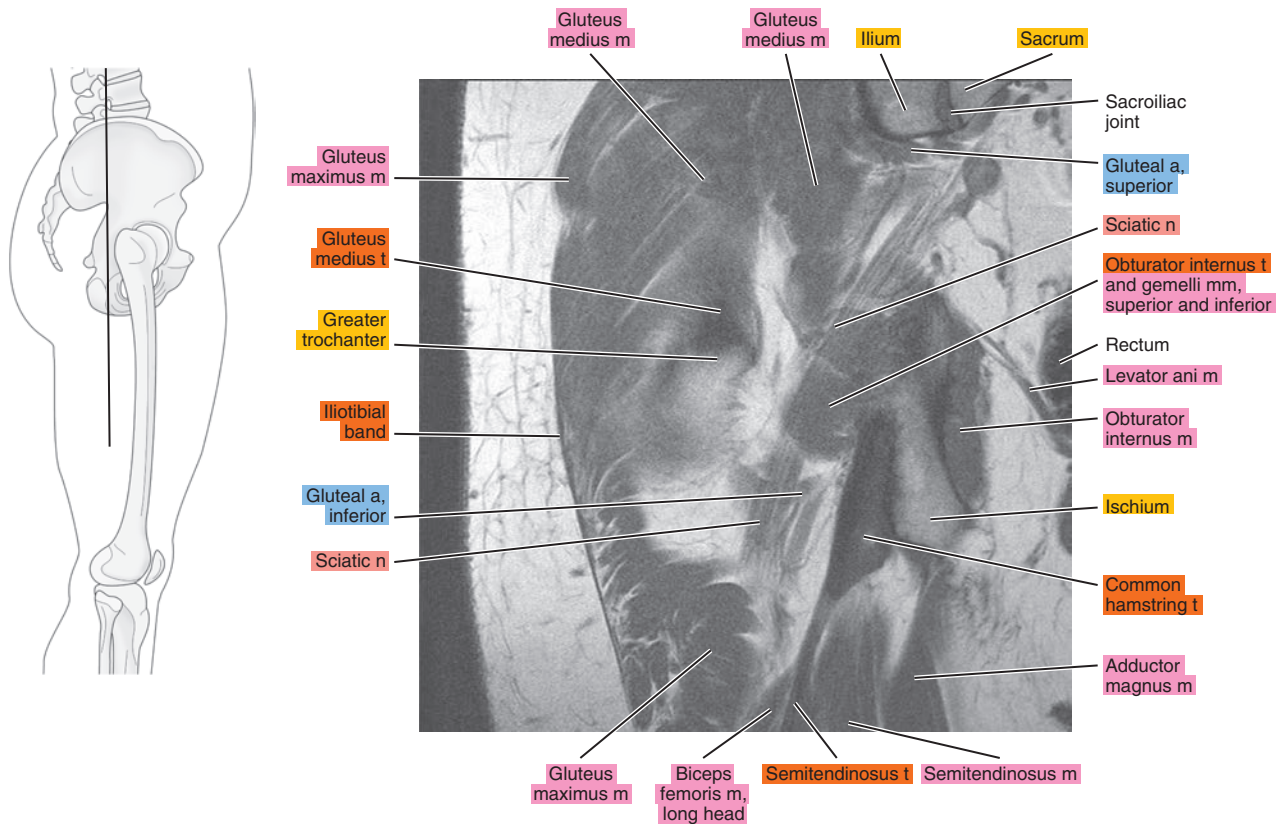




Figure 18.3.11

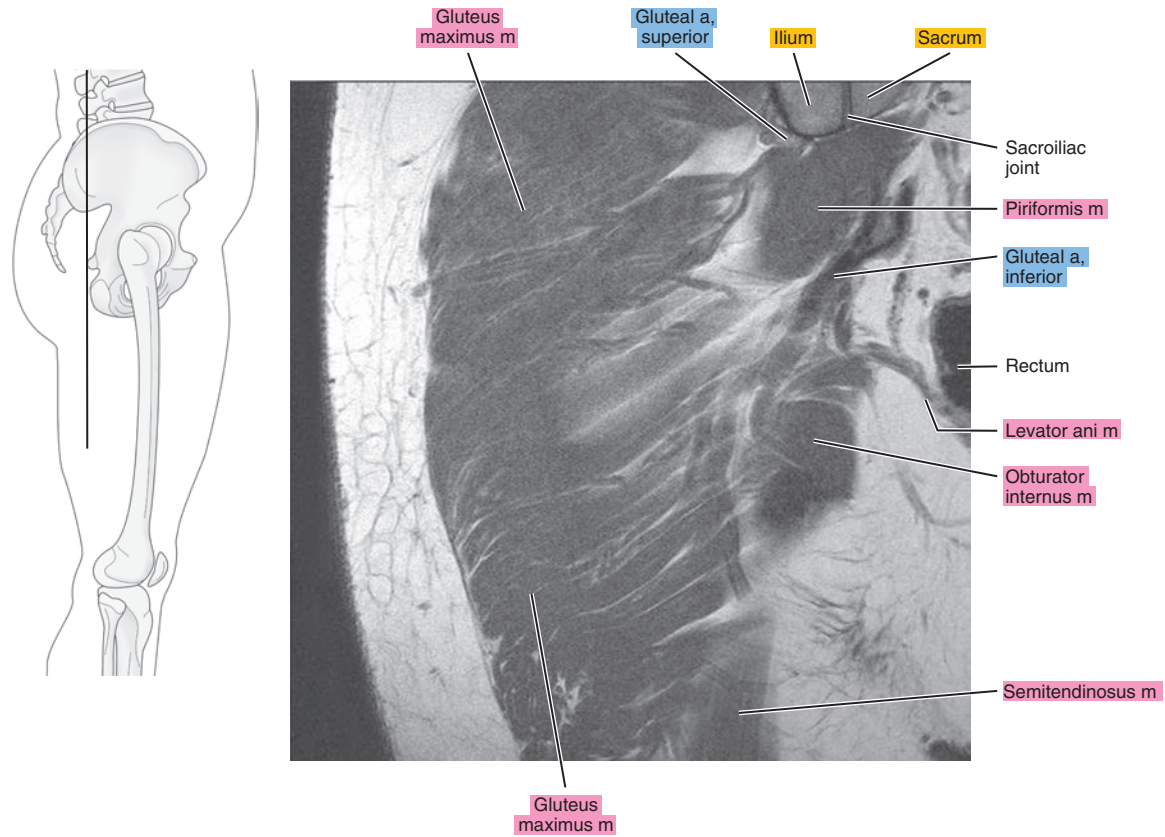


Figure 18.3.12

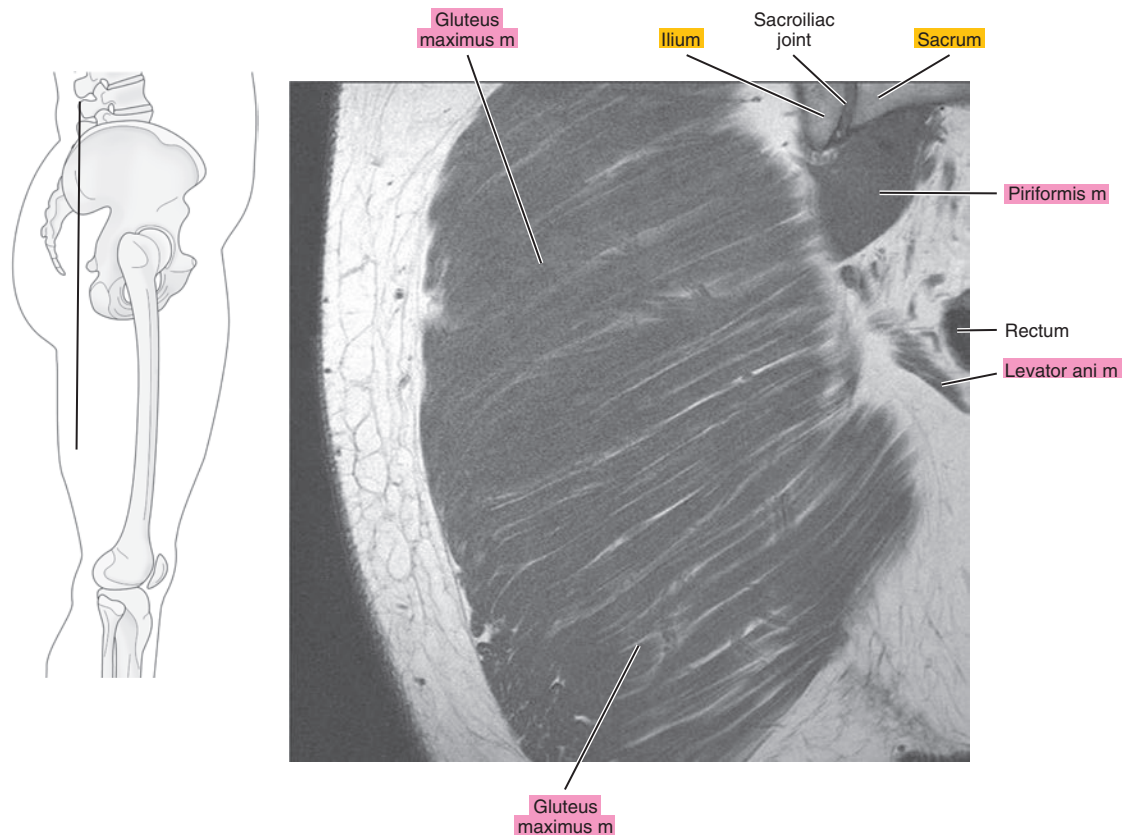
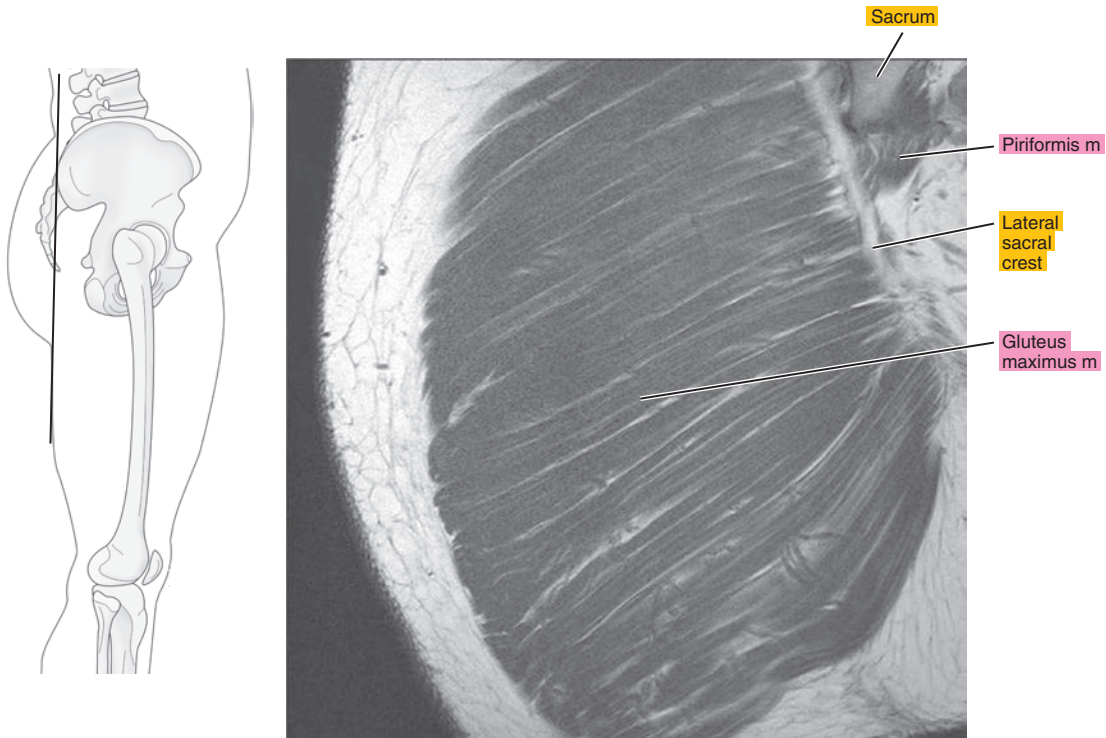


Figure 18.3.13



**Table 18-1. Muscles of the Hip**

MUSCLE	ORIGIN	INSERTION	NERVE SUPPLY
<b>Obturator internus</b>	Pelvic surface of the pubic rami near the obturator foramen, pelvic surface of the ischium between the foramen and the greater sciatic notch, deep surface of the obturator internus fascia, fibrous arch that surrounds the foramen for obturator vessels and nerve, most of the pelvic surface of the obturator membrane except the lower part	Medial side of the greater trochanter in front of the trochanteric fossa of the femur	Nerve to the obturator internus, from the lumbosacral trunk, and first and second sacral
<b>Obturator externus</b>	Lateral surface of the pubic and ischial rami, where they surround the obturator membrane, lateral surface of the obturator membrane	Trochanteric fossa	Obturator
<b>Gemellus superior</b>	Outer surface of the ischial spine and edge of the lesser sciatic notch	After union with the tendon of the obturator internus, inserts into the medial side of the greater trochanter in front of the trochanteric fossa	By a small nerve, branch of the nerve to obturator internus or branch of the nerve to the quadratus femoris
<b>Gemellus inferior</b>	Upper part of the inner border of the tuberosity of the ischium, sacrotuberous ligament, and edge of the lesser sciatic notch	By union with the tendon of the obturator internus or with the tendon onto the greater trochanter below the obturator internus muscle	By a small branch of the nerve to the quadratus femoris
<b>Quadratus femoris</b>	Upper part of the outer border of the tuberosity of the ischium	The inferior dorsal angle of the greater trochanter	Lumbosacral trunk and first sacral
<b>Psoas major</b>	By a series of thick fasciculi from the intervertebral discs and bodies between T12 and L5, from the bodies of L1 to L4, and from slender fascicles from the ventral surfaces of the transverse processes of the lumbar vertebrae	The lesser trochanter of the femur	Branches from L1 (often), L2, L3, and L4
<b>Iliacus</b>	Iliac crest, iliolumbar ligament, iliac fossa, anterior sacroiliac ligaments, often from the ala of the sacrum, and from the ventral border of the ilium between the two anterior spines	Lateral surface of the psoas tendon (above the inguinal ligament) onto the femur immediately distal to the lesser trochanter; the lateral portion arises from the ventral border of the ilium and is attached to the tendon of the rectus femoris and the capsule of the hip joint	Femoral and L1 to L4
<b>Tensor fasciae latae</b>	Anterior superior iliac spine and anterior part of the external lip of the iliac crest	Muscle fibers pass distally in a parallel array, unite with the tendon, and join the iliotibial tract about one-third of the way down the thigh	Superior gluteal
<b>Gluteus medius</b>	Ventral three-fourths of the iliac crest, outer surface of the ilium between the anterior and posterior gluteal lines, and from the investing fascia	Onto the posterosuperior angle and the external surface of the greater trochanter	Superior gluteal (L4, L5, and S1)

**Table 18-1. Muscles of the Hip**

MUSCLE	ORIGIN	INSERTION	NERVE SUPPLY
<b>Piriformis</b>	Lateral part of the ventral surface of S2, S3, and S4, posterior border of the greater sciatic notch, from the sacrotuberous ligament near the sacrum	Onto the anterior and inner parts of the upper border of the greater trochanter	S1 or S2 or from a loop between S1 and S2
<b>Gluteus maximus</b>	Dorsal fifth of the outer lip of the iliac crest, ilium dorsal to the posterior gluteal line, thoracolumbar fascia between the posterior superior spine of the ilium and the side of the sacrum, lateral parts of S4, S5, and coccygeal vertebrae, and from the back of the sacrotuberous ligament	Into the iliotibial tract, gluteal tuberosity of the femur, adjacent part of the tendinous origin of the vastus lateralis	Inferior gluteal by two branches from the sacral plexus (separately or as a united nerve)
<b>Gluteus minimus</b>	Outer surface of the ilium between the anterior and inferior gluteal lines, from the septum between the gluteus minimus and the gluteus medius near the anterior superior iliac spine and the capsule of the hip joint	Onto the anterior border of the greater trochanter of the femur	Superior gluteal from a branch that supplies the tensor fasciae latae
<b>Biceps femoris, long head</b>	Medial facet on the posterior surface of the ischial tuberosity and sacrotuberous ligament	By a tendon that extends to the head of the fibula	Tibial part of the sciatic
<b>Semitendinosus</b>	Distal margin of the ischial tuberosity and from the tendon common to it and the long head of the biceps femoris	By a triangular tendinous expansion into the proximal part of the medial surface of the tibia behind and distal to the insertion of the gracilis	Sciatic or directly from the lumbosacral plexus by two nerves: from S1 and S2 and from L5 and S1
<b>Semimembranosus</b>	Lateral facet on the posterior surface of the ischial tuberosity	Posterior aspect of the medial tibial condyle	Sciatic branch (also supplies the adductor magnus)



*Chapter*  
**19**

**MR Arthrography of  
the Hip**

# AXIAL

Figure 19.1.1

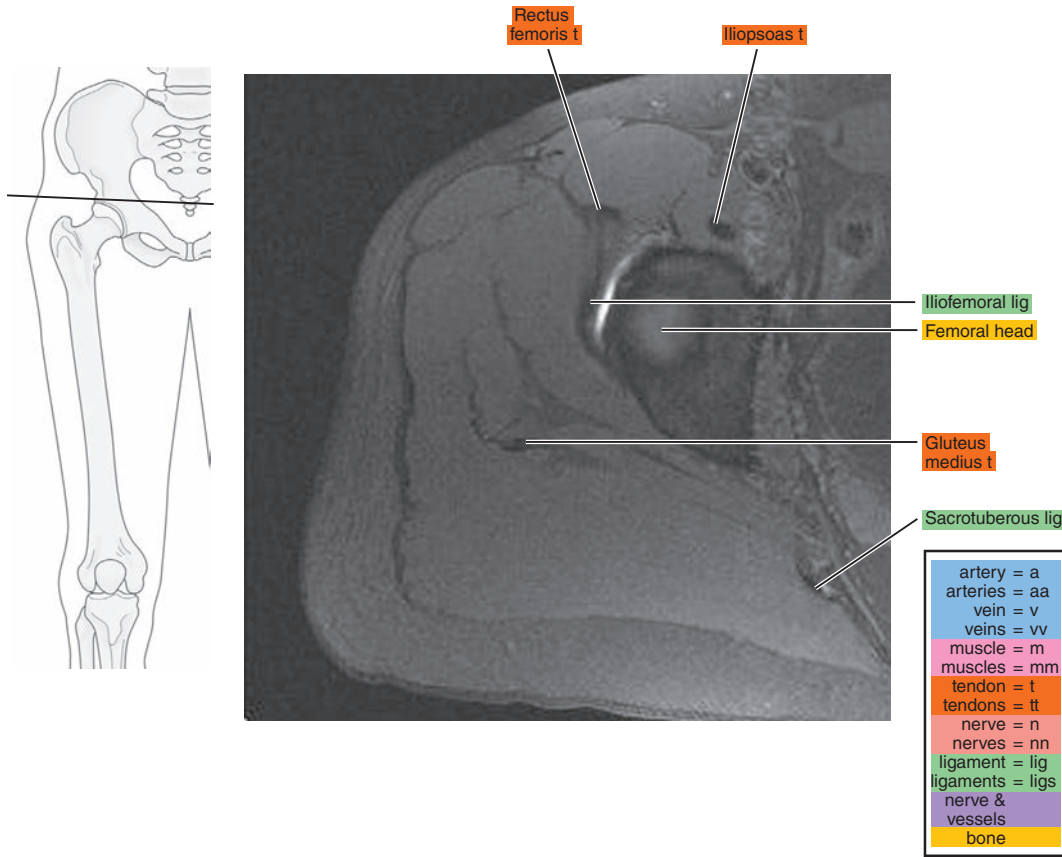


Figure 19.1.2

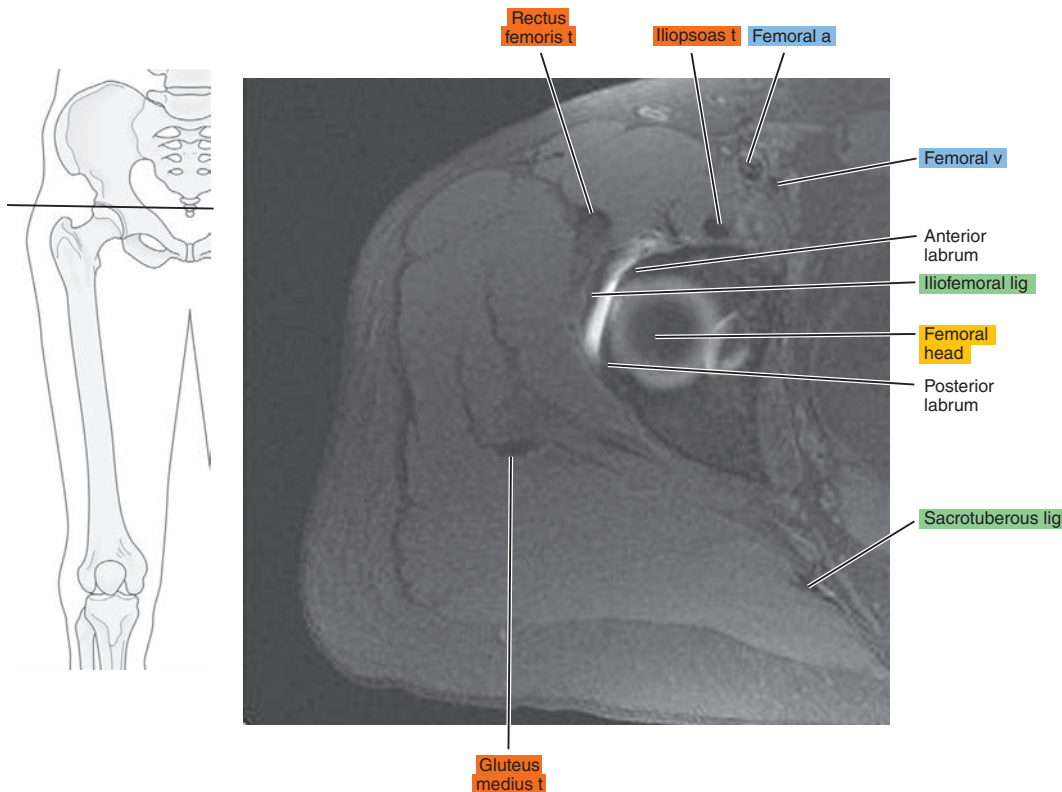


Figure 19.1.3

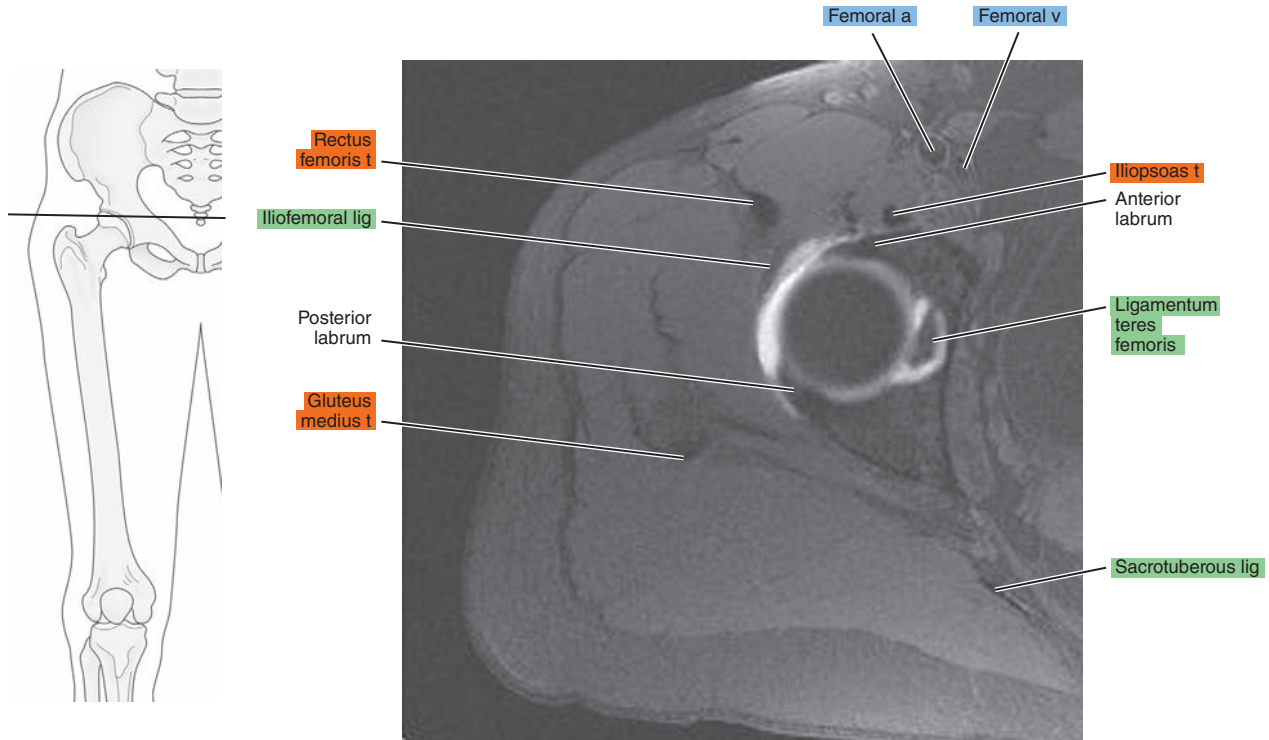


Figure 19.1.4

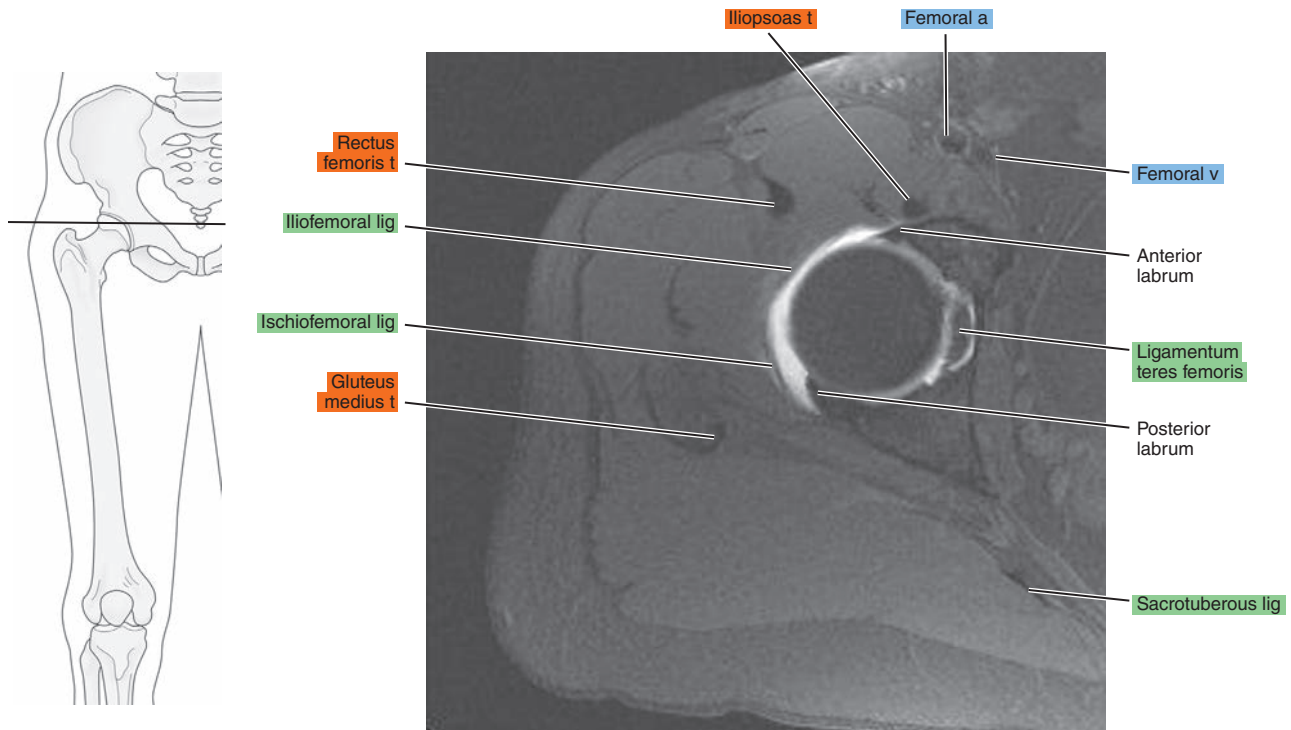


Figure 19.1.5

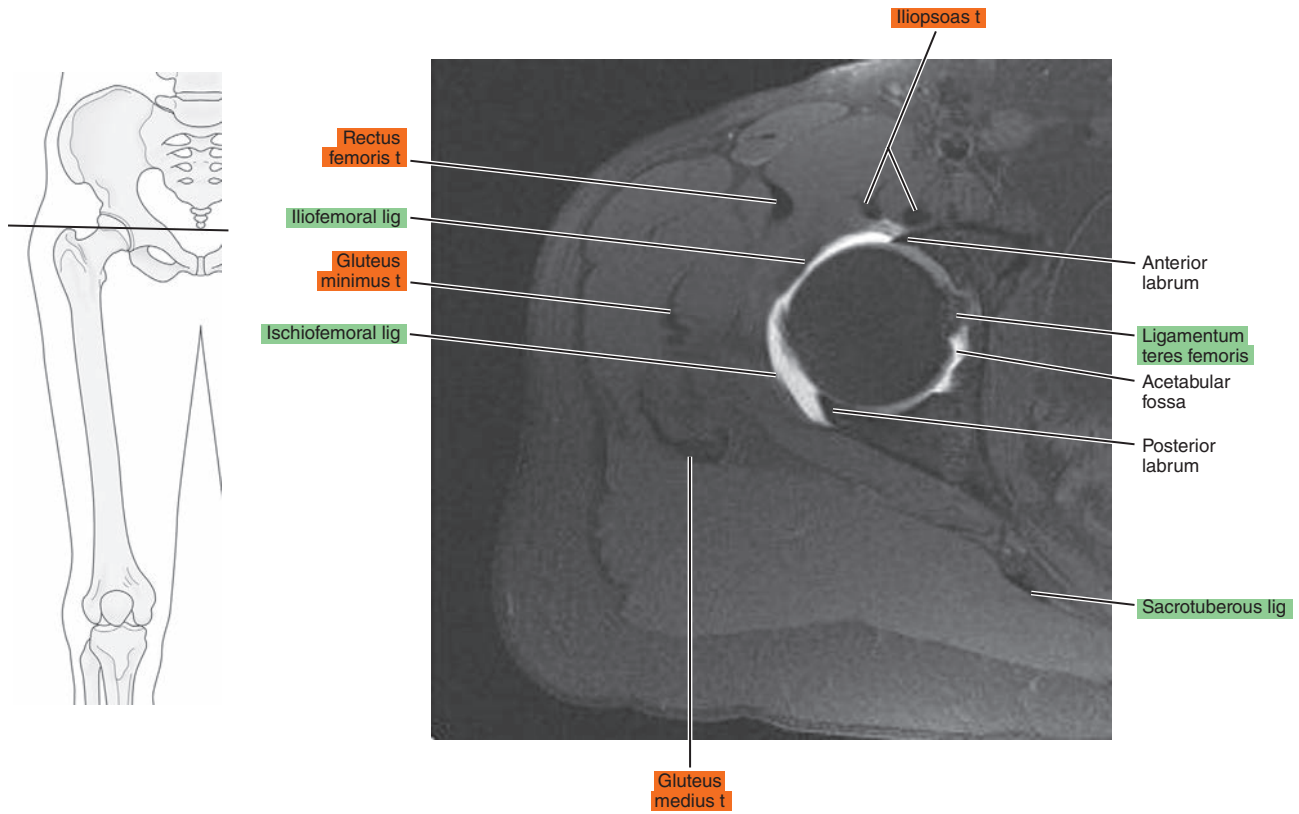


Figure 19.1.6

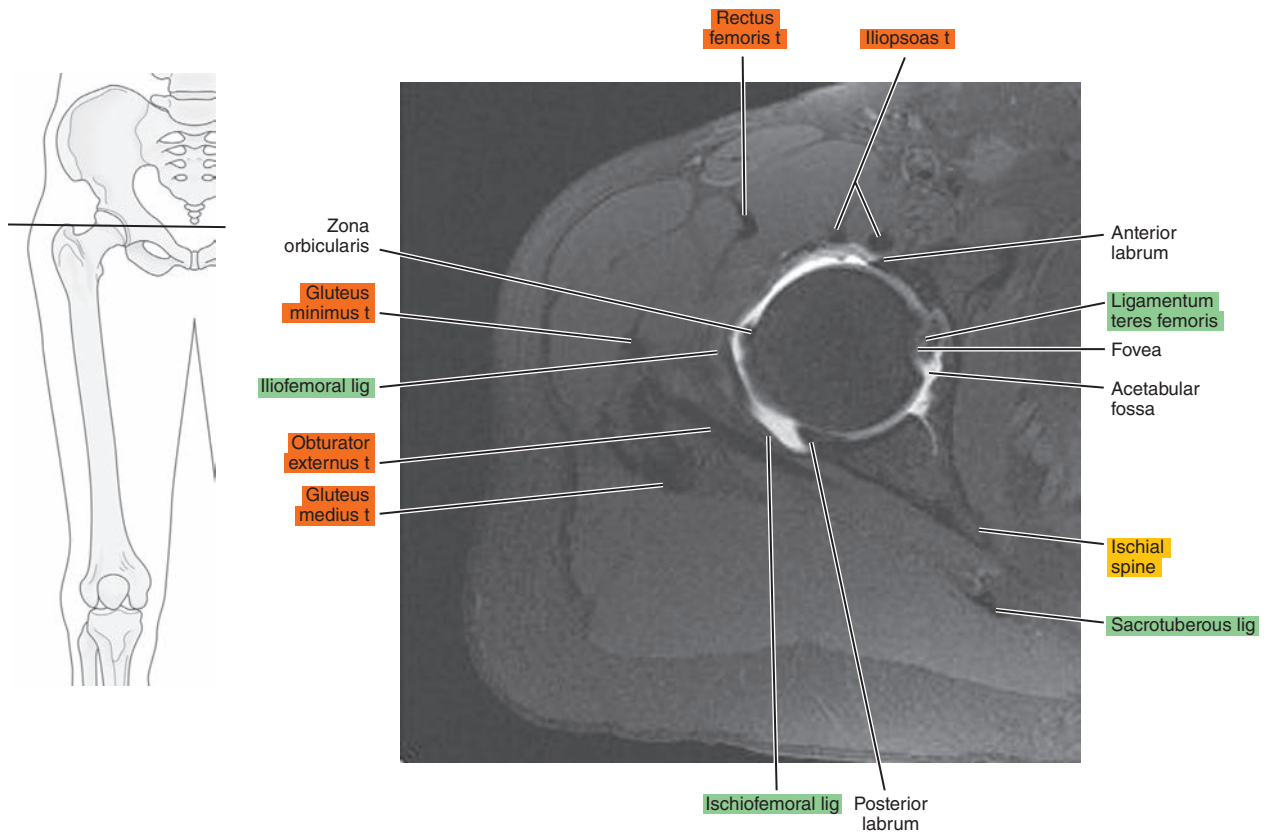




Figure 19.1.7

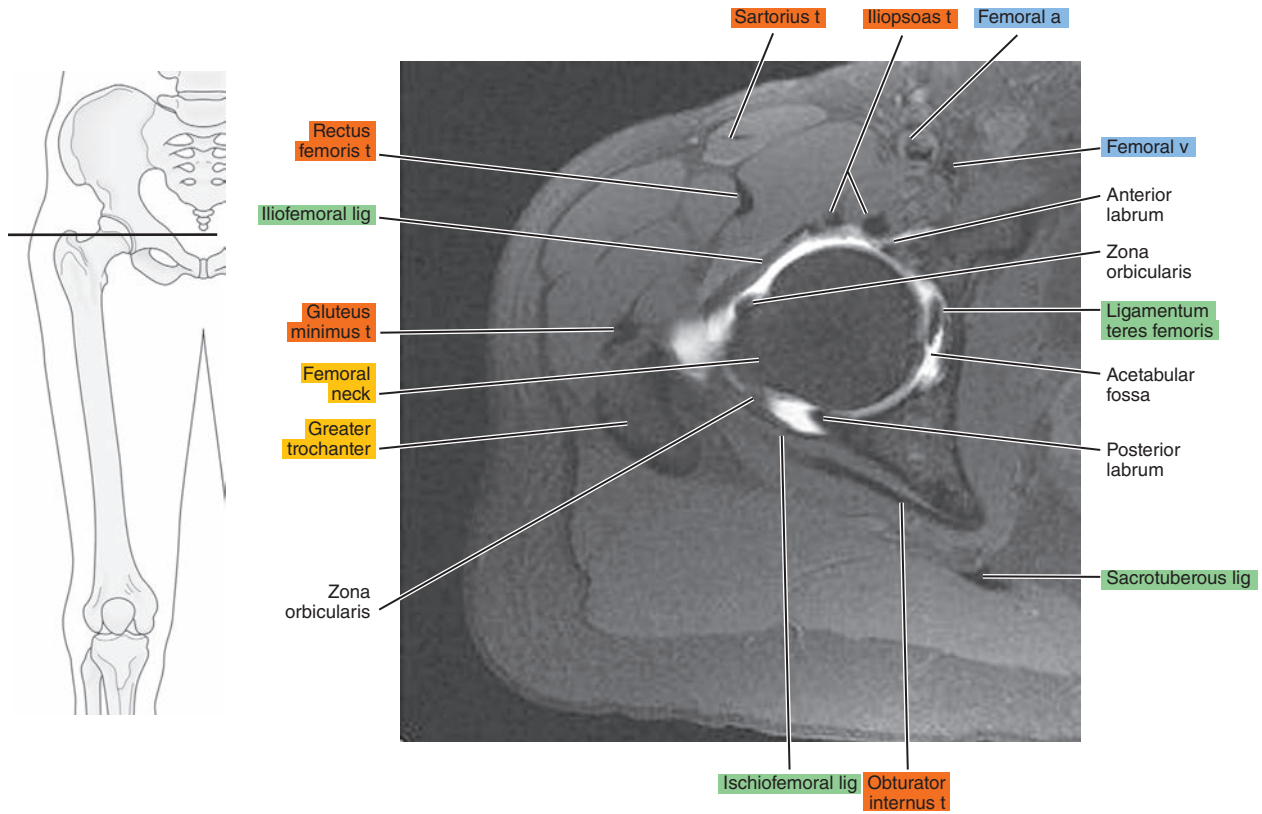


Figure 19.1.8

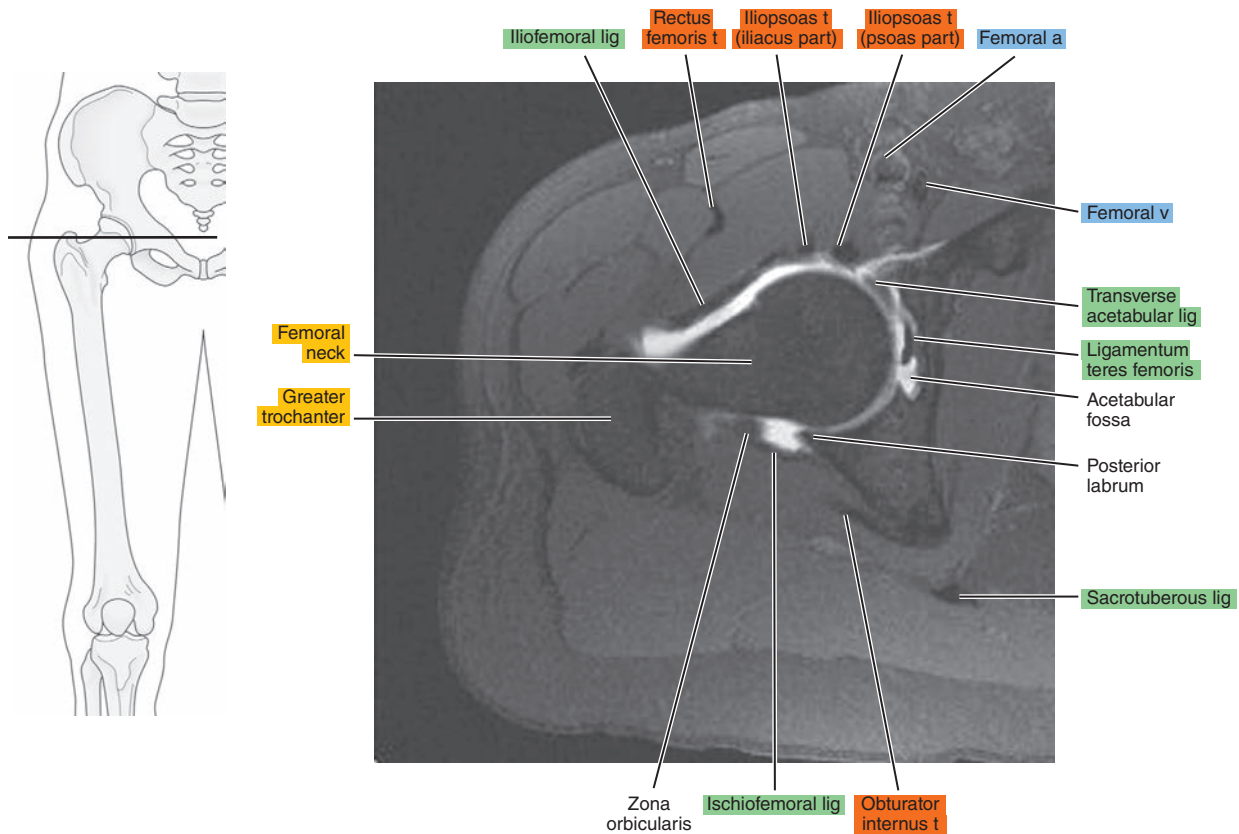


Figure 19.1.9

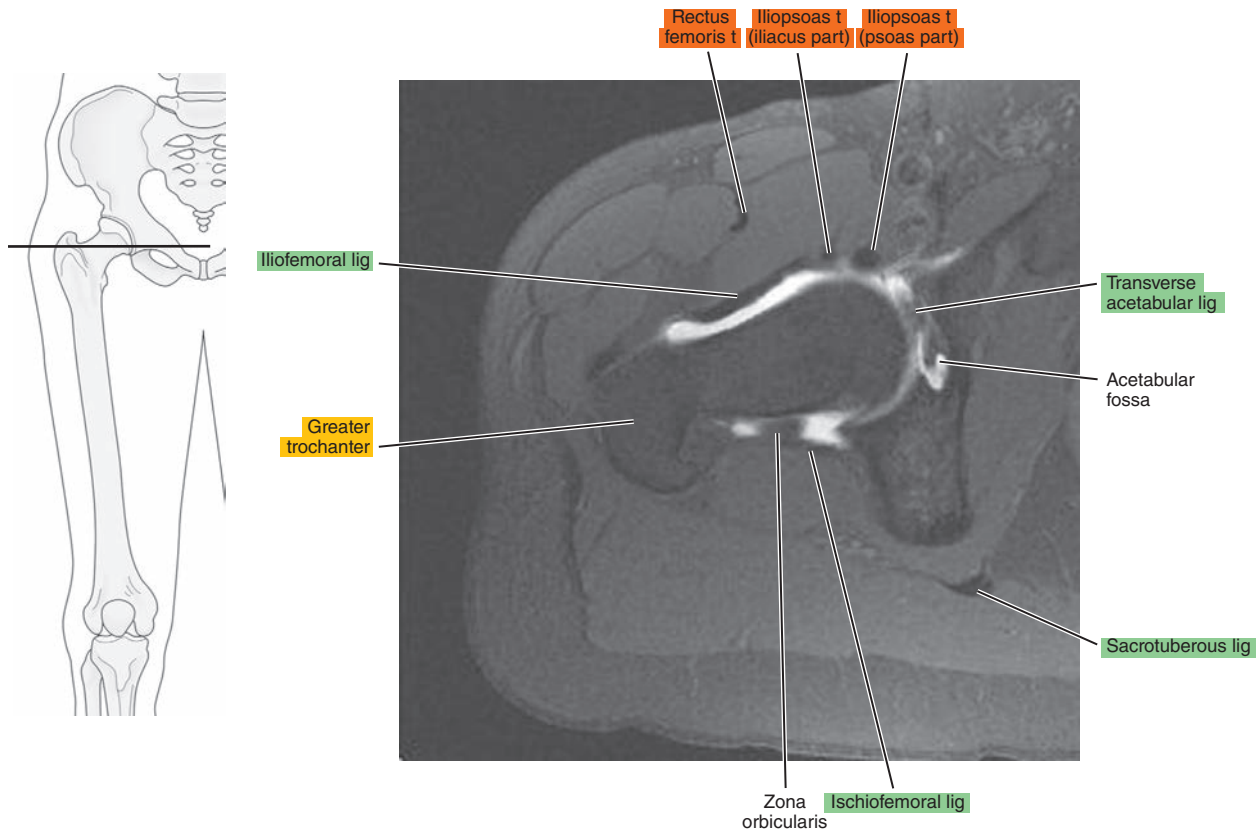


Figure 19.1.10

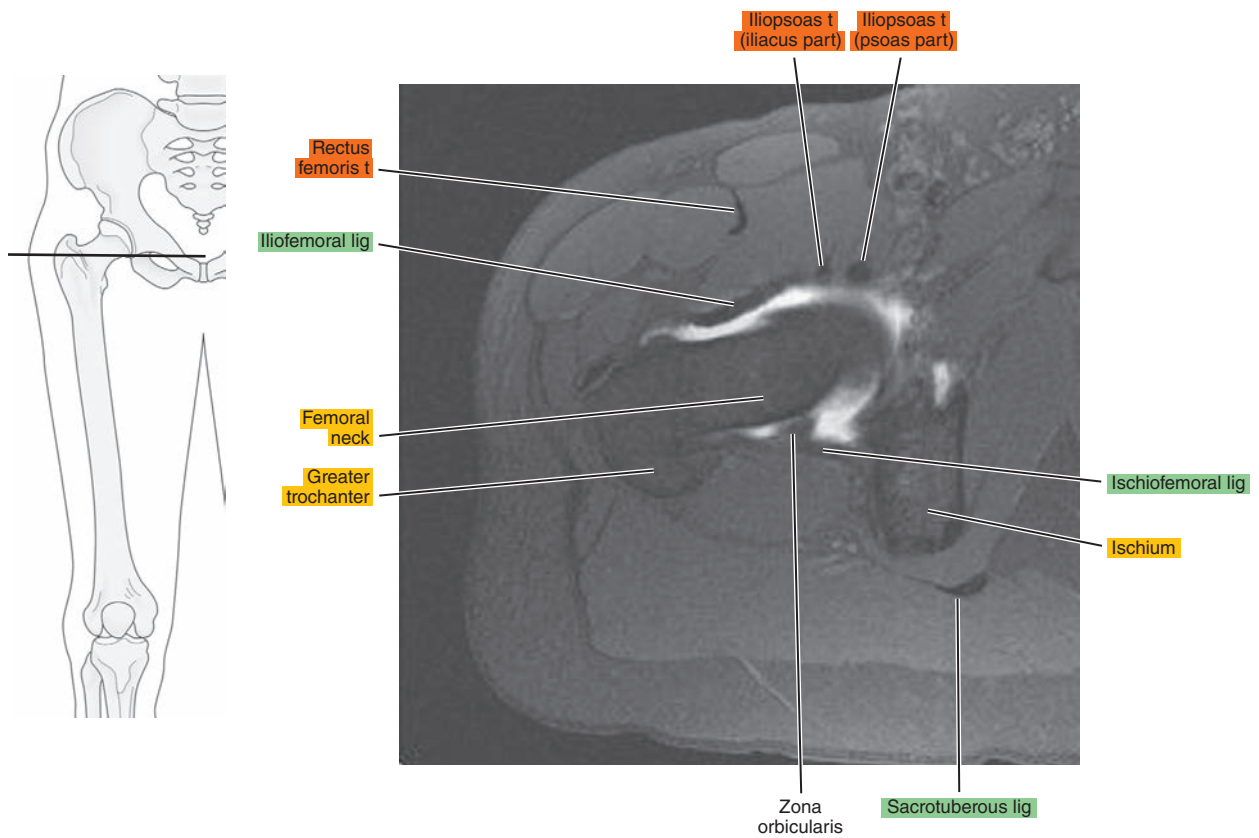


Figure 19.1.11

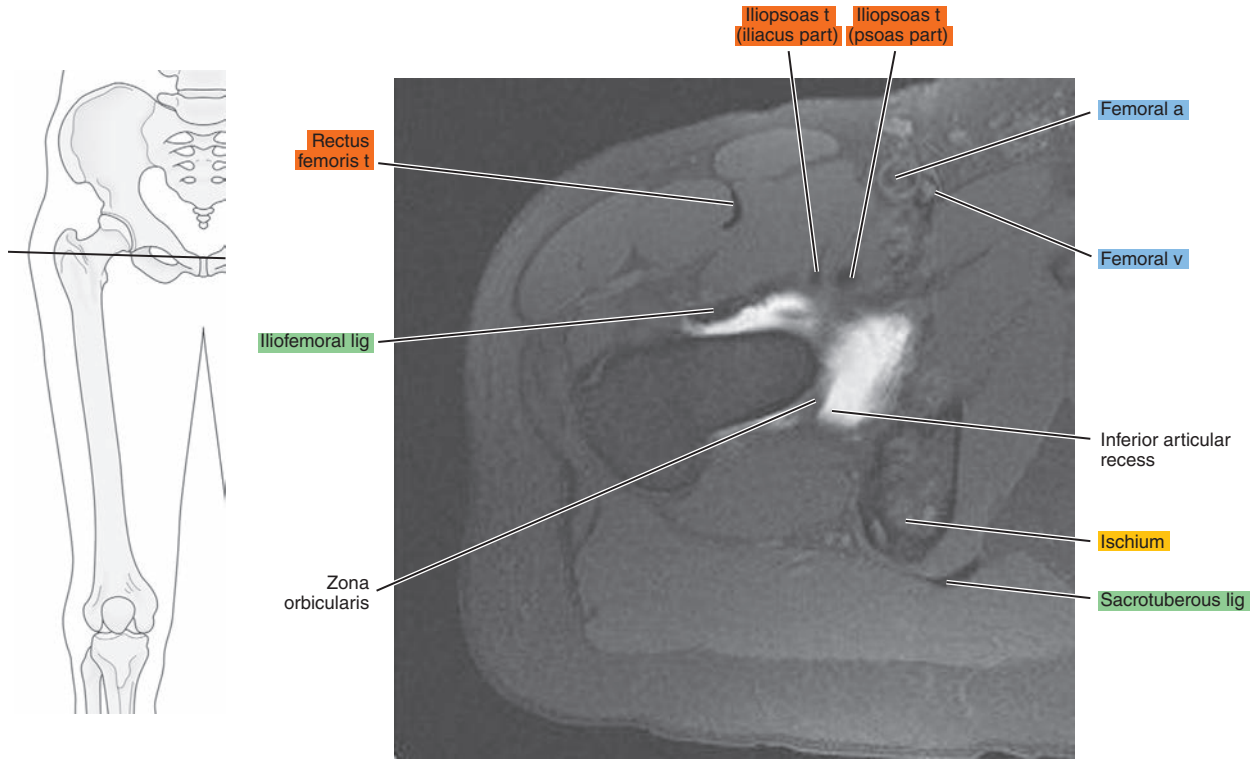
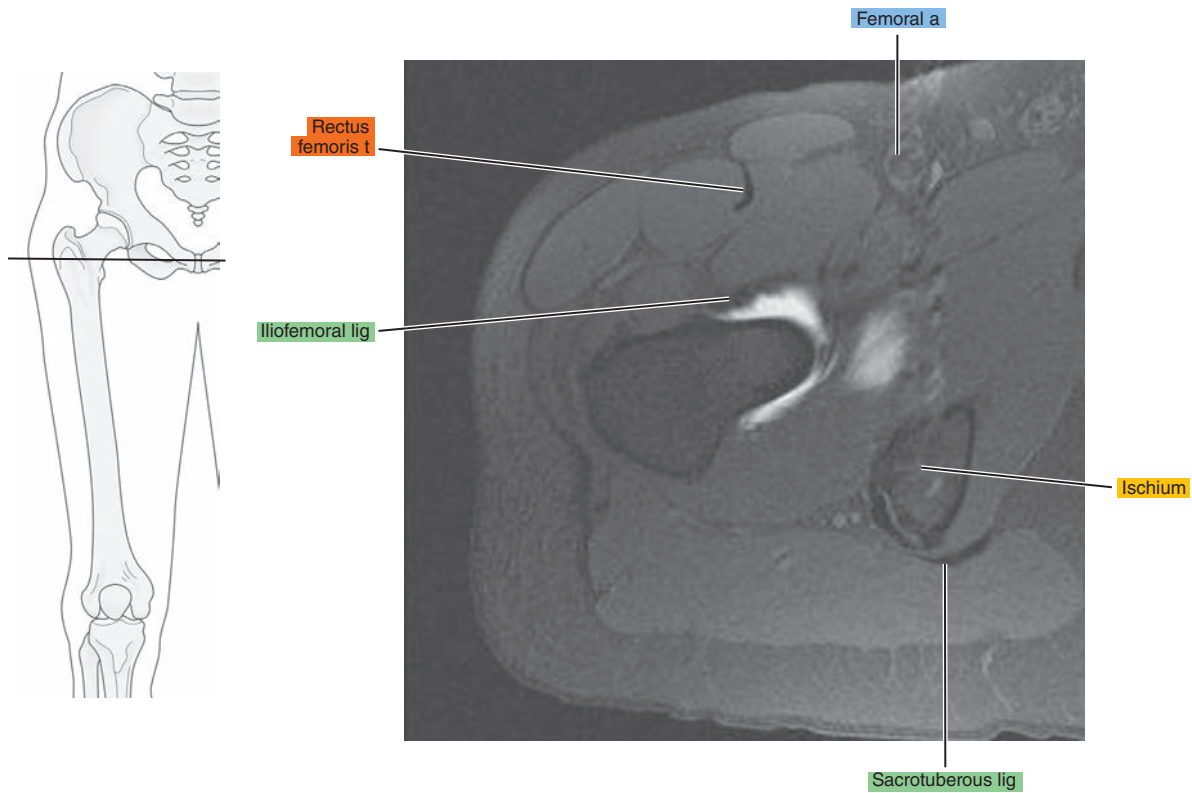


Figure 19.1.12



# SAGITTAL

Figure 19.2.1

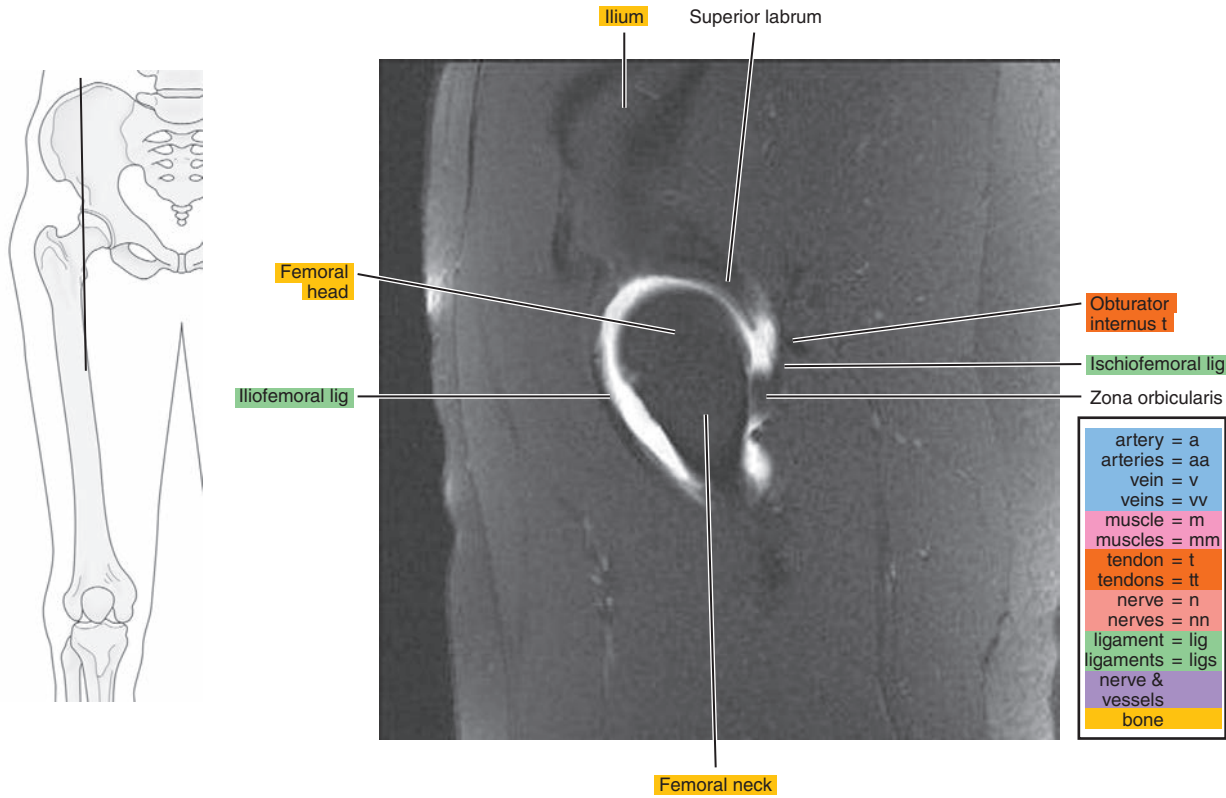


Figure 19.2.2

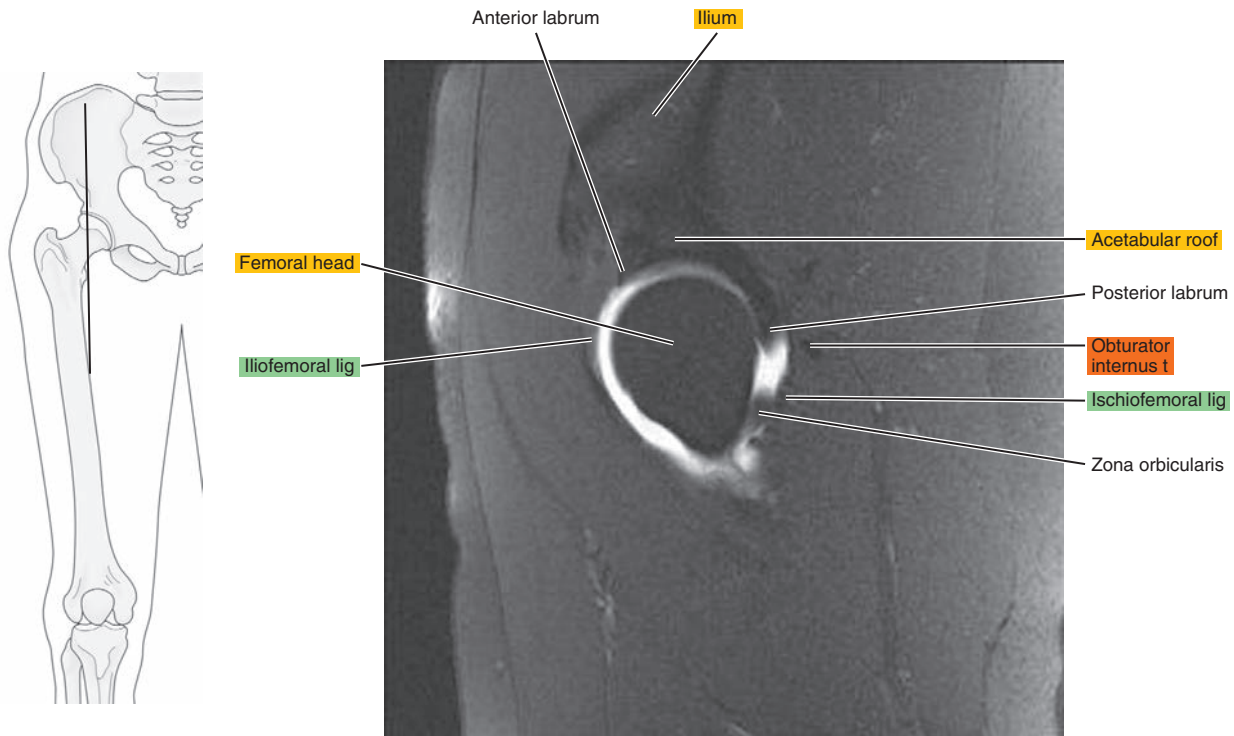




Figure 19.2.3

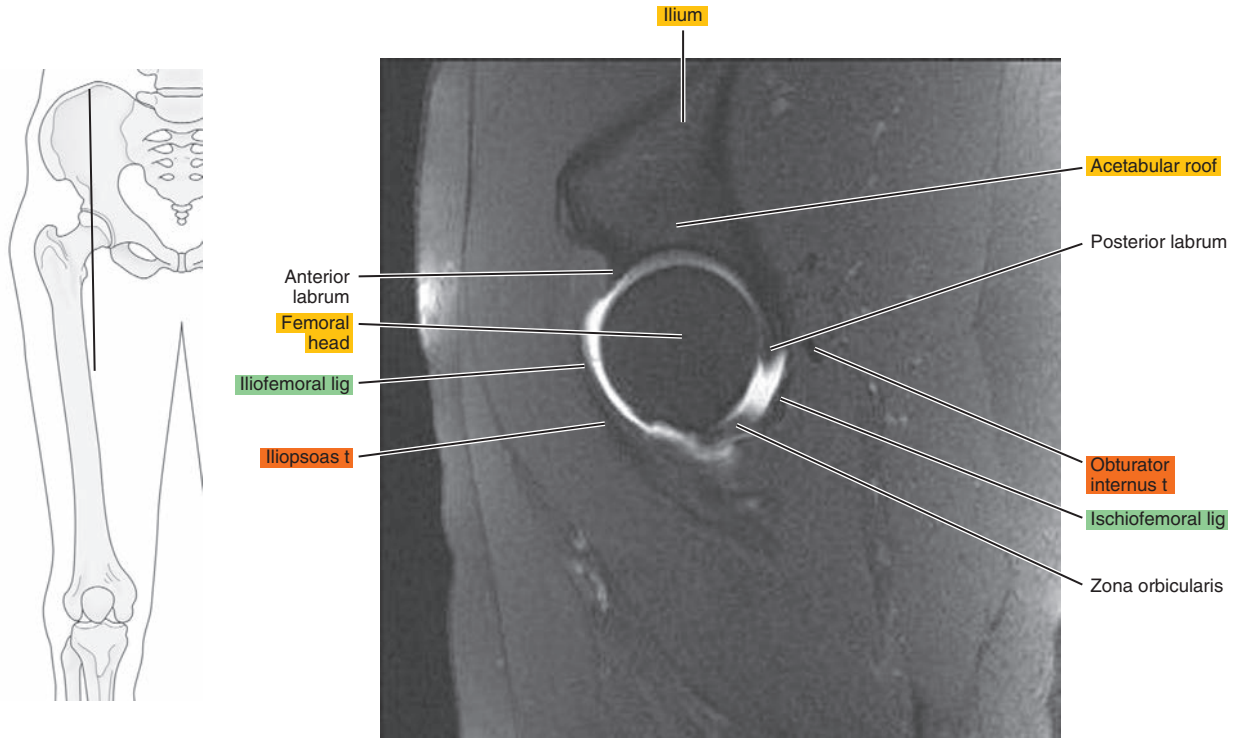


Figure 19.2.4

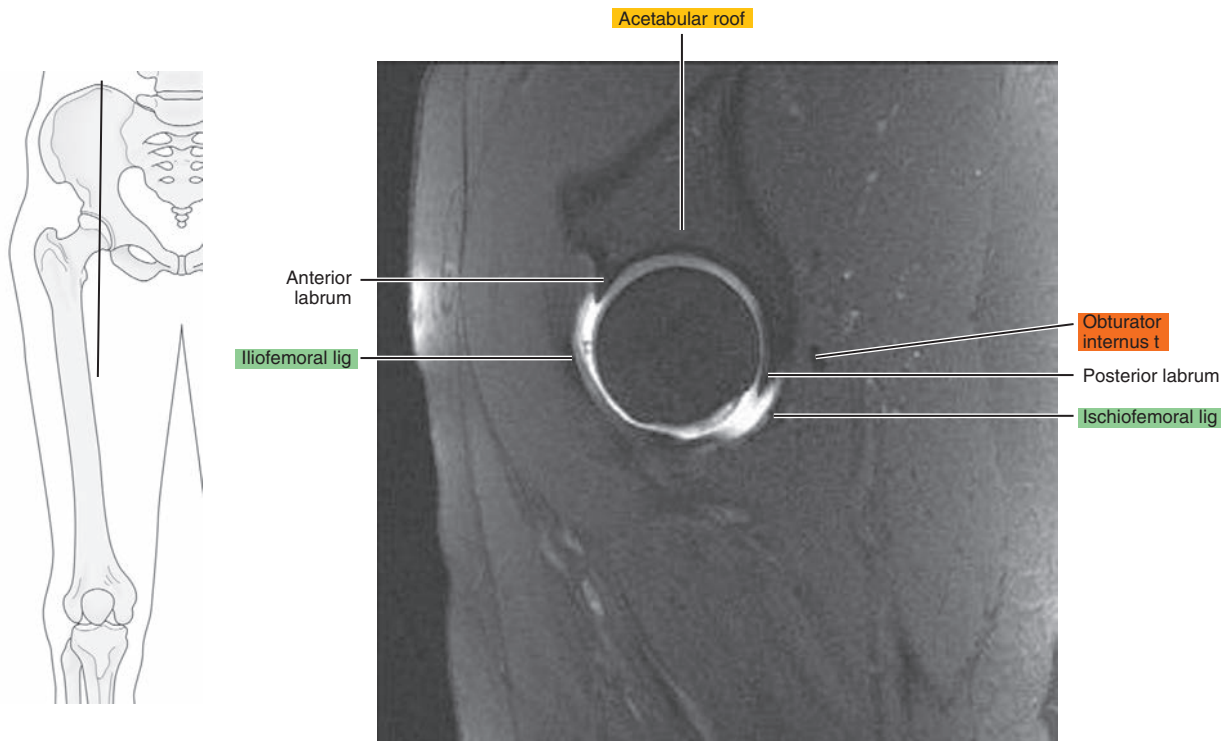


Figure 19.2.5

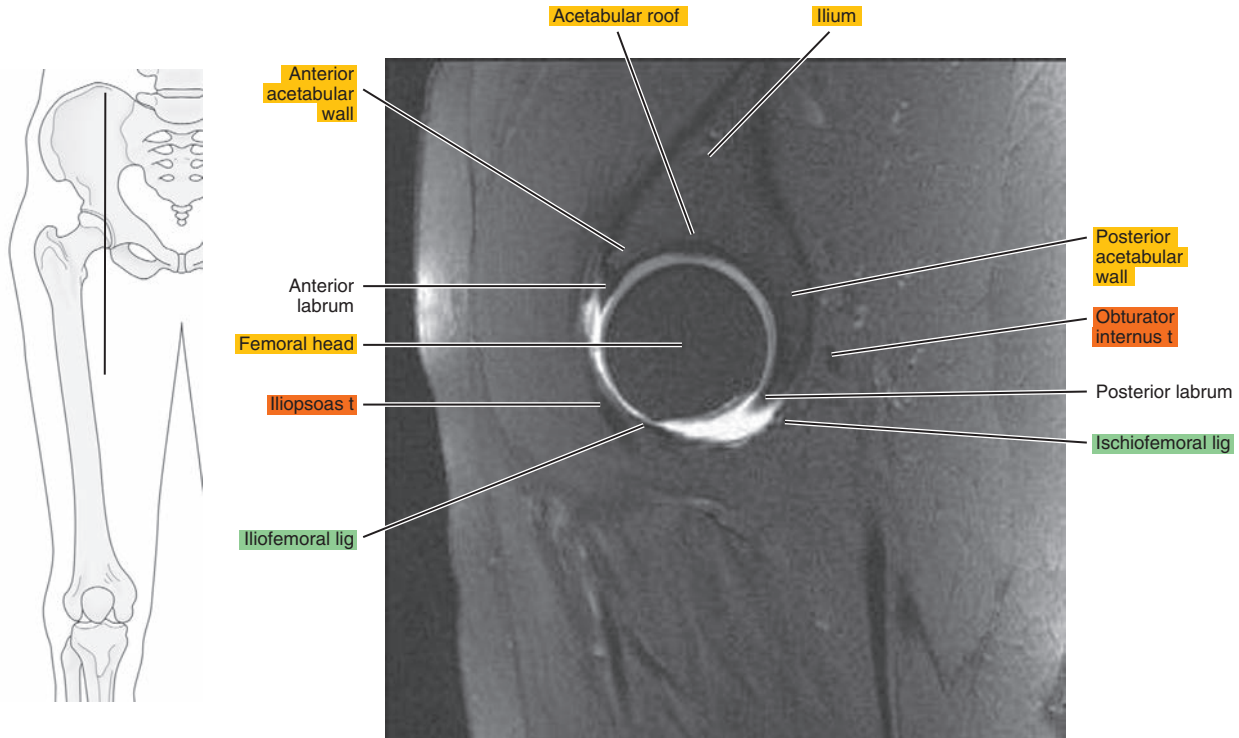


Figure 19.2.6

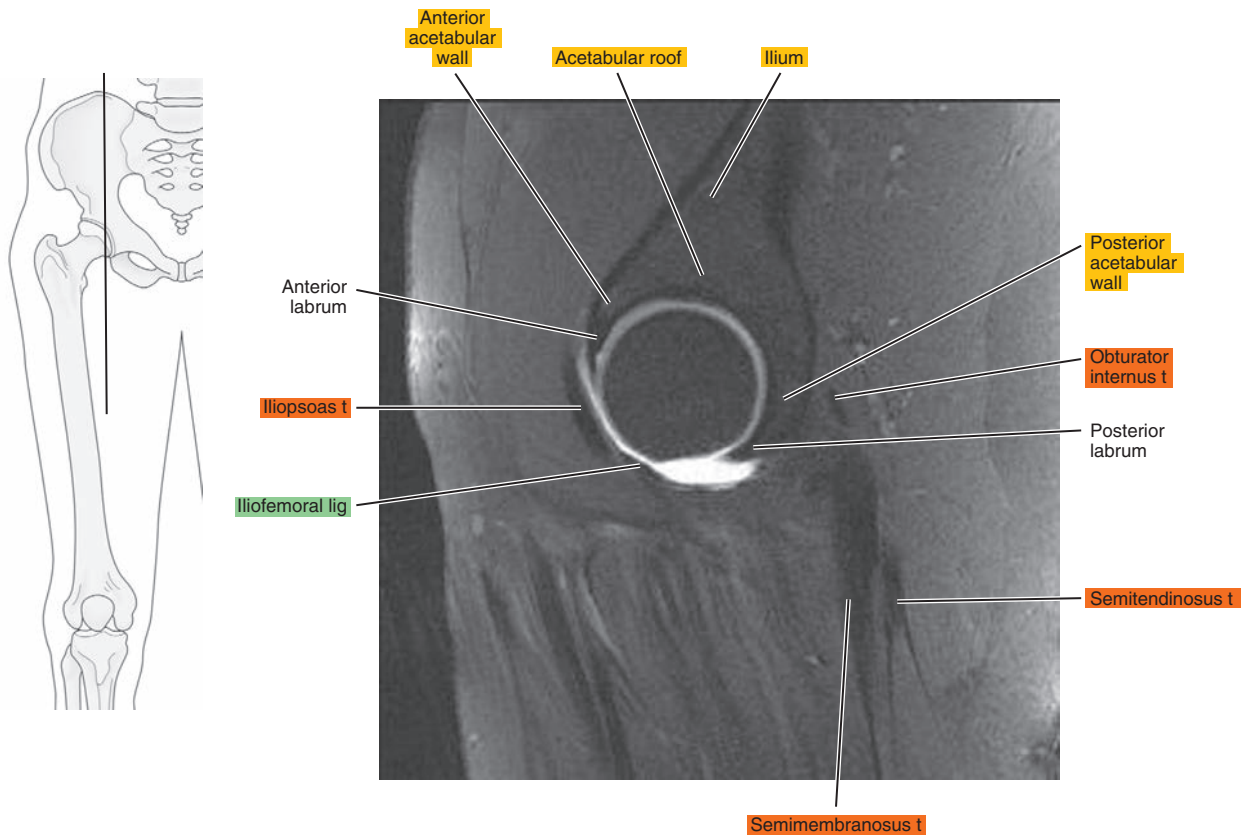


Figure 19.2.7

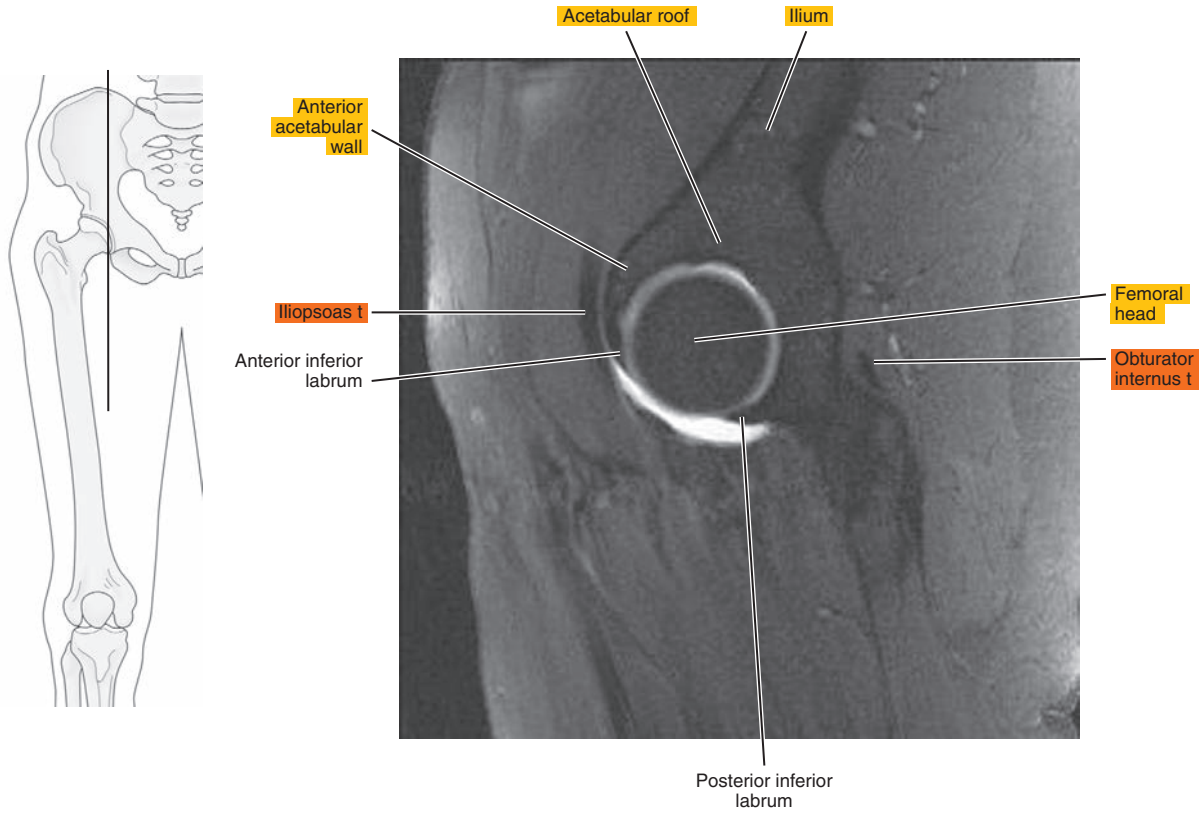


Figure 19.2.8

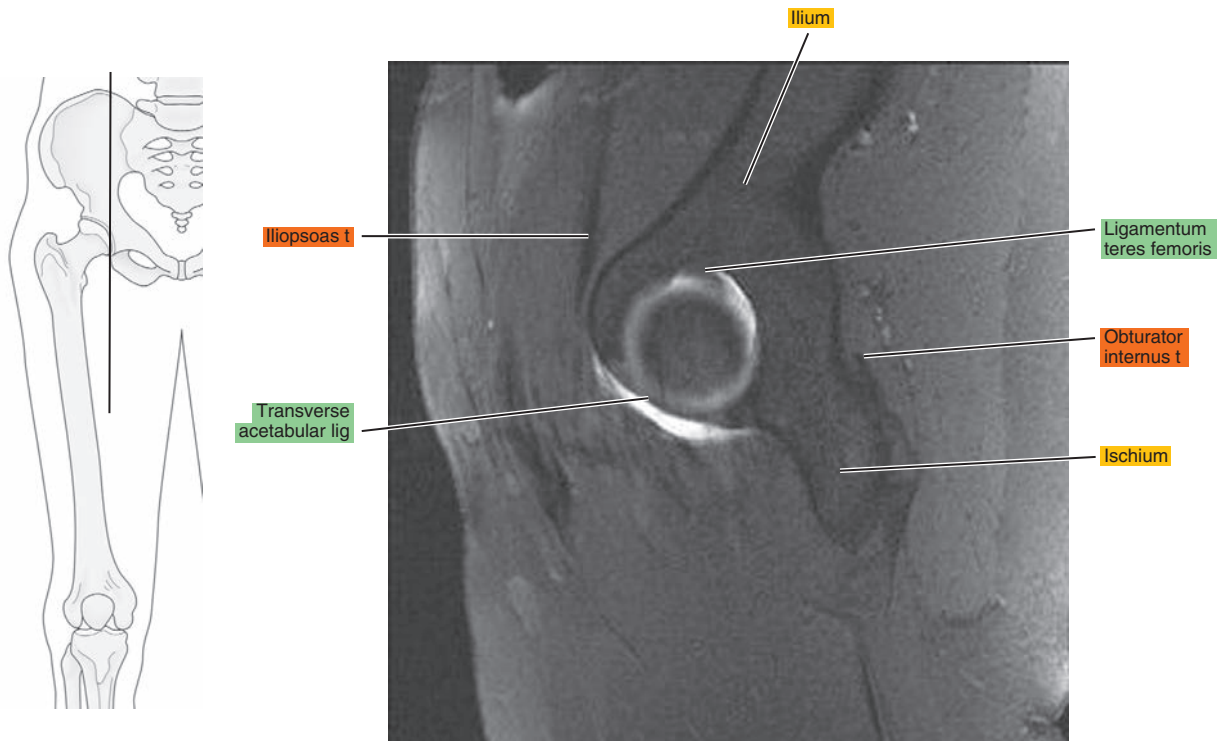


Figure 19.2.9

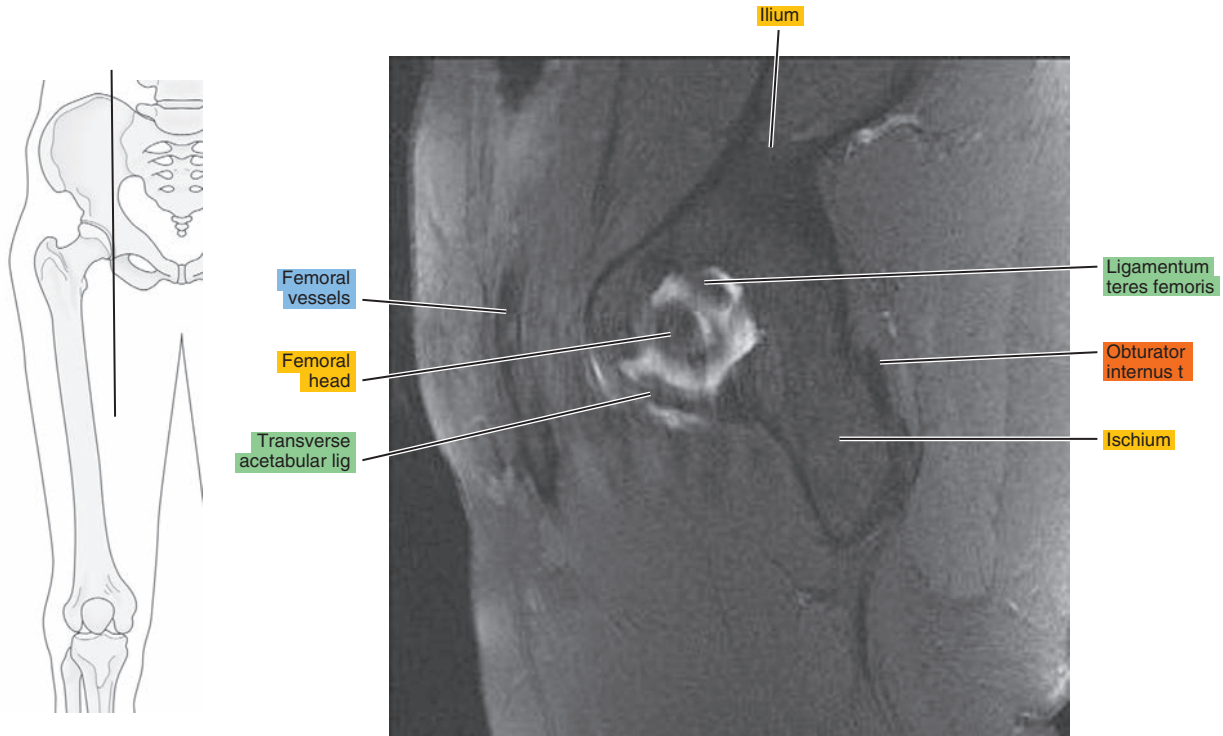
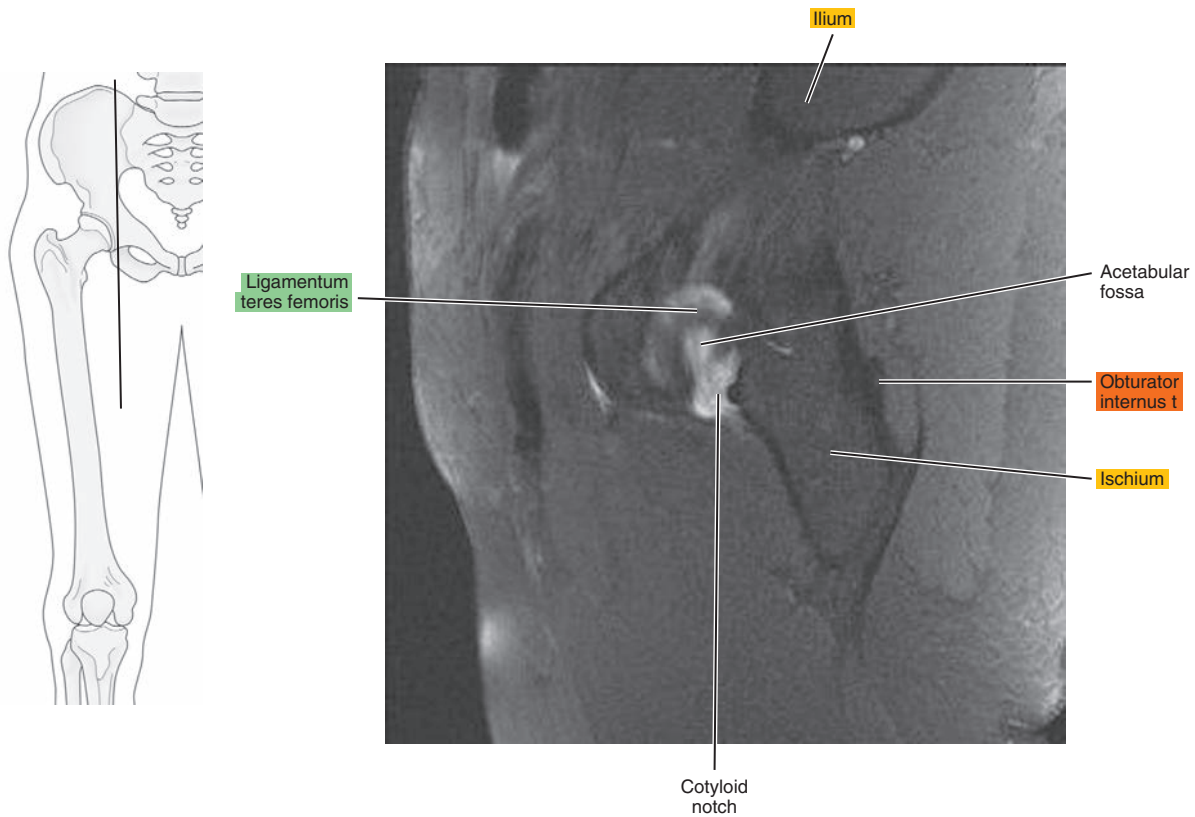


Figure 19.2.10





# CORONAL

Figure 19.3.1

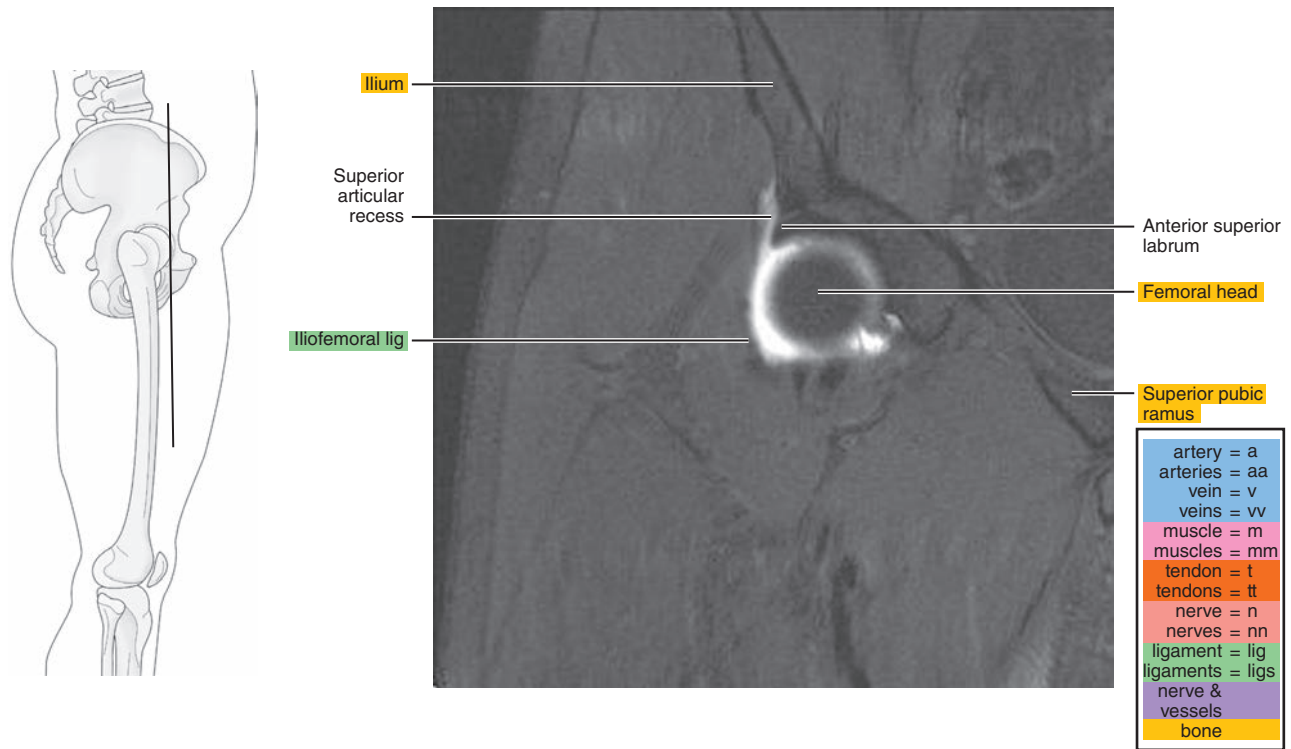


Figure 19.3.2

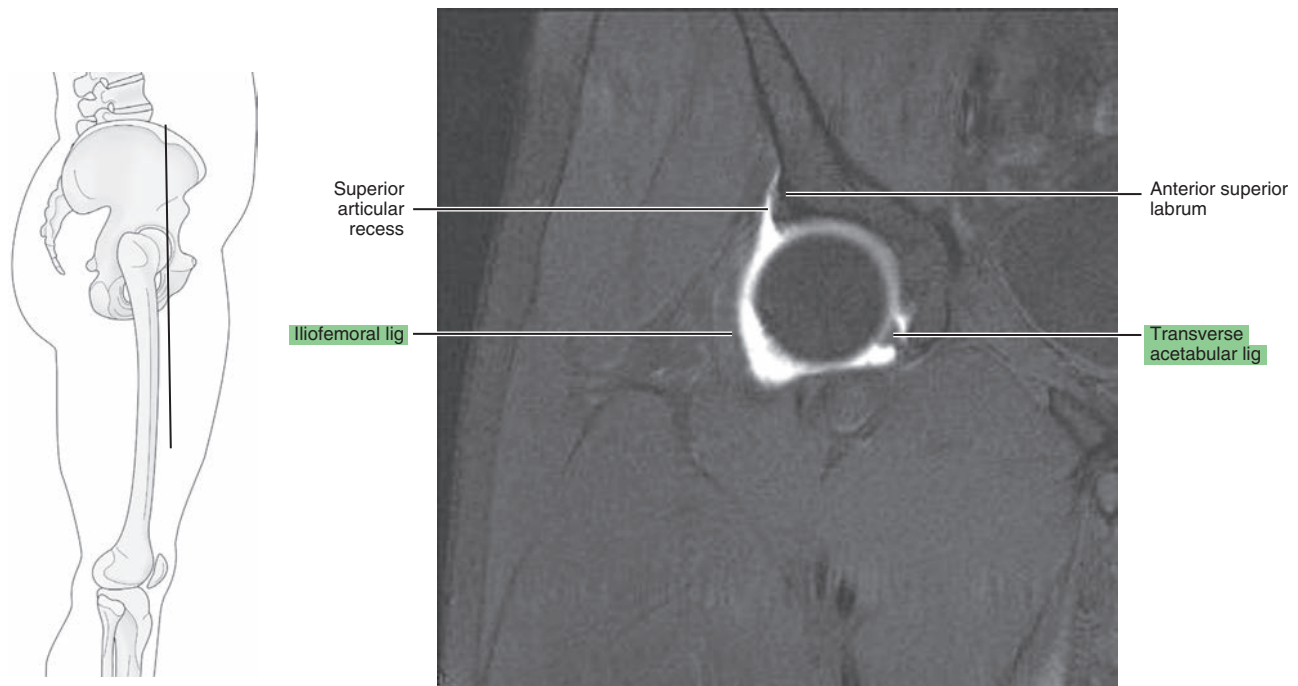


Figure 19.3.3

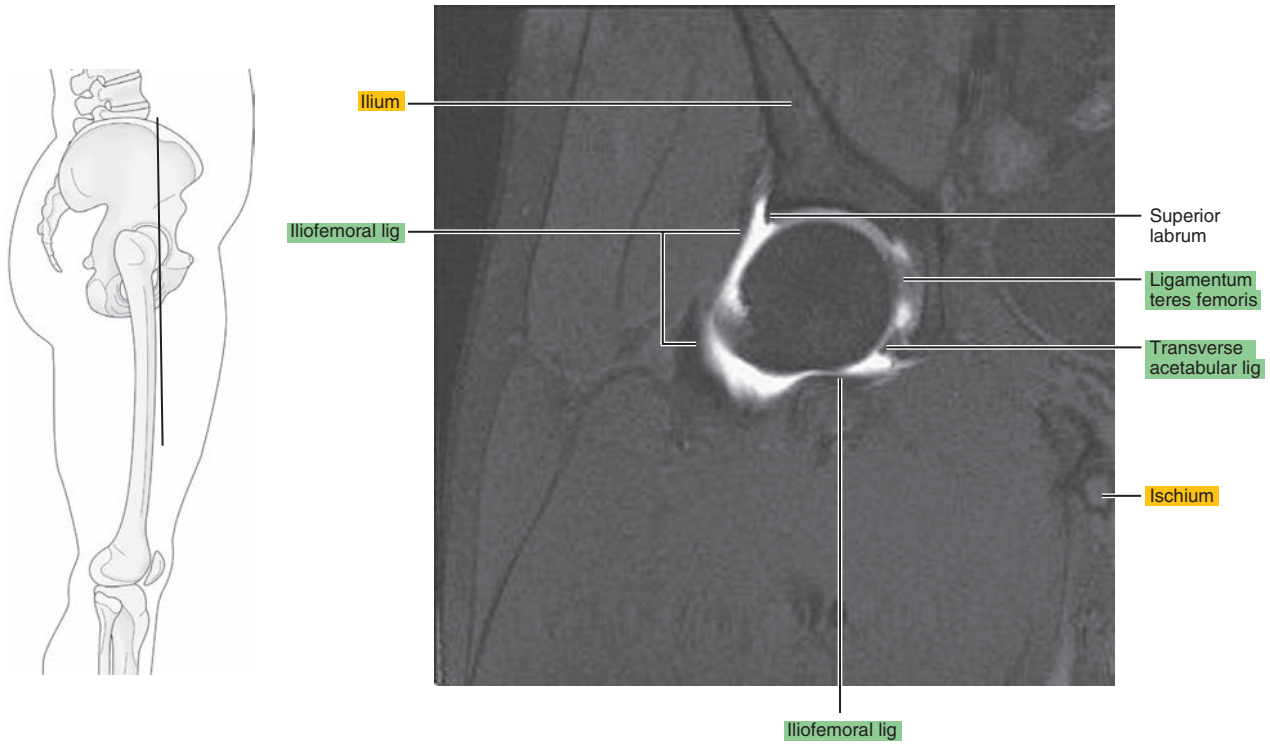


Figure 19.3.4

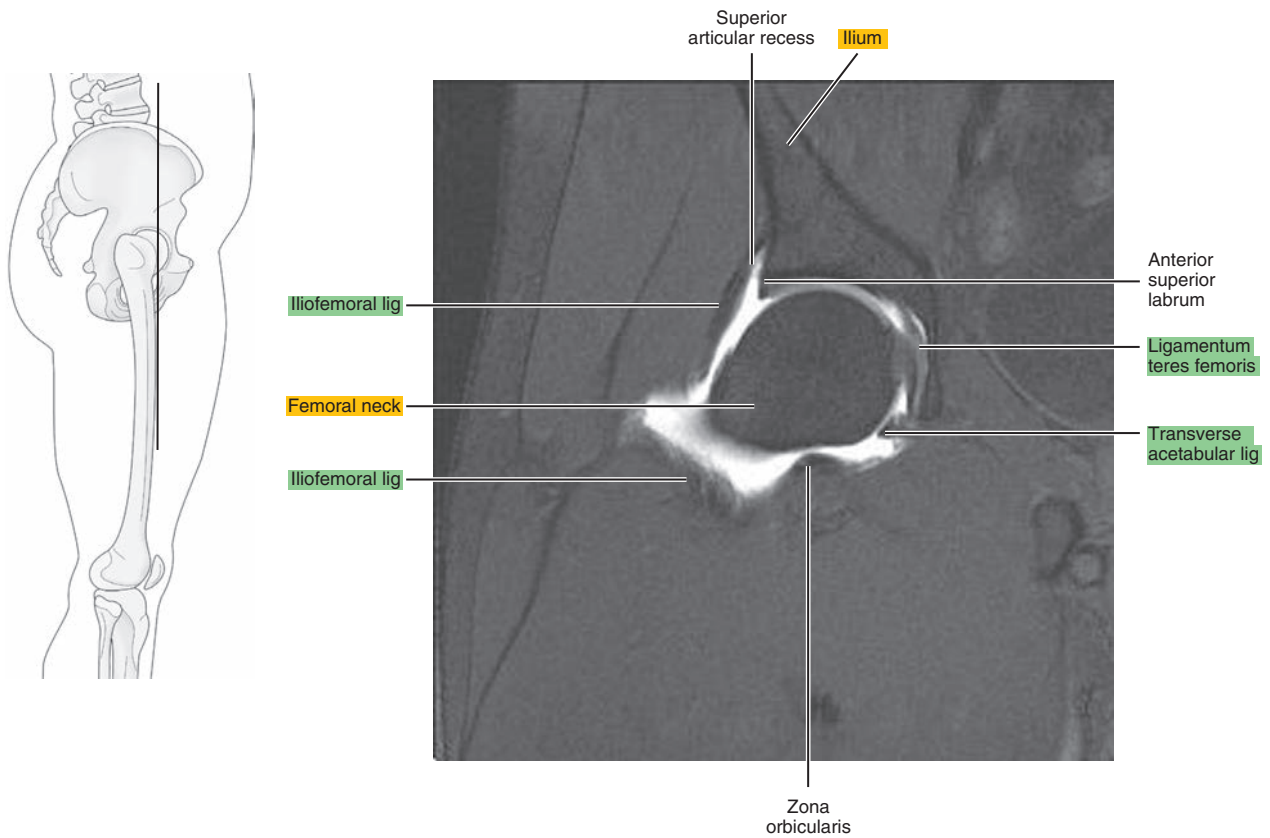


Figure 19.3.5

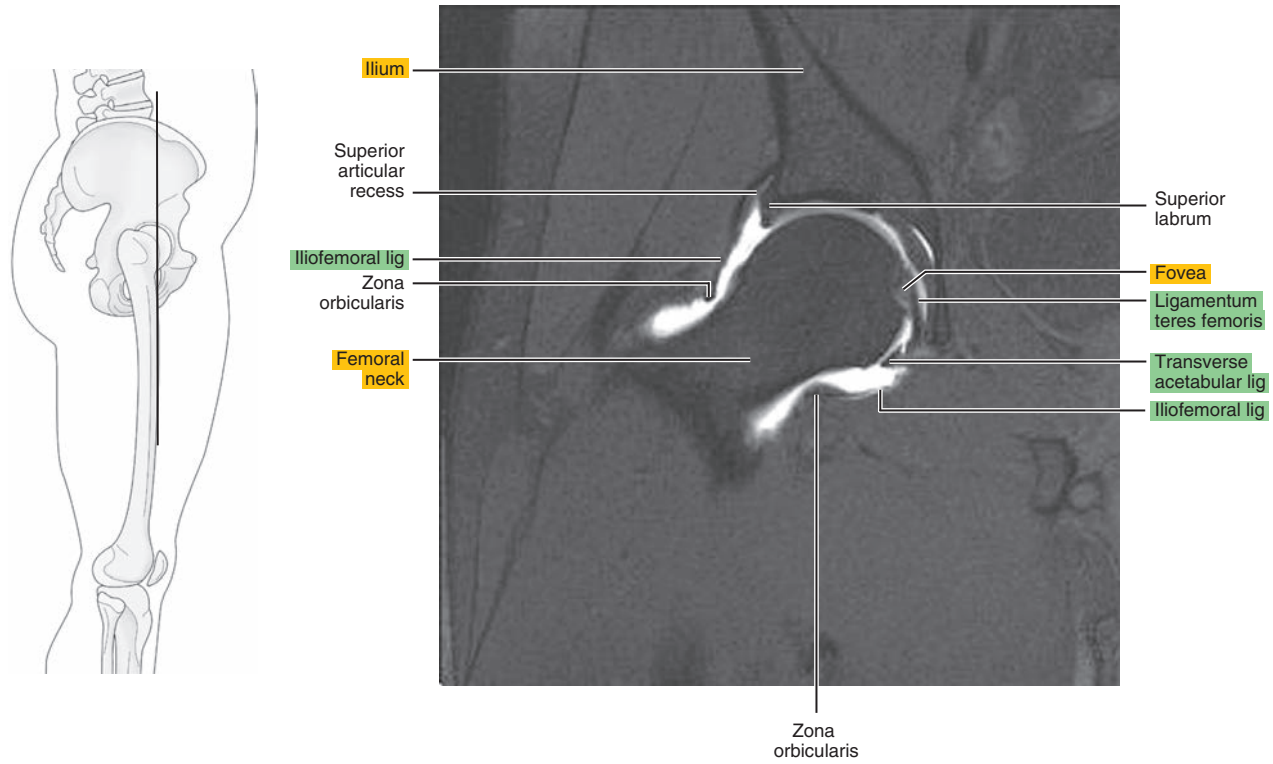


Figure 19.3.6

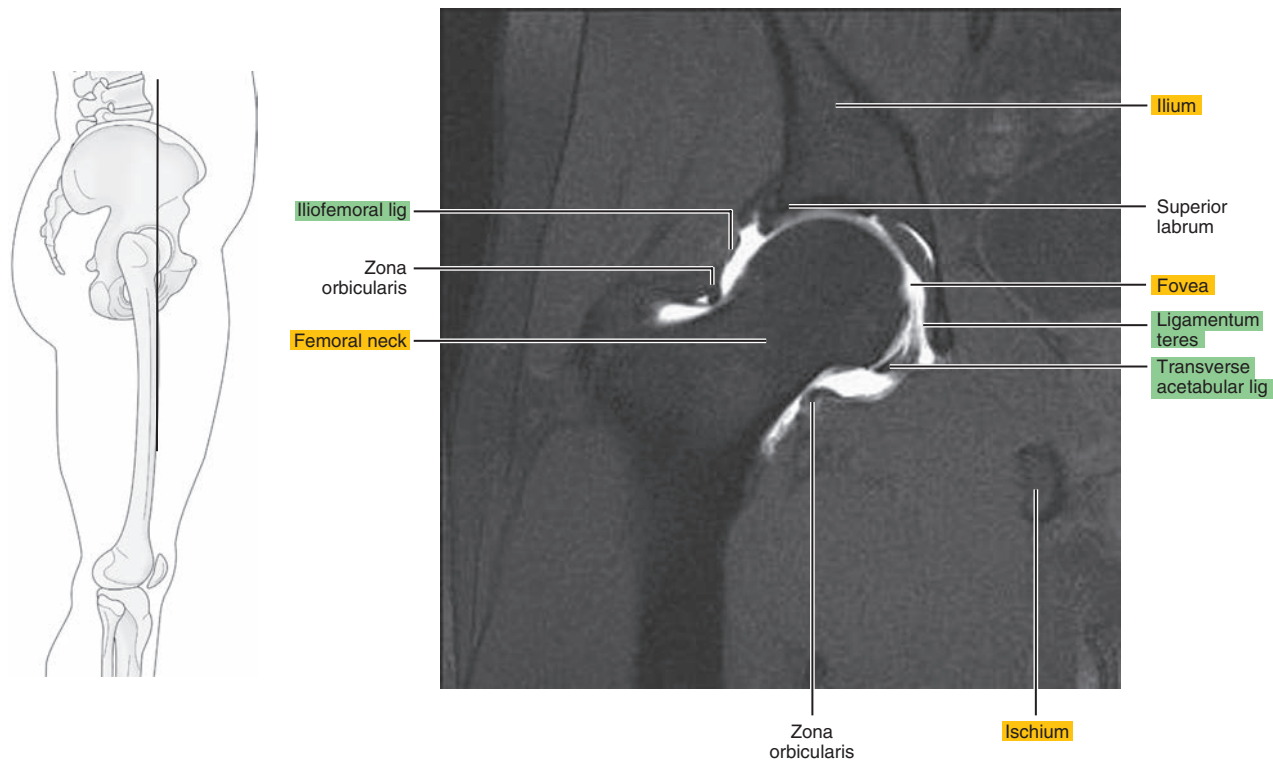


Figure 19.3.7

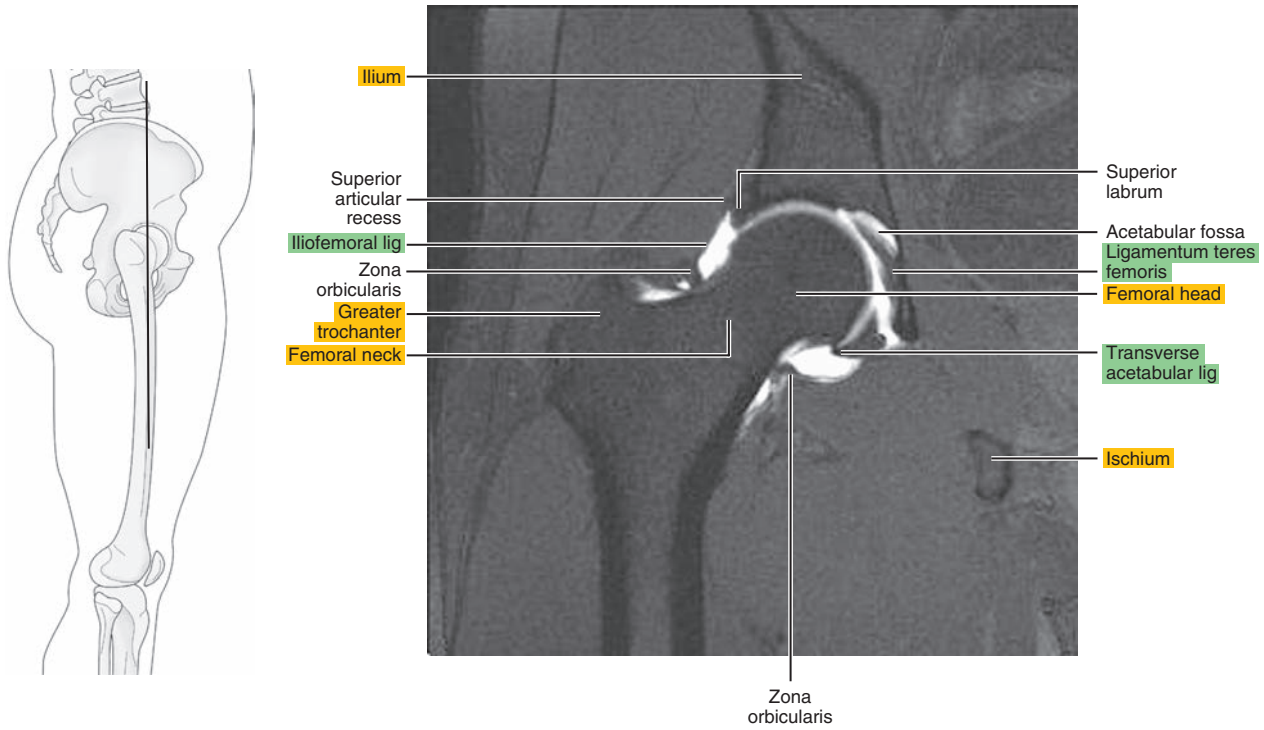


Figure 19.3.8

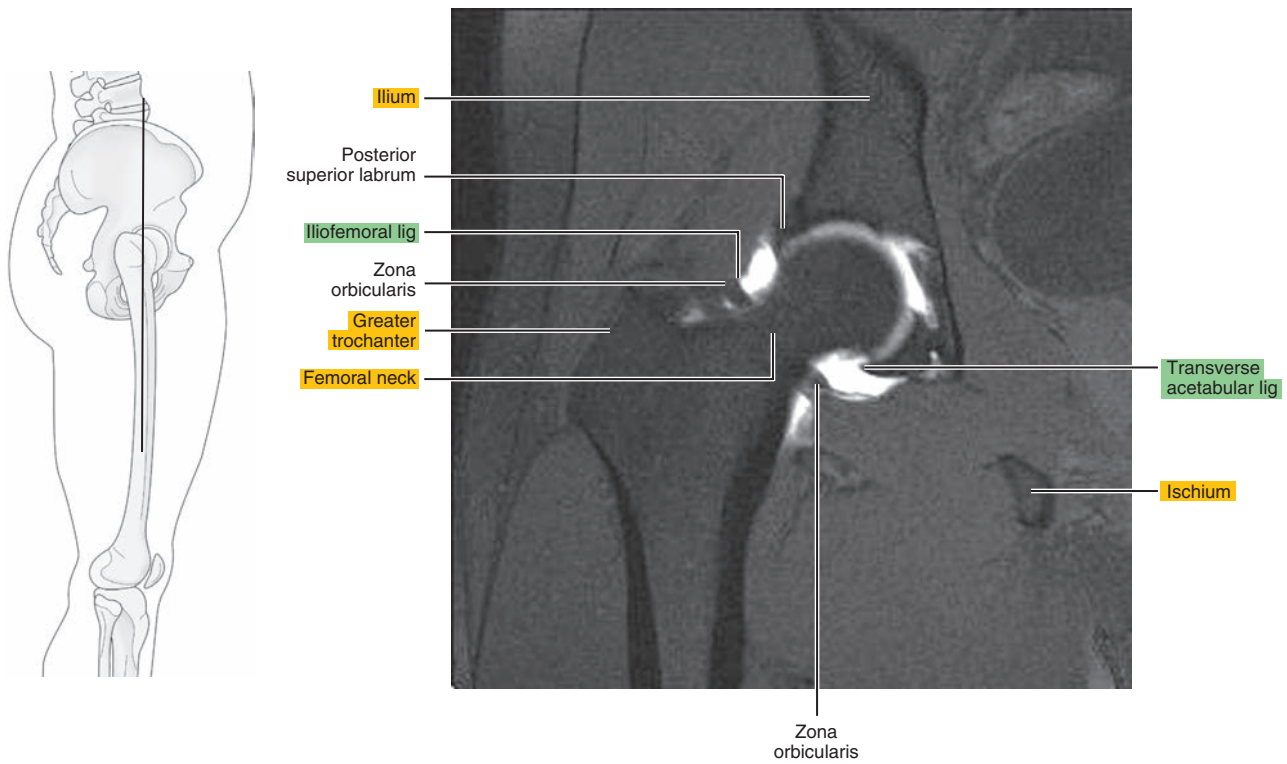




Figure 19.3.9

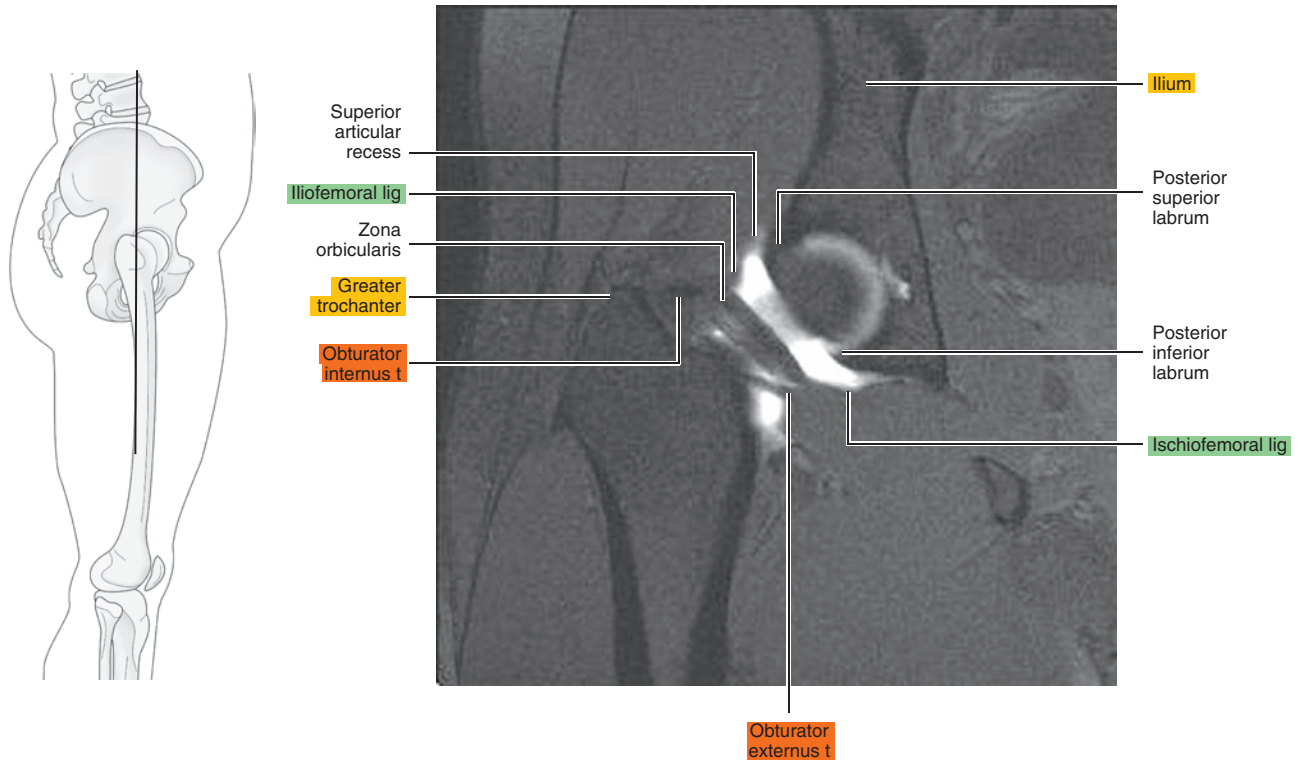
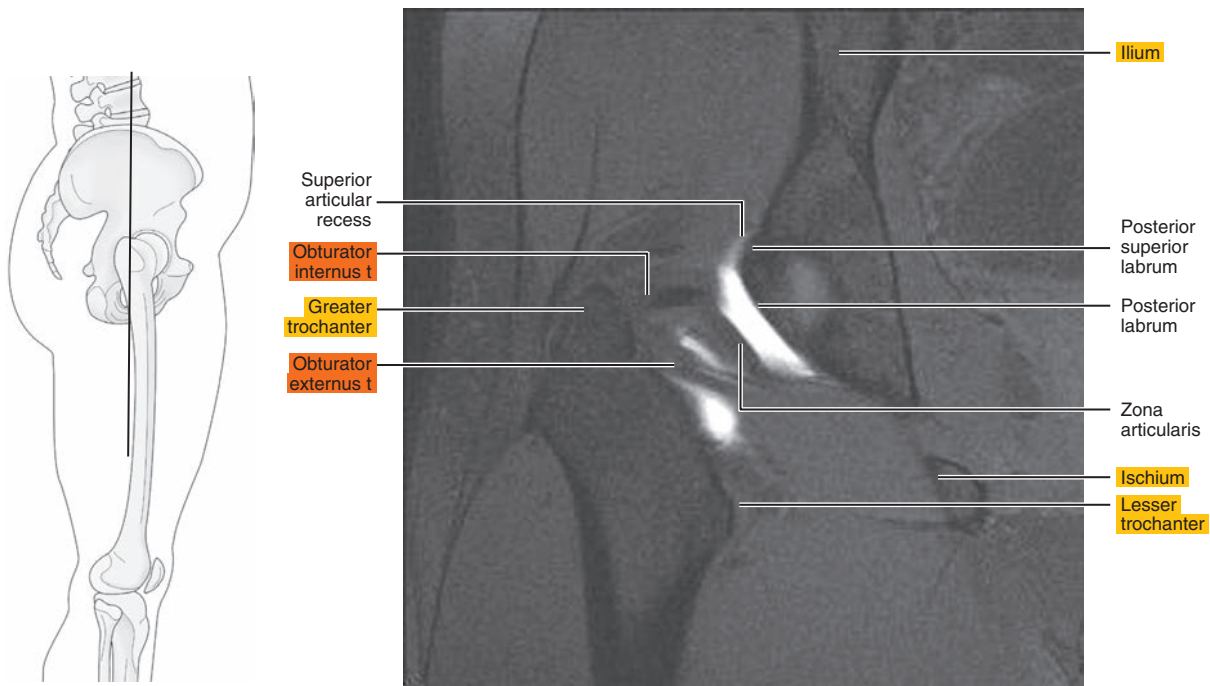


Figure 19.3.10



*Chapter*  
**20**

**MRI of the Thigh**

# AXIAL

Figure 20.1.1

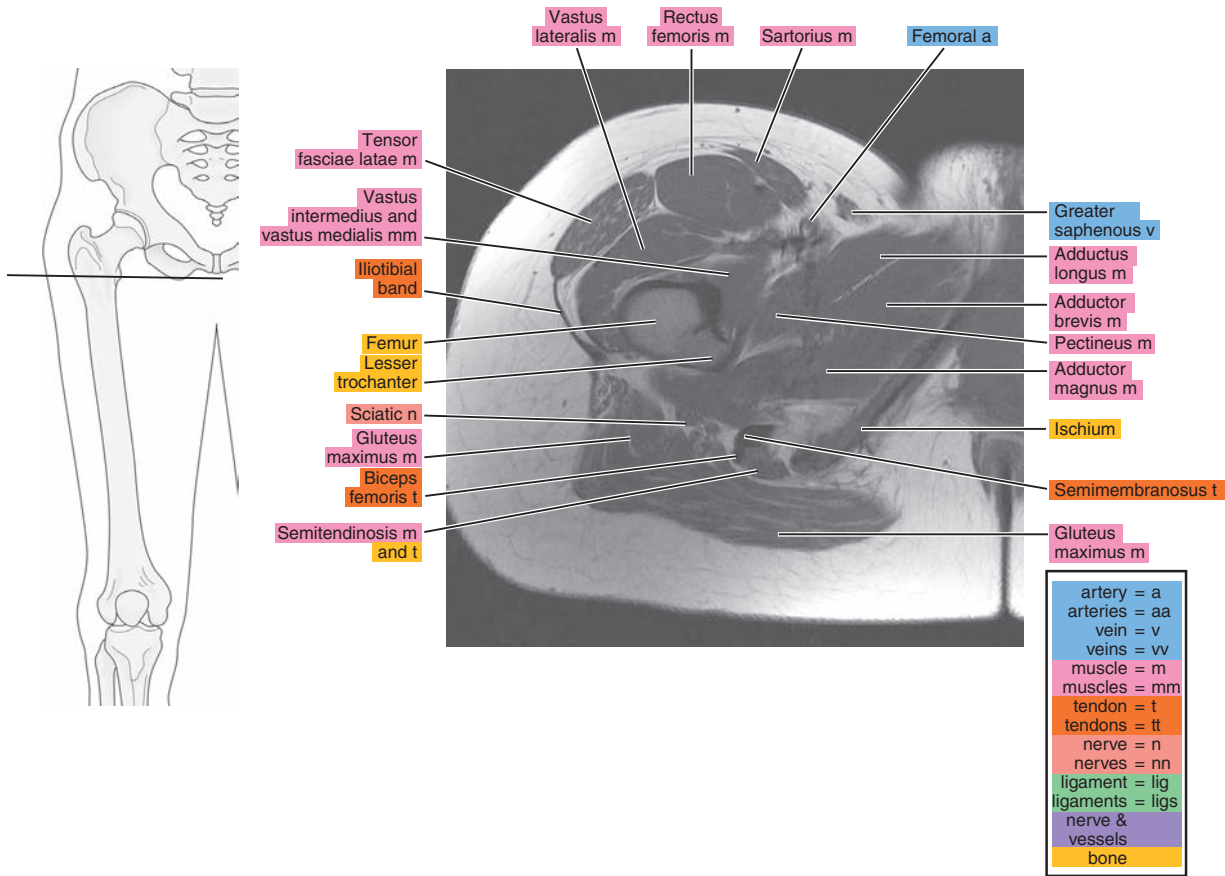


Figure 20.1.2

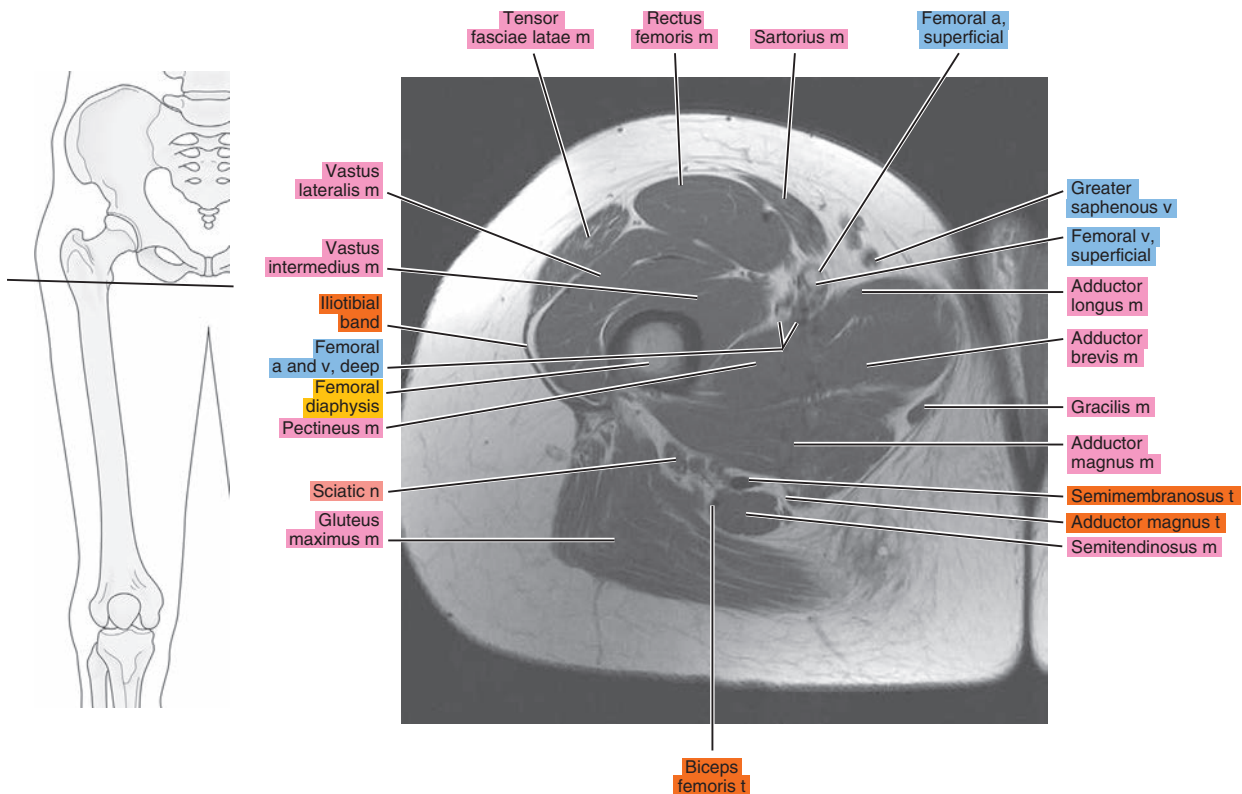


Figure 20.1.3

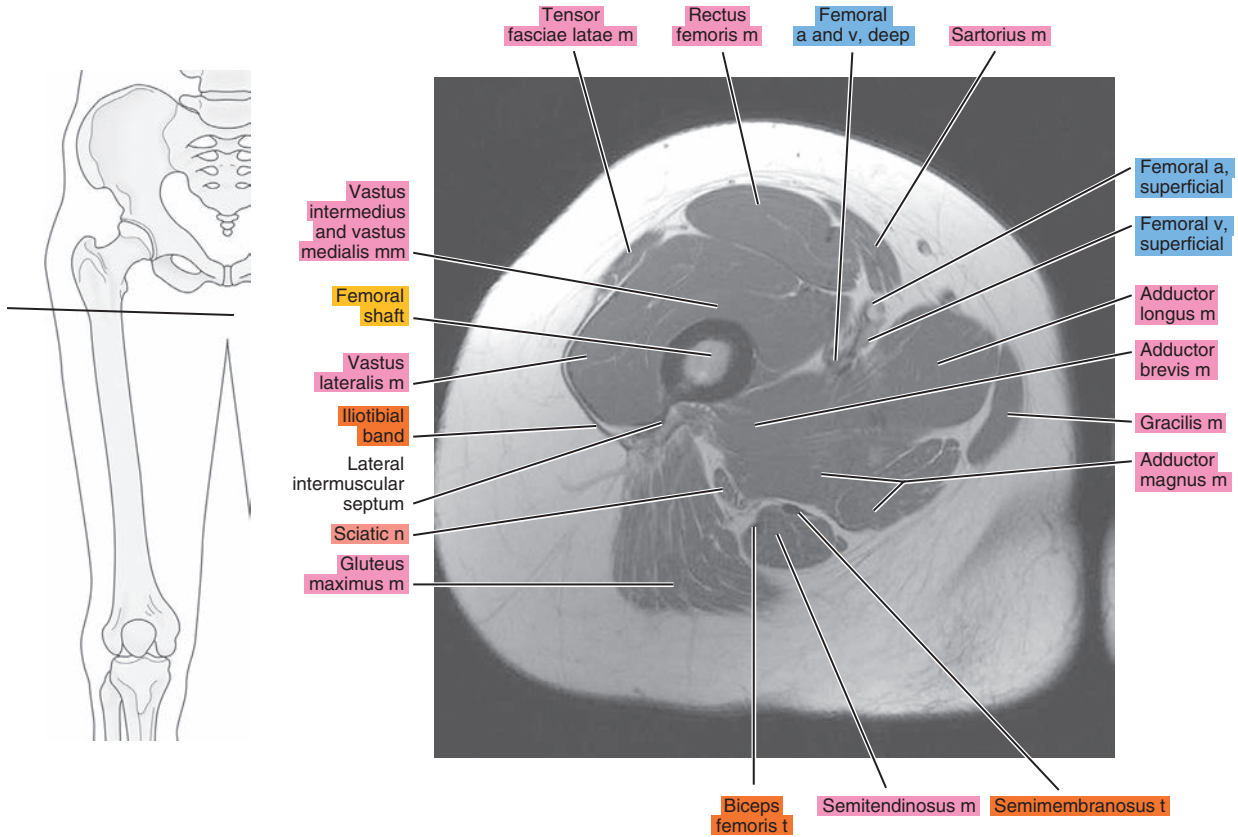


Figure 20.1.4

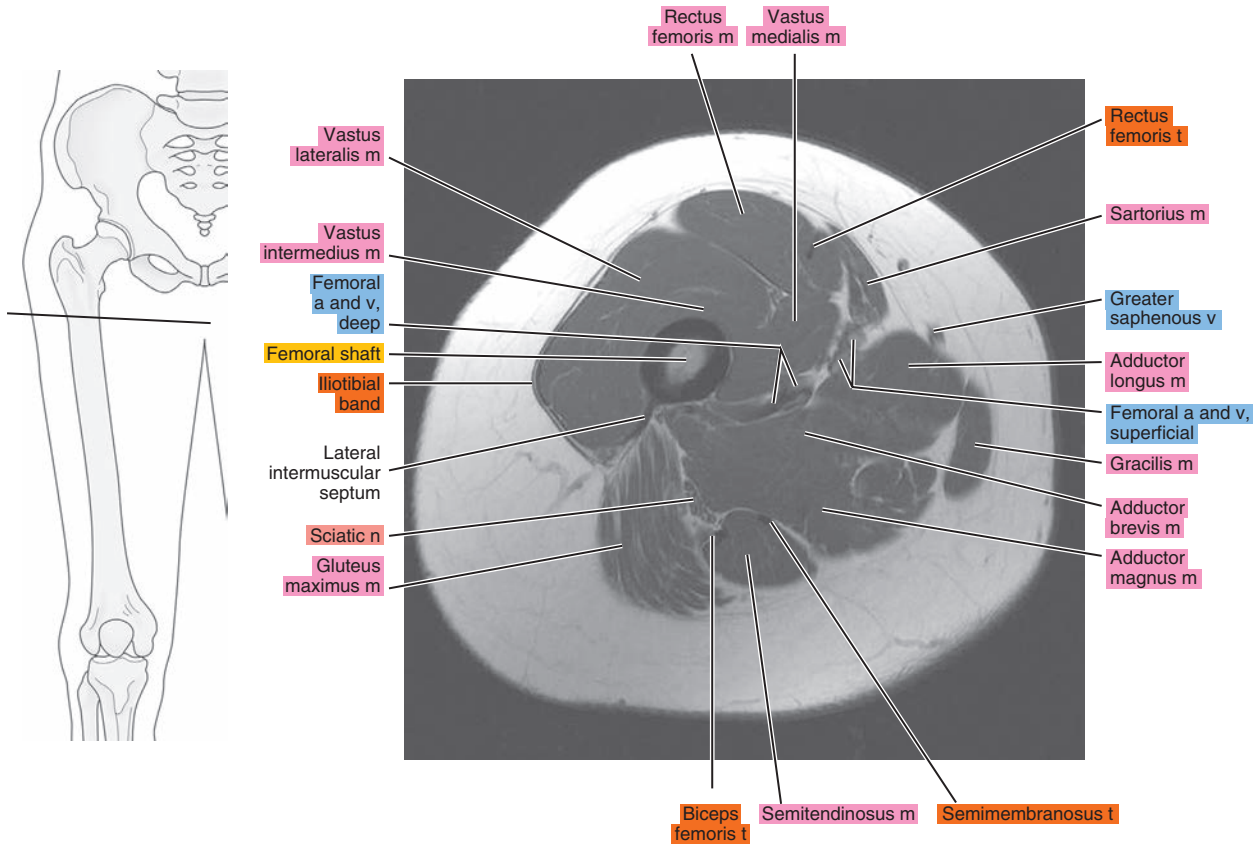




Figure 20.1.5

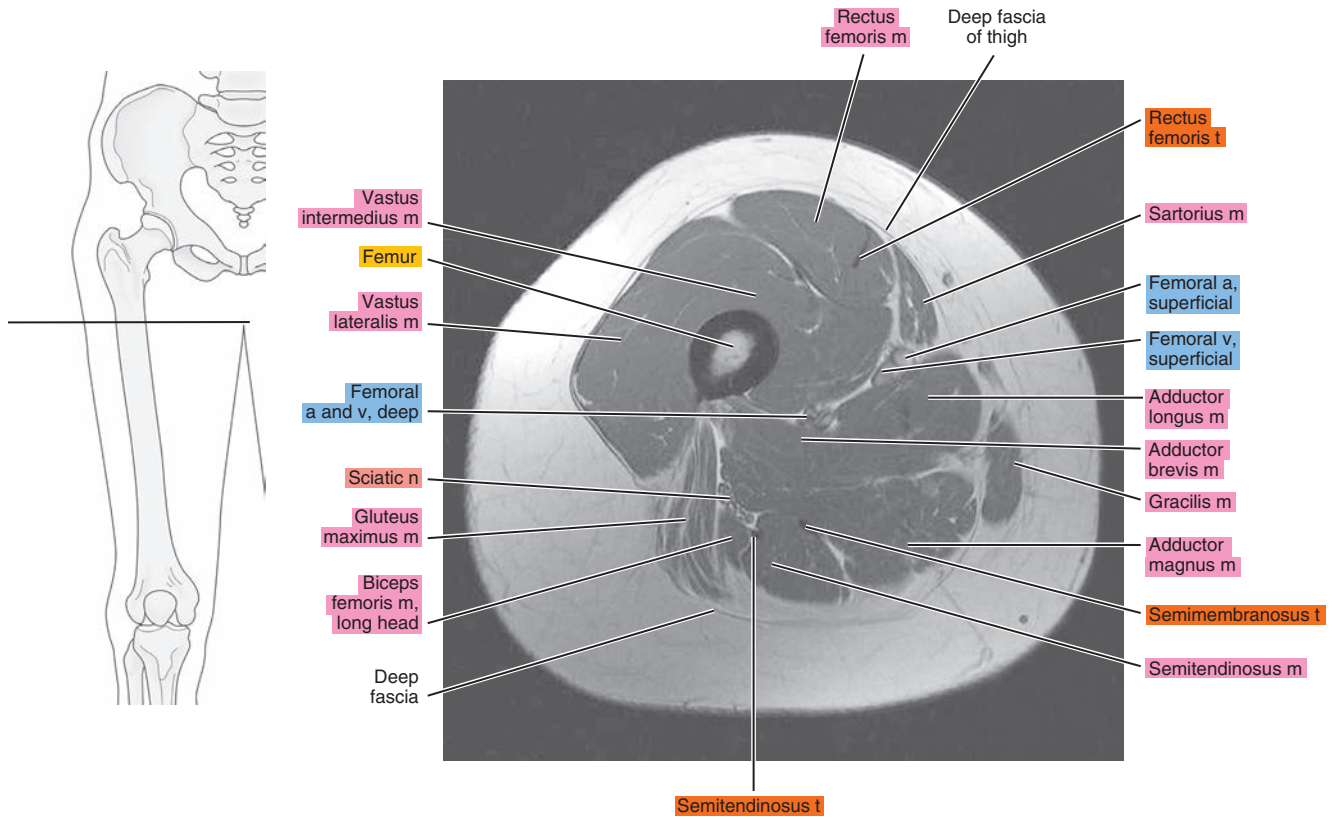


Figure 20.1.6

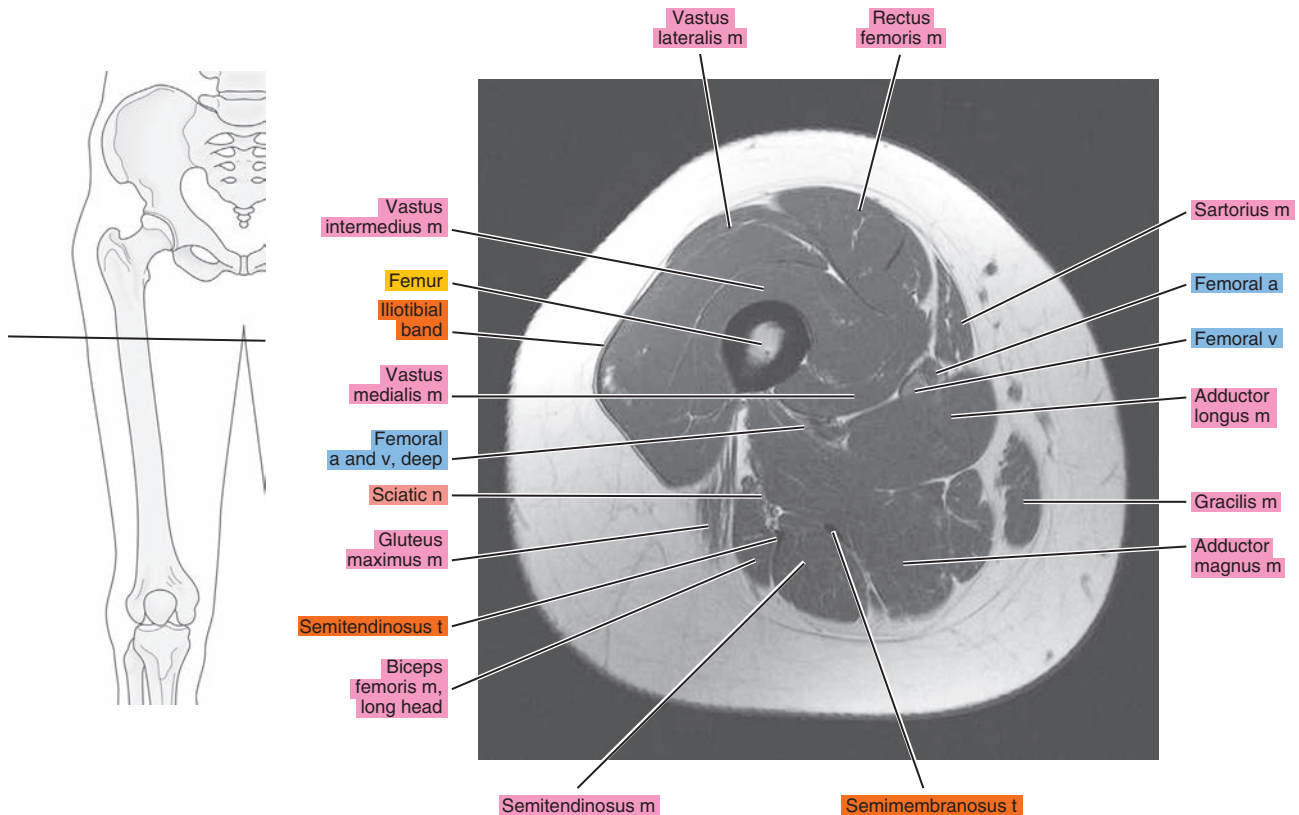


Figure 20.1.7

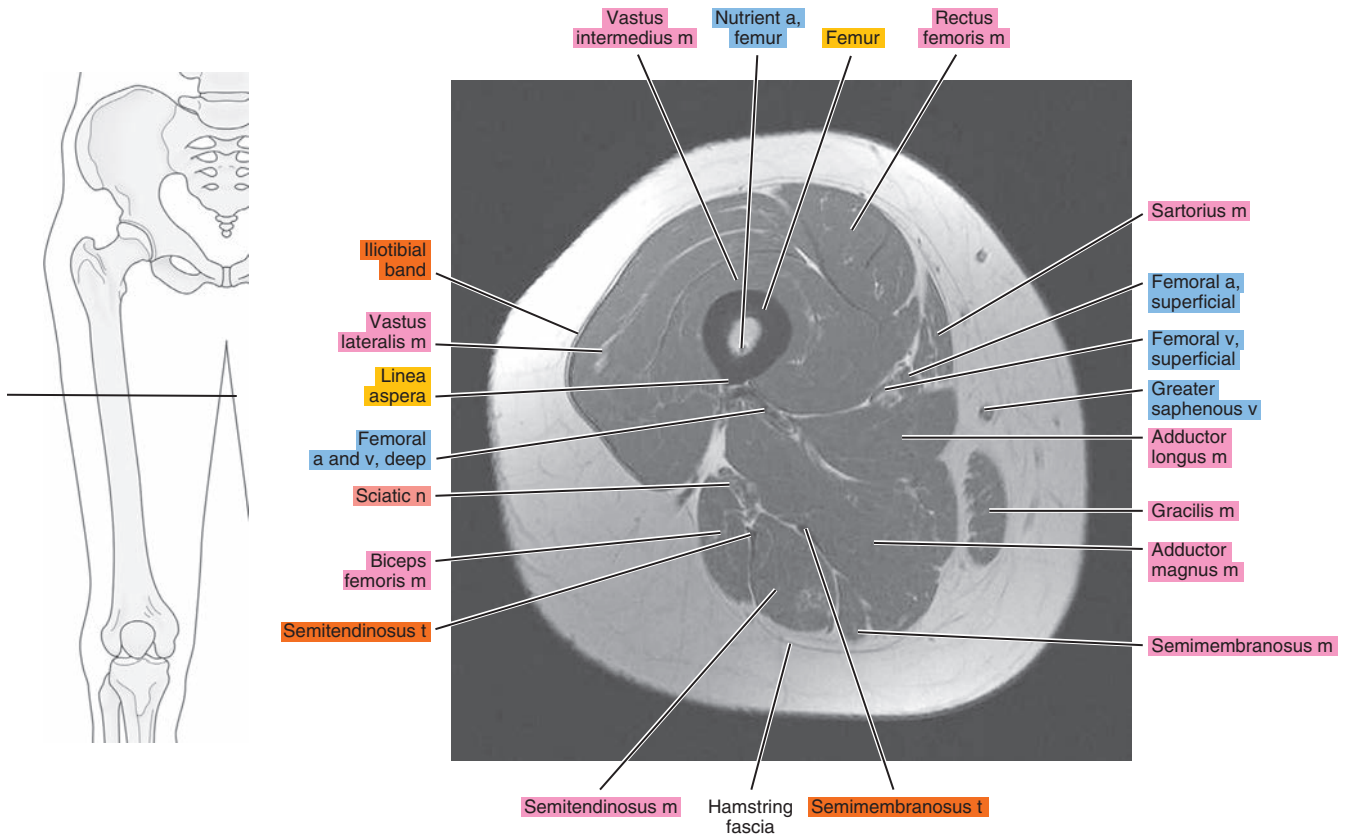


Figure 20.1.8

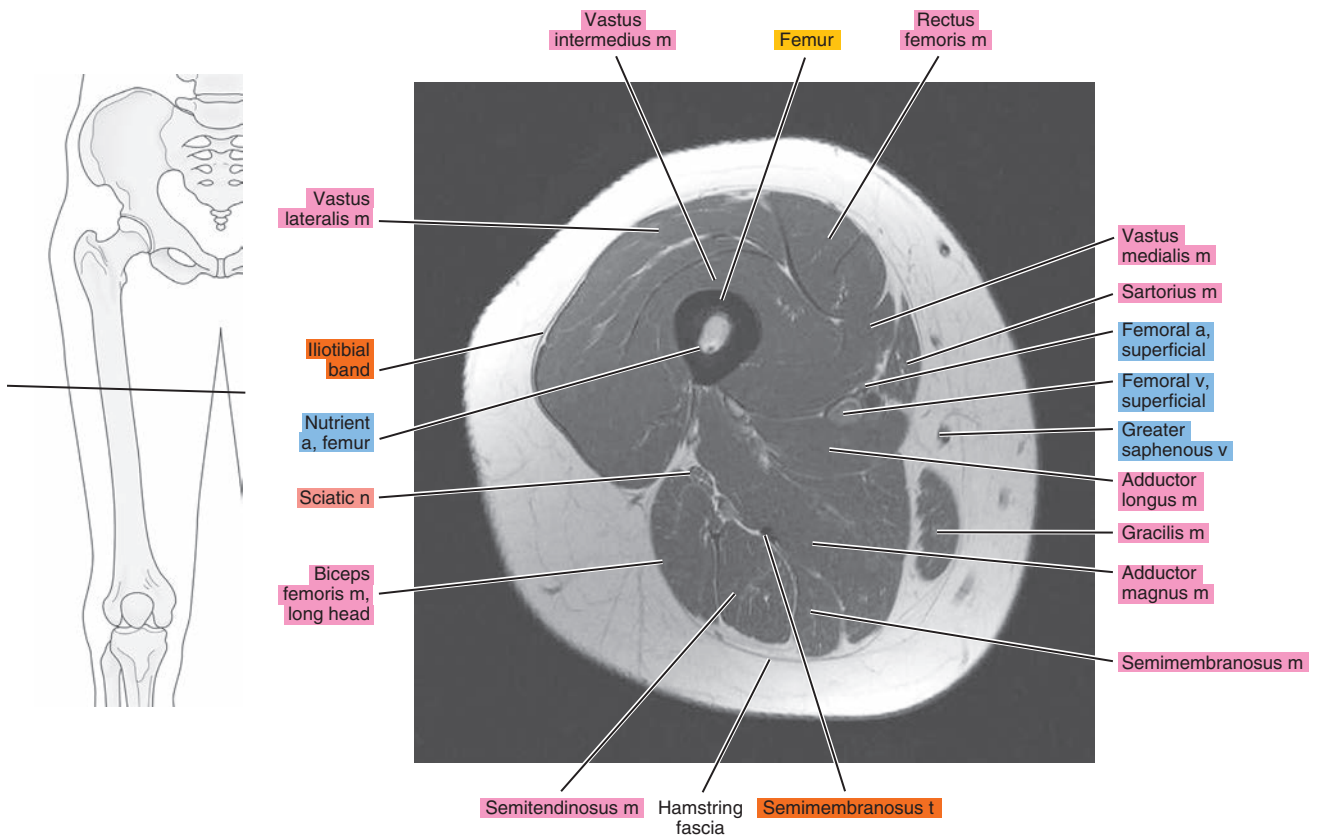


Figure 20.1.9

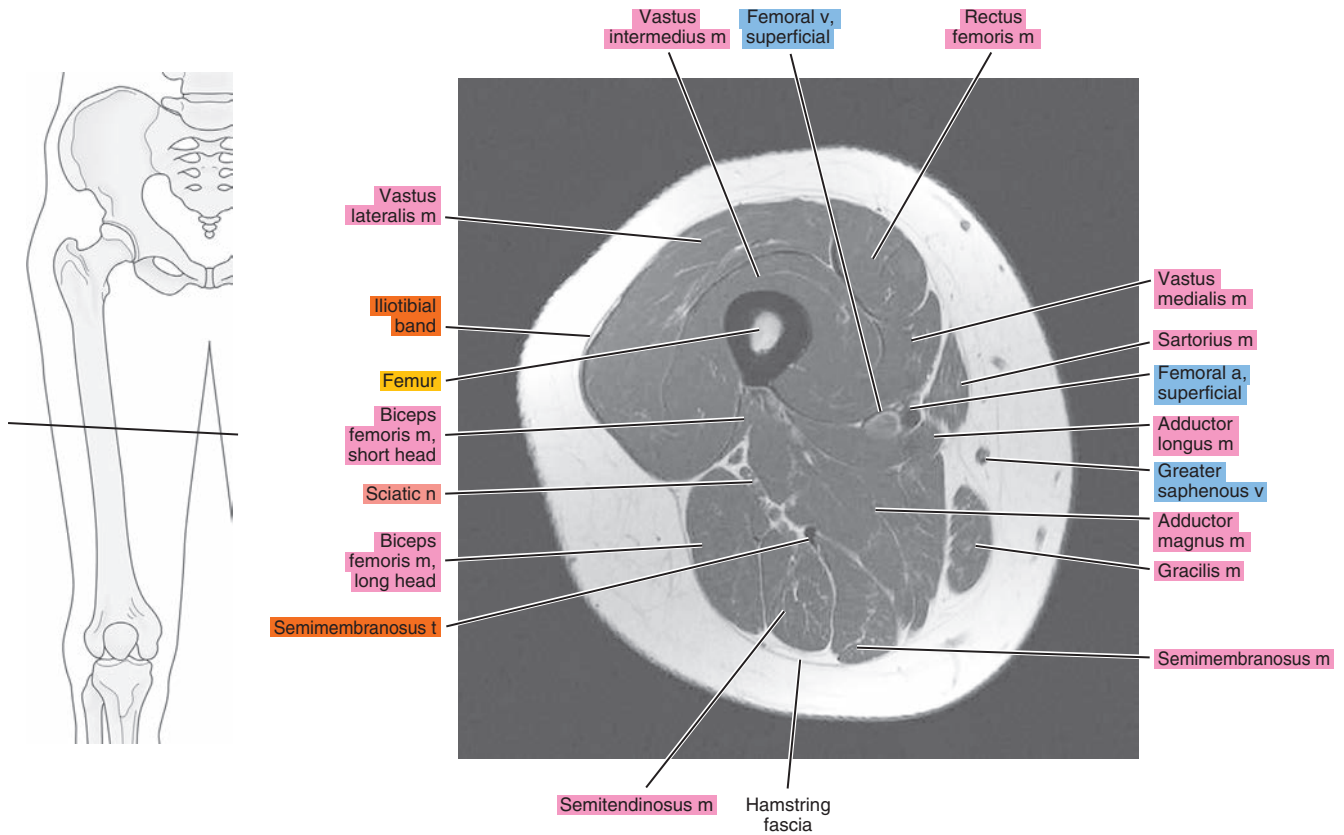


Figure 20.1.10

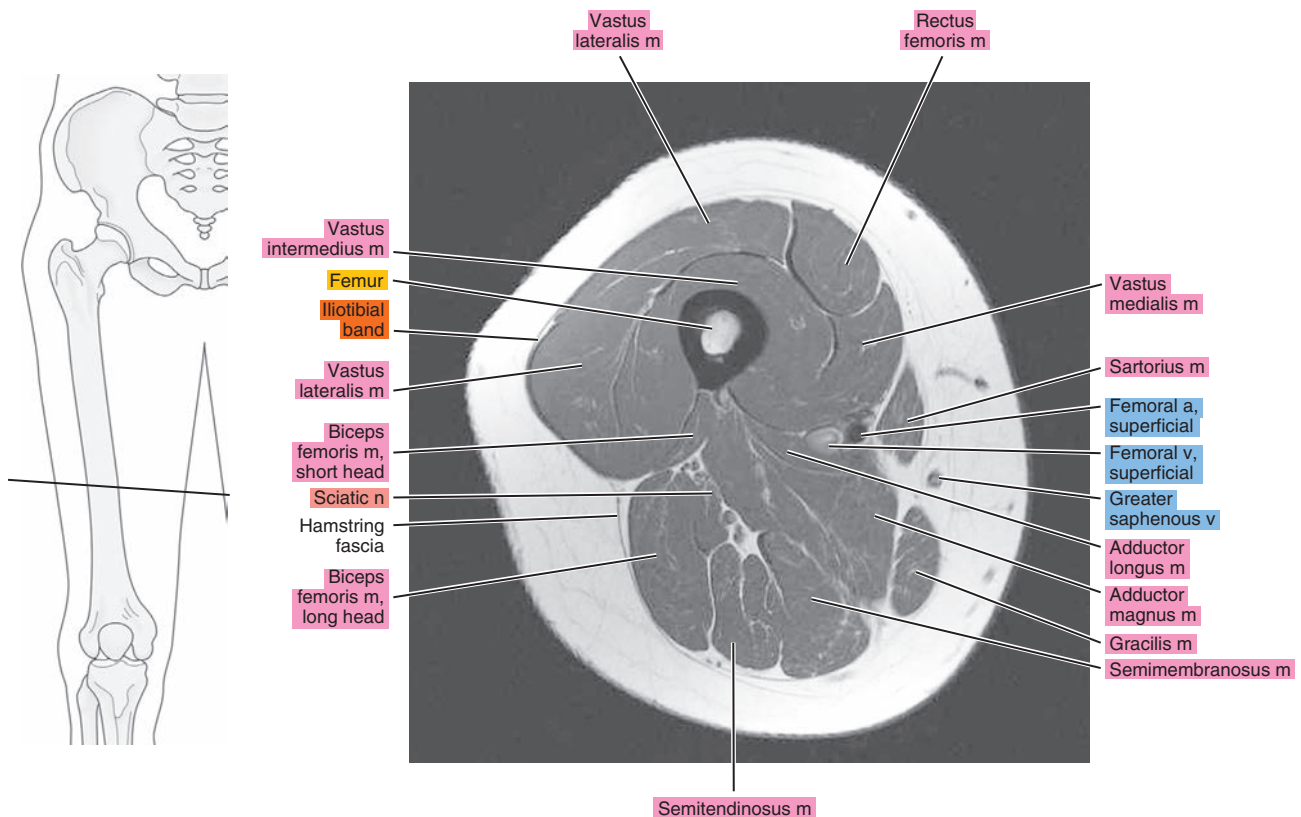




Figure 20.1.11

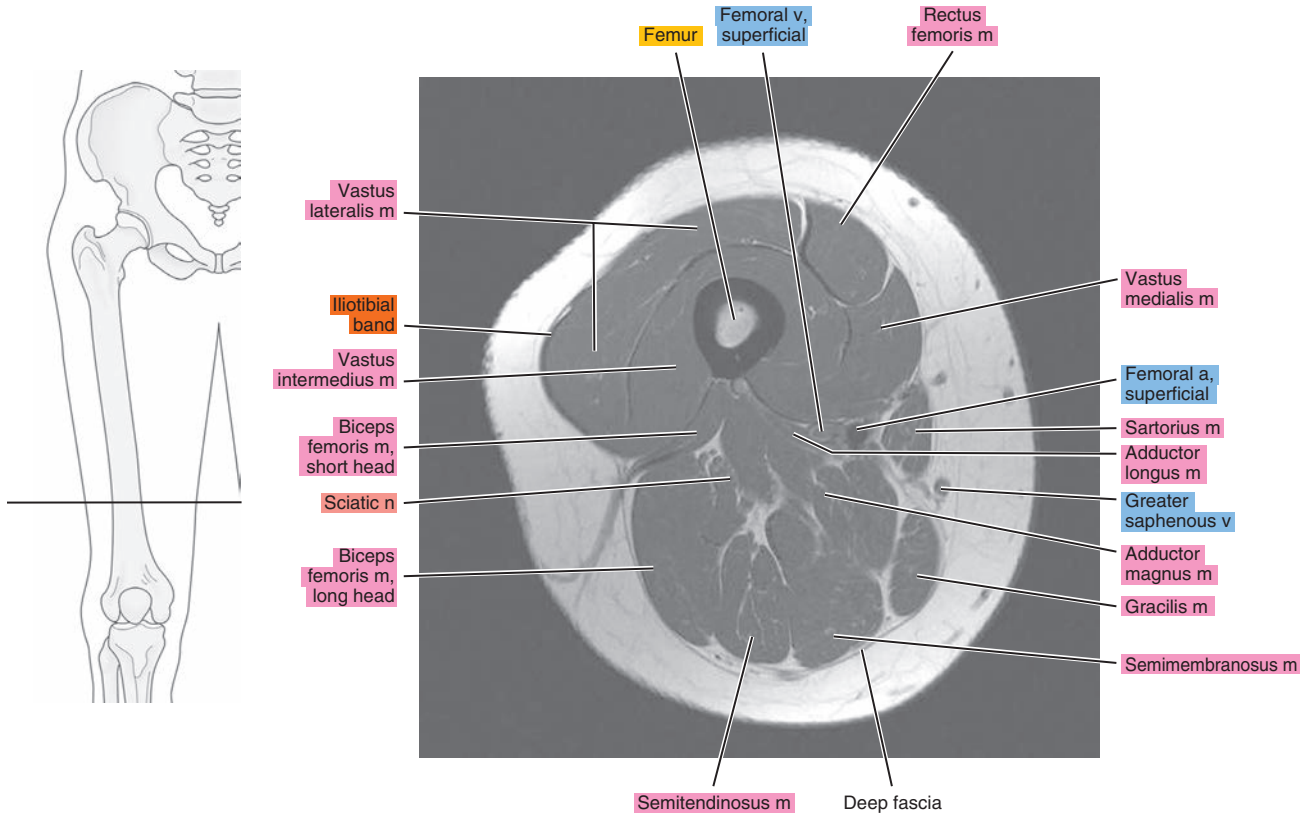


Figure 20.1.12

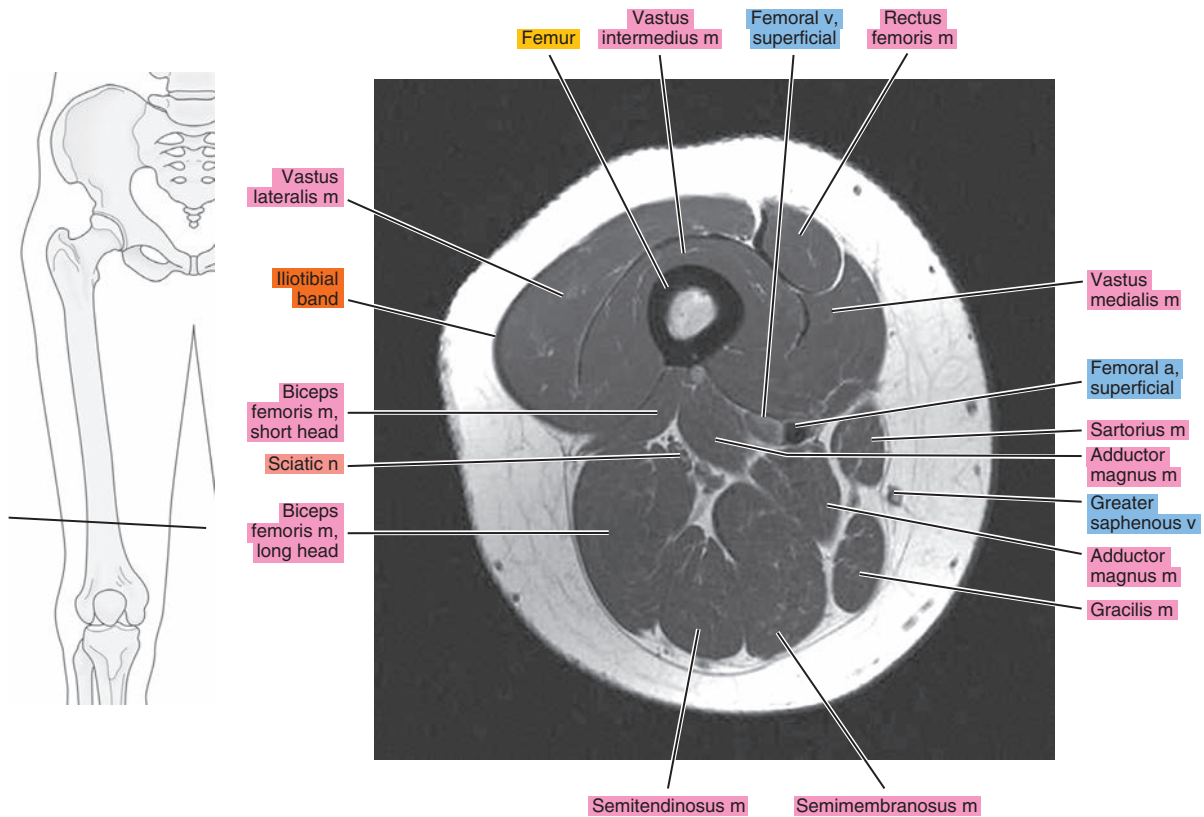




Figure 20.1.13

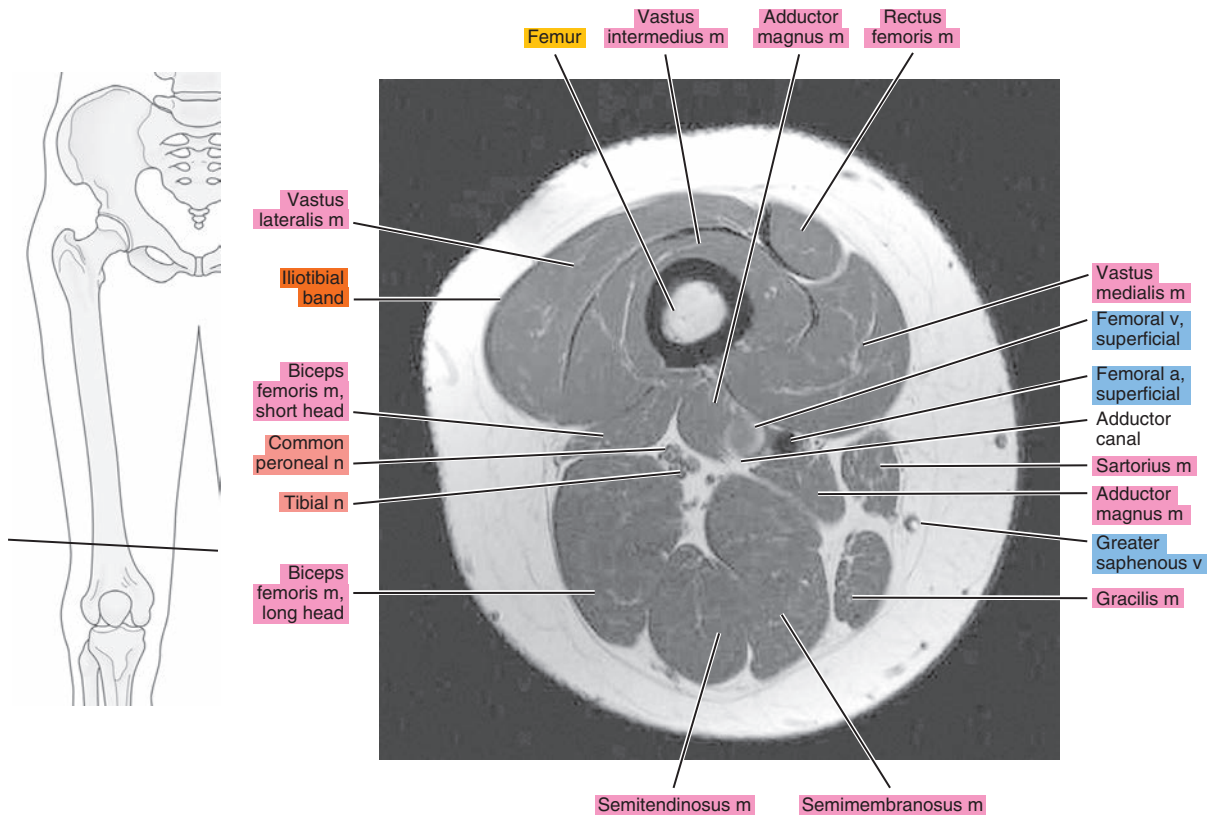


Figure 20.1.14

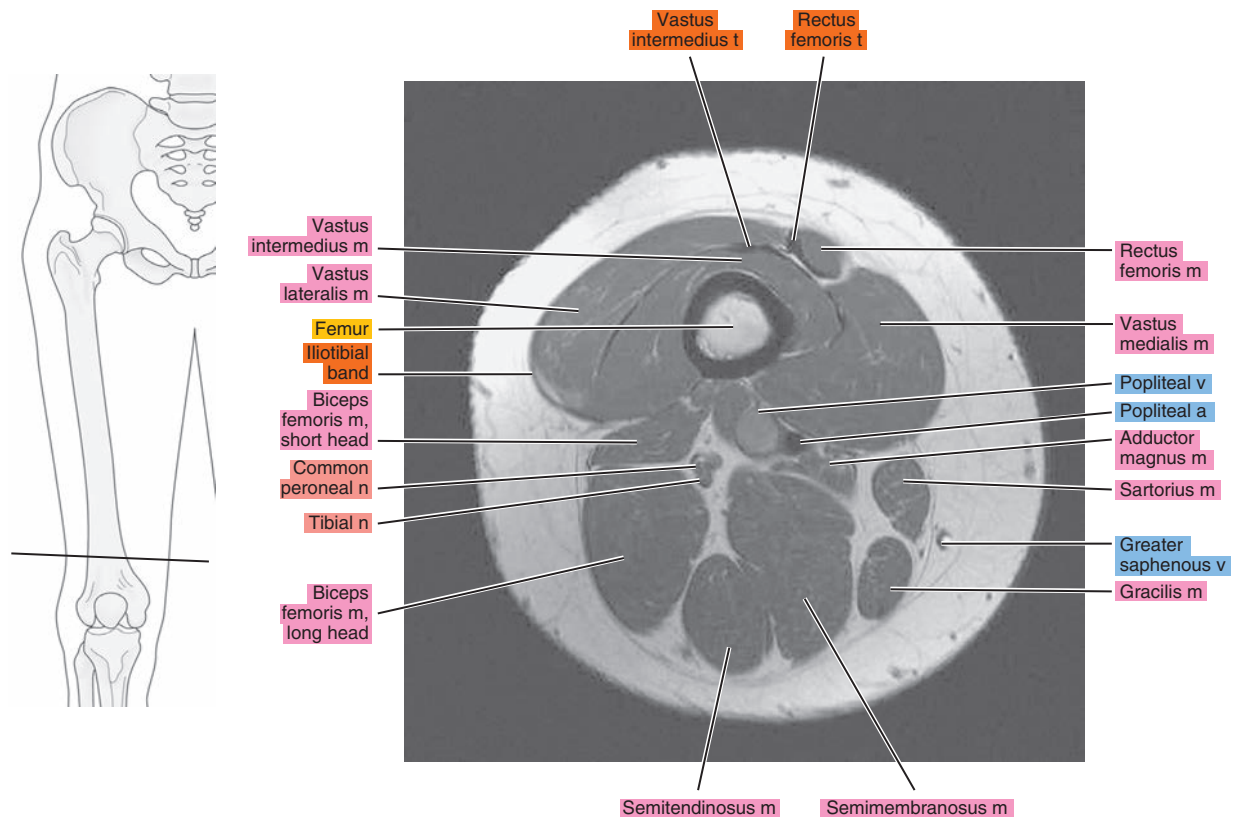


Figure 20.1.15

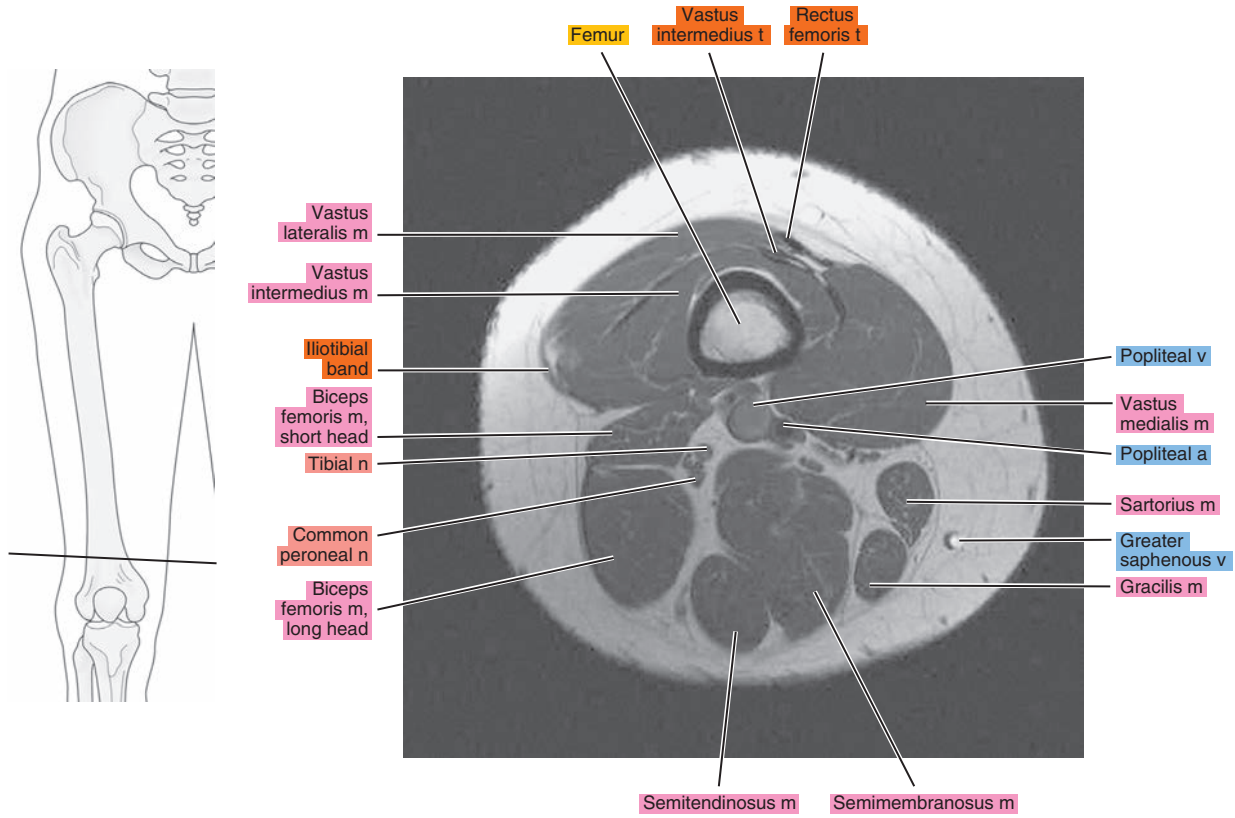
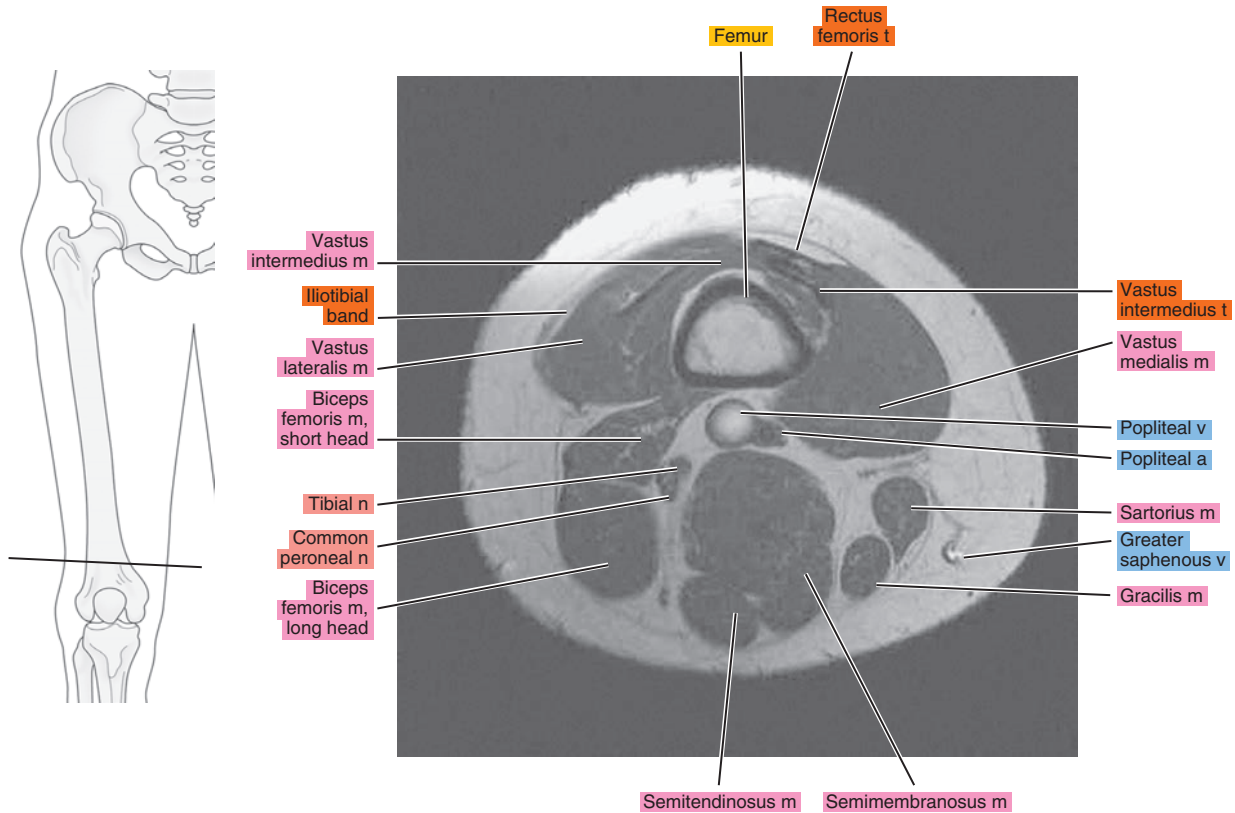


Figure 20.1.16



# SAGITTAL

Figure 20.2.1

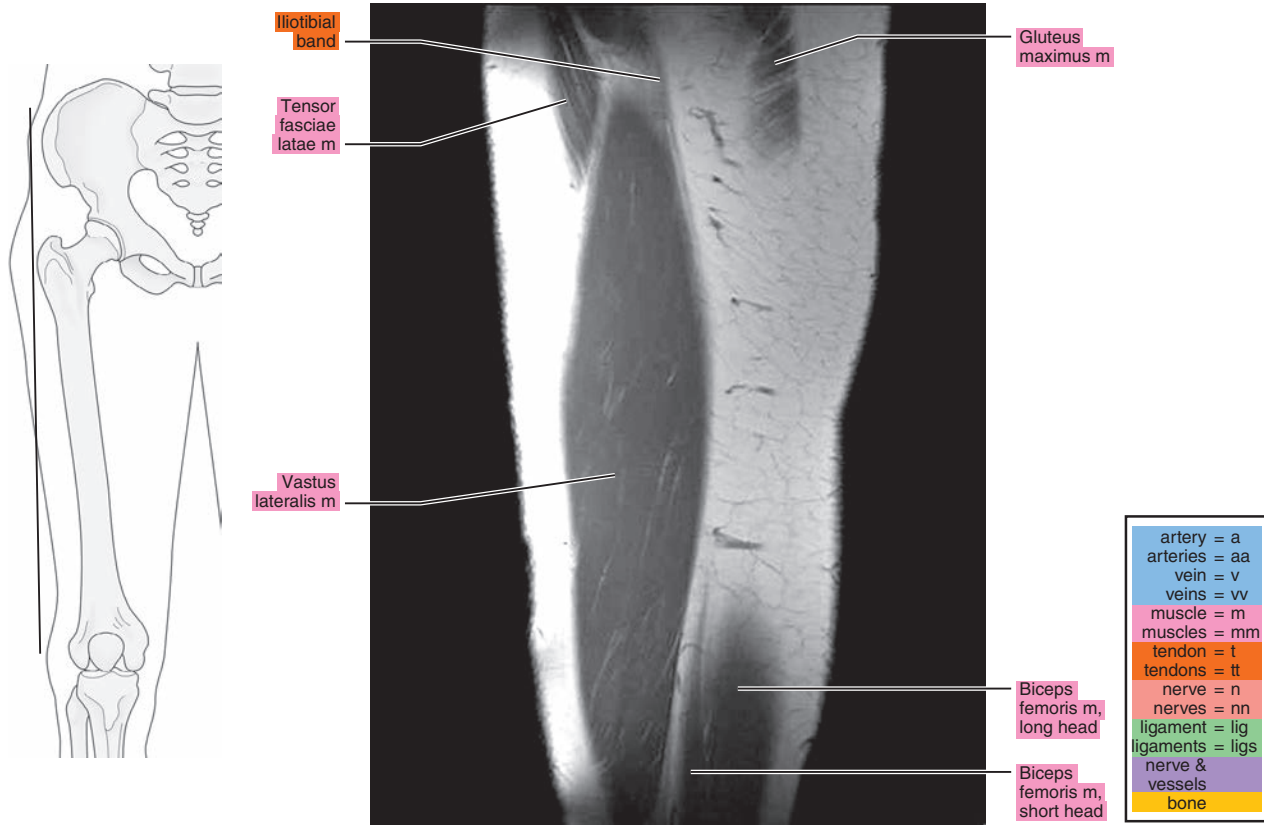


Figure 20.2.2

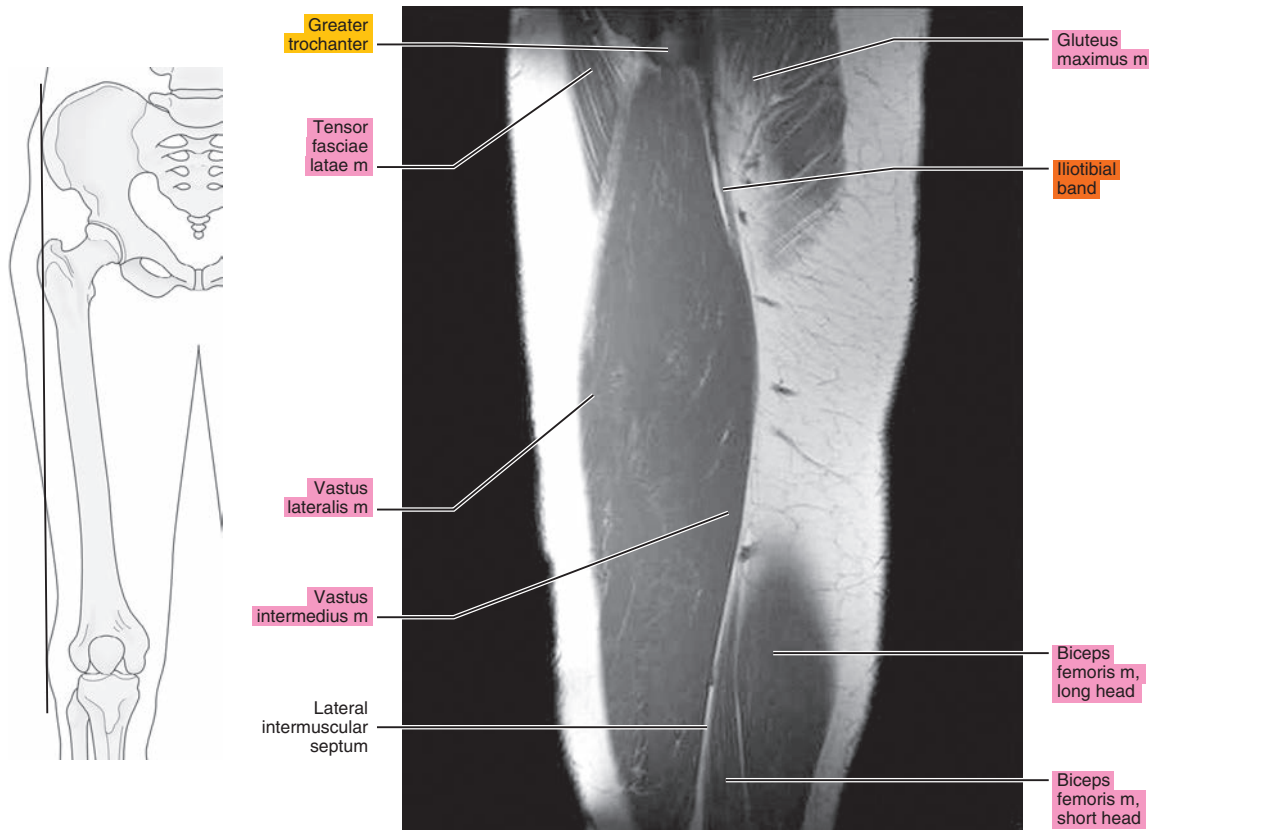


Figure 20.2.3

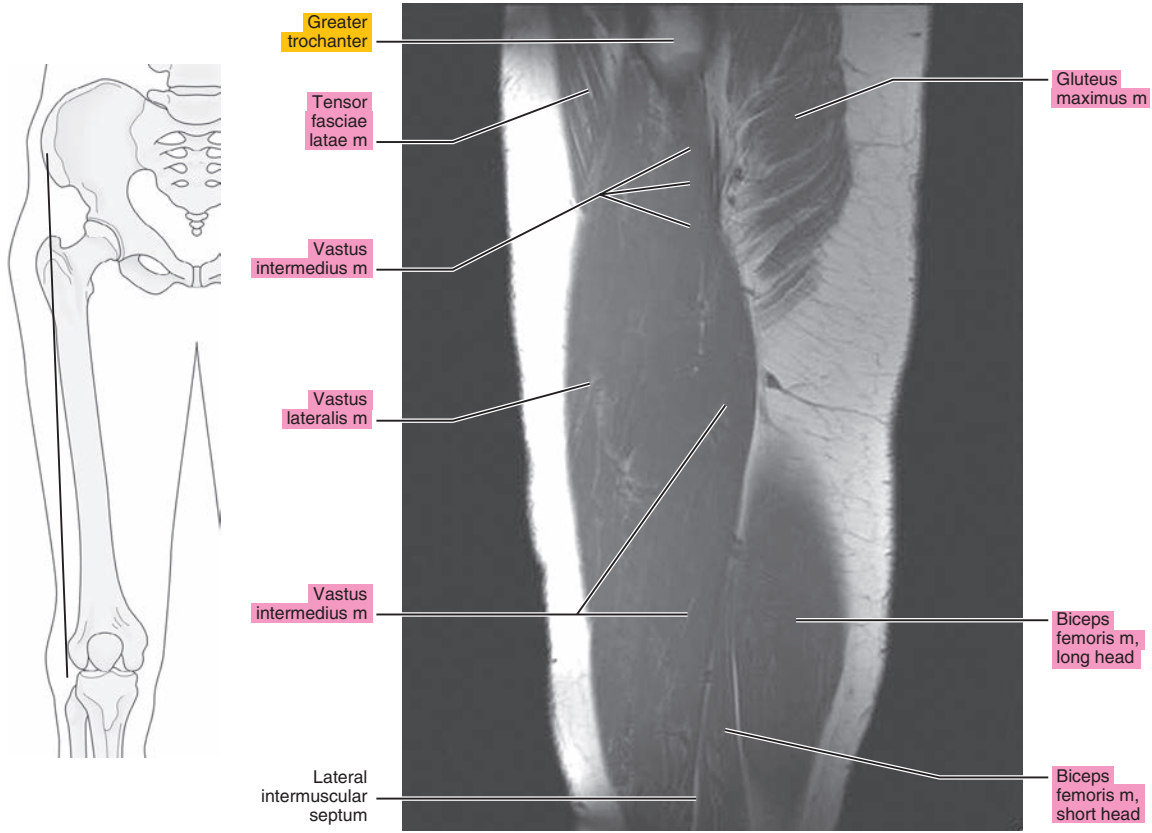


Figure 20.2.4

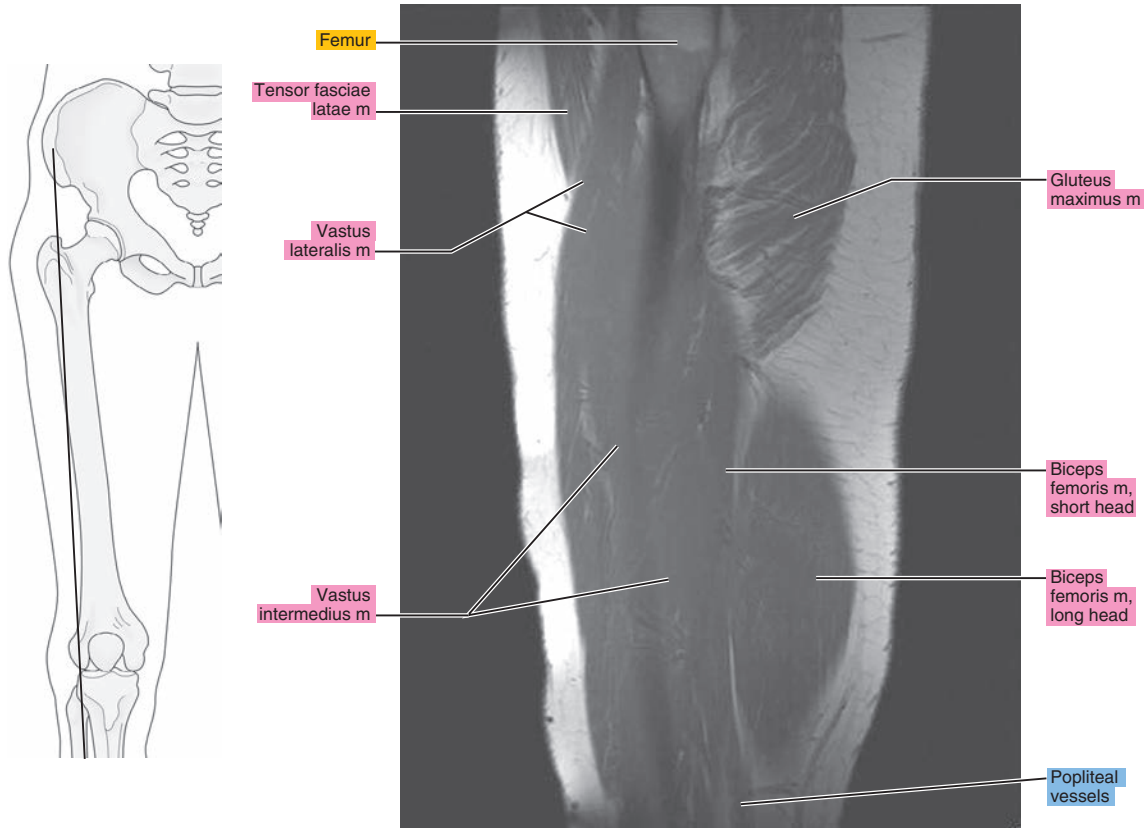




Figure 20.2.5

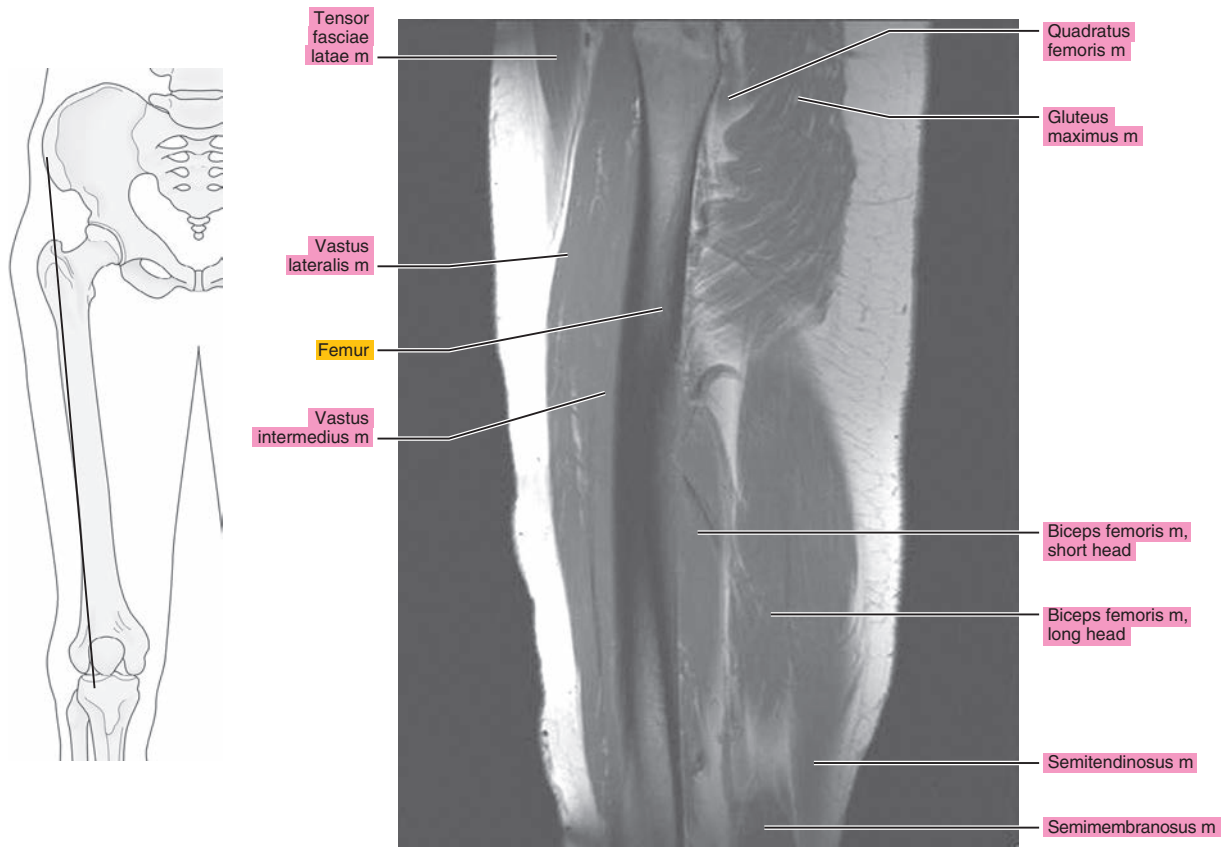


Figure 20.2.6

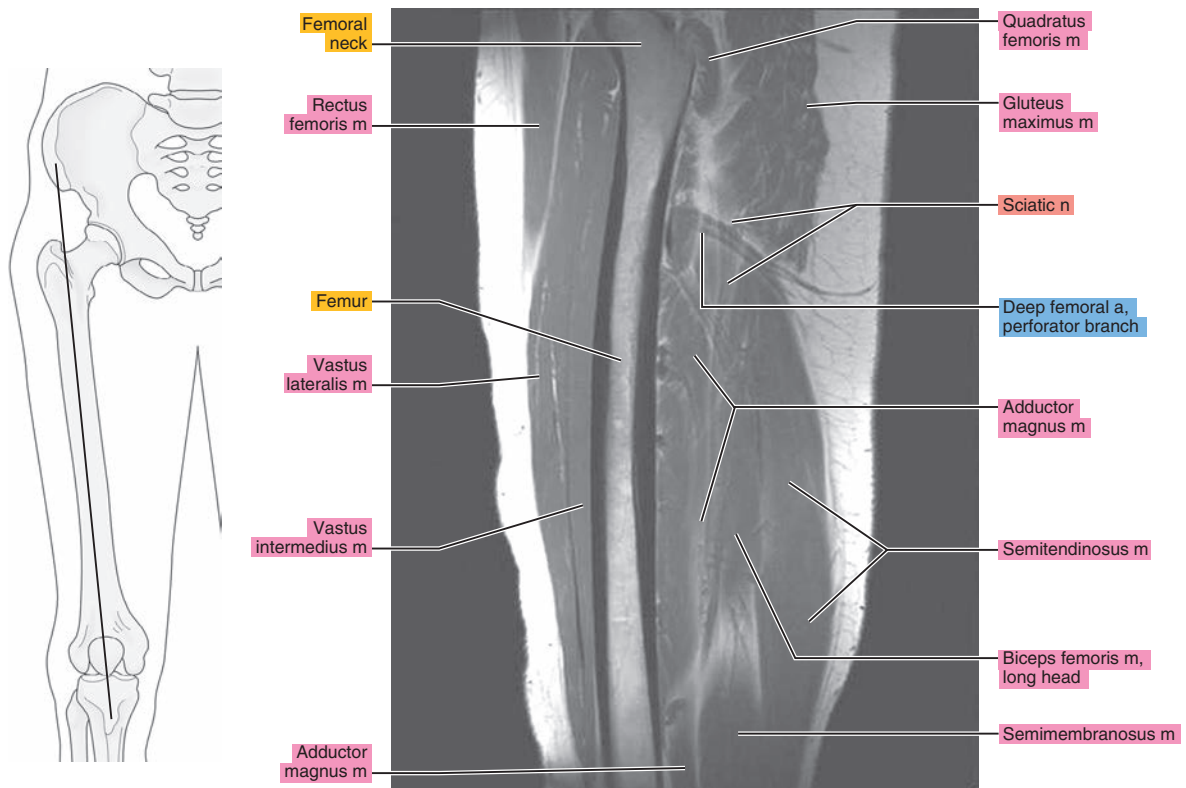


Figure 20.2.7

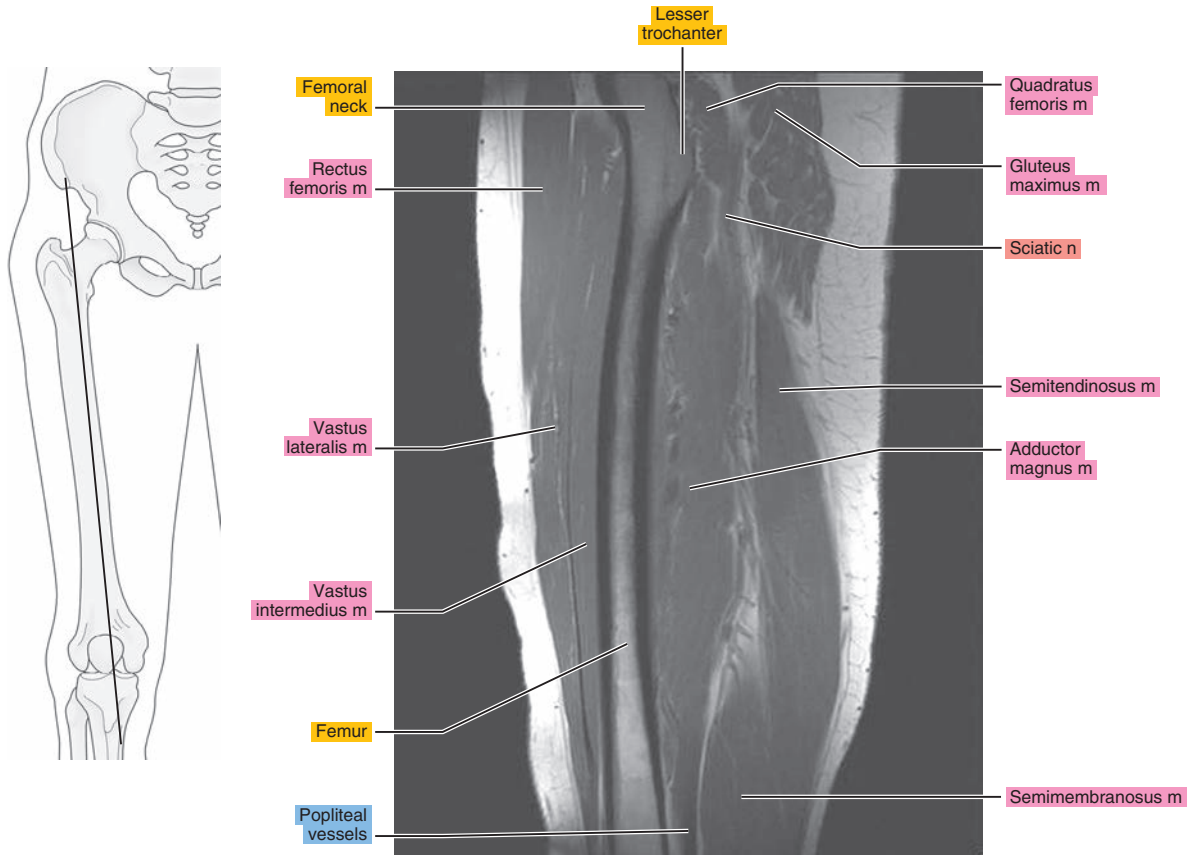


Figure 20.2.8

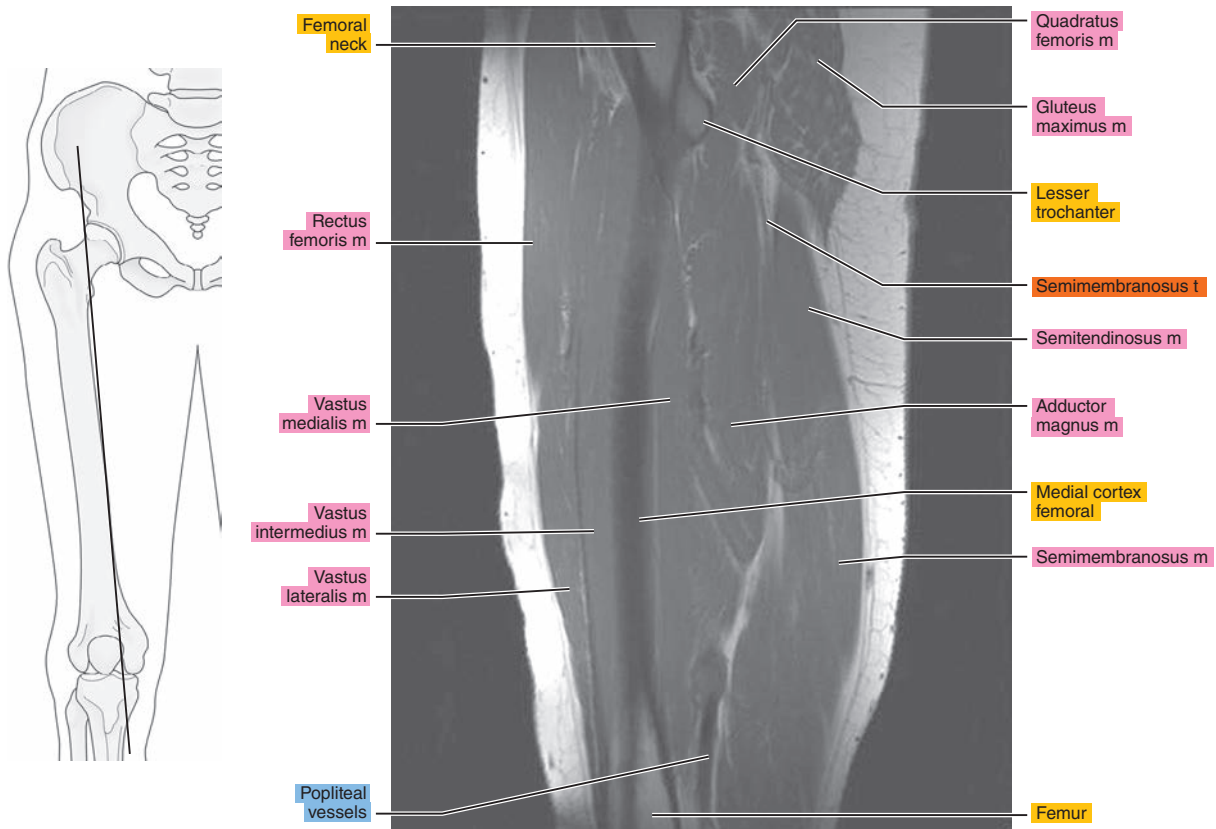


Figure 20.2.9

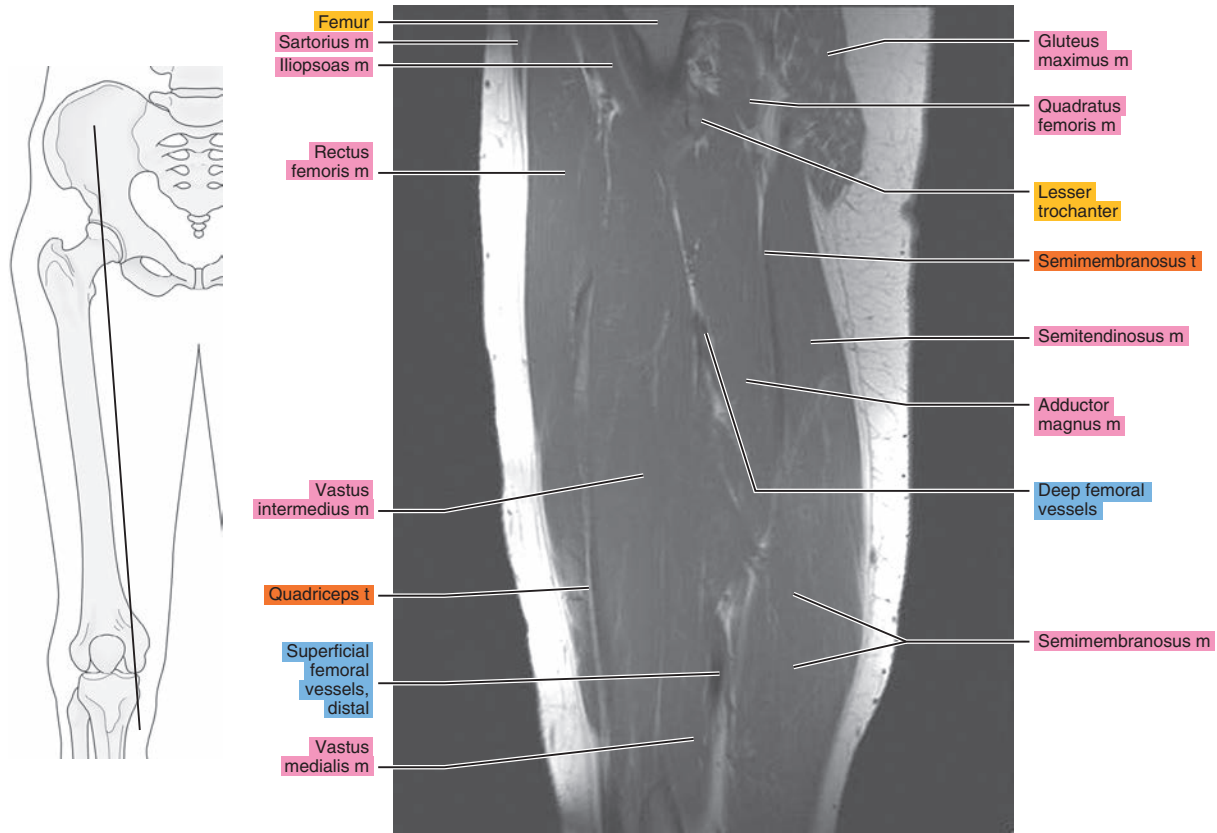


Figure 20.2.10

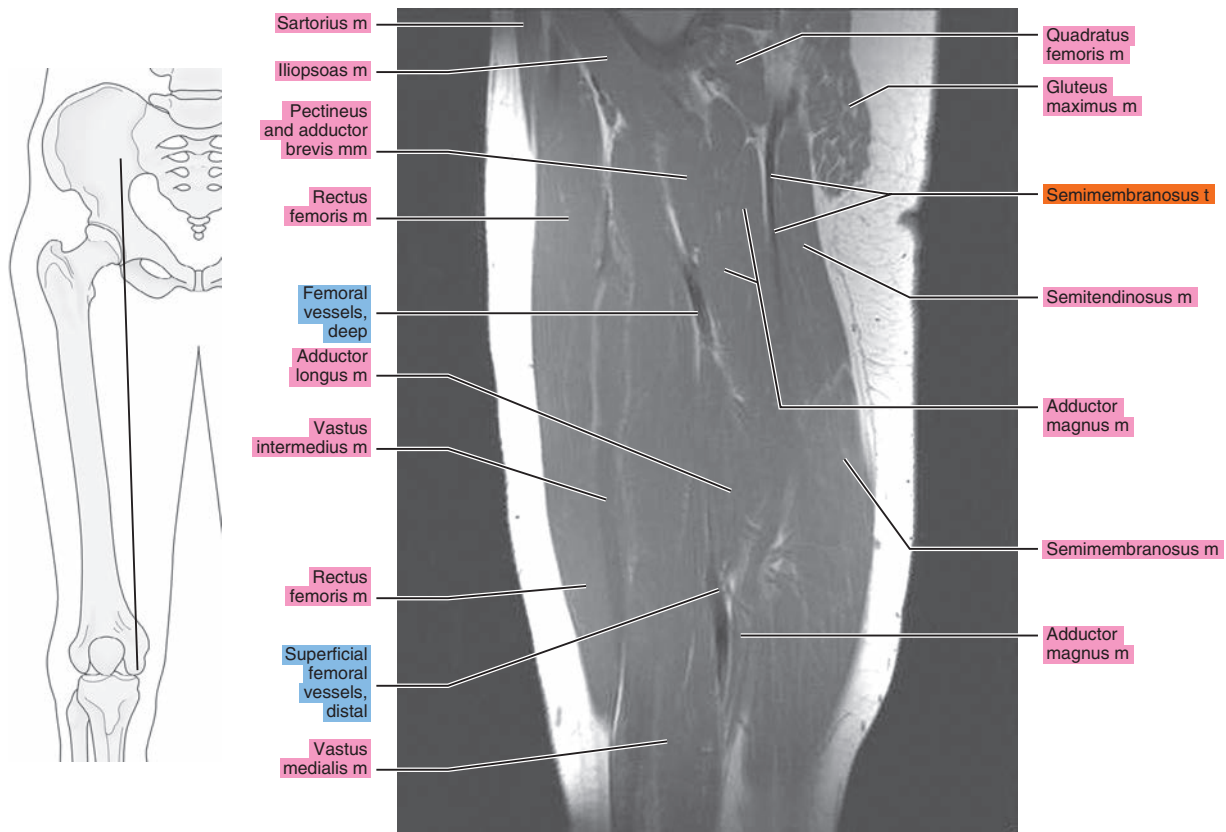


Figure 20.2.11

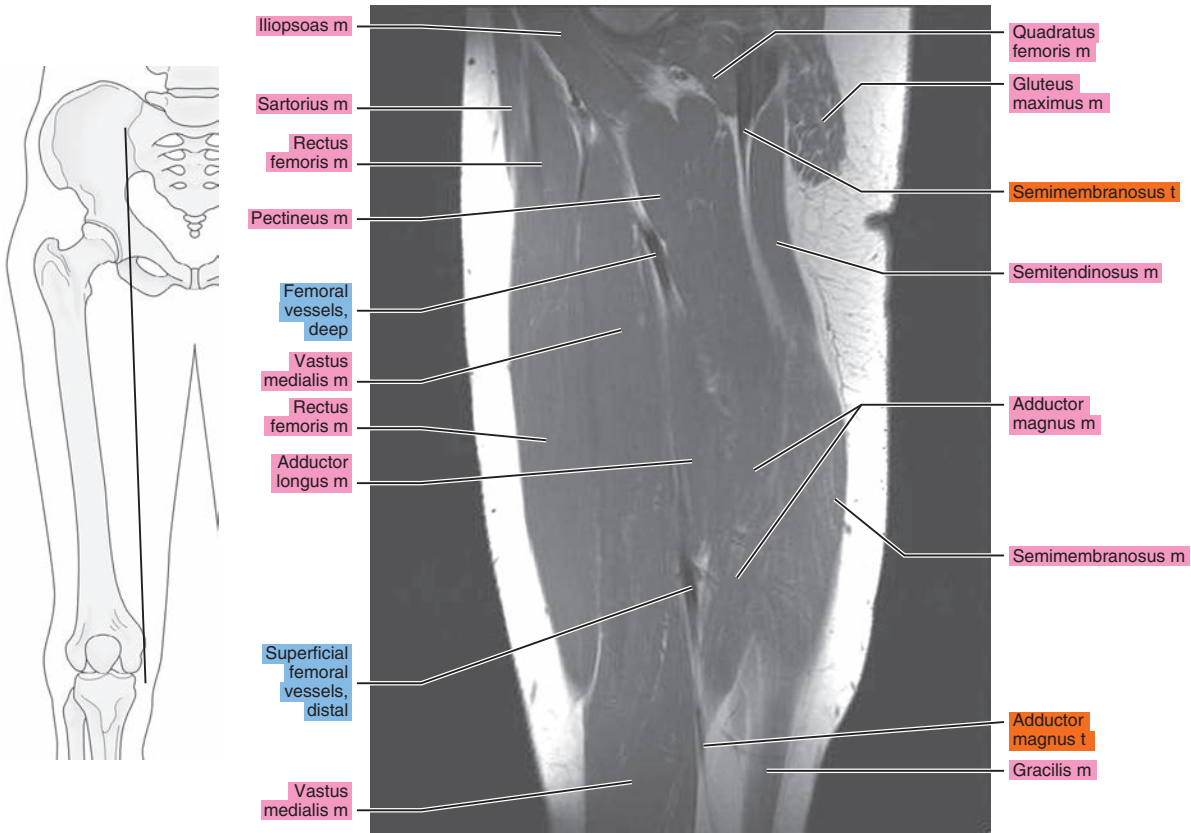


Figure 20.2.12

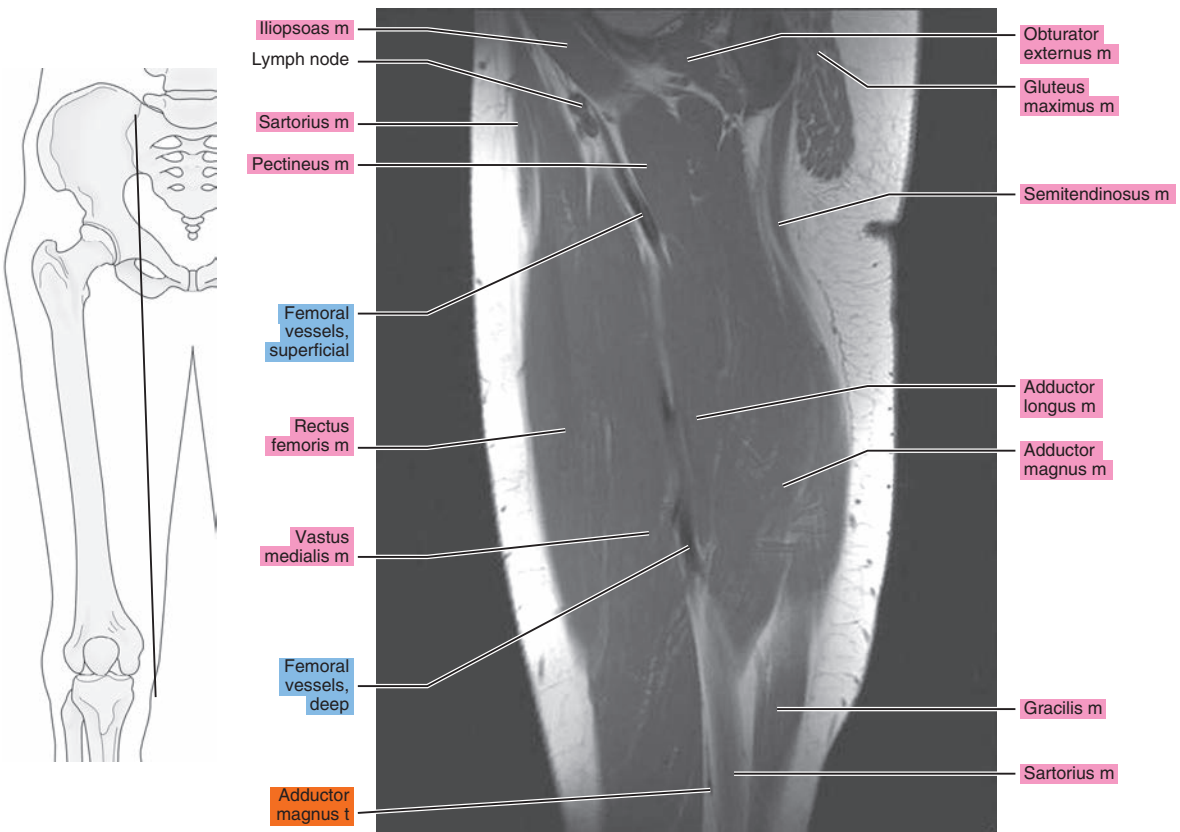




Figure 20.2.13

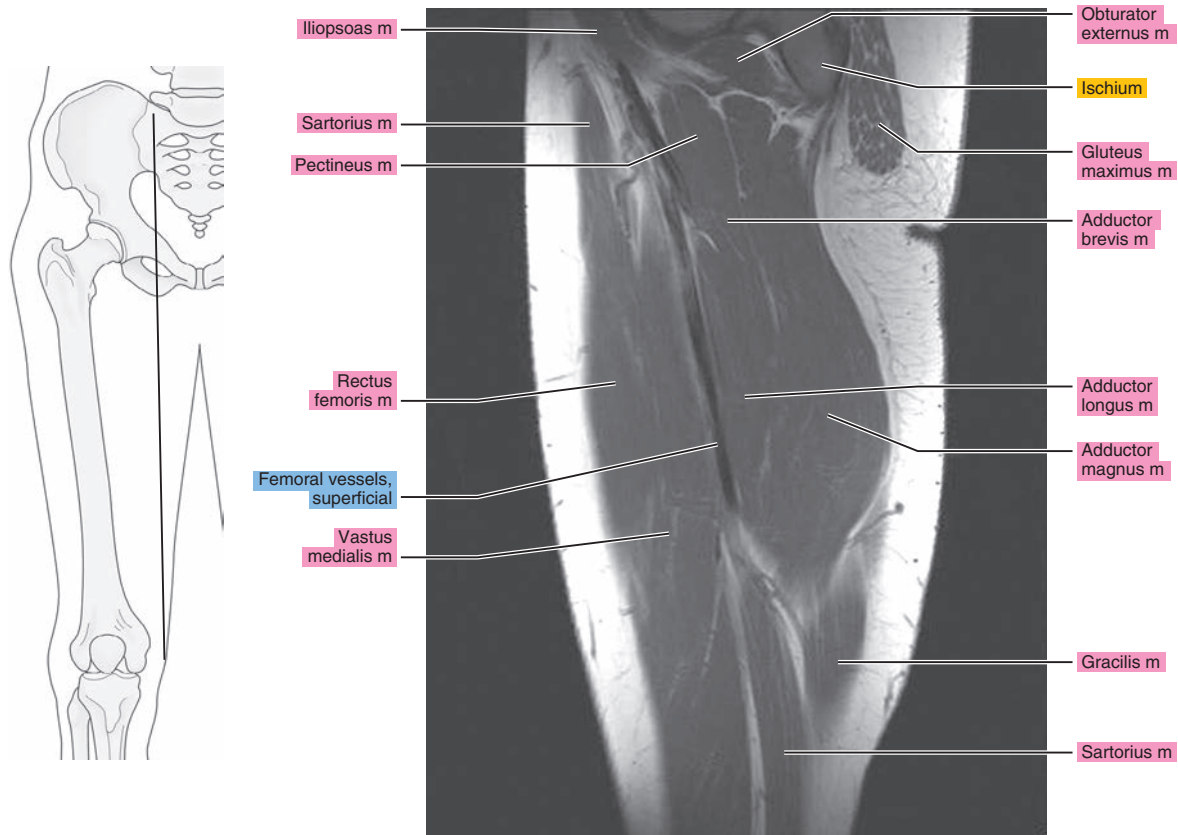


Figure 20.2.14

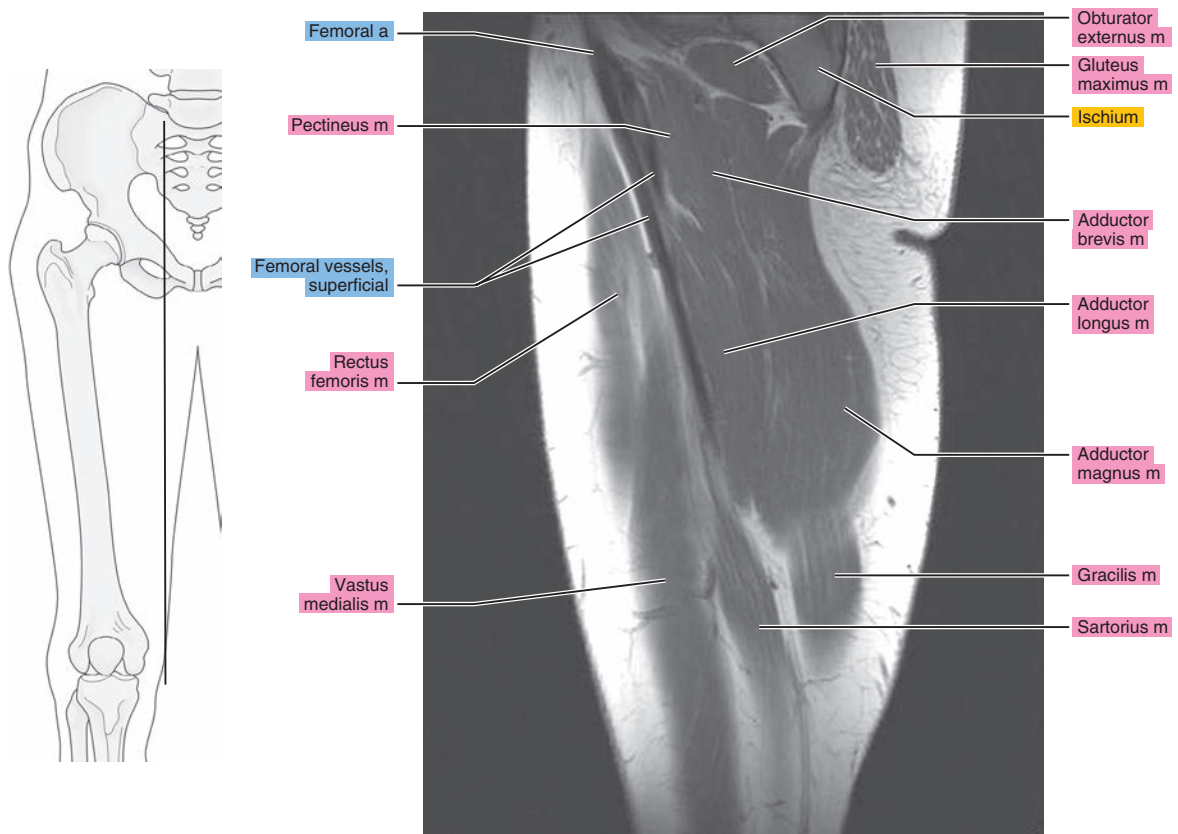


Figure 20.2.15

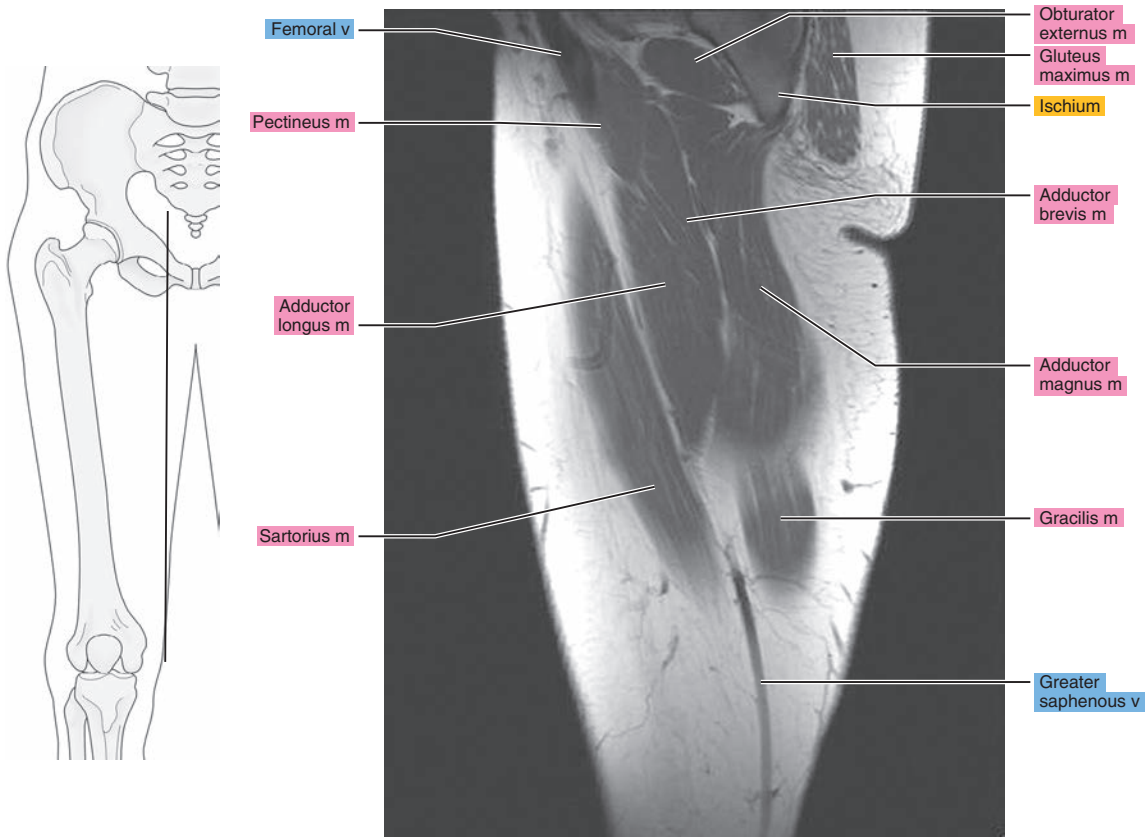


Figure 20.2.16

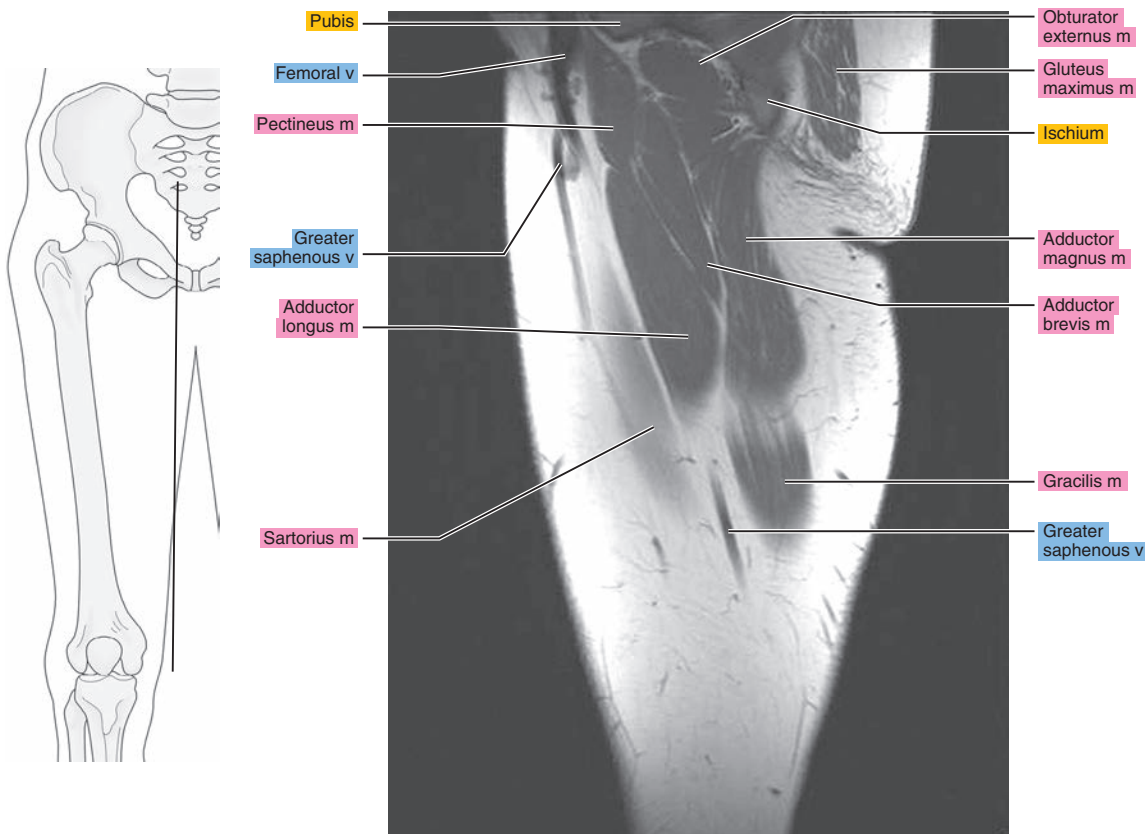
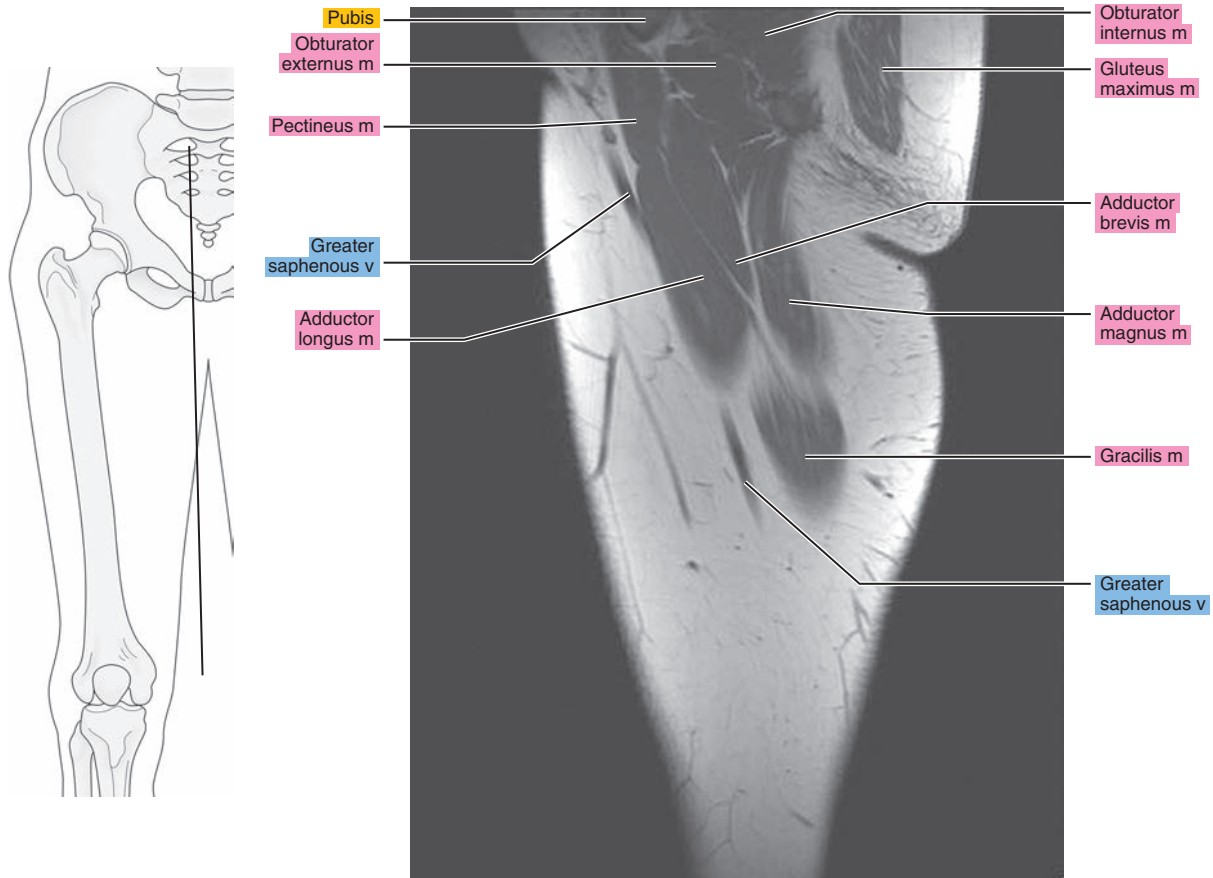


Figure 20.2.17



# CORONAL

Figure 20.3.1

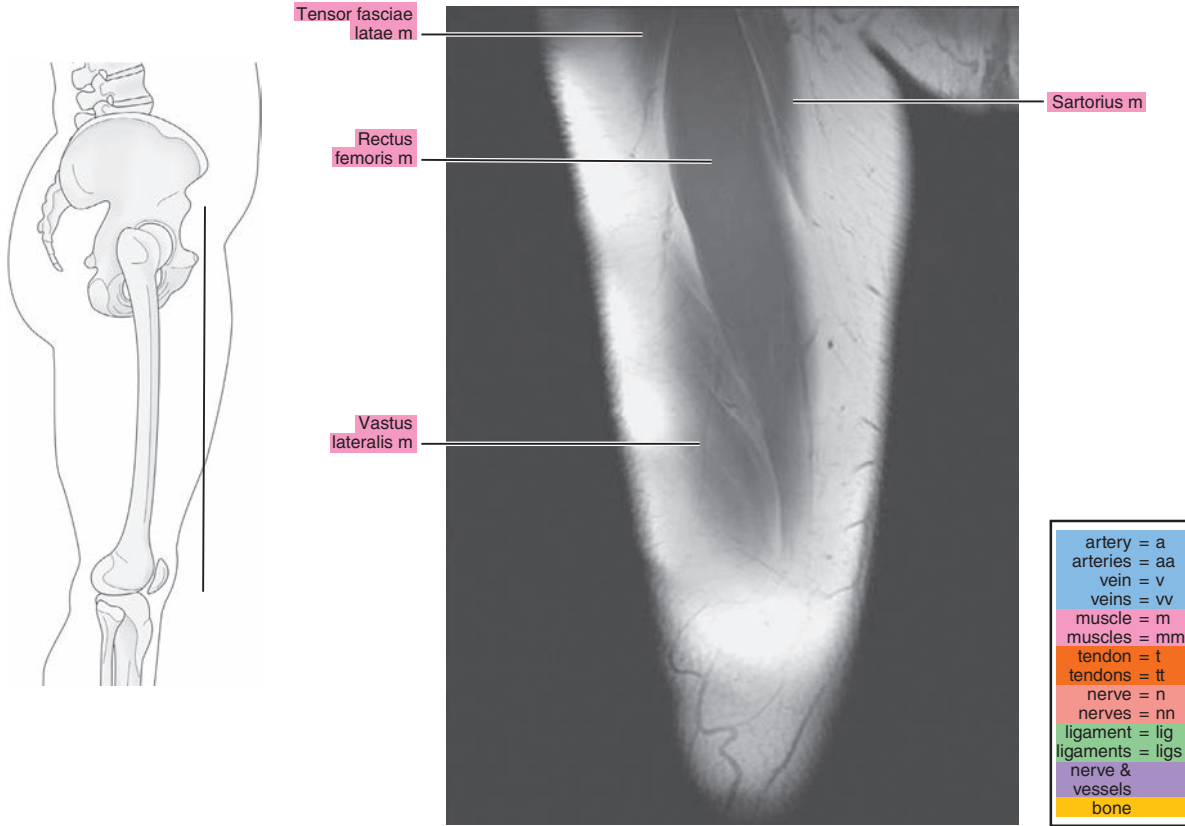


Figure 20.3.2

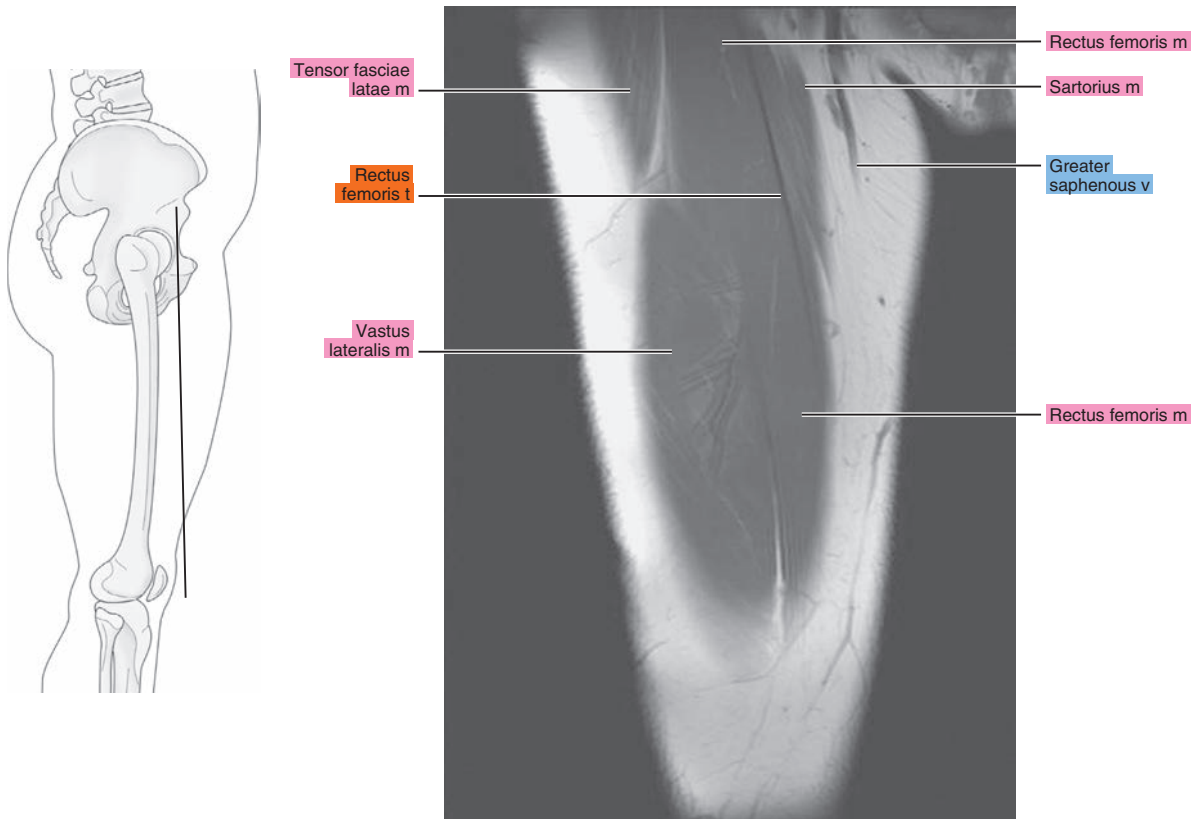




Figure 20.3.3

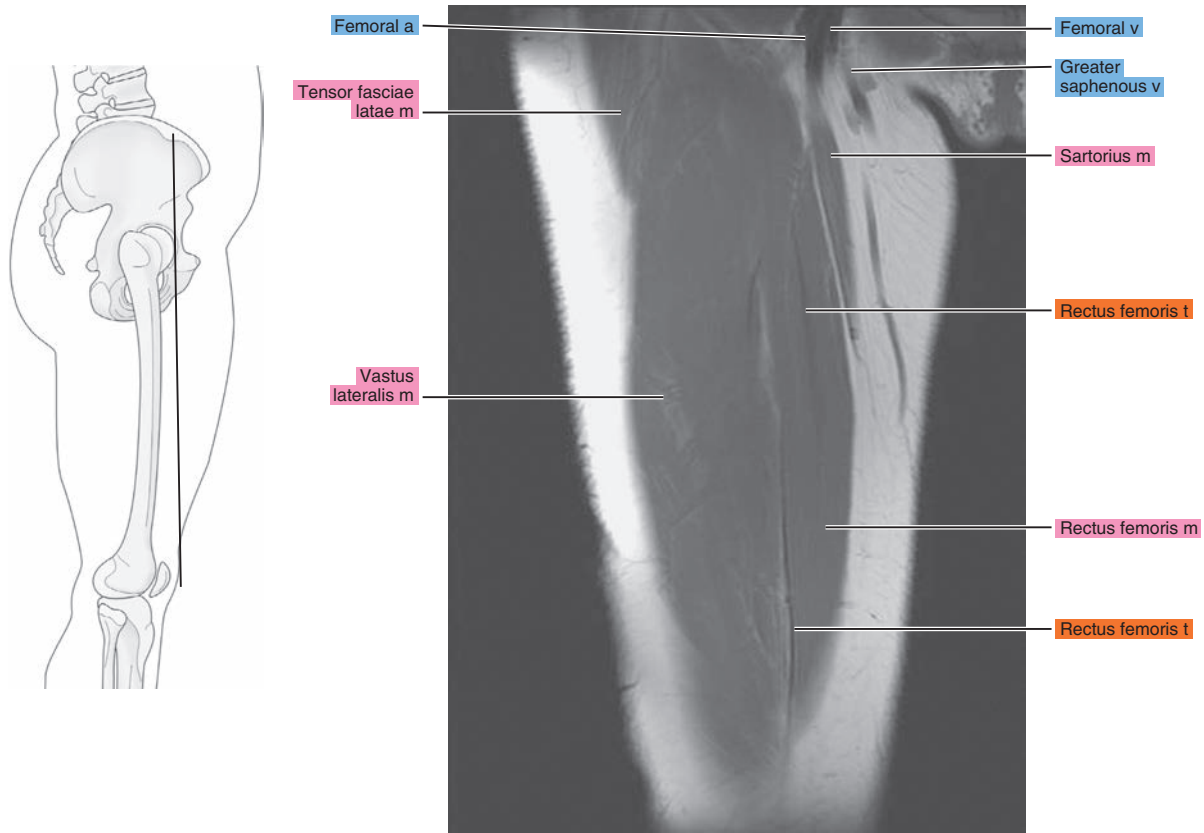


Figure 20.3.4

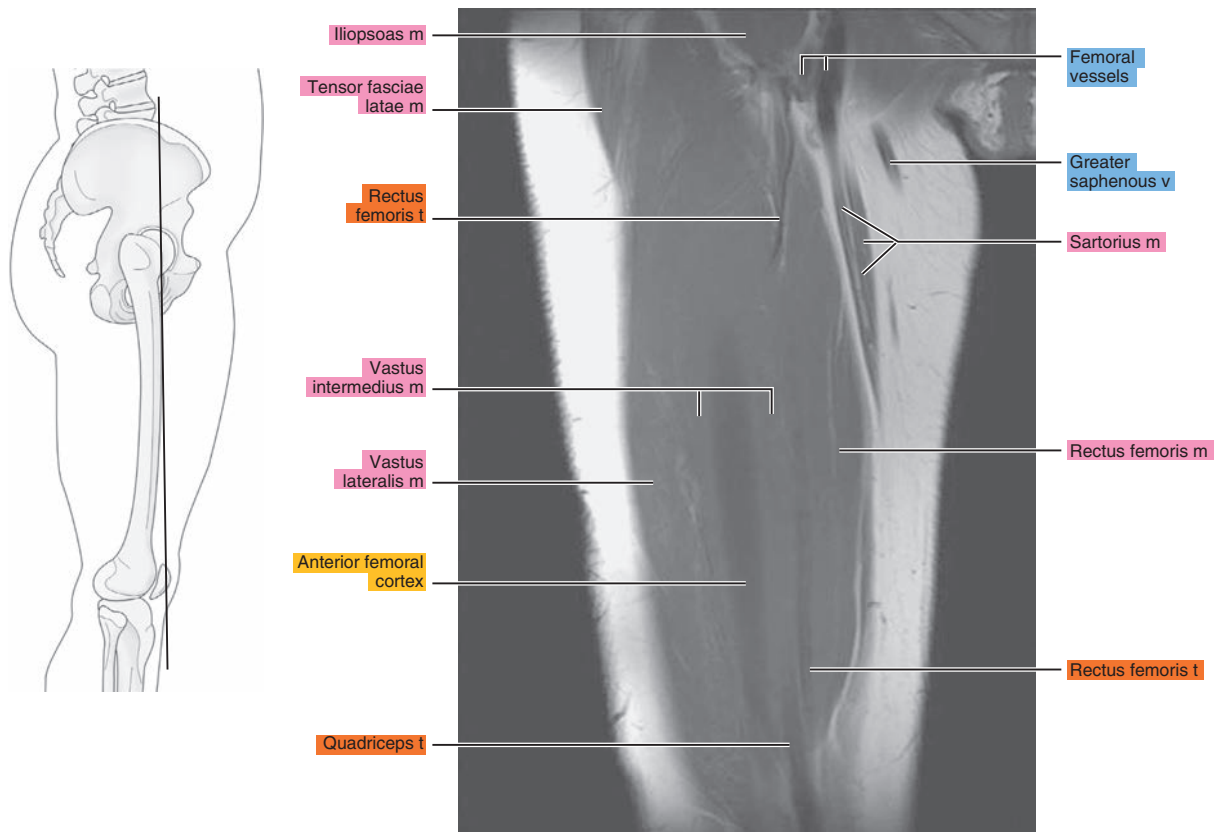


Figure 20.3.5

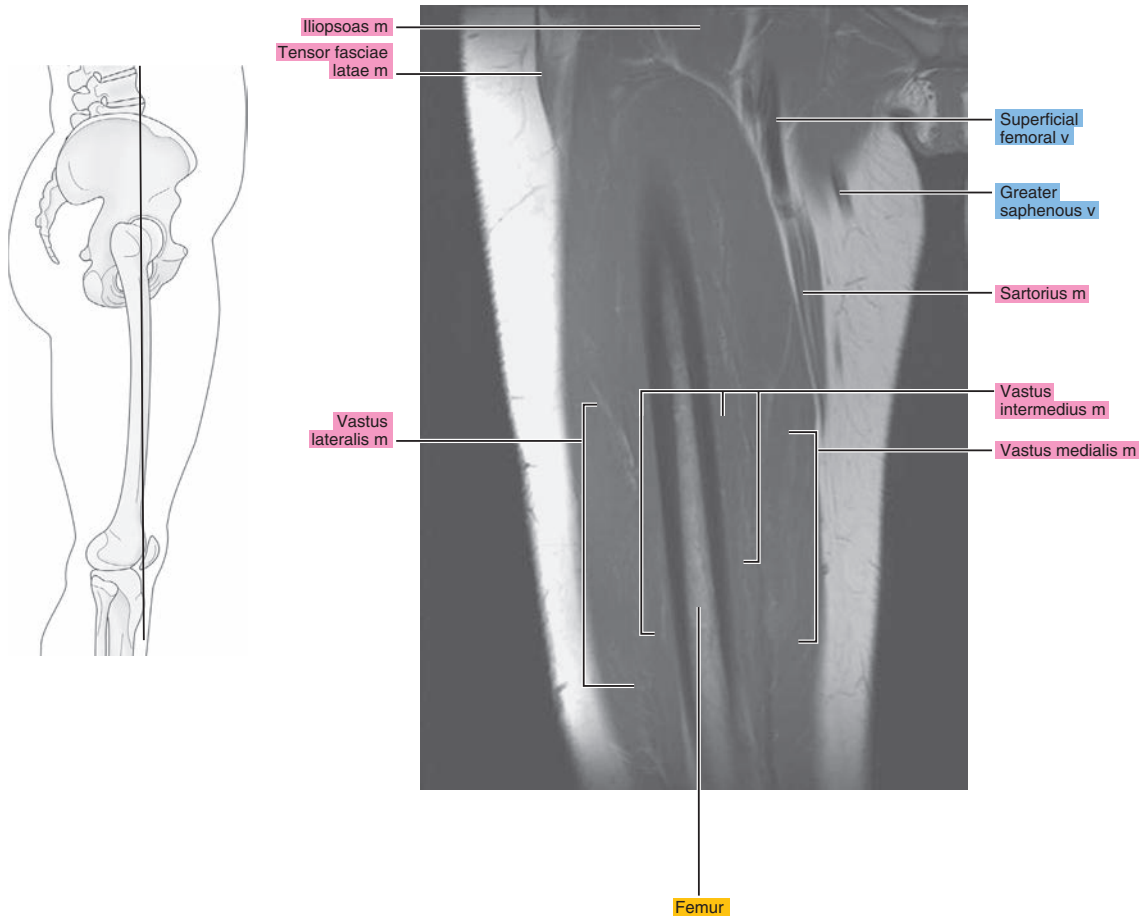


Figure 20.3.6

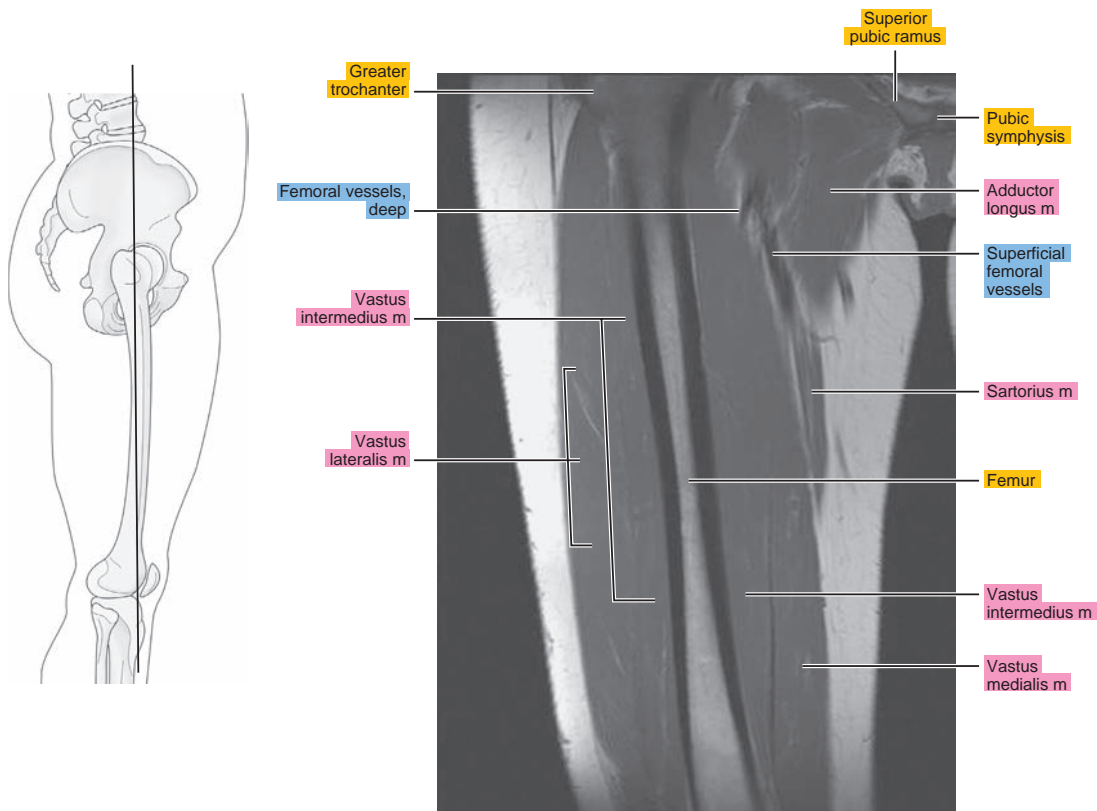


Figure 20.3.7

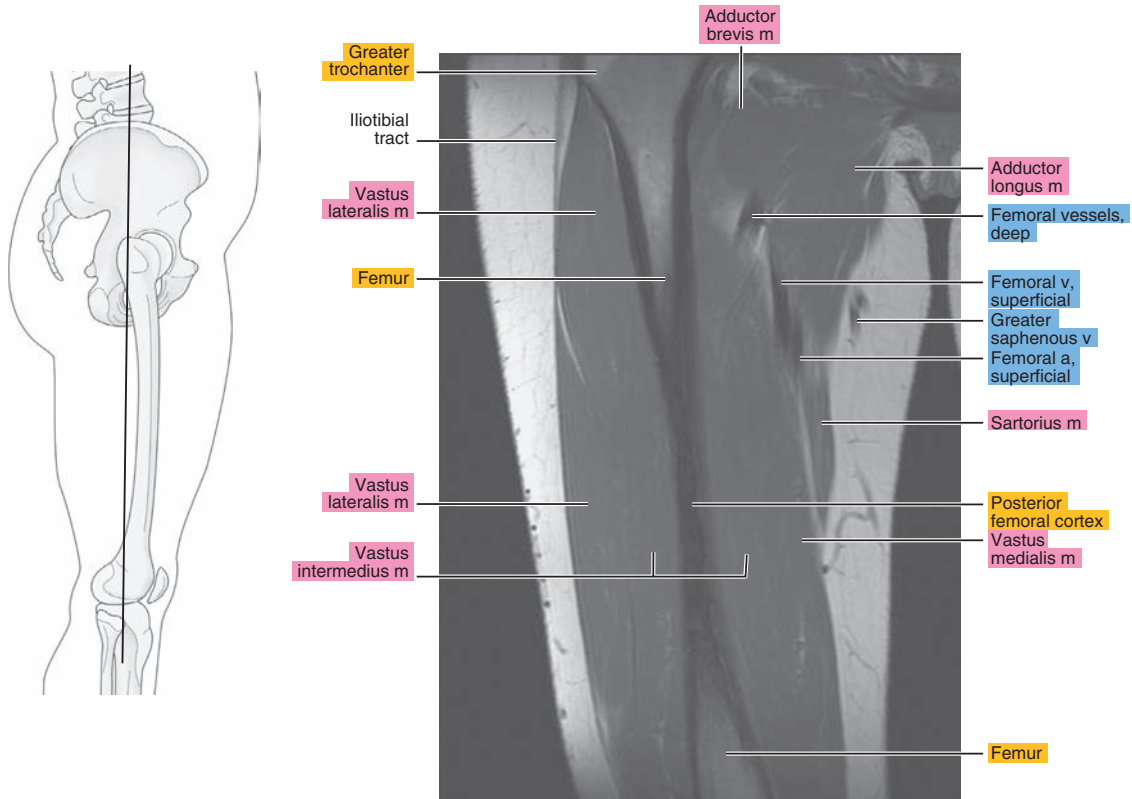


Figure 20.3.8

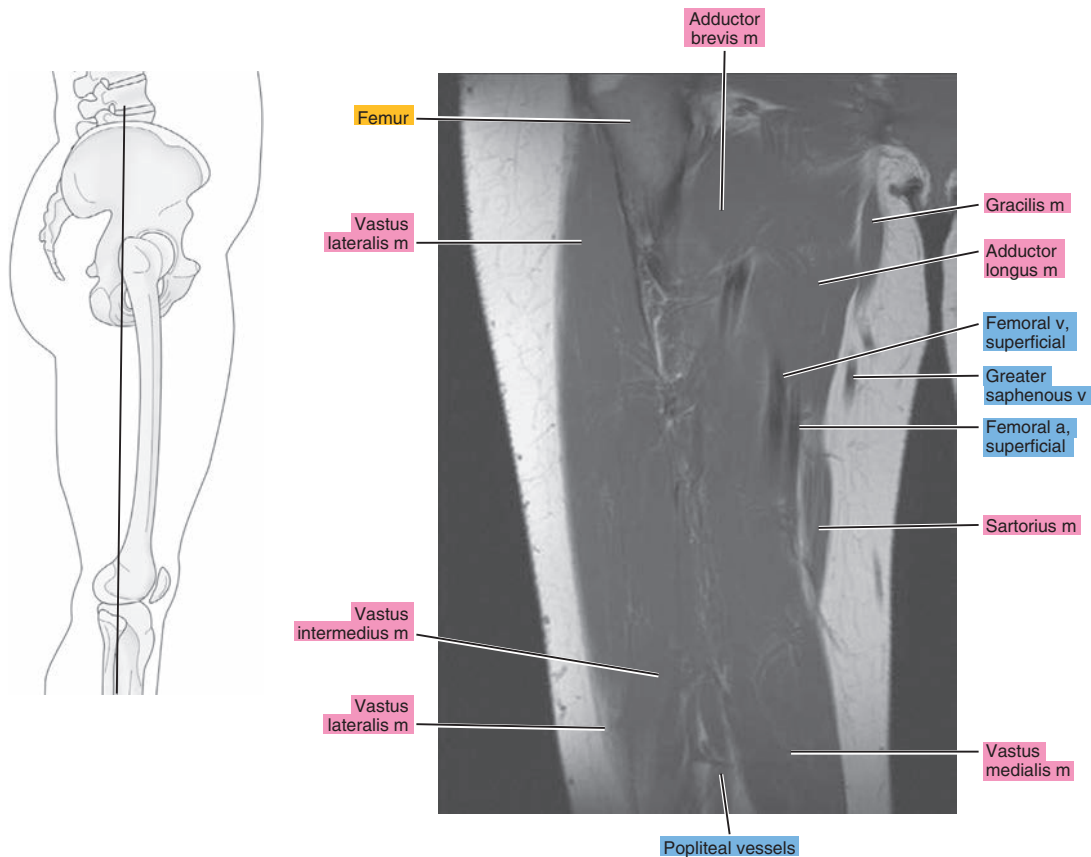


Figure 20.3.9

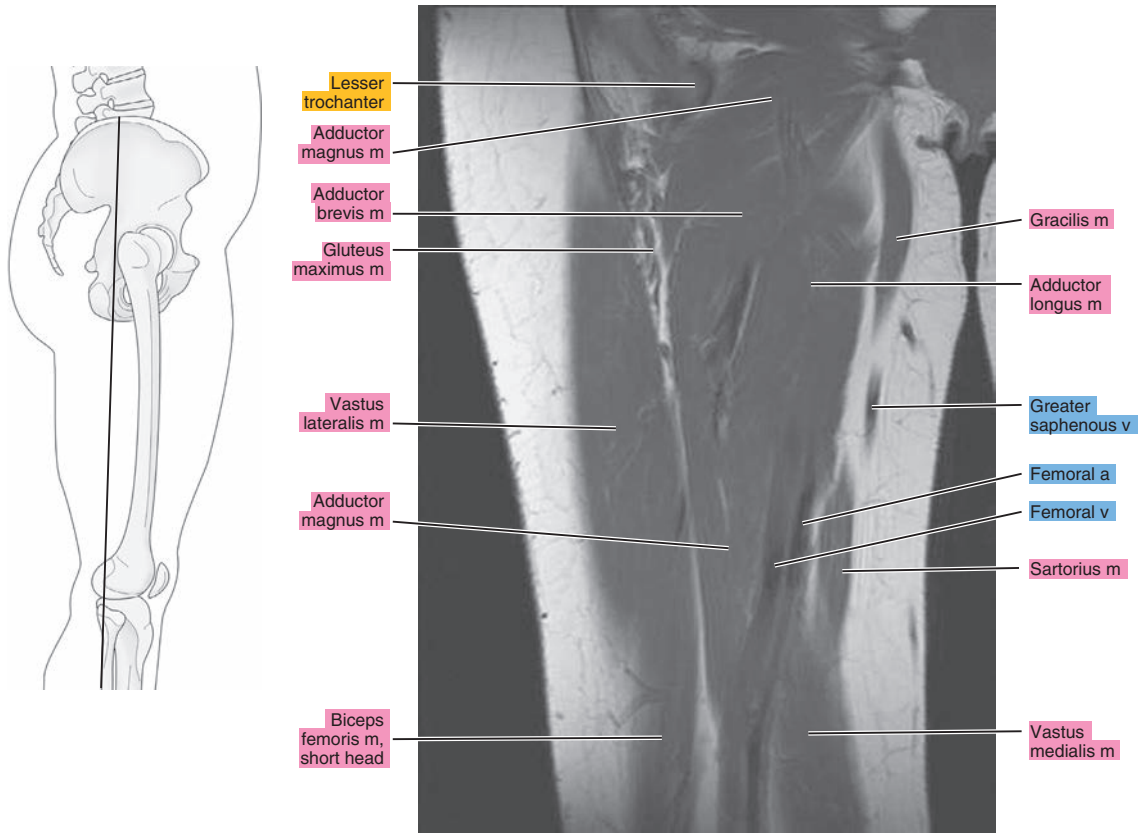


Figure 20.3.10

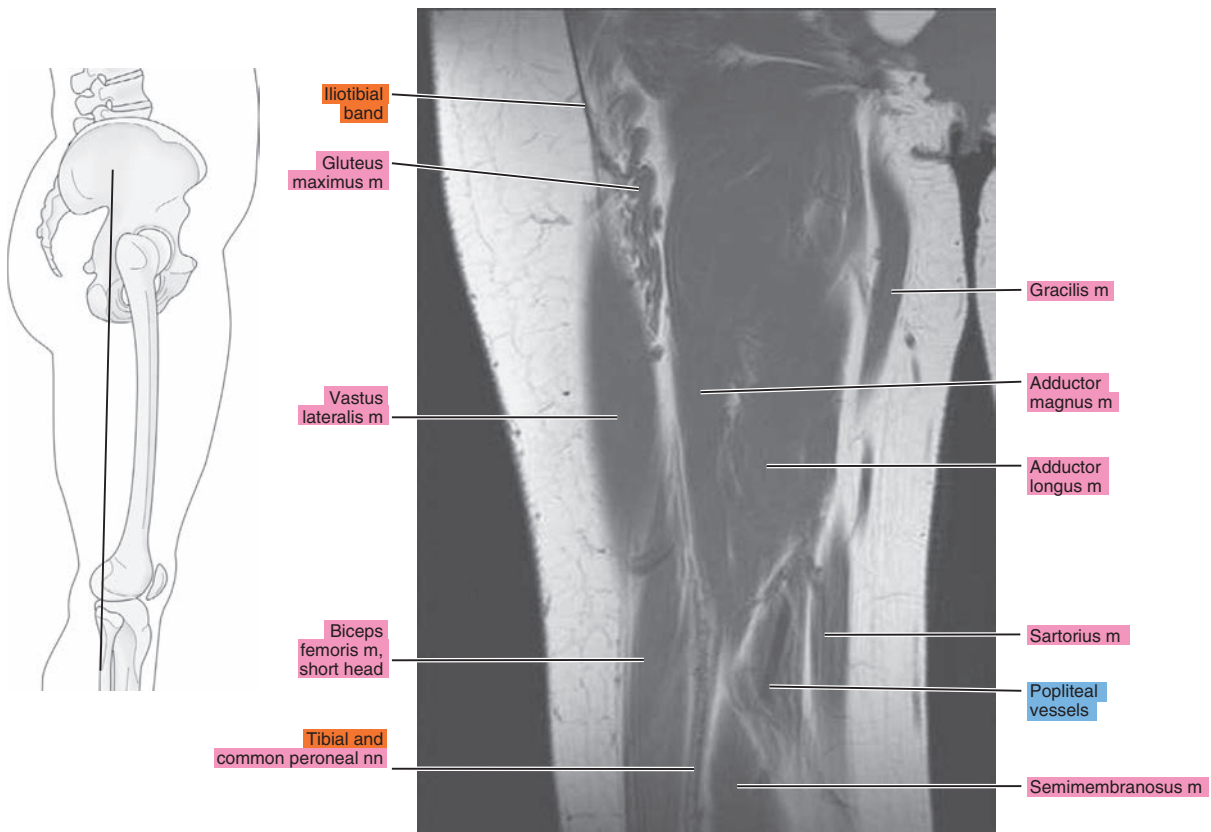




Figure 20.3.11

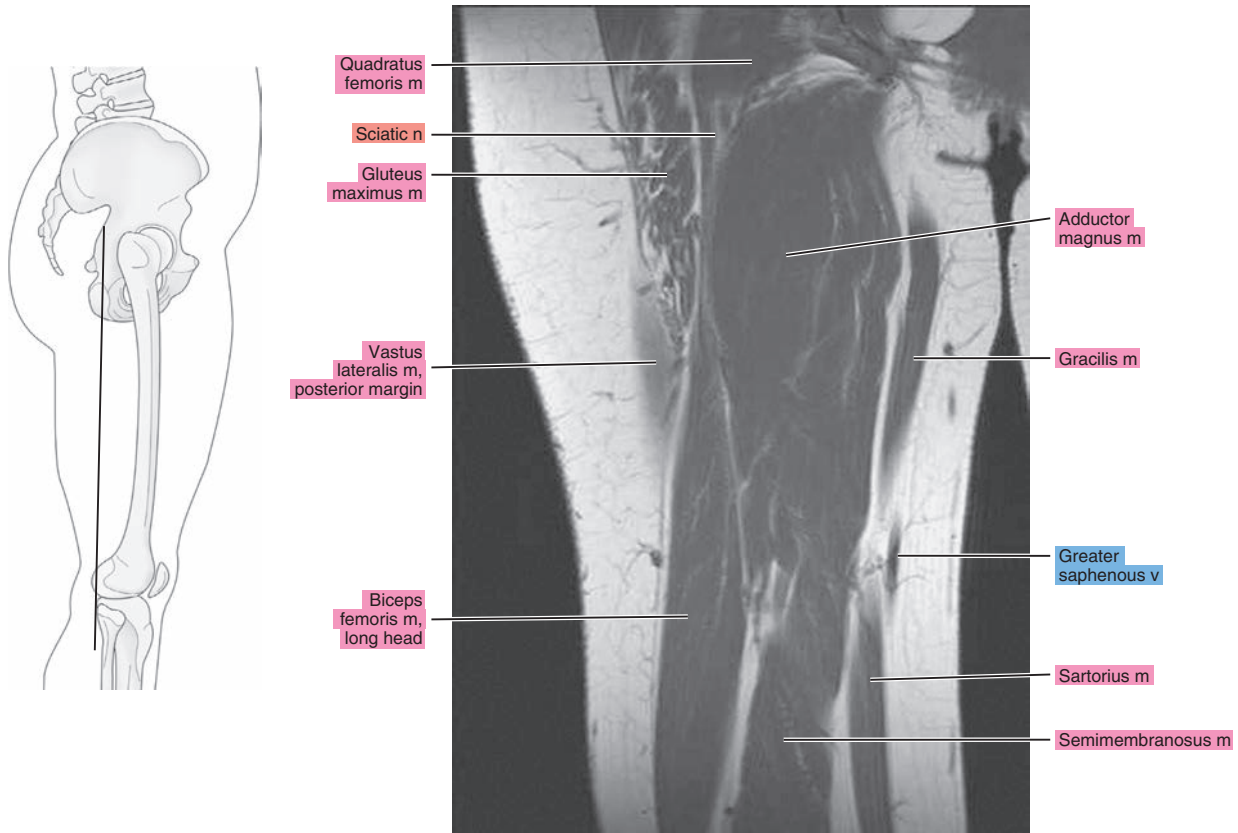


Figure 20.3.12

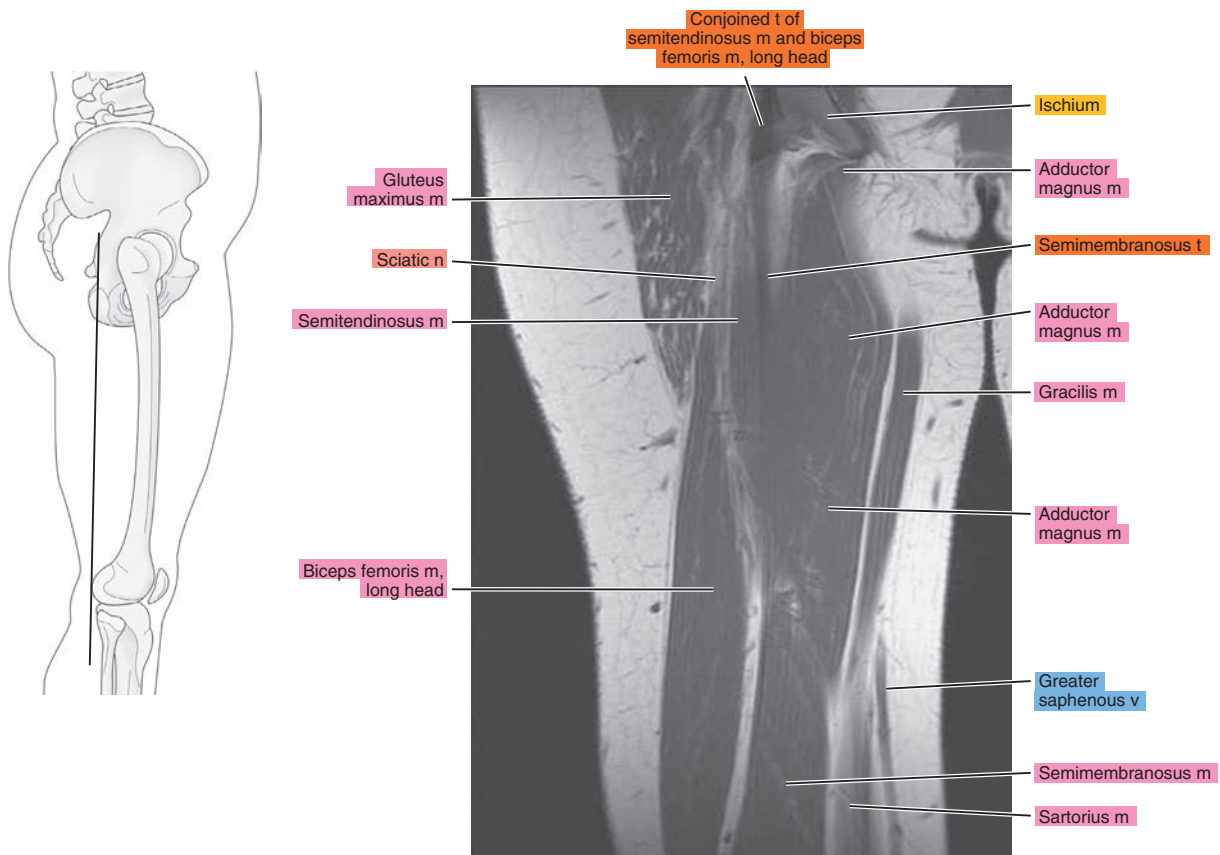


Figure 20.3.13

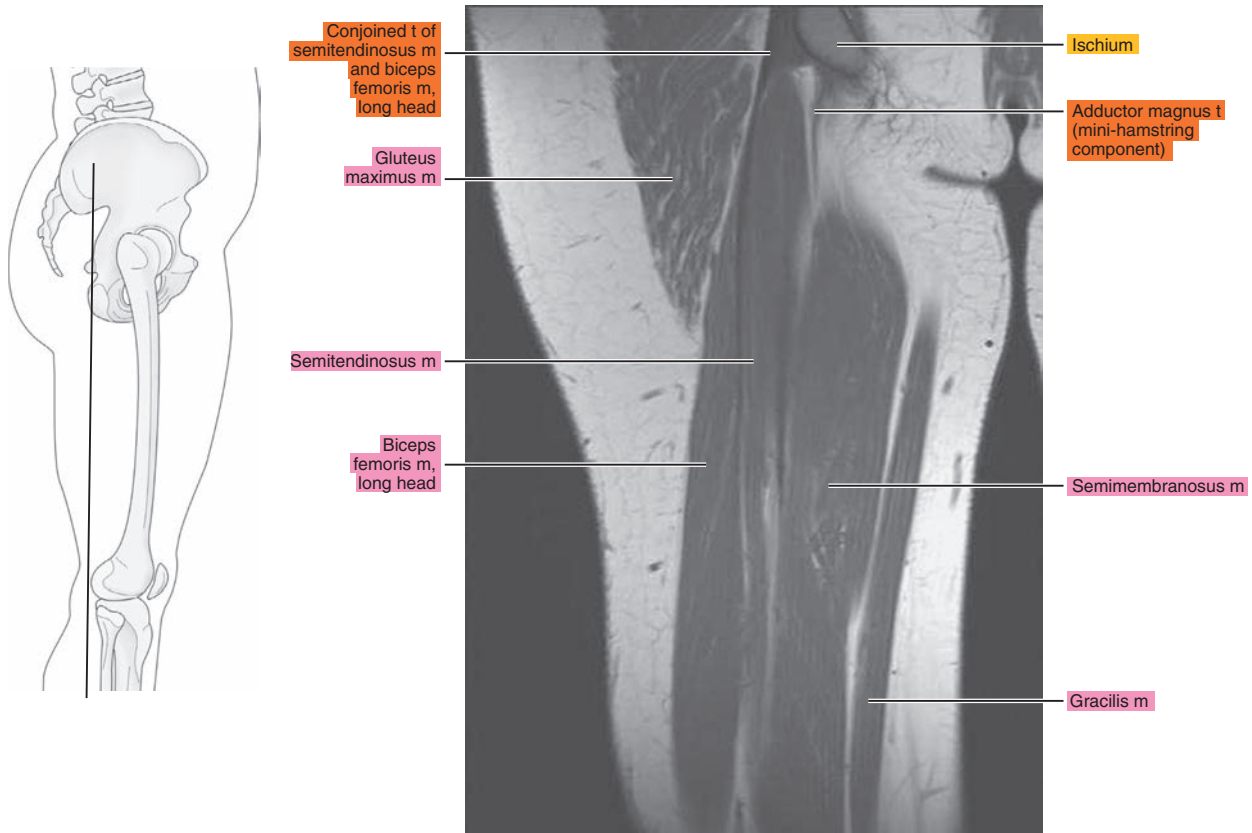


Figure 20.3.14

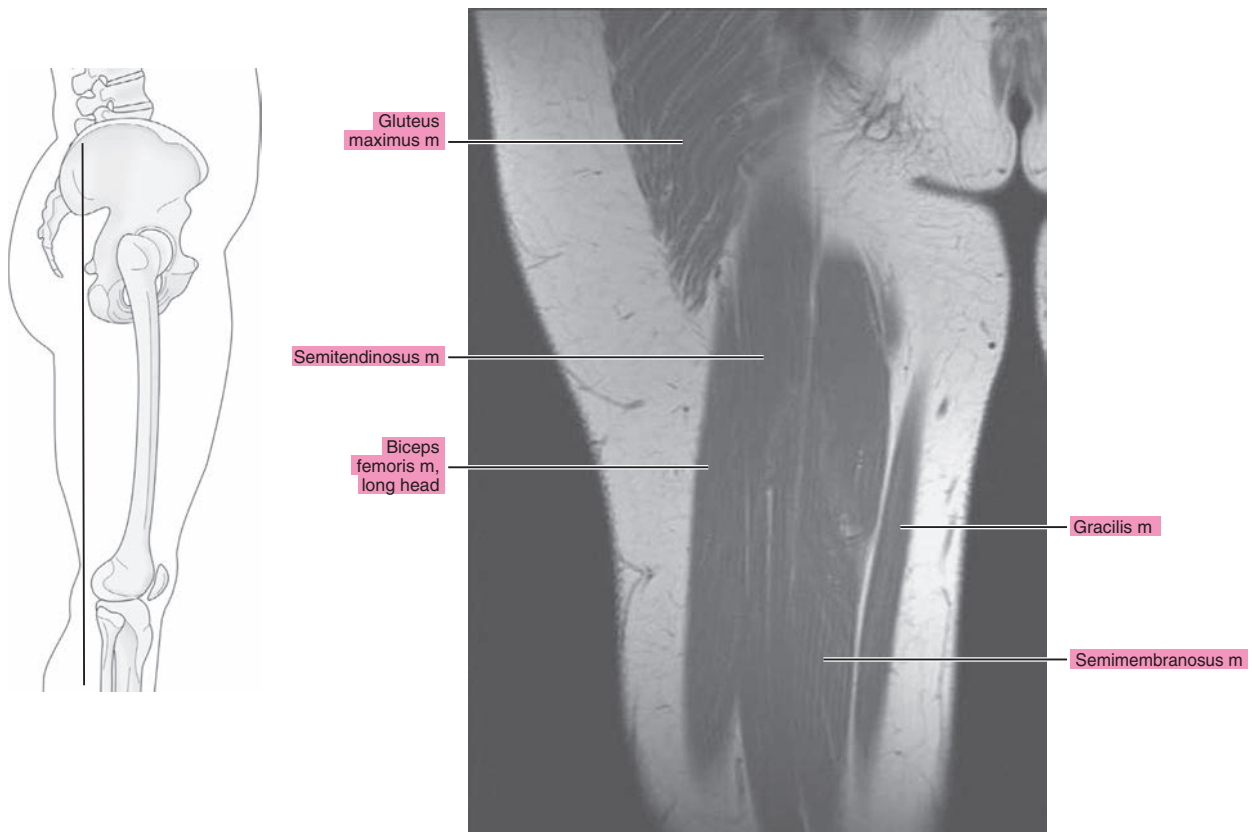
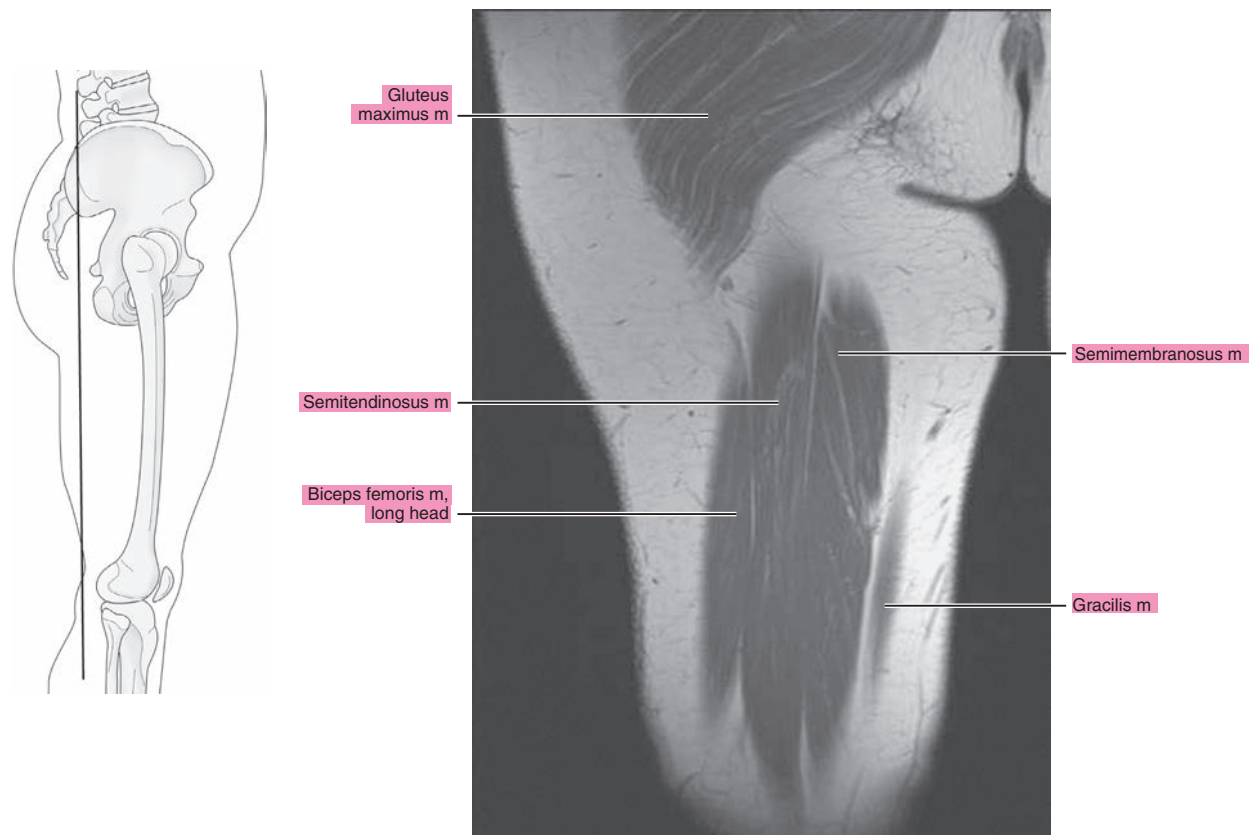


Figure 20.3.15



**Table 20-1. Muscles of the Thigh**

MUSCLE	ORIGIN	INSERTION	NERVE SUPPLY
<b>Sartorius</b>	Anterior superior iliac spine and the adjacent area below	Medial surface of the tibia; near the tuberosity and neighboring fascia	Femoral
<b>Rectus femoris</b>	Straight head: anterior inferior iliac spine; reflected head: posterosuperior surface of the rim of the acetabulum	Through the patellar ligament to the tibial tuberosity	Femoral
<b>Vastus lateralis</b>	Shaft of the femur along the anteroinferior margin of the greater trochanter, above the gluteal tuberosity, and the upper half of the linea aspera	Proximal border of the patella, front of the lateral condyle of the tibia, and fascia of the leg	Femoral
<b>Vastus medialis</b>	Medial lip of the linea aspera and the distal half of the intertrochanteric line, and the aponeurosis of the tendons of insertion of the adductor muscles	Upper two-thirds of the medial margin and proximal margin of the patella, medial condyle of the tibia, and investing deep fascia of the leg with the tendons of vastus intermedius, lateralis, and rectus, and through the patellar ligament onto the front of the tibial tuberosity	Femoral
<b>Vastus</b>	Distal half of the lateral margin of the linea aspera and its lateral bifurcation and from the anterolateral part of the shaft of the femur	Proximal margin and deep surface of the patella, aponeurosis of the vastus lateralis, medially and laterally to the tendons of the vastus medialis and lateralis, to the patellar ligament and onto the tibial tuberosity	Femoral
<b>Gracilis</b>	Medial margin of inferior ramus of the pubis and the pubic end of the inferior ramus of the ischium	By an expanded tendinous process onto the tibia below the medial condyle	Anterior division of the obturator
<b>Pectineus</b>	Pectineal line, pectineal fascia, and anterior margin of the obturator sulcus, and from the pubofemoral ligament	Upper half of the pectineal line behind the lesser trochanter	Femoral, also from the accessory obturator and/or obturator
<b>Adductor longus</b>	Pubic tubercle to symphysis pubis	Middle third of the linea aspera	Anterior division of the obturator; also, occasionally, branch from the femoral
<b>Adductor brevis</b>	Medial part of the outer surface of the inferior ramus of the pubis	Distal two-thirds of the pectineal line and the upper one-third of the linea aspera	Anterior (or posterior) branch of the obturator
<b>Adductor magnus</b>	Inferior ramus of the pubis	Medial side of the gluteal ridge and the superior part of the linea aspera by a tendon from the distal three-fourths of the linea aspera and the adductor tubercle at the distal end of the medial supracondylar ridge	Posterior branch of the obturator and a branch from the sciatic
<b>Biceps femoris</b>	From the lateral lip of the linea aspera of the femur, from the middle of the shaft to the bifurcation of the linea aspera proximal two-thirds of the supracondylar ridge, and lateral intermuscular septum	Head of the fibula in front of the apex, partially onto the lateral condyle of the tibia, and into the fascia of the leg	Peroneal part of the sciatic



*Chapter*  
**21**

**MRI of the Knee**

# AXIAL

Figure 21.1.1

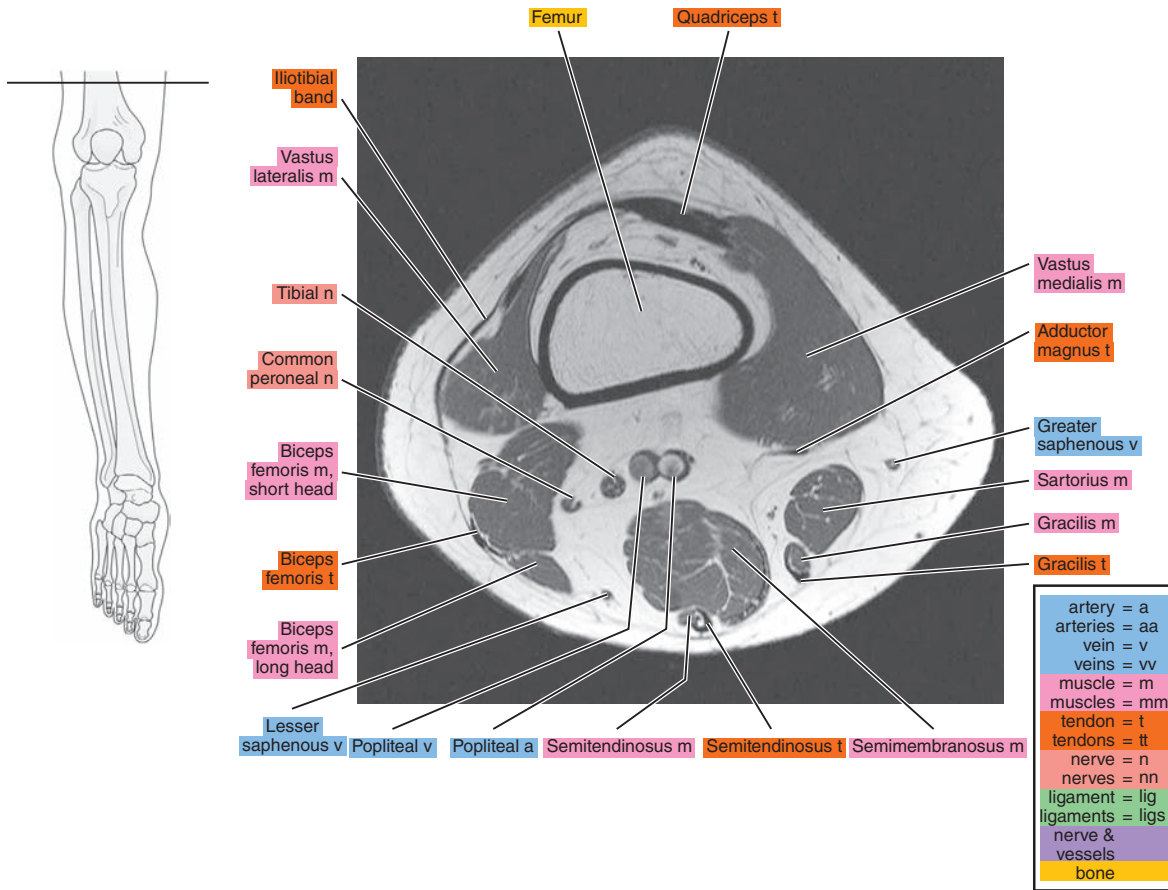


Figure 21.1.2

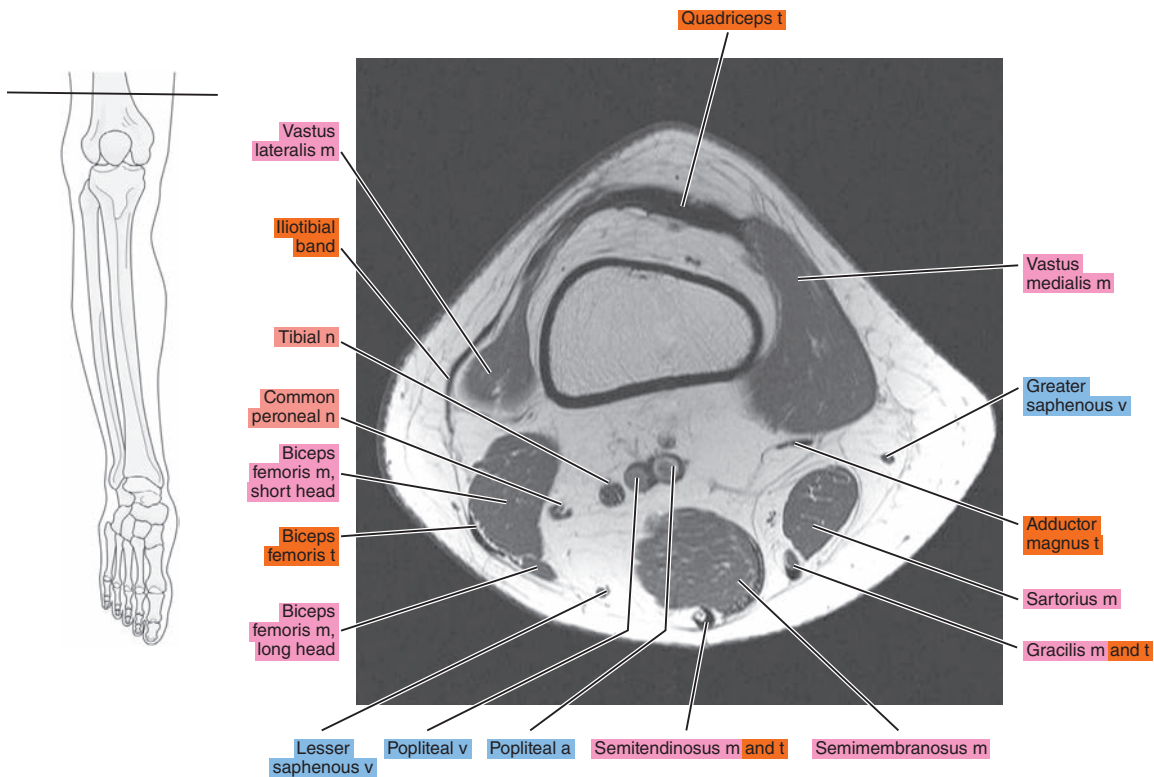


Figure 21.1.3

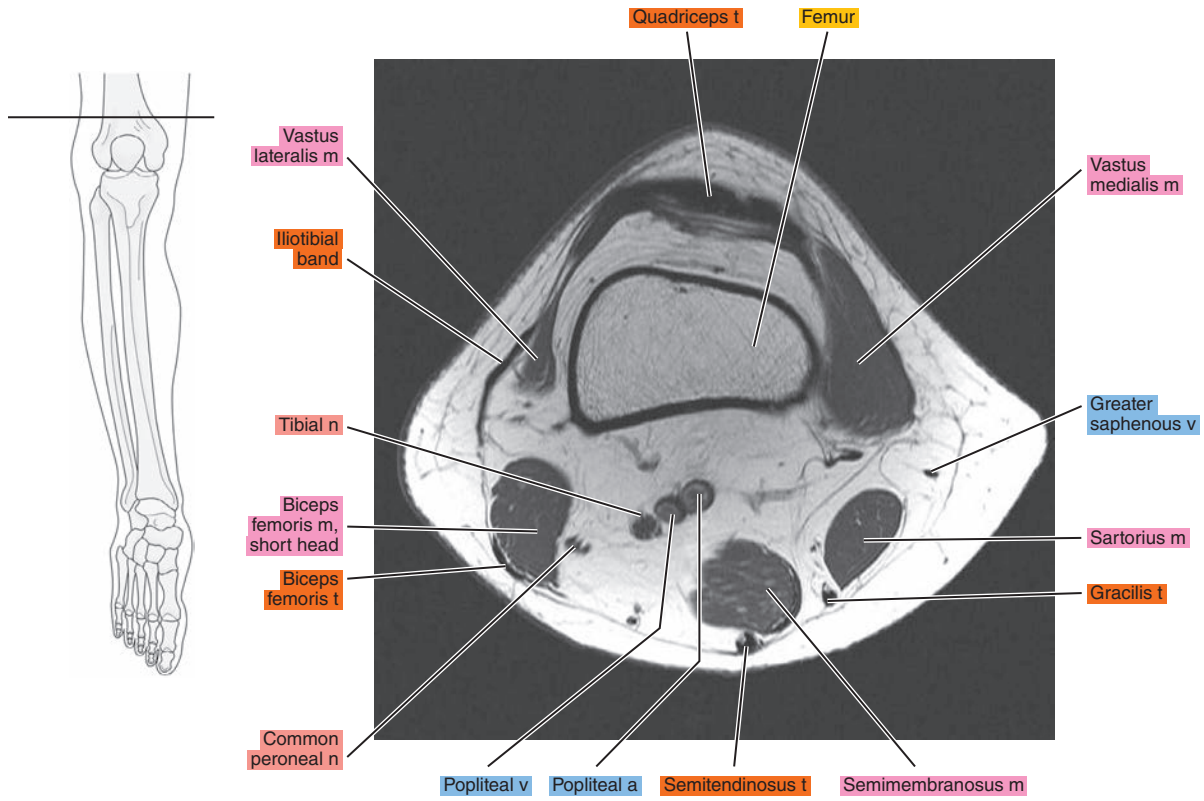


Figure 21.1.4

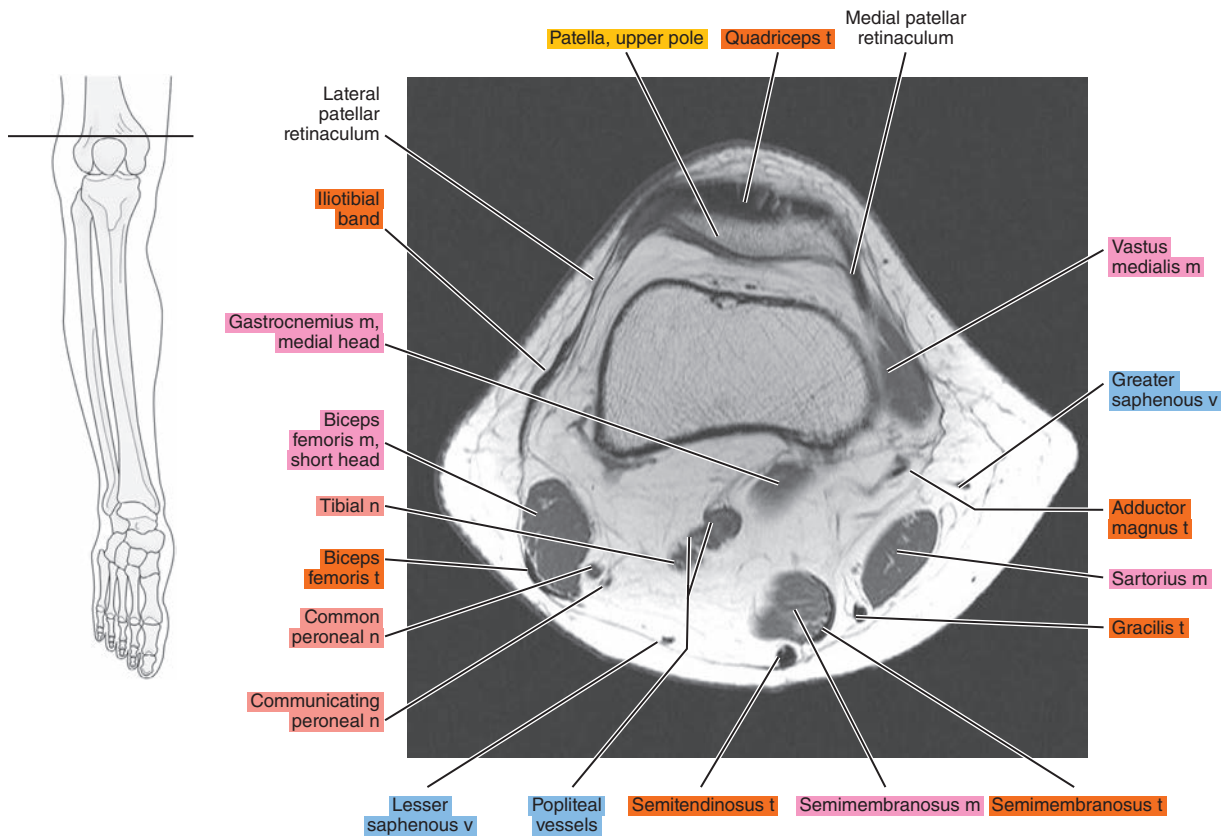


Figure 21.1.5

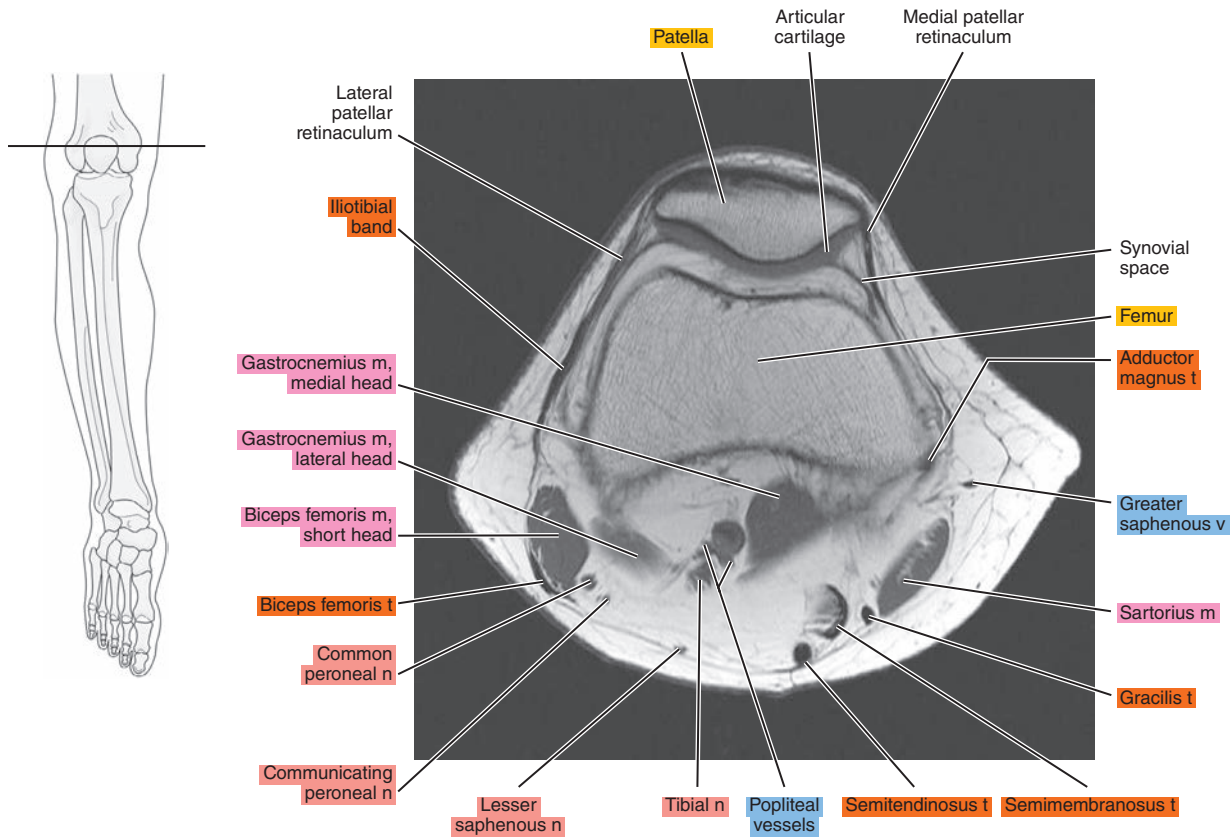


Figure 21.1.6

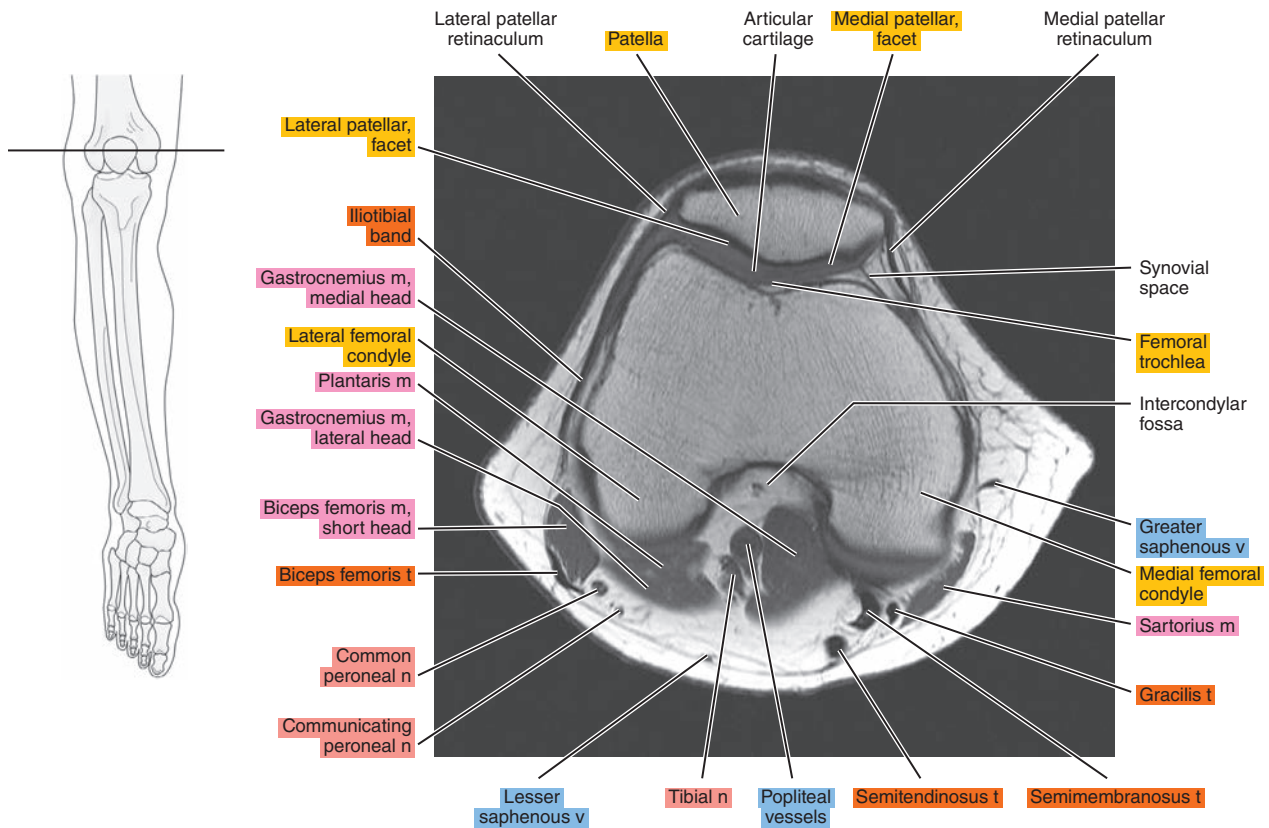




Figure 21.1.7

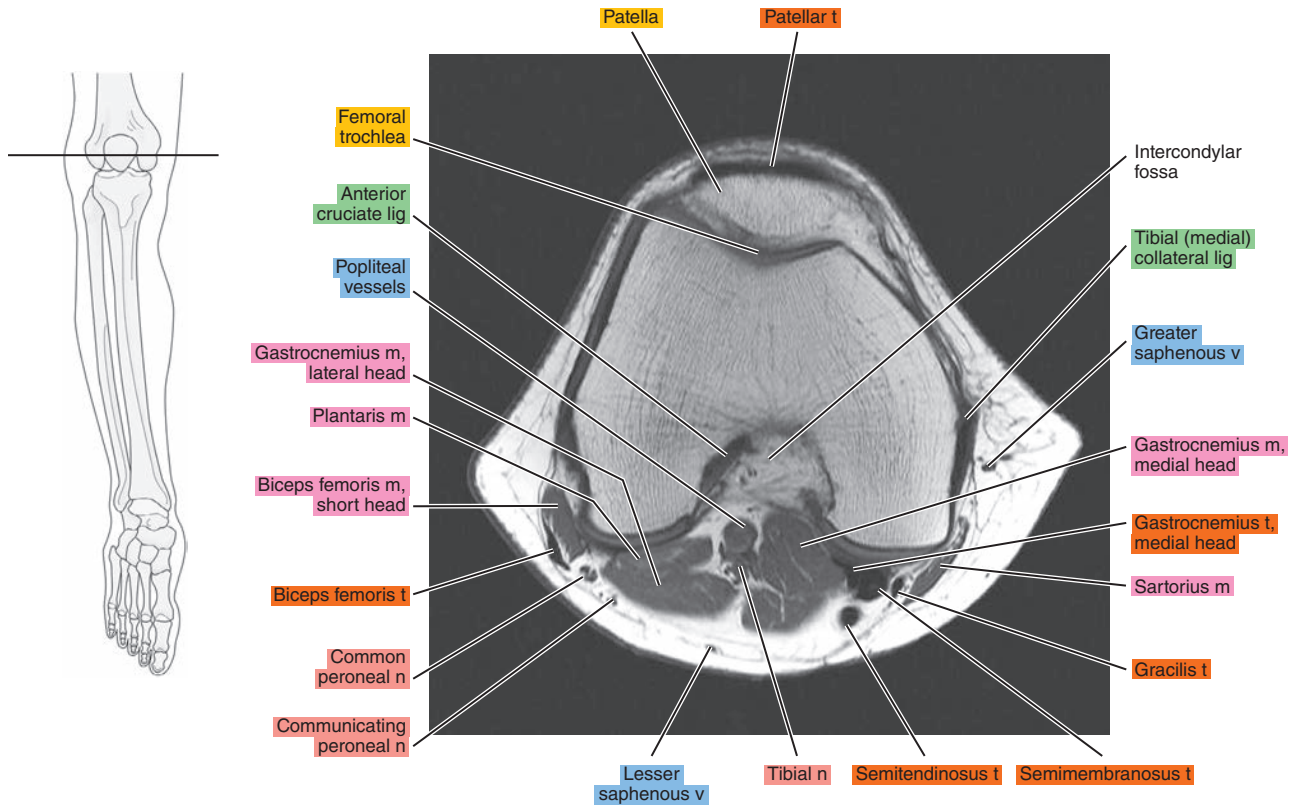


Figure 21.1.8

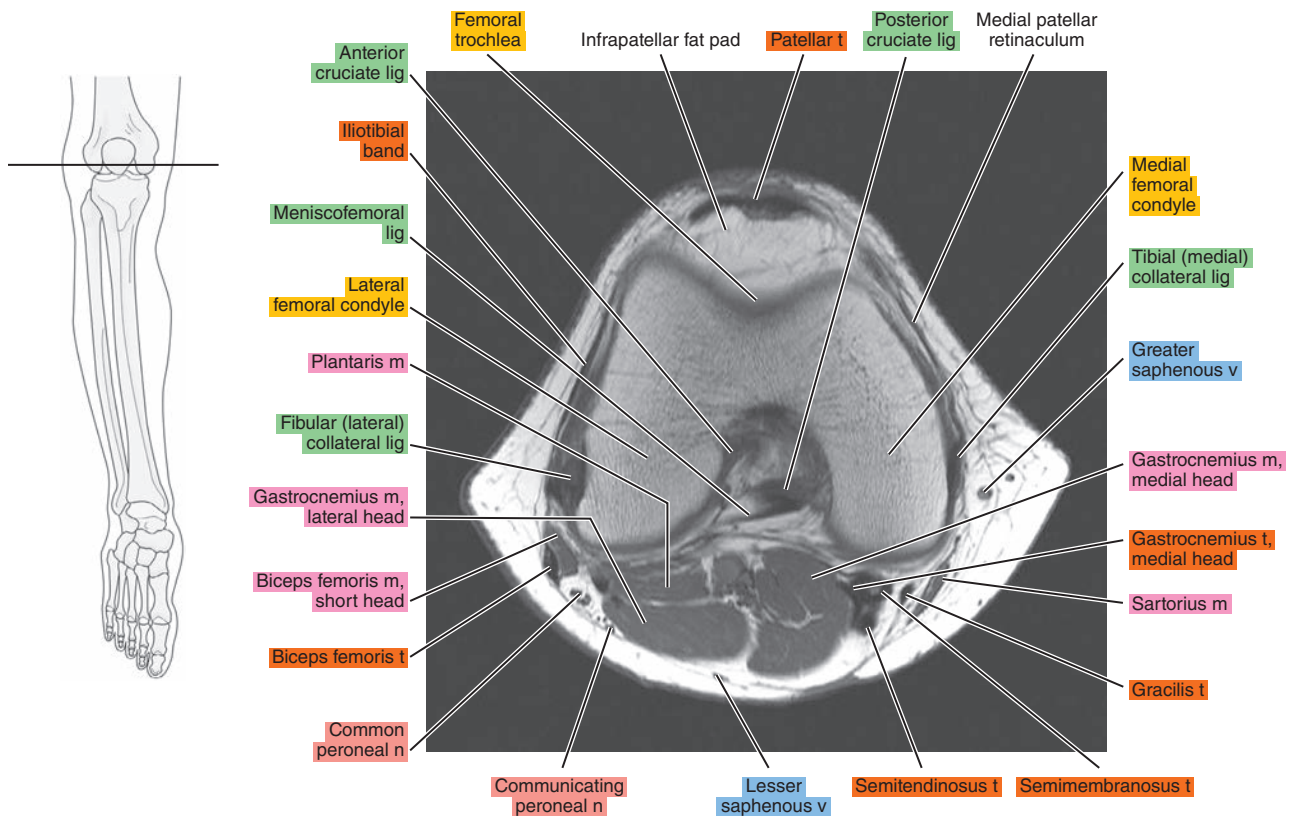


Figure 21.1.9

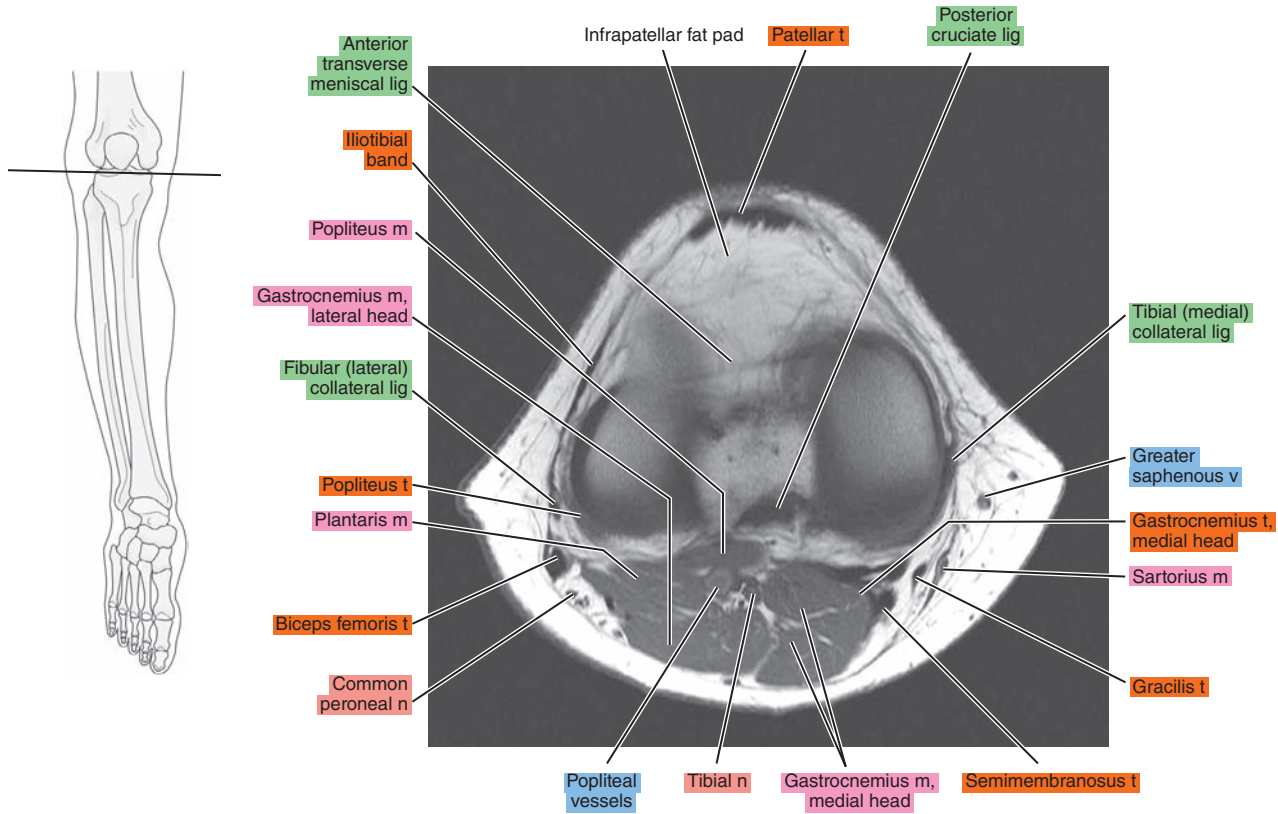


Figure 21.1.10

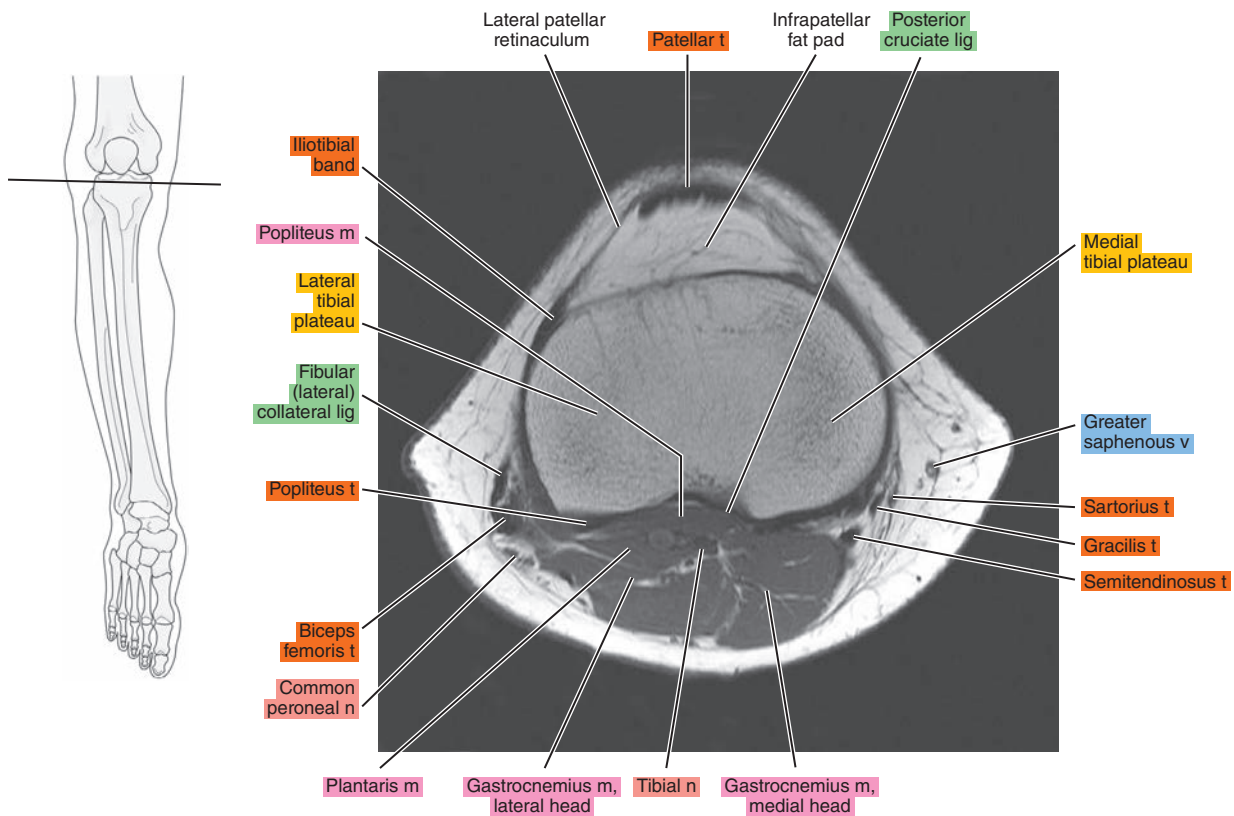


Figure 21.1.11

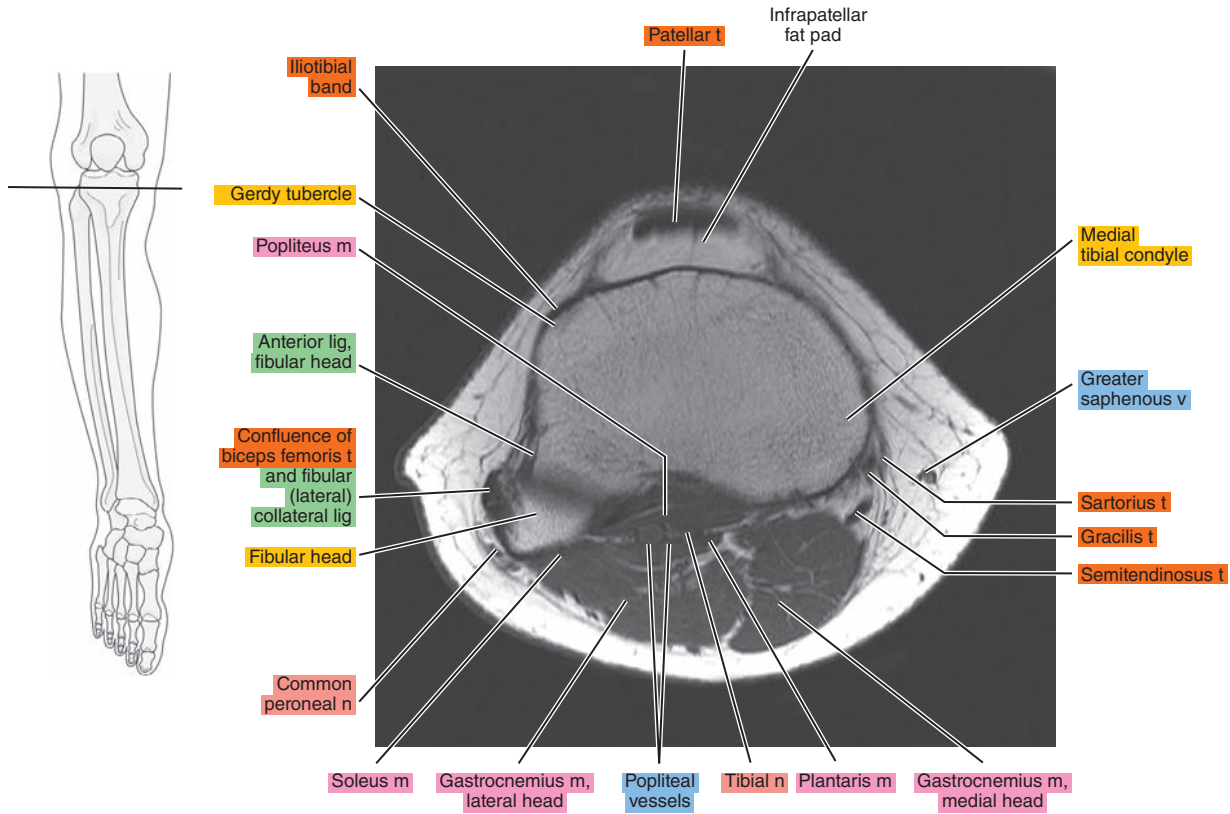


Figure 21.1.12

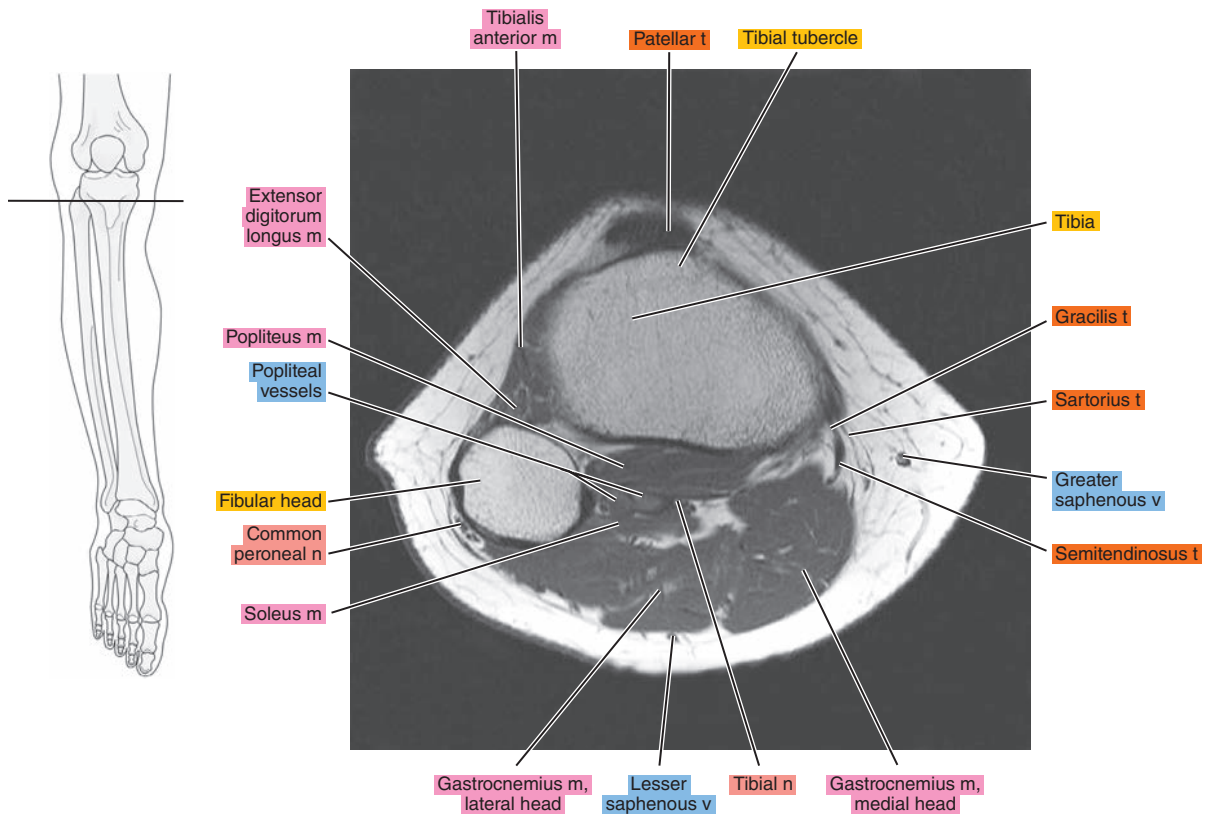




Figure 21.1.13

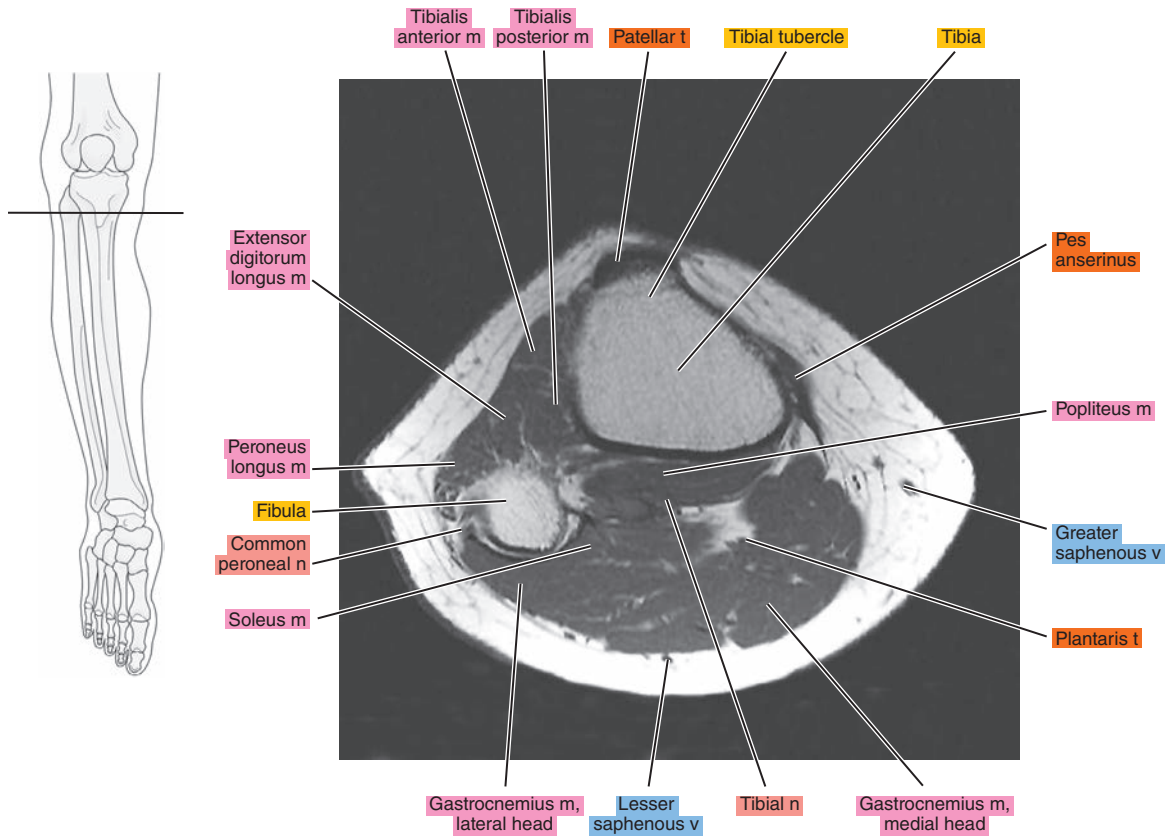
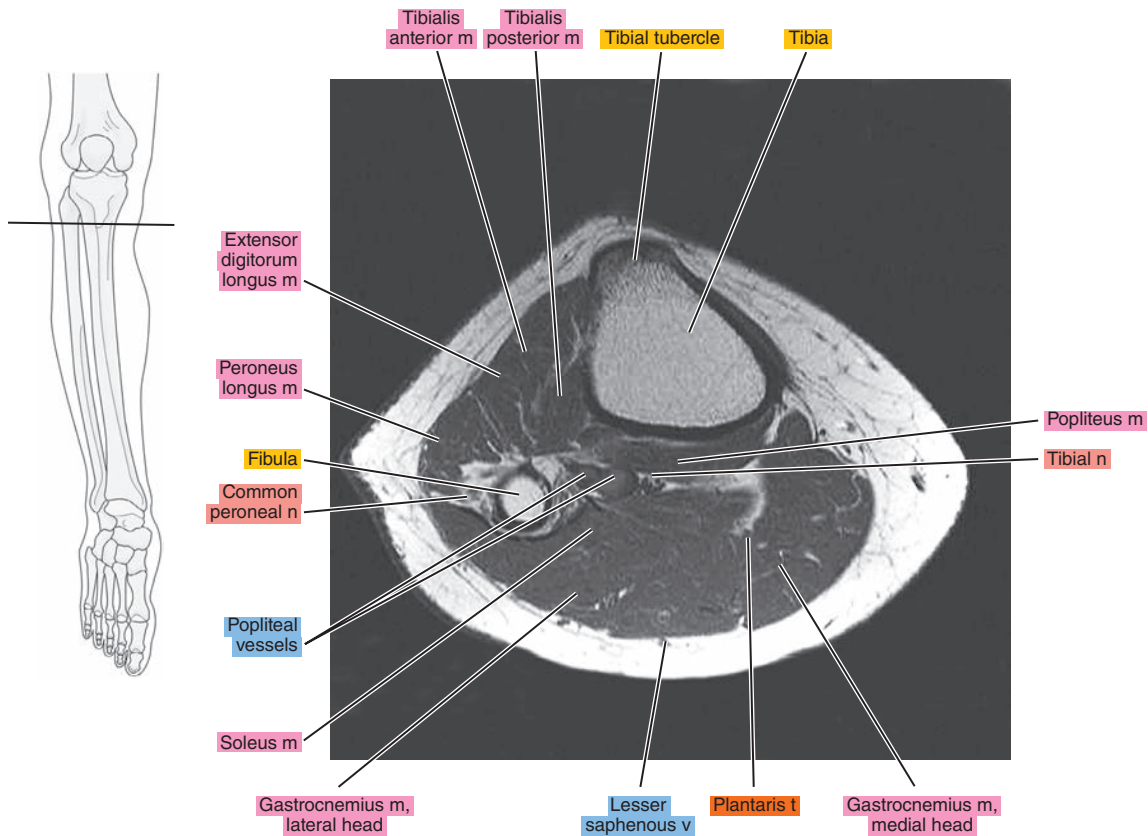


Figure 21.1.14





# SAGITTAL

Figure 21.2.1

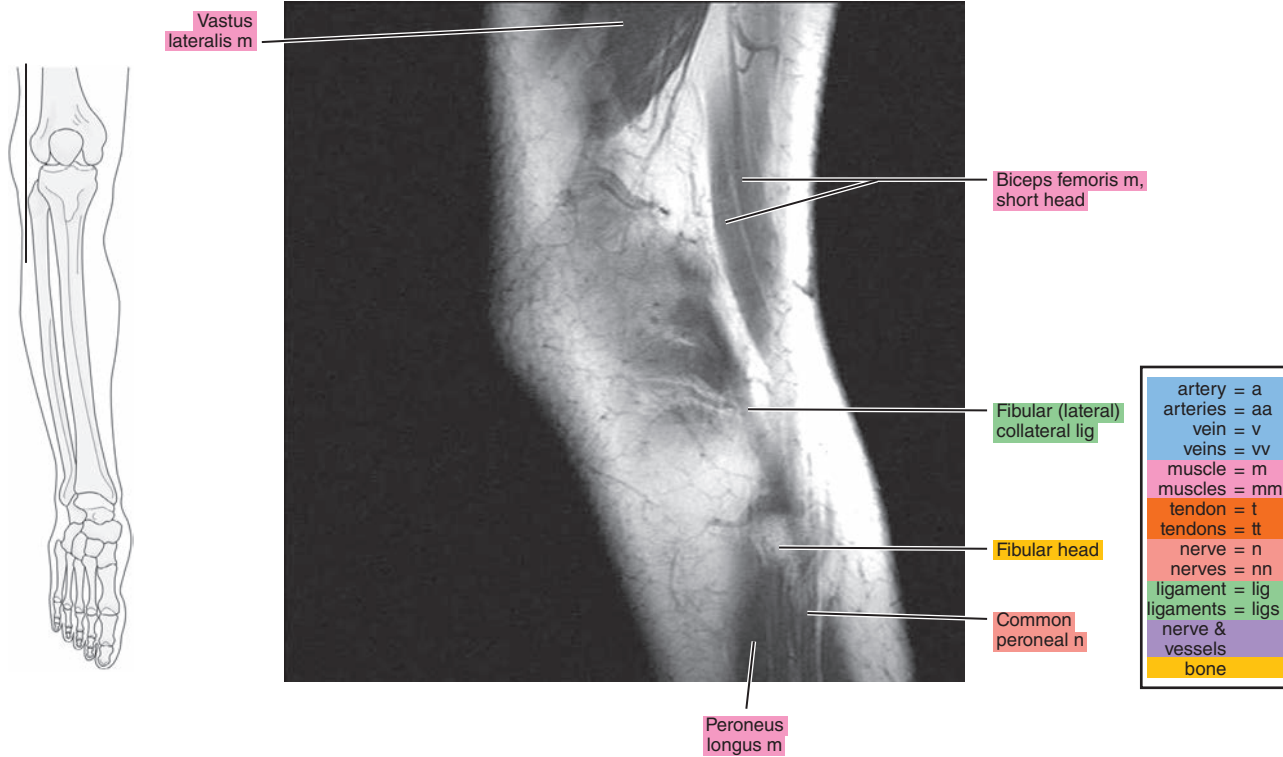


Figure 21.2.2

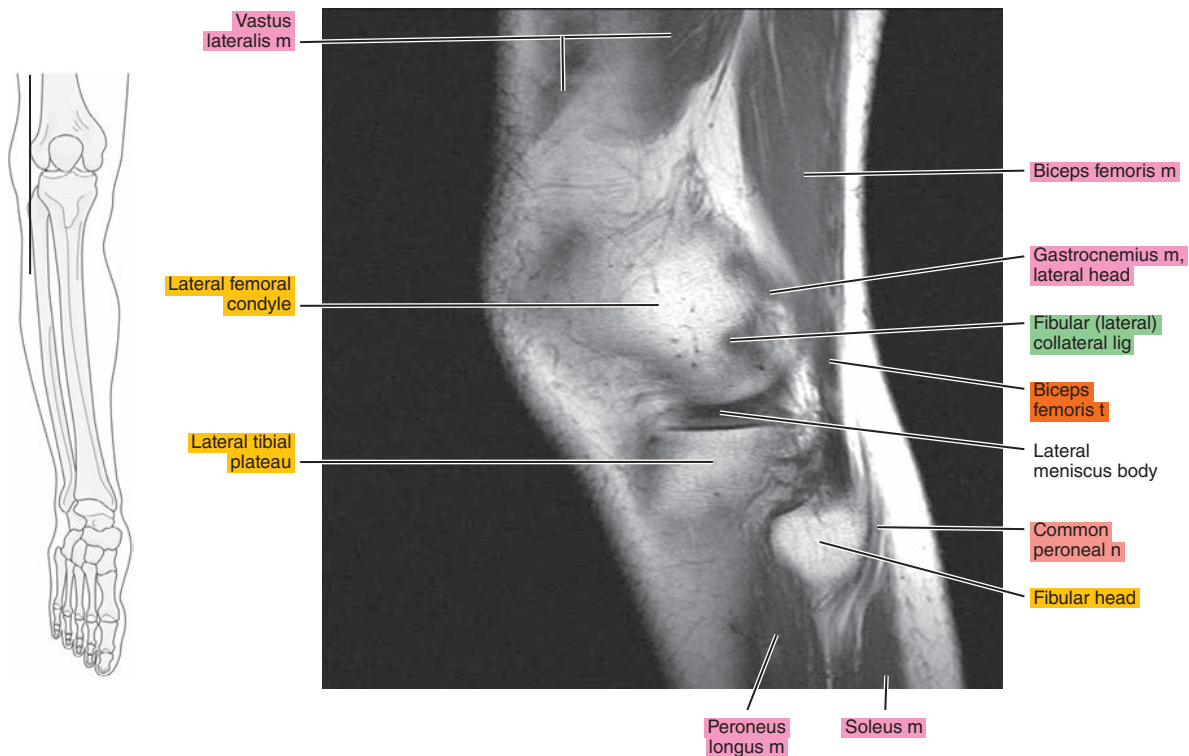


Figure 21.2.3

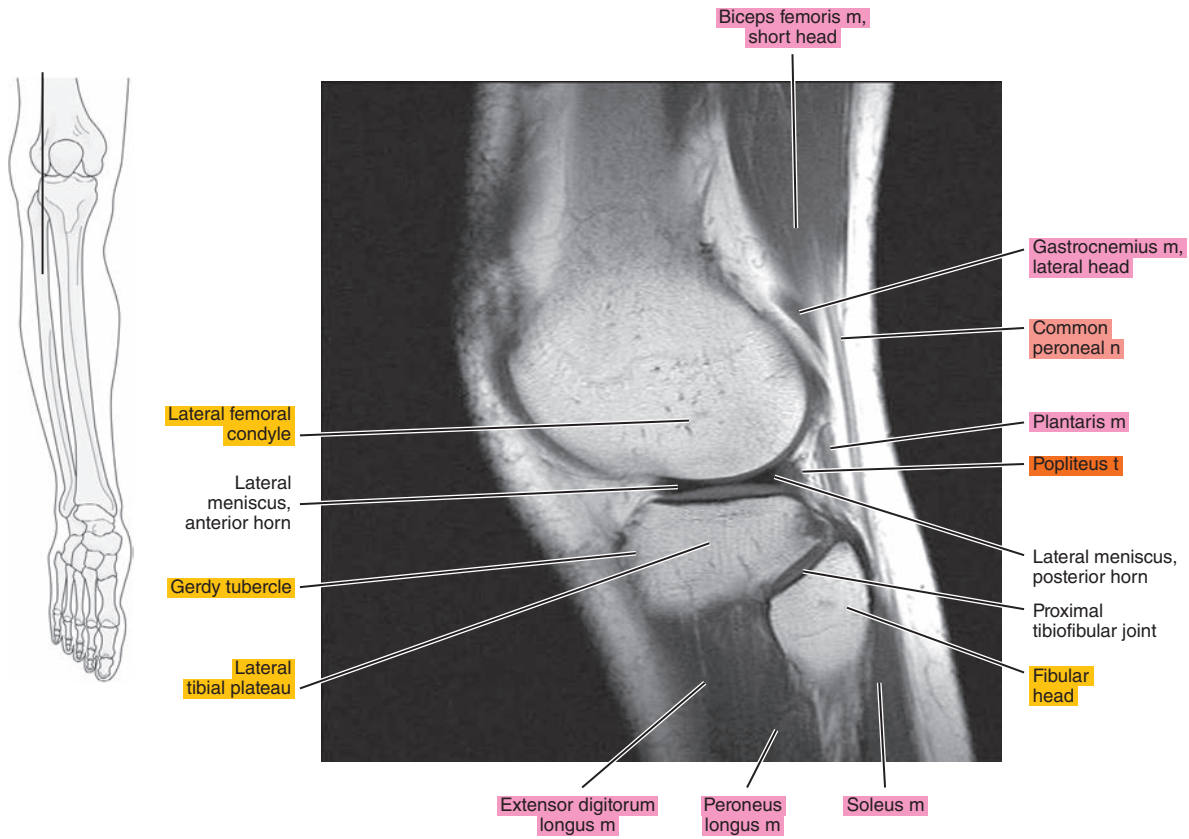


Figure 21.2.4

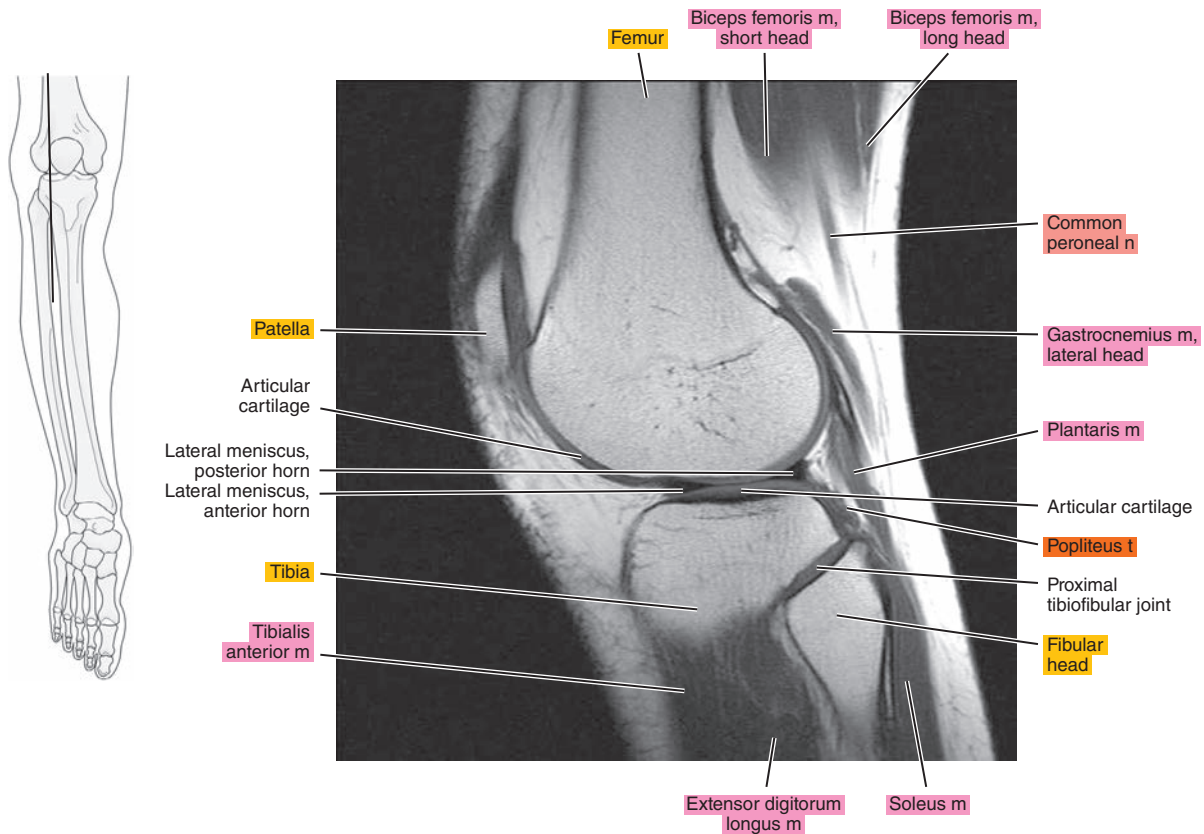


Figure 21.2.5

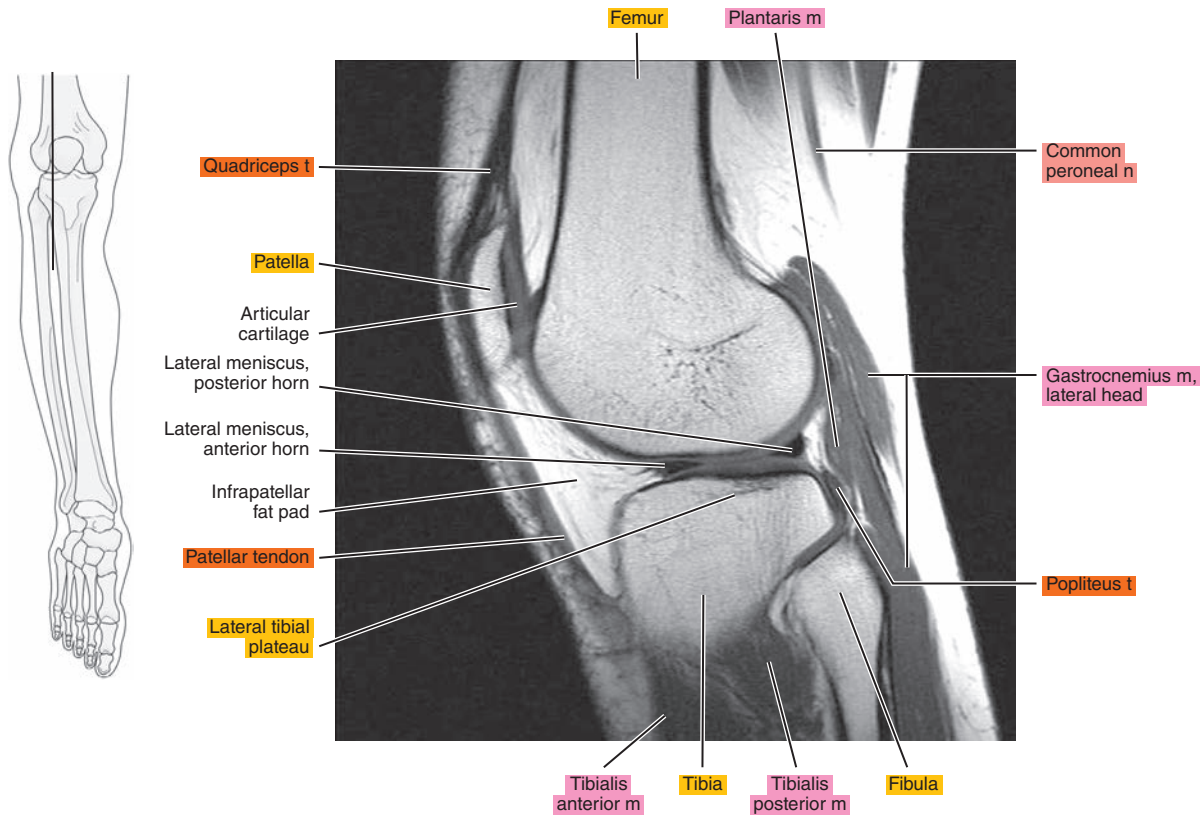


Figure 21.2.6

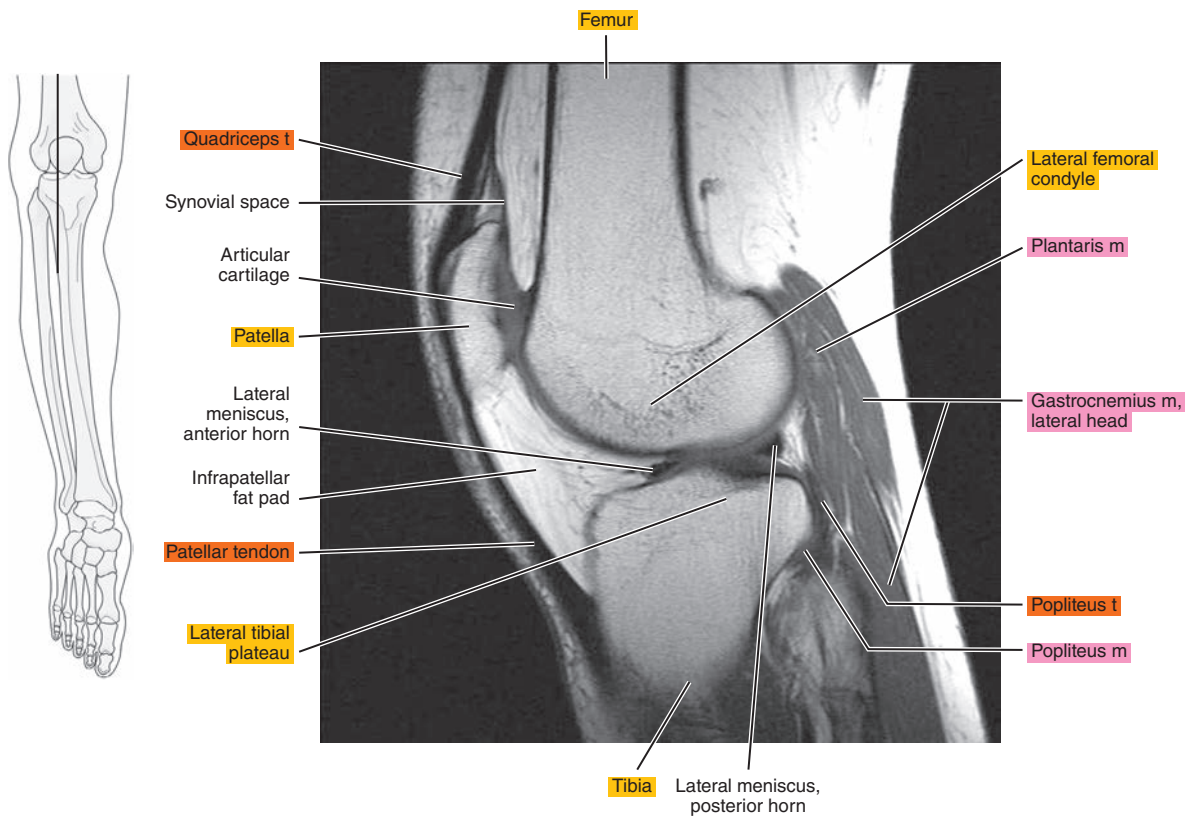




Figure 21.2.7

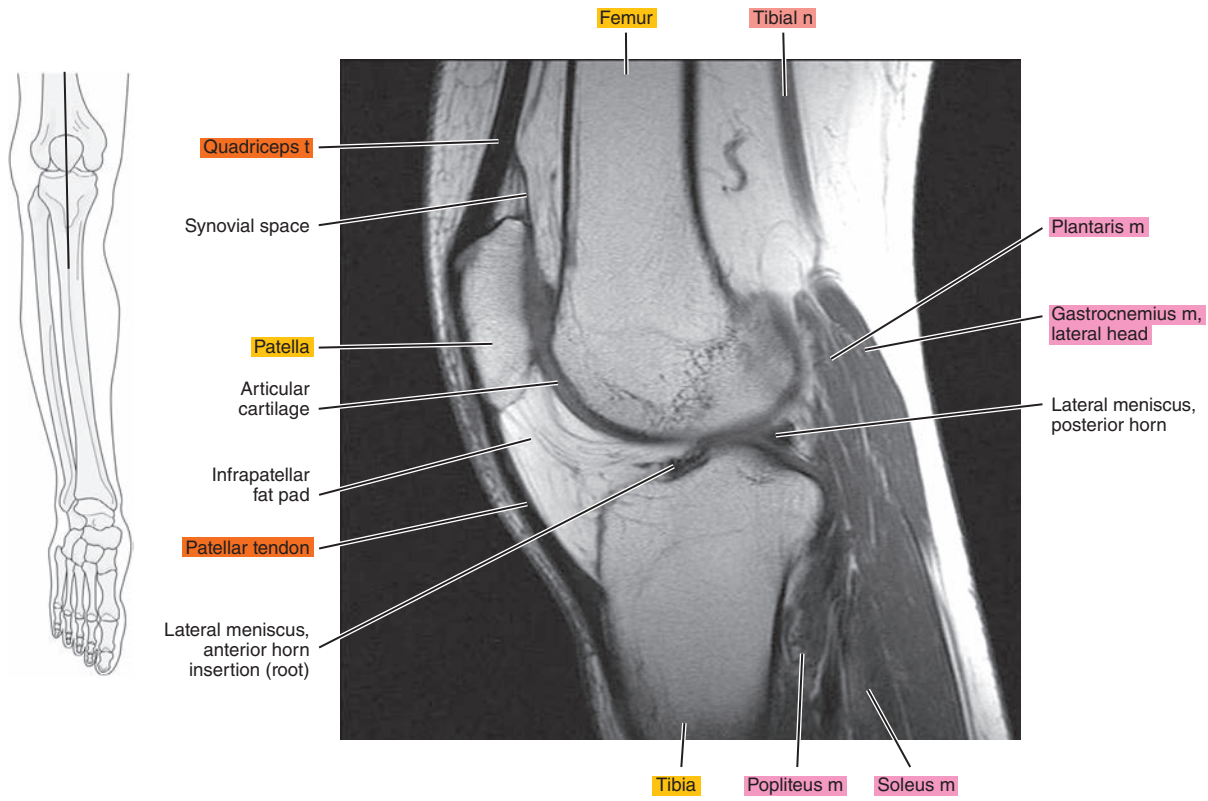


Figure 21.2.8

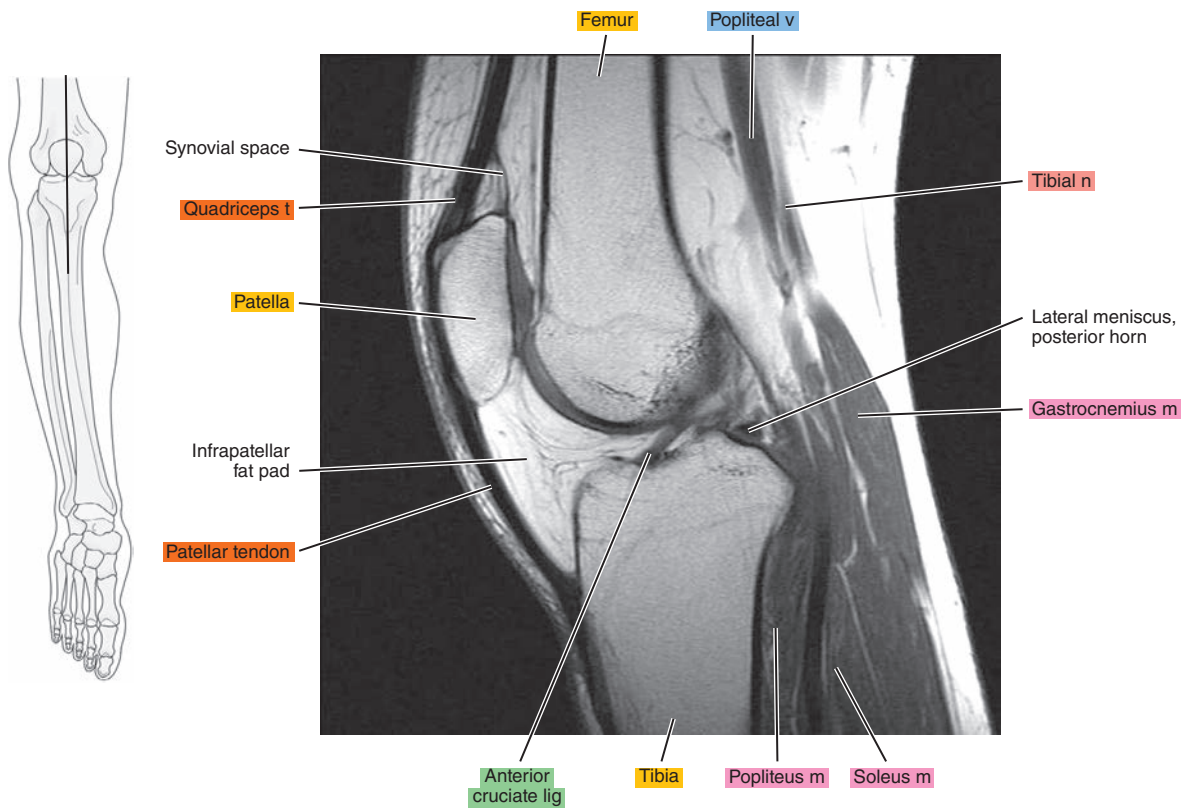




Figure 21.2.9

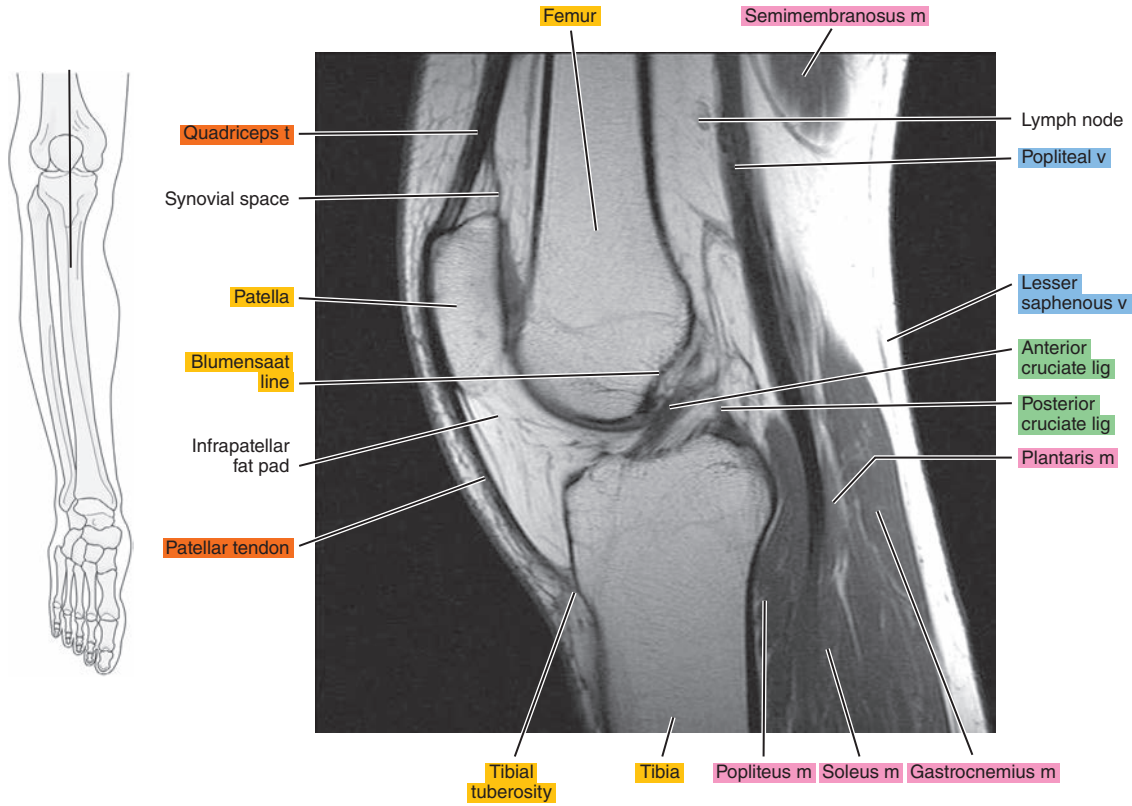


Figure 21.2.10

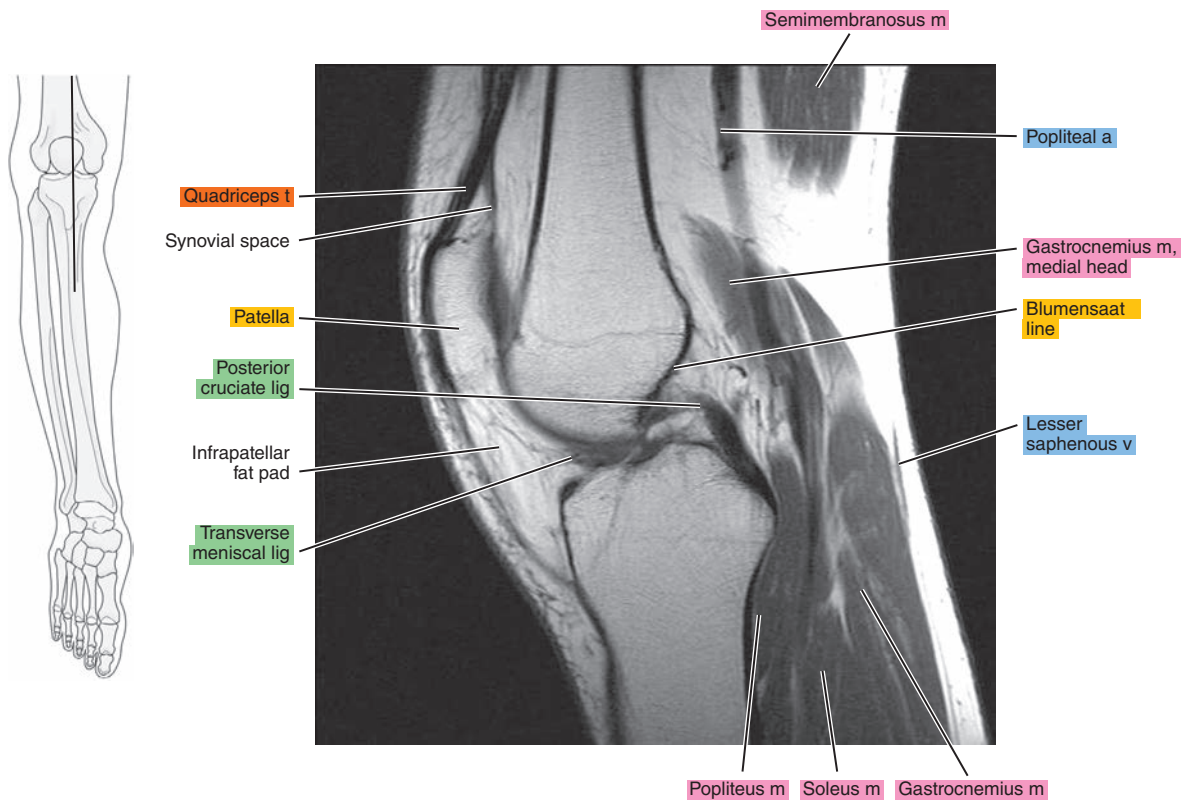


Figure 21.2.11

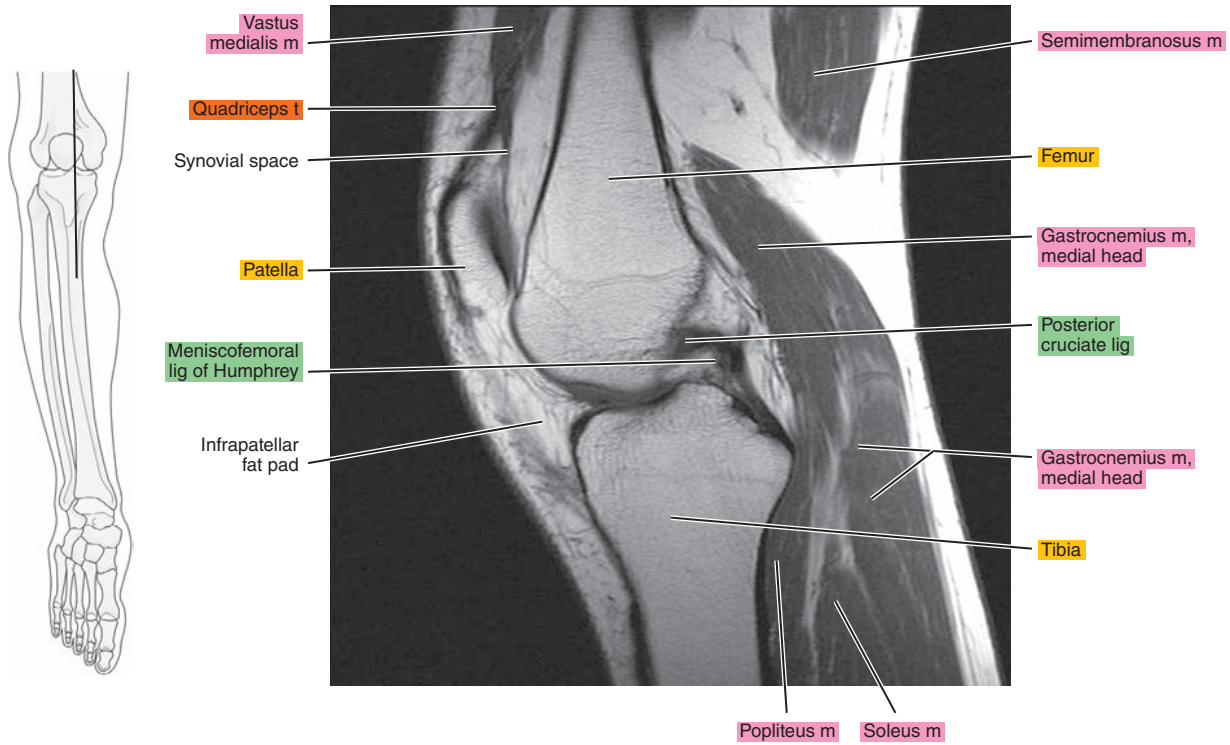


Figure 21.2.12

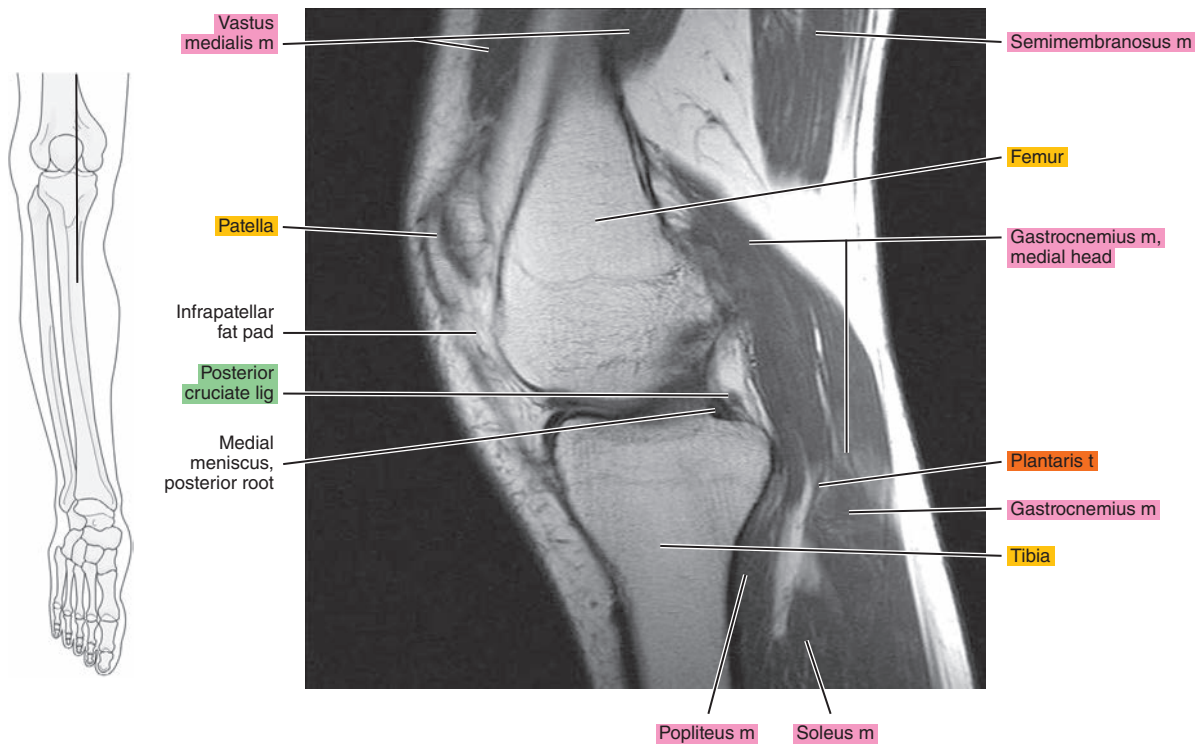


Figure 21.2.13

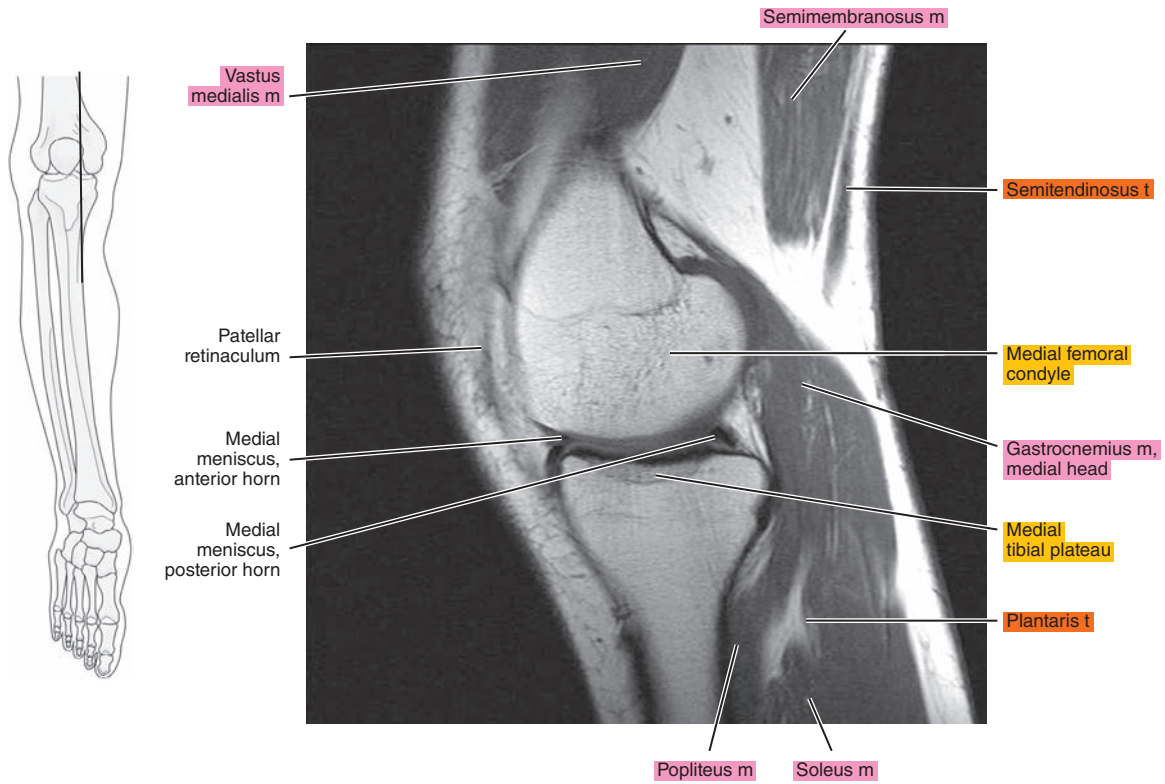


Figure 21.2.14

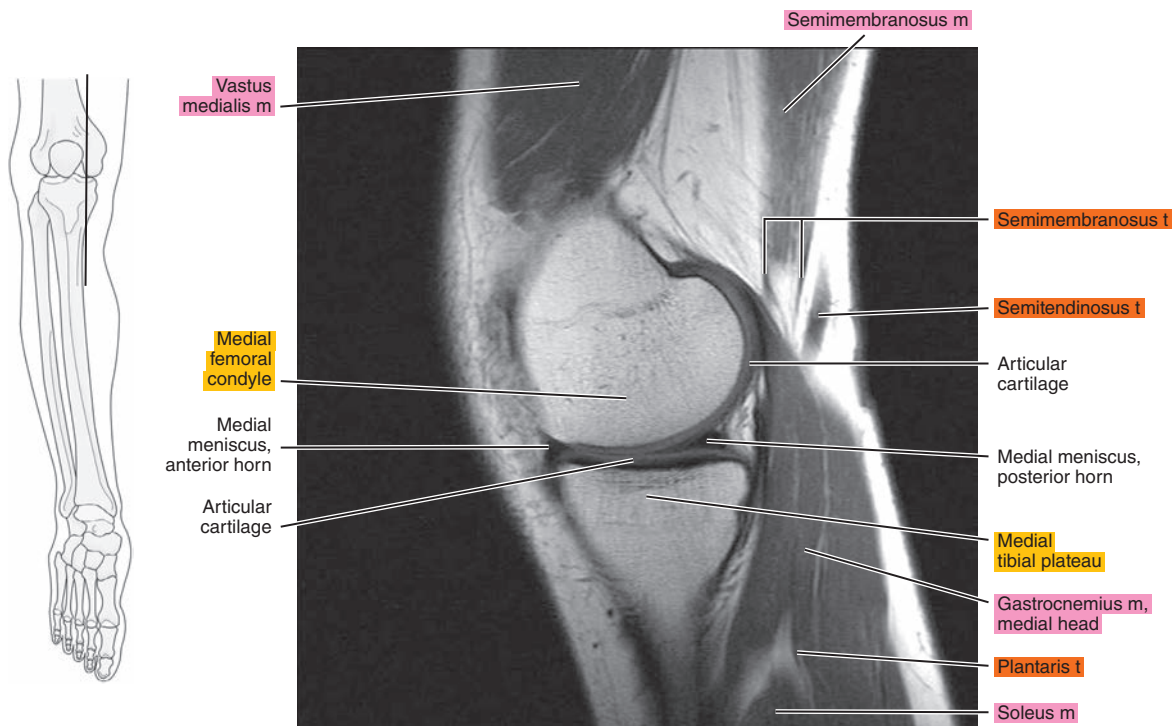




Figure 21.2.15

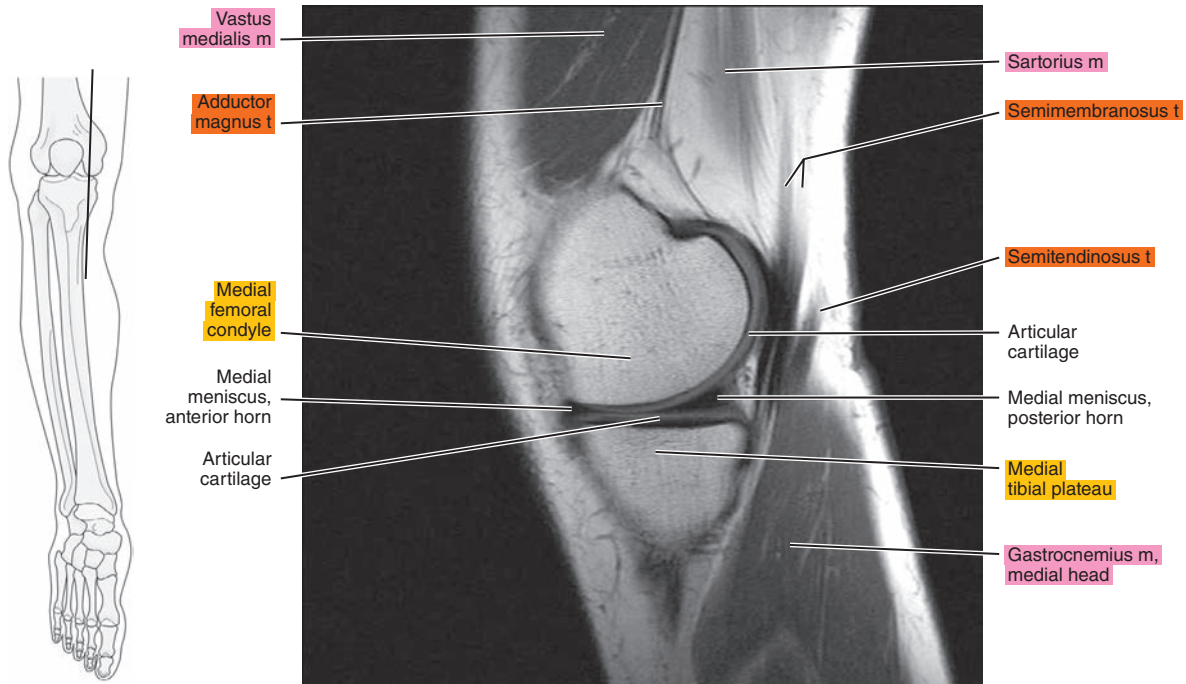


Figure 21.2.16

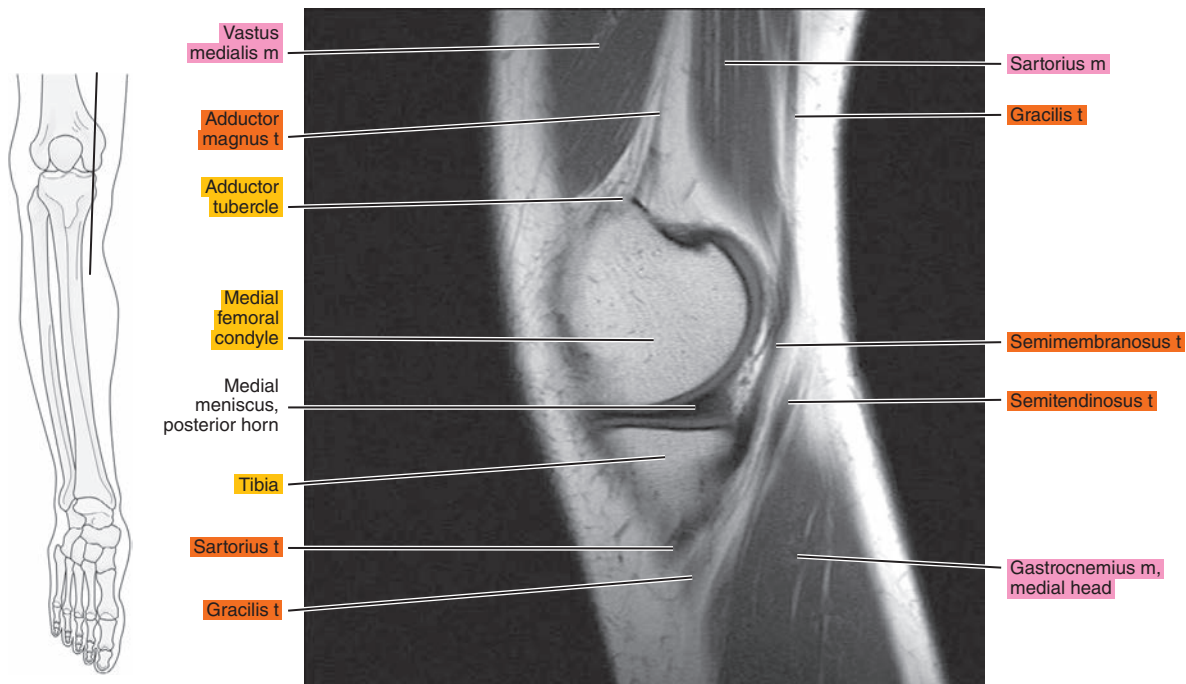
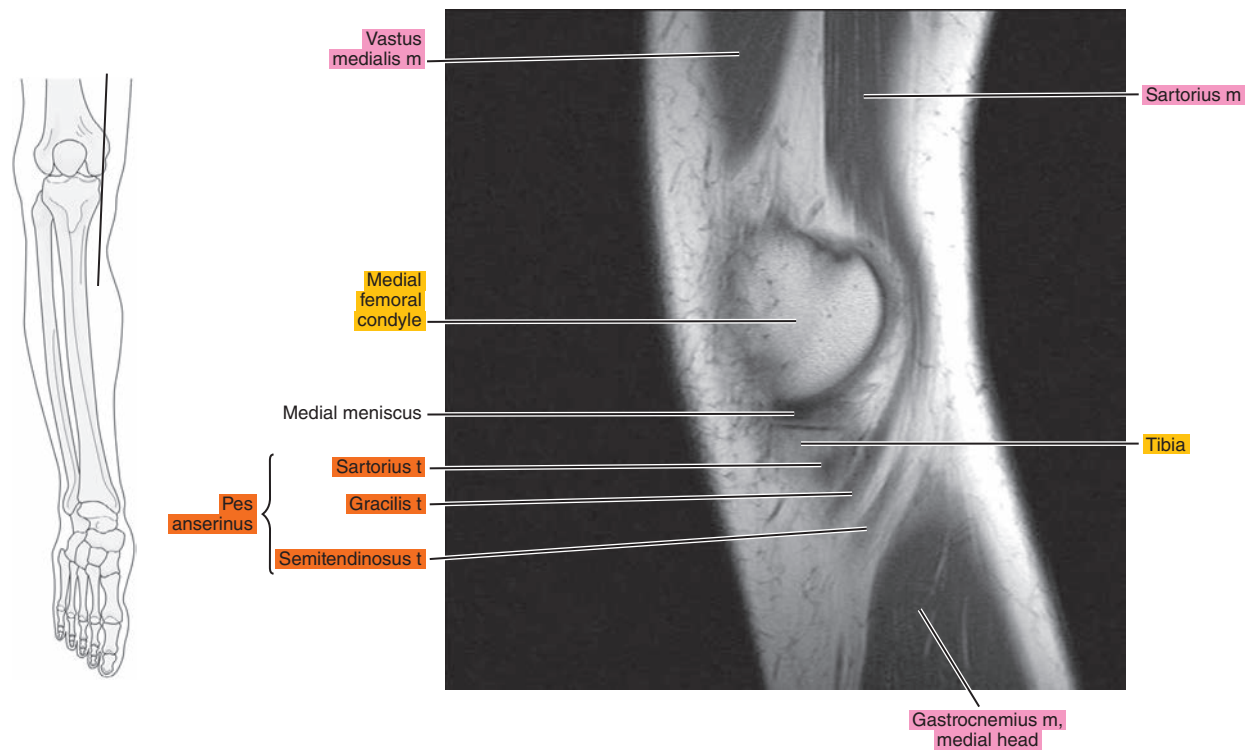




Figure 21.2.17



# CORONAL

Figure 21.3.1

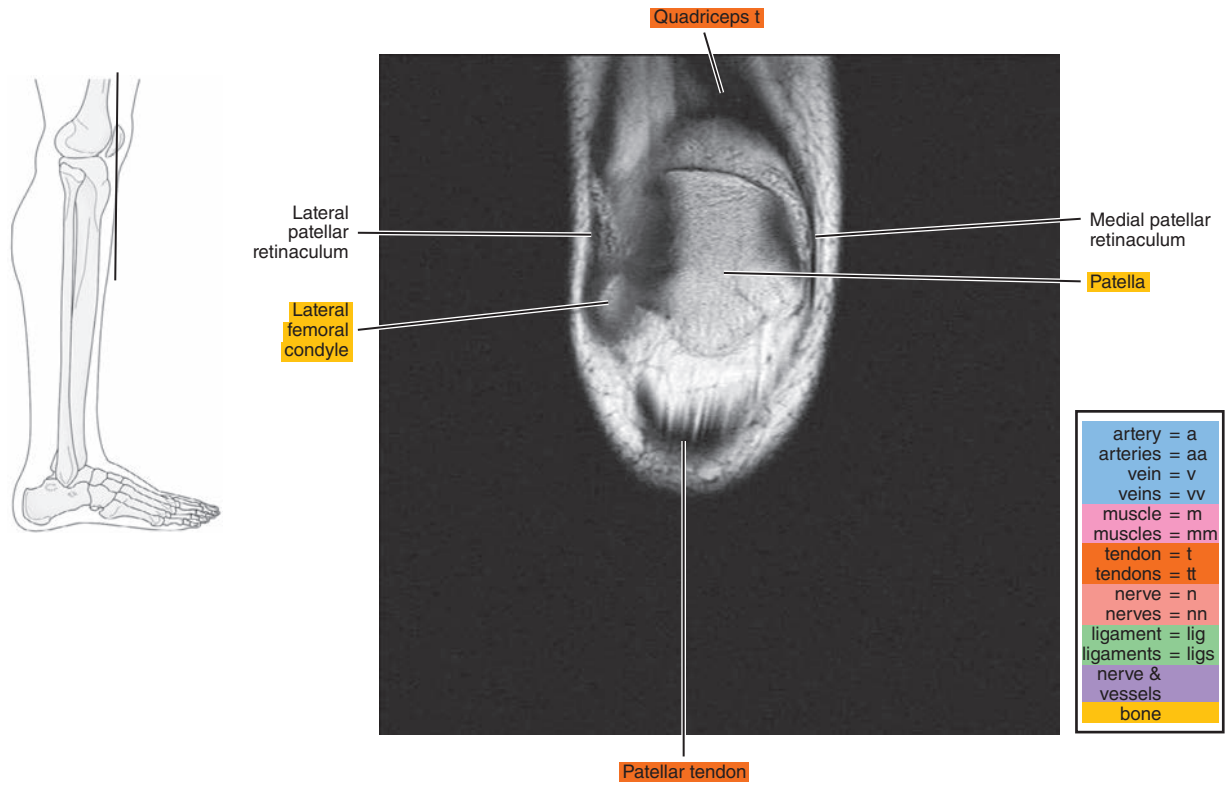


Figure 21.3.2

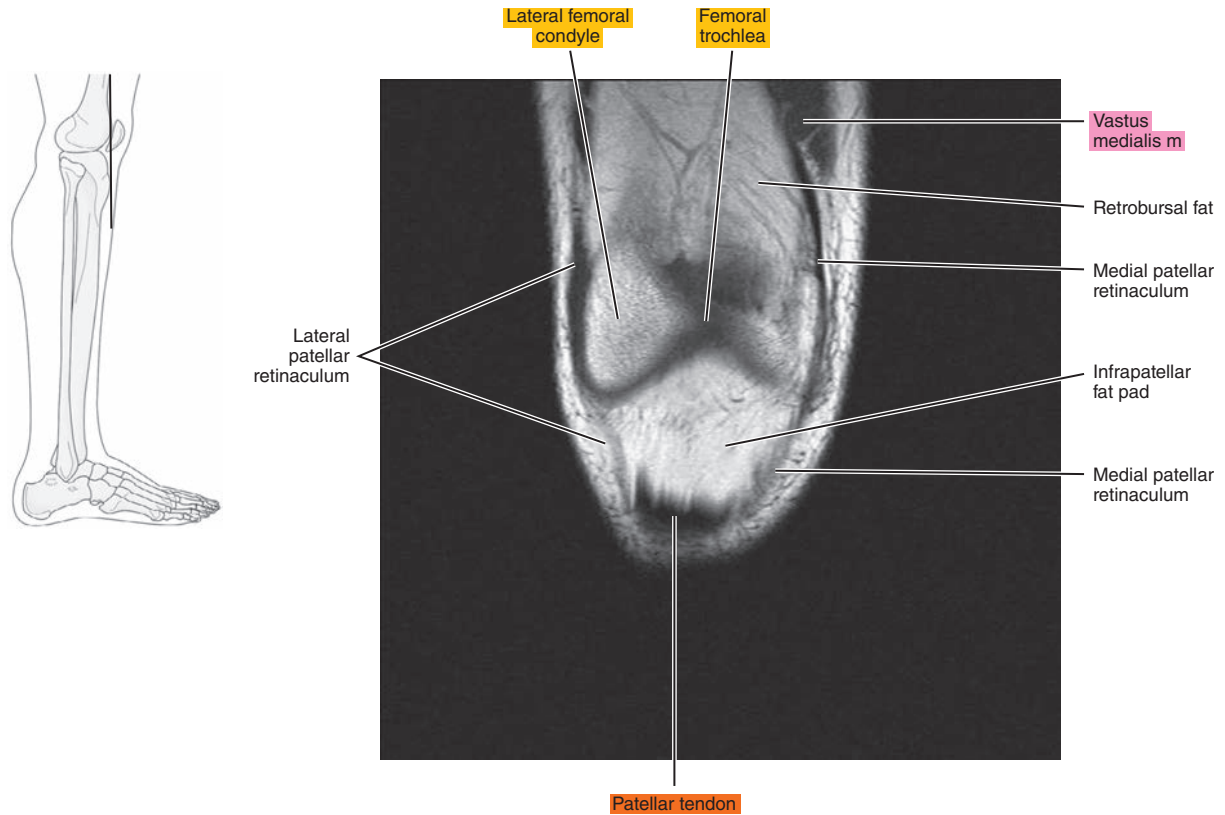


Figure 21.3.3

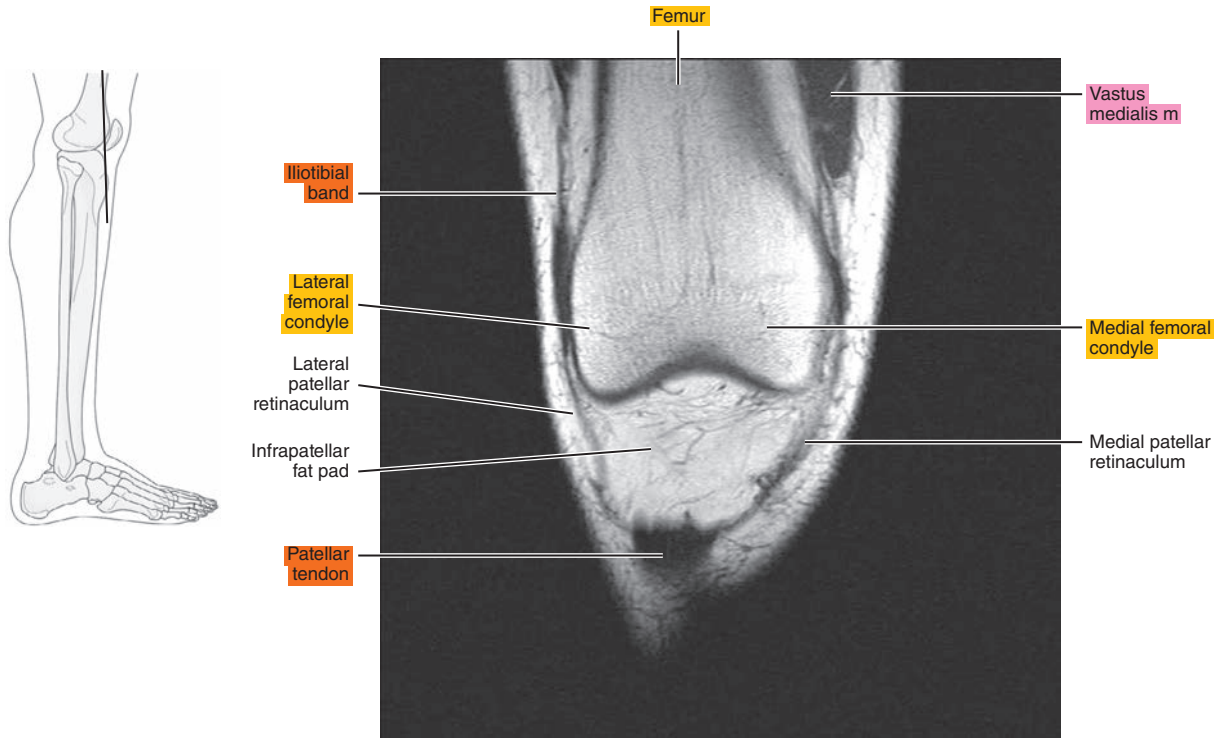


Figure 21.3.4

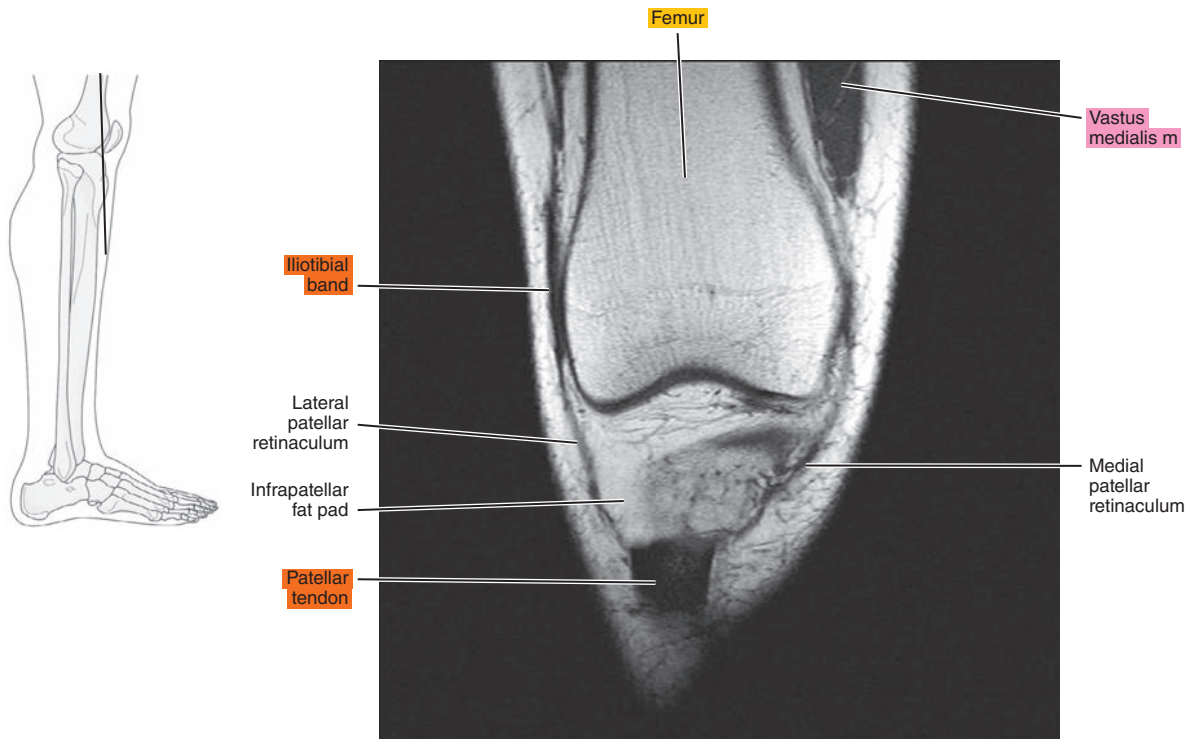


Figure 21.3.5

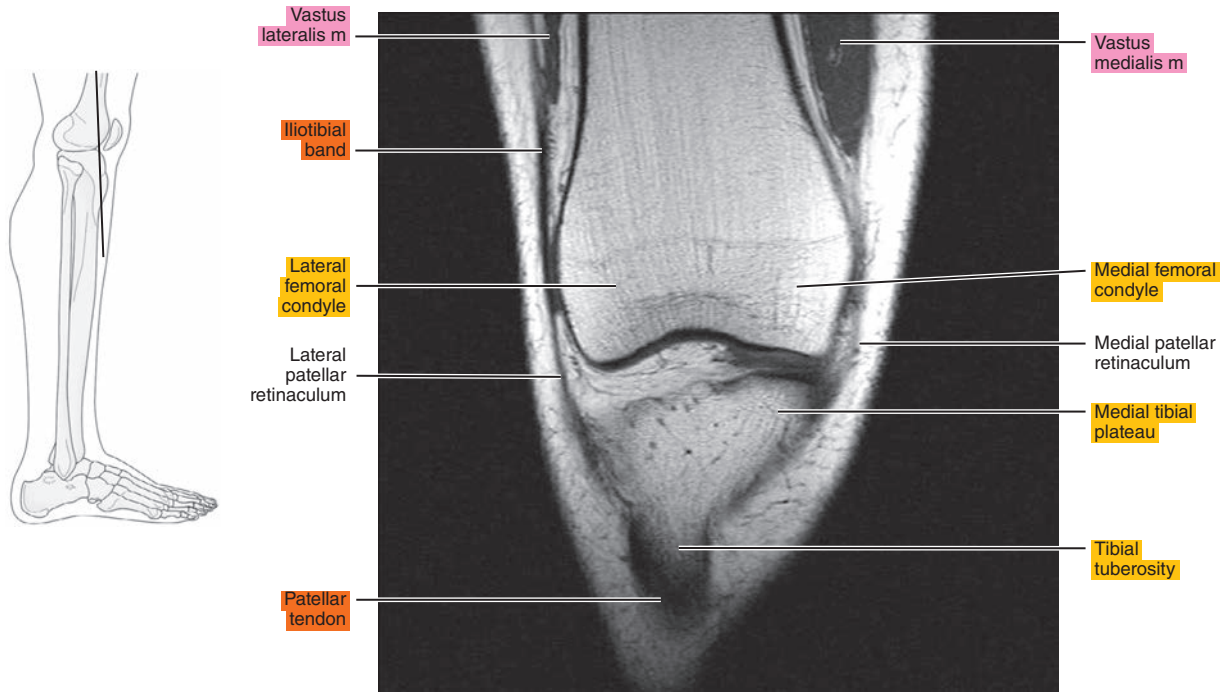


Figure 21.3.6

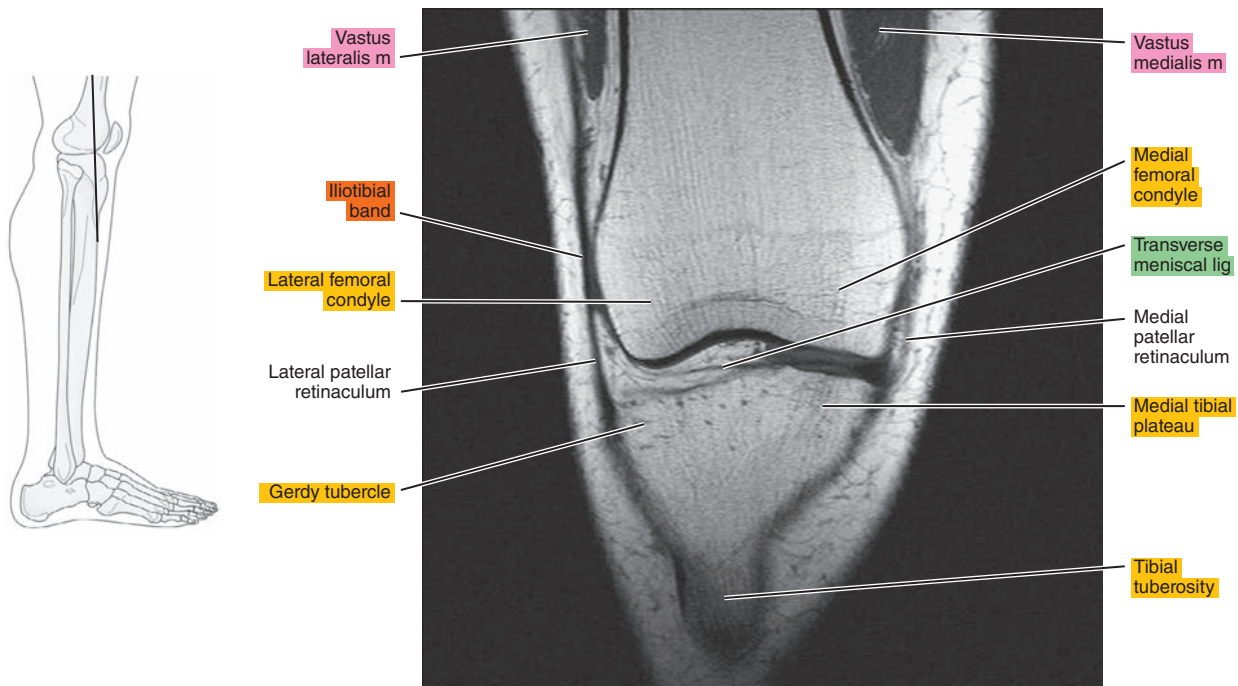




Figure 21.3.7

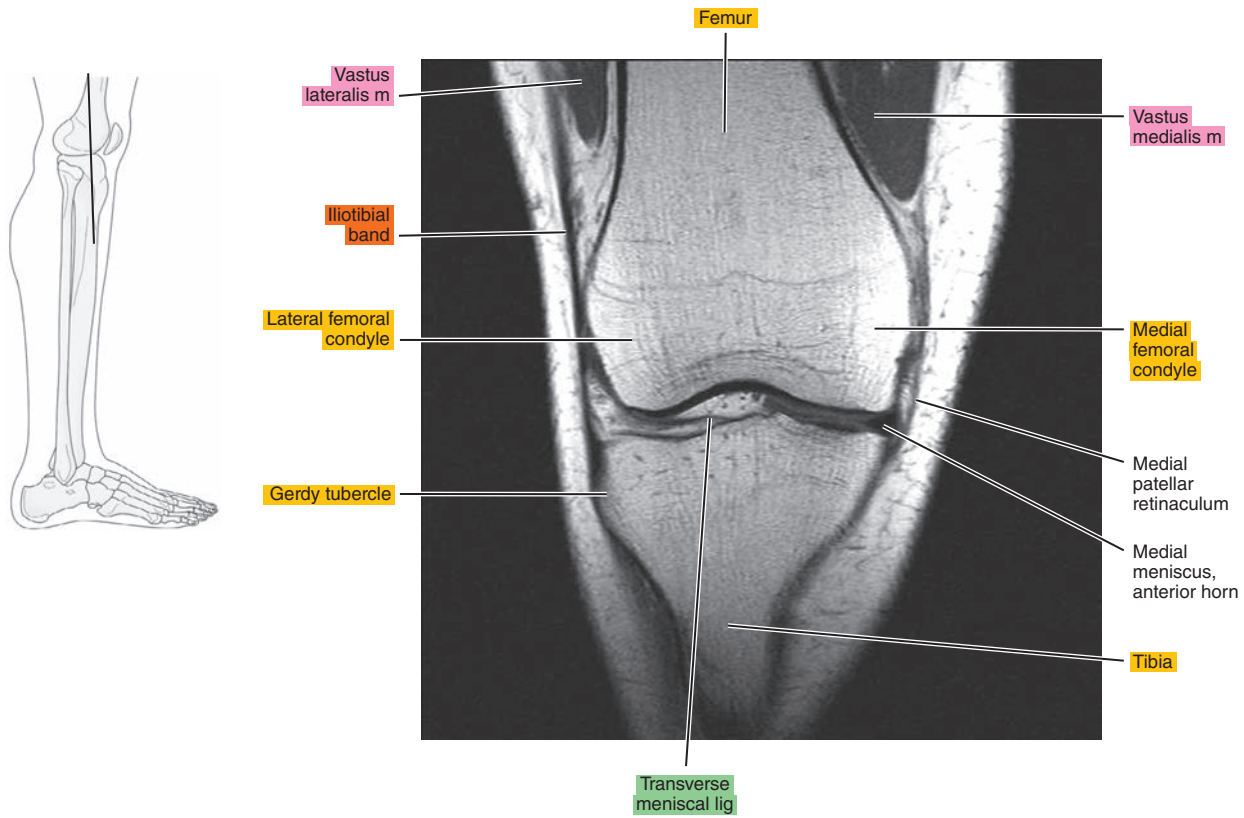


Figure 21.3.8

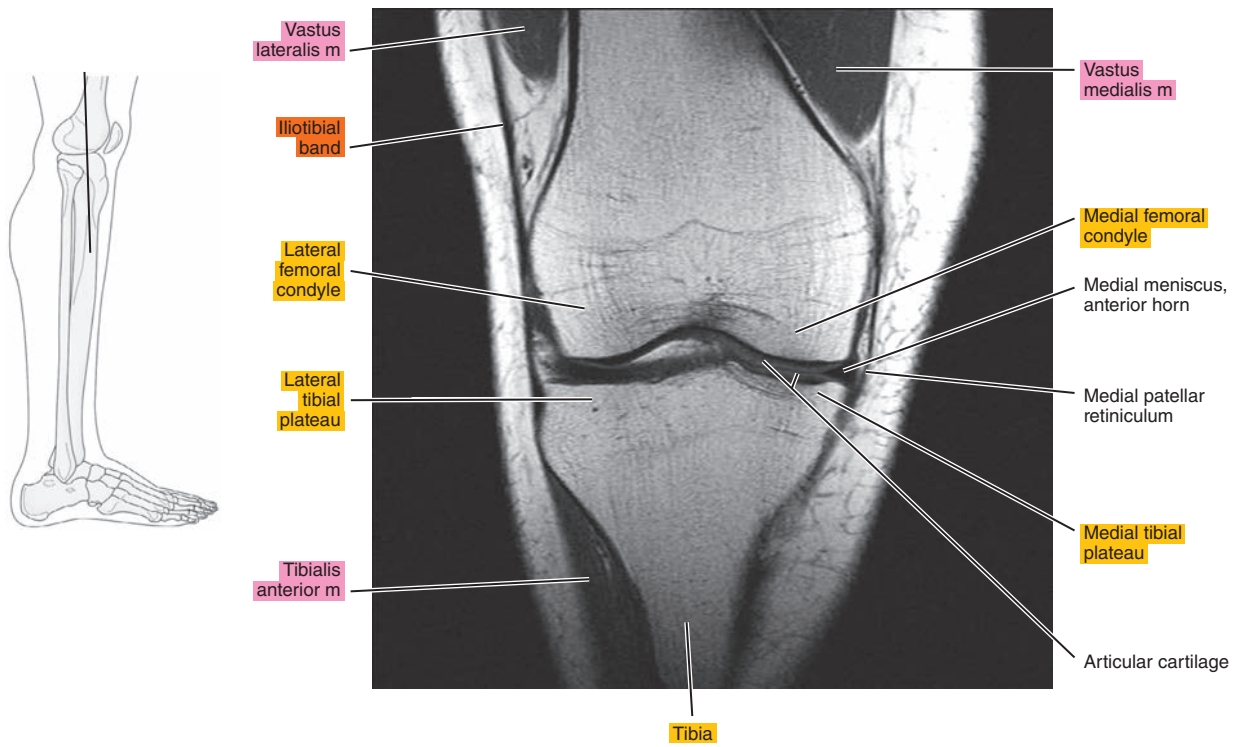


Figure 21.3.9

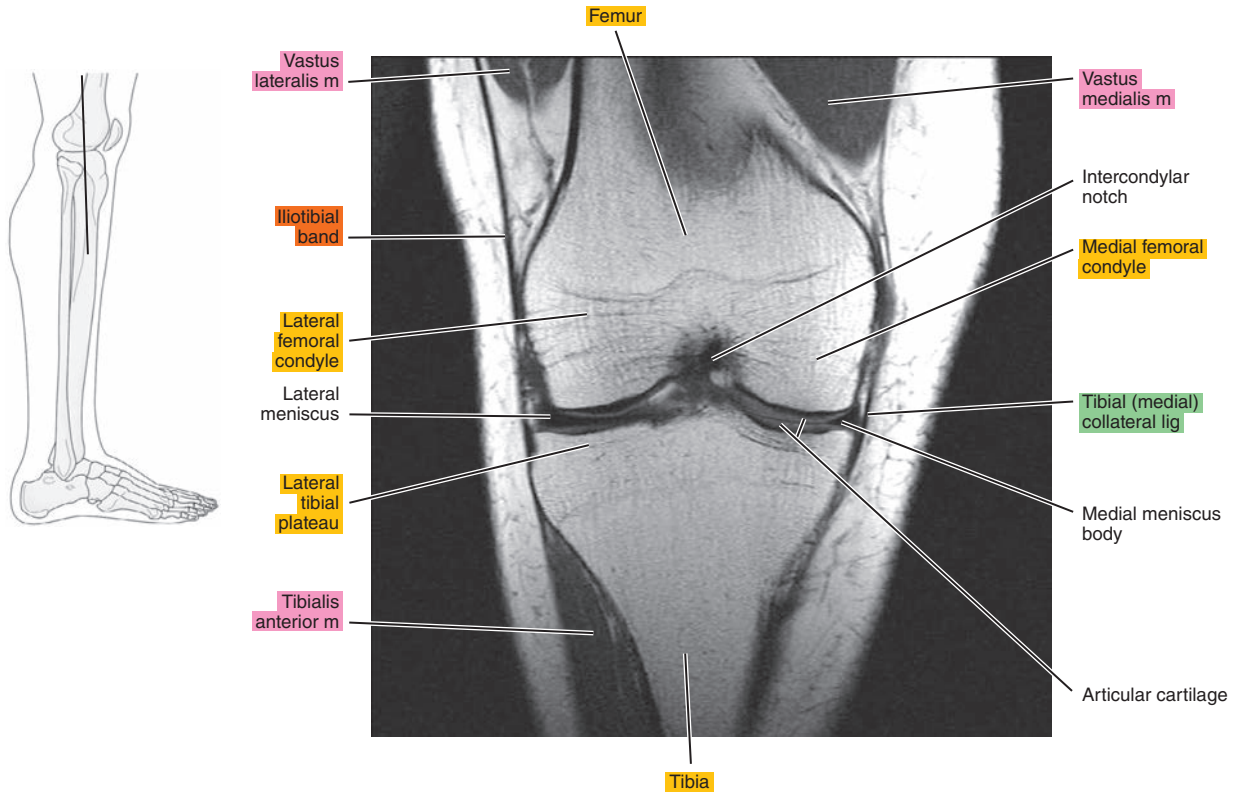


Figure 21.3.10

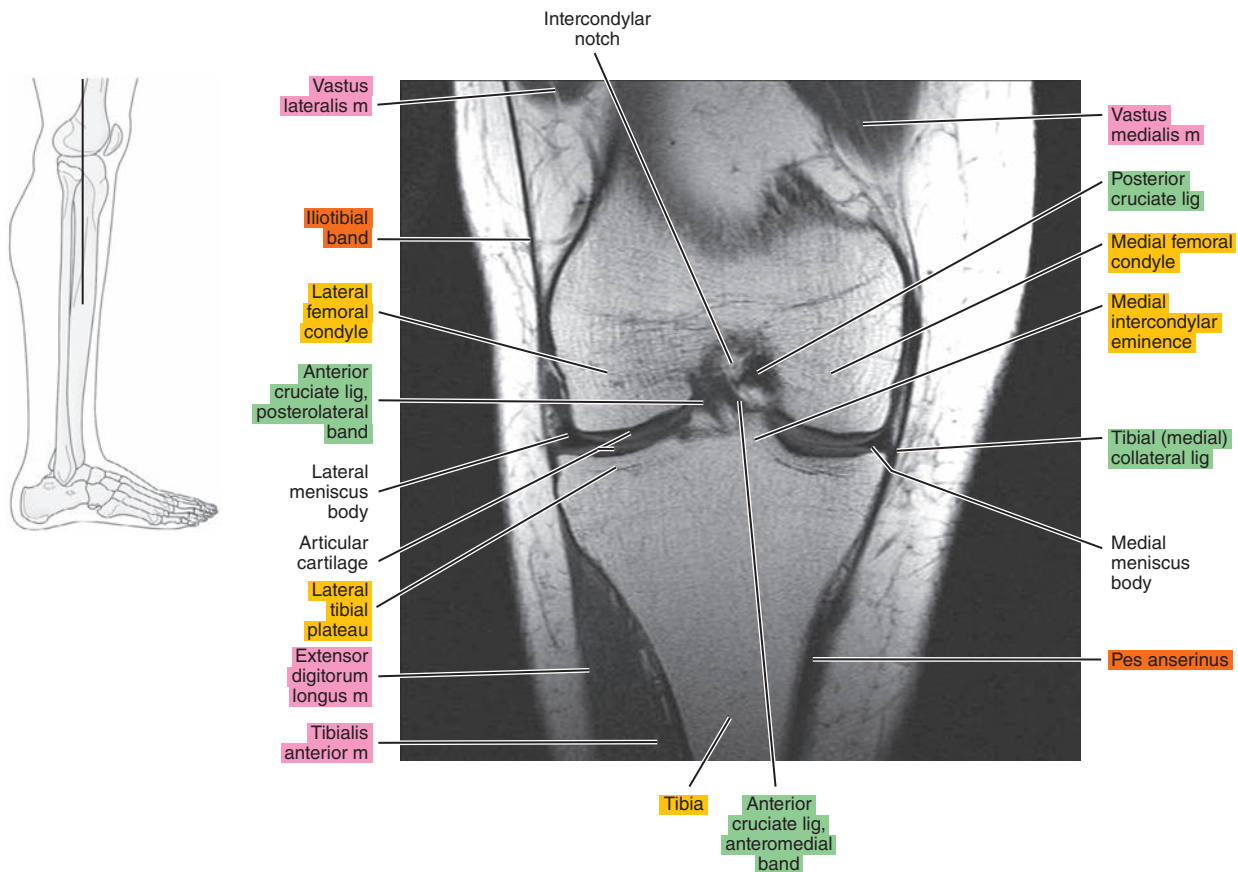


Figure 21.3.11

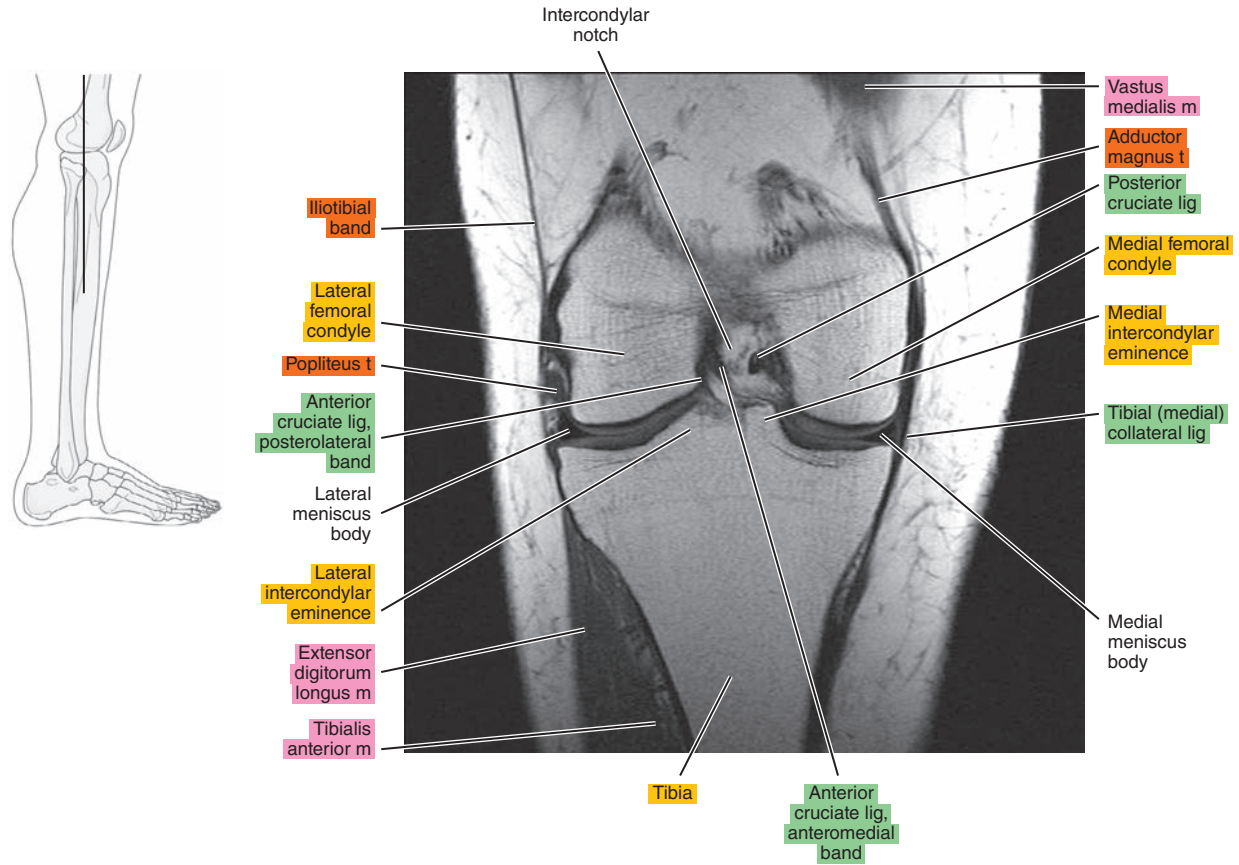


Figure 21.3.12

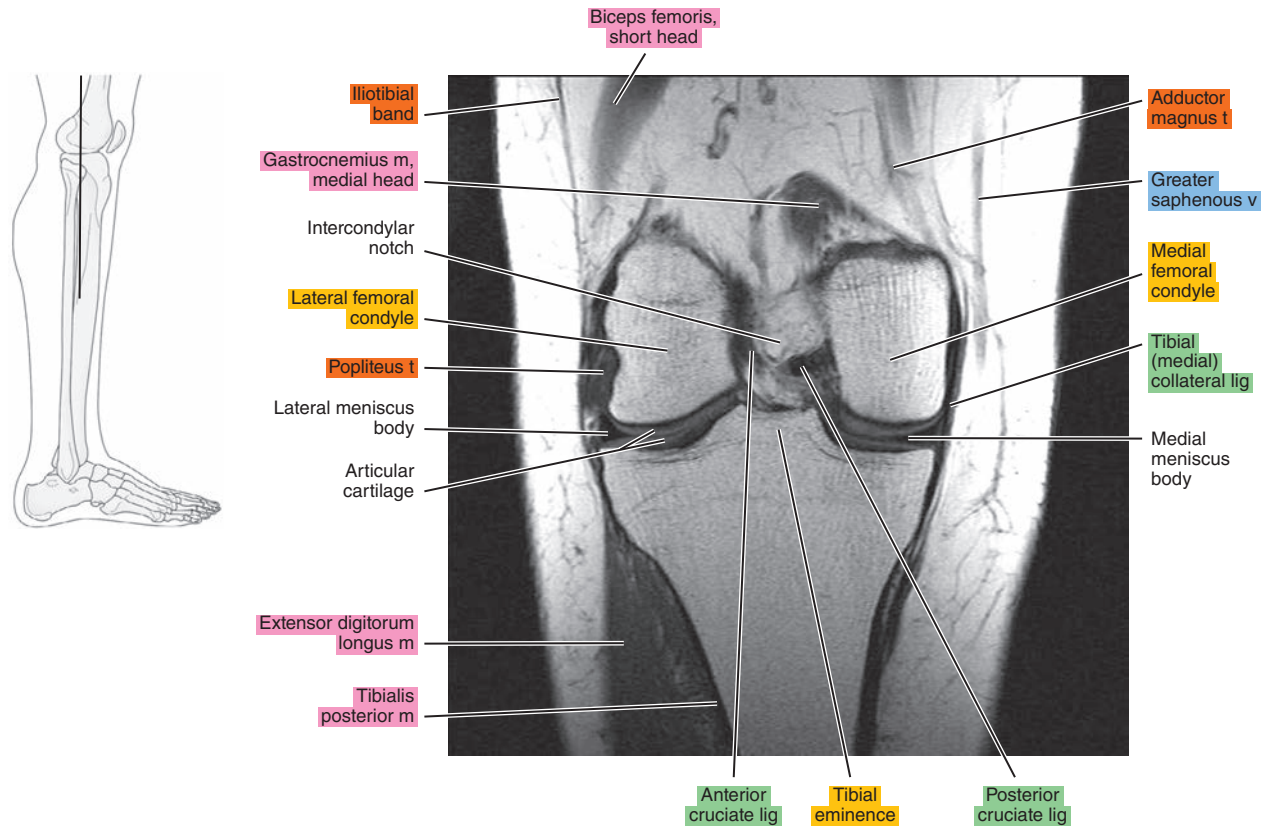




Figure 21.3.13

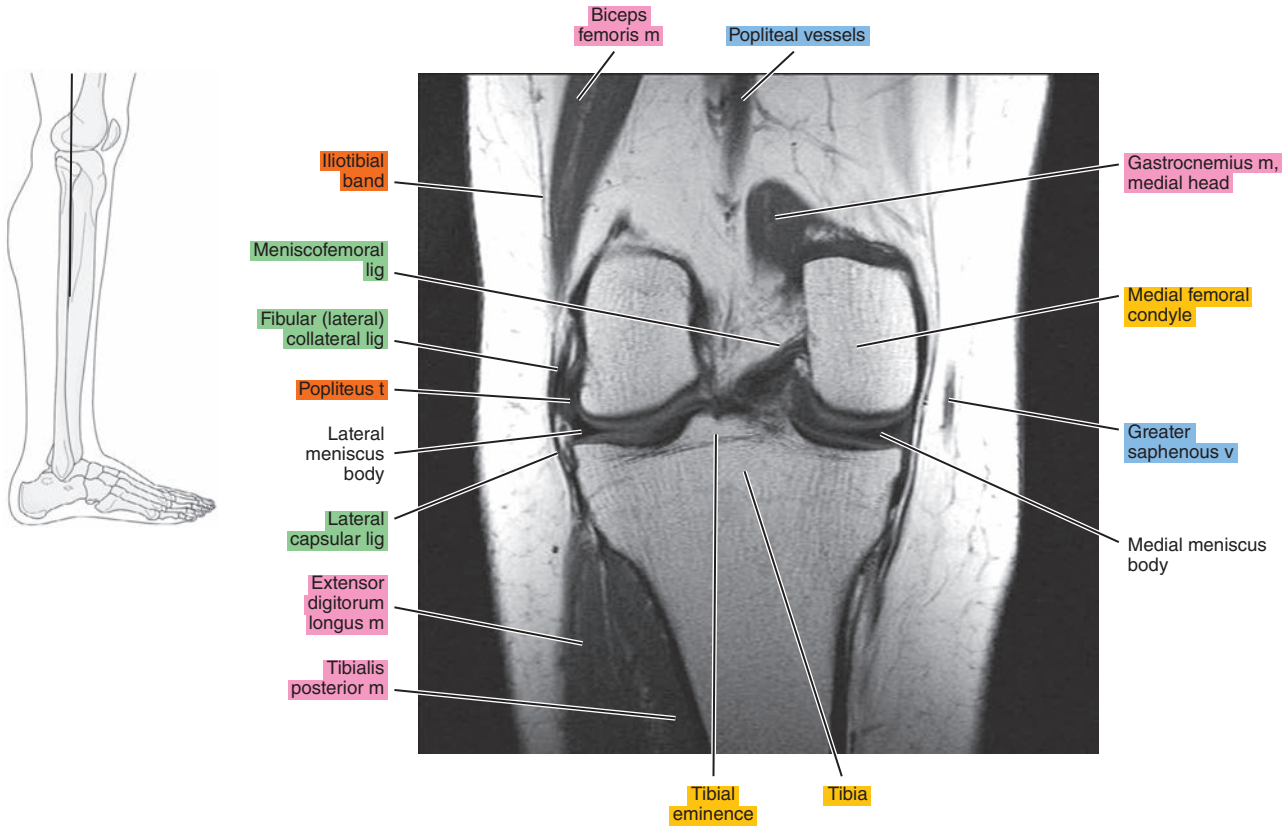


Figure 21.3.14

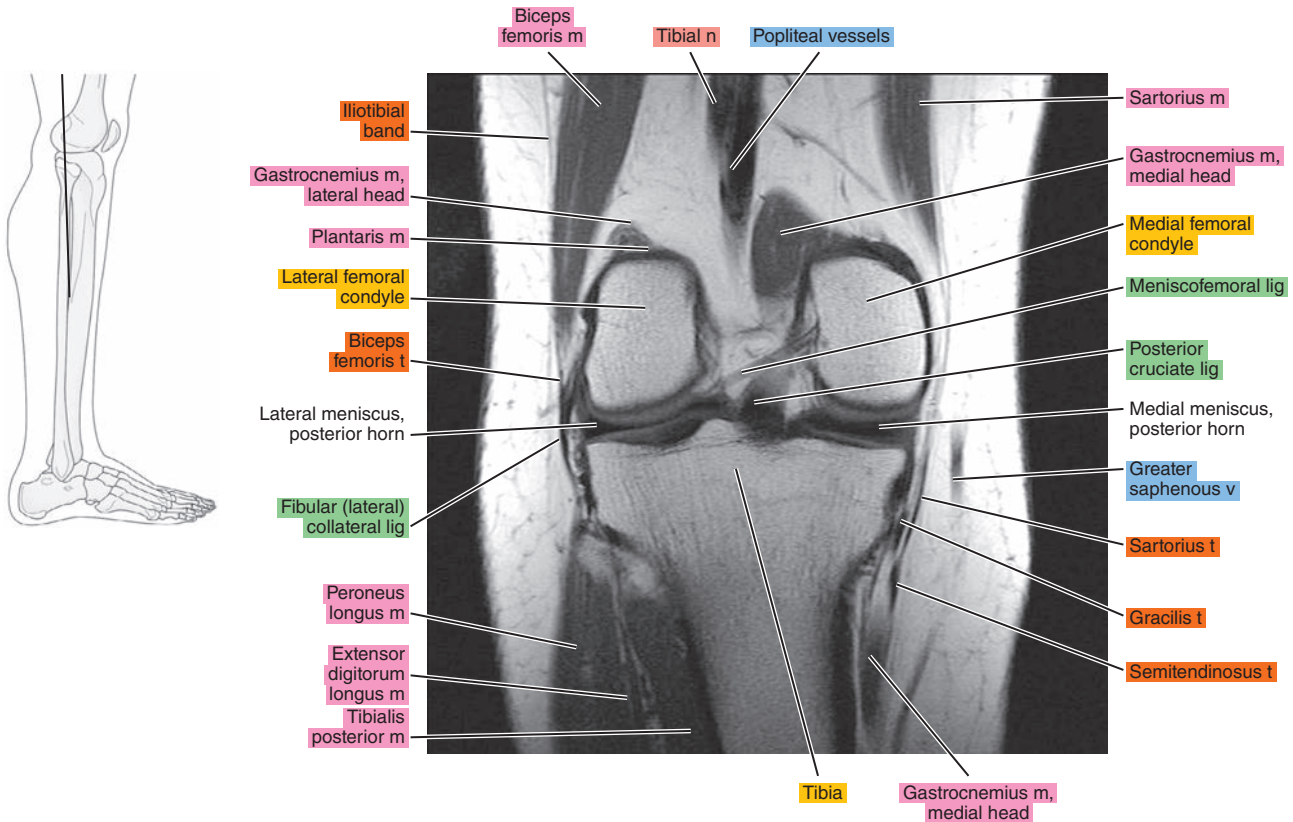




Figure 21.3.15

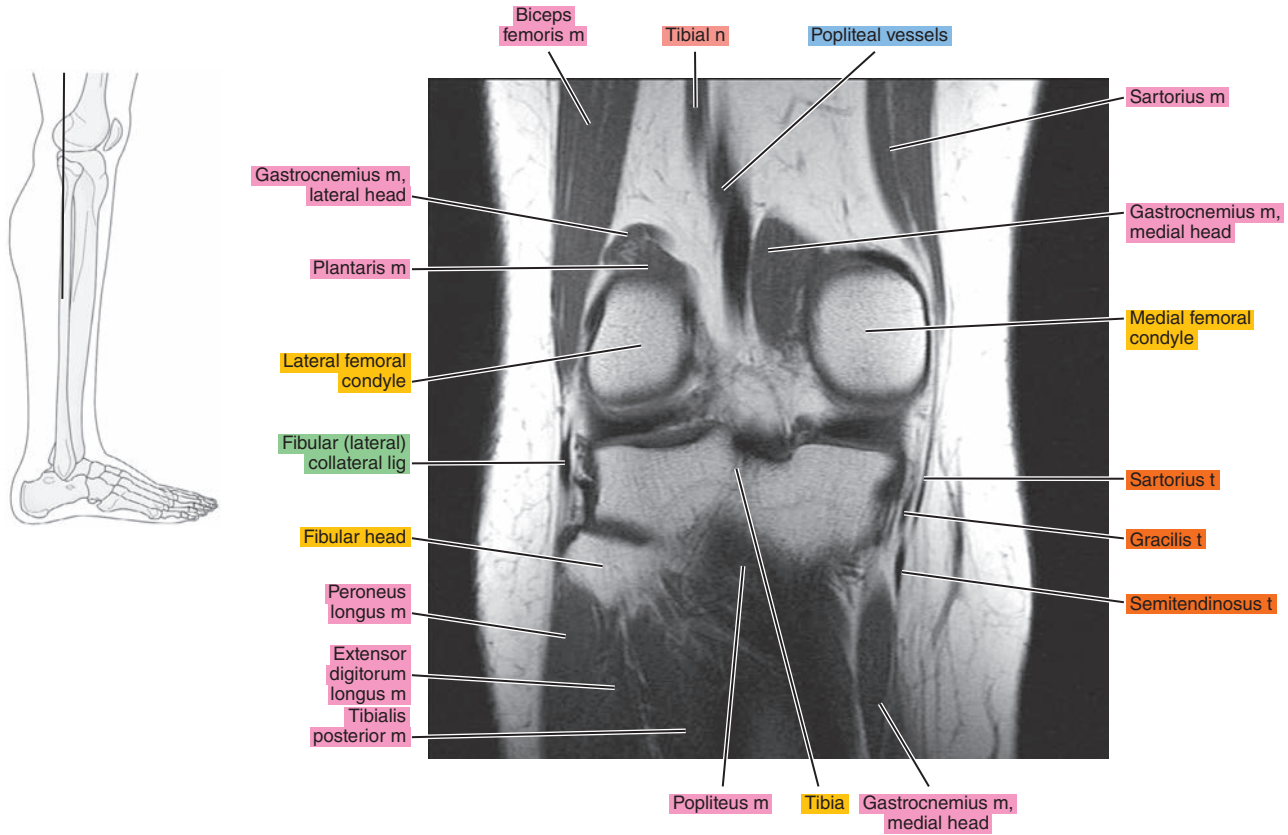


Figure 21.3.16

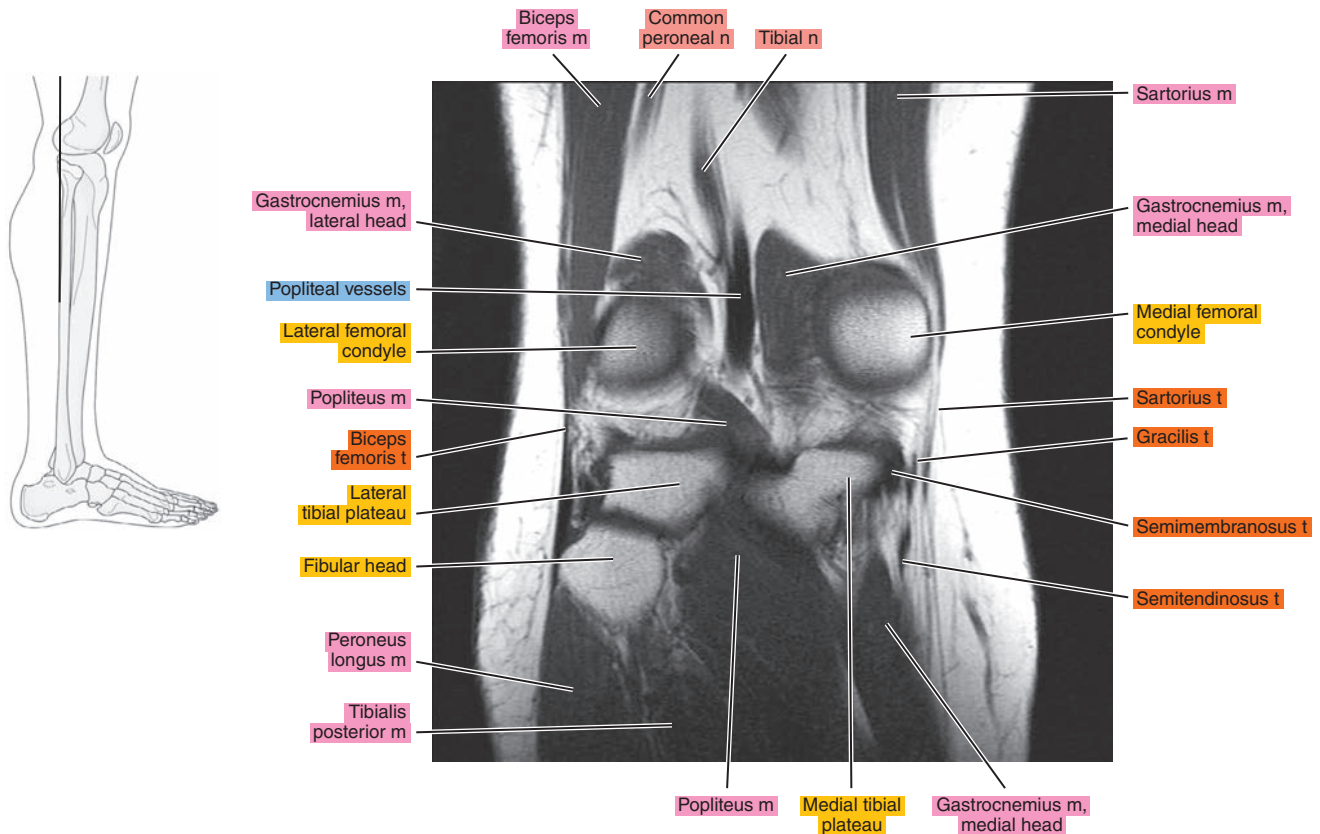


Figure 21.3.17

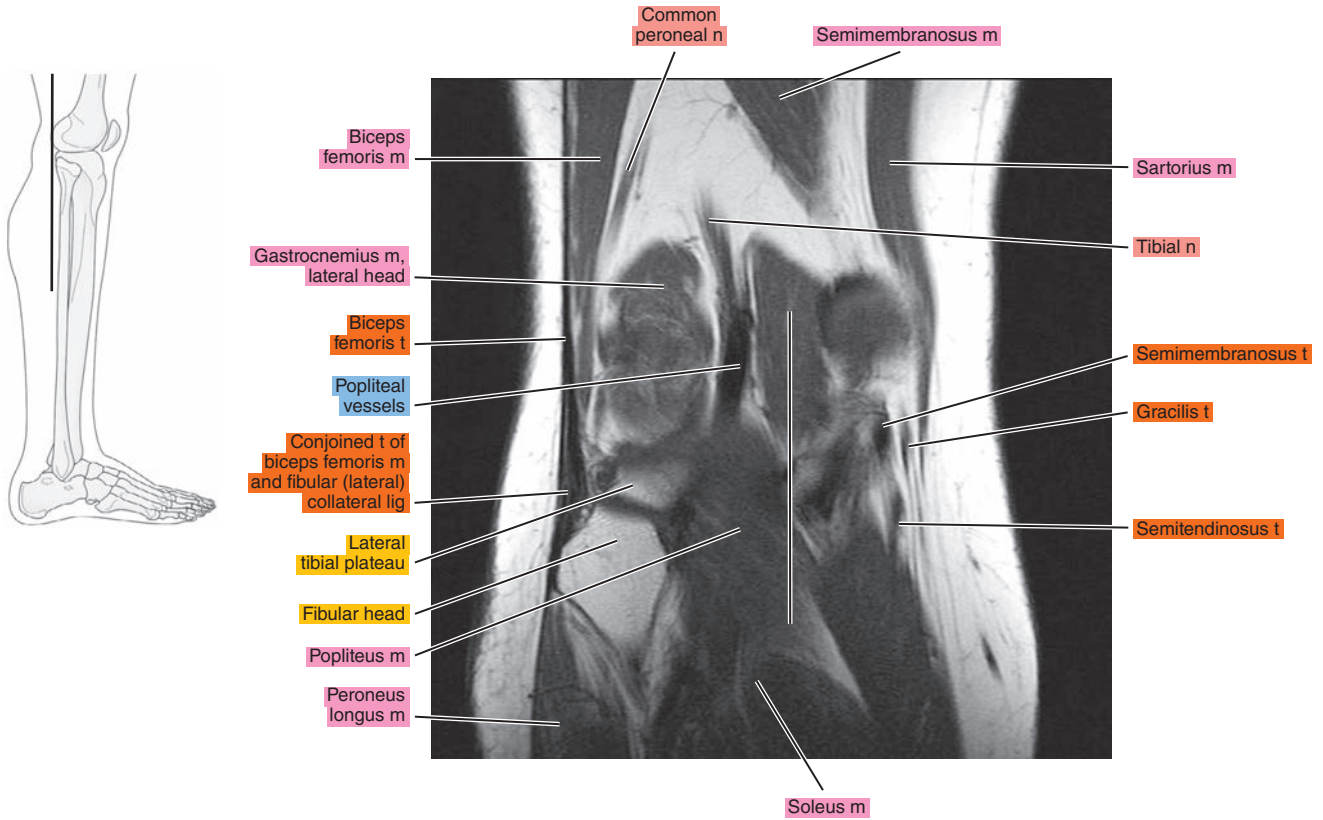


Figure 21.3.18

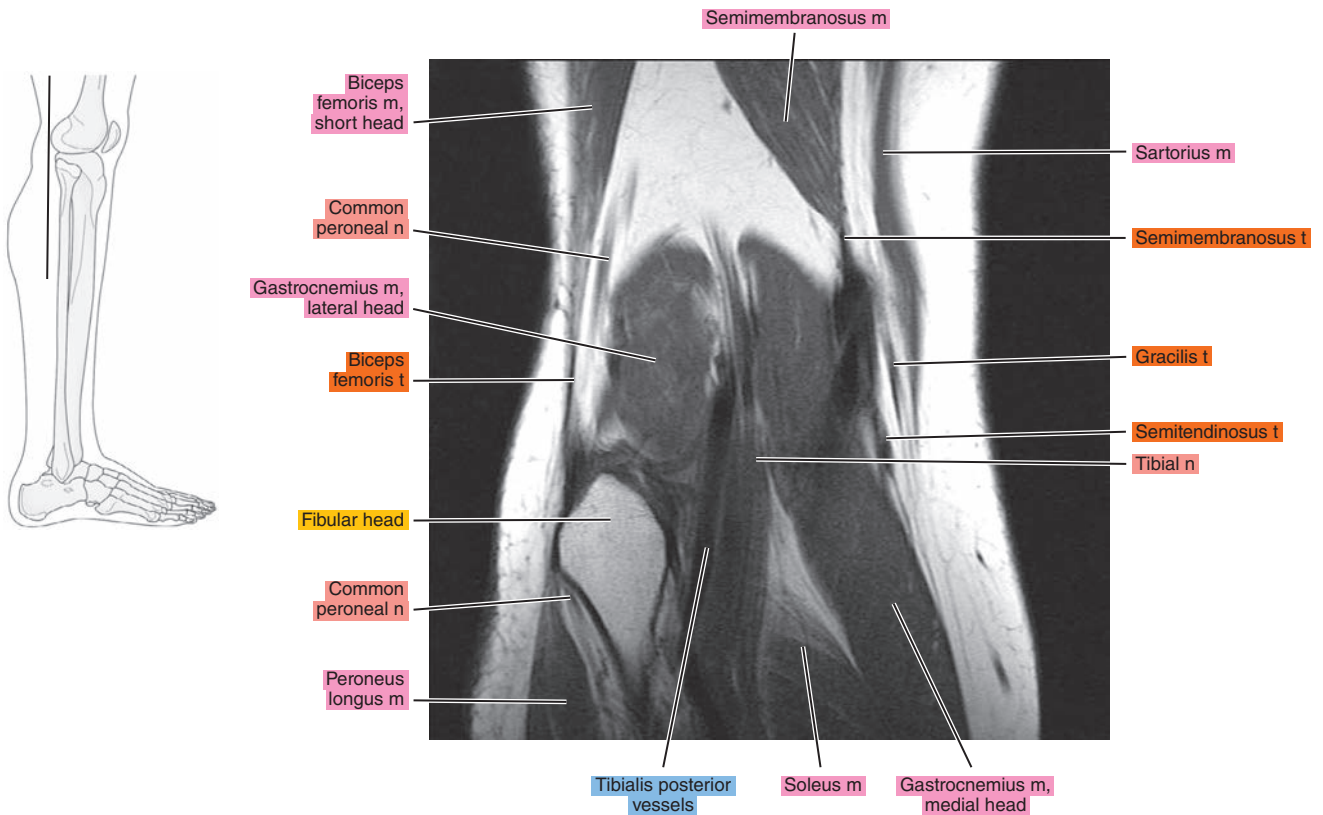
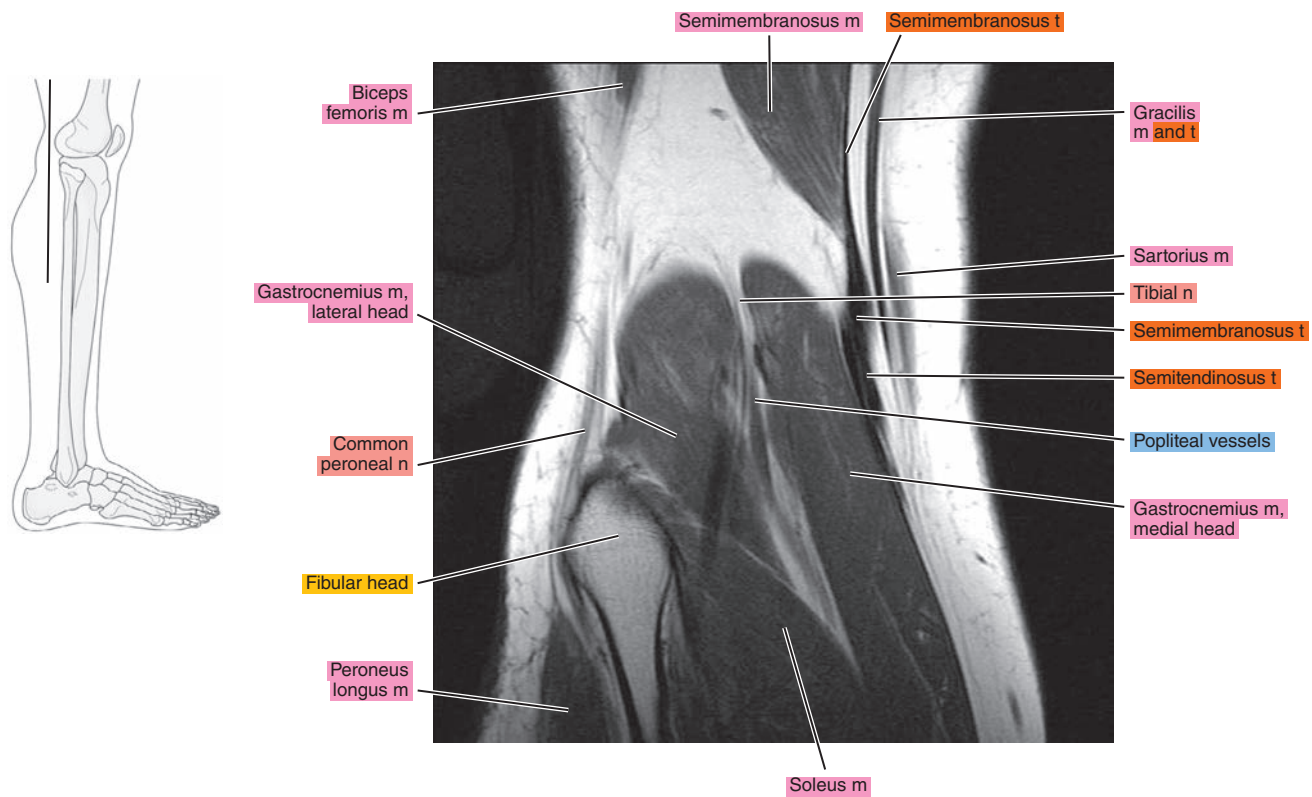


Figure 21.3.19



*Chapter*  
**22**

**MRI of the Leg**



# AXIAL

Figure 22.1.1

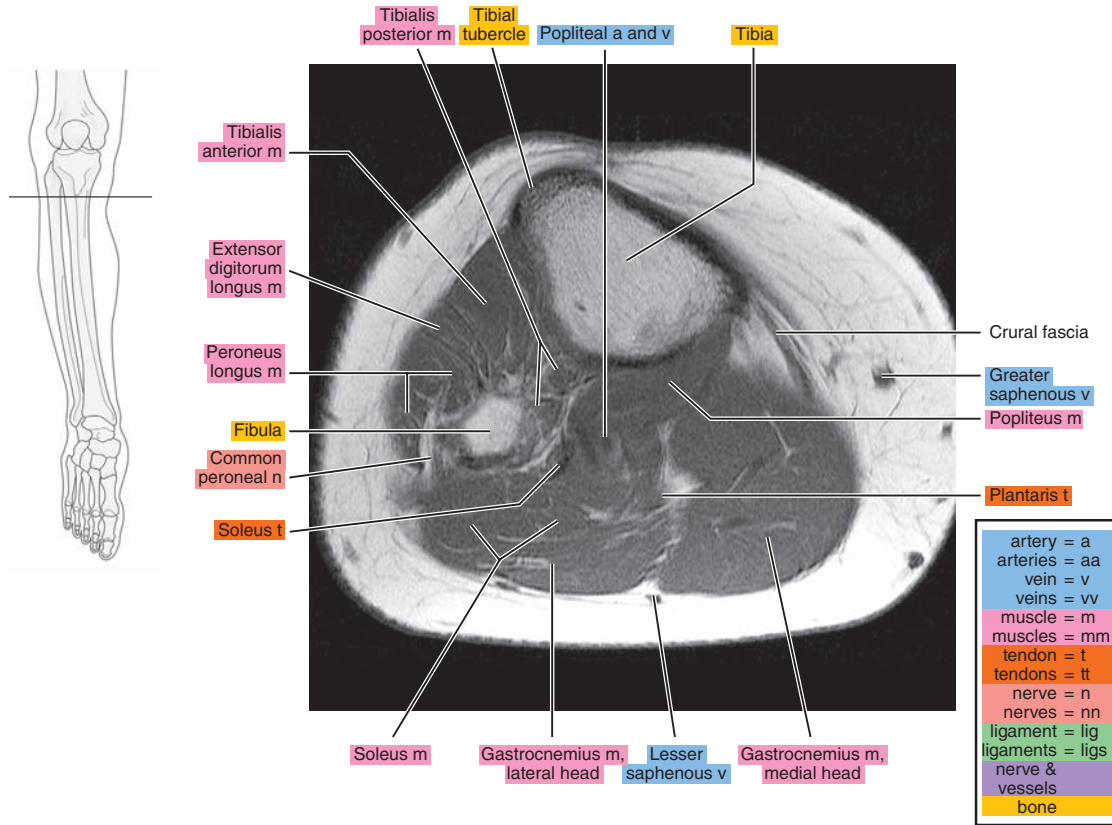


Figure 22.1.2

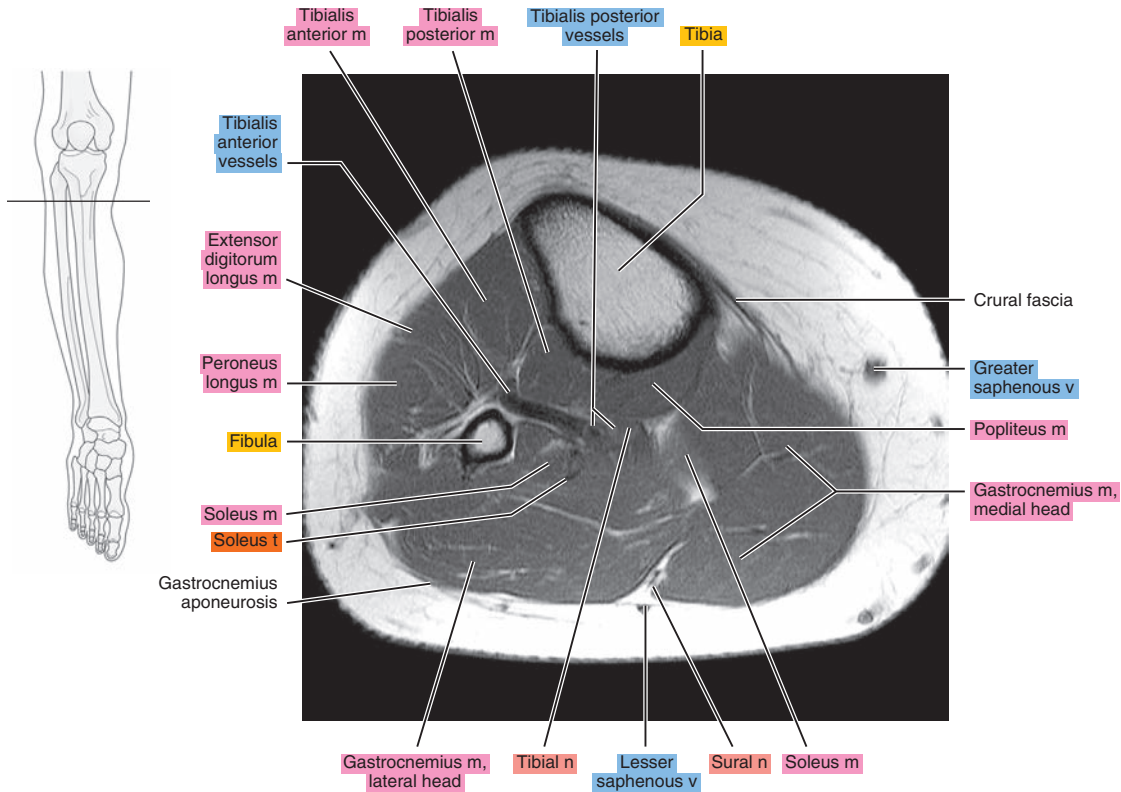


Figure 22.1.3

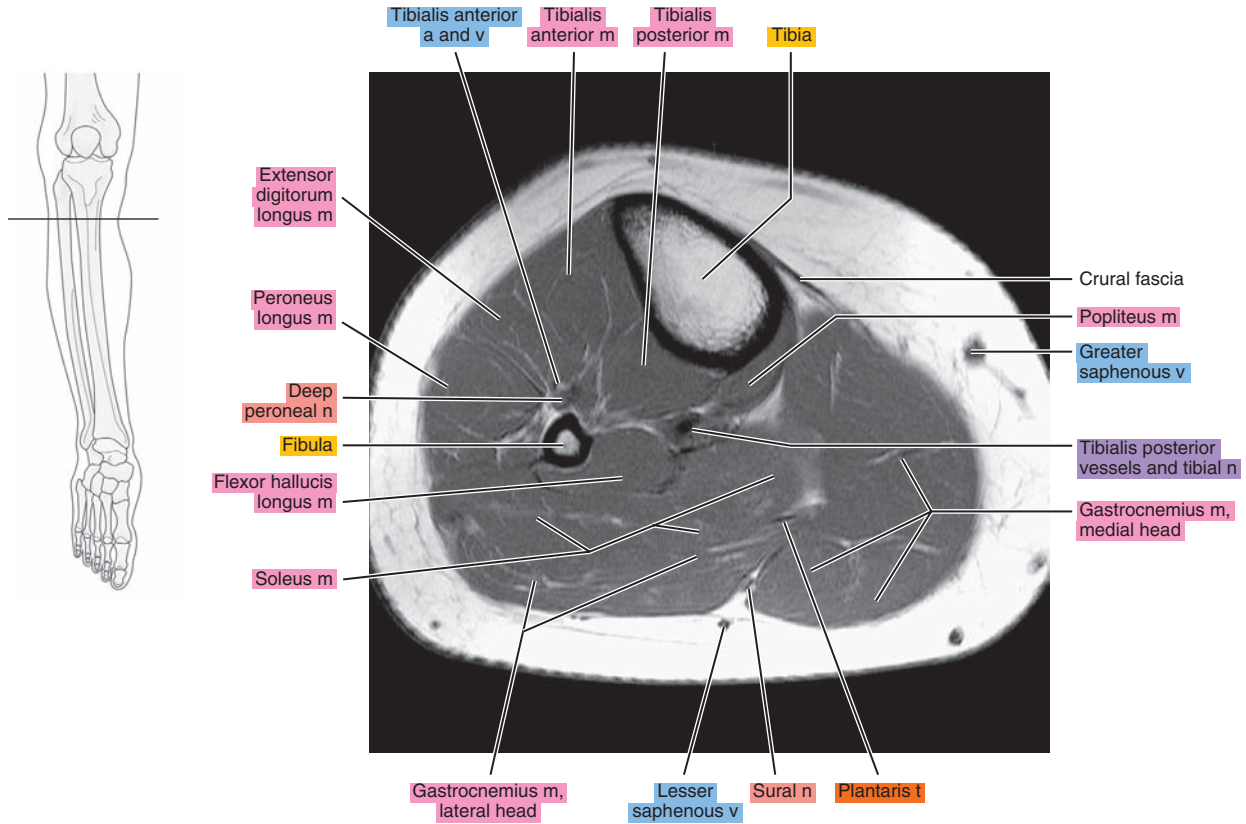


Figure 22.1.4

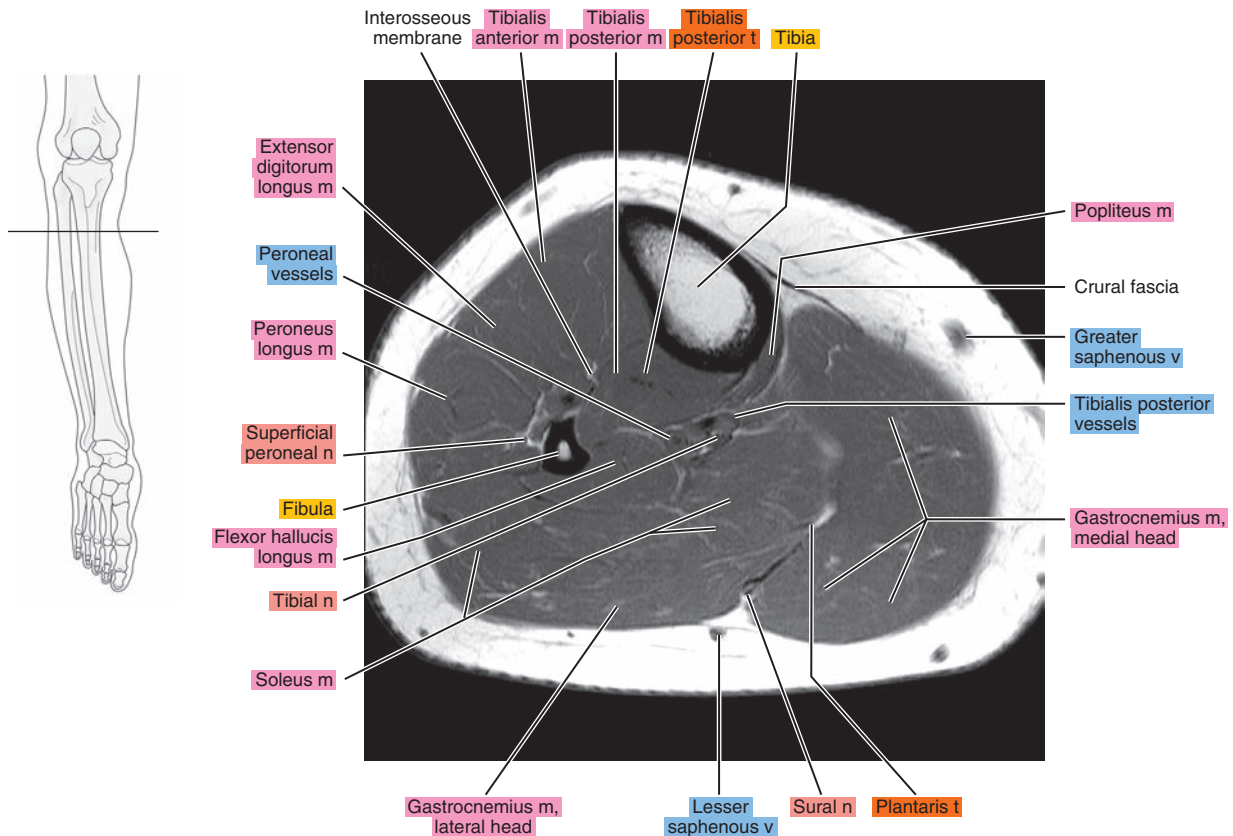


Figure 22.1.5

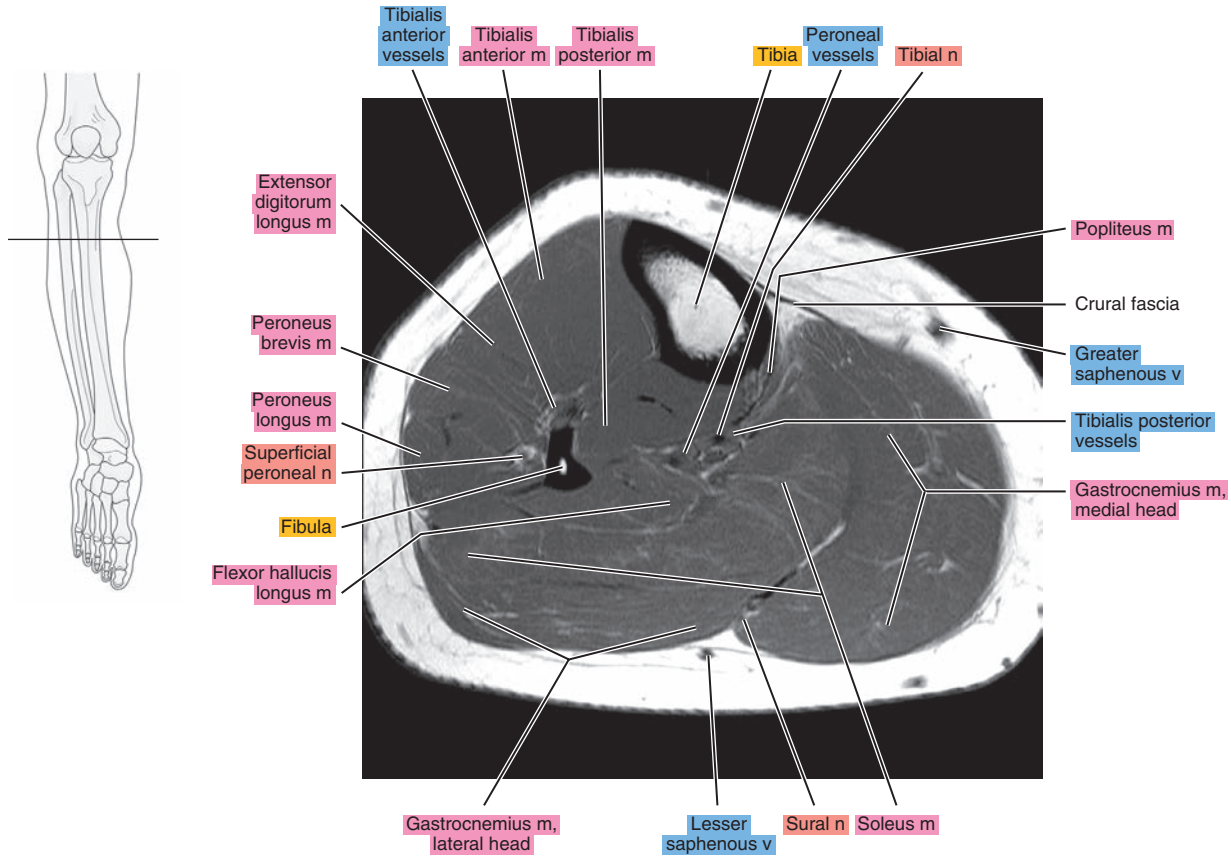


Figure 22.1.6

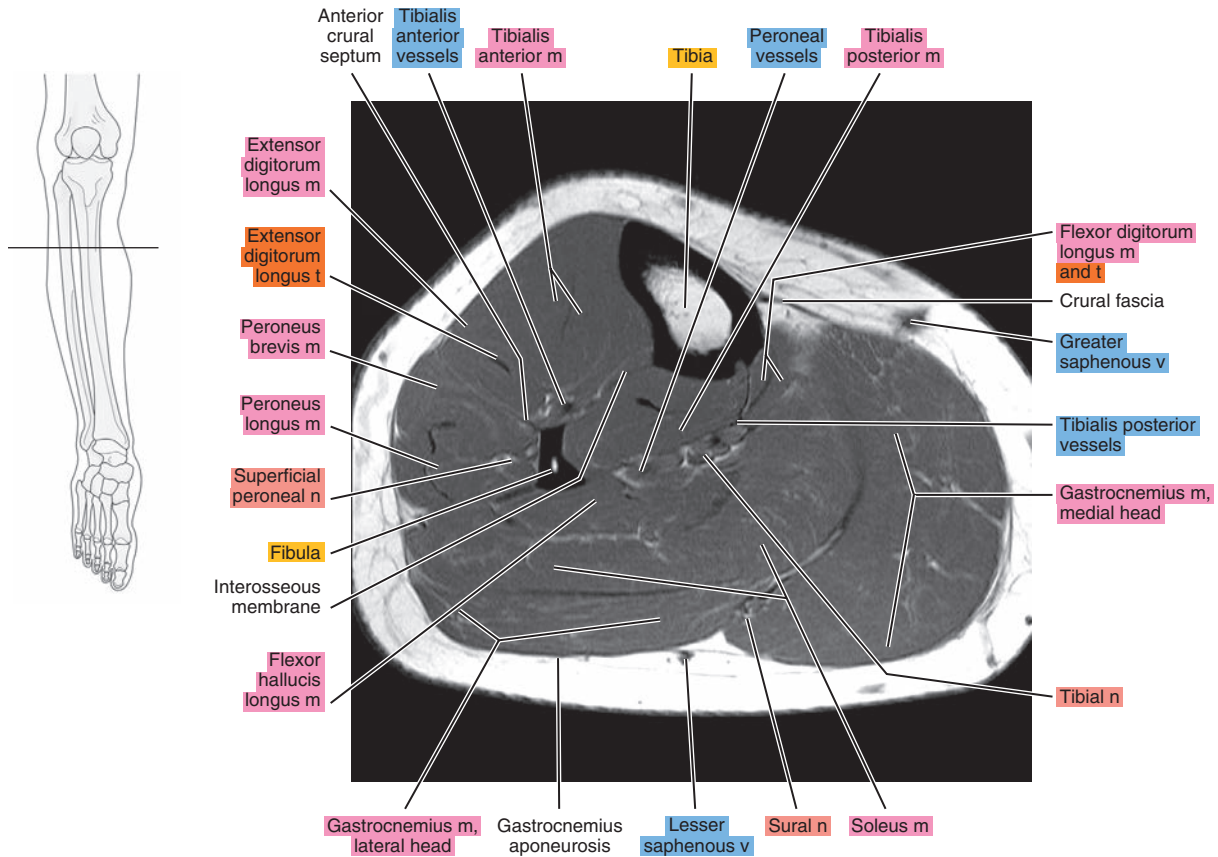




Figure 22.1.7

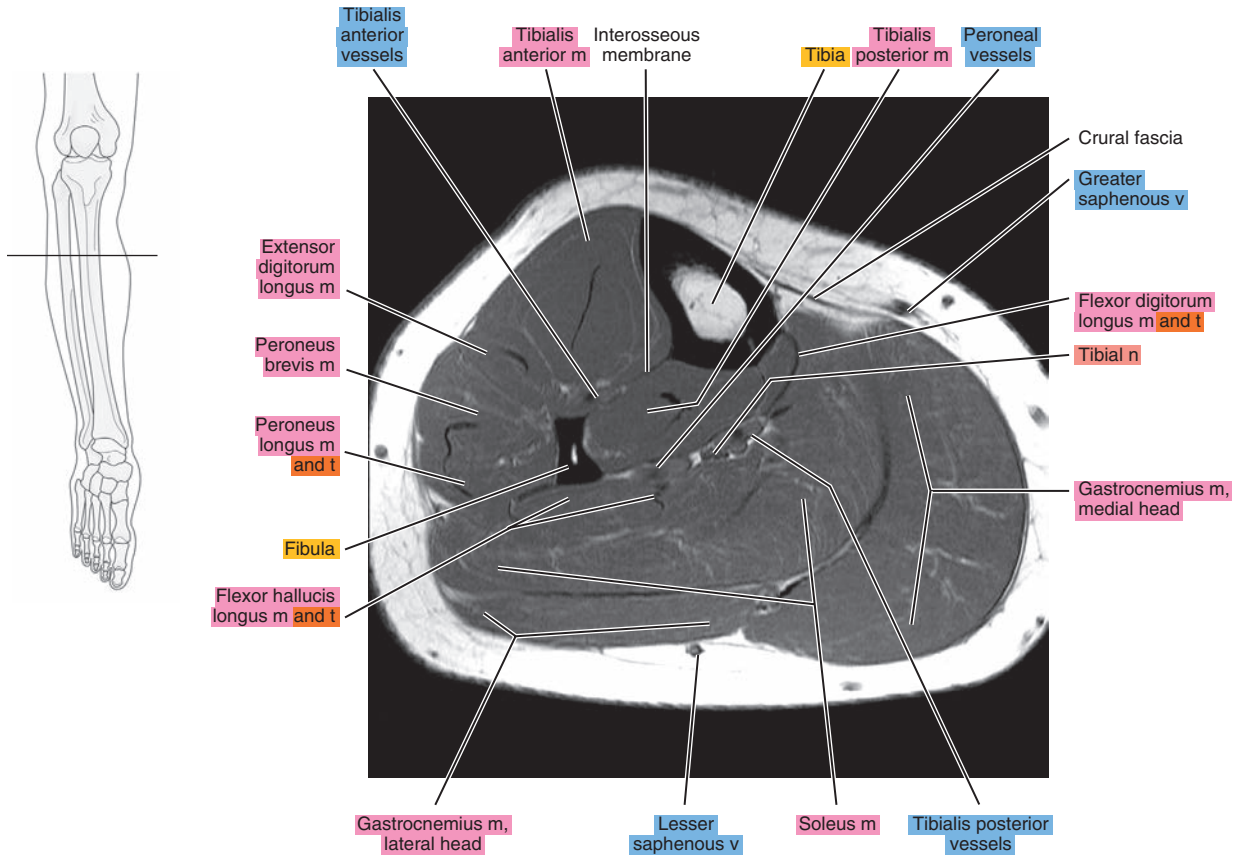


Figure 22.1.8

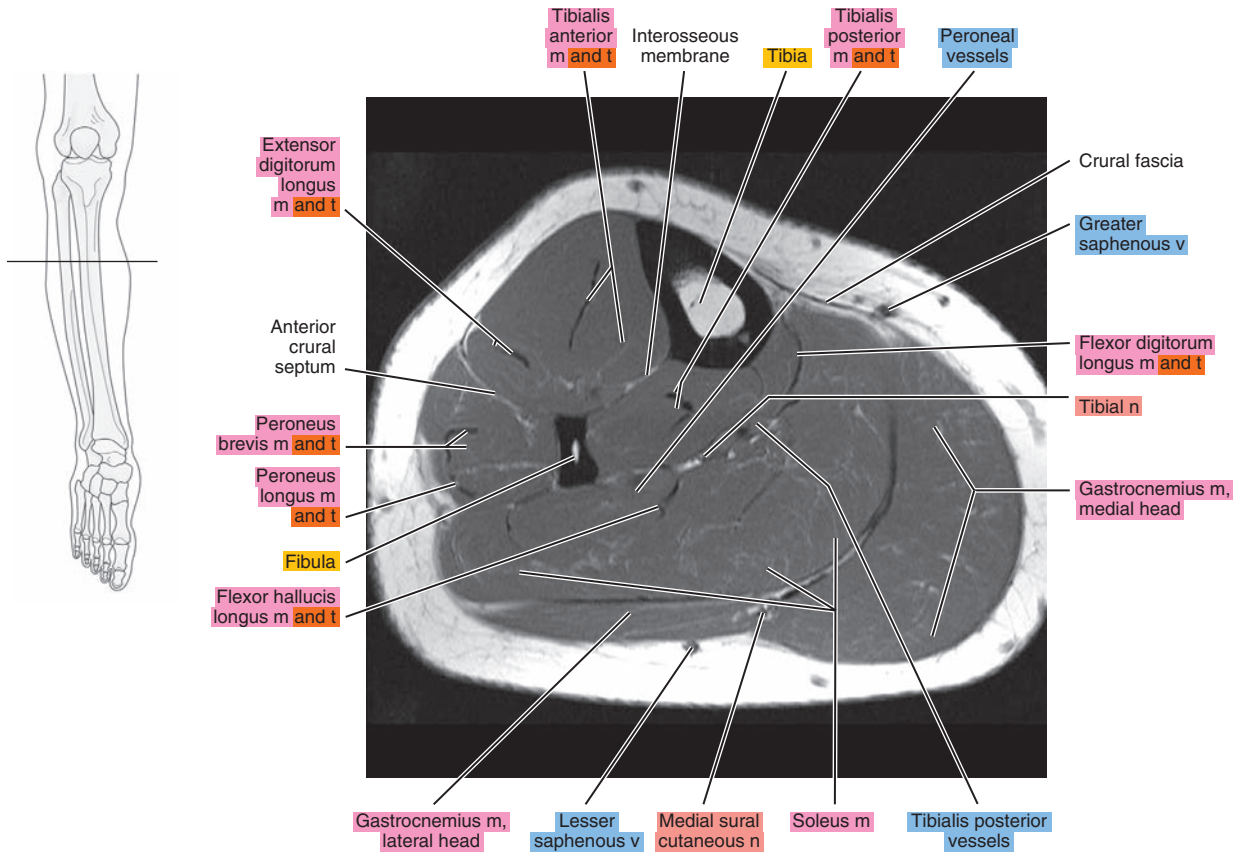




Figure 22.1.9

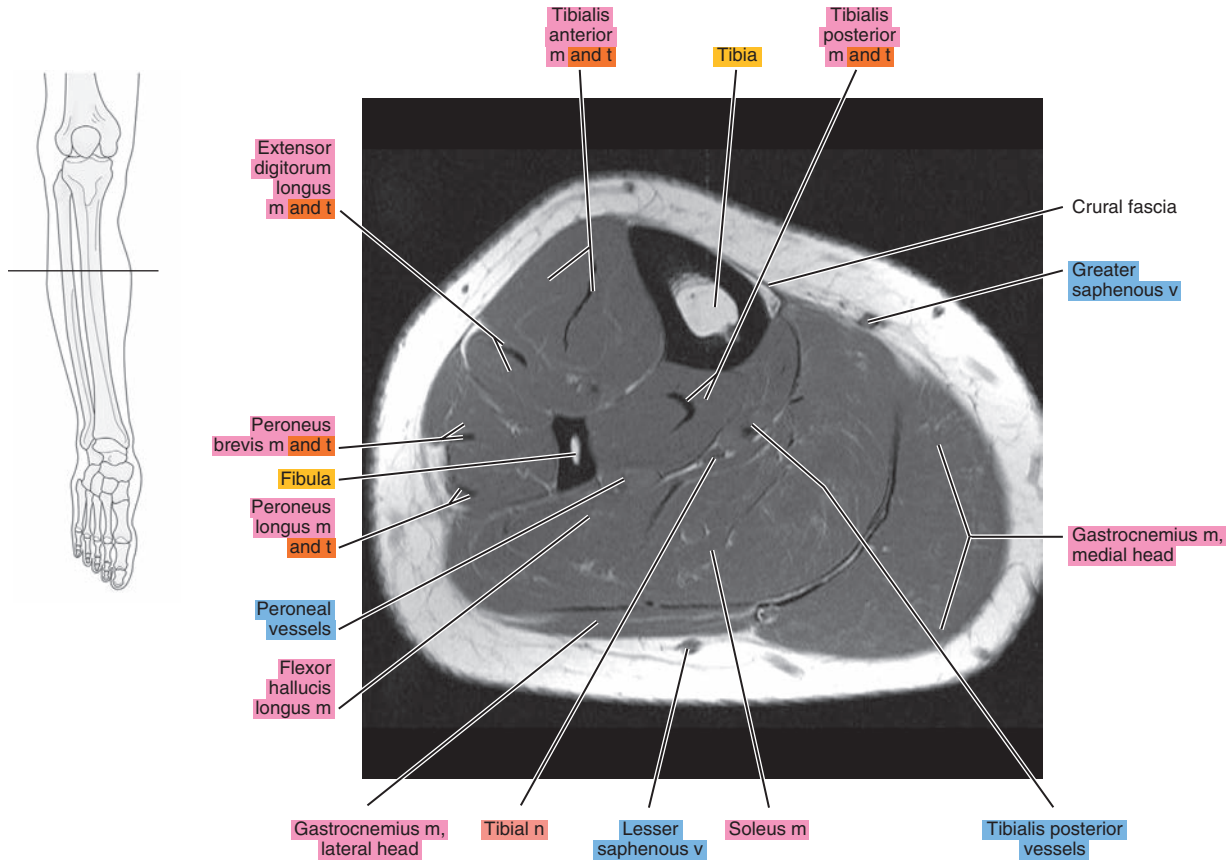


Figure 22.1.10

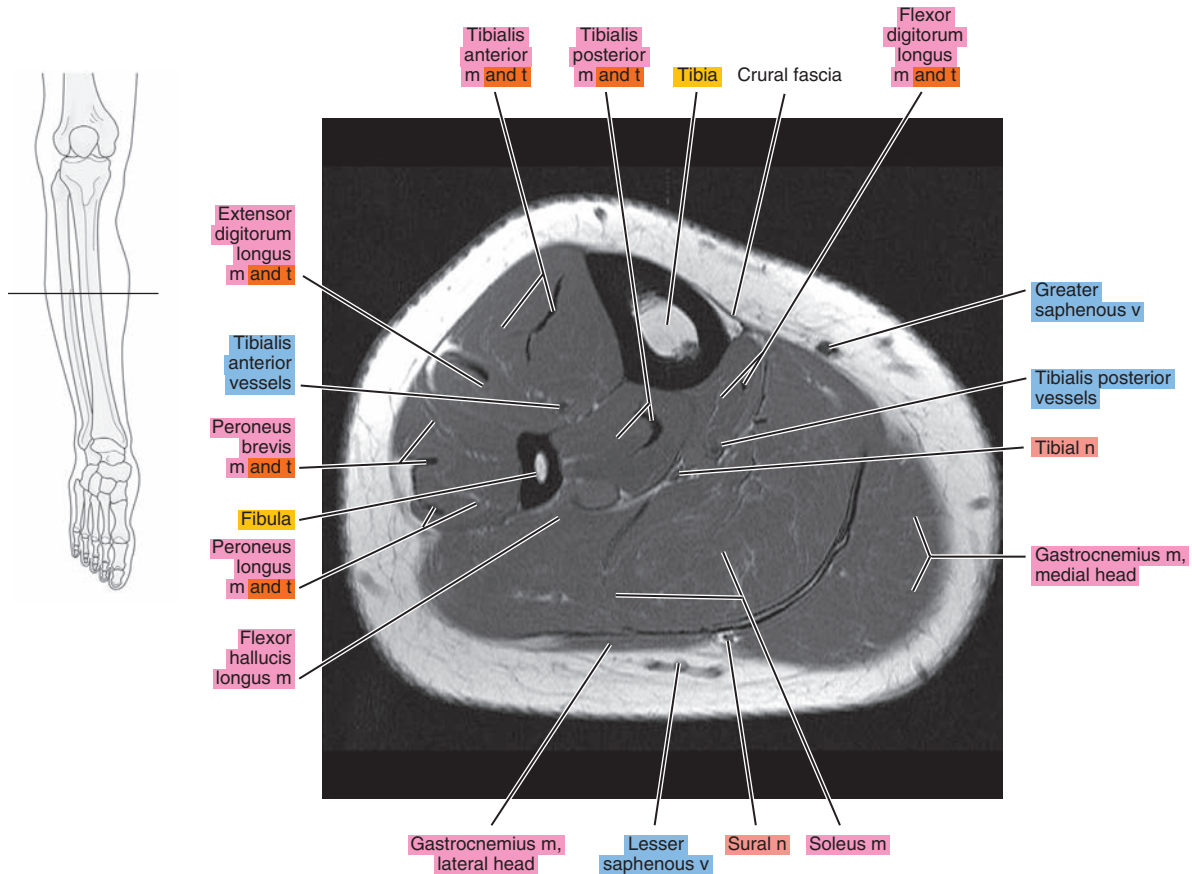


Figure 22.1.11

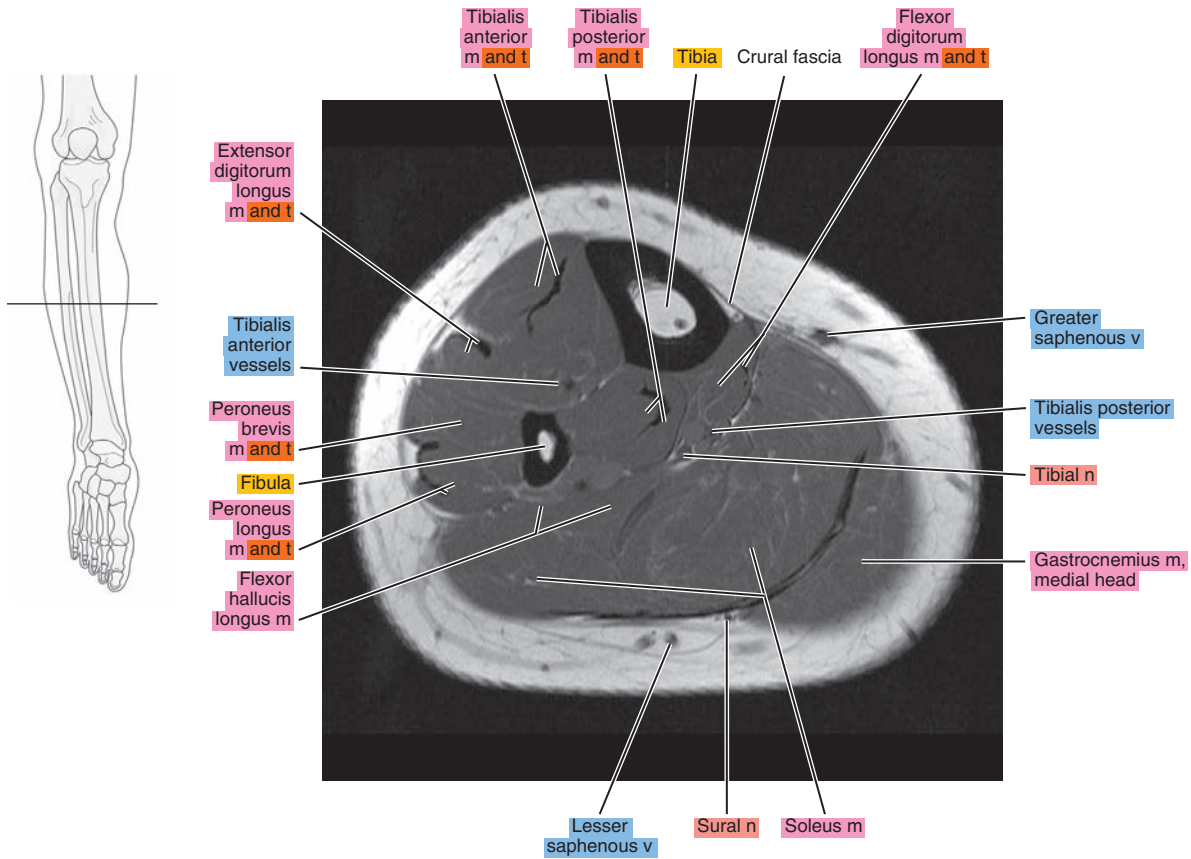


Figure 22.1.12

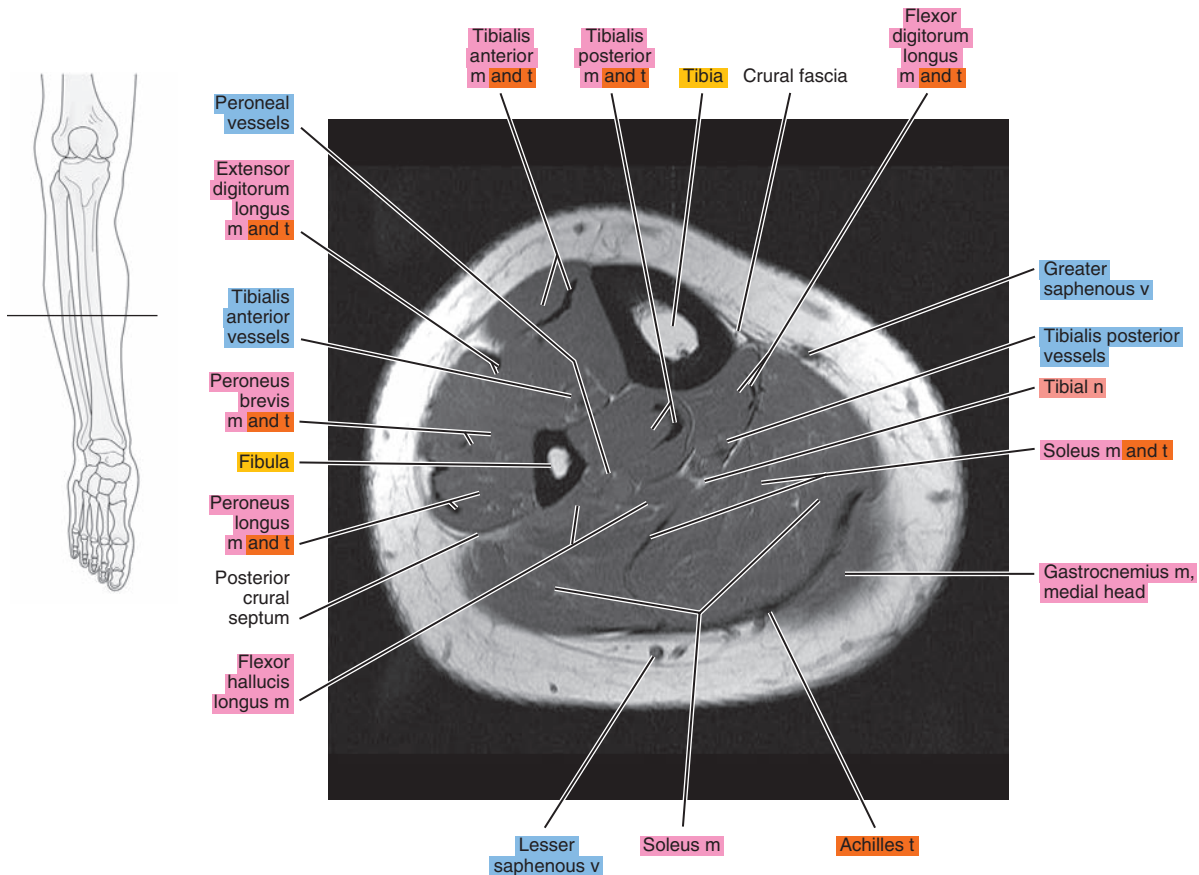


Figure 22.1.13

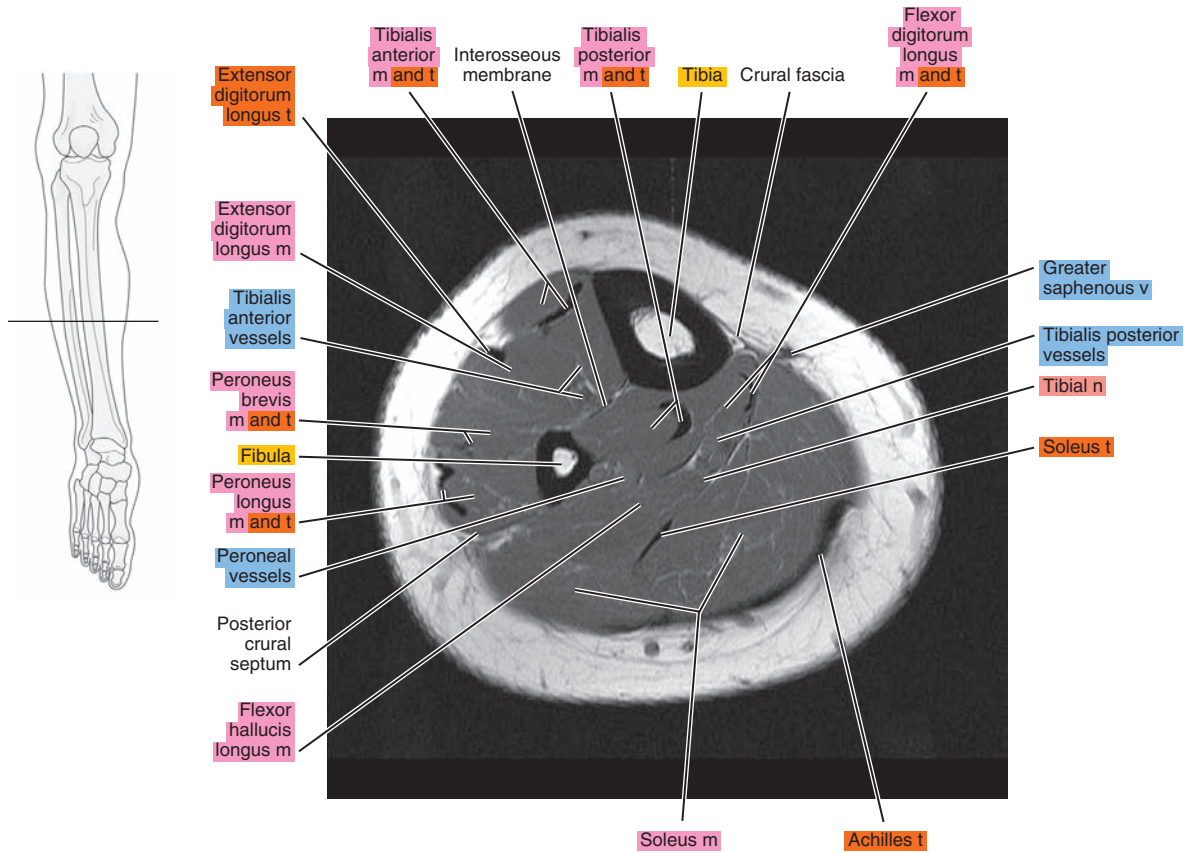


Figure 22.1.14

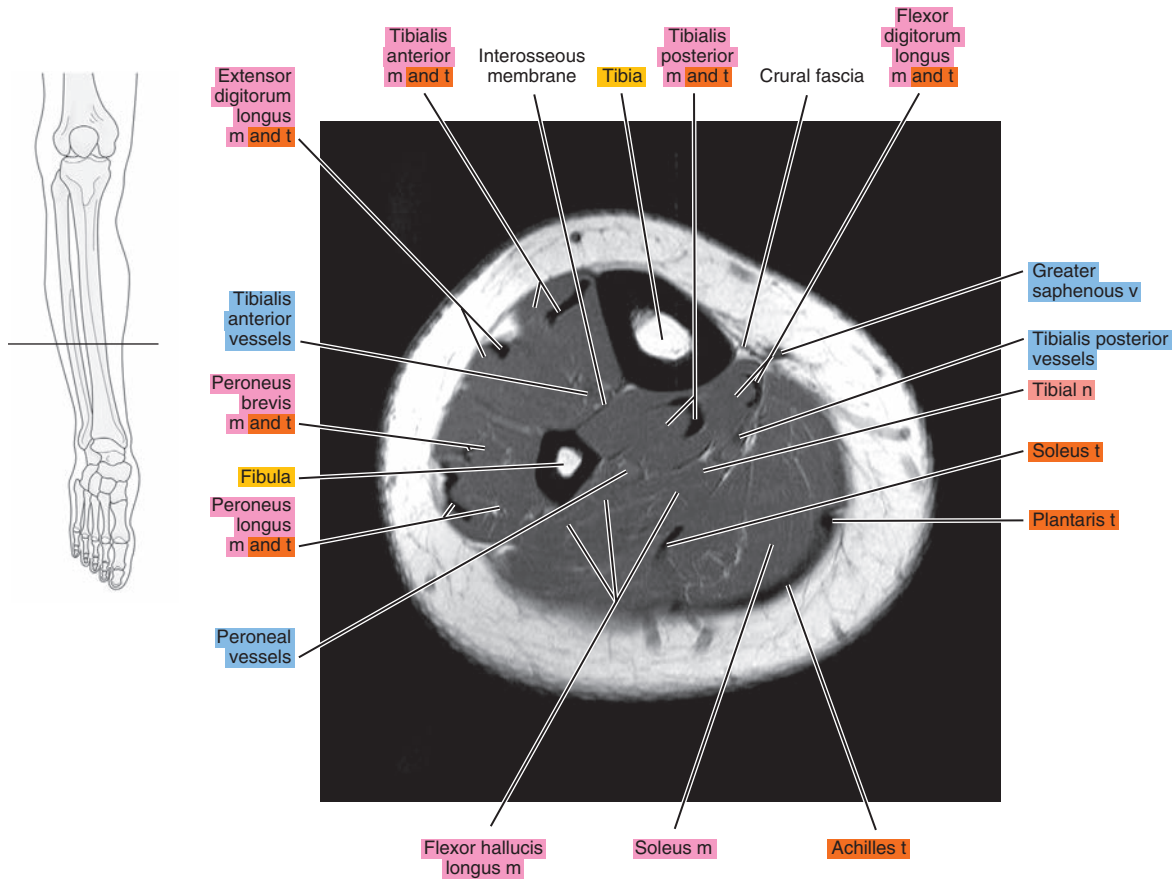




Figure 22.1.15

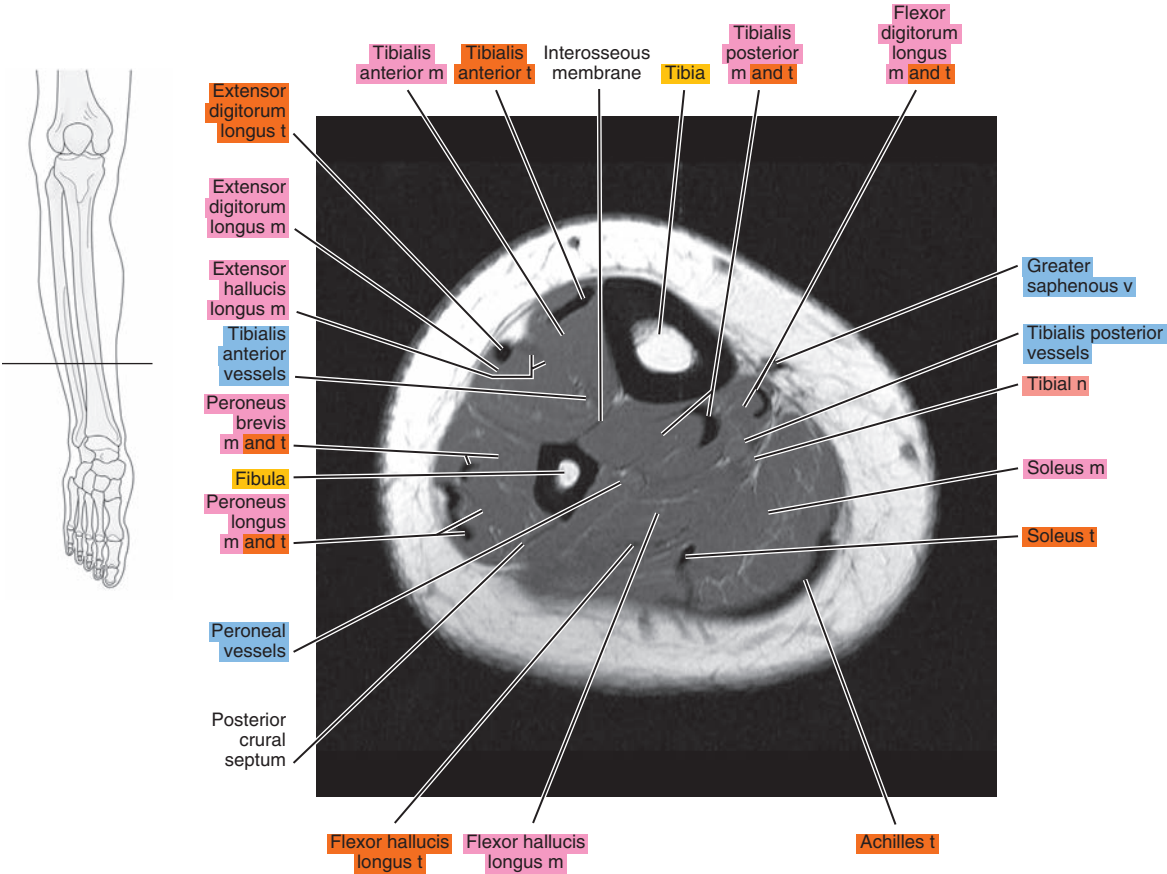


Figure 22.1.16

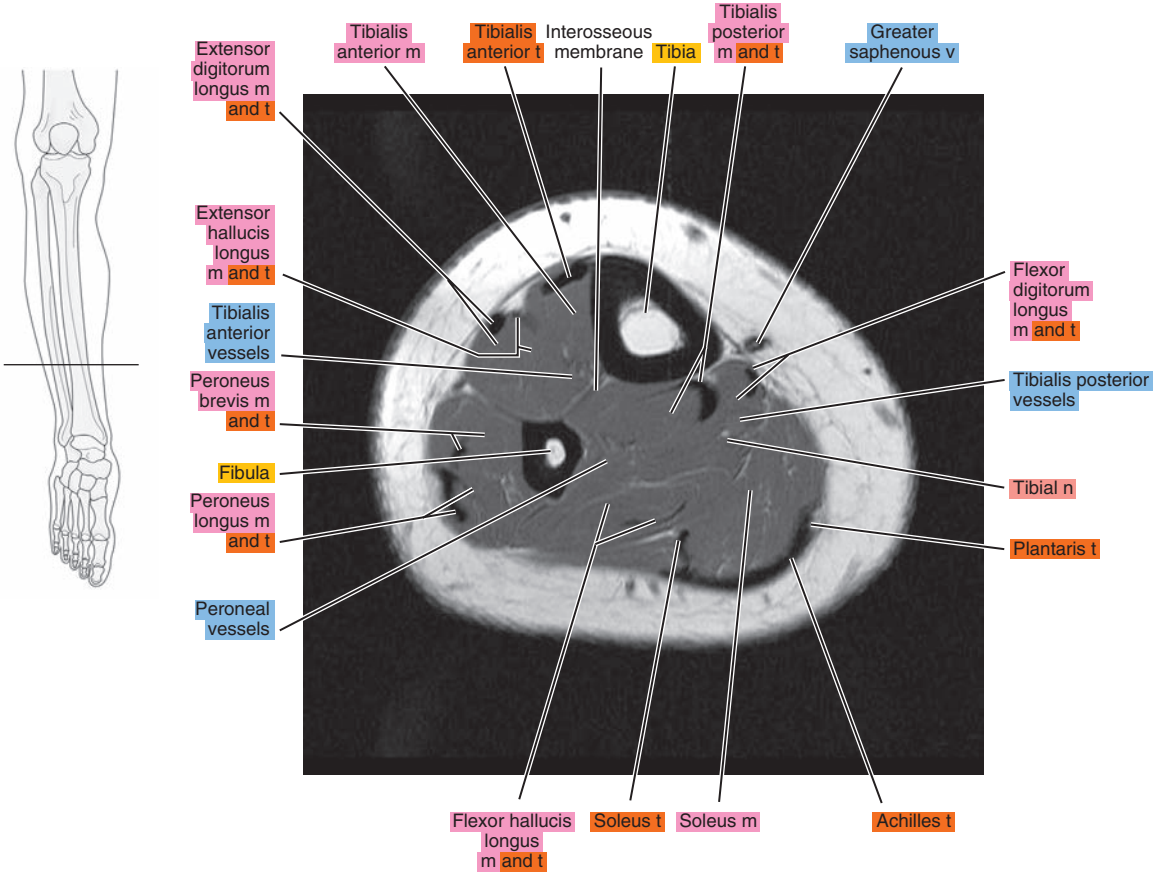




Figure 22.1.17

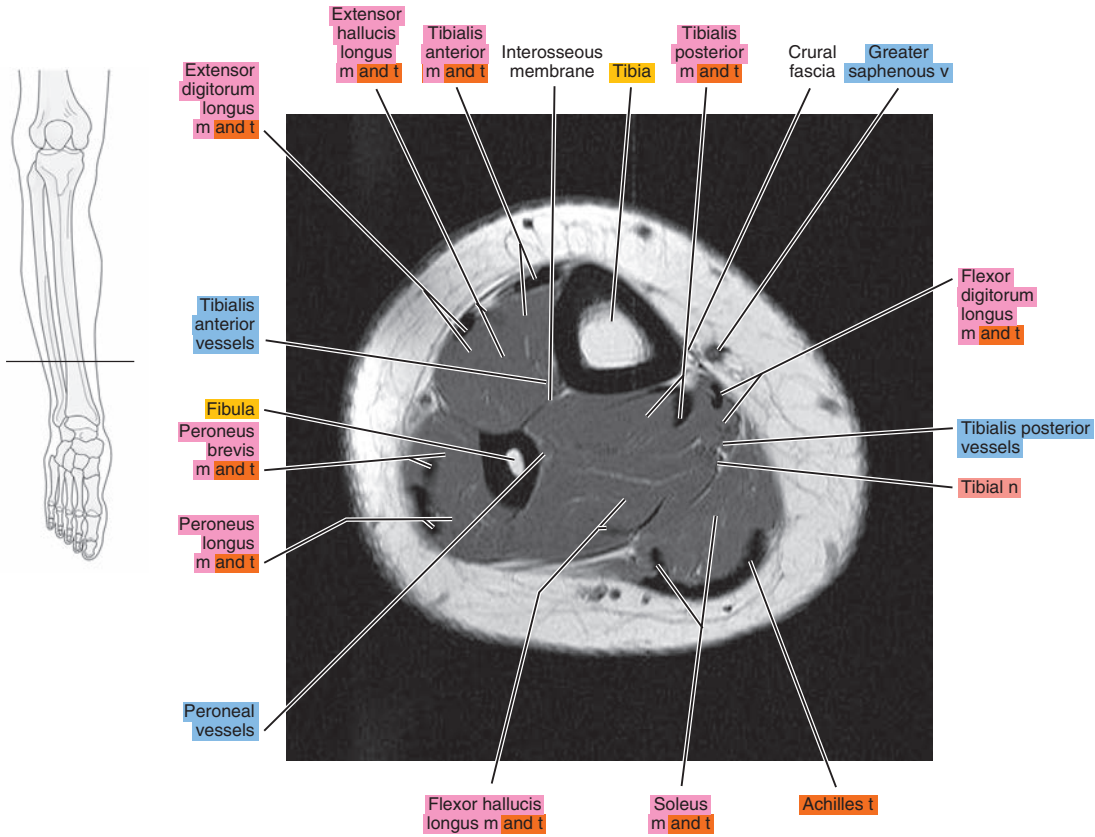


Figure 22.1.18

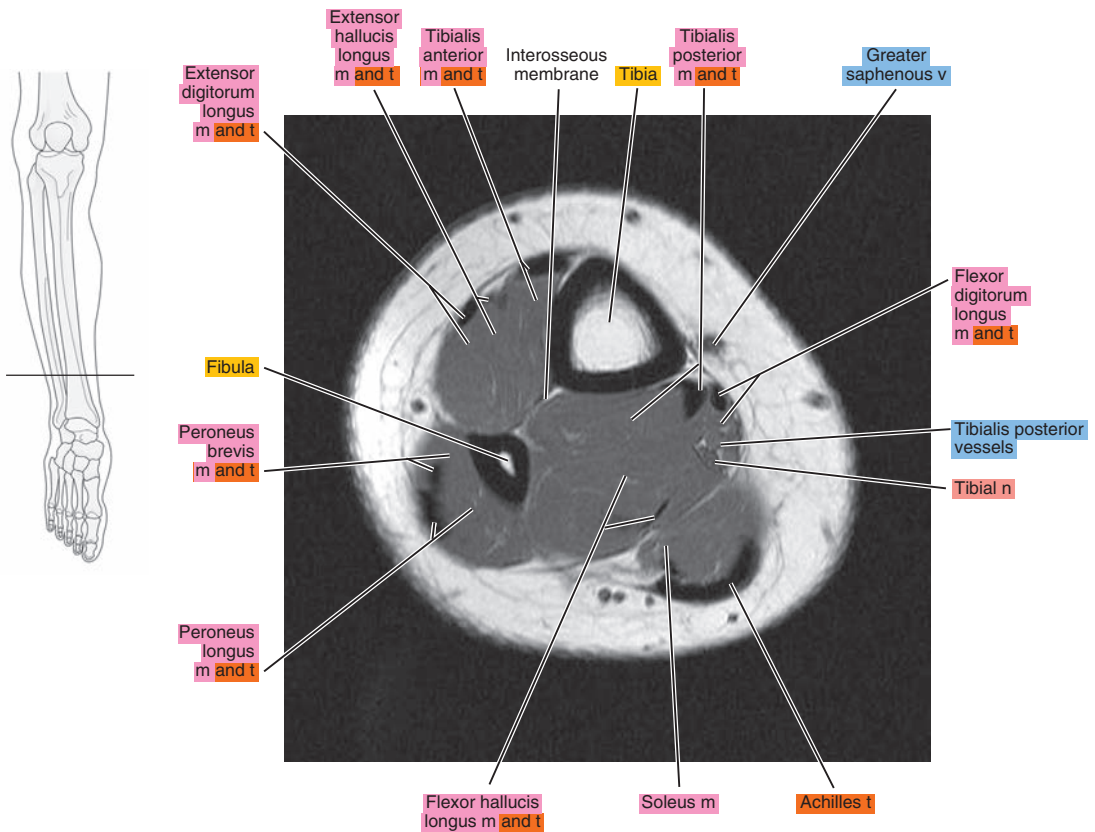


Figure 22.1.19

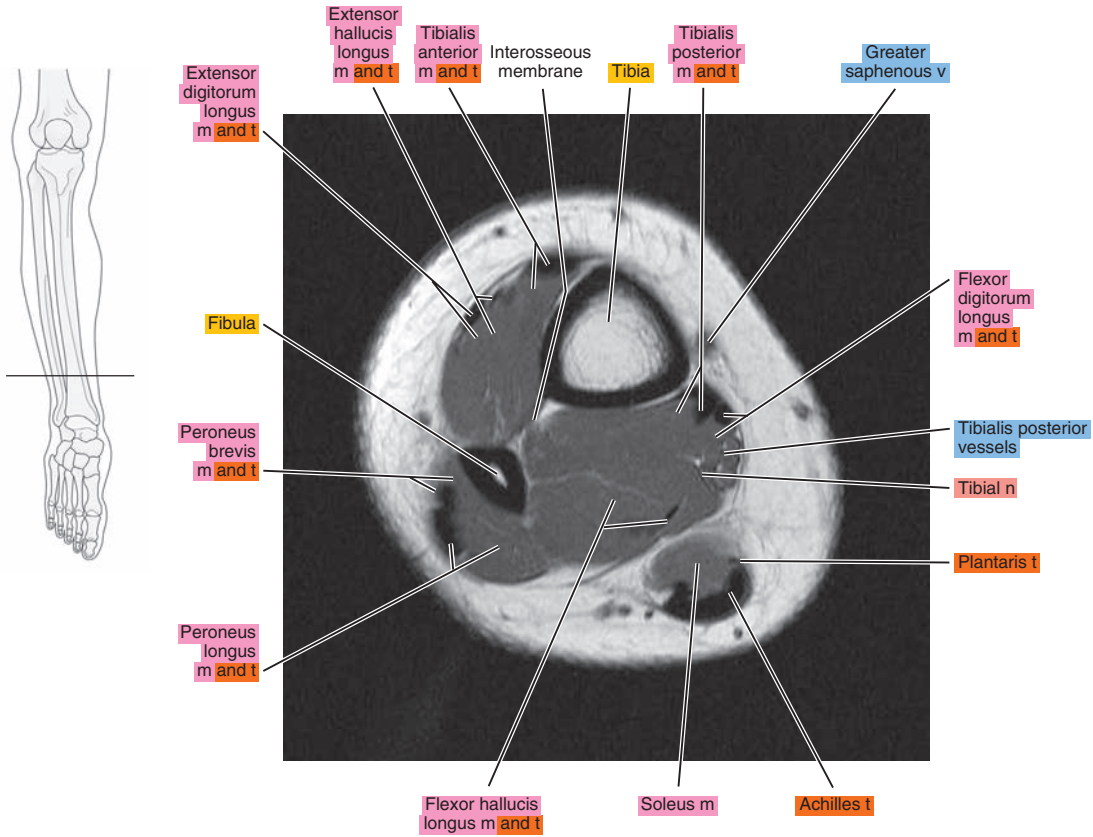
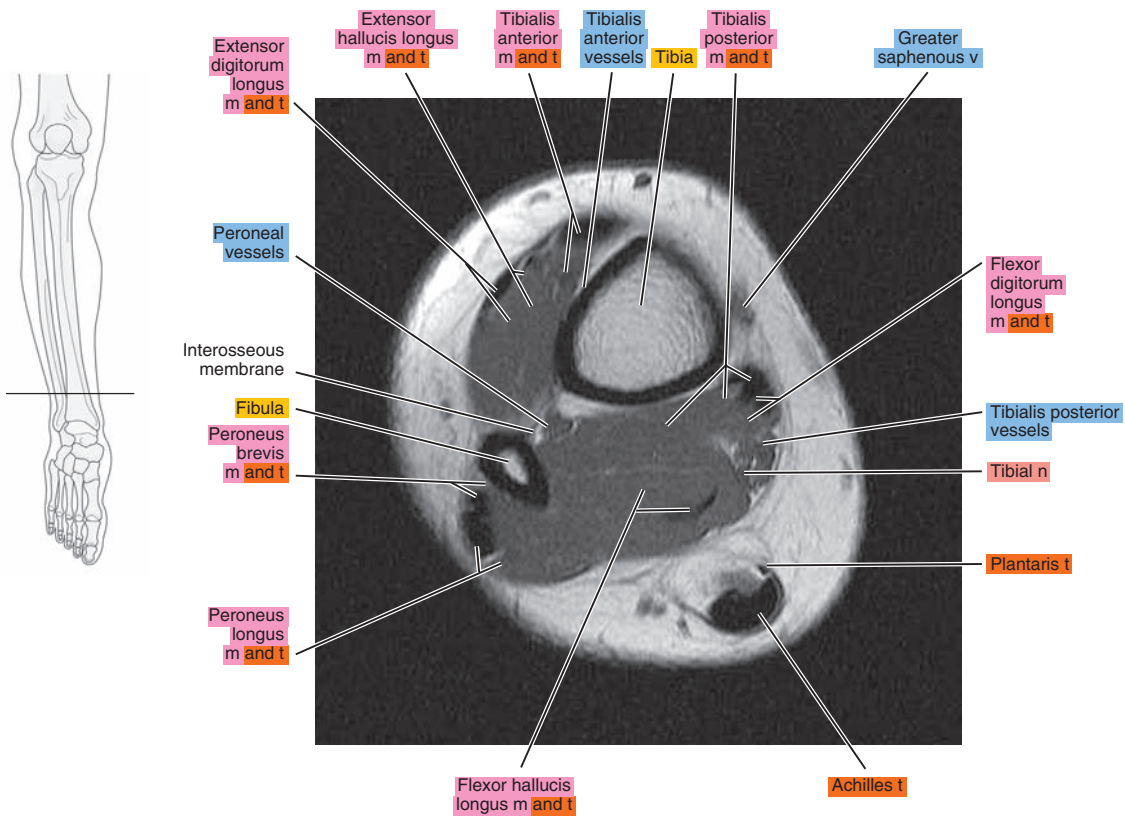


Figure 22.1.20



# SAGITTAL

Figure 22.2.1

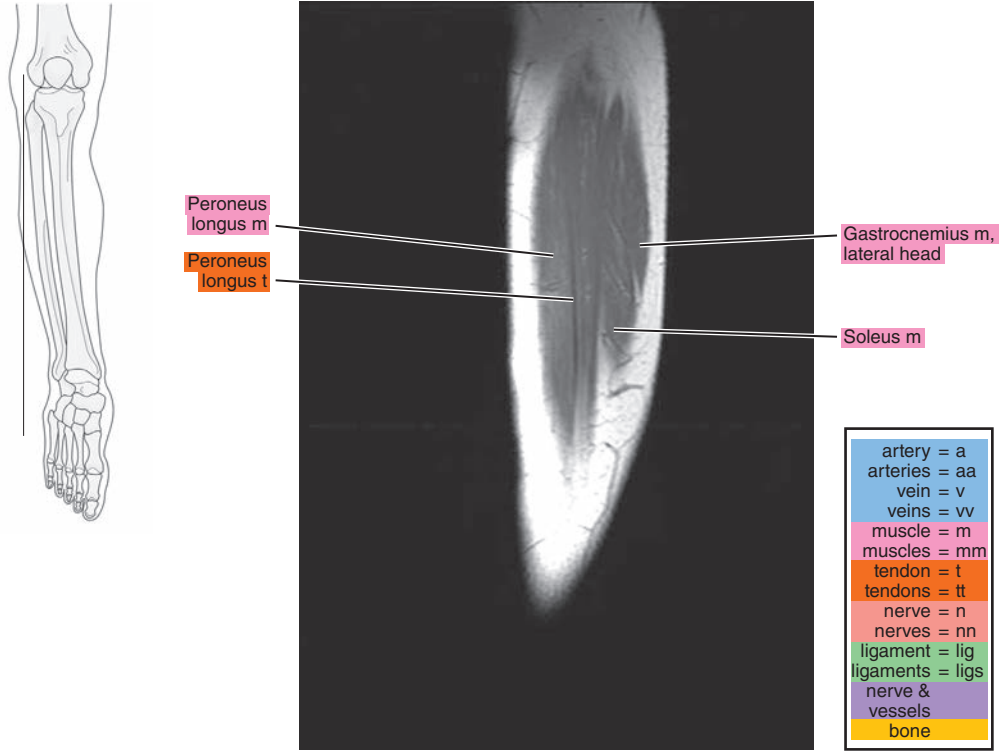


Figure 22.2.2

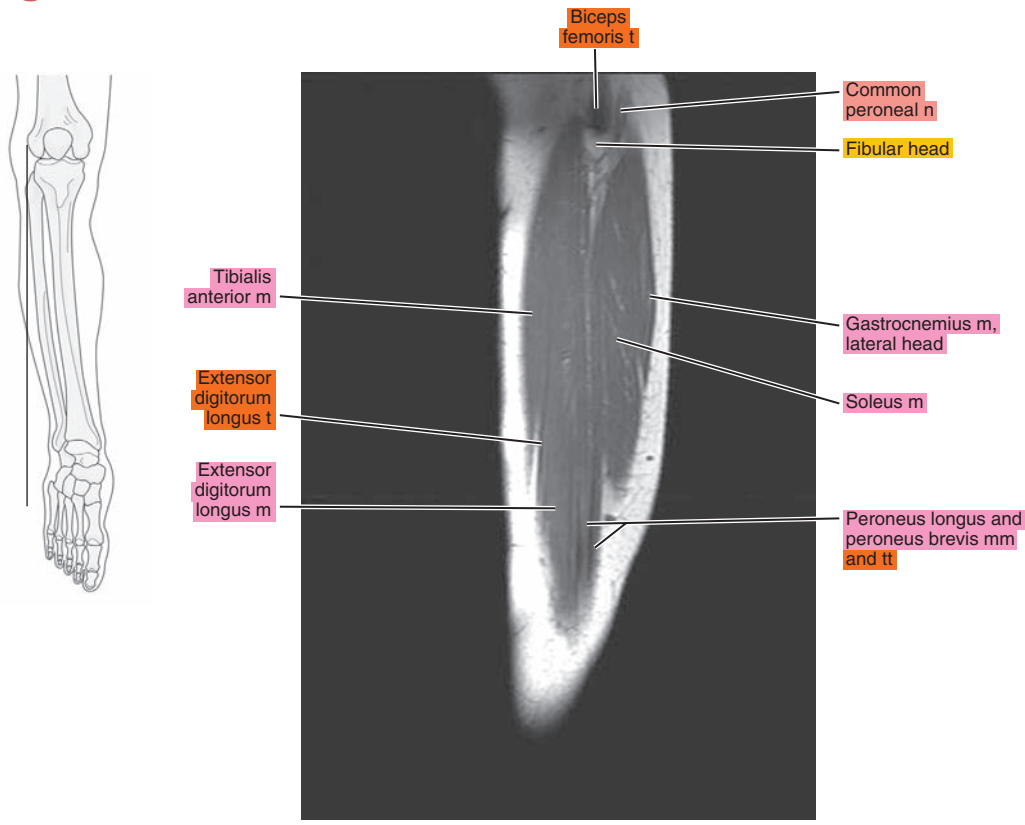


Figure 22.2.3

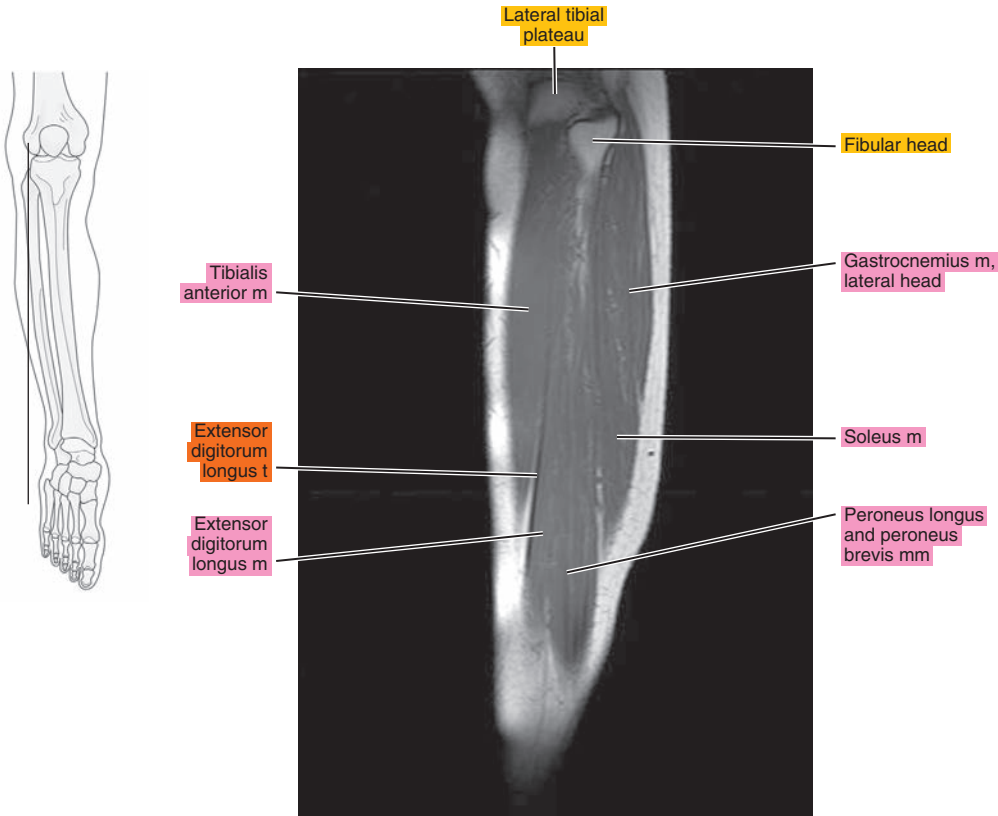


Figure 22.2.4

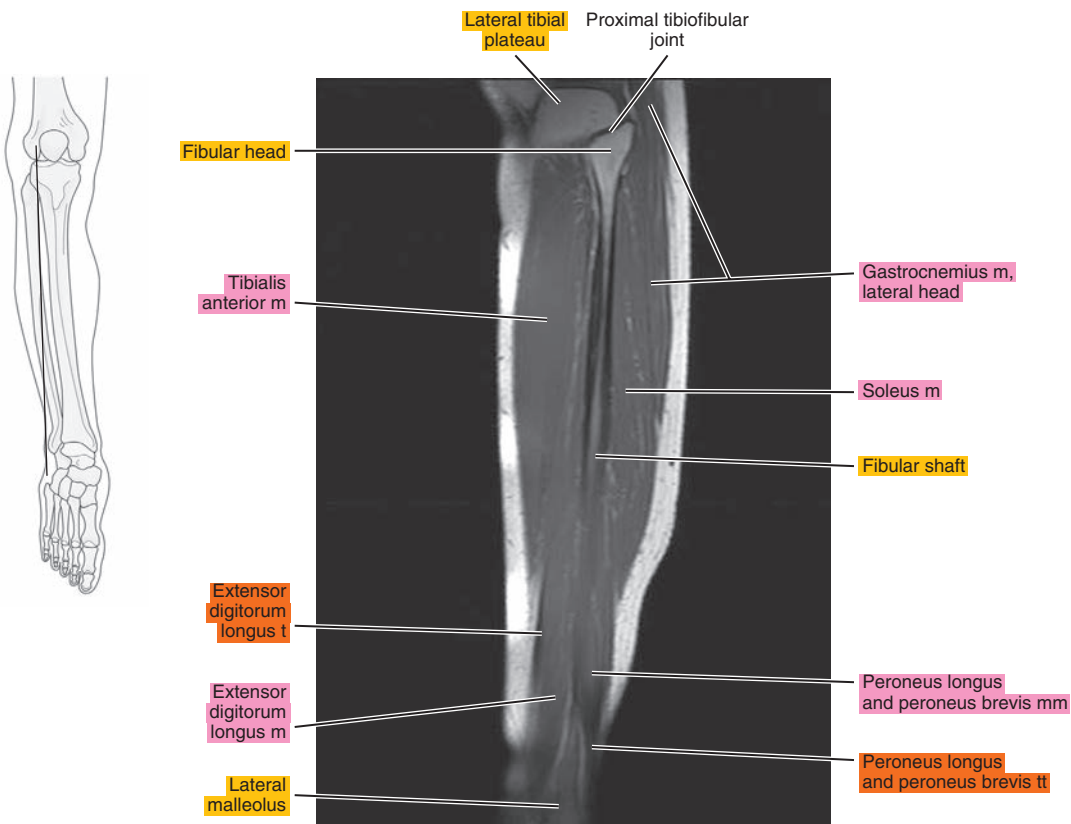




Figure 22.2.5

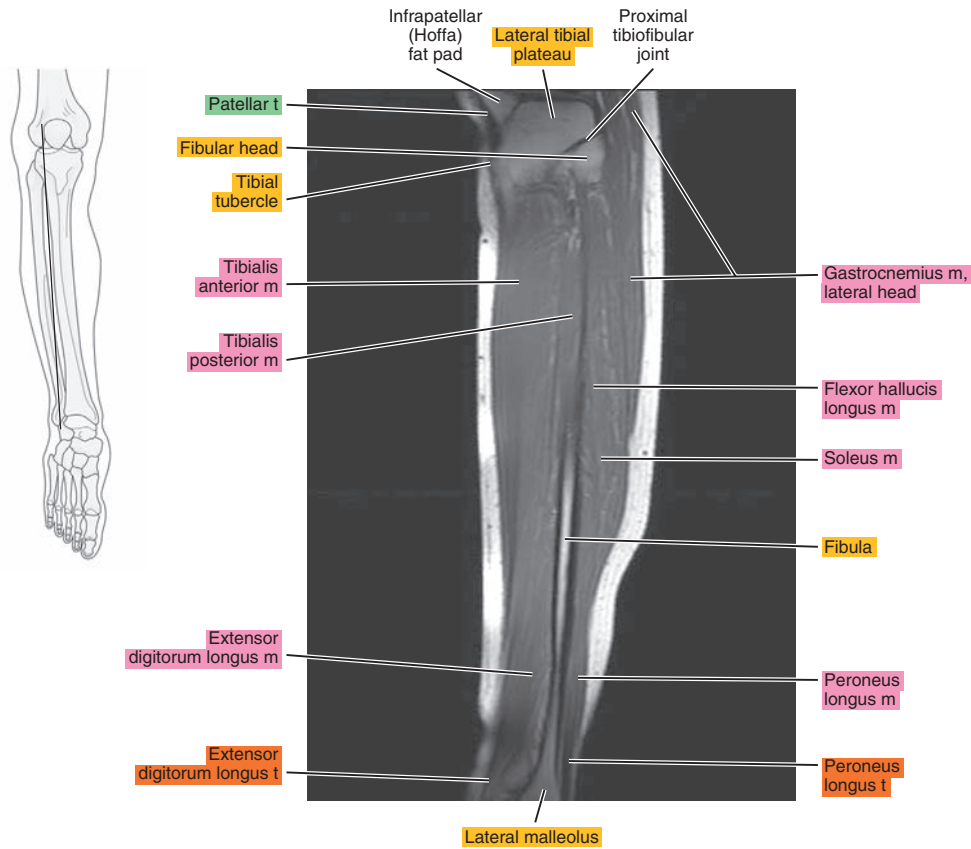


Figure 22.2.6

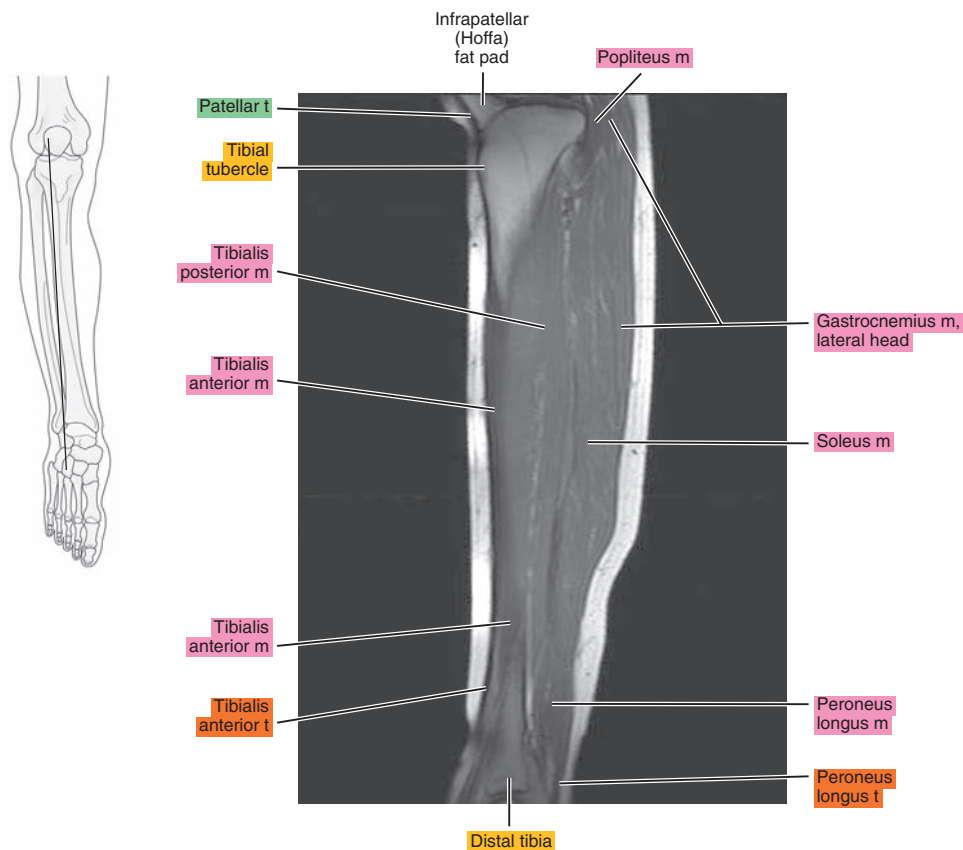


Figure 22.2.7

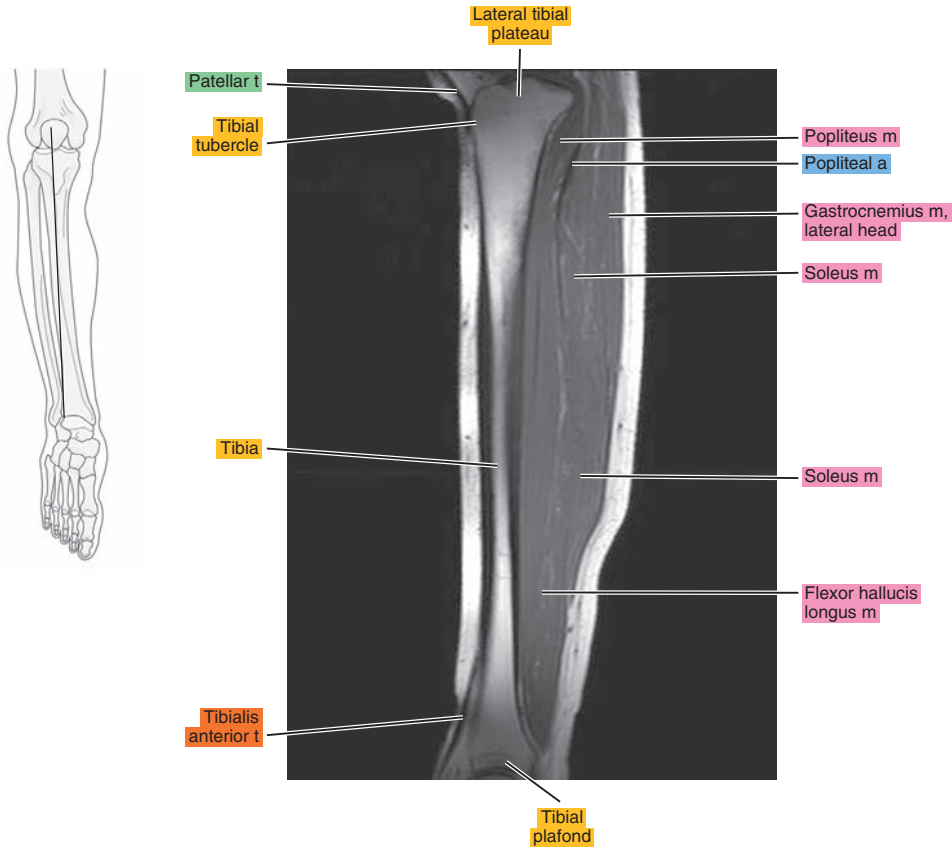


Figure 22.2.8

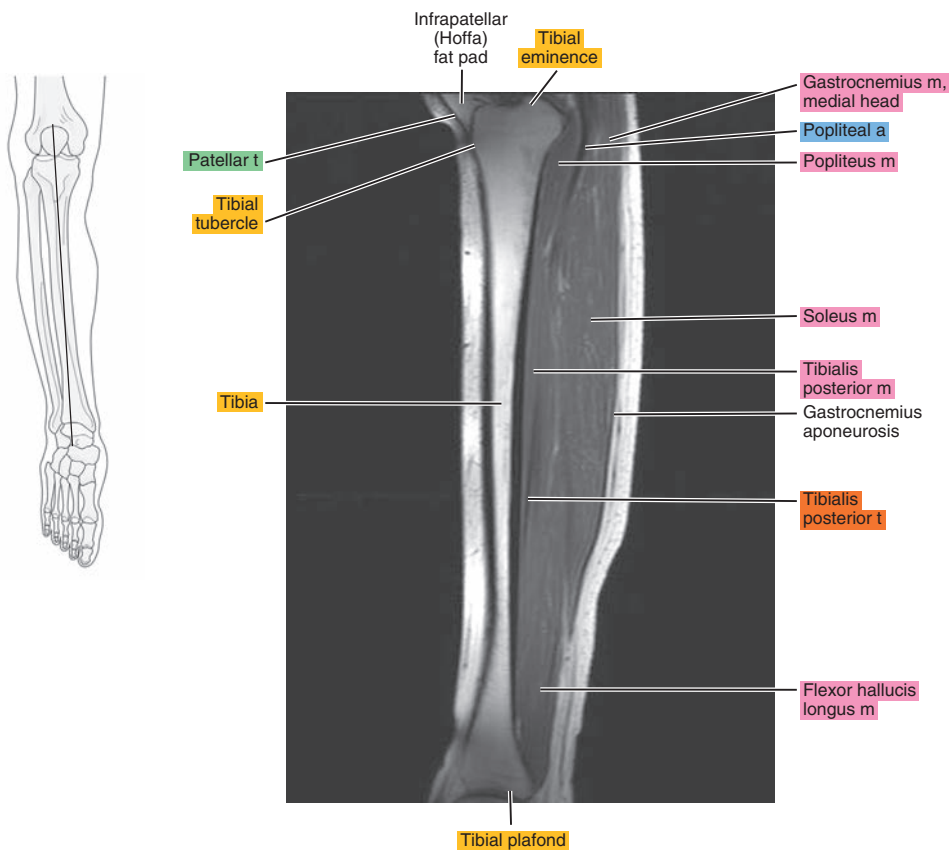


Figure 22.2.9

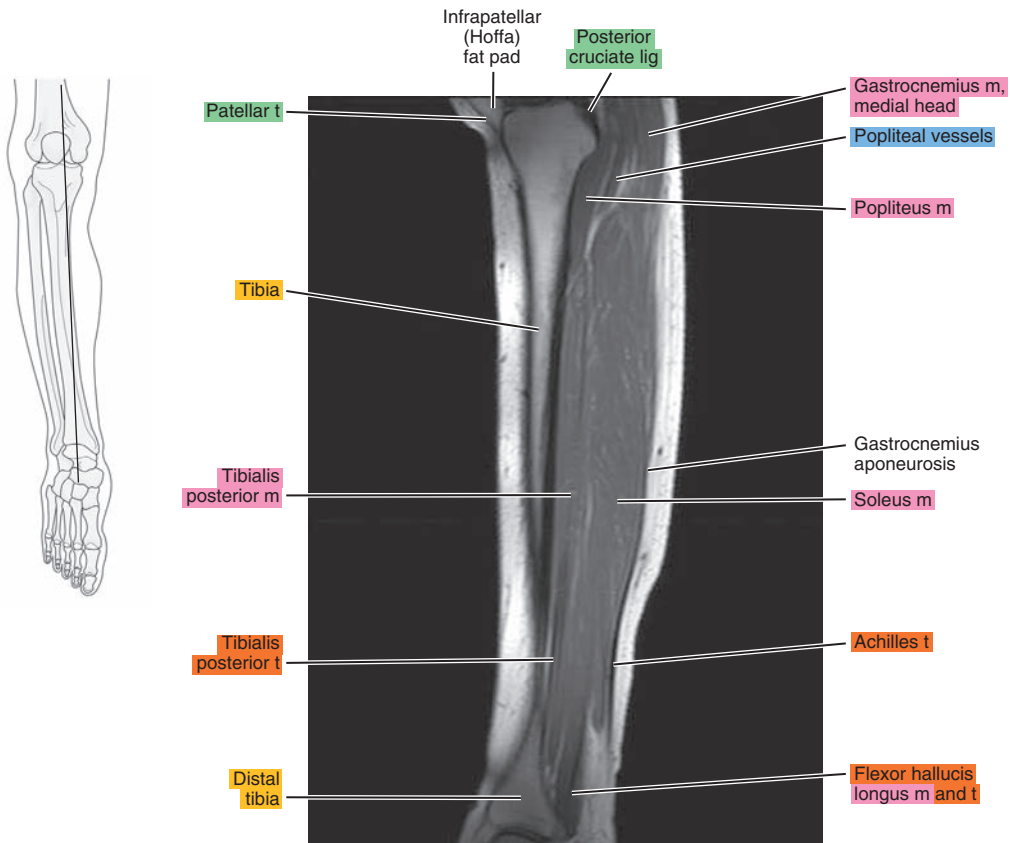


Figure 22.2.10

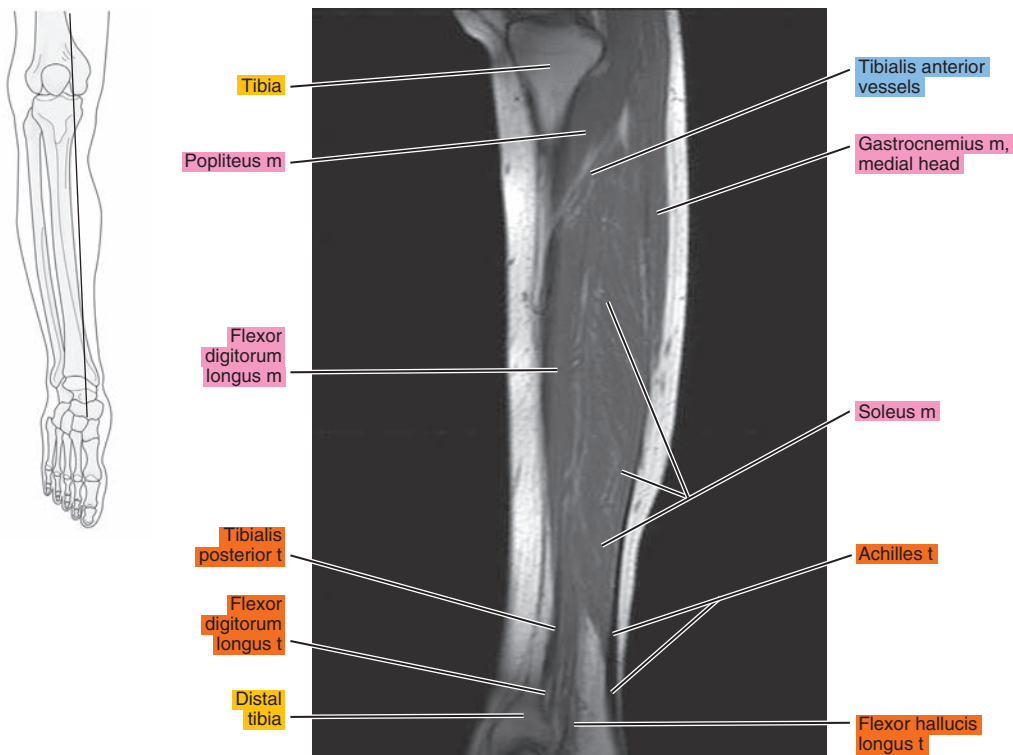


Figure 22.2.11

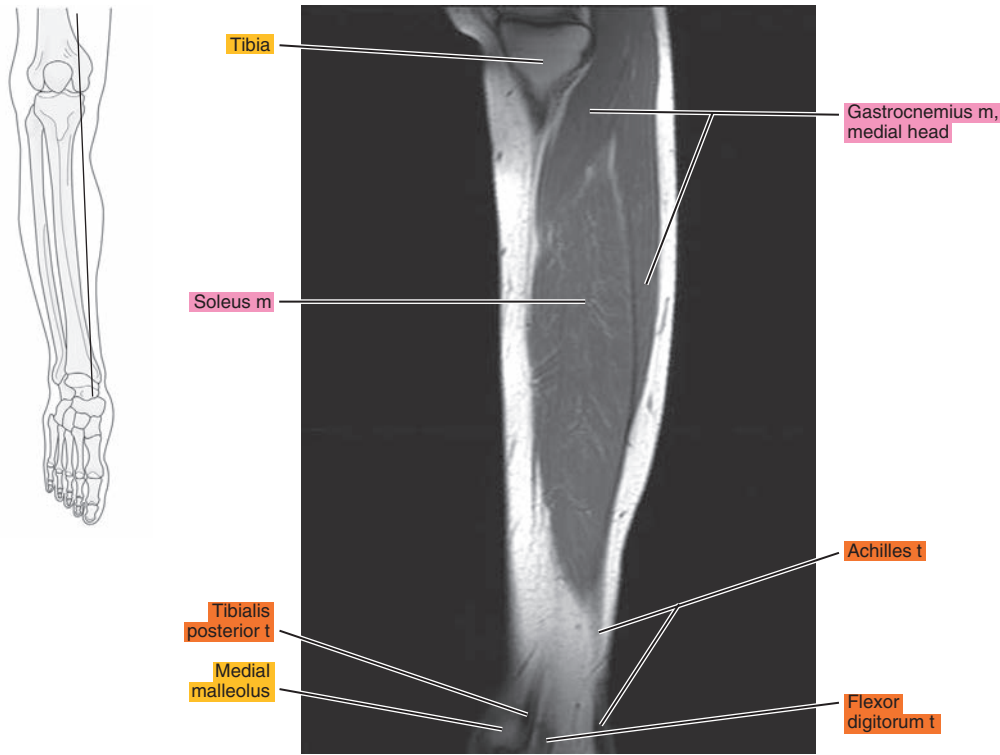


Figure 22.2.12

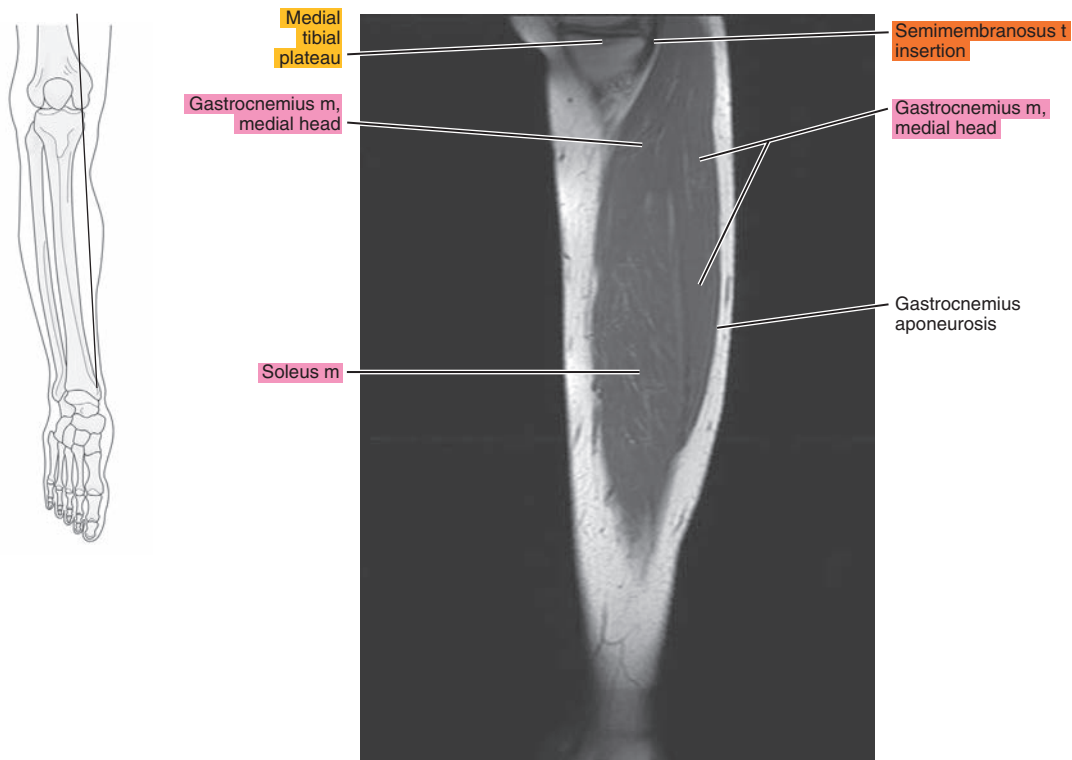




Figure 22.2.13

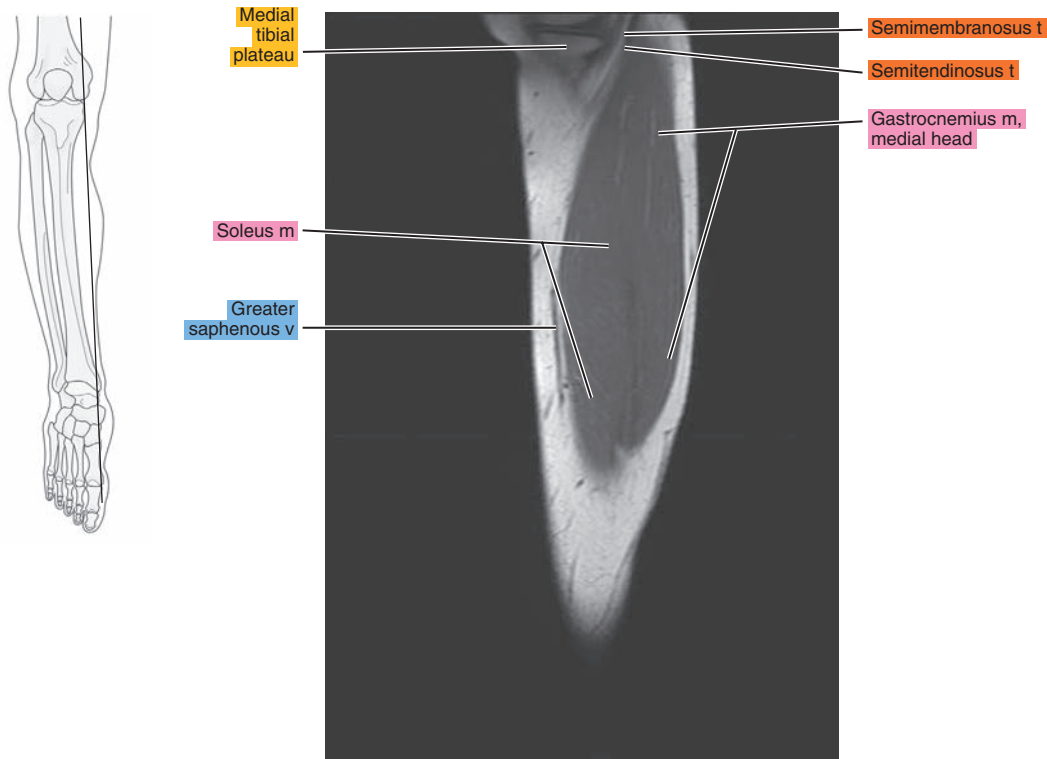


Figure 22.2.14

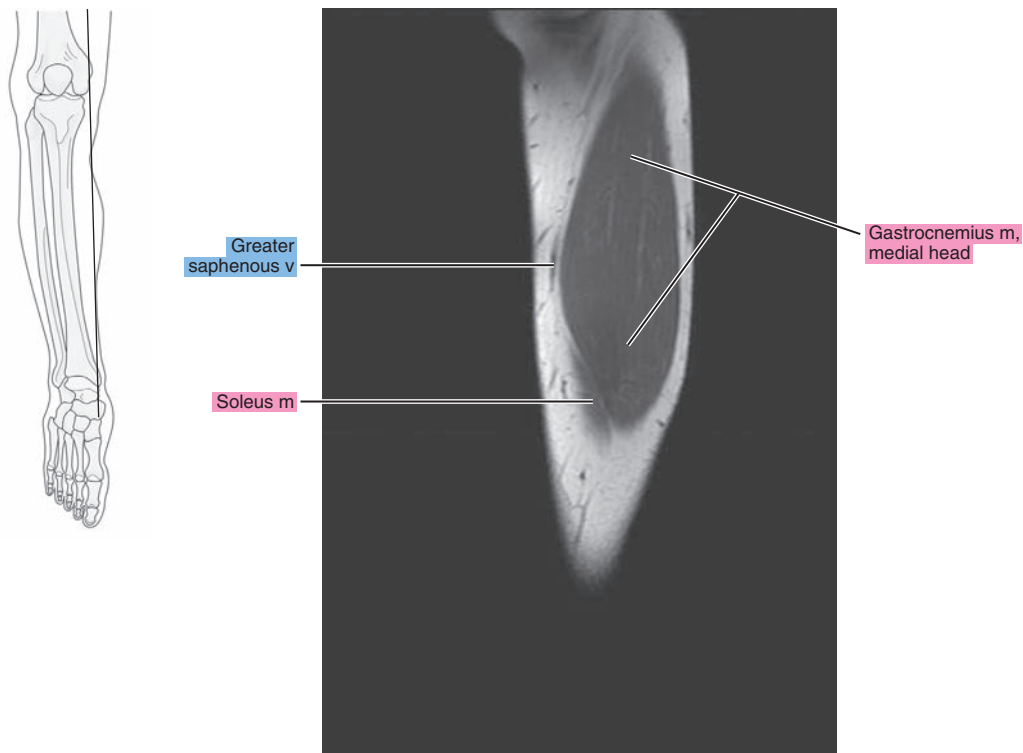
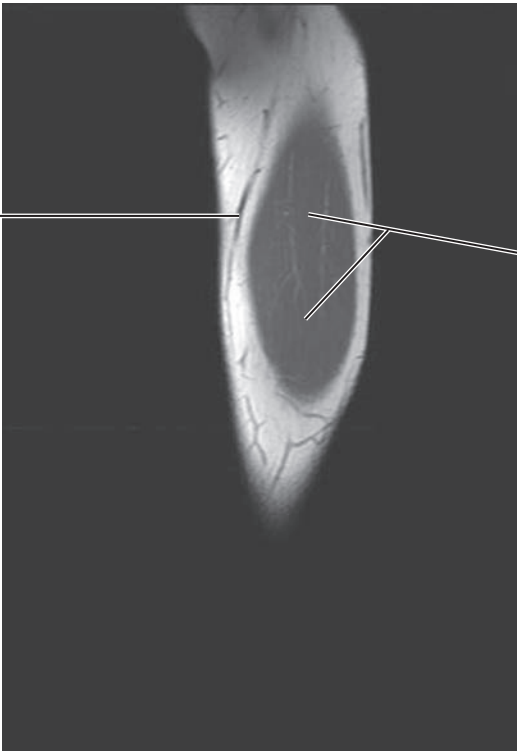


Figure 22.2.15



Greater saphenous v

Gastrocnemius m, medial head

# CORONAL

Figure 22.3.1

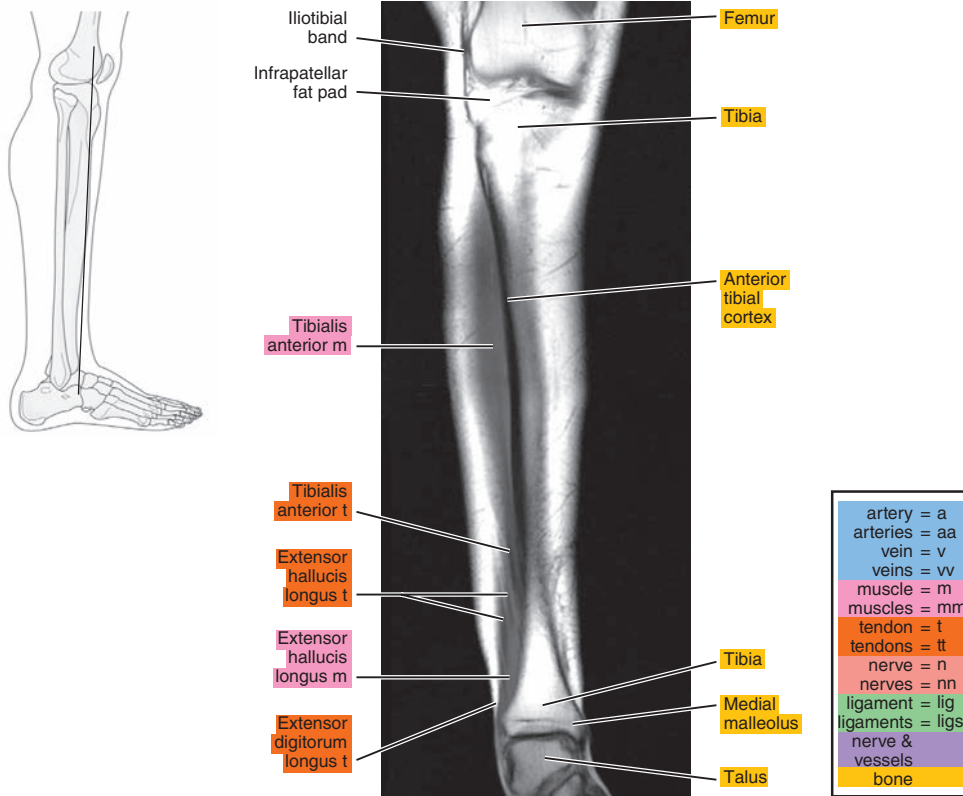


Figure 22.3.2

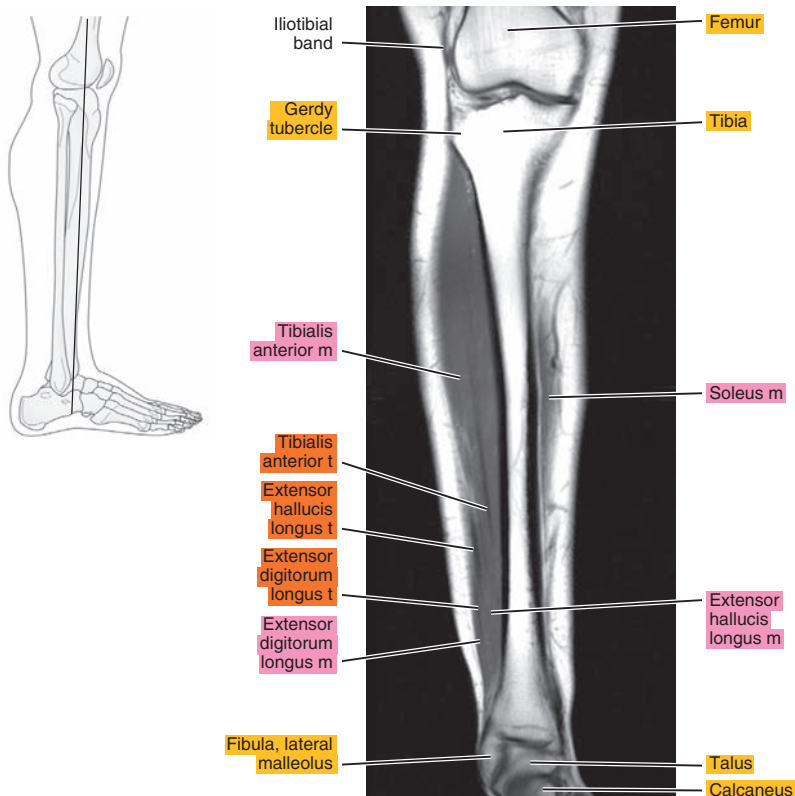


Figure 22.3.3

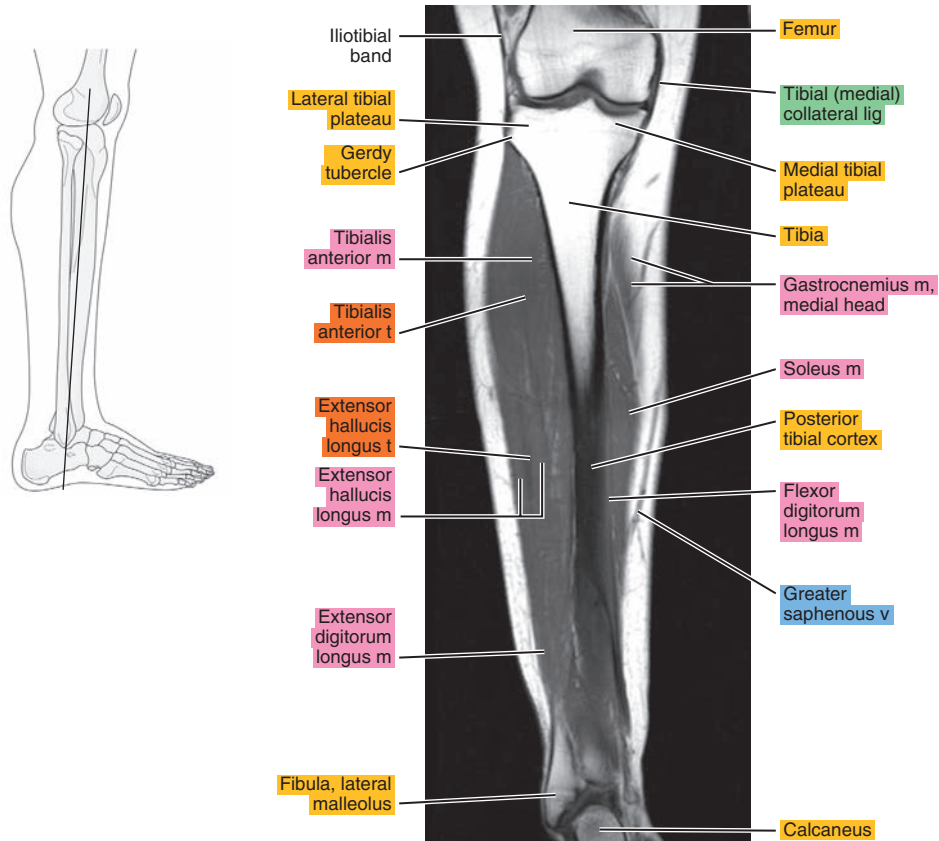


Figure 22.3.4

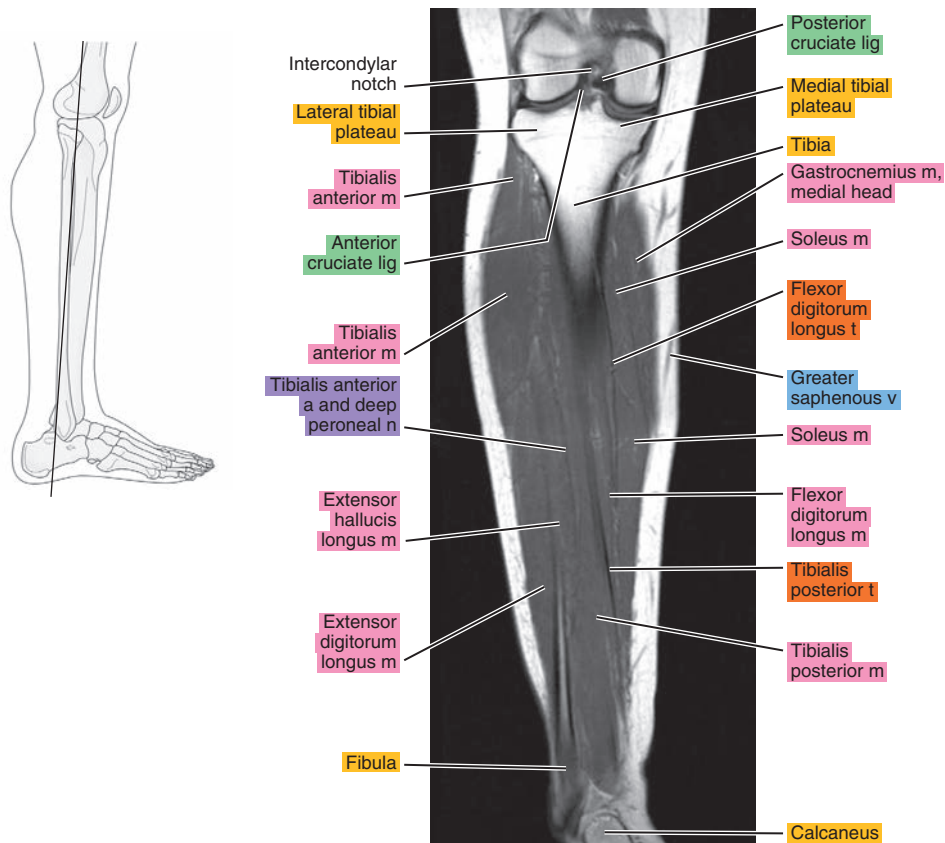




Figure 22.3.5

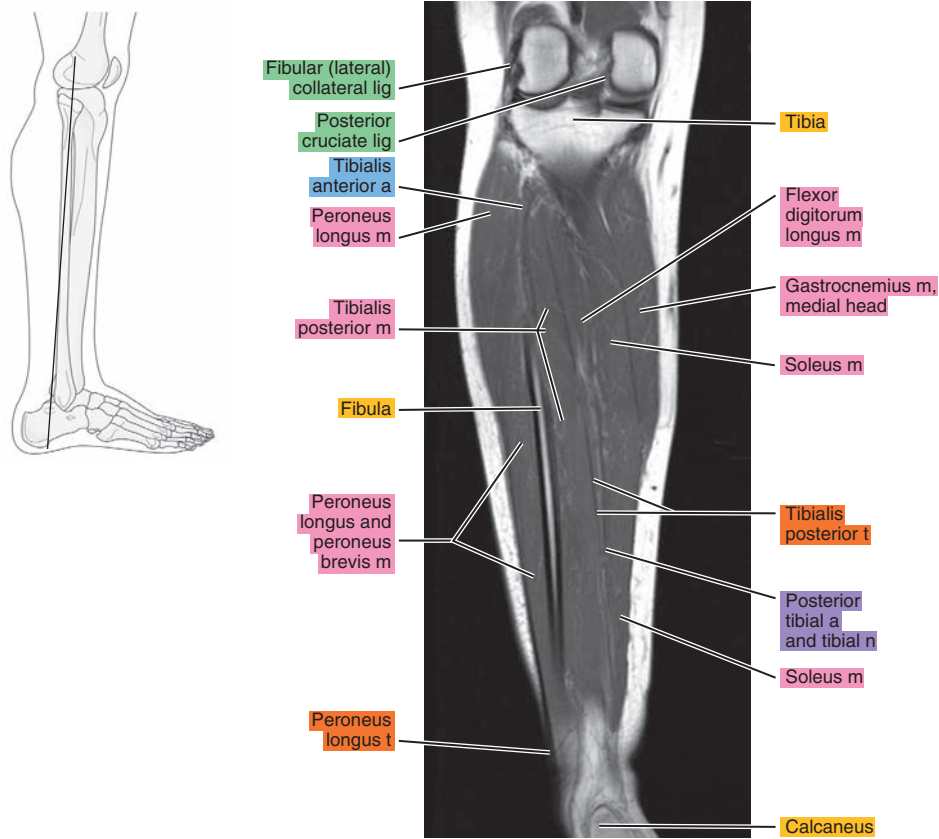


Figure 22.3.6

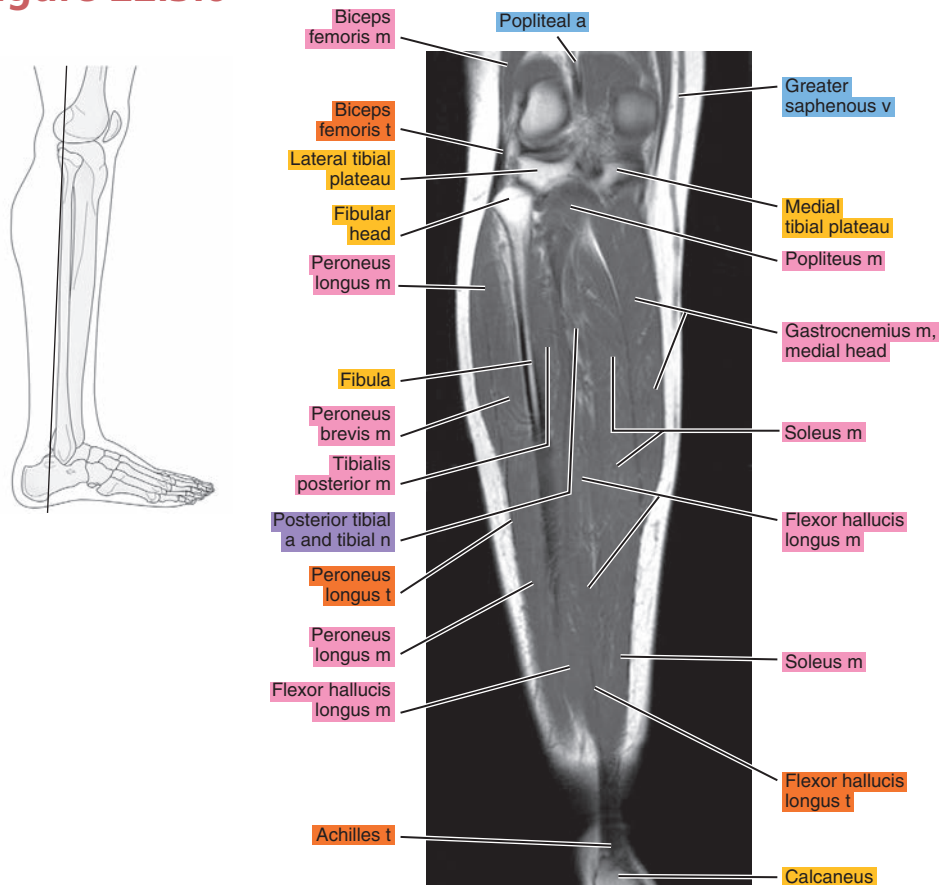


Figure 22.3.7

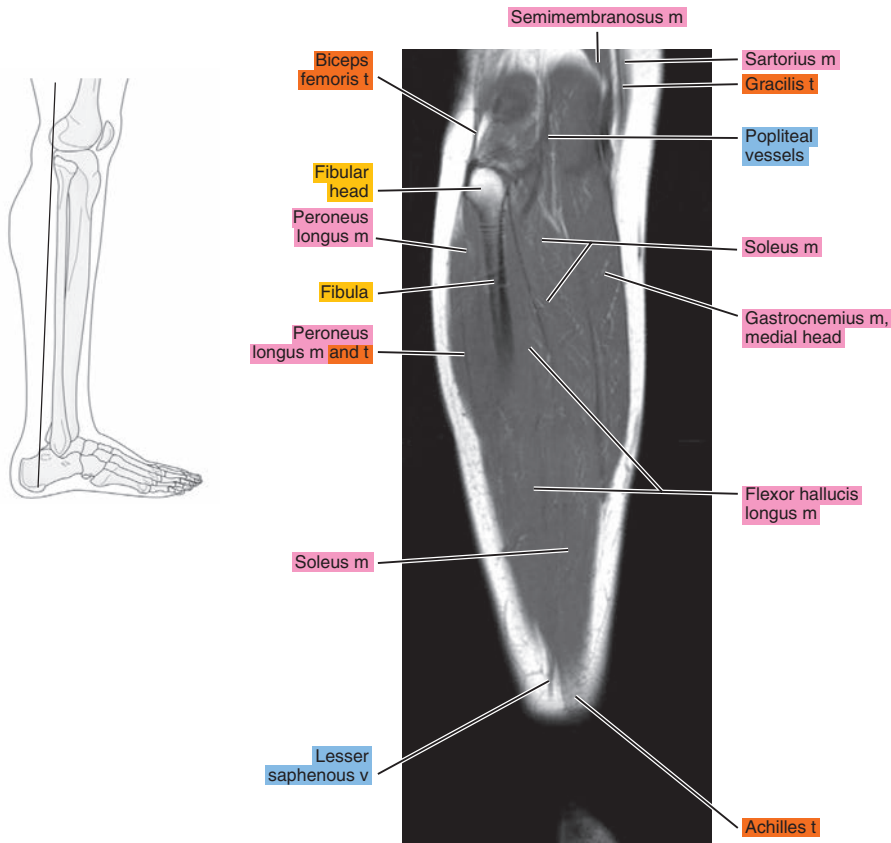


Figure 22.3.8

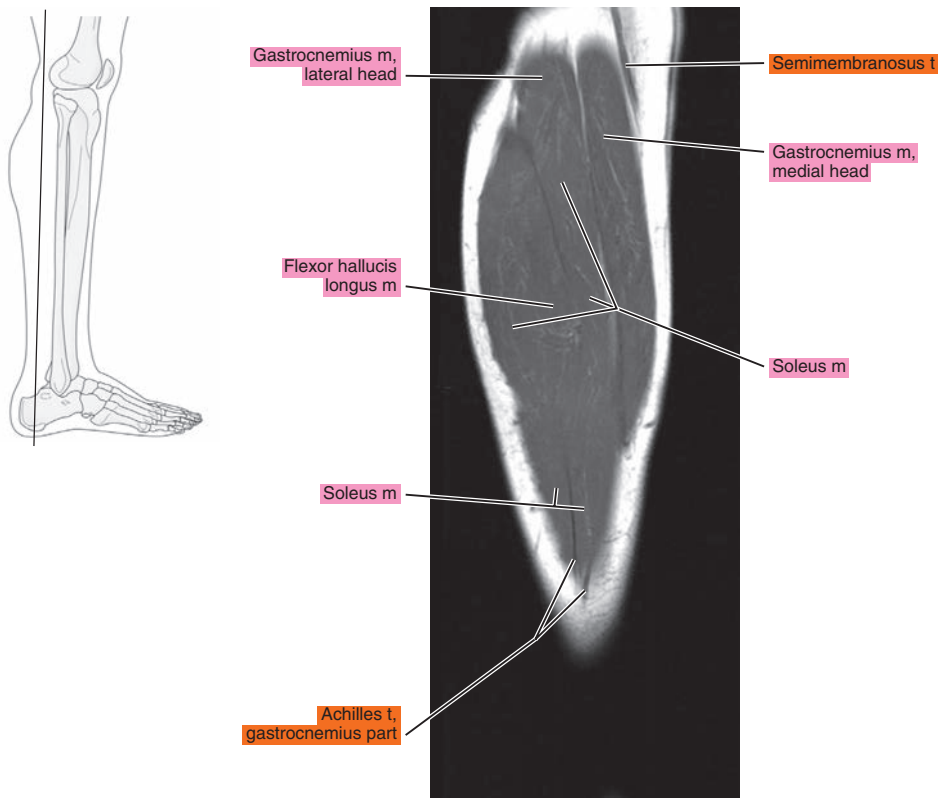


Figure 22.3.9

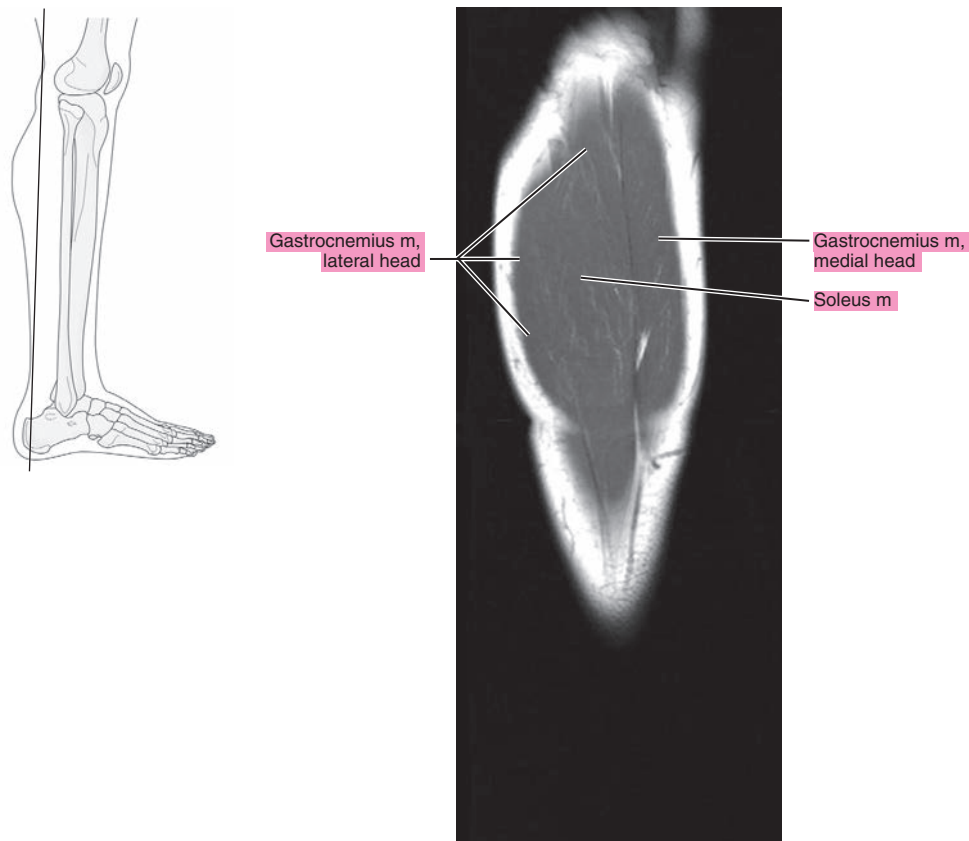


Figure 22.3.10

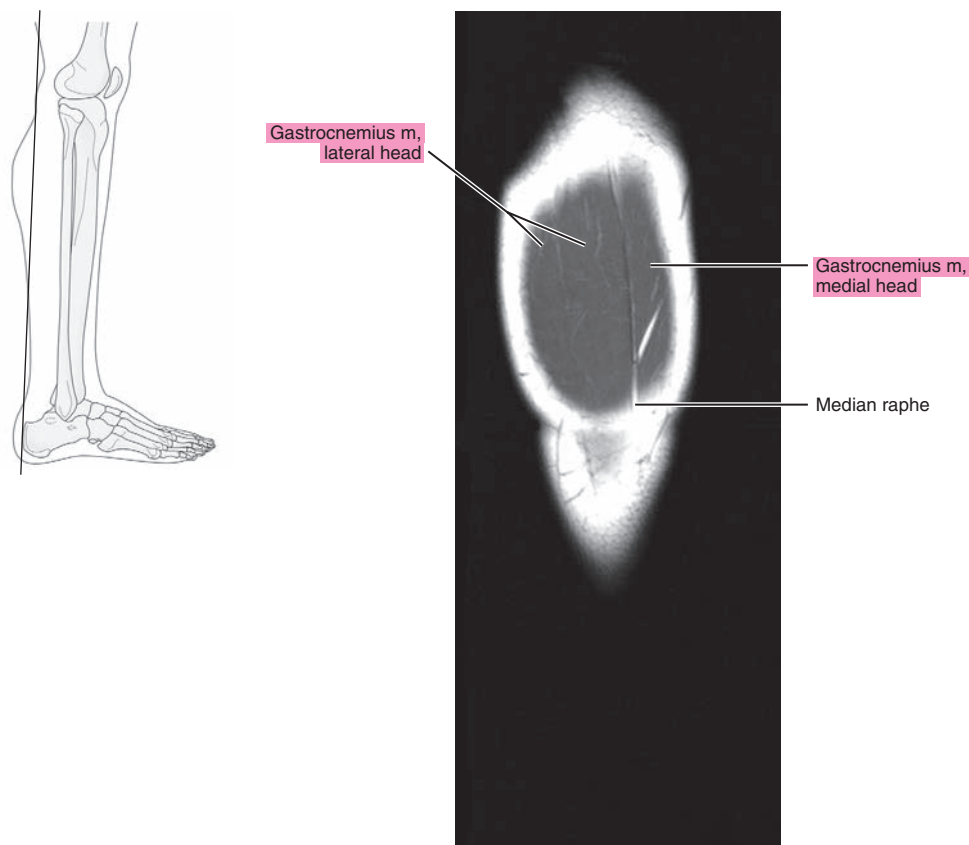


Figure 22.3.11

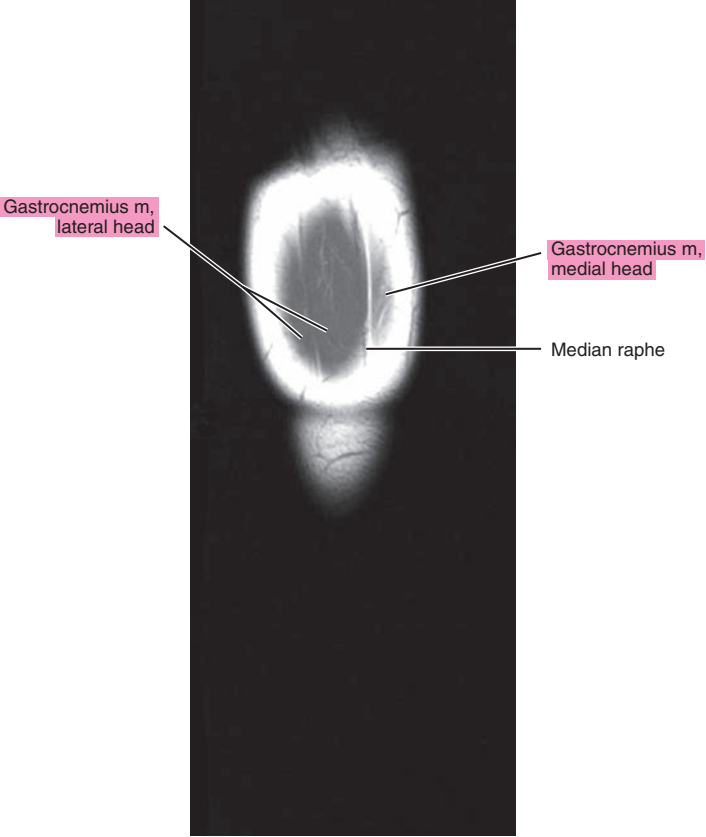
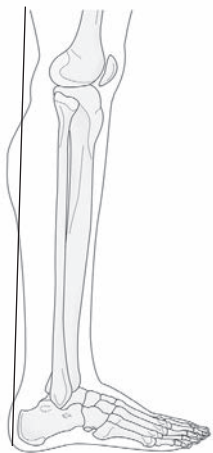



Table 22-1. Muscles of the Leg

MUSCLE	ORIGIN	INSERTION	NERVE SUPPLY
<b>Tibialis anterior</b>	Distal part of the lateral condyle of the tibia, lateral surface of the proximal half of the shaft of the tibia, adjacent interosseous membrane, overlying fascia near the condyle of the tibia, and intermuscular septum between it and the extensor digitorum longus	Medial surface of the first cuneiform and the base of the first metatarsal.	Branch from the common peroneal and another from the deep peroneal
<b>Extensor digitorum longus</b>	Lateral condyle of the tibia, anterior crest of the fibula intermuscular membrane between it and the tibialis anterior, lateral margin of the interosseous membrane, the septum between it and the peroneus longus, and fascia of the leg near the tibial origin	Each tendon, located on the dorsal surface of the toe to which it goes, divides into three fasciculi: the intermediate, attached to the dorsum of the base of the middle phalanx, and two lateral, which converge to the dorsum of the base on the distal phalanx. The margins of each tendon are bound to the sides of the back of the proximal phalanx.	By two branches of the deep peroneal
<b>Peroneus tertius</b>	Distal one-third of the anterior surface of the fibula, neighboring interosseous membrane, and anterior intermuscular septum	Onto the base of the fifth metatarsal and often onto the base of the fourth.	The more distal nerve to the extensor digitorum supplies this muscle (deep peroneal)
<b>Extensor hallucis longus</b>	Middle half of the anterior surface of the fibula near the interosseous crest and distal half of the interosseous membrane	At the base of the dorsal aspect of the great toe.	Deep peroneal
<b>Peroneus longus</b>	Proximal two-thirds of the lateral surface of the fibula	Inferior surface of the first cuneiform and on the adjacent part of the inferolateral border and the base of the first metatarsal.	Usually, the common peroneal, sometimes partially by superficial peroneal
<b>Peroneus brevis</b>	Middle one-third of the lateral surface of the fibula, from the septum that separates it from the anterior and posterior groups of muscles	Dorsal aspect of the tuberosity of the fifth metatarsal.	Superficial peroneal or a branch to peroneus longus
<b>Popliteus</b>	Facet at the anterior end of the groove on the lateral aspect of the femoral condyle	Proximal lip of the popliteal line of the tibia and the shaft of the tibia proximal to this line.	Tibial: a branch that arises independently or with the nerve to the posterior tibial muscle
<b>Flexor digitorum longus</b>	Popliteal line, medial side of the second quarter of the dorsal surface of the tibia, fibrous septum between the muscle and the tibialis fascia posterior, and covering its proximal extremity	Onto the bases of the terminal phalanges of the second to fourth toes.	Tibial: in company with nerves to other muscles of this group

**Table 22-1. Muscles of the Leg**

MUSCLE	ORIGIN	INSERTION	NERVE SUPPLY
<b>Flexor hallucis longus</b>	Distal two-thirds of the posterior surface of the fibula, the septa between it and the tibialis posterior, and peroneal muscles	Onto the base of the terminal phalanx of the great toe.	Tibial: often in company with the nerve to the flexor digitorum longus or other muscles of this group
<b>Tibialis posterior</b>	Lateral half of the popliteal line and lateral half of the middle one-third of the posterior surface of the tibia, medial side of the head and part of the body of the fibula next to the interosseous membrane in the proximal two-thirds, the entire proximal and lateral portion of the lateral part of the posterior surface of the interosseous membrane, and the septum between its proximal portion and the long flexor muscles	The tendon divides into two parts: the deep part becomes attached primarily to the tubercle of the navicular bone and usually to the first cuneiform; the superficial part attaches to the third cuneiform and the base of the fourth metatarsal, and also, in part, to the second cuneiform, to the capsule of the naviculocuneiform joint, to the sulcus of the cuboid, and usually also to the origin of the short flexor of the big toe and base of the second metatarsal; slip may extend to other structures.	Tibial: in company with nerves to other muscles of this group
	Medial head: posterior surface of the medial condyle of the femur above the articular surface; lateral head: a facet on the proximal part of the posterolateral surface of the lateral condyle of the femur	Via the Achilles tendon onto the posterior surface of the calcaneus.	Sciatic, tibial part
<b>Soleus</b>	By a fibular head from the back of the head and the proximal one-third of the posterior surface of the shaft of the fibula; intermuscular septum between it and the peroneus longus, by a tibial head from the popliteal line and the middle one-third of the medial border of the tibia	Via the calcaneal tendon onto the posterior surface of the calcaneus.	Sciatic, tibial part
<b>Plantaris</b>	Distal part of the lateral line of the bifurcation of the linea aspera, in close association with the lateral head of the gastrocnemius	Via a flat narrow tendon running along the medial edge of the Achilles tendon to the posterior surface of the calcaneus.	Sciatic, tibial part

*Chapter*  
**23**

**MRI of the Ankle**

# AXIAL

Figure 23.1.1

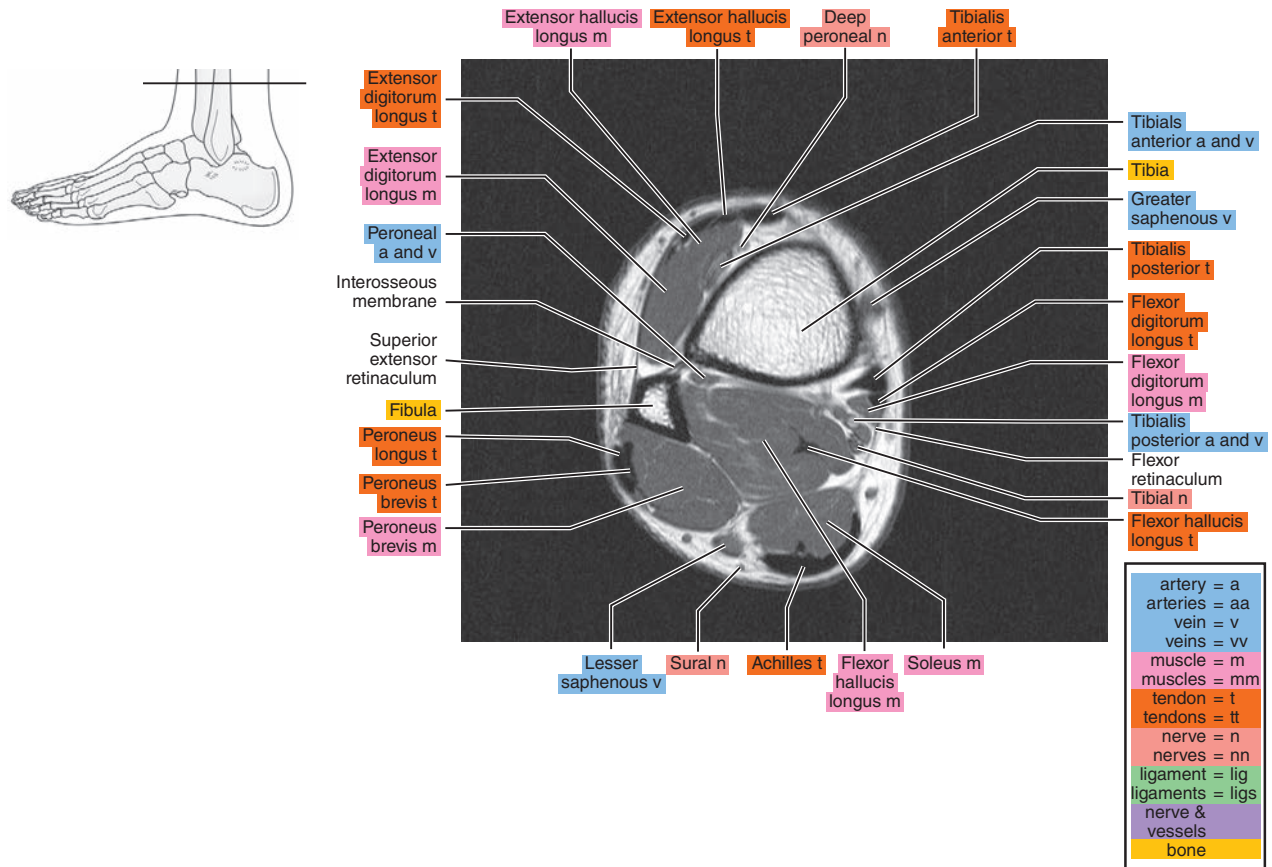


Figure 23.1.2

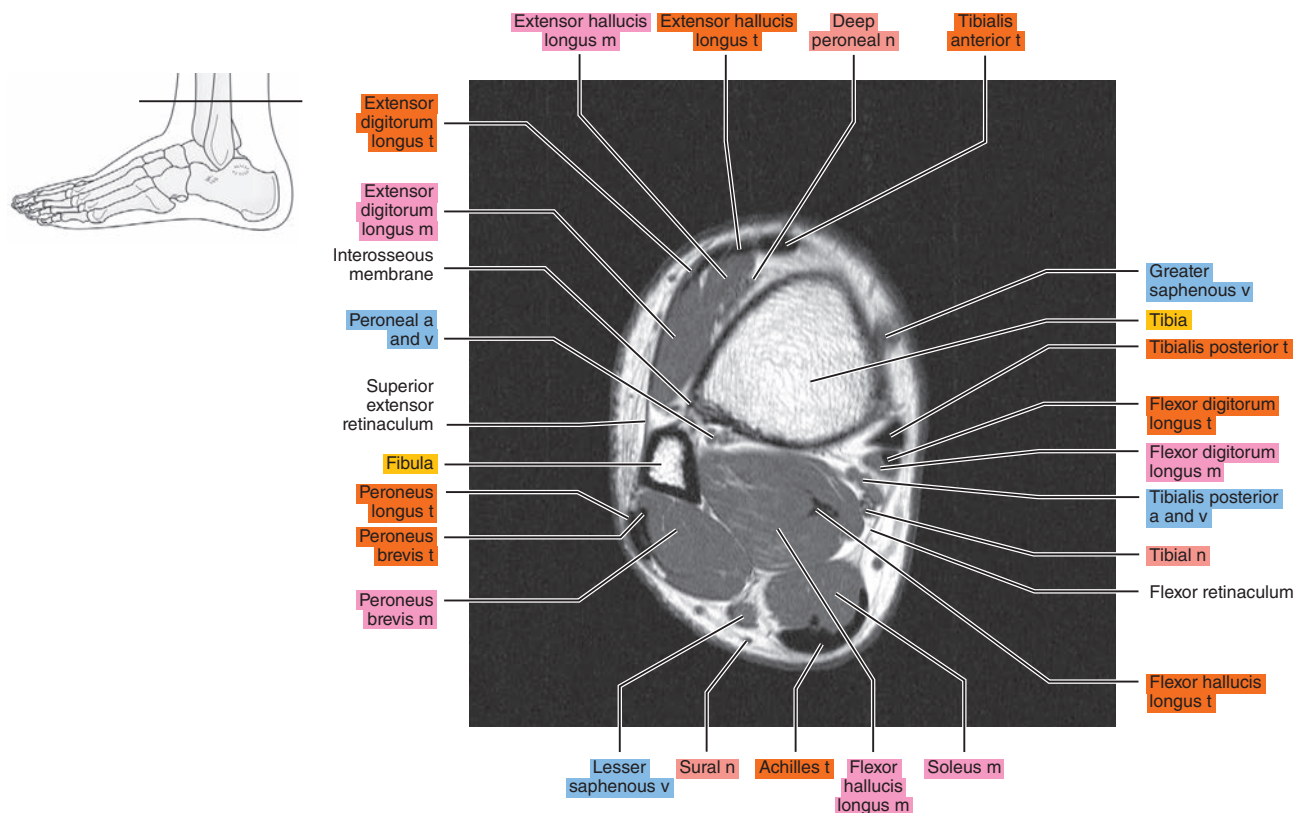




Figure 23.1.3

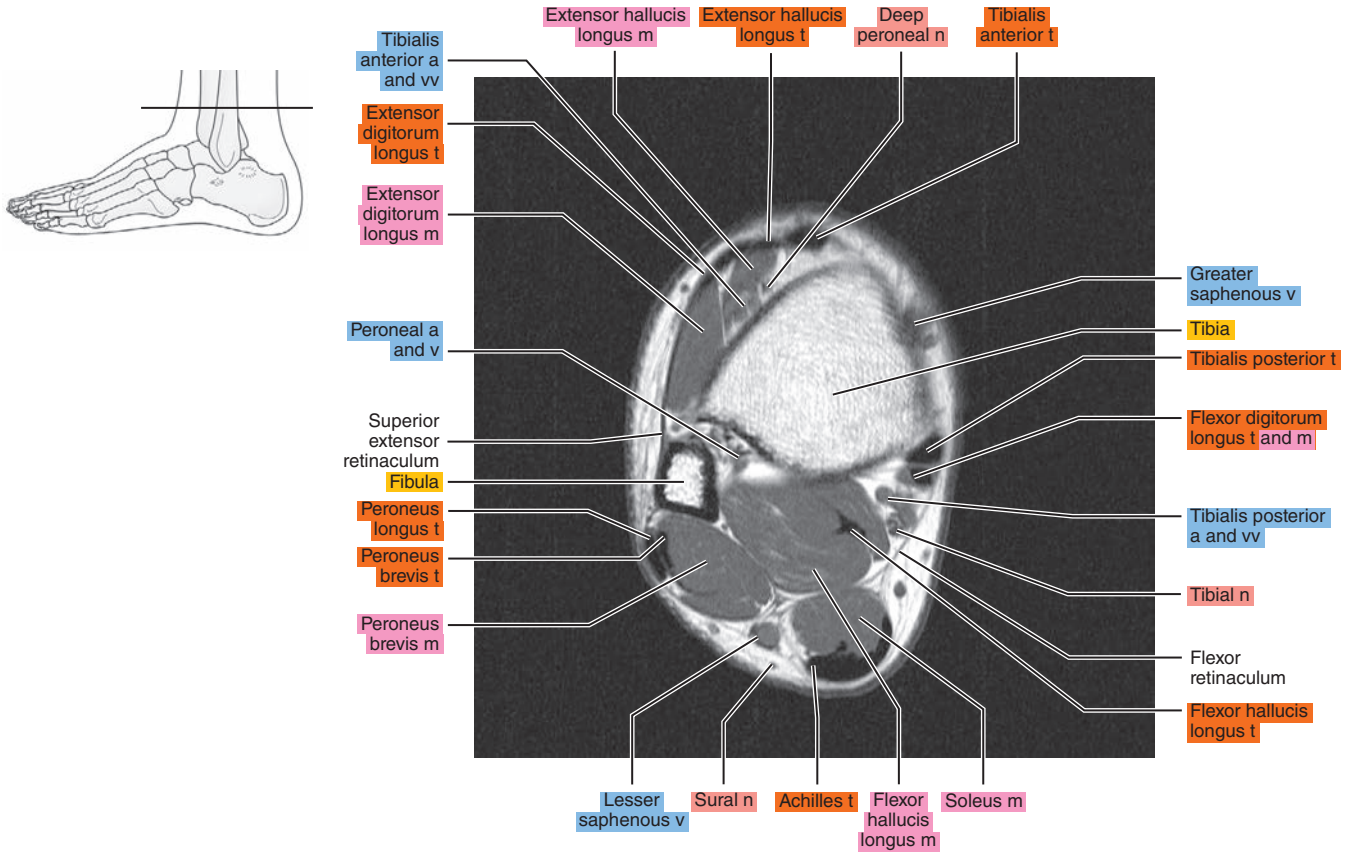


Figure 23.1.4

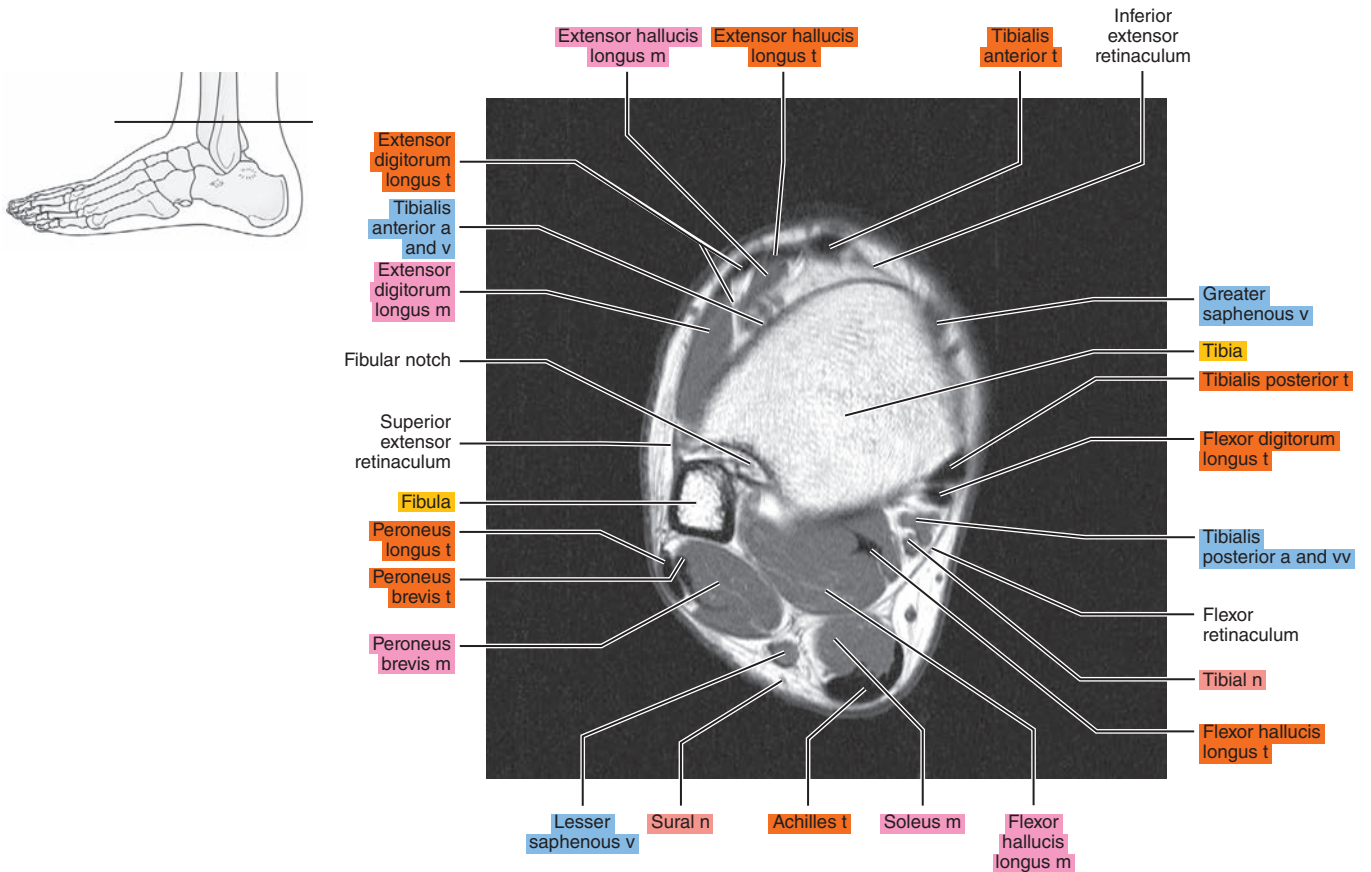


Figure 23.1.5

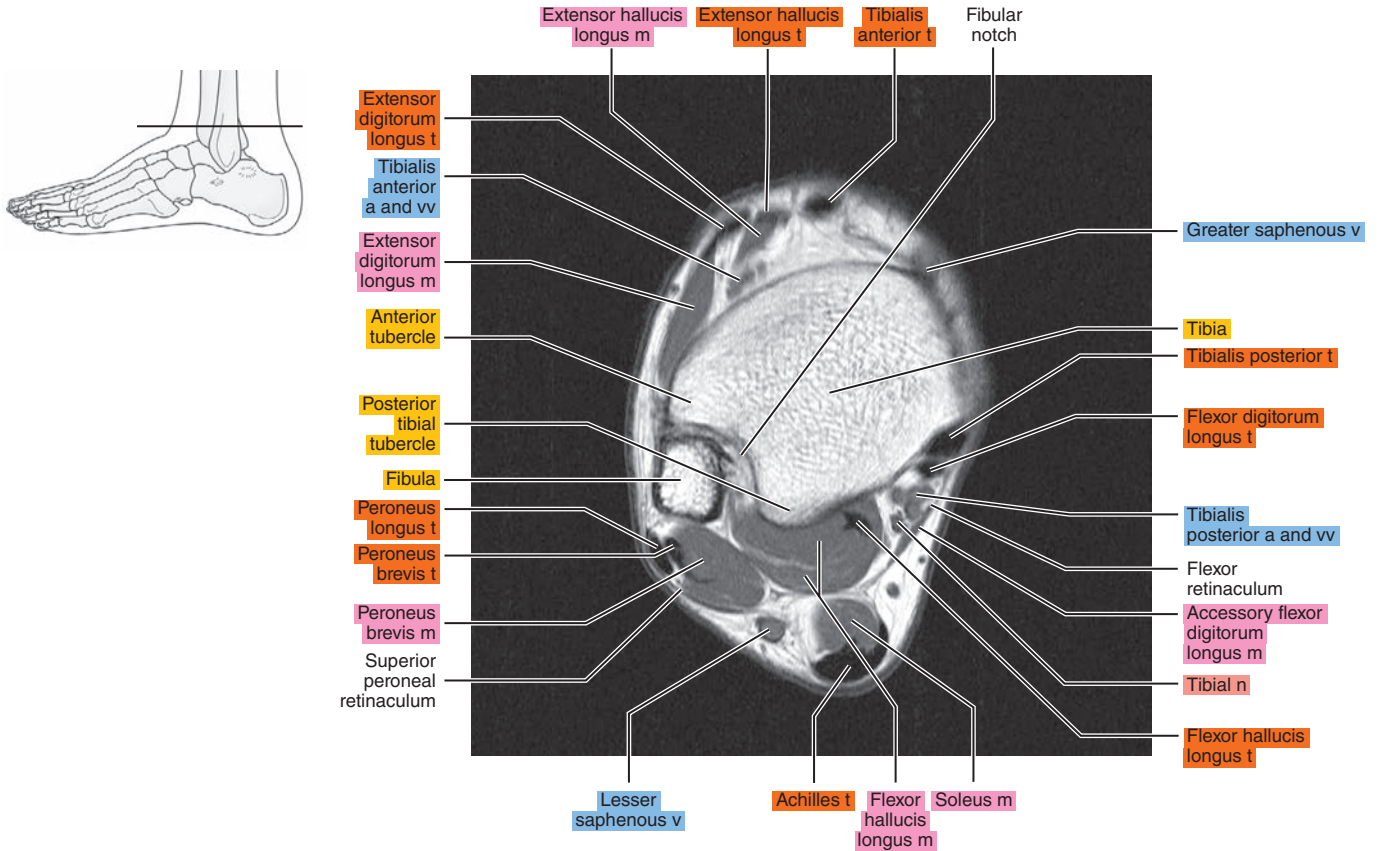


Figure 23.1.6

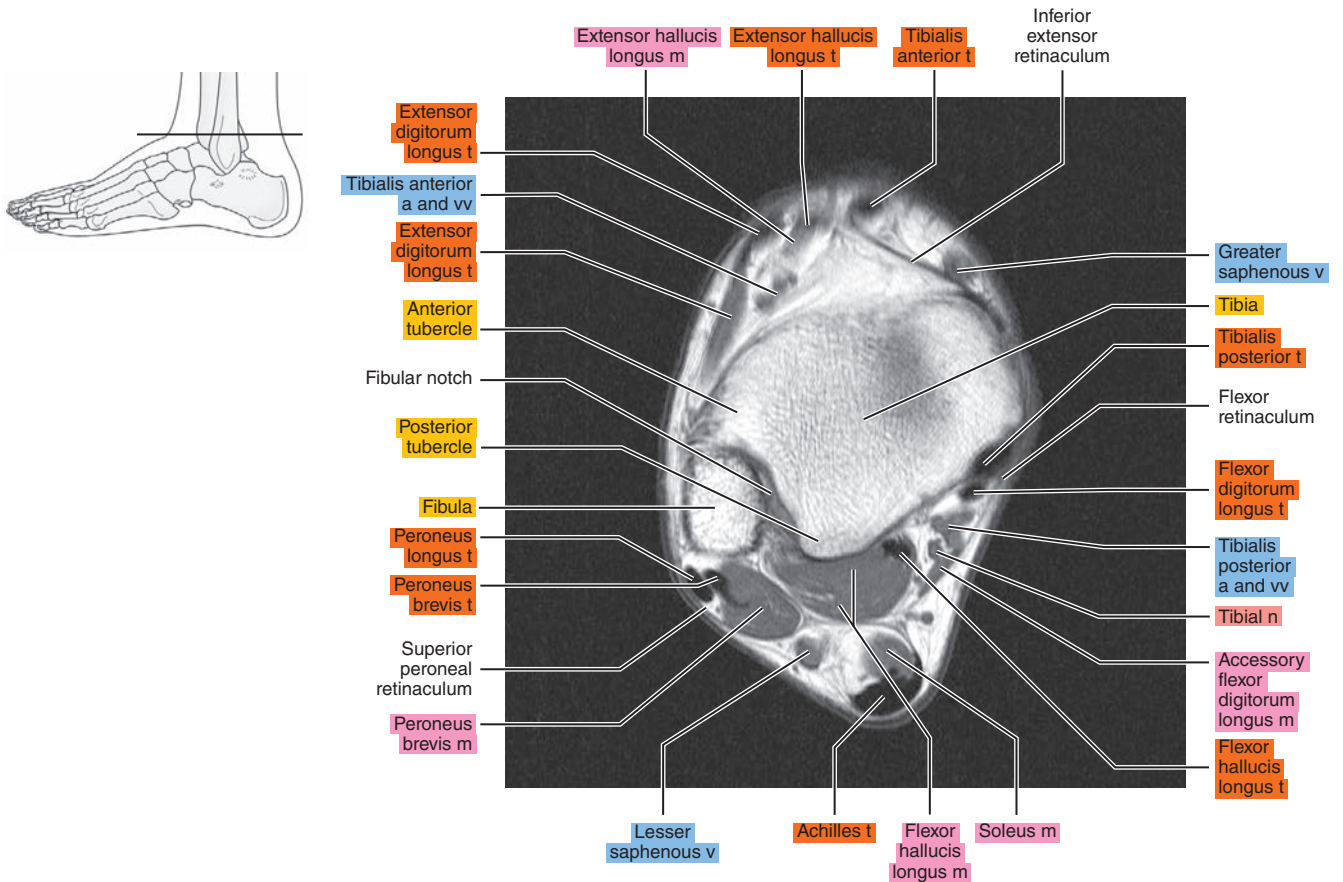




Figure 23.1.7

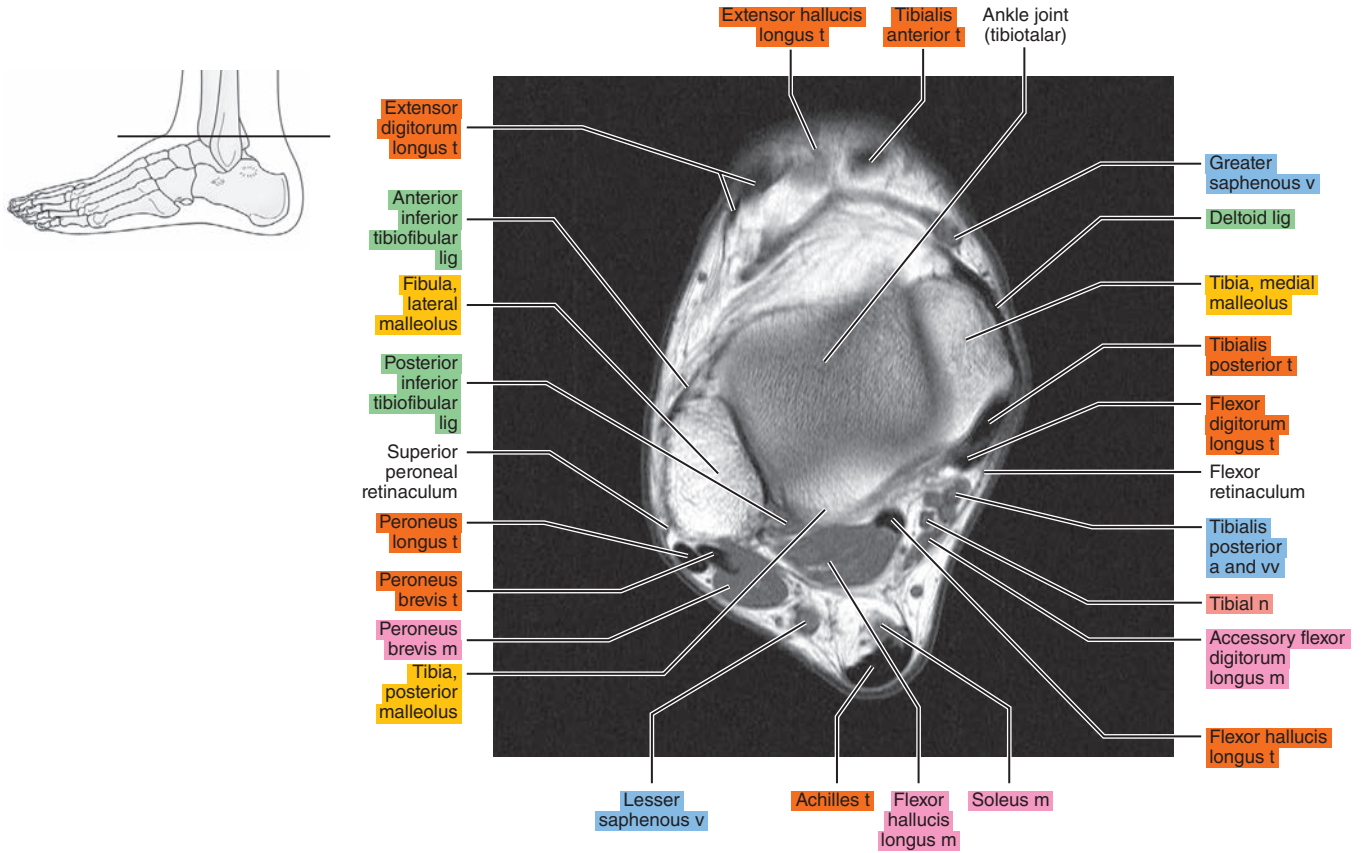


Figure 23.1.8

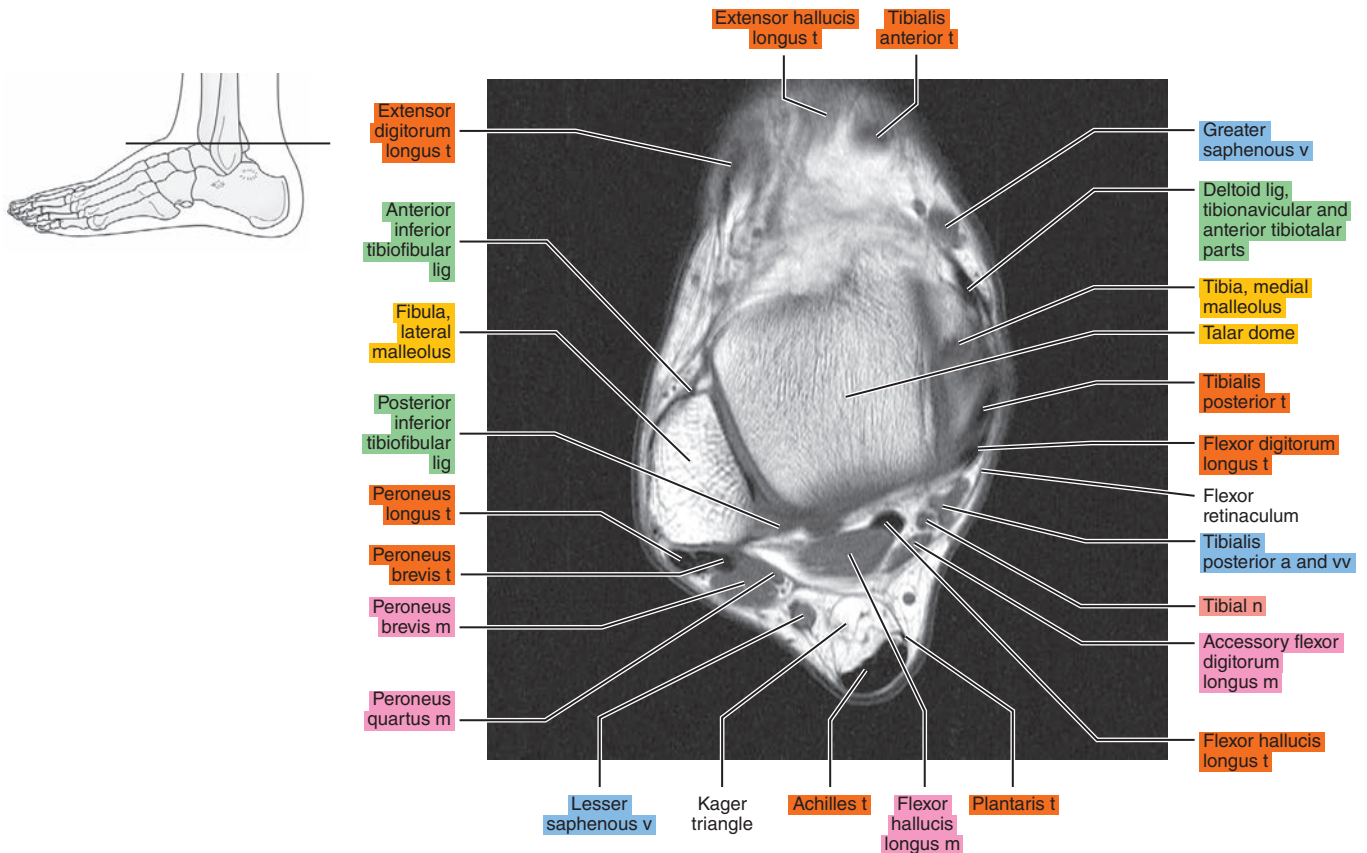


Figure 23.1.9

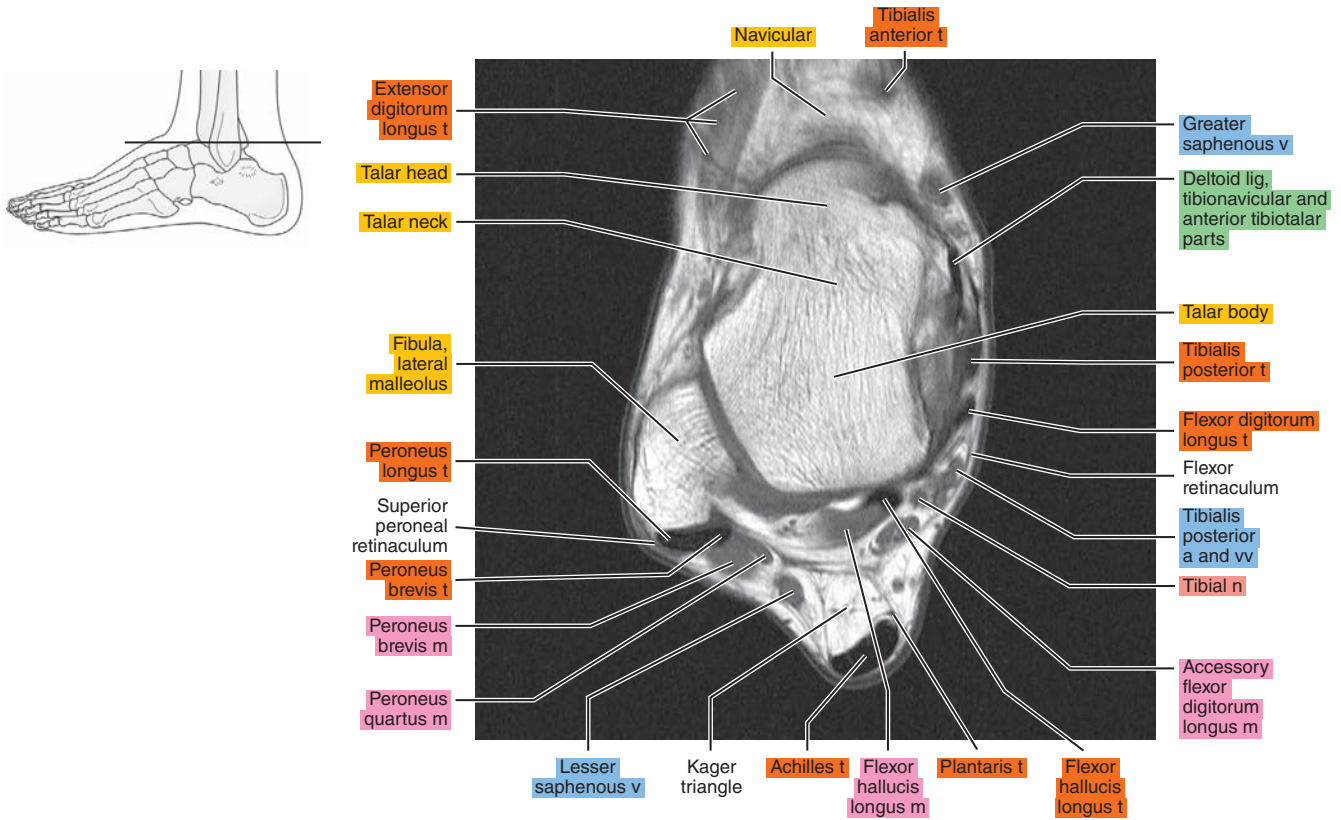


Figure 23.1.10

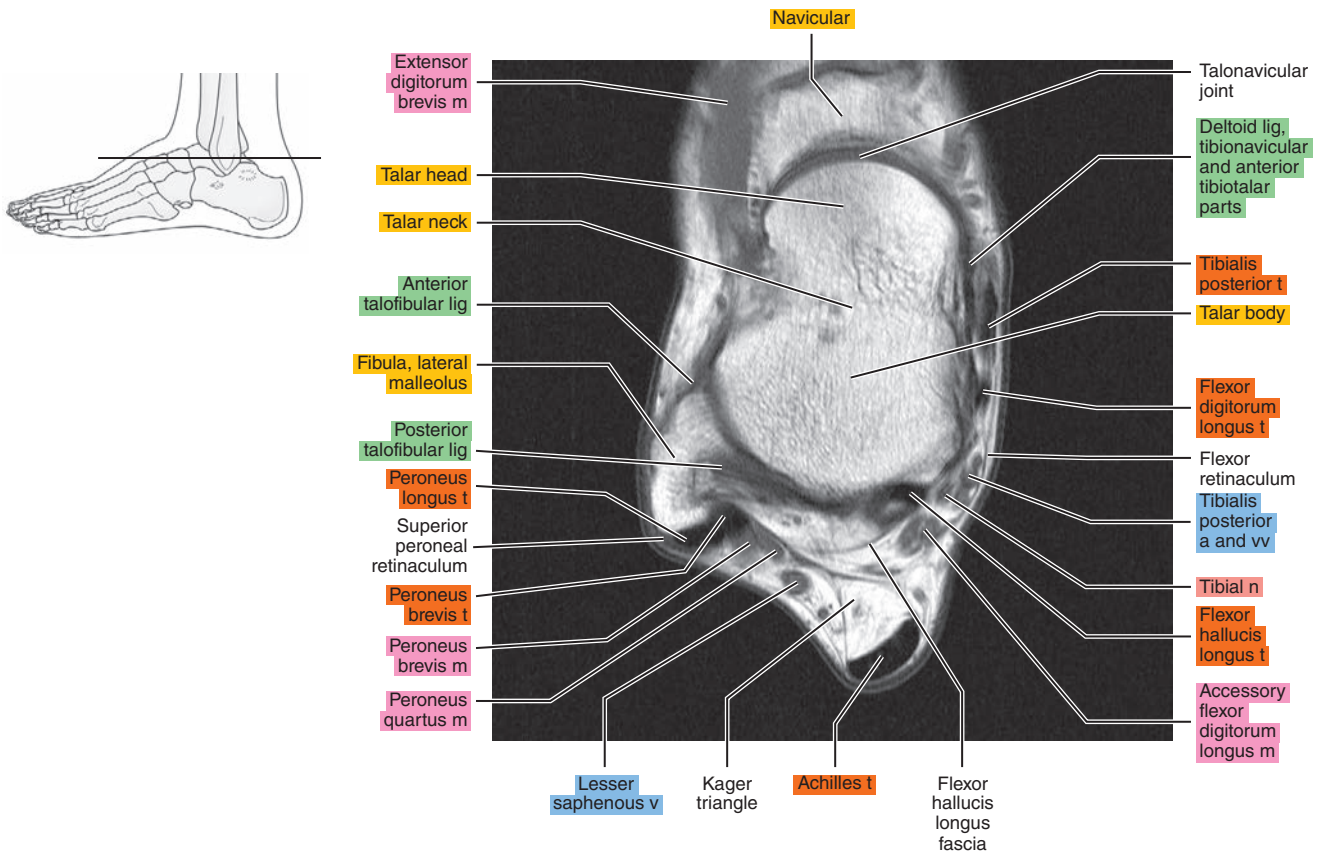






Figure 23.1.13

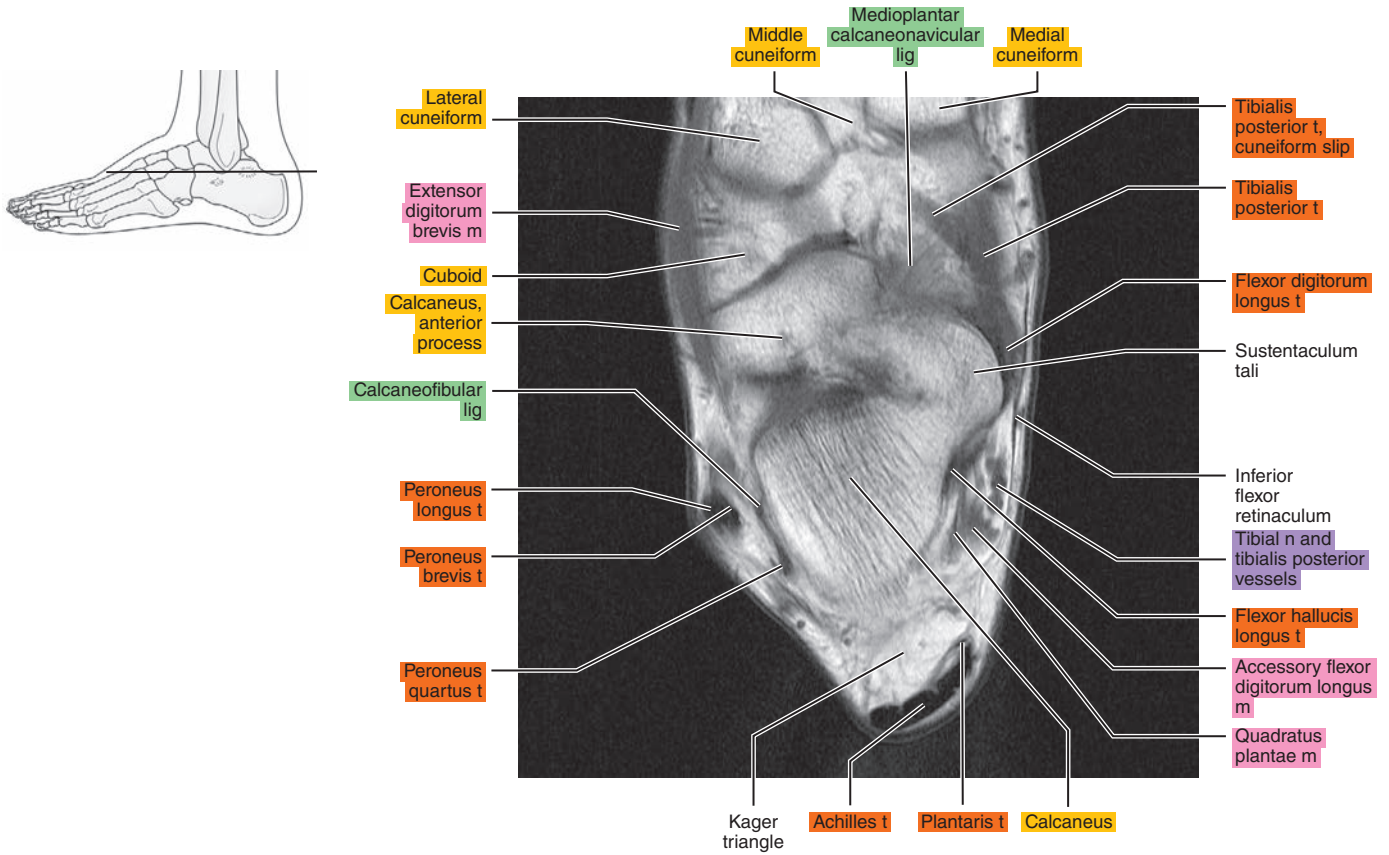


Figure 23.1.14

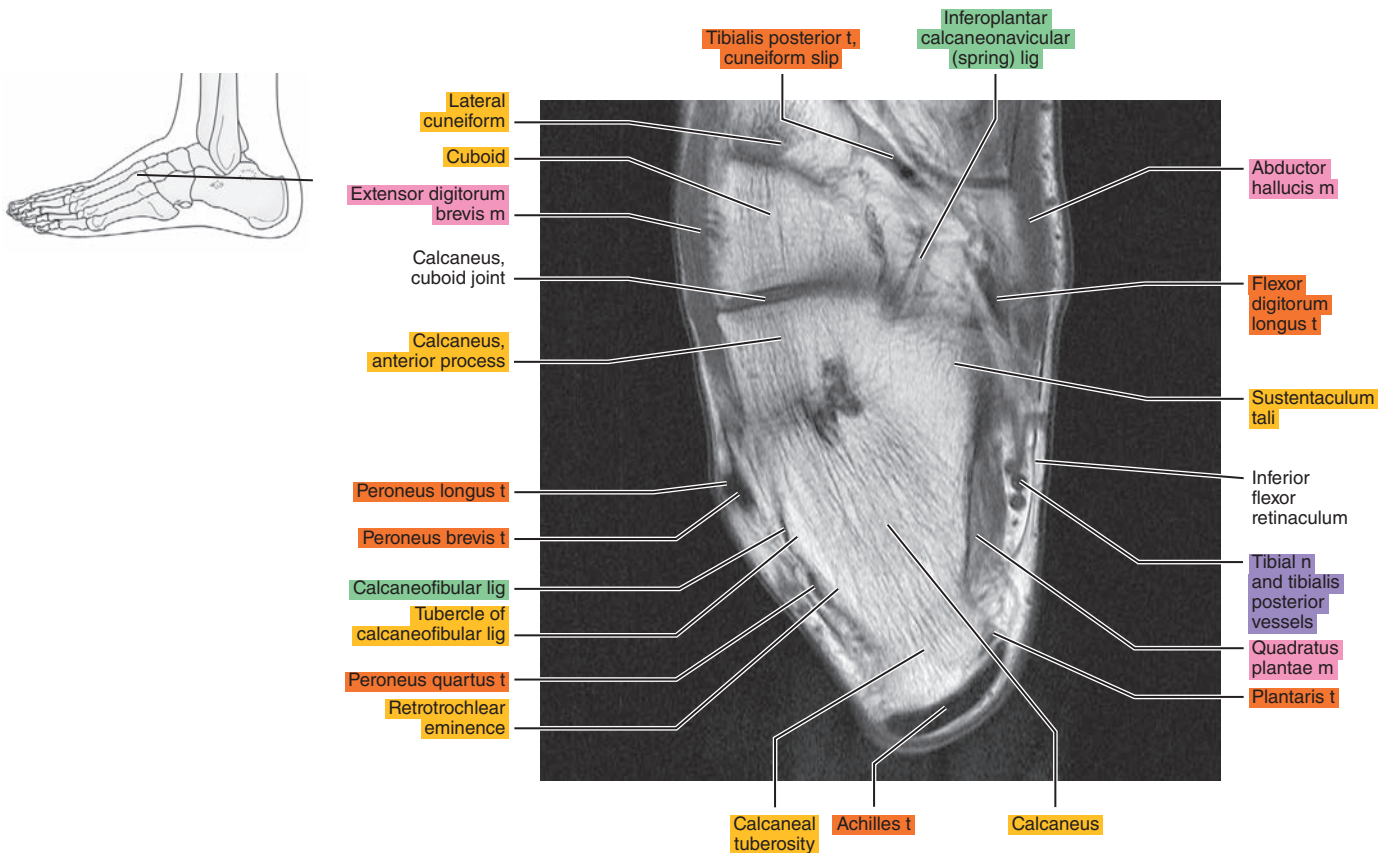




Figure 23.1.15

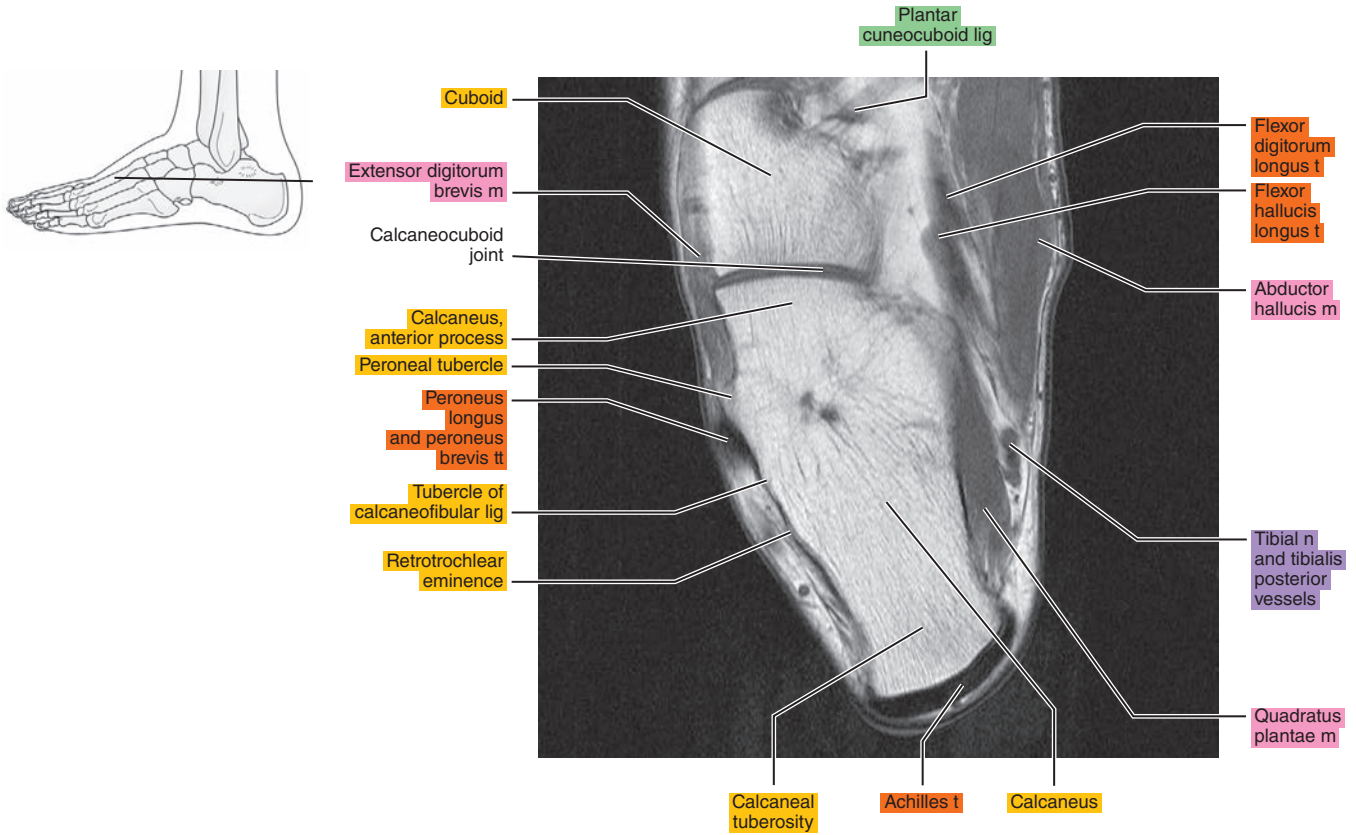


Figure 23.1.16

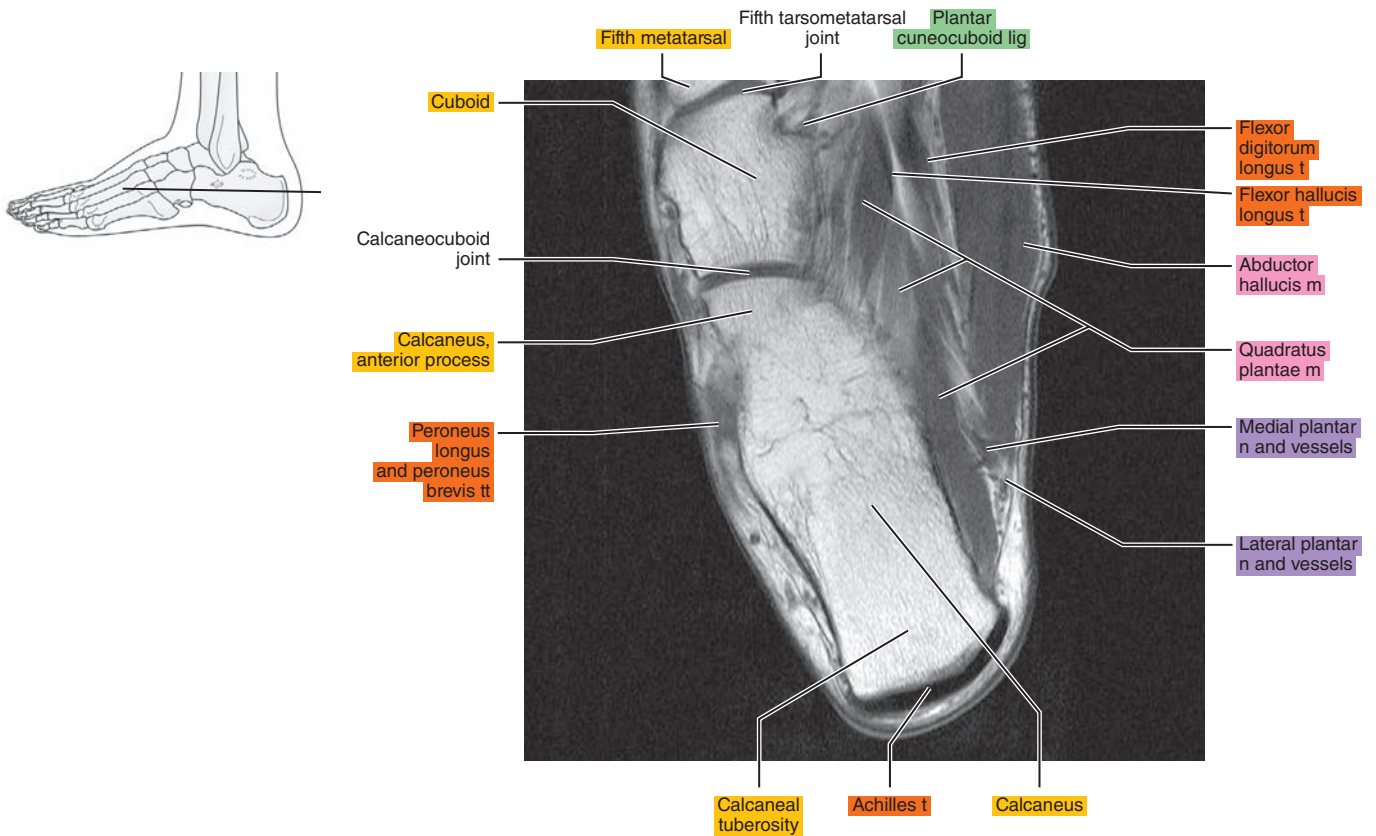


Figure 23.1.17

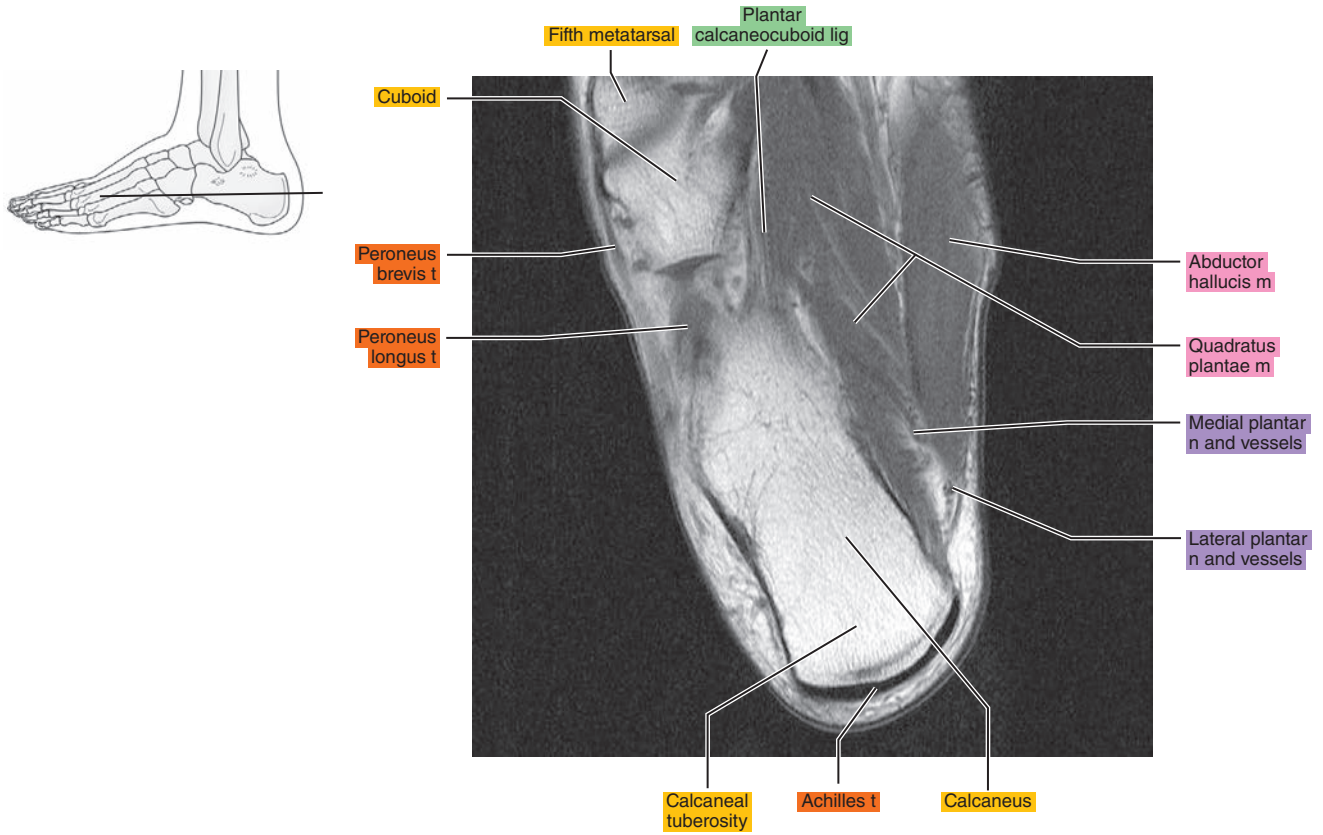


Figure 23.1.18

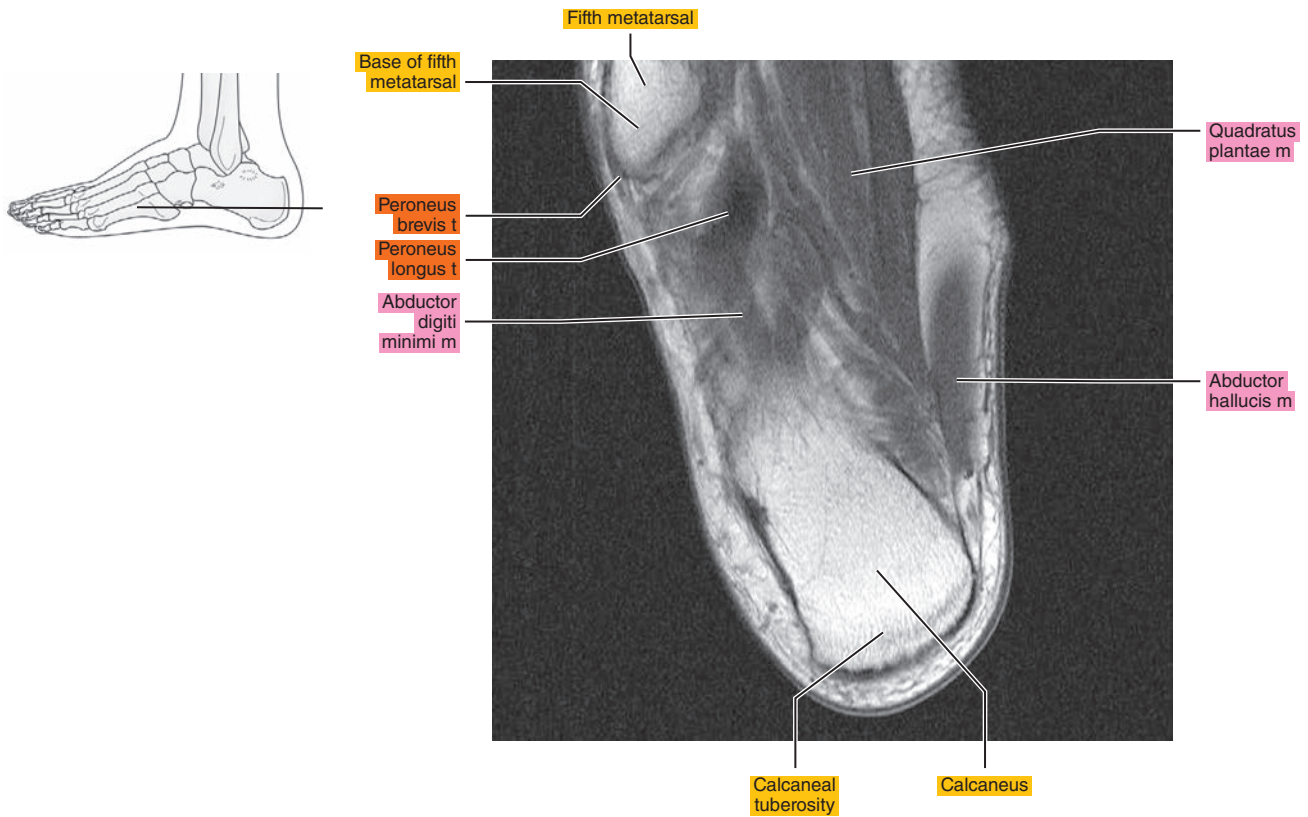




Figure 23.1.19

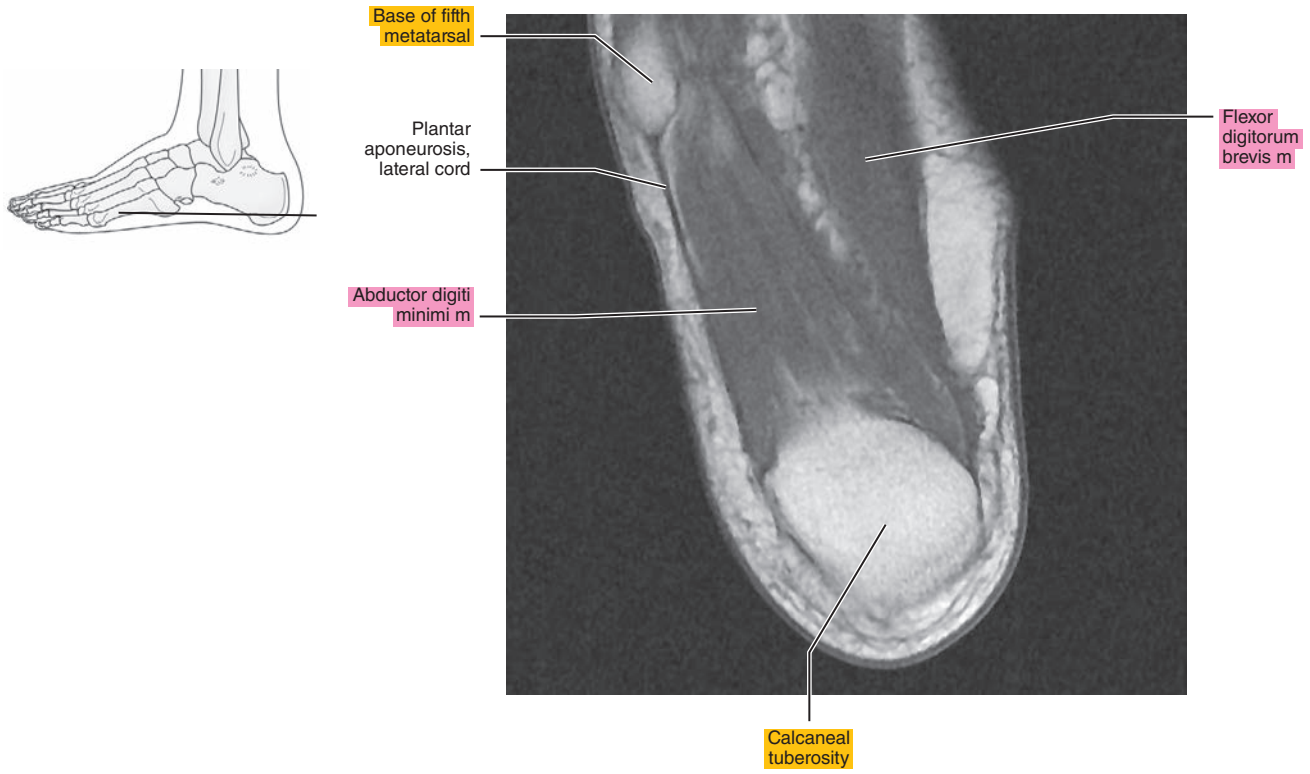


Figure 23.1.20

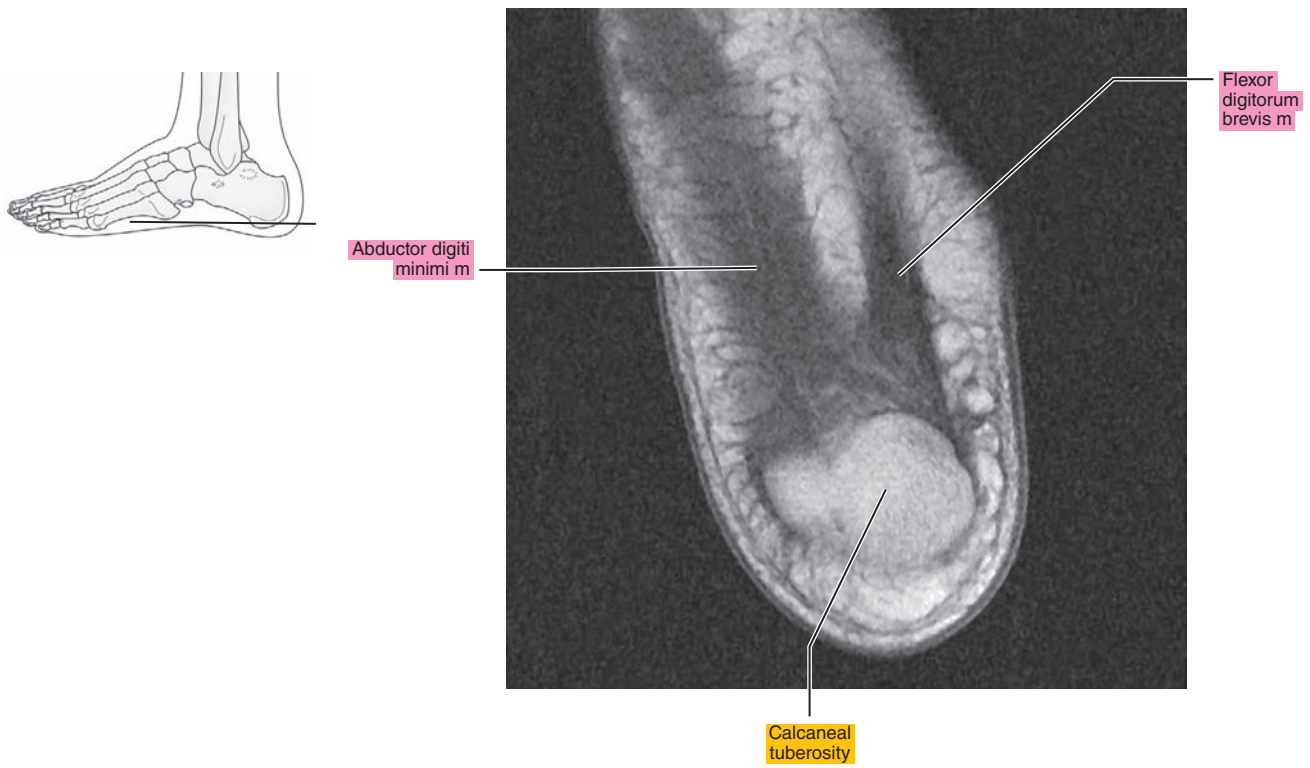




Figure 23.2.3

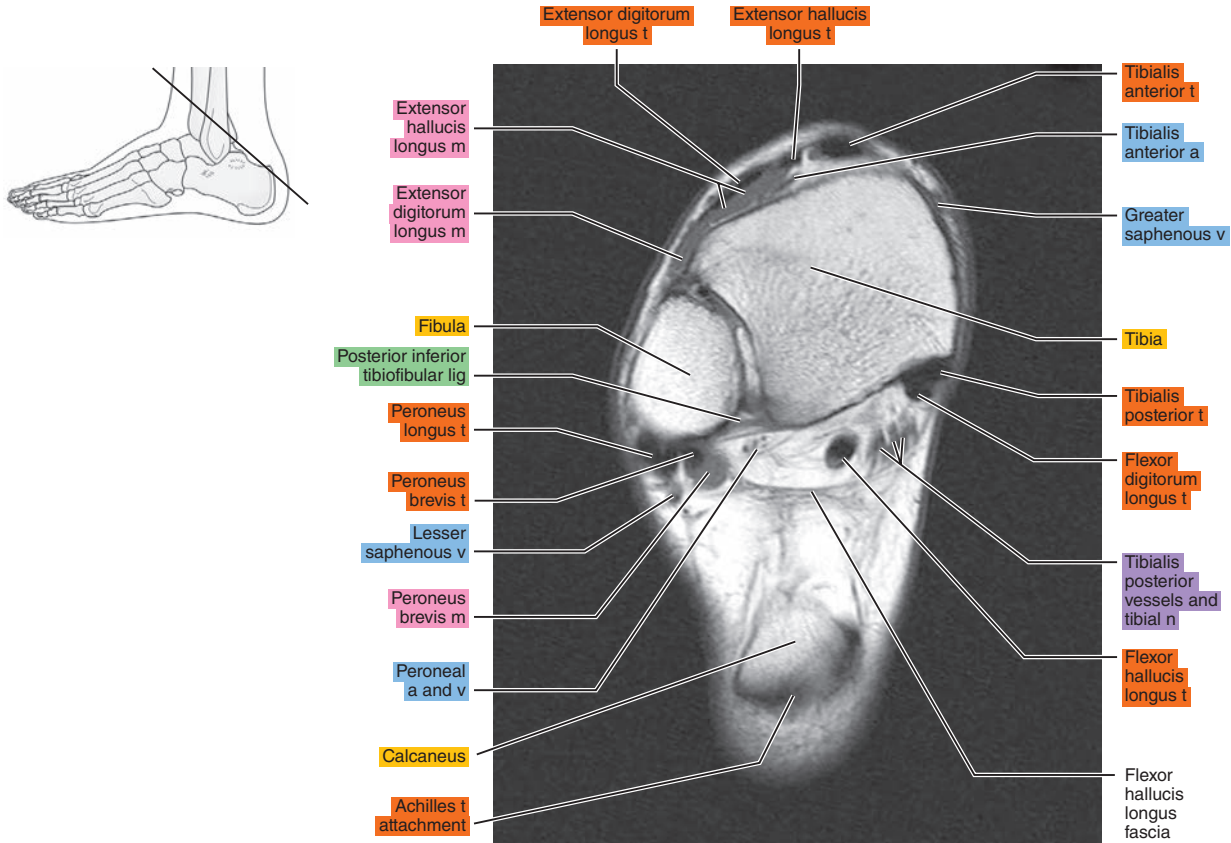


Figure 23.2.4

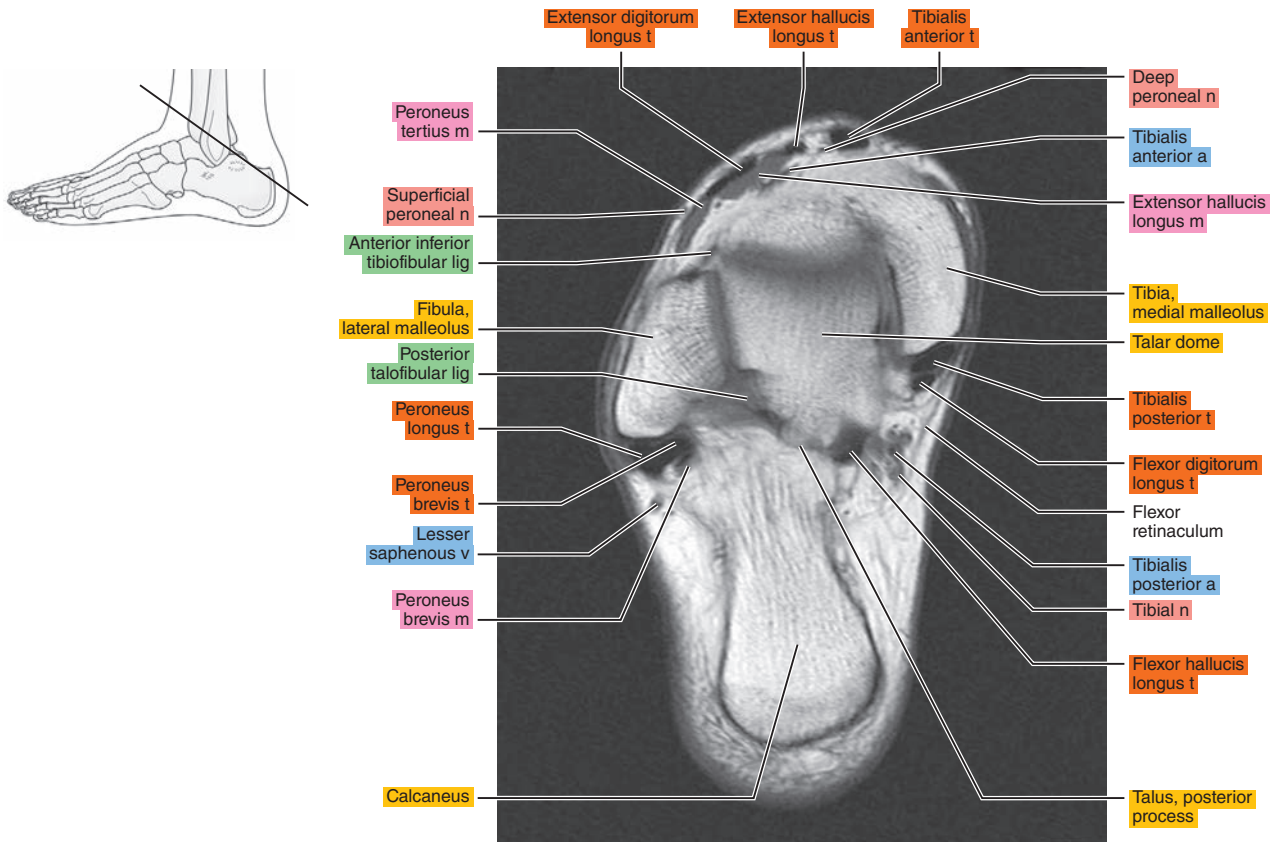




Figure 23.2.5

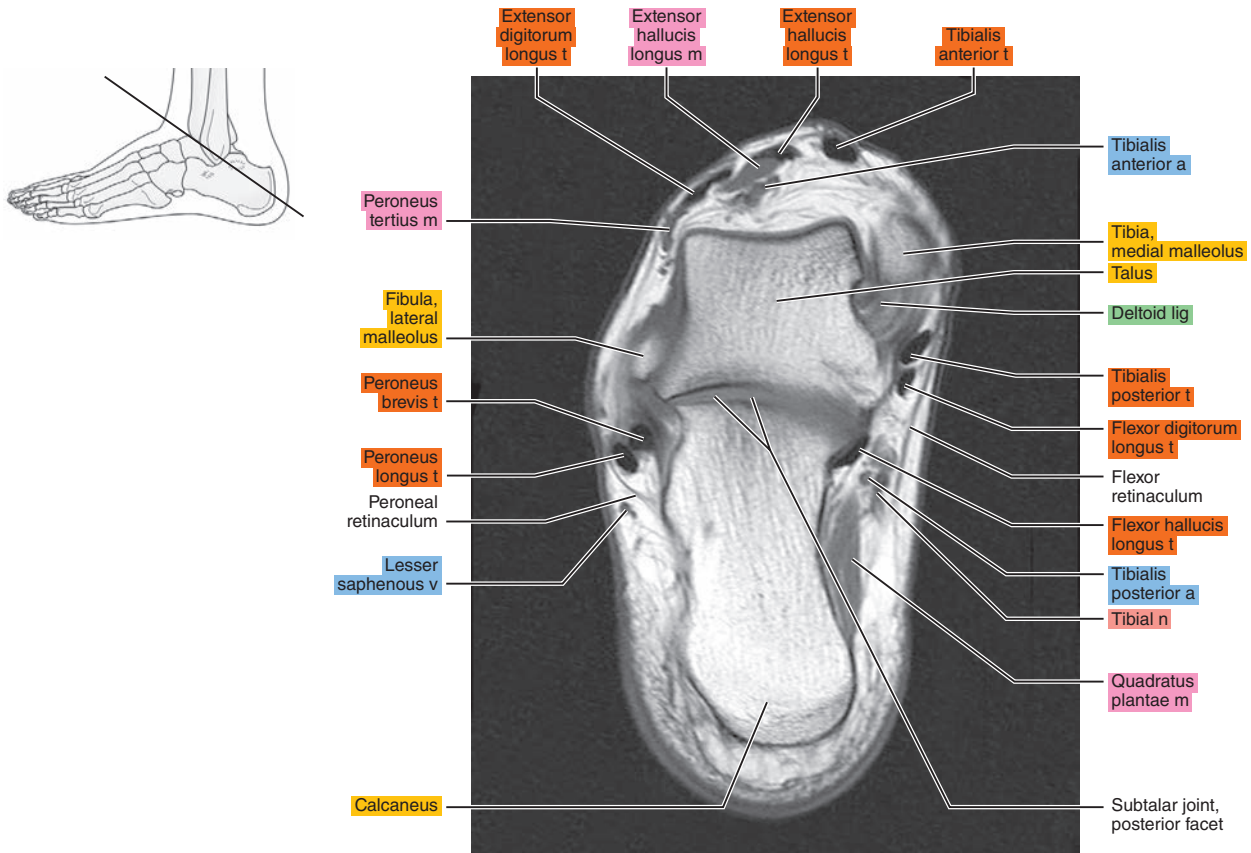


Figure 23.2.6

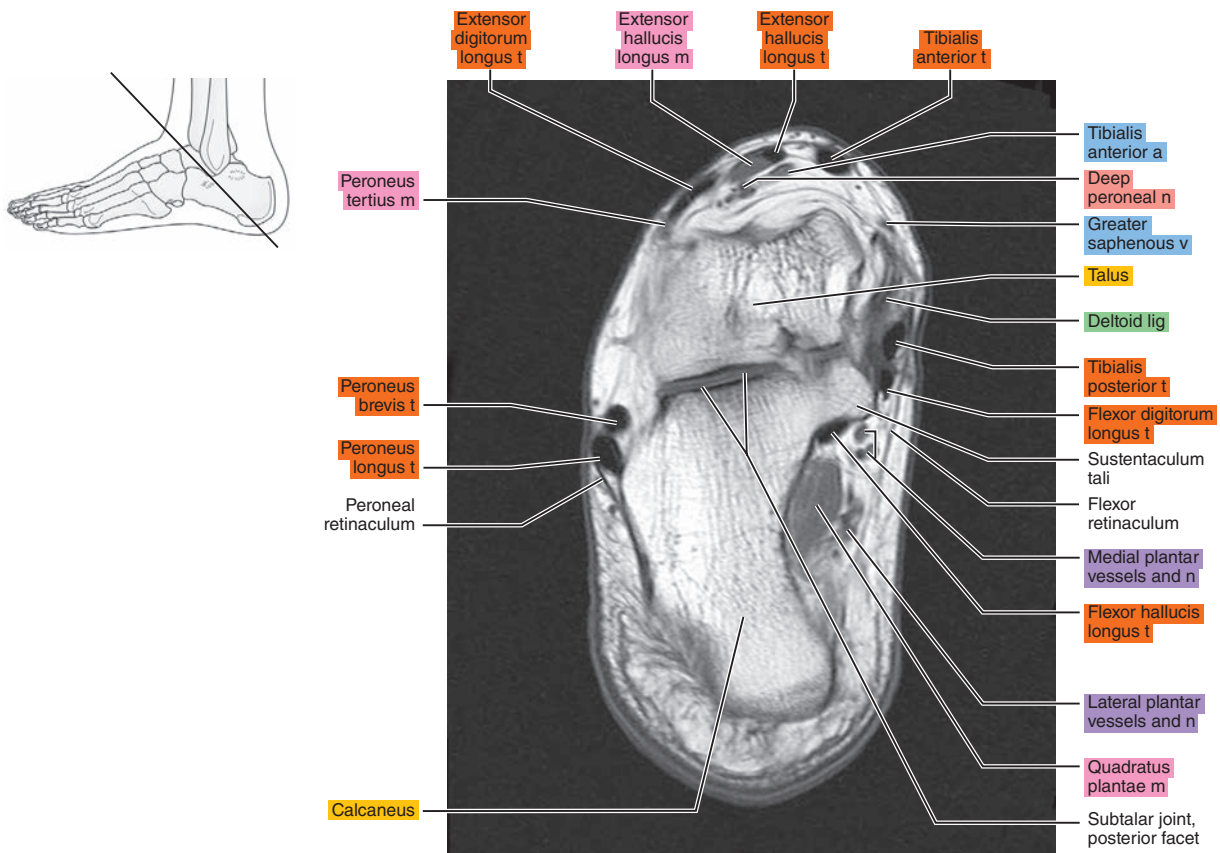




Figure 23.2.7

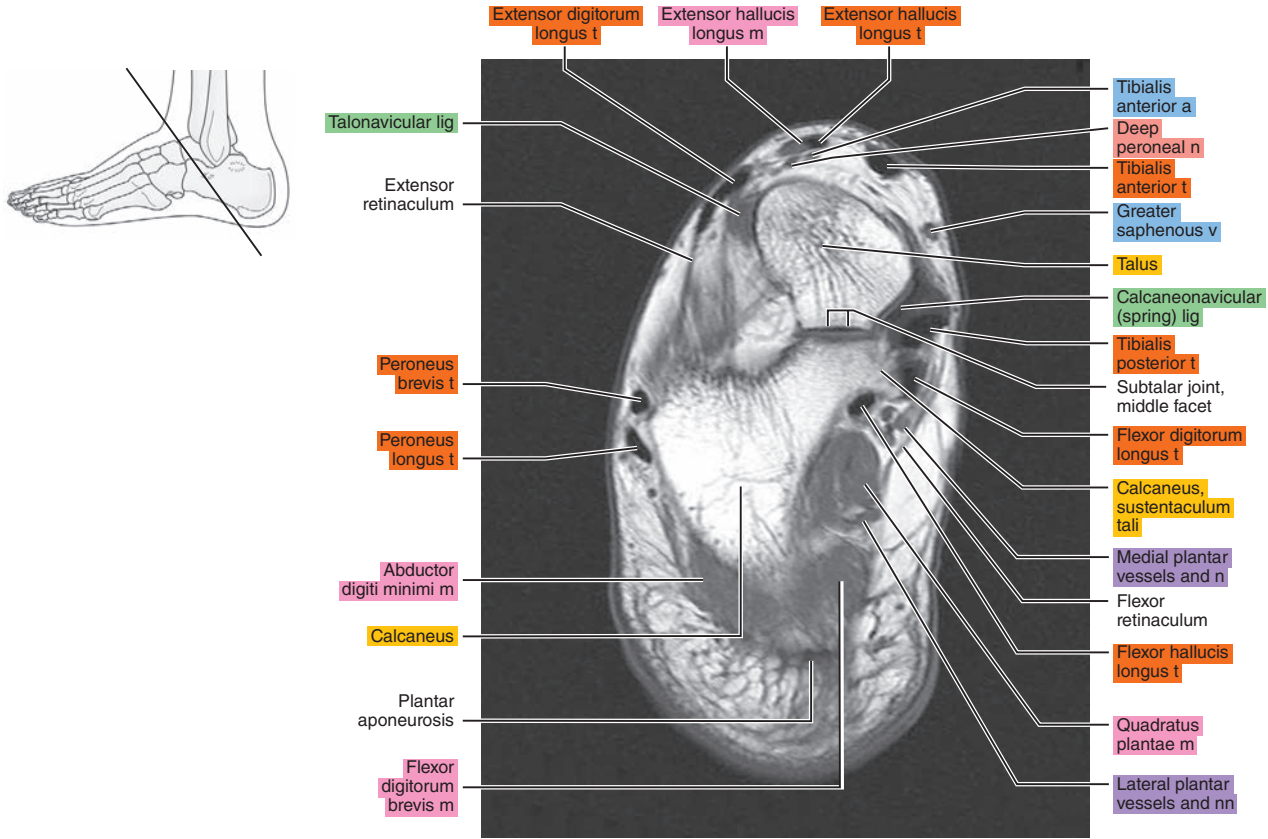


Figure 23.2.8

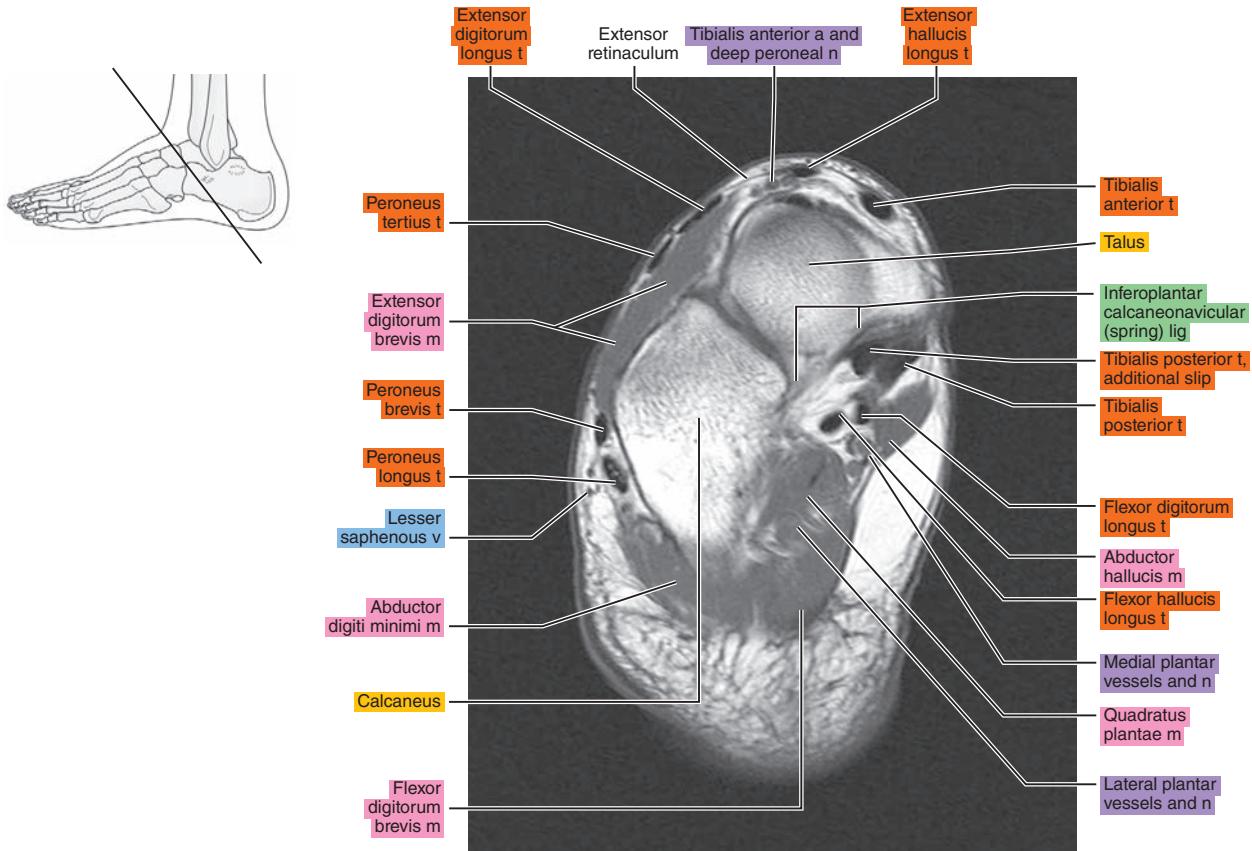


Figure 23.2.9

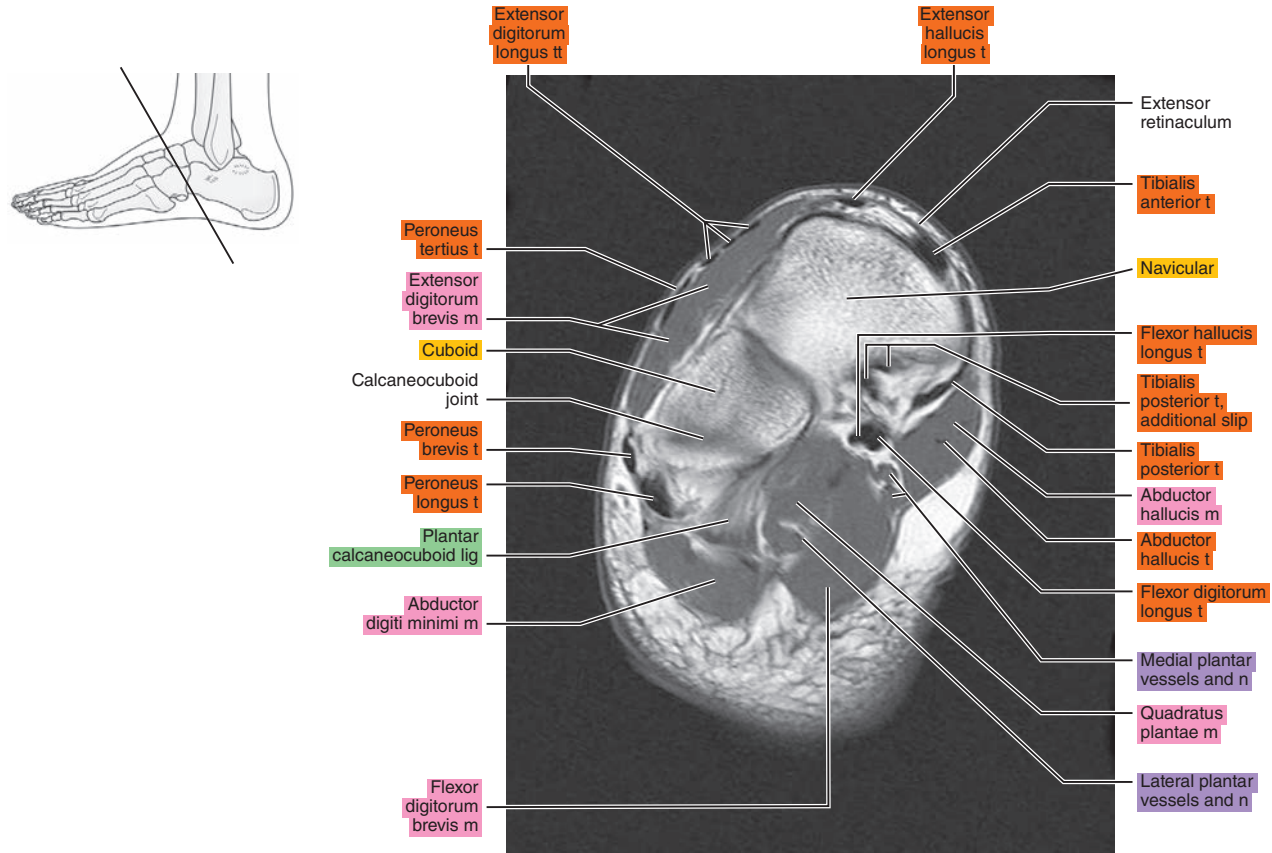


Figure 23.2.10

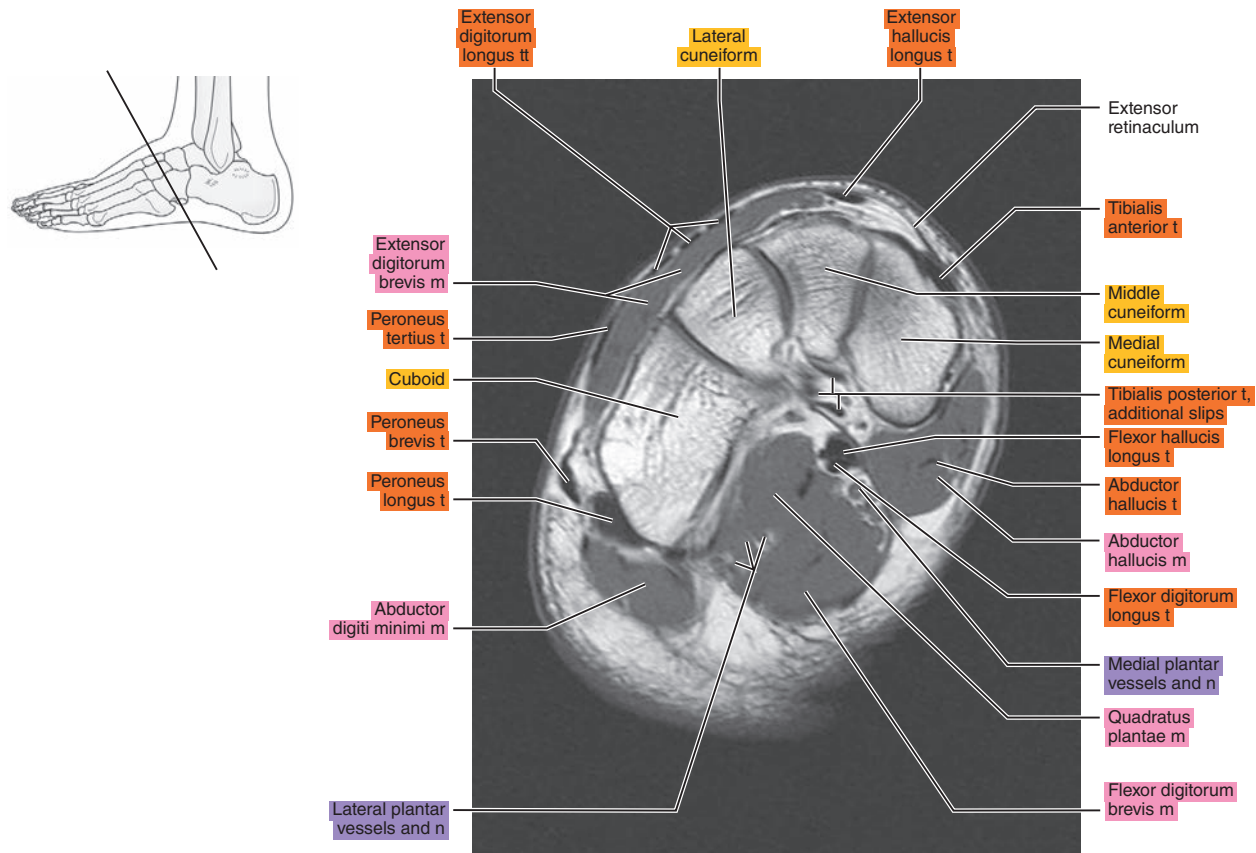
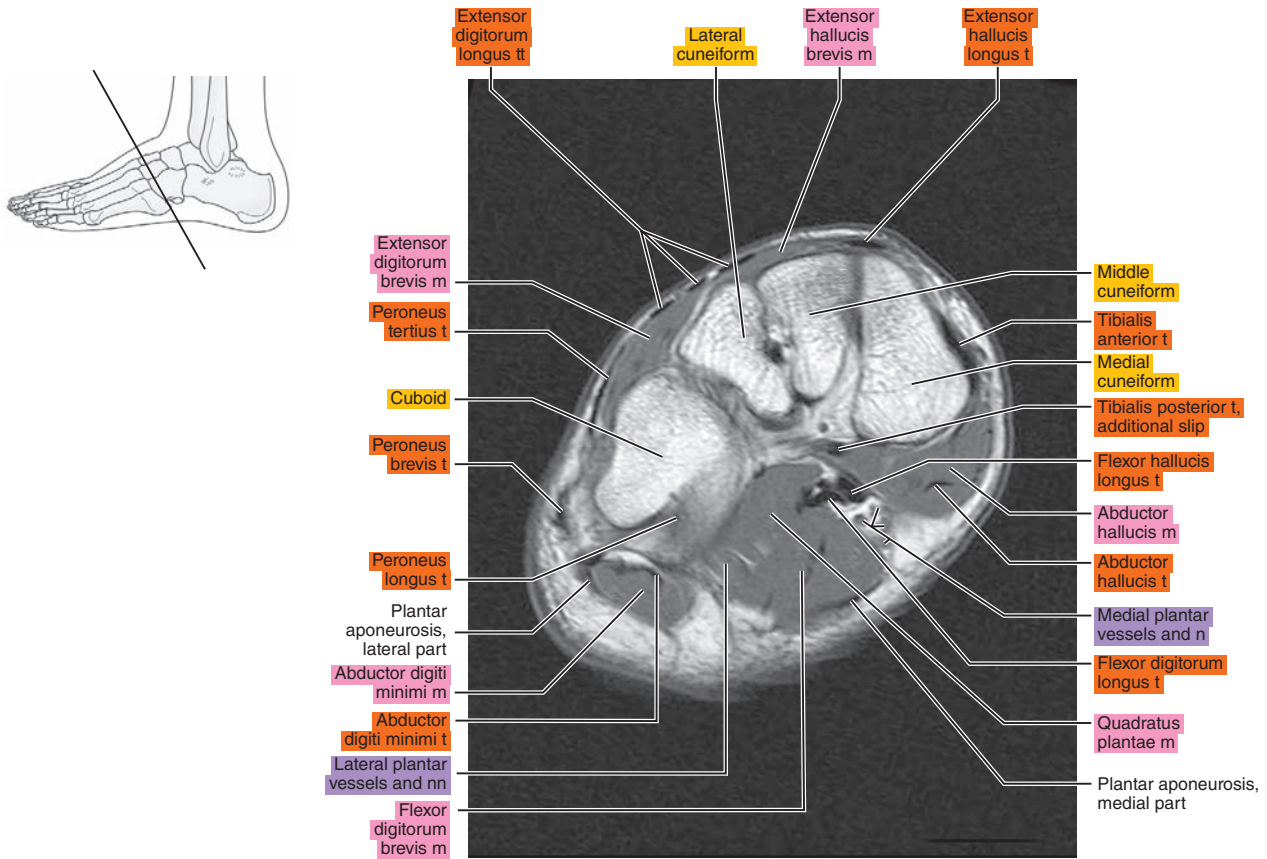


Figure 23.2.11





# SAGITTAL

Figure 23.3.1

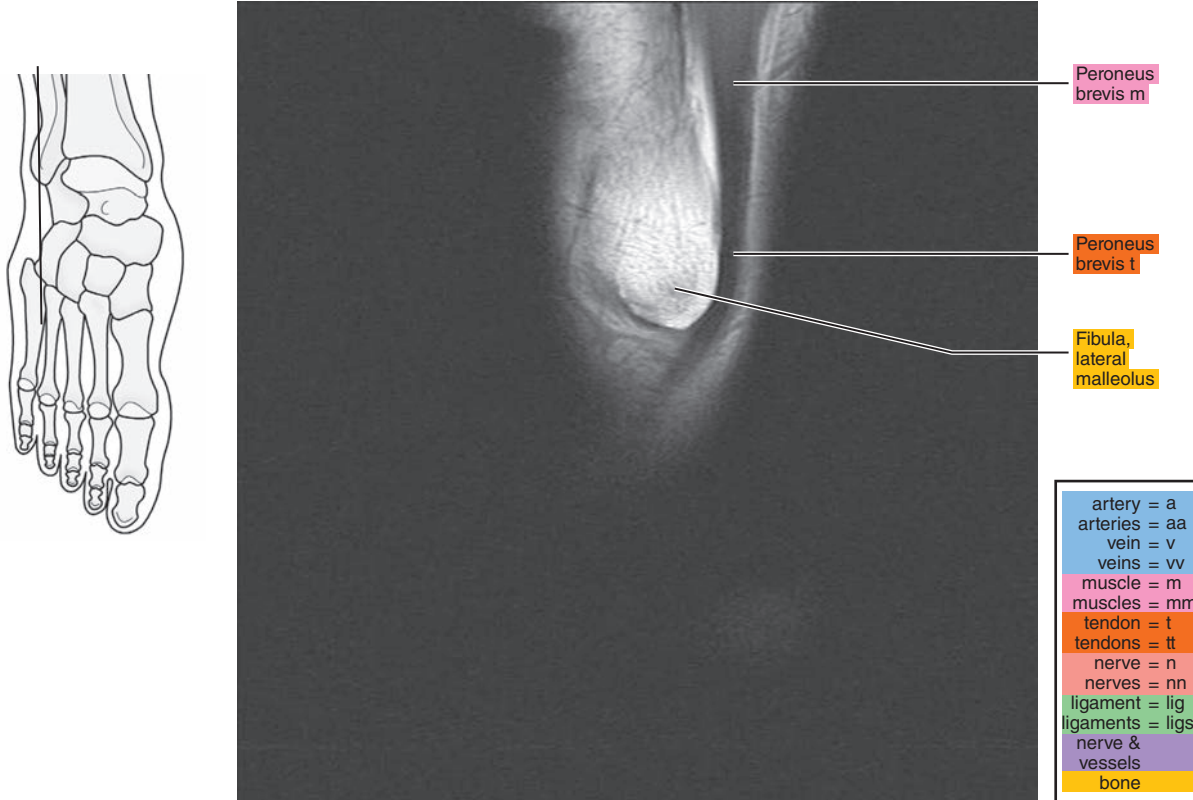


Figure 23.3.2

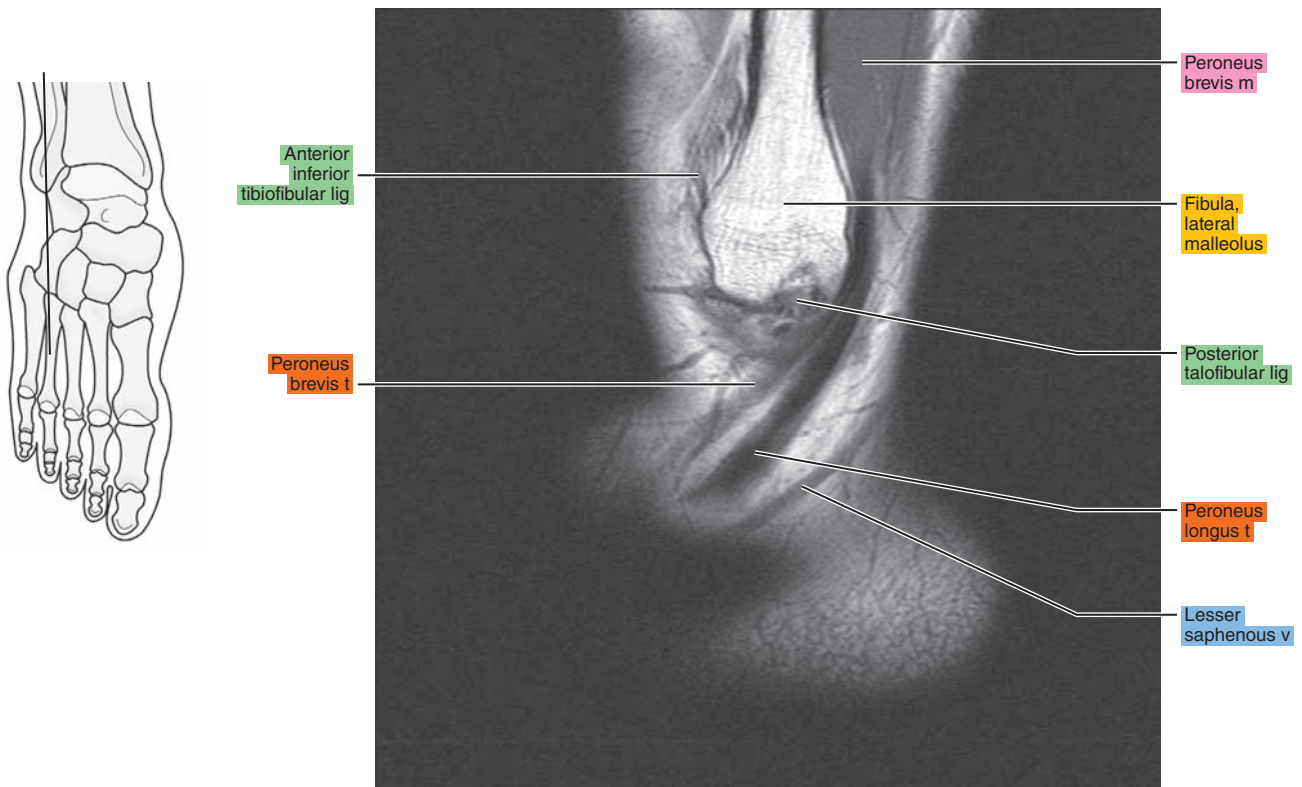




Figure 23.3.3

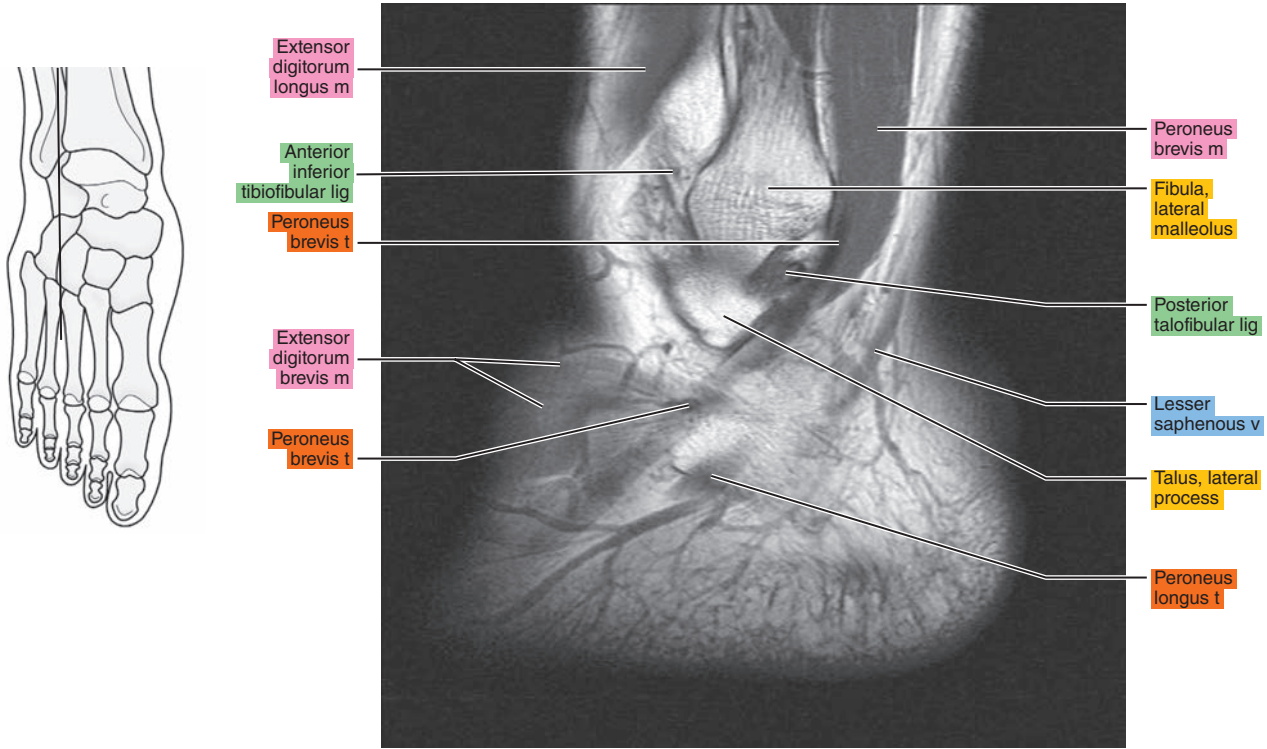


Figure 23.3.4

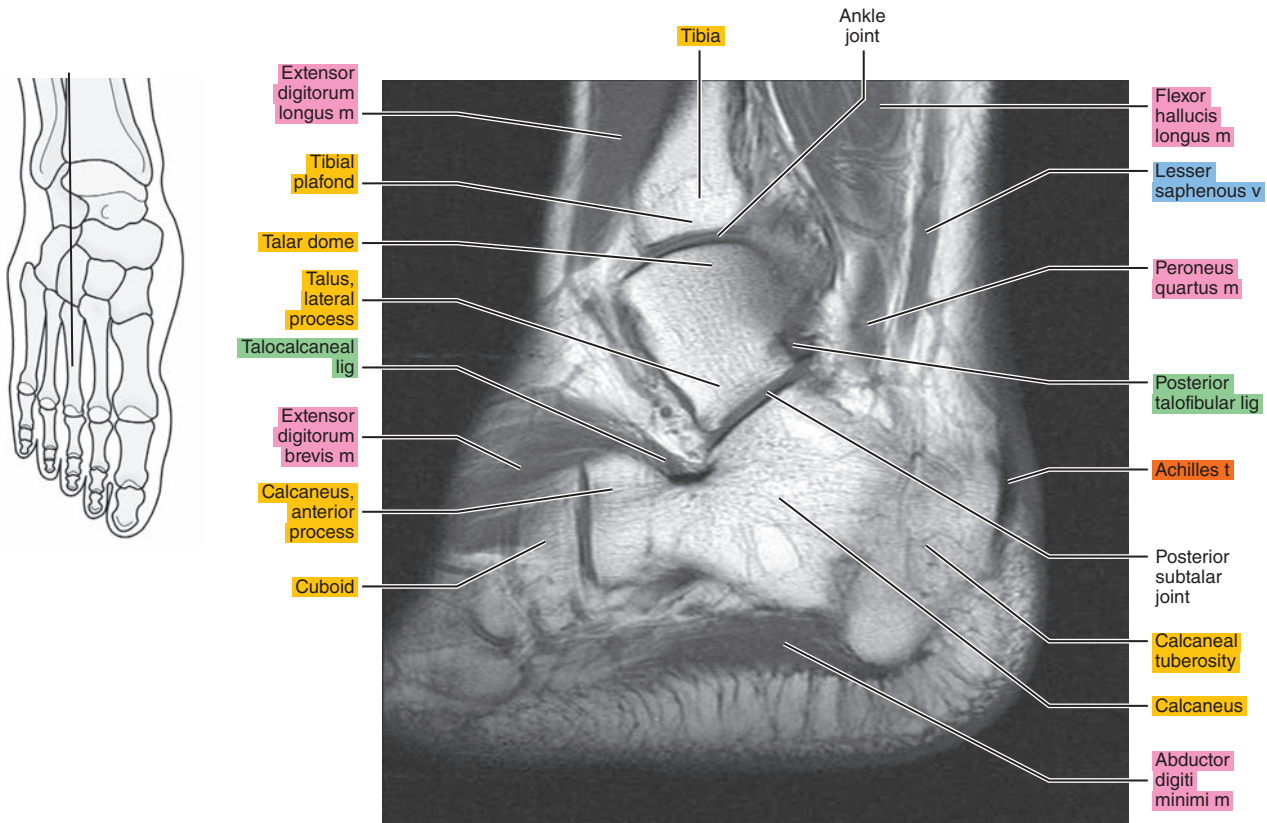


Figure 23.3.5

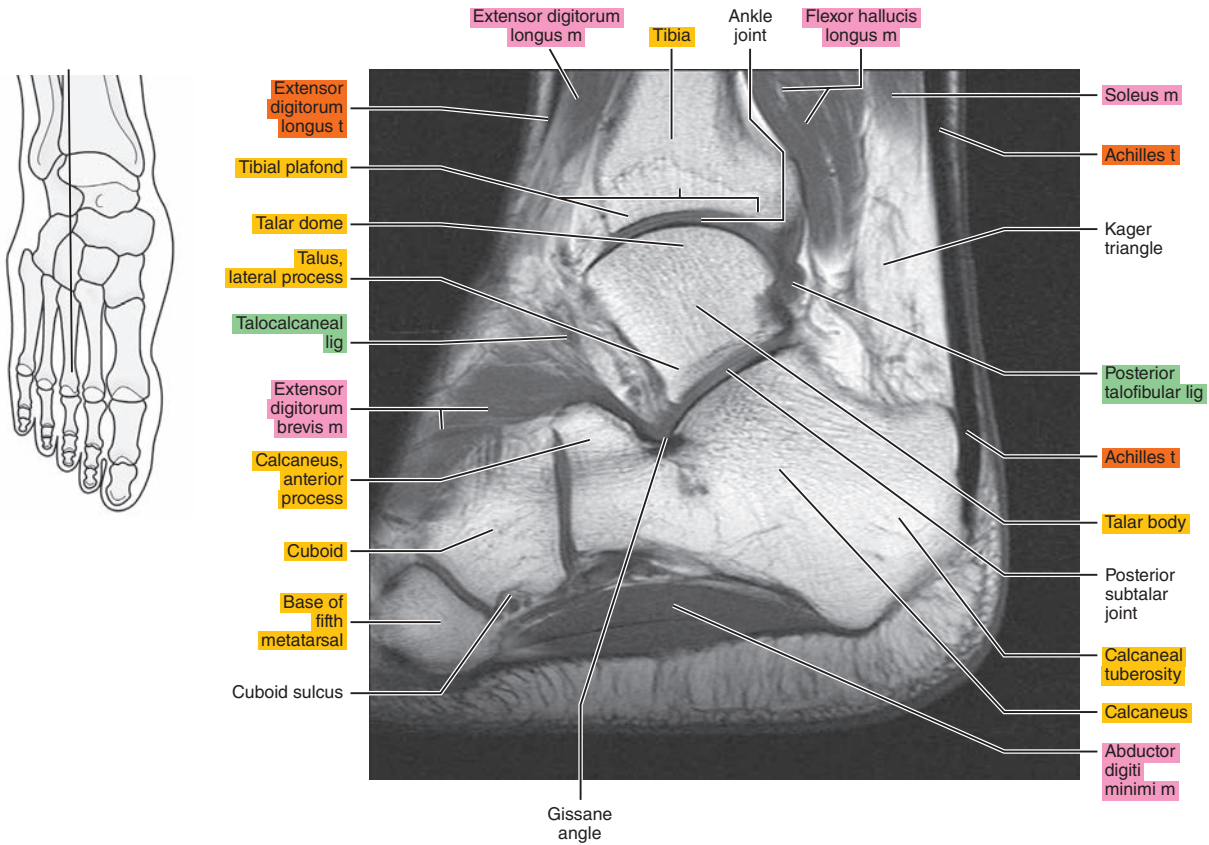


Figure 23.3.6

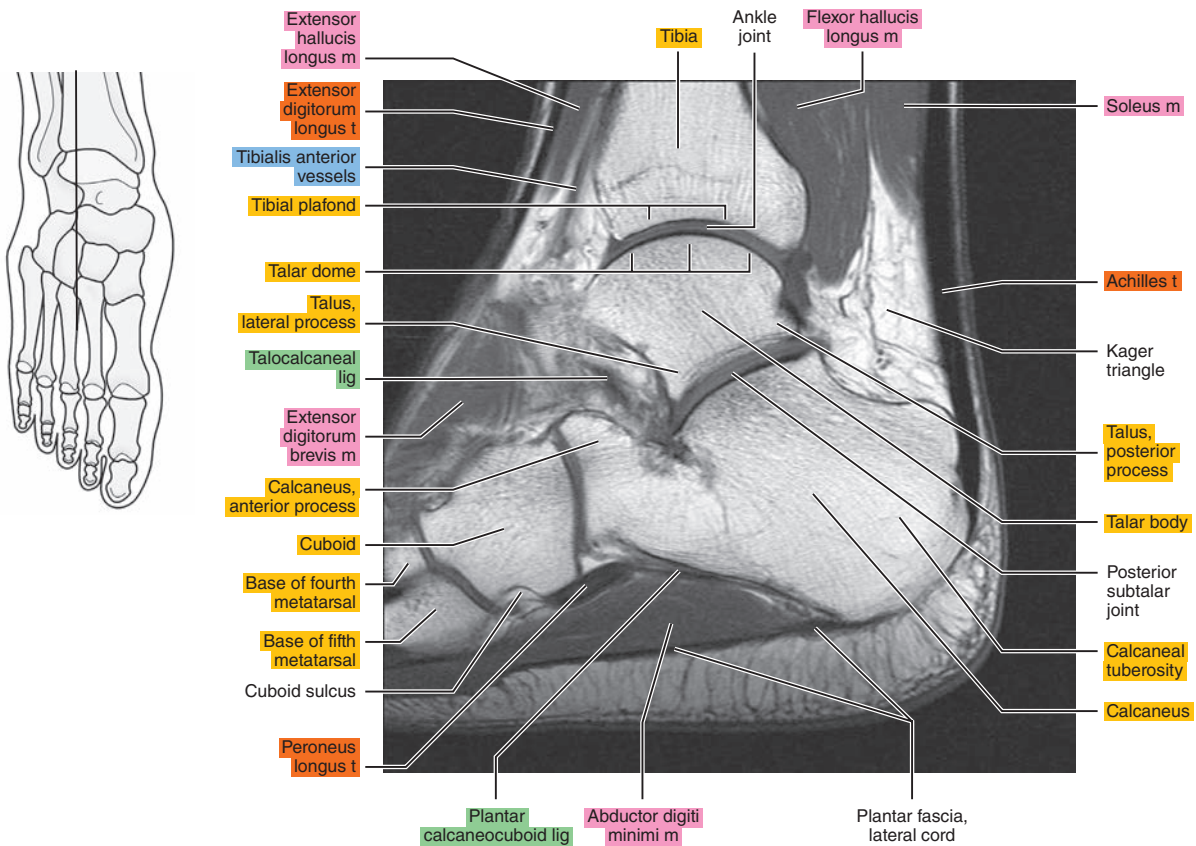




Figure 23.3.7

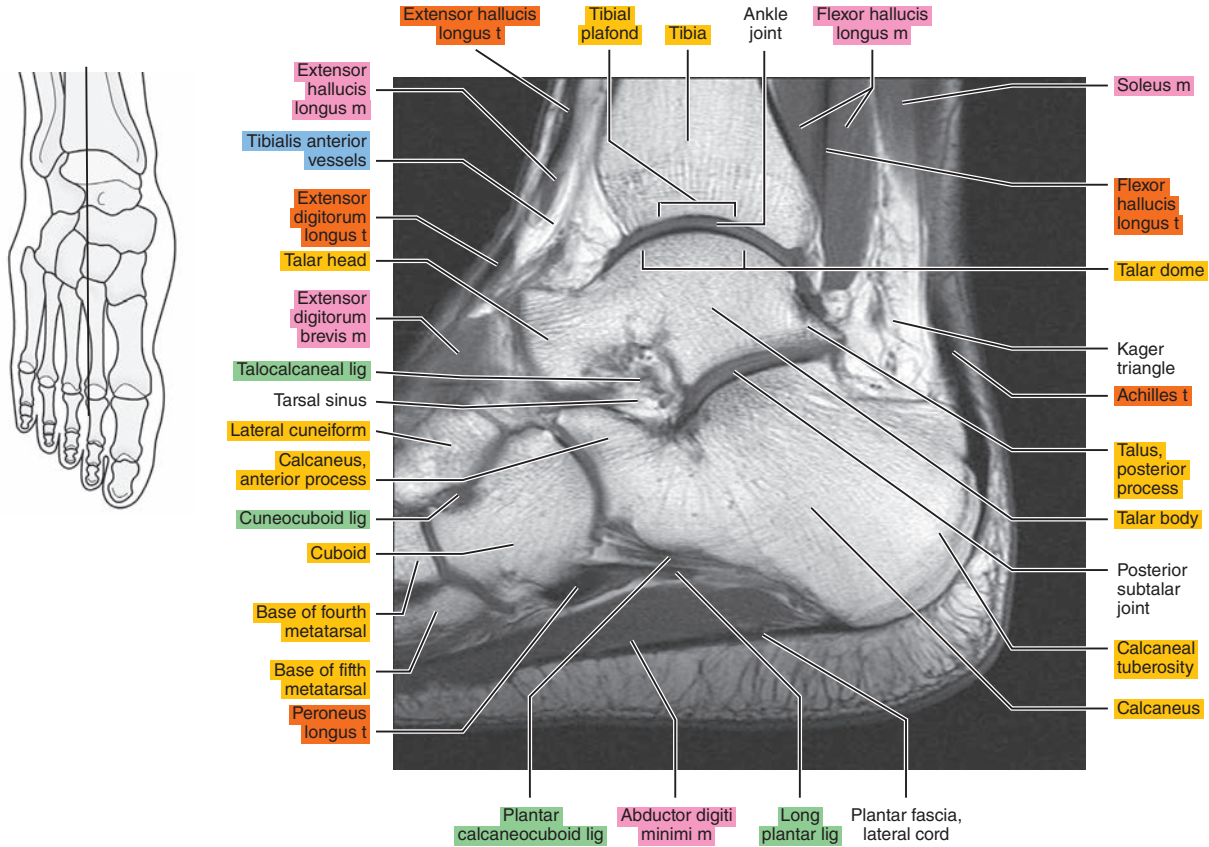


Figure 23.3.8

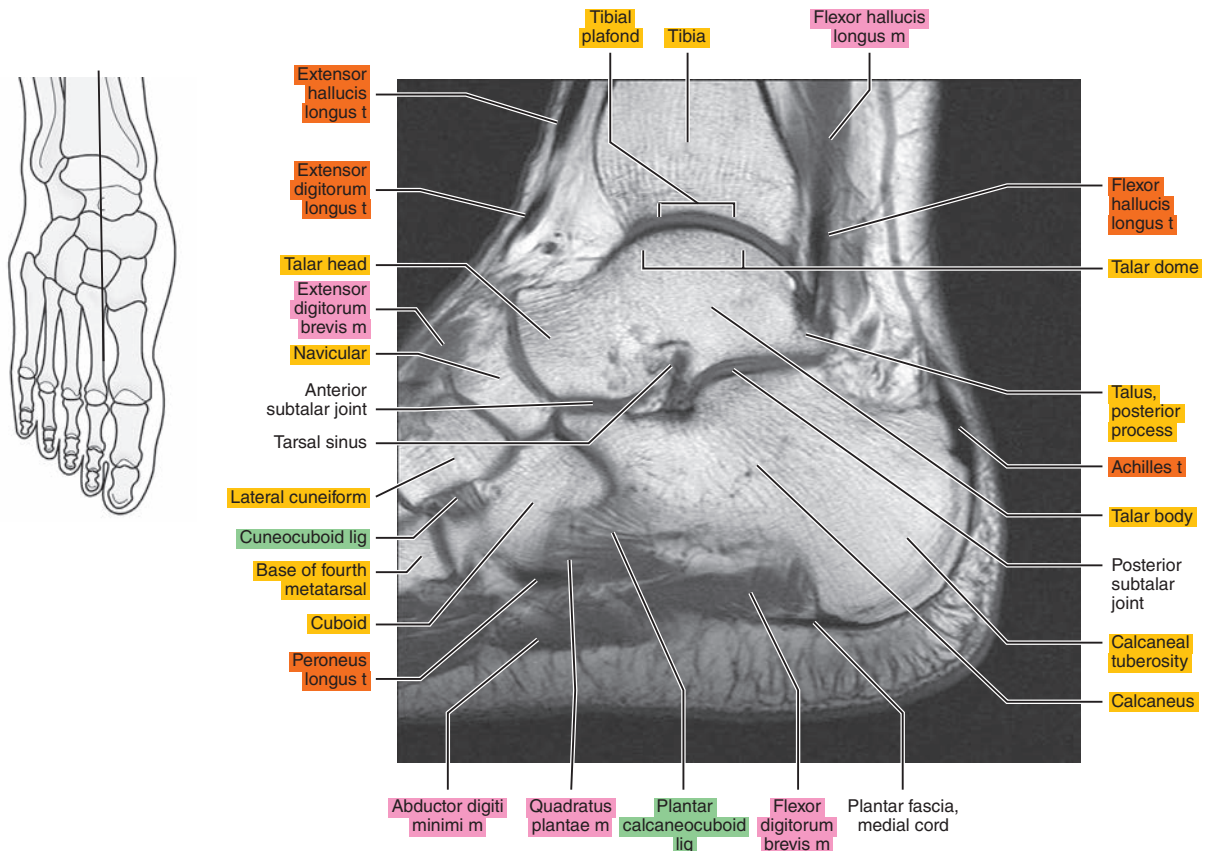


Figure 23.3.9

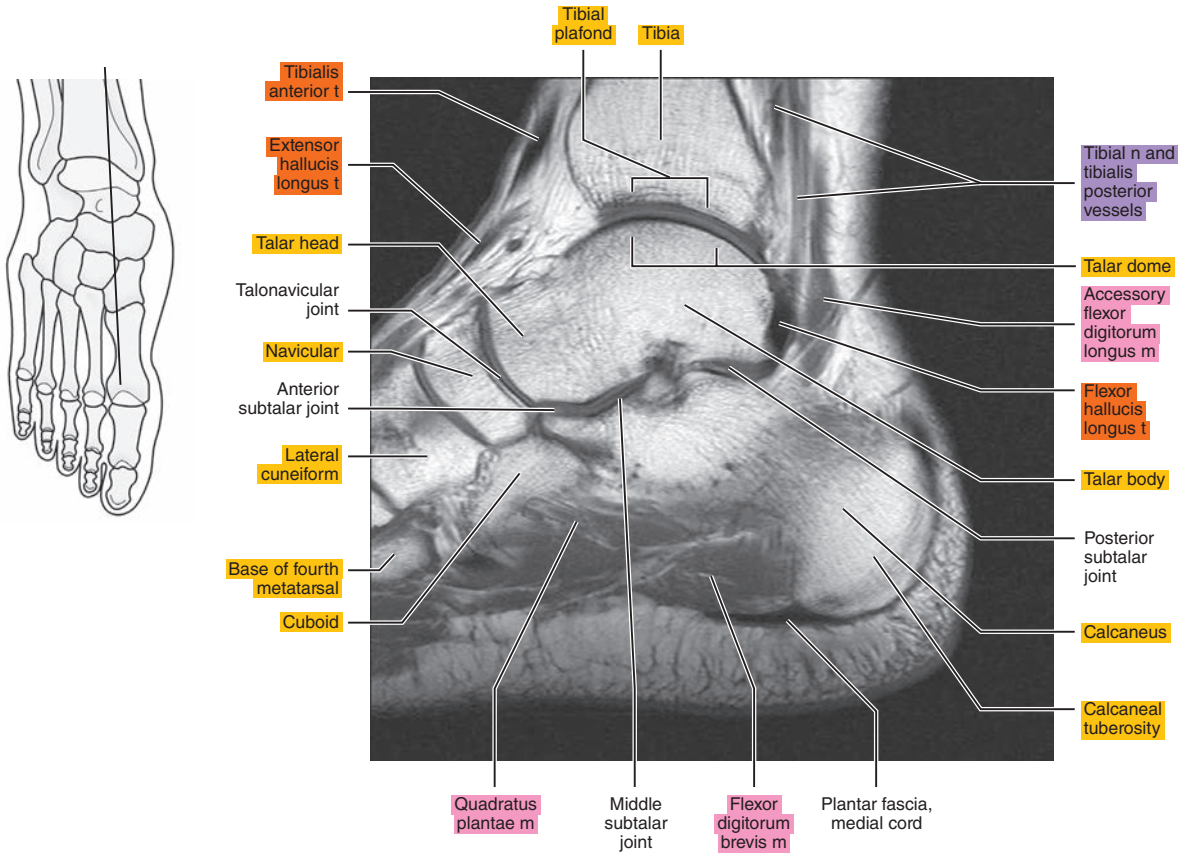


Figure 23.3.10

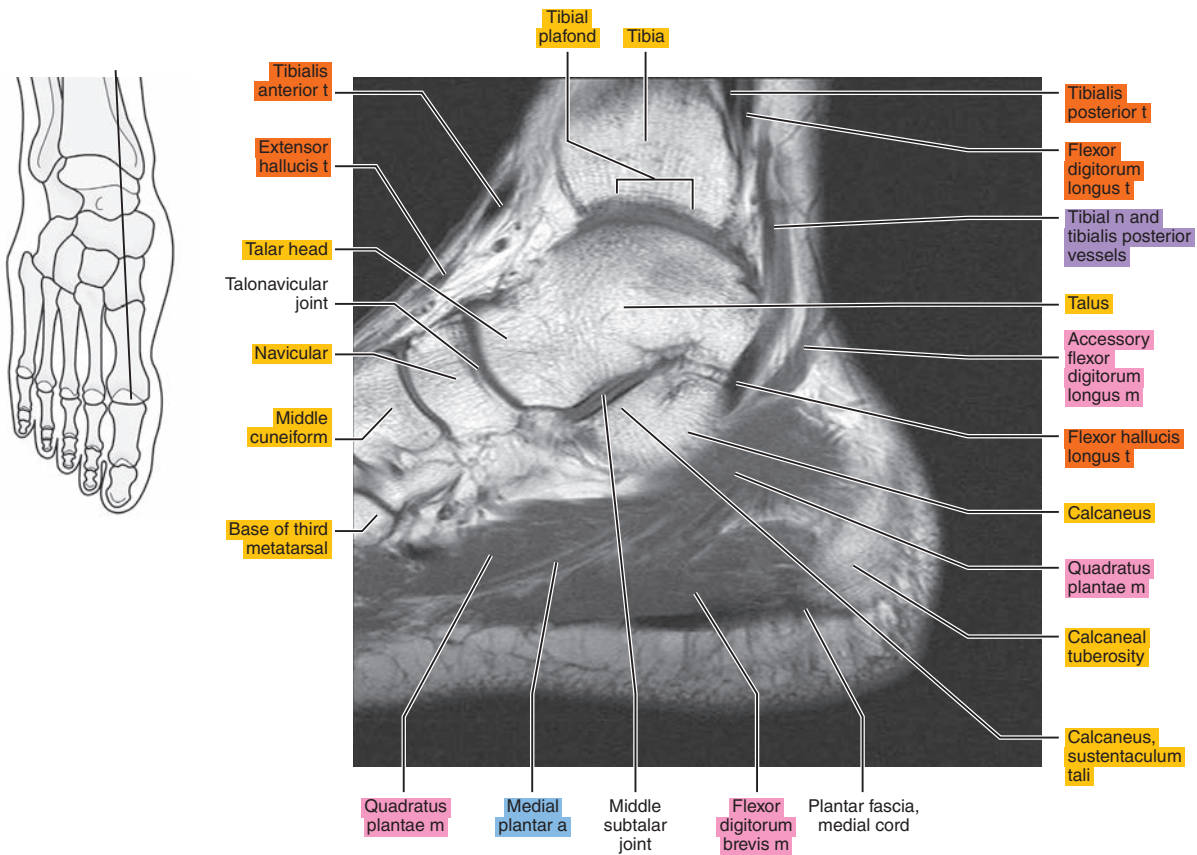




Figure 23.3.11

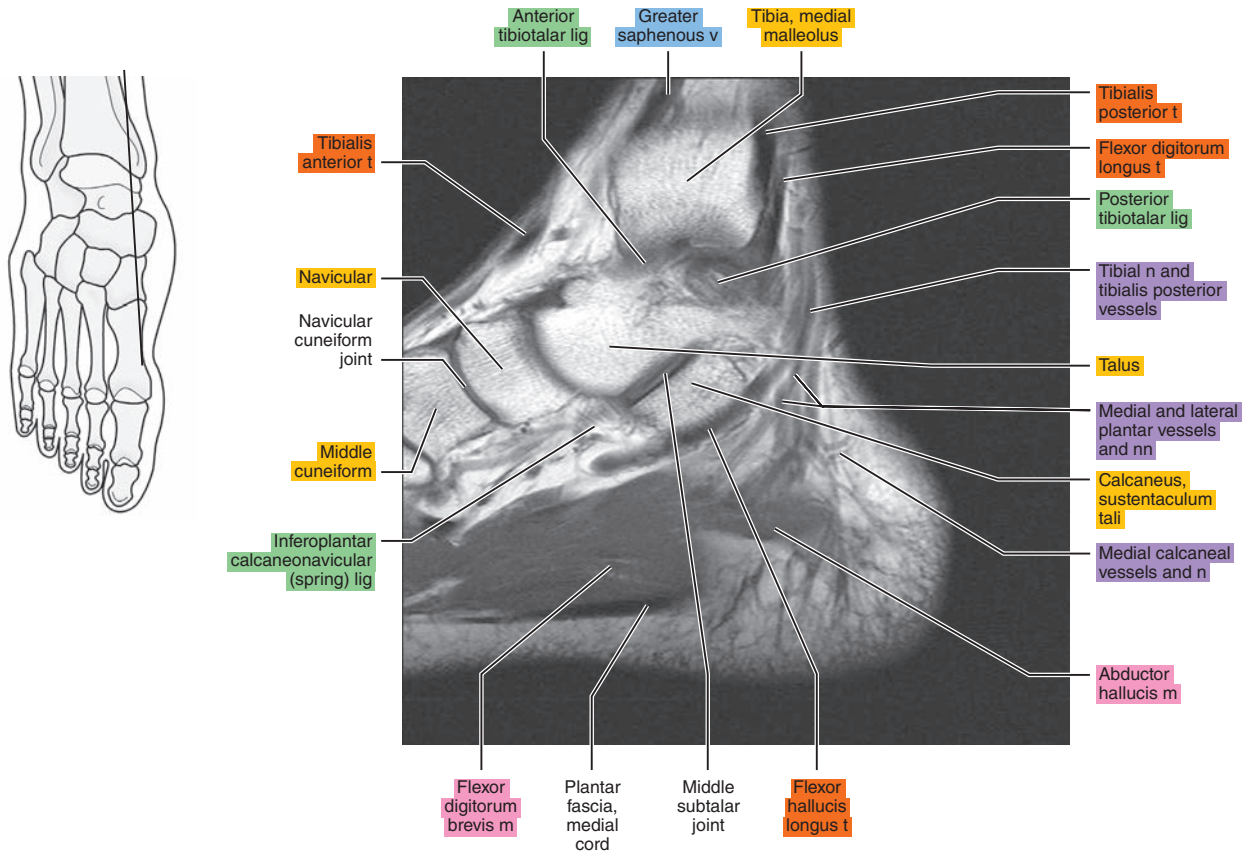


Figure 23.3.12

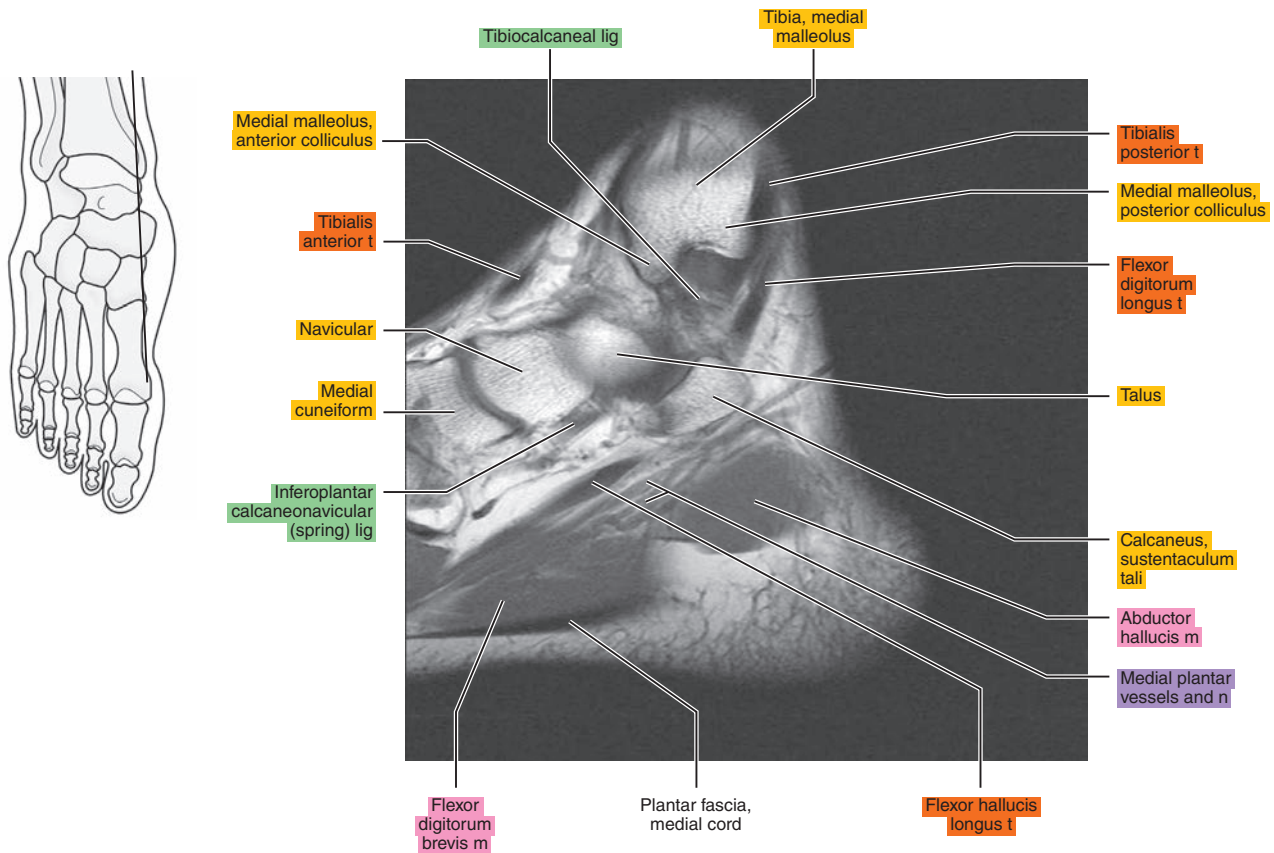
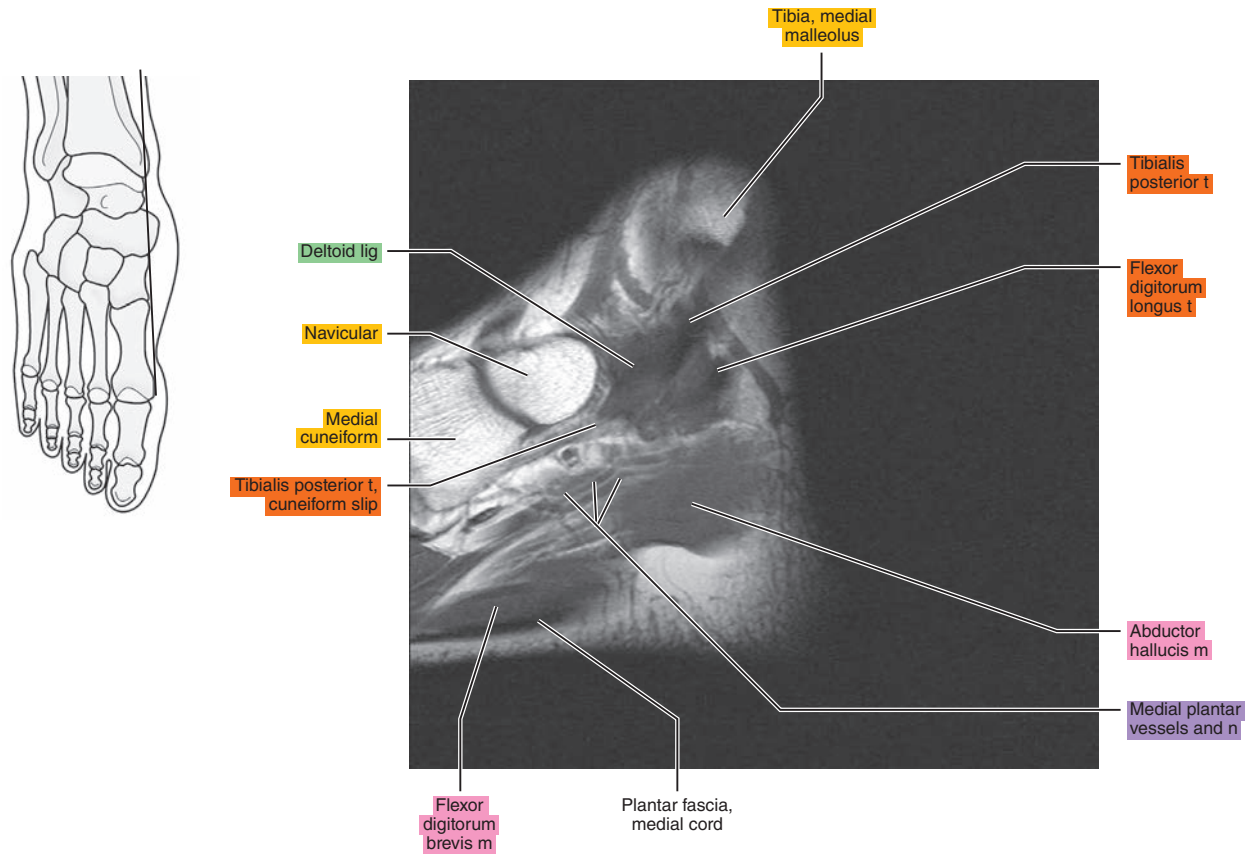


Figure 23.3.13



# CORONAL

Figure 23.4.1

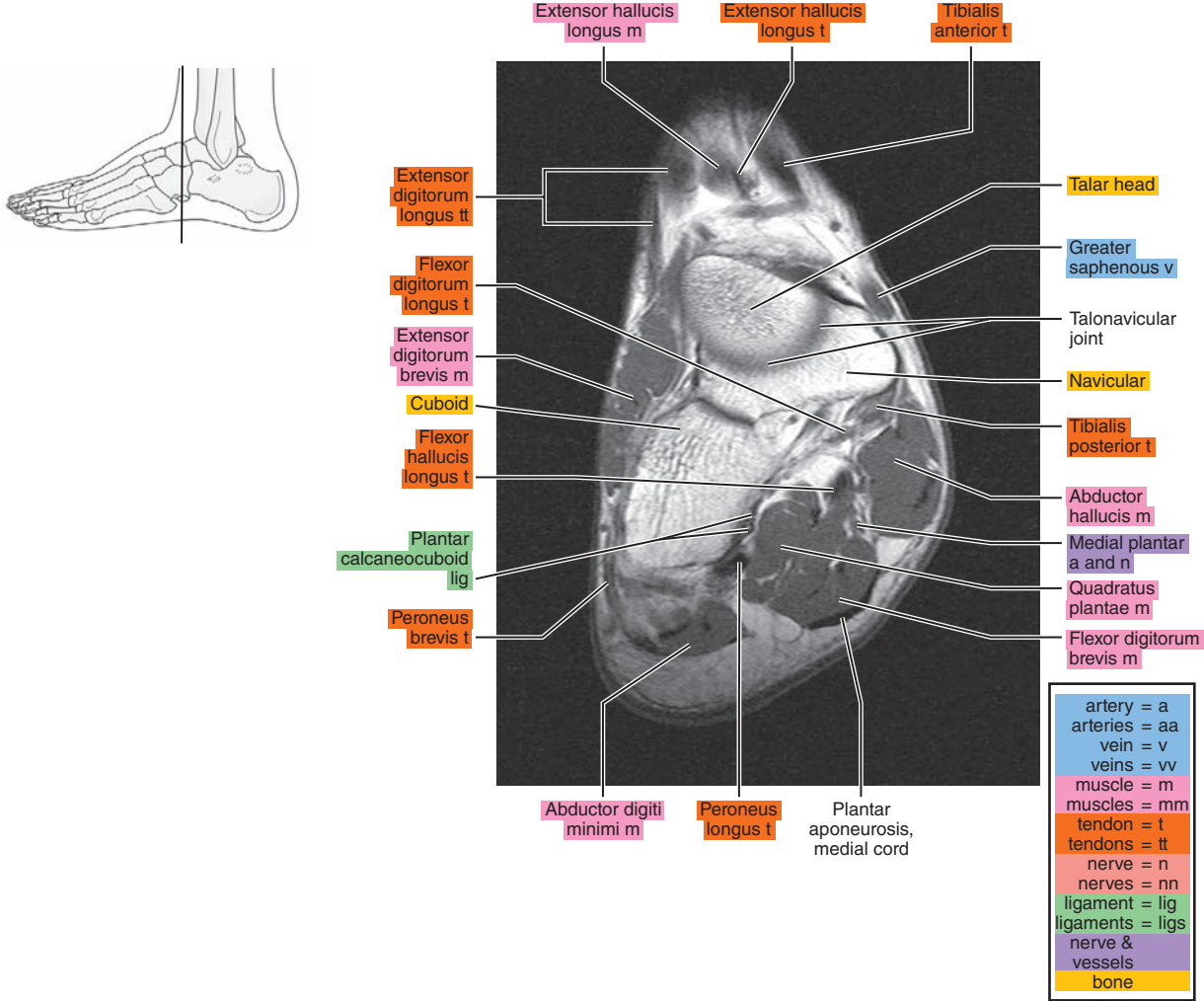


Figure 23.4.2

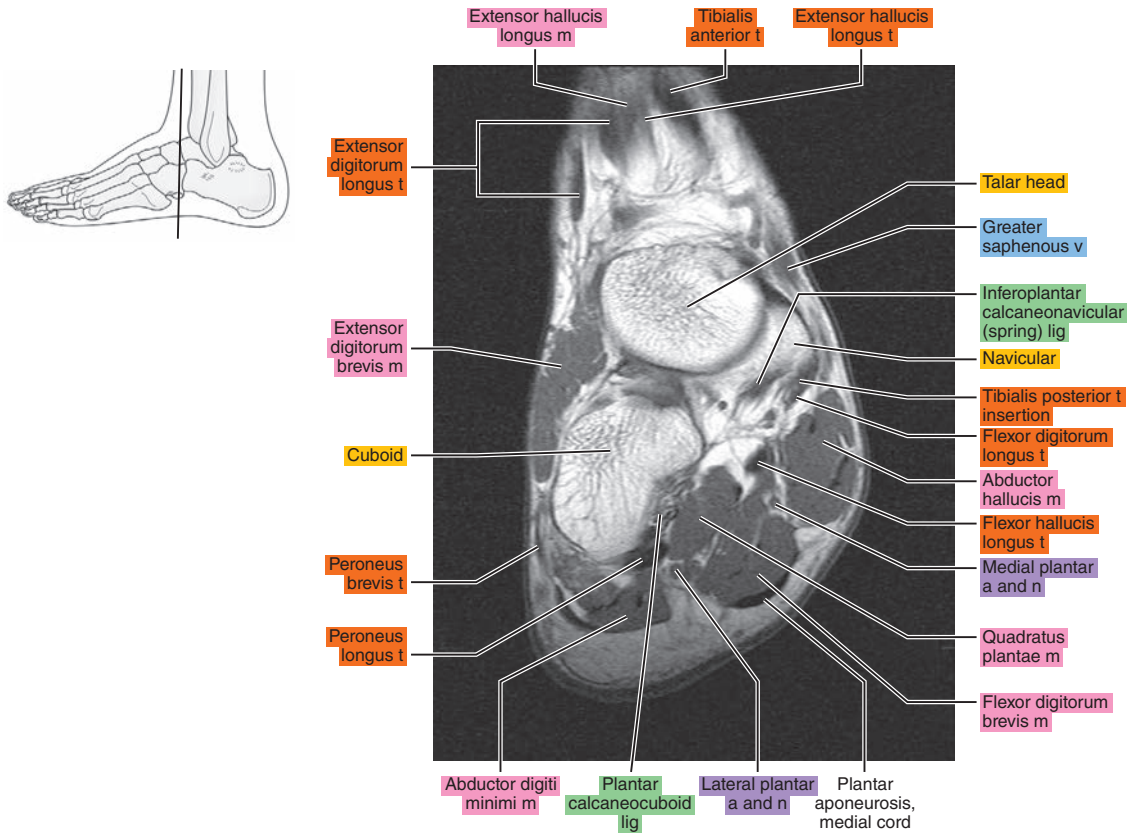


Figure 23.4.3

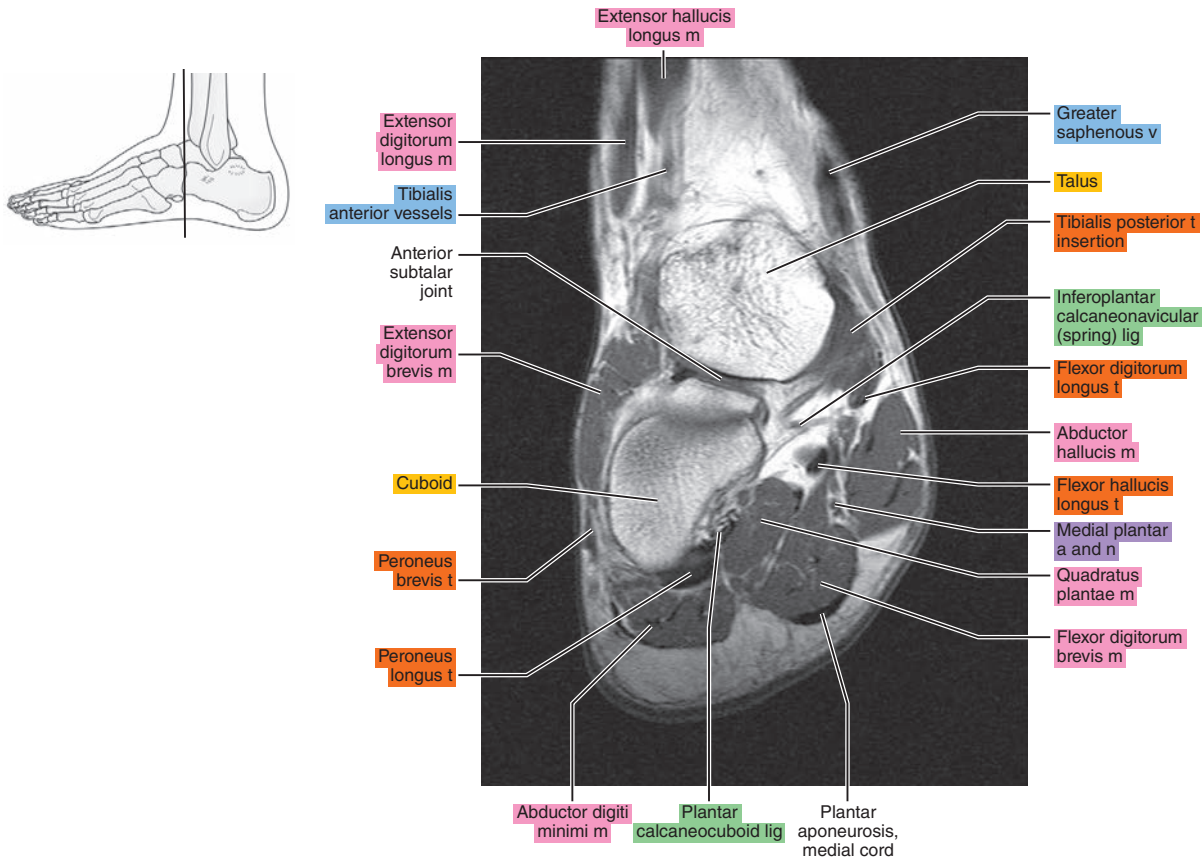




Figure 23.4.4

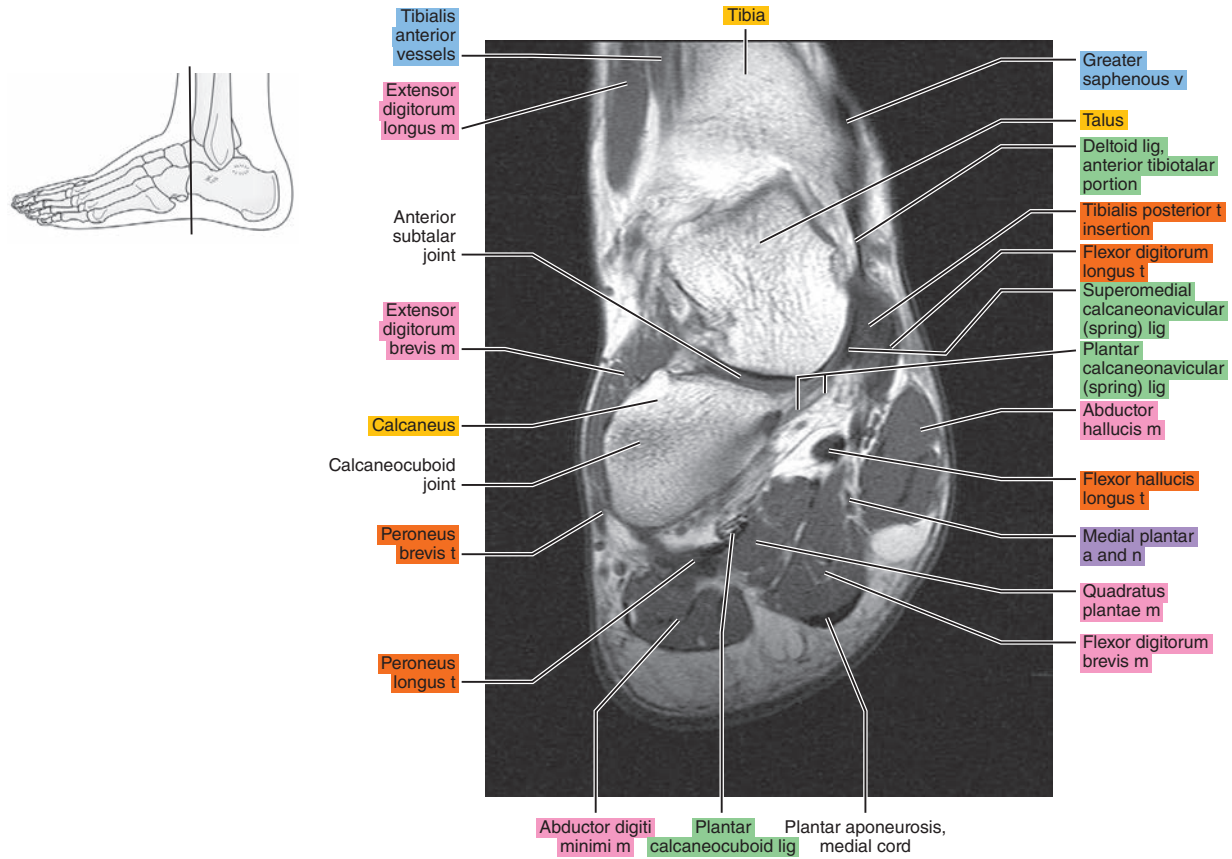


Figure 23.4.5

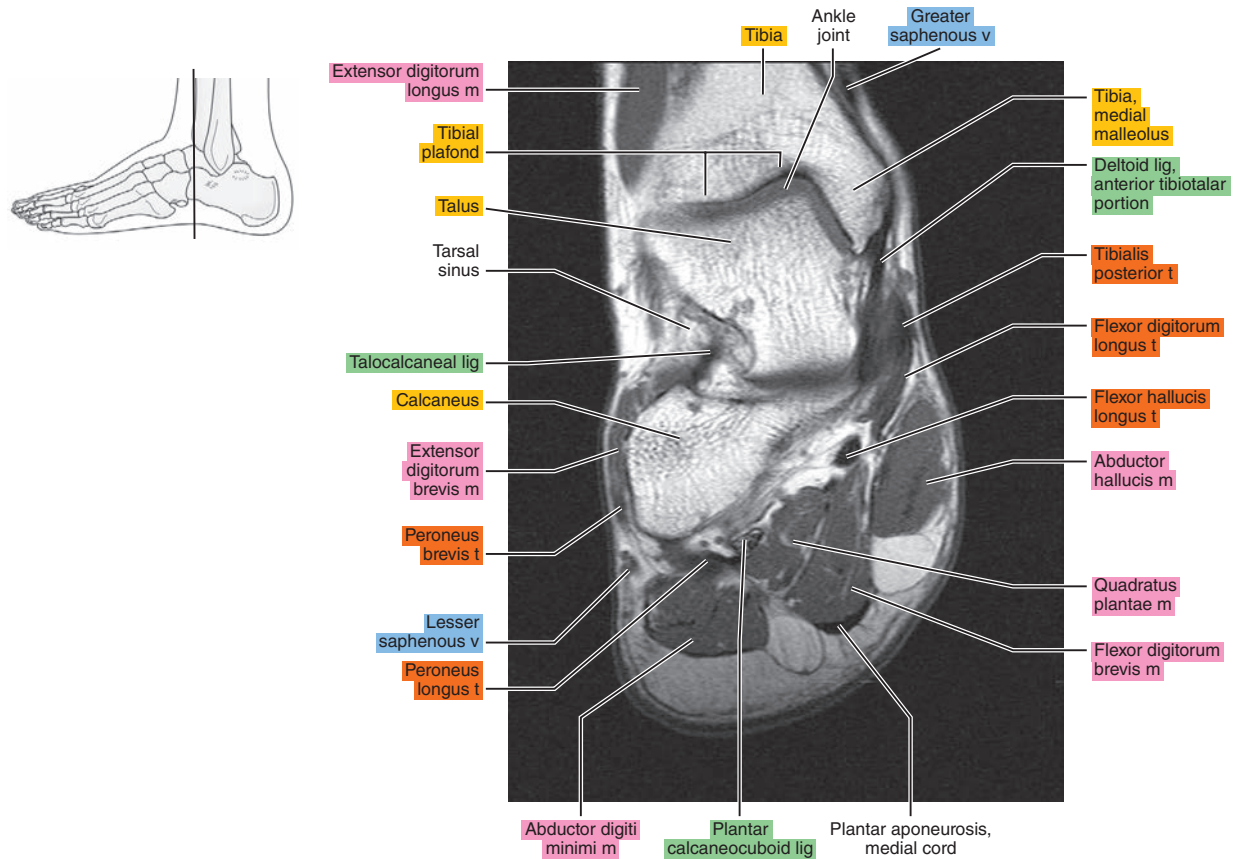


Figure 23.4.6

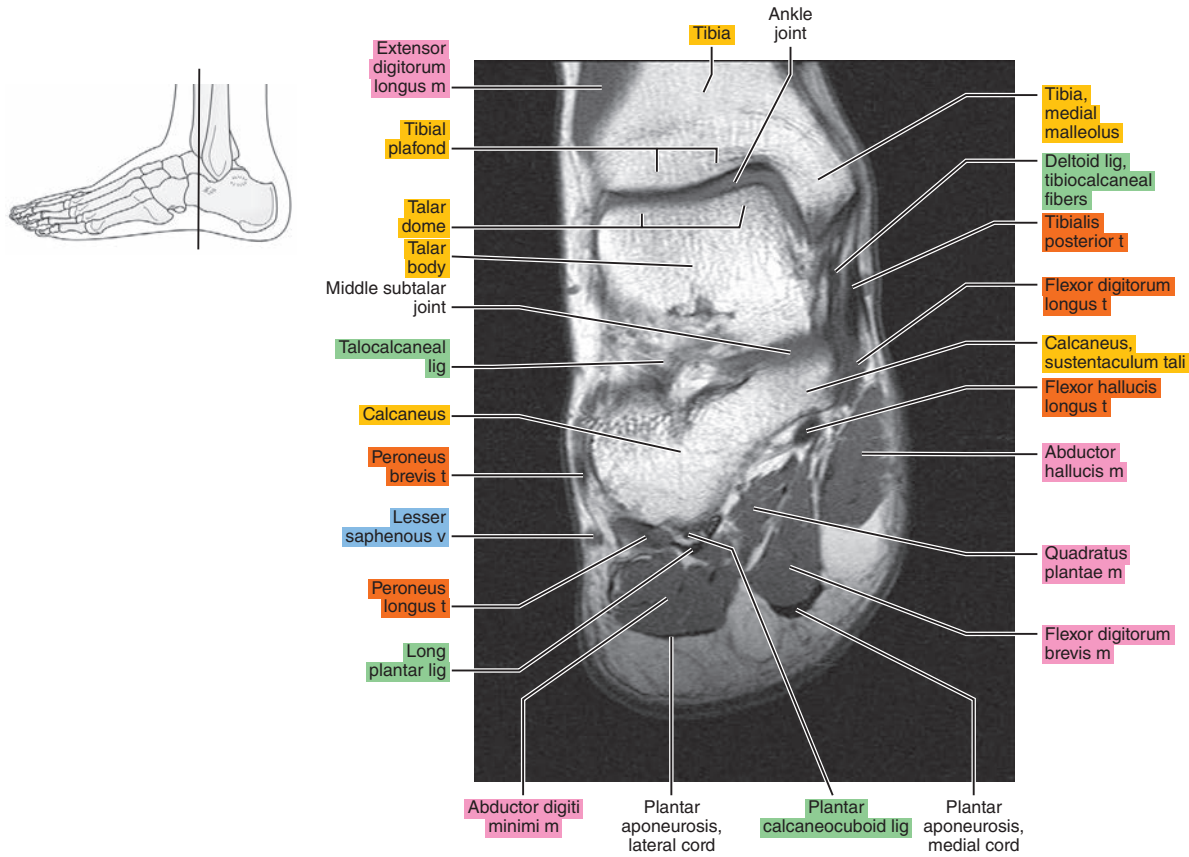


Figure 23.4.7

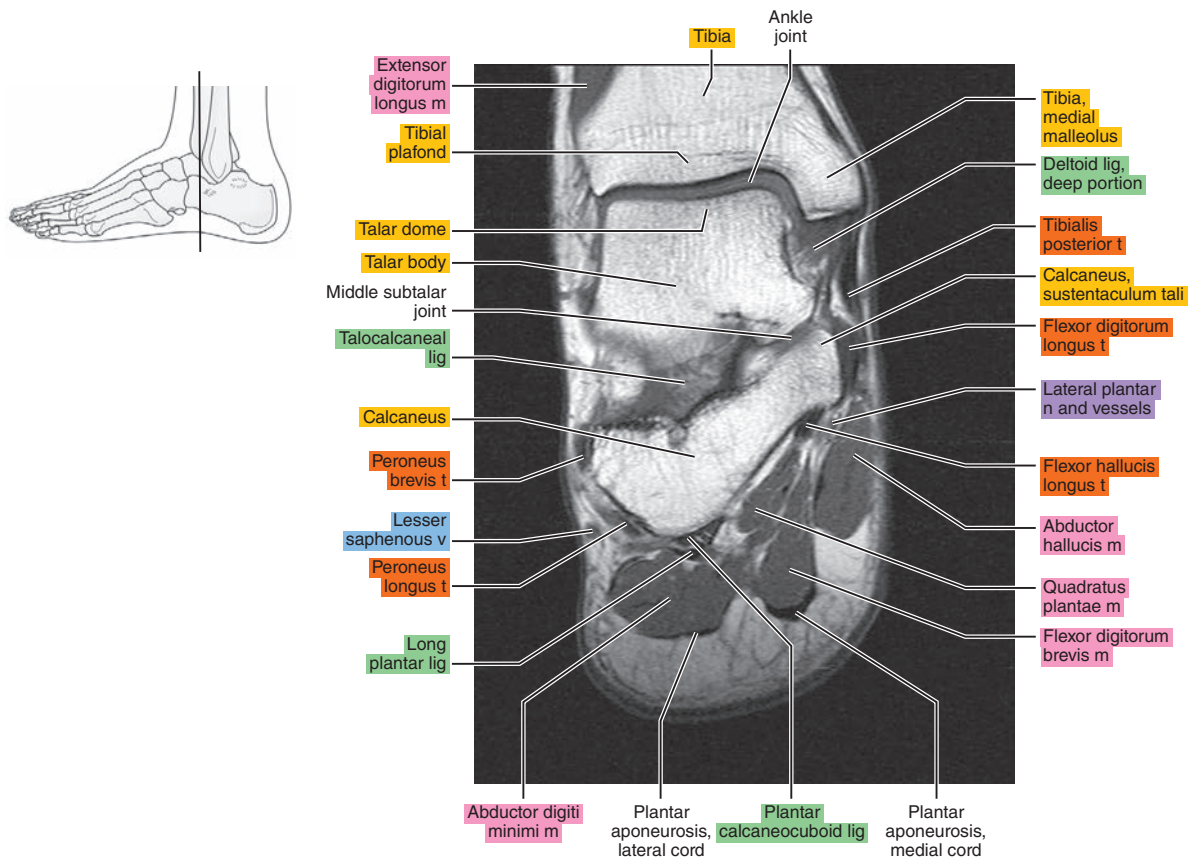


Figure 23.4.8

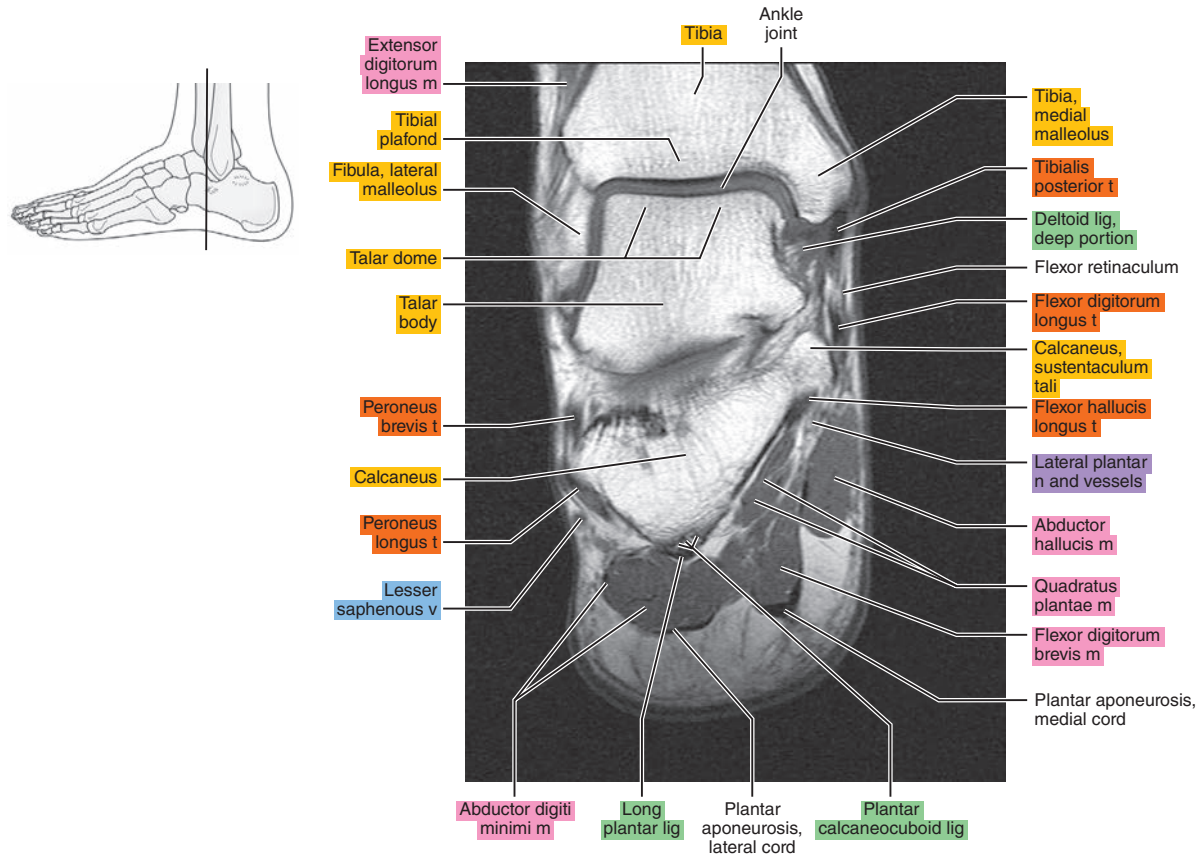


Figure 23.4.9

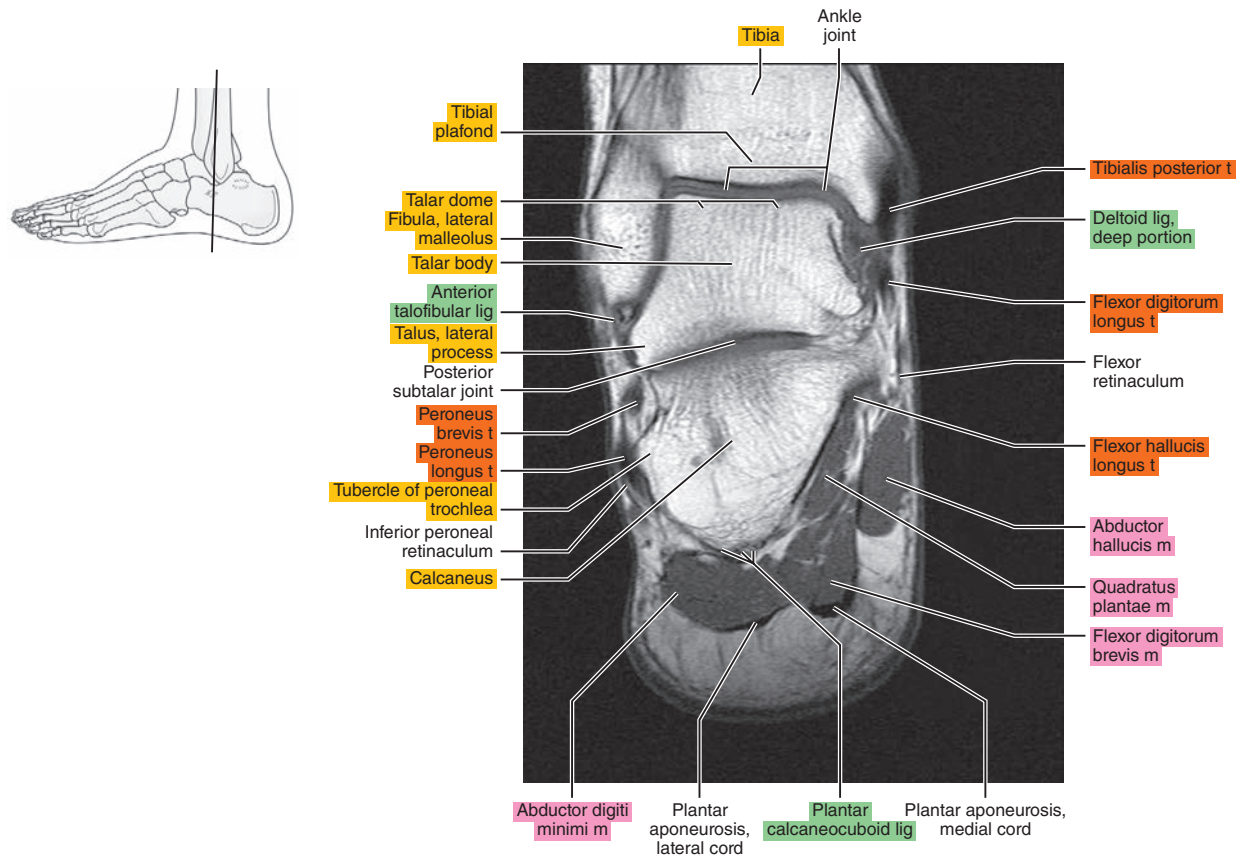




Figure 23.4.10

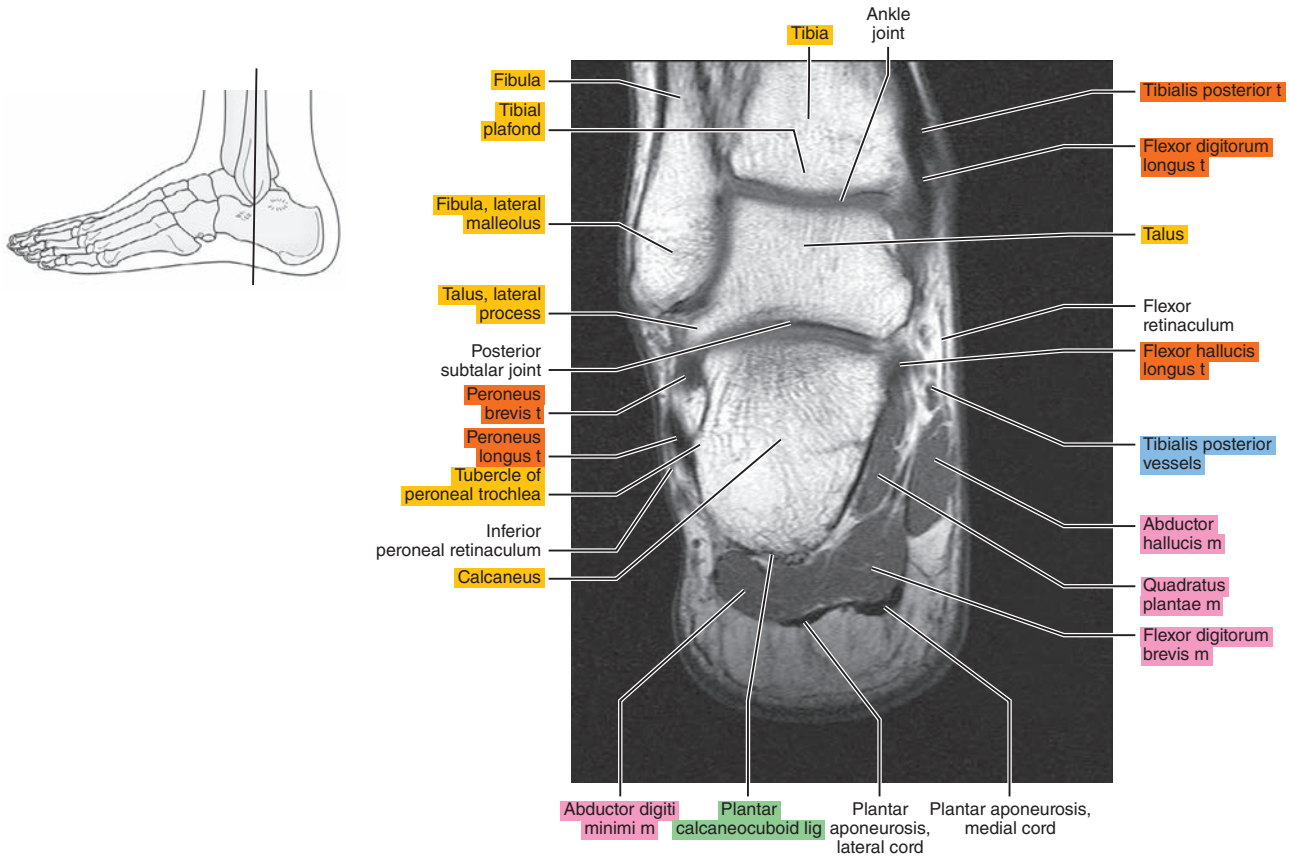


Figure 23.4.11

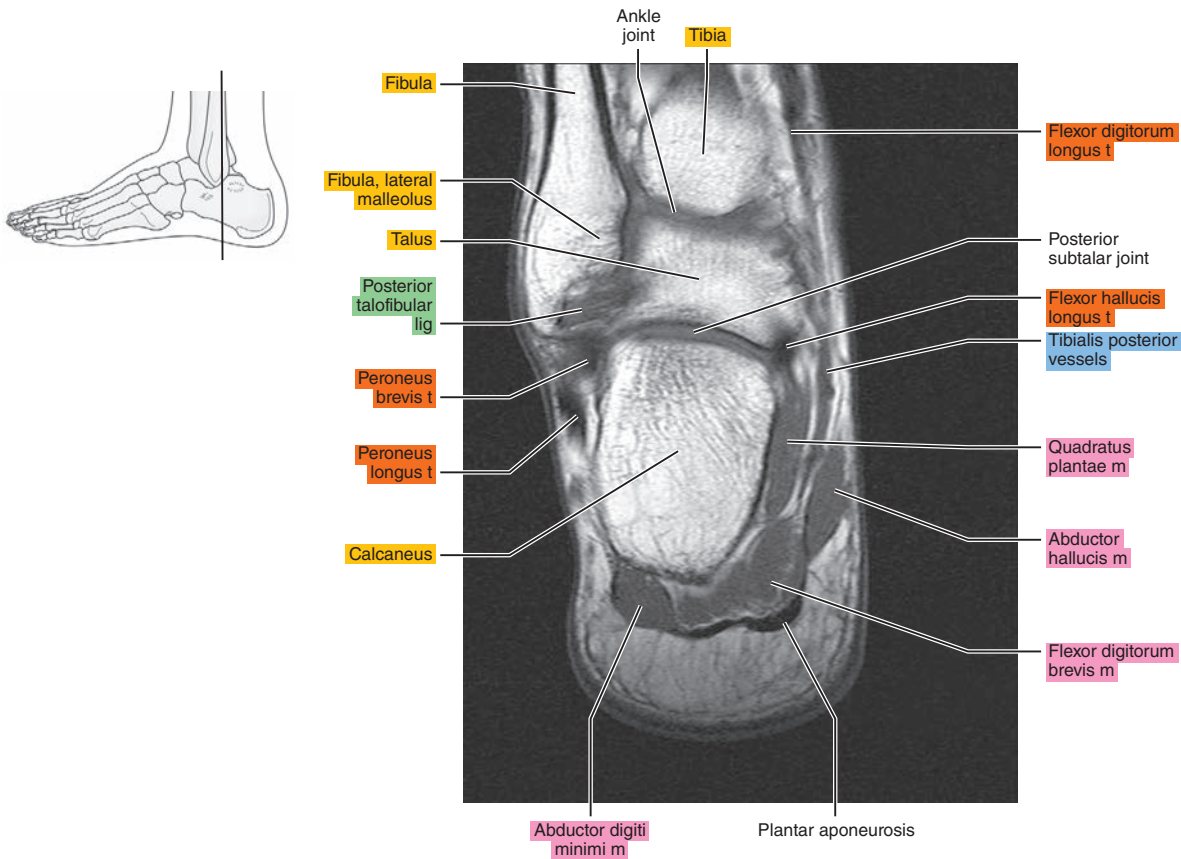




Figure 23.4.12

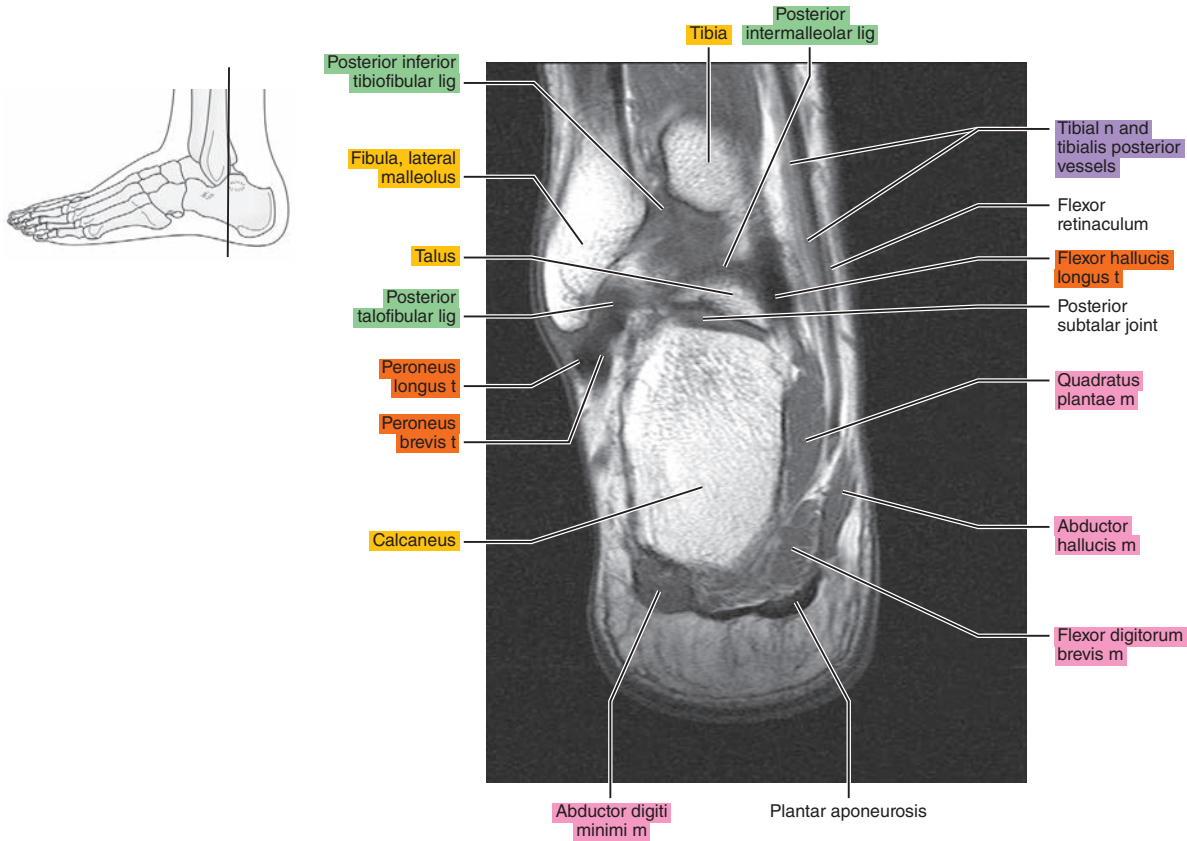


Figure 23.4.13

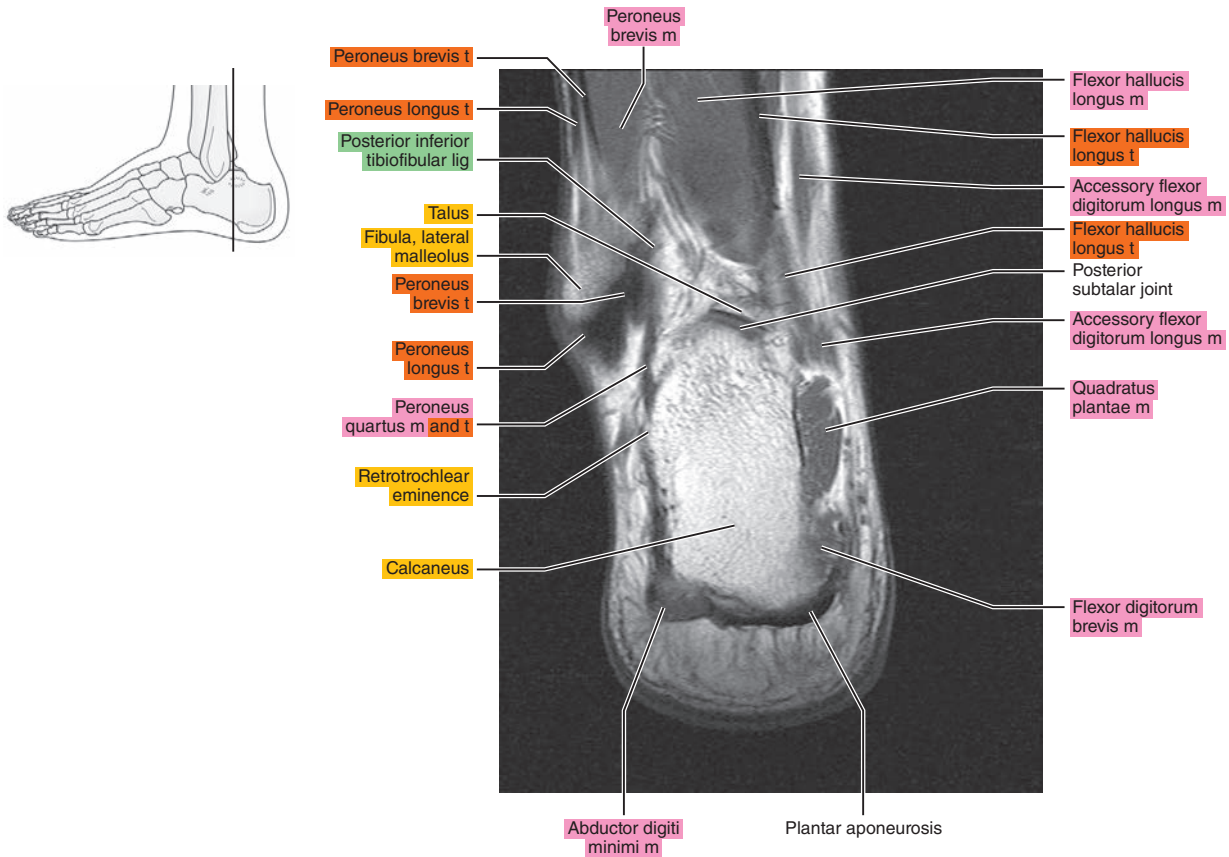


Figure 23.4.14

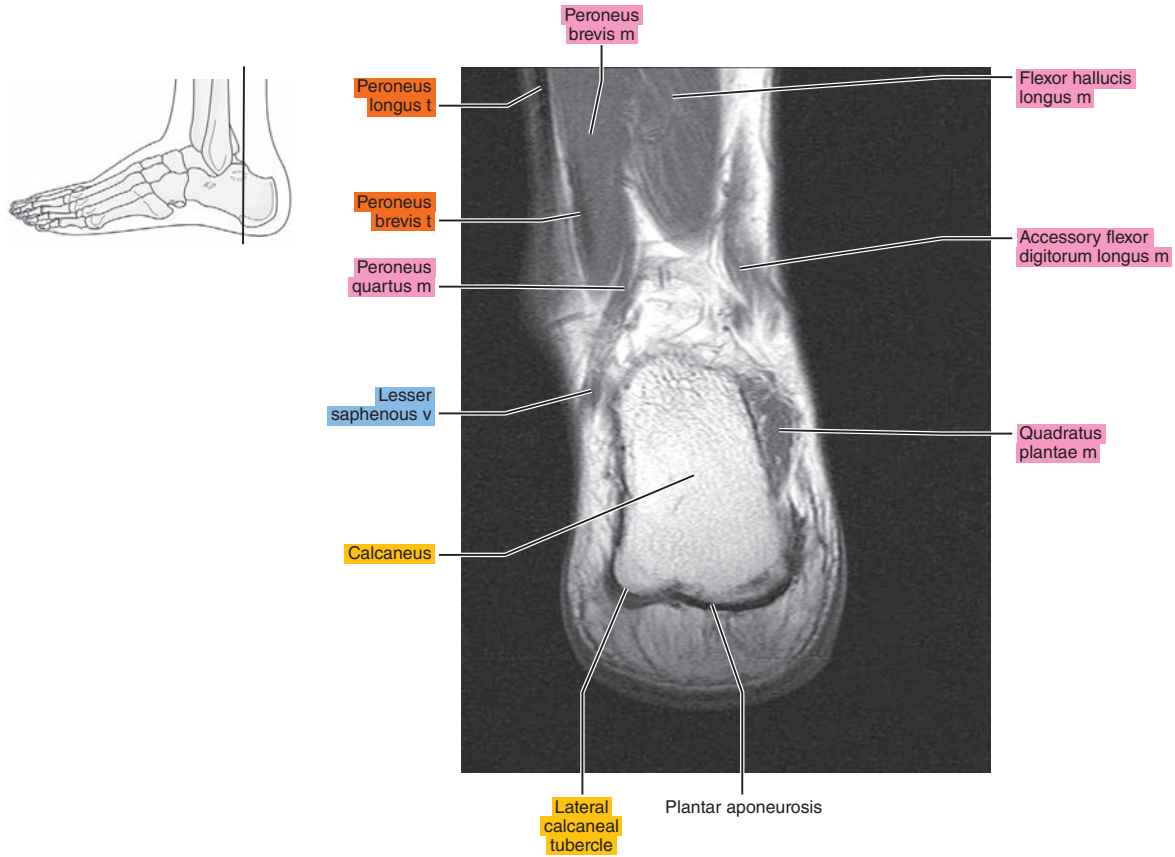


Figure 23.4.15

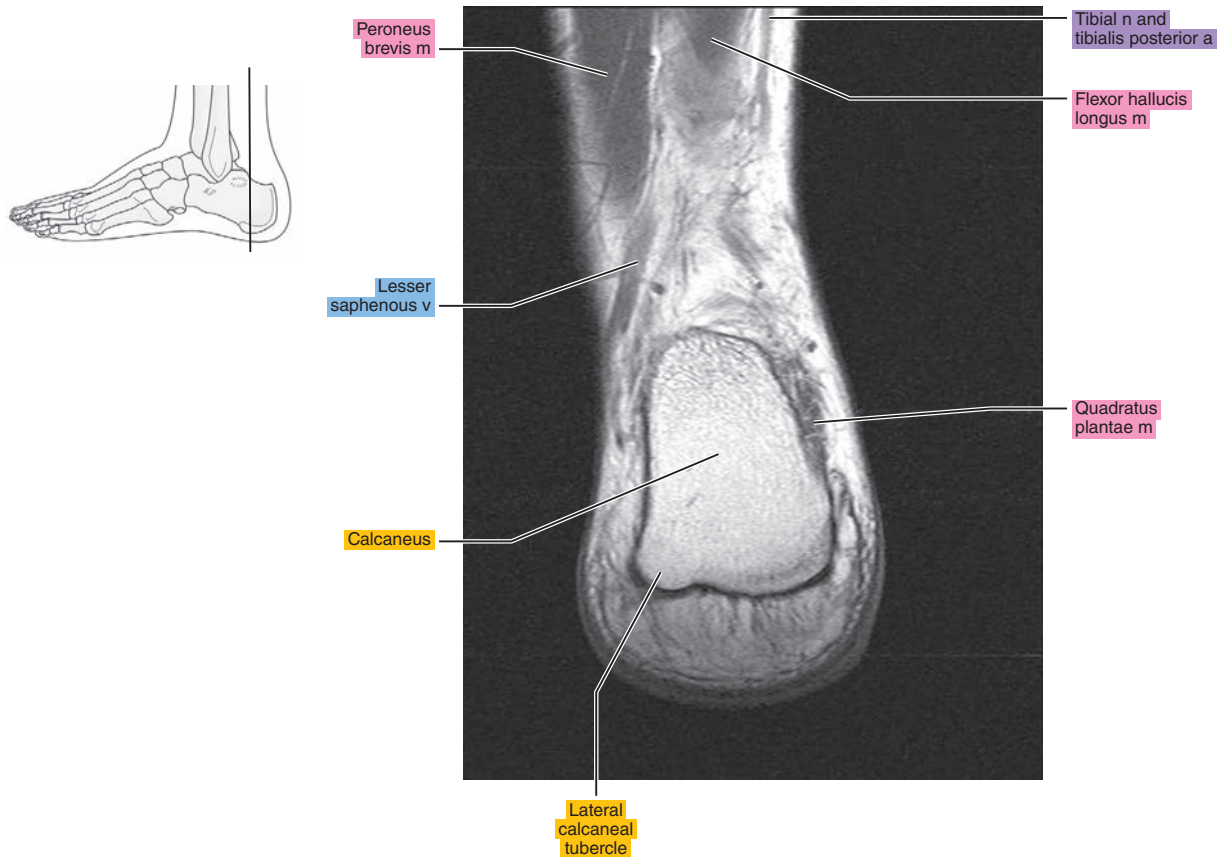


Figure 23.4.16

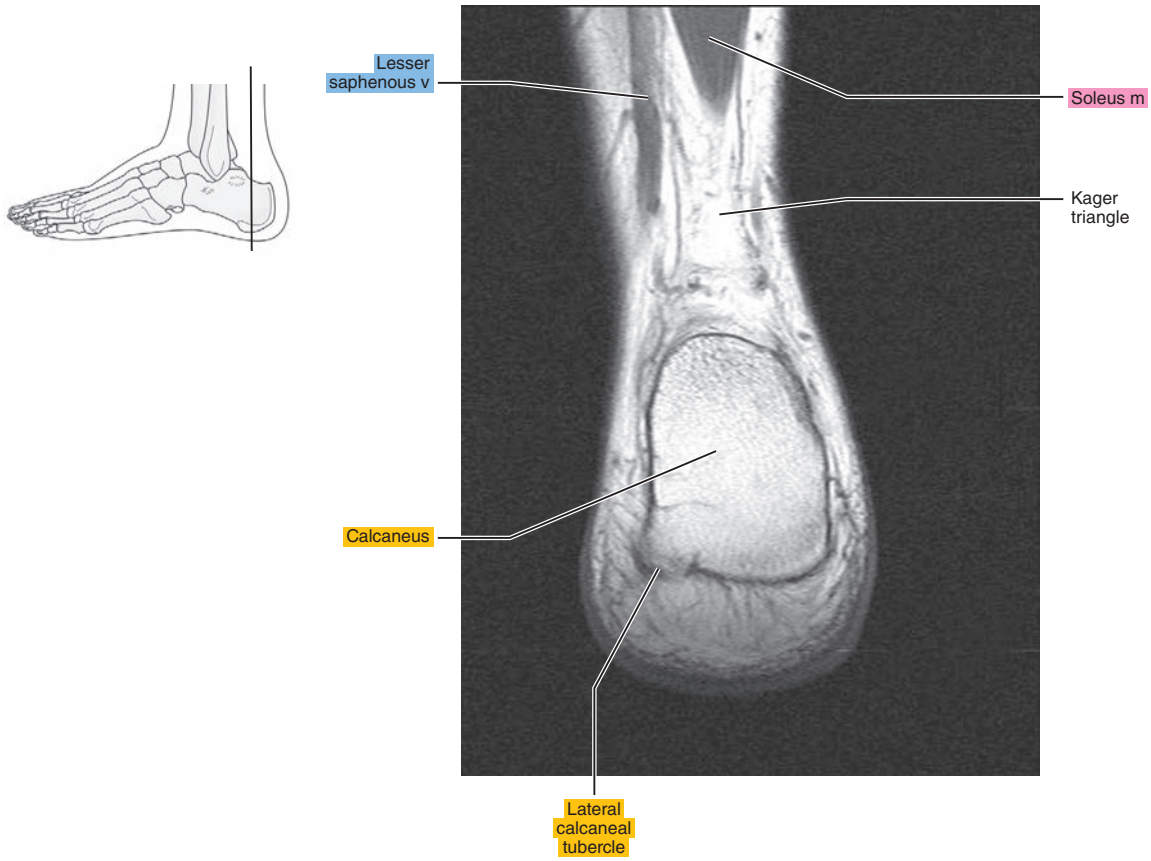


Figure 23.4.17

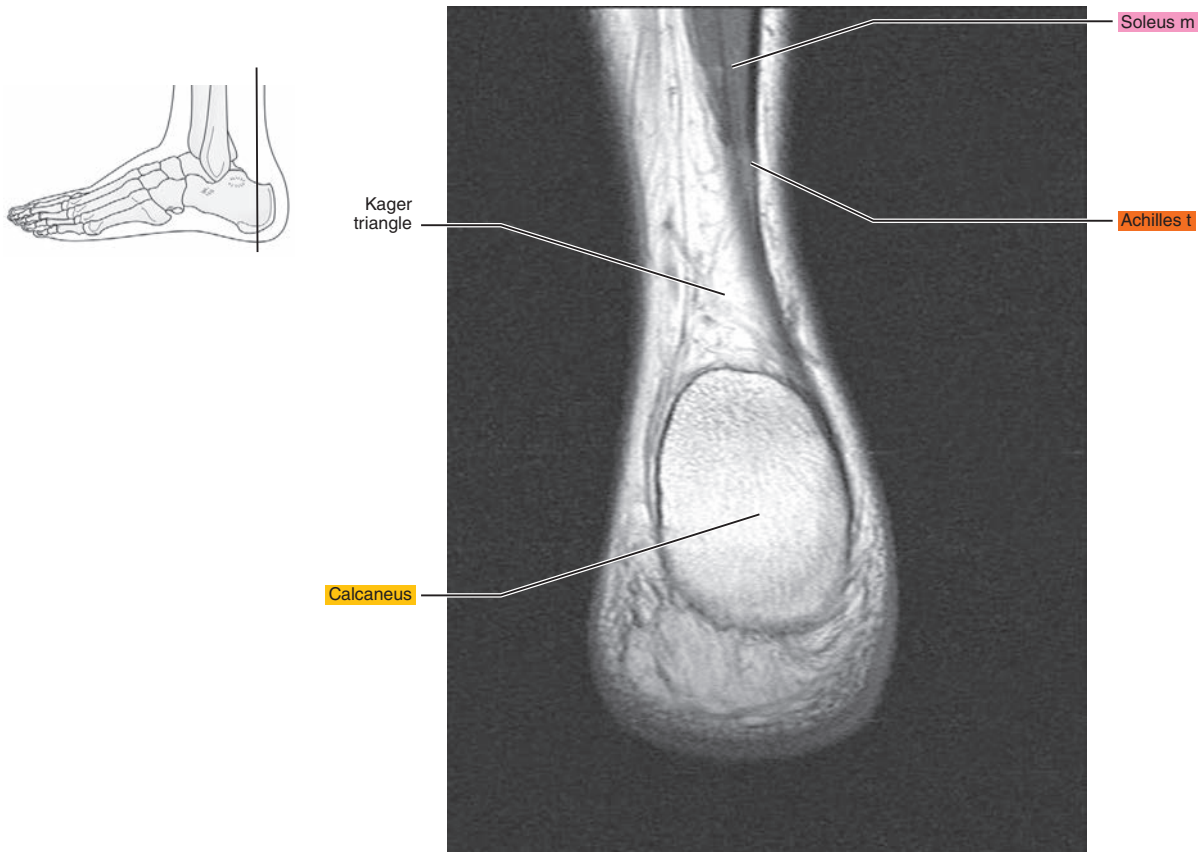
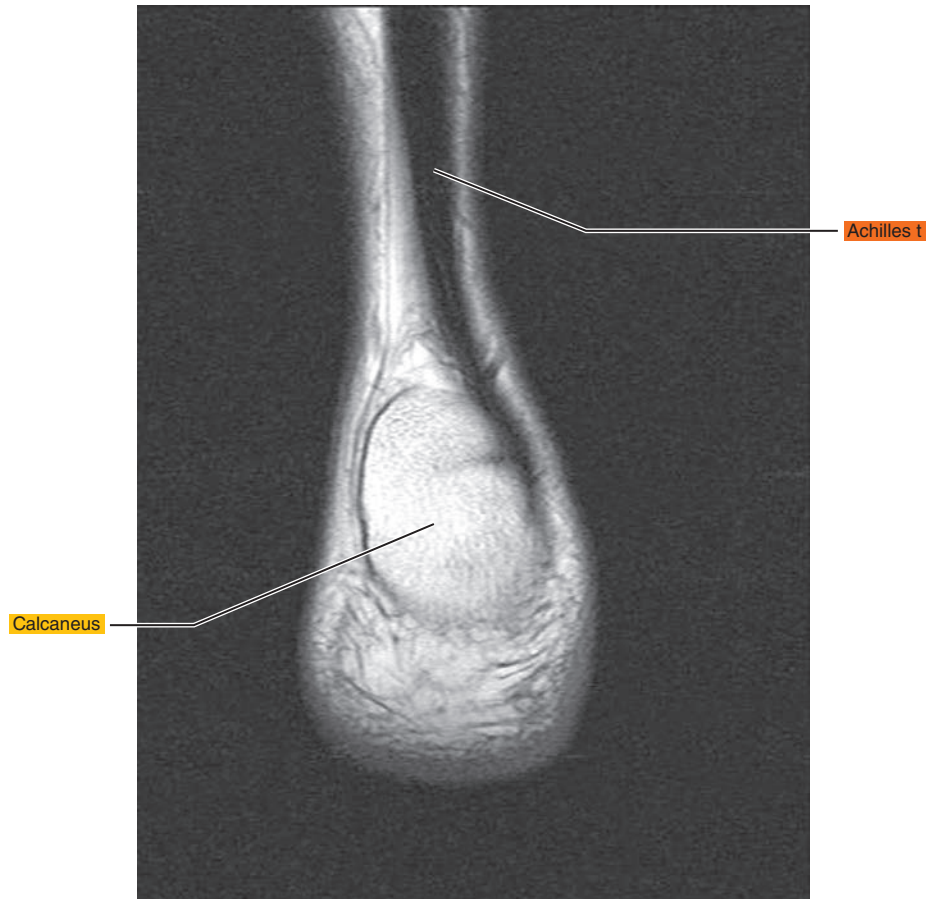
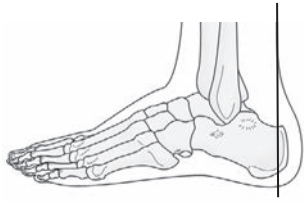

Figure 23.4.18





*Chapter*  
**24**

**MRI of the Foot**

# AXIAL

Figure 24.1.1

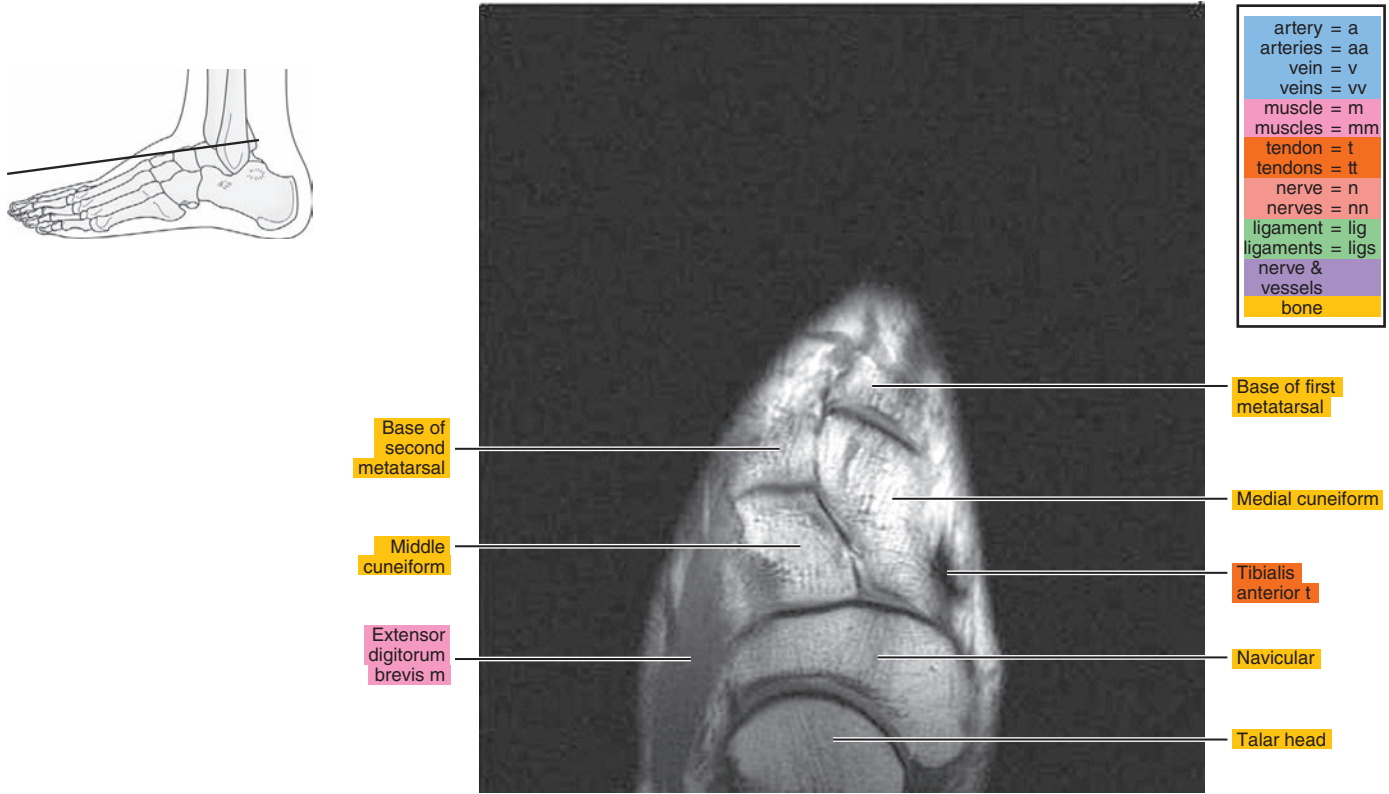


Figure 24.1.2

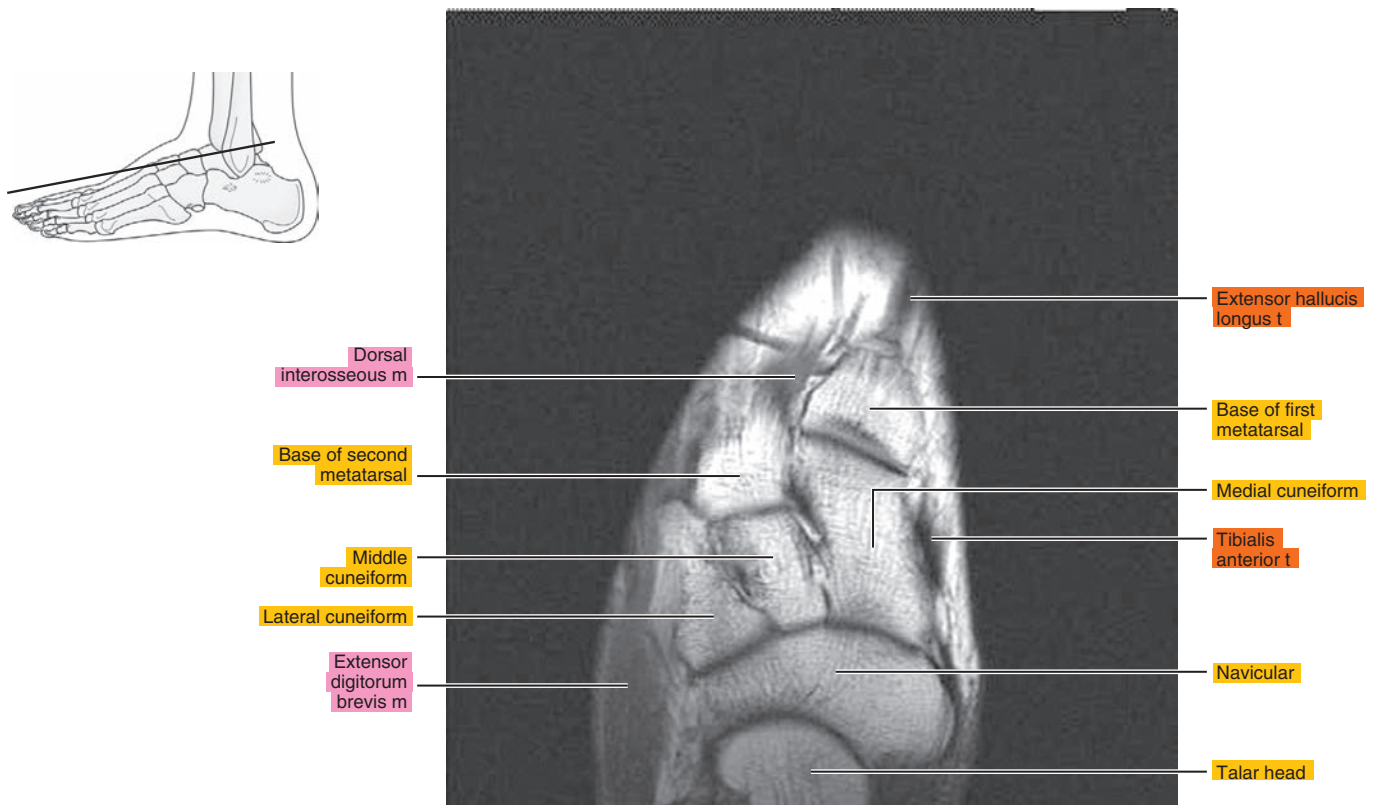


Figure 24.1.3

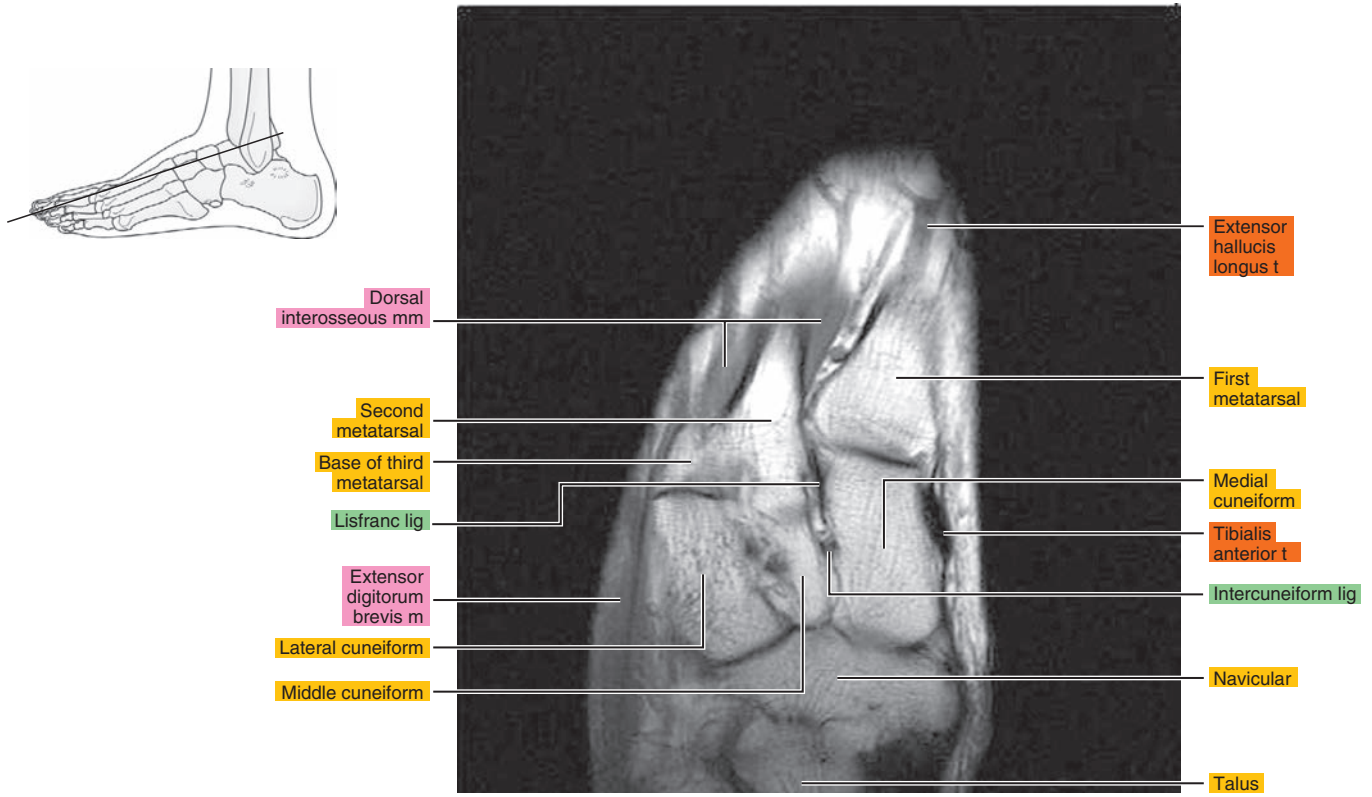


Figure 24.1.4

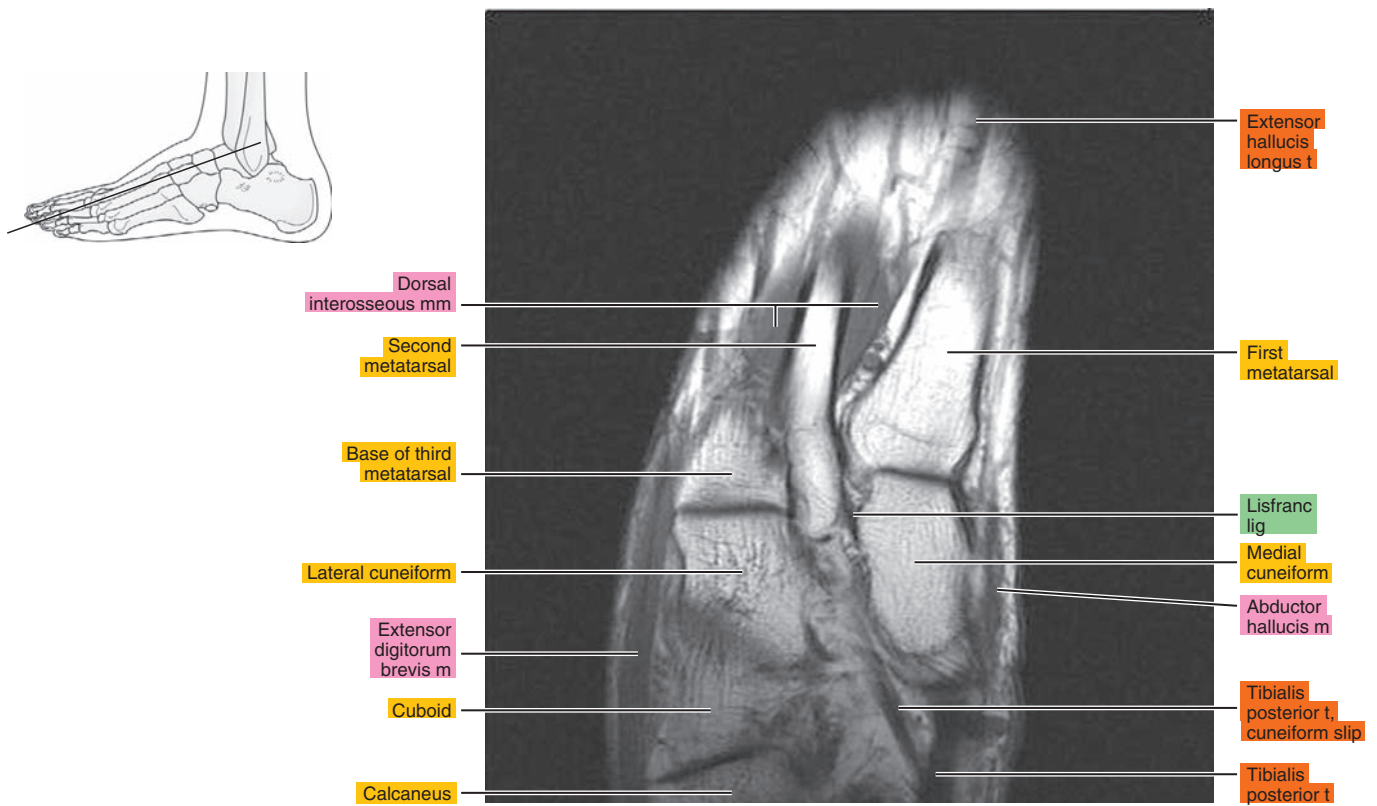


Figure 24.1.5

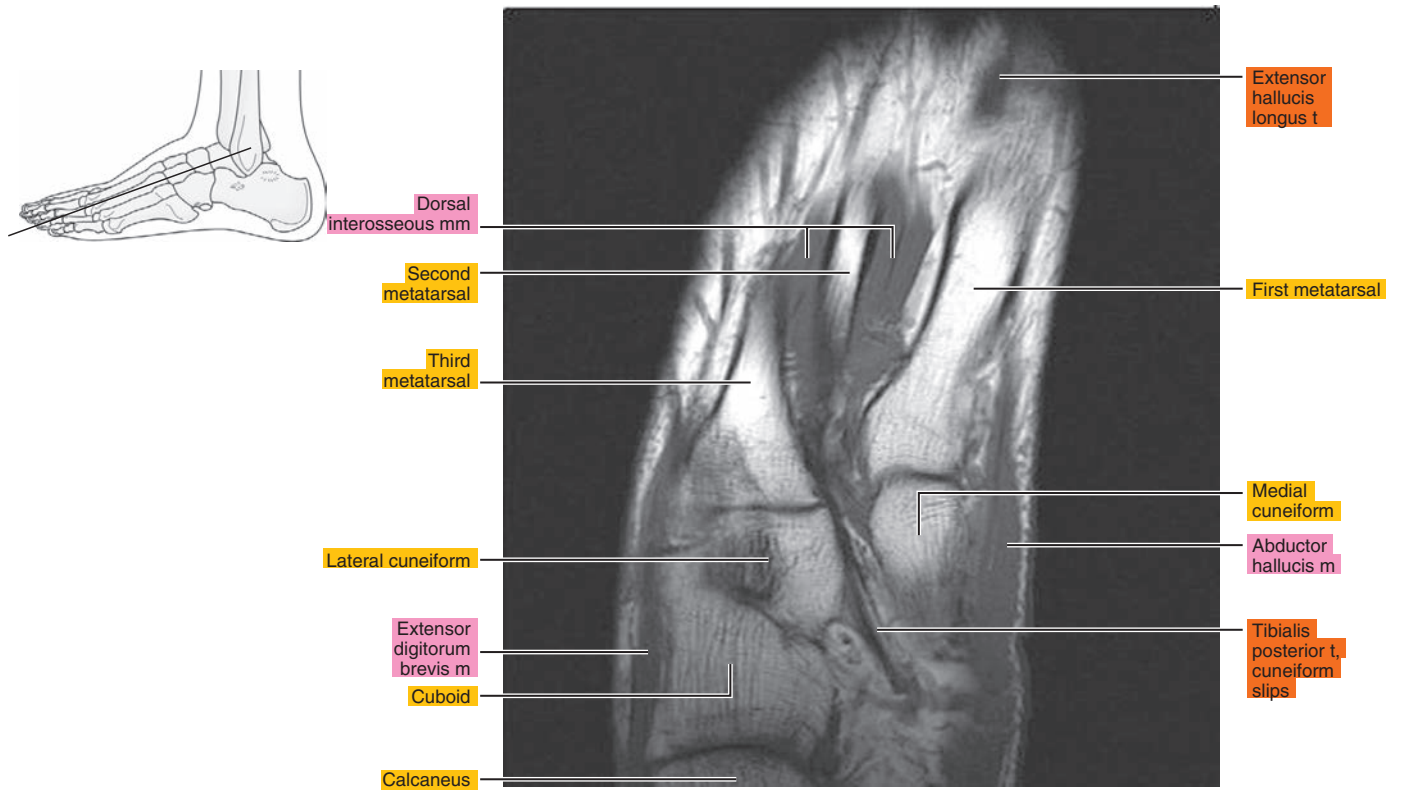


Figure 24.1.6

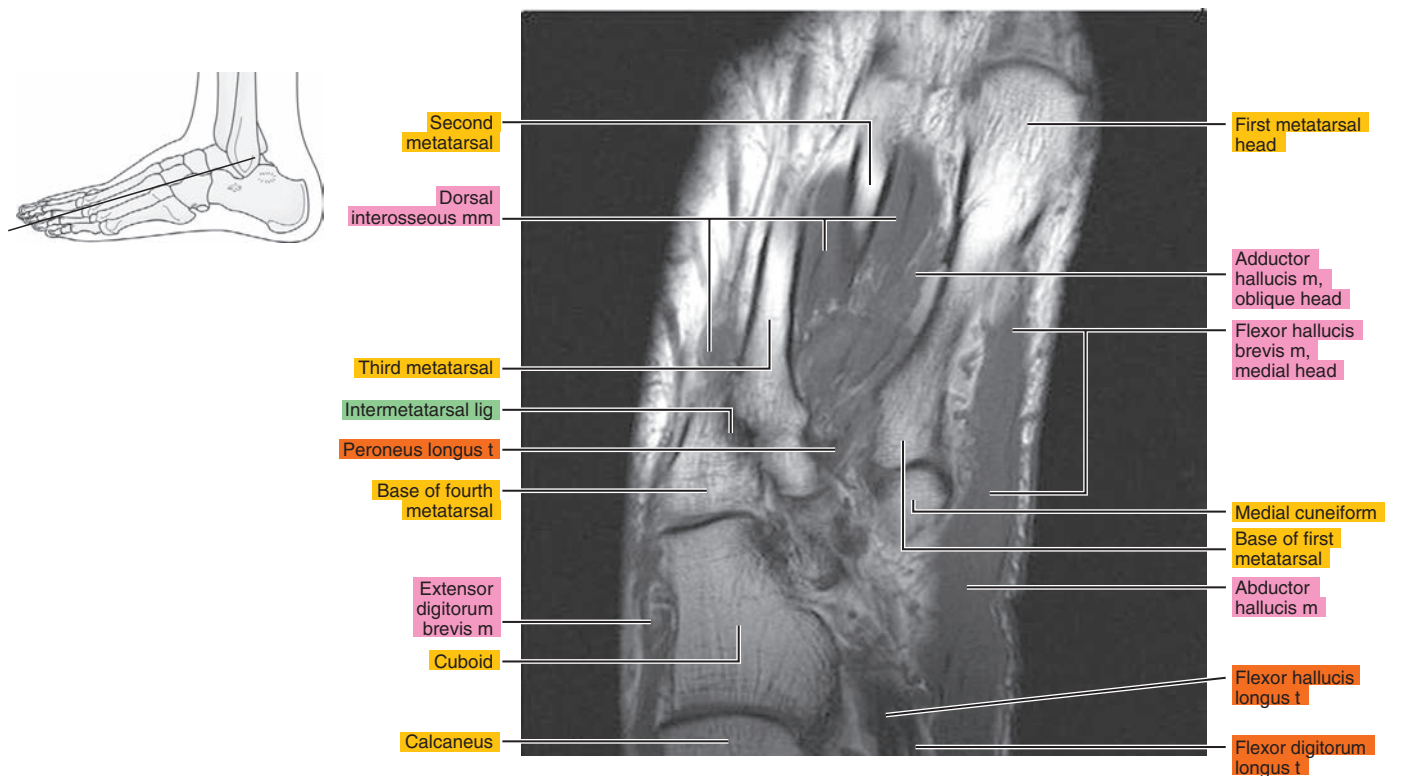




Figure 24.1.7

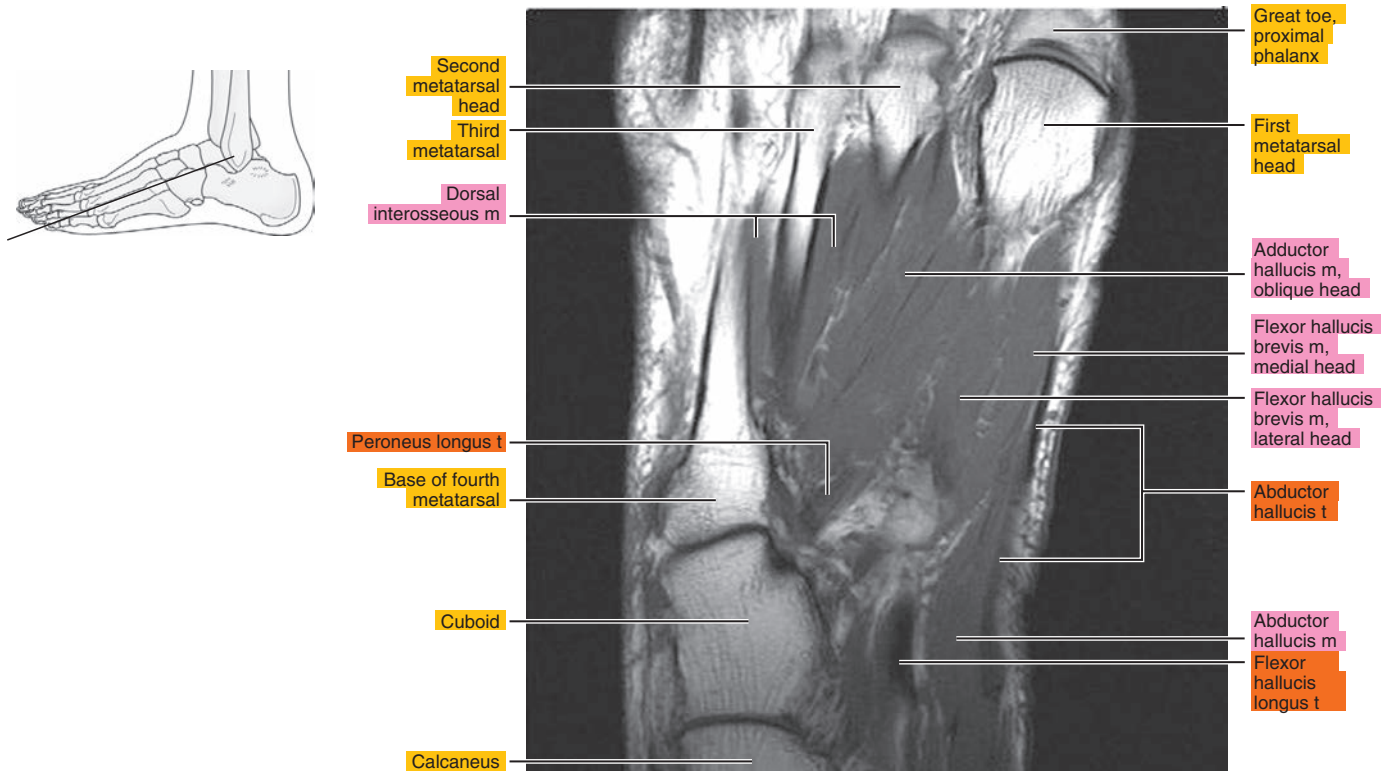


Figure 24.1.8

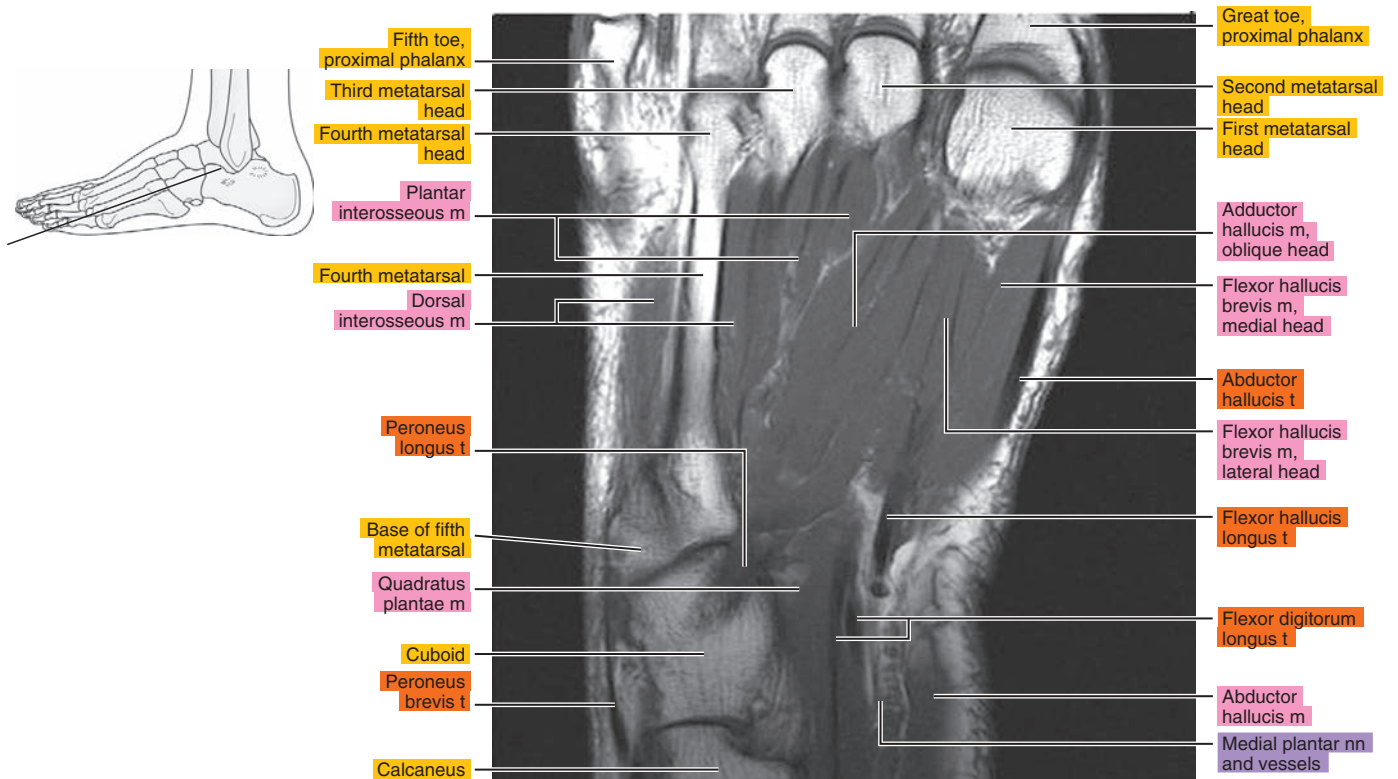


Figure 24.1.9

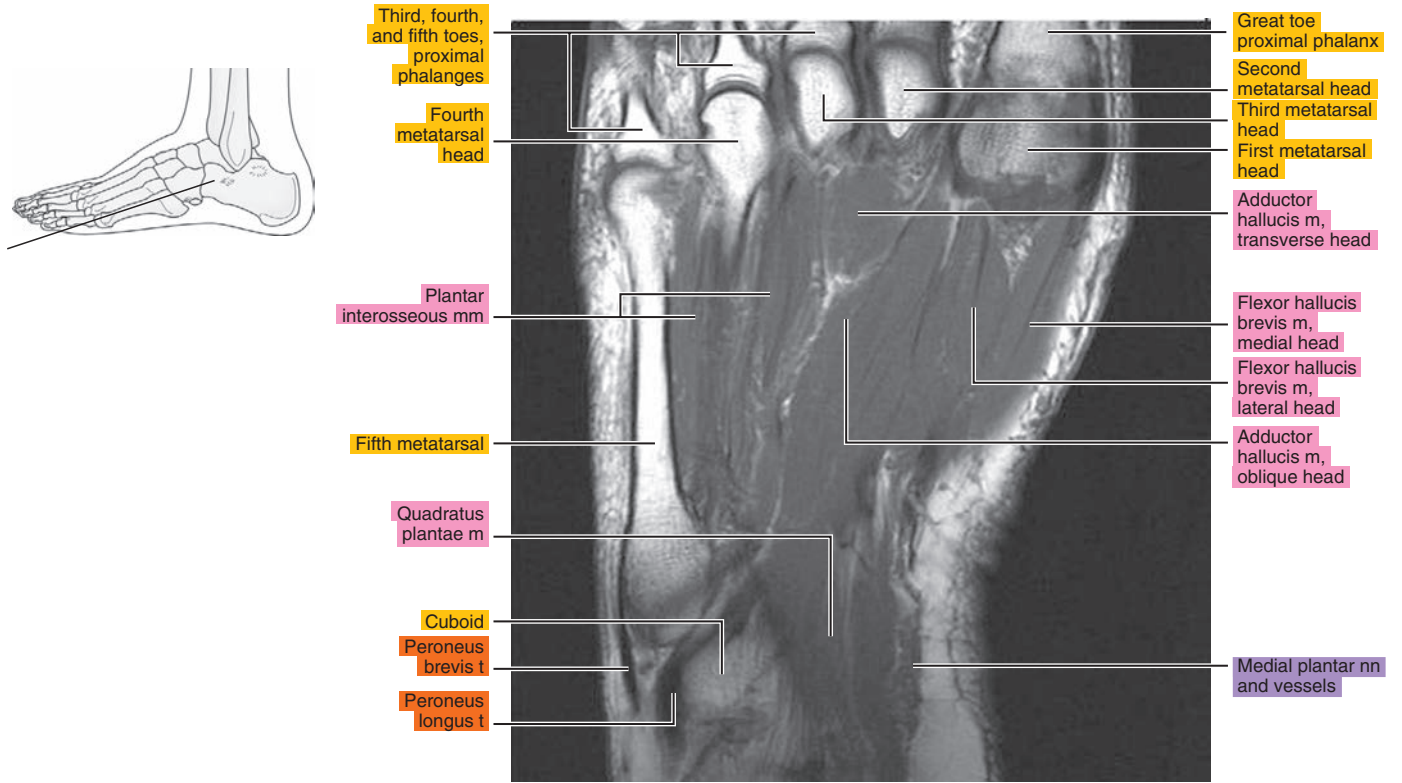


Figure 24.1.10

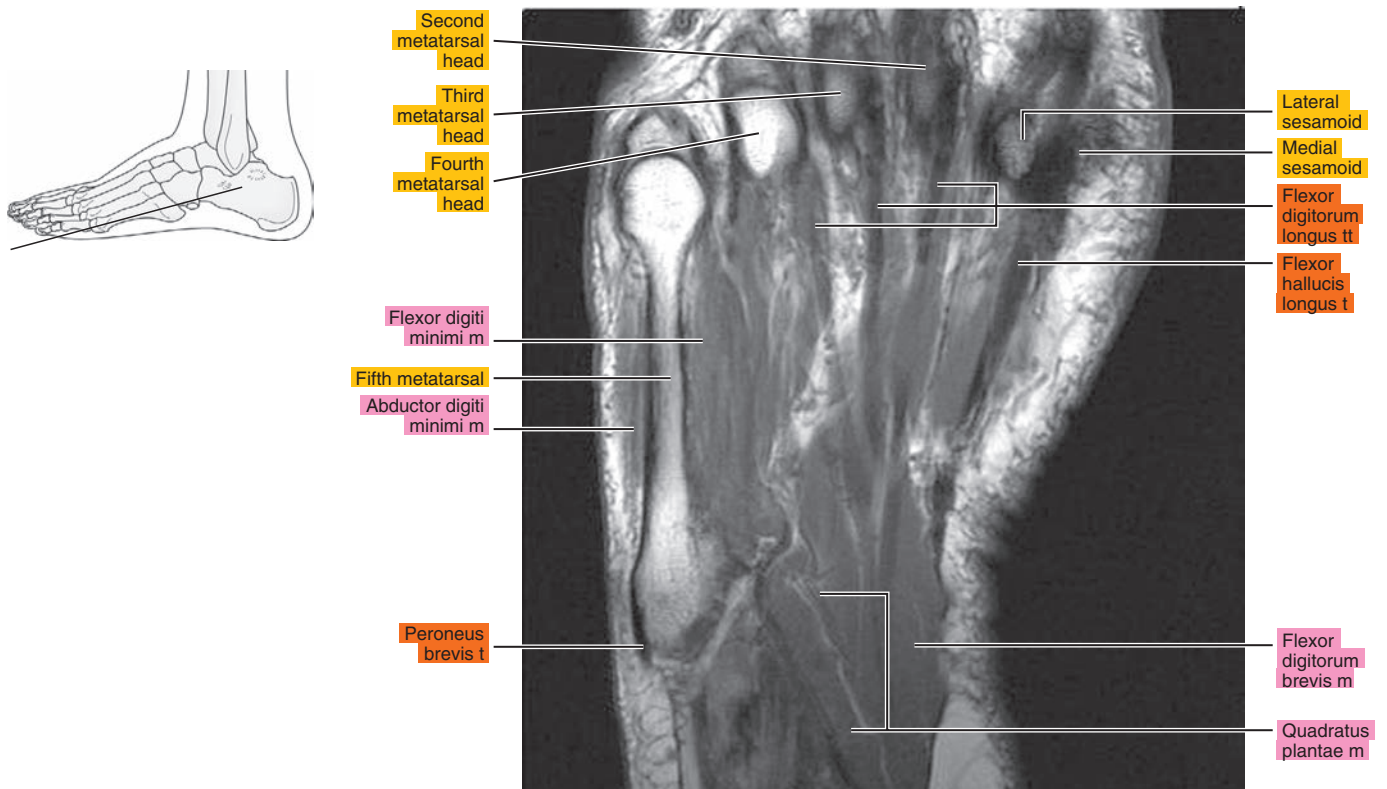


Figure 24.1.11

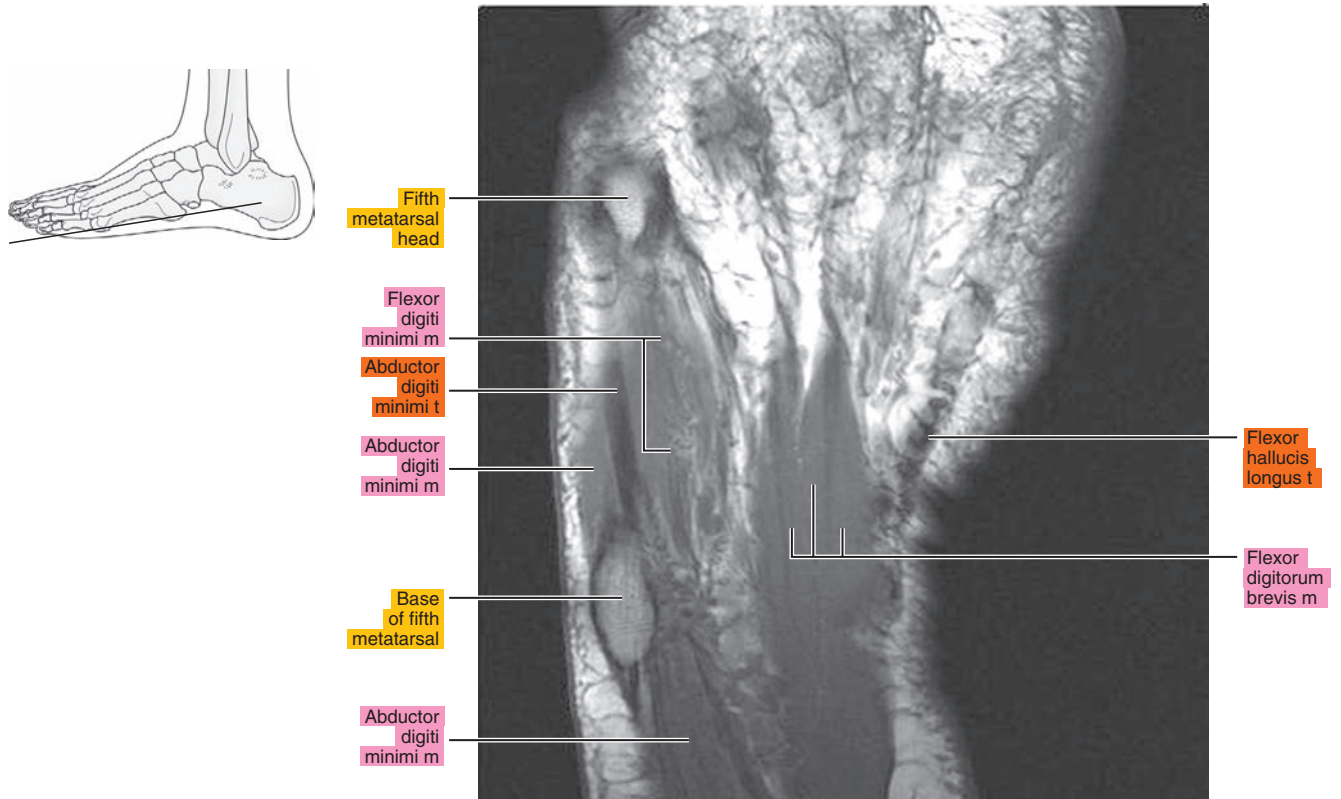
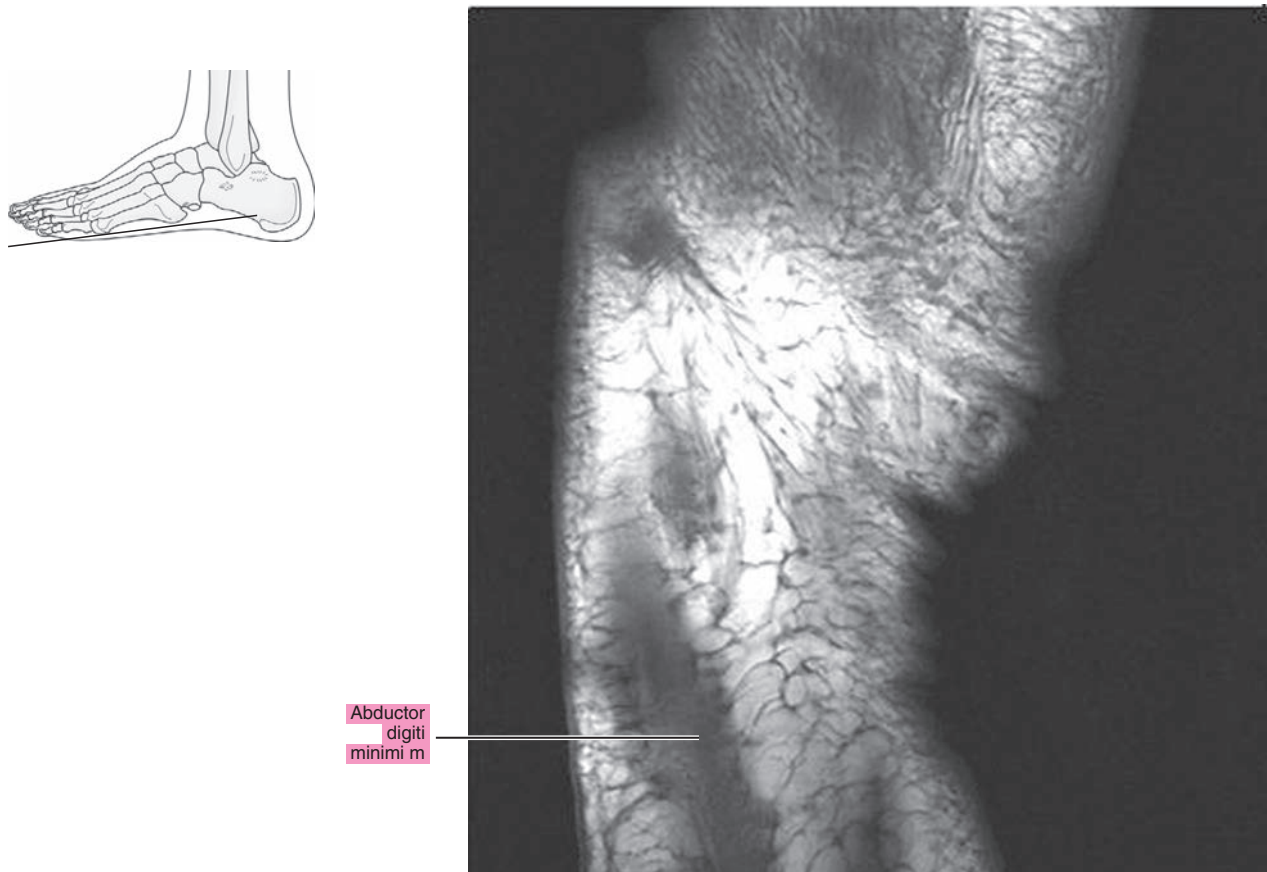

Figure 24.1.12





# SAGITTAL

Figure 24.2.1

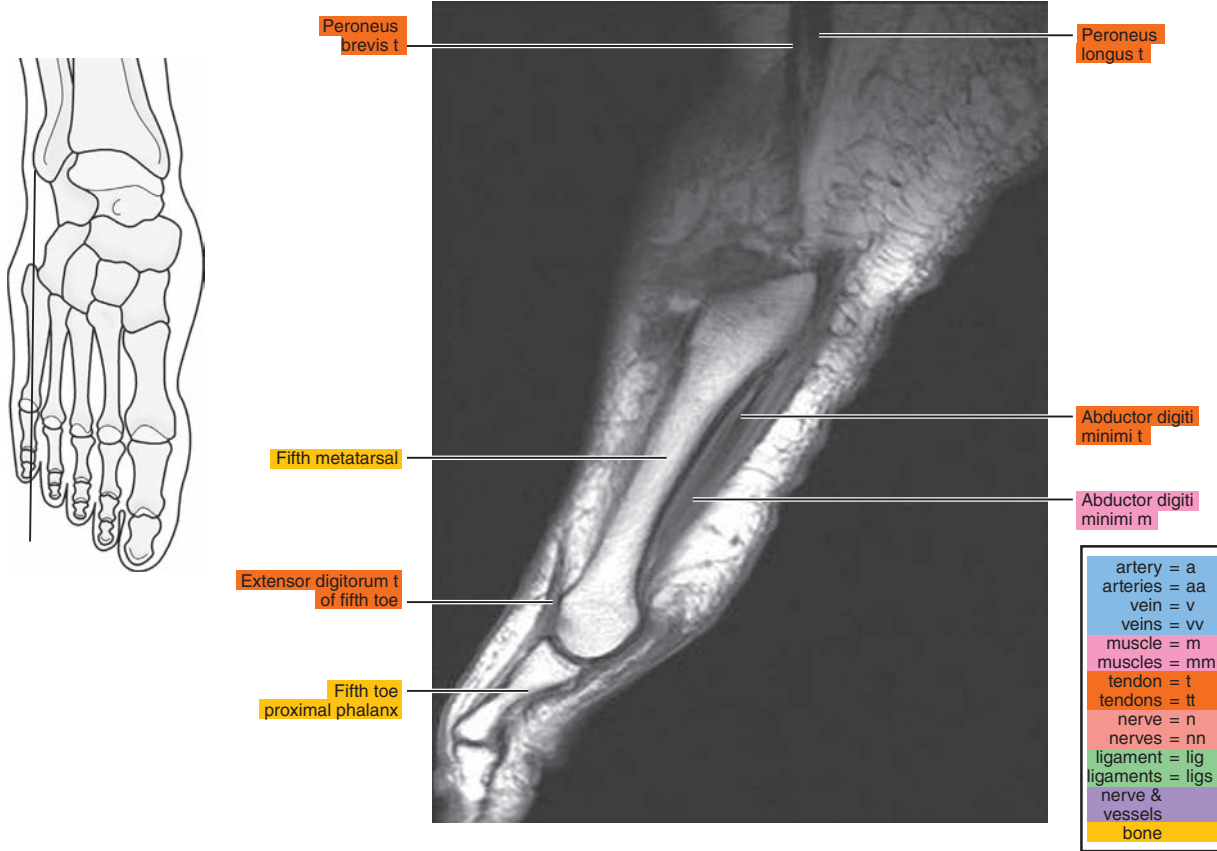

Figure 24.2.2

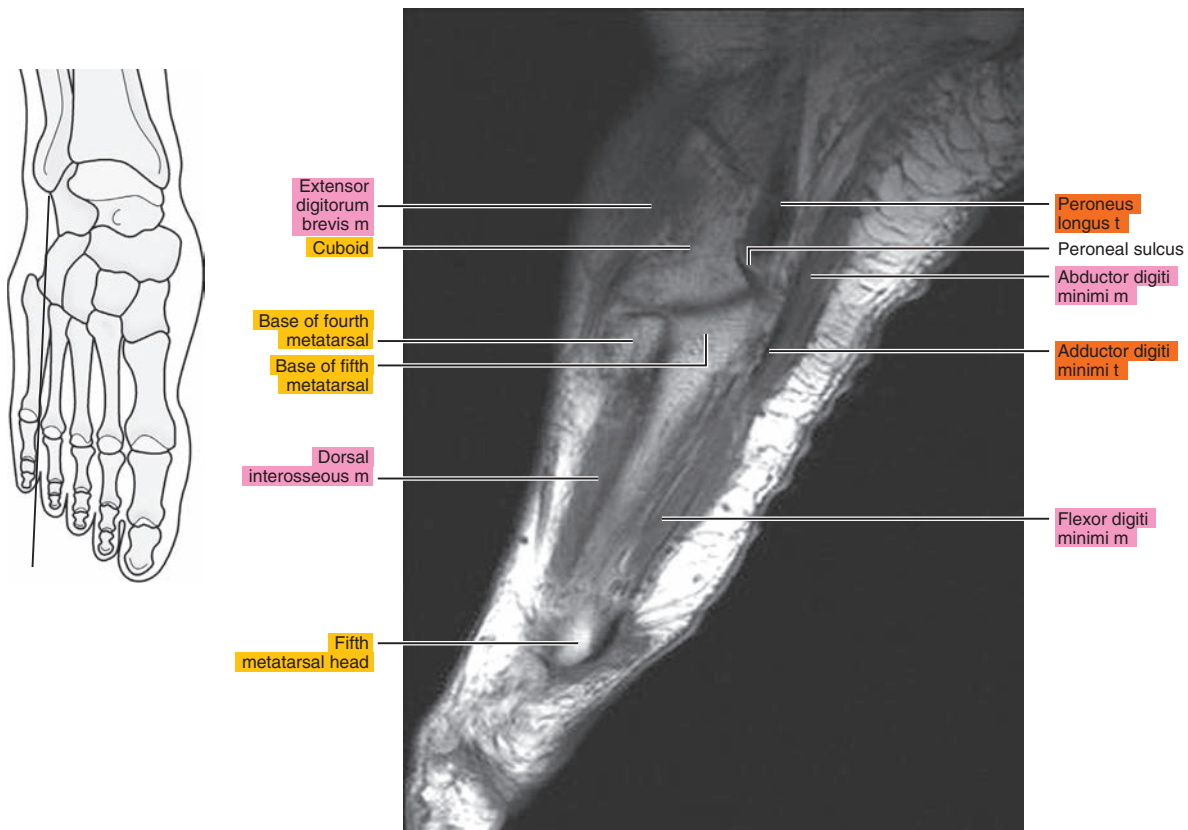




Figure 24.2.3

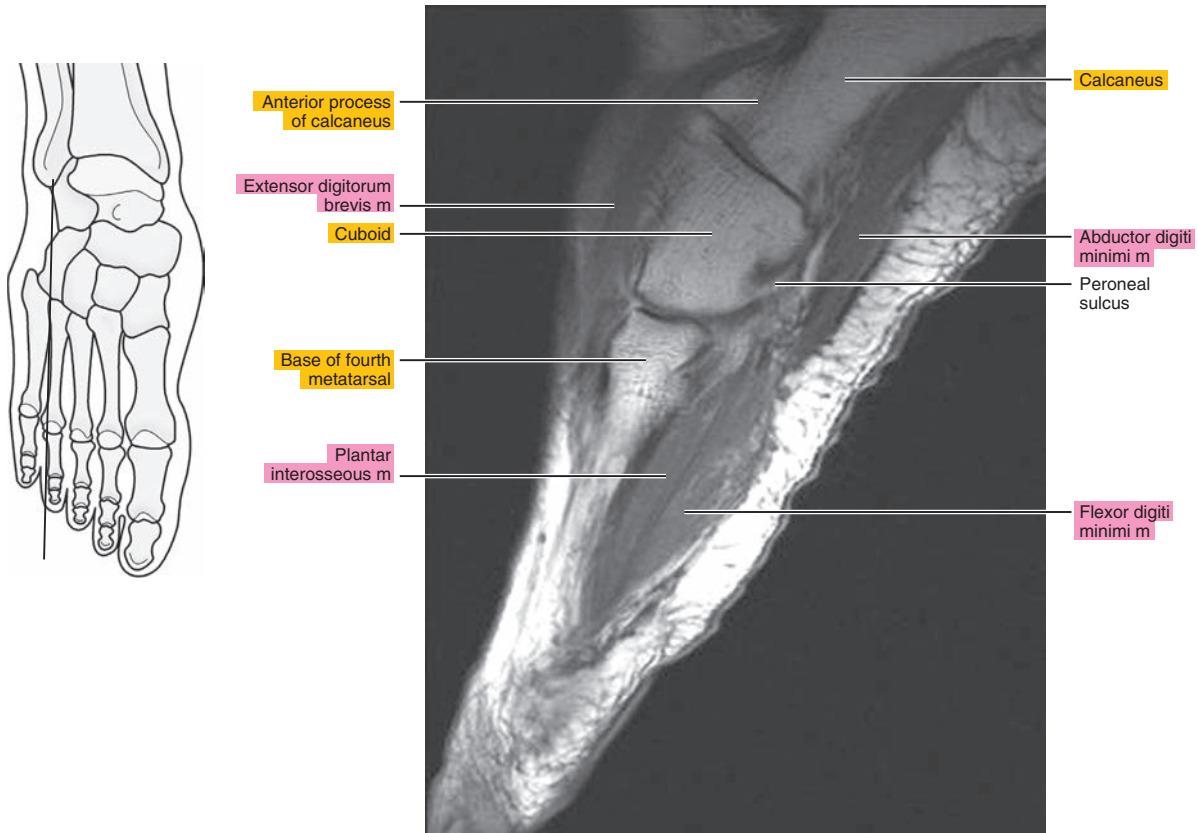


Figure 24.2.4

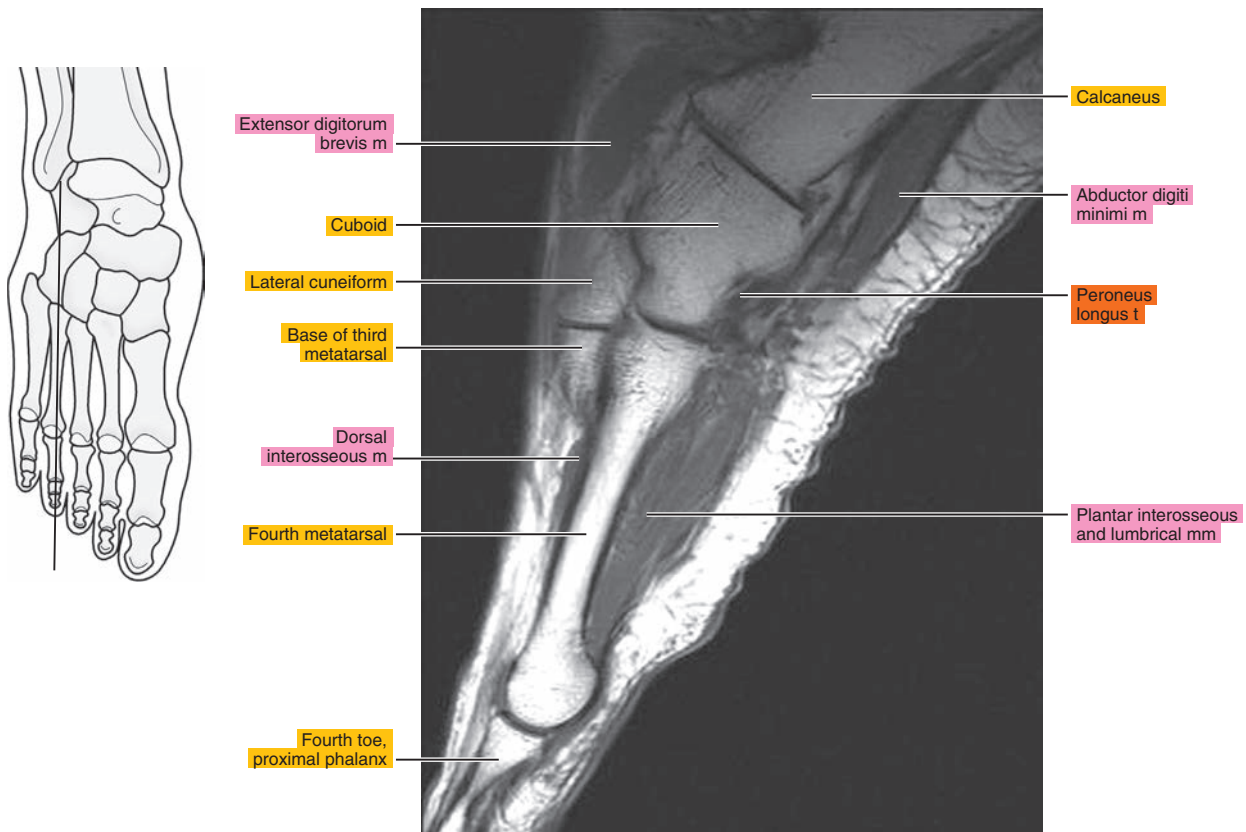


Figure 24.2.5

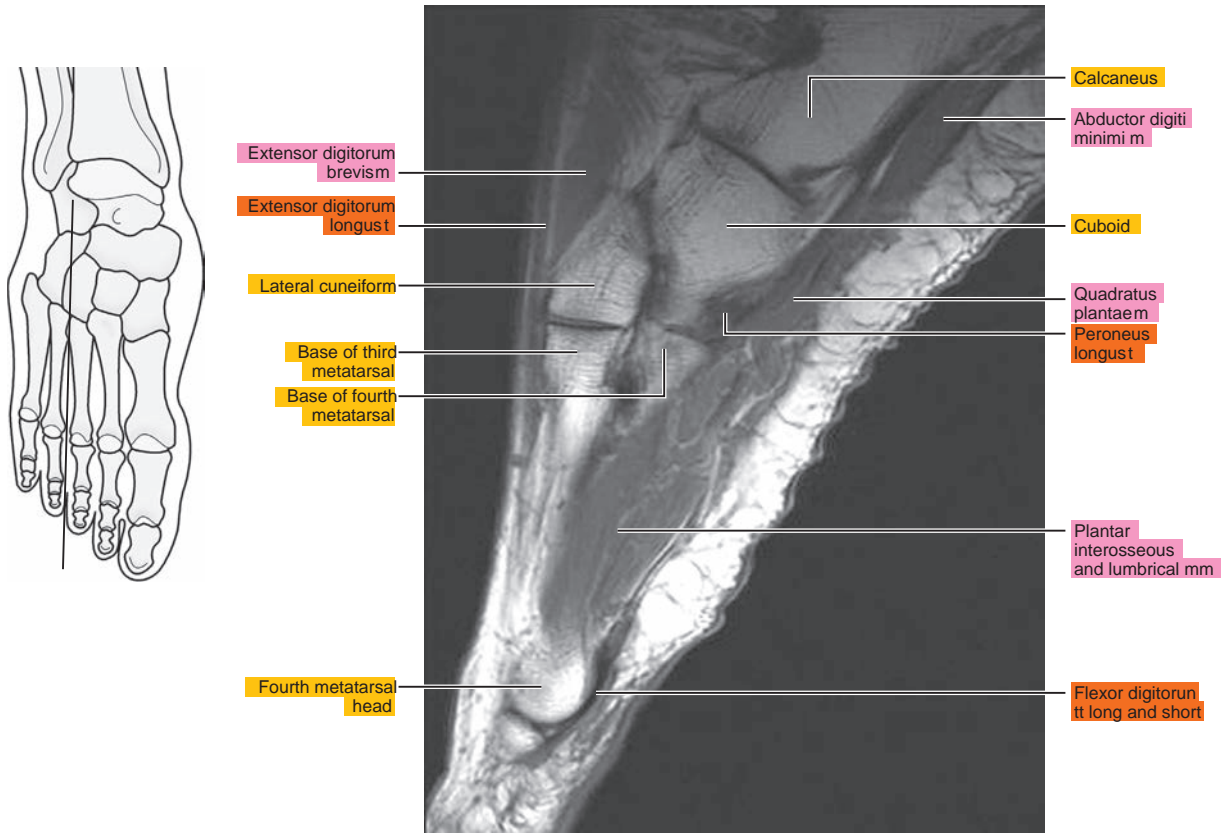


Figure 24.2.6

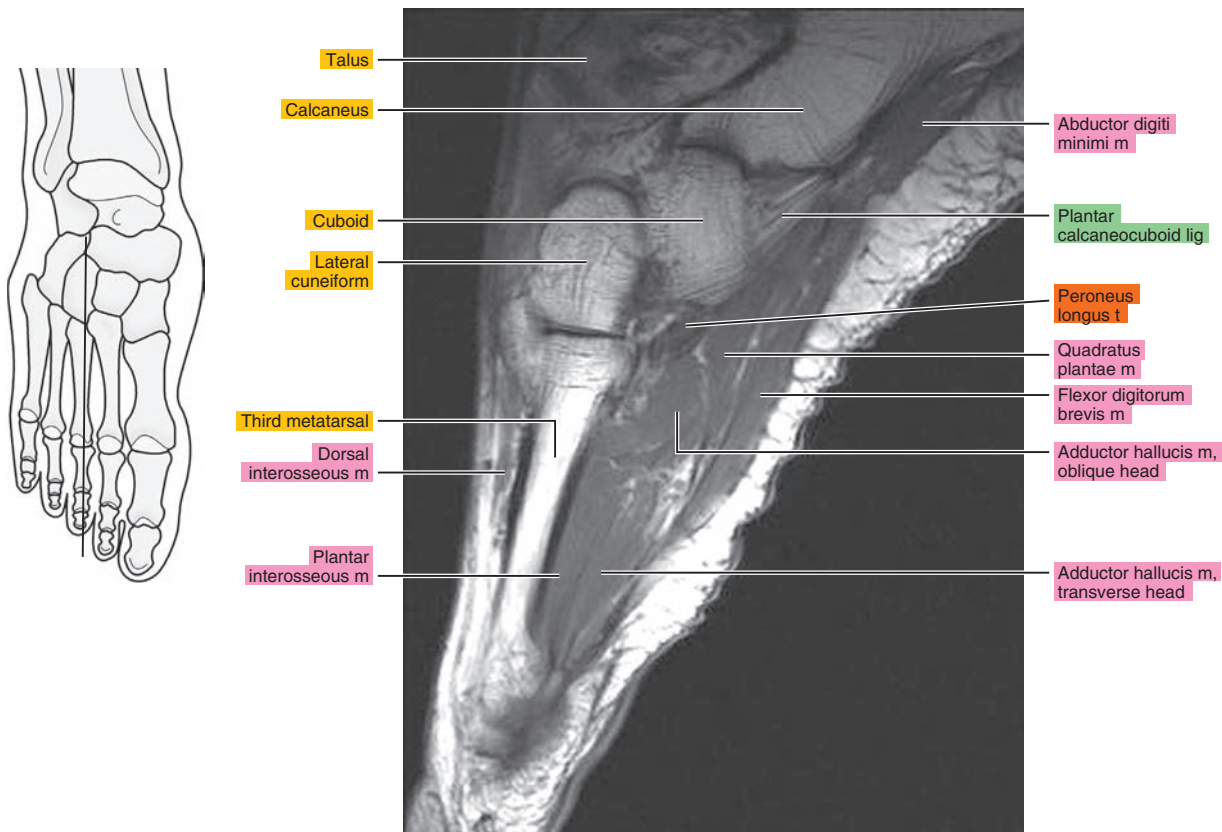


Figure 24.2.7

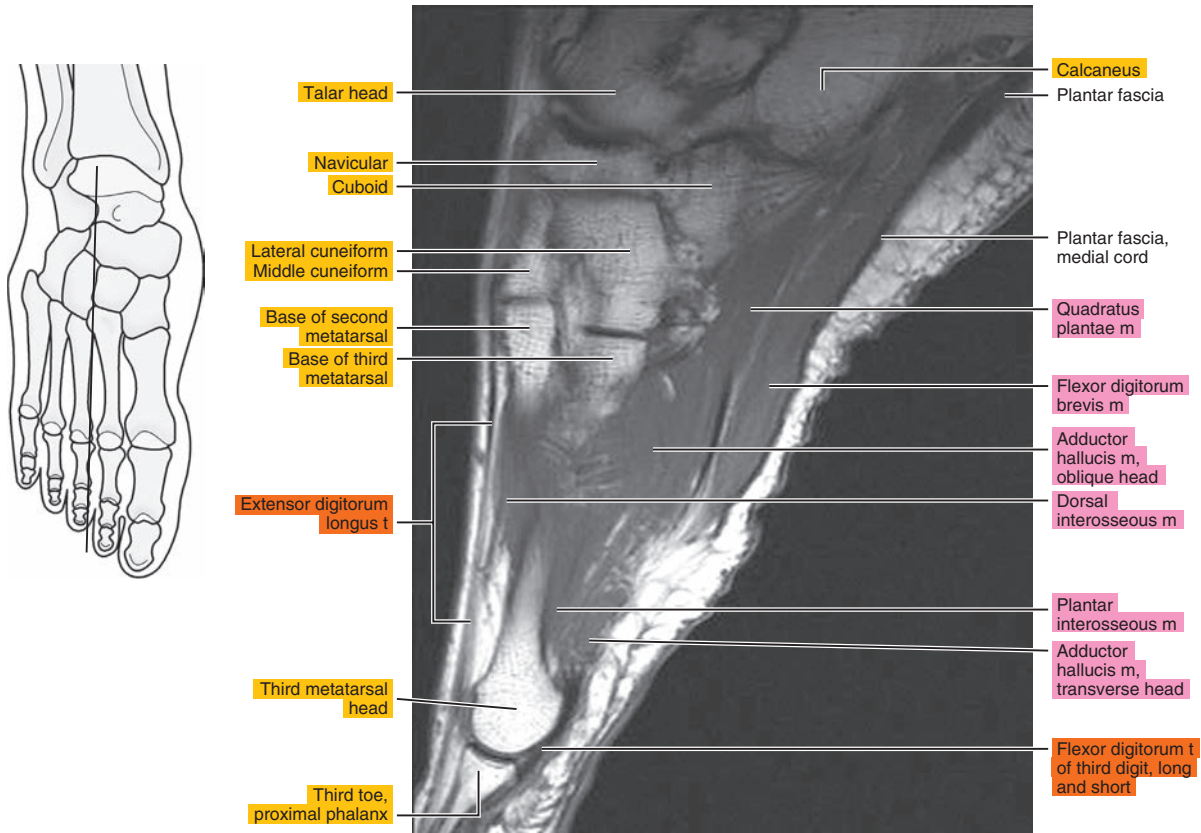


Figure 24.2.8

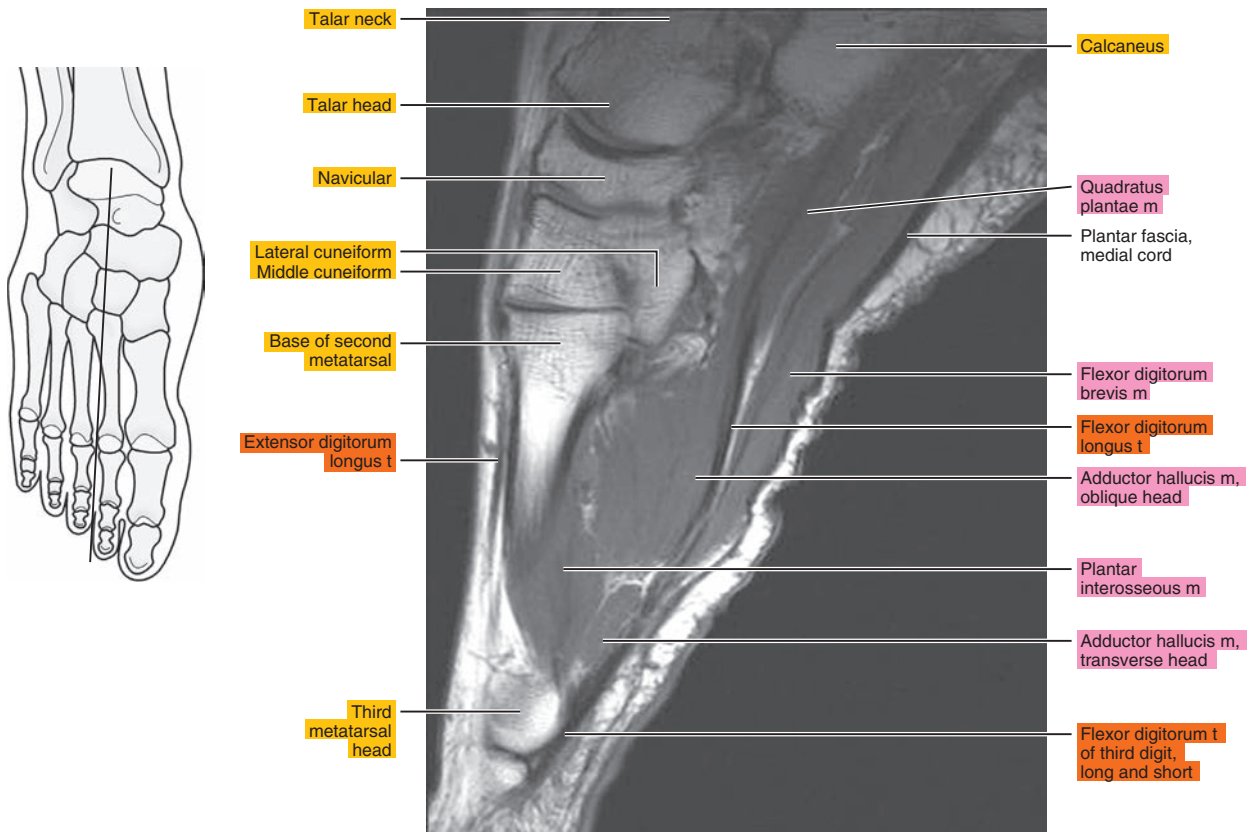




Figure 24.2.9

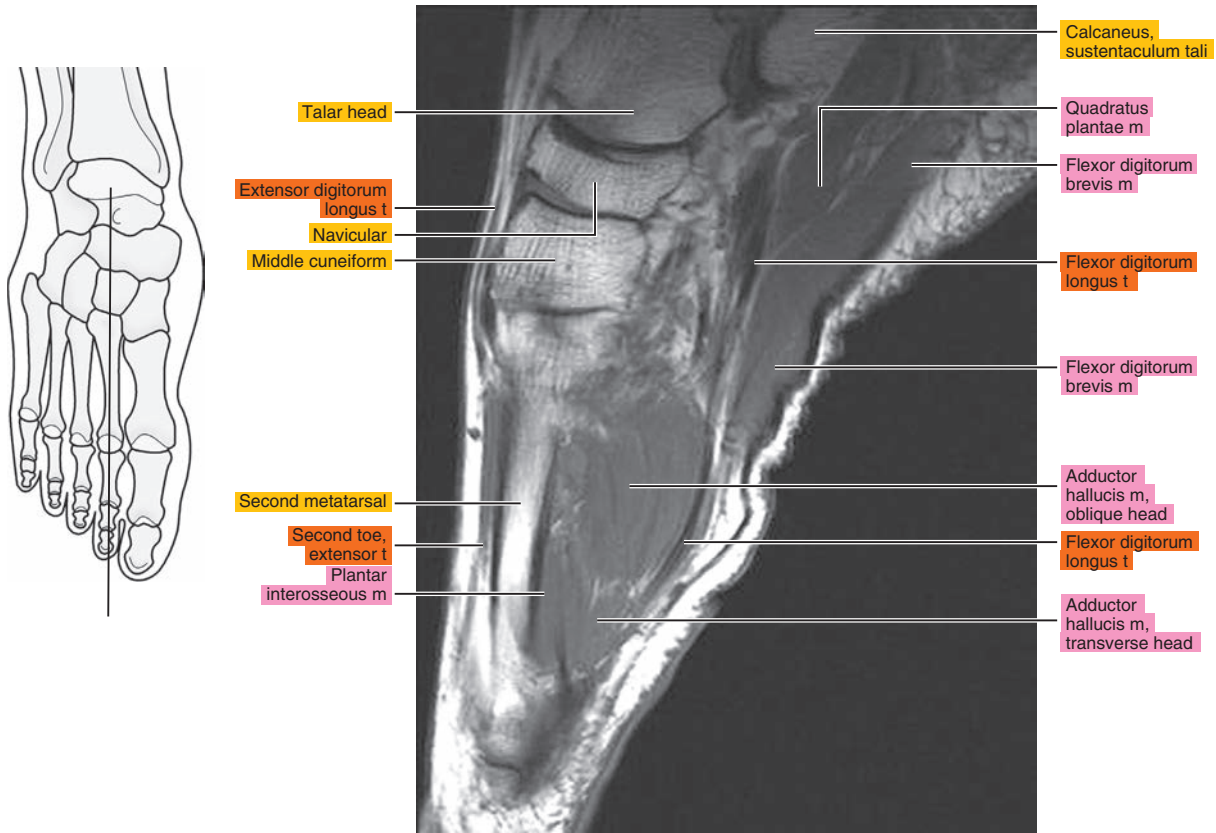


Figure 24.2.10

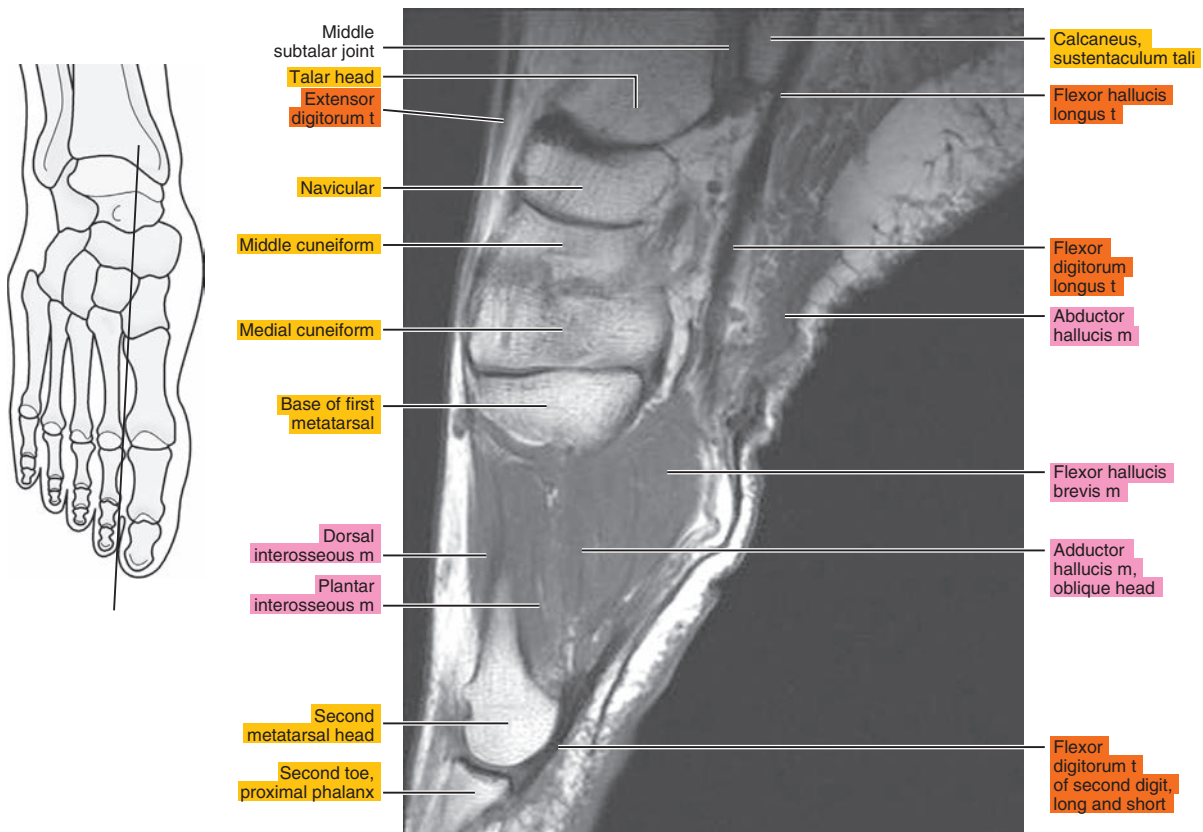




Figure 24.2.11

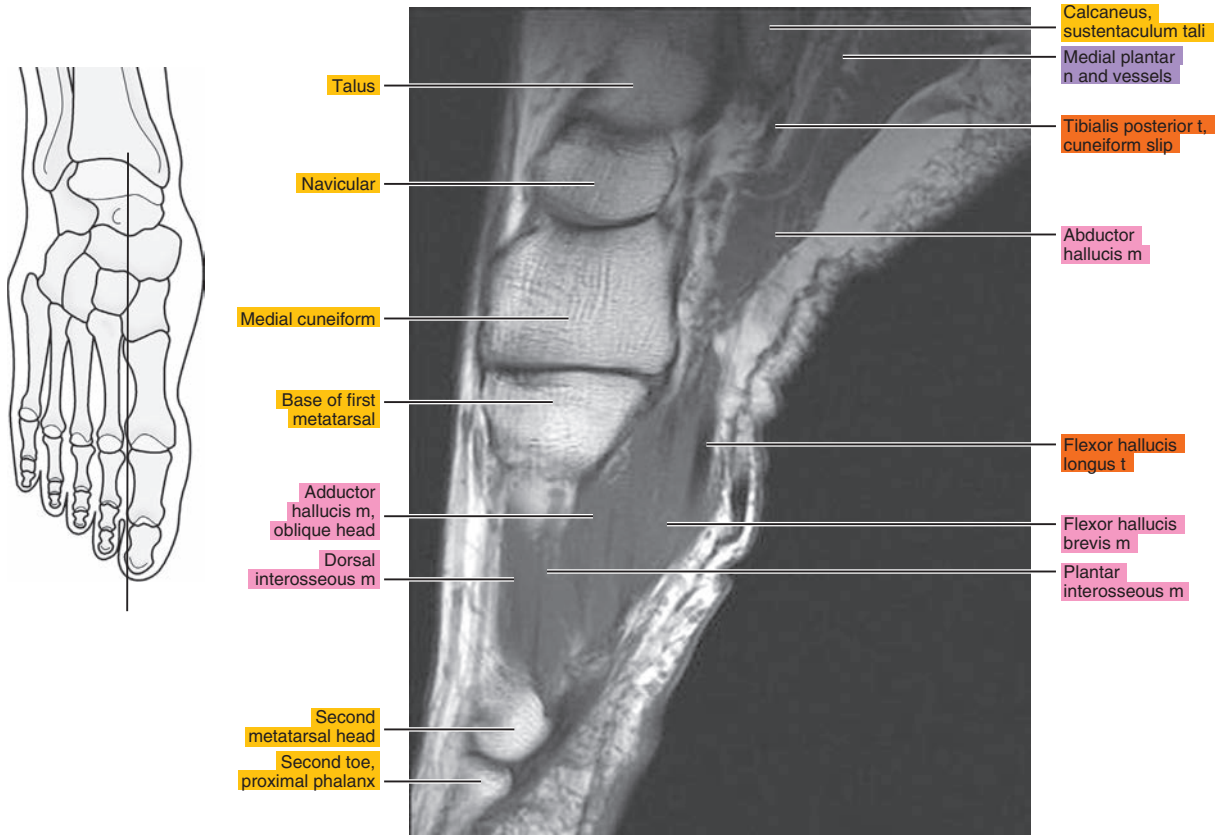


Figure 24.2.12

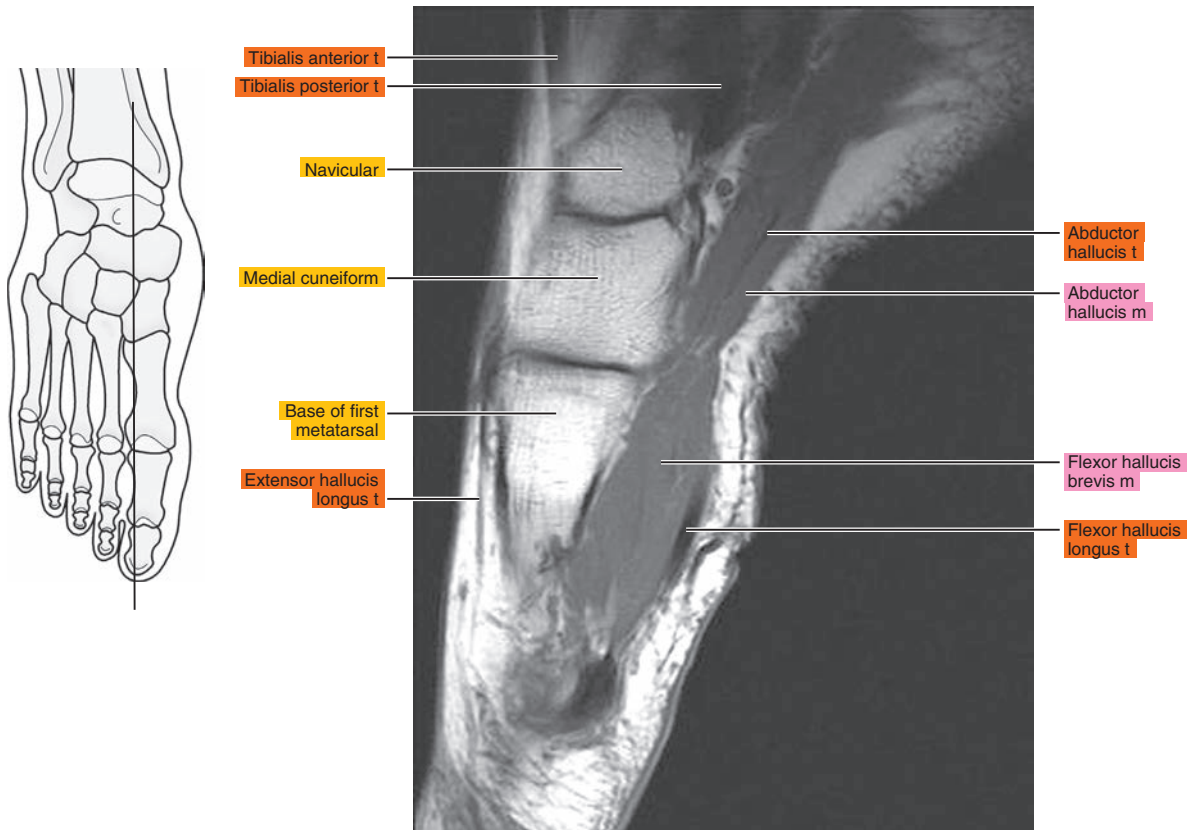


Figure 24.2.13

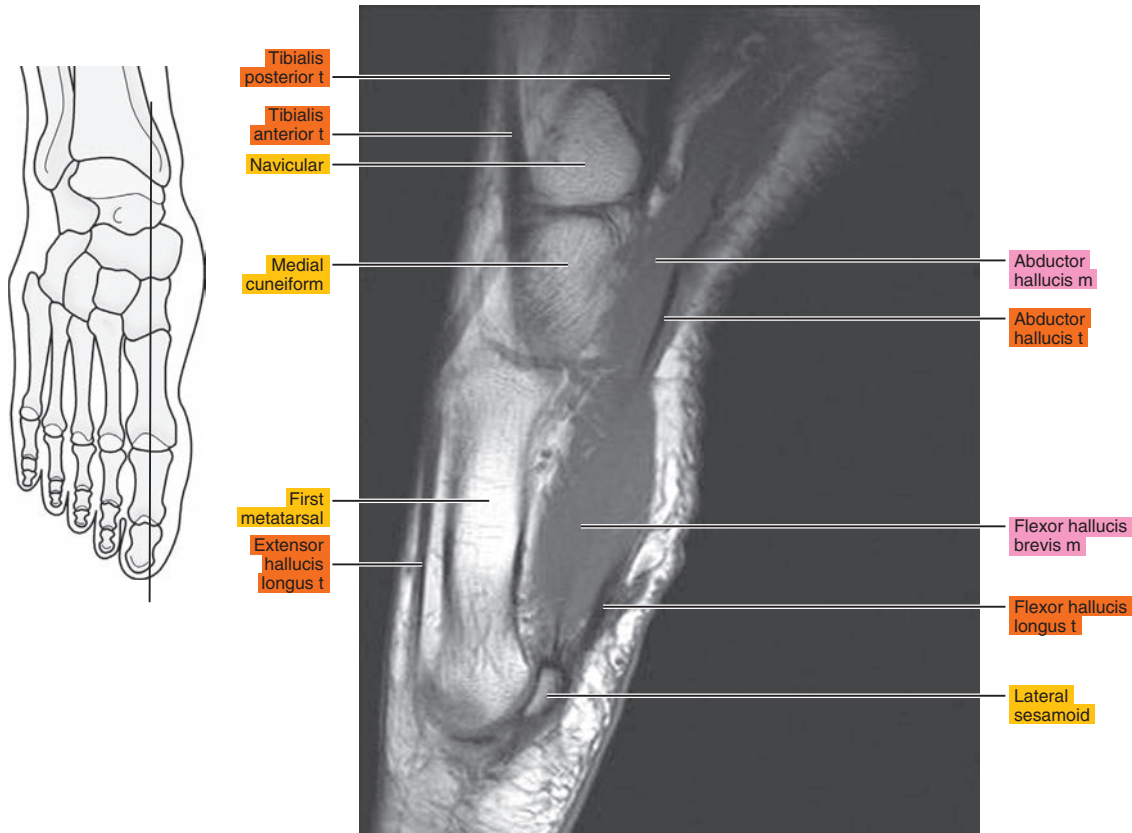


Figure 24.2.14

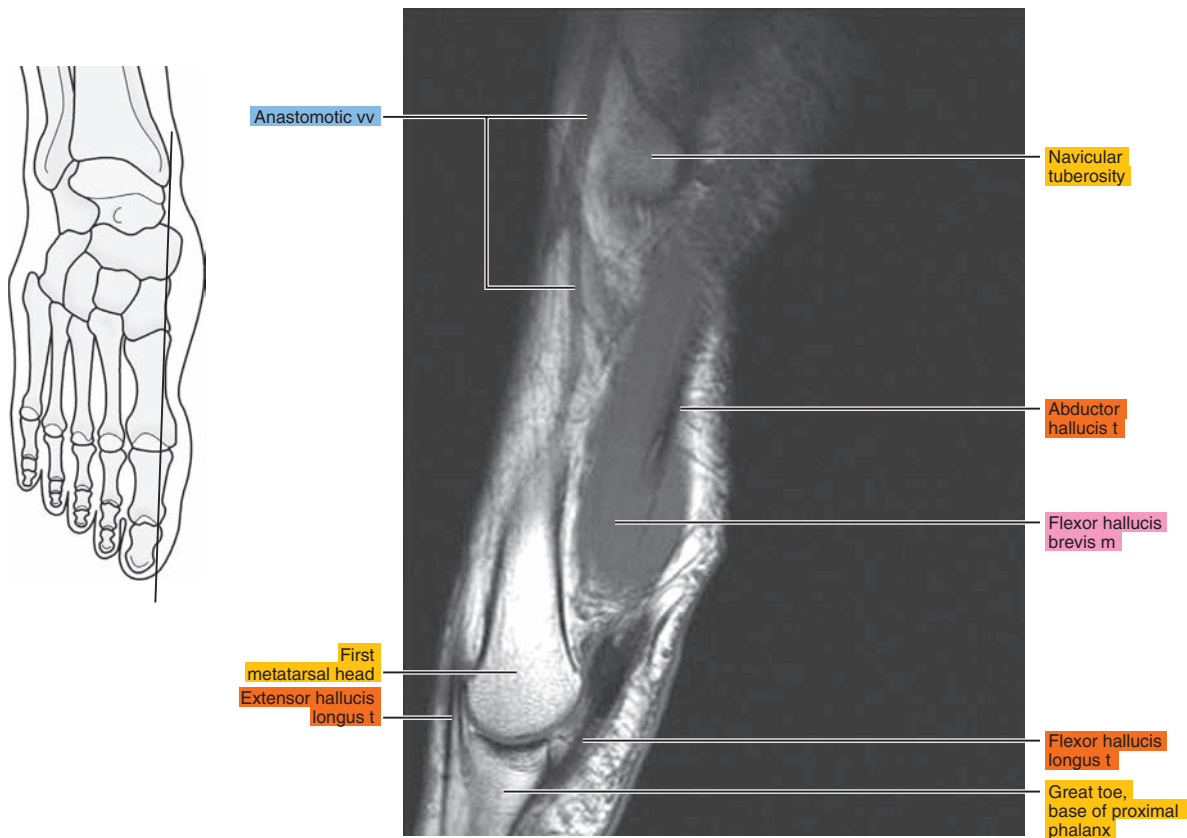
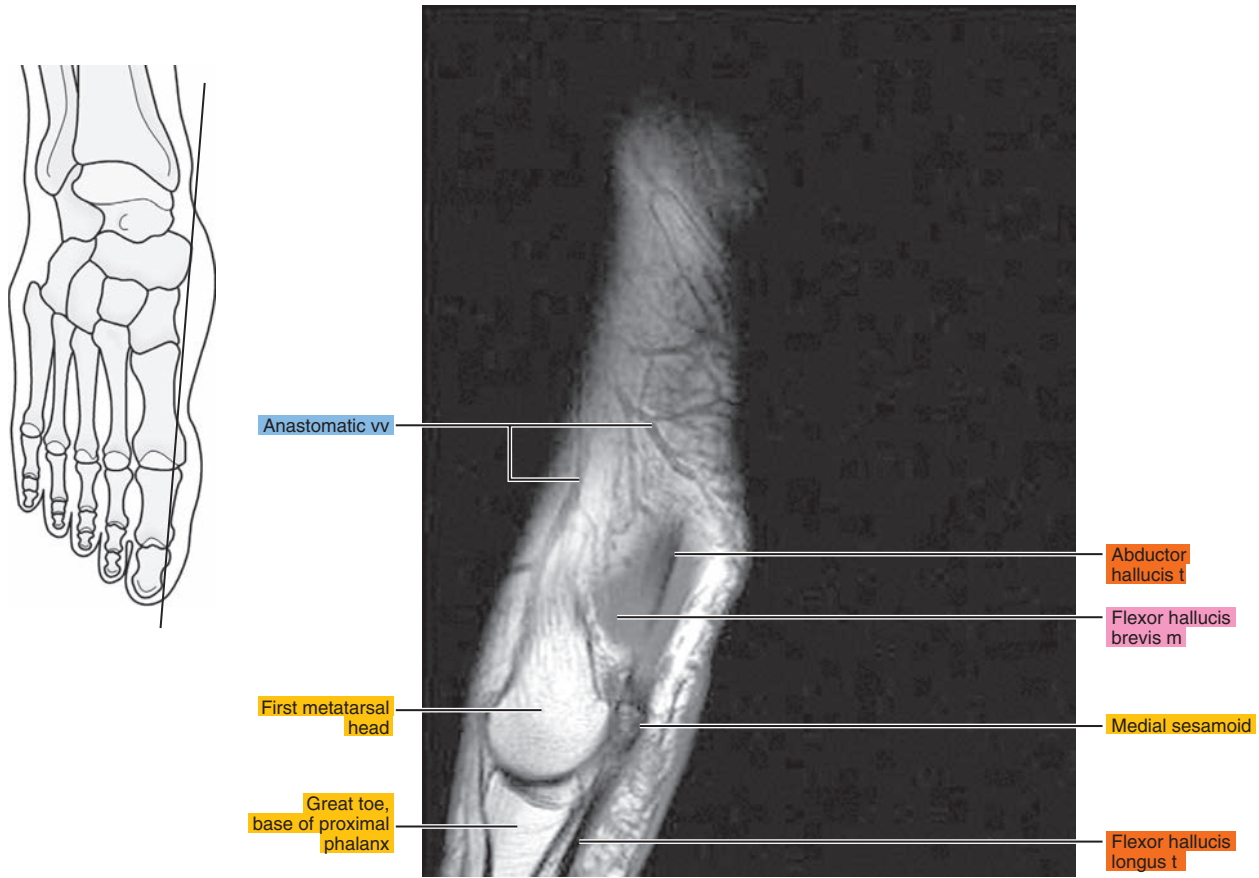


Figure 24.2.15



# CORONAL

Figure 24.3.1

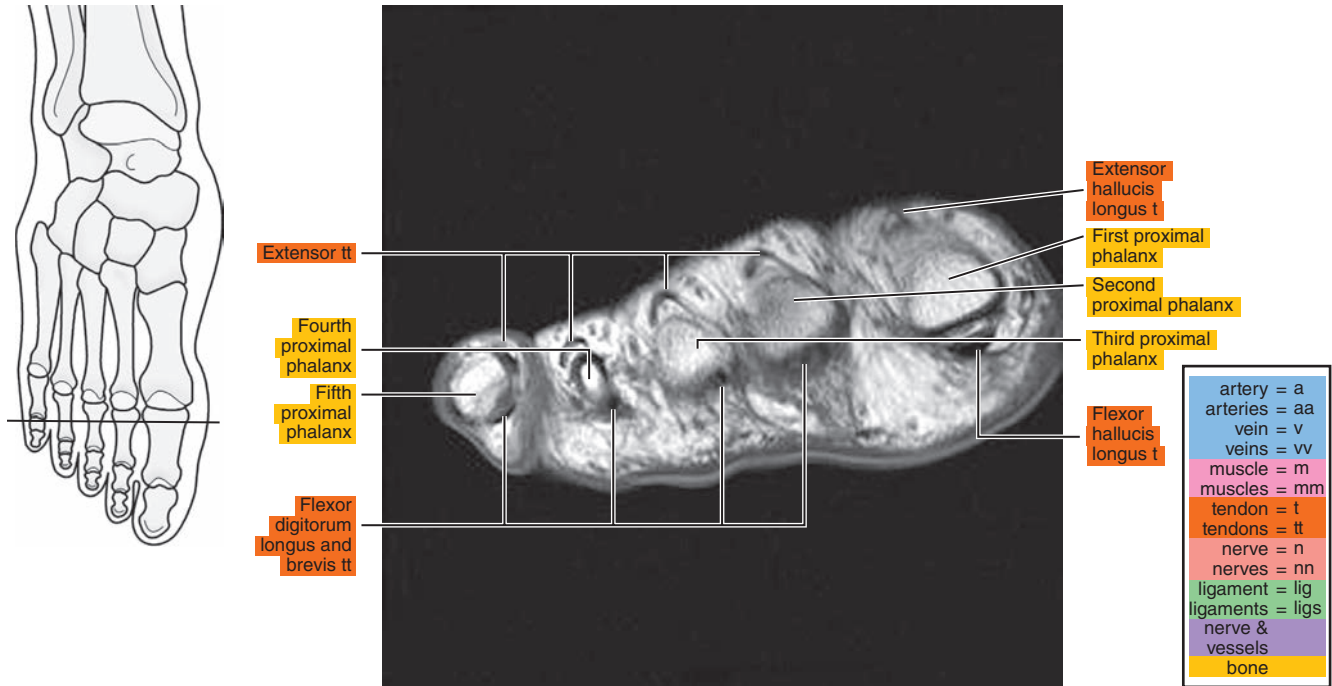


Figure 24.3.2

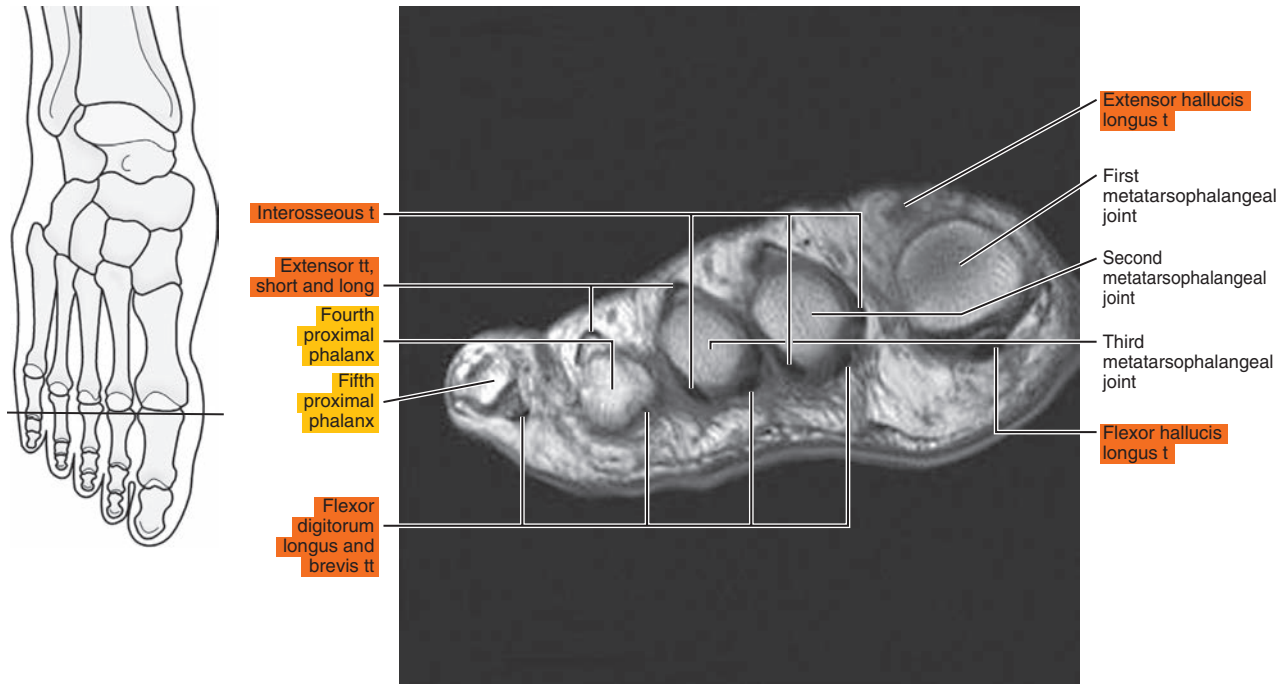




Figure 24.3.3

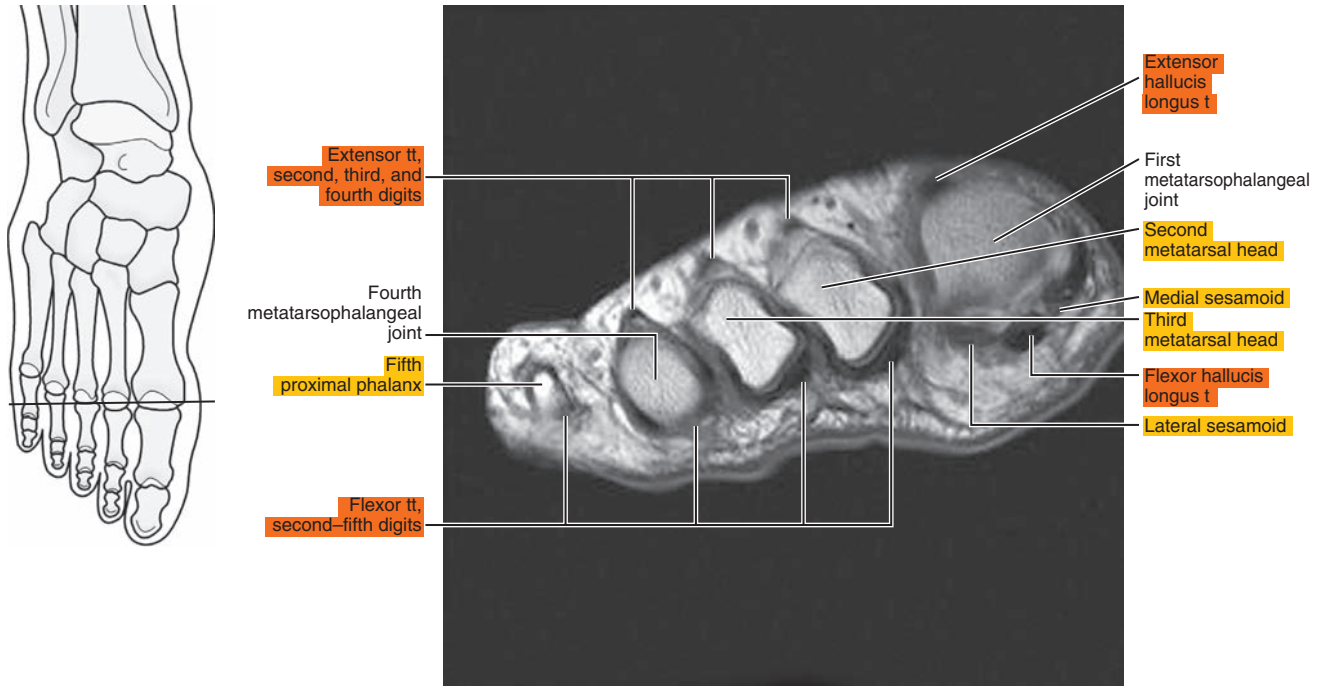


Figure 24.3.4

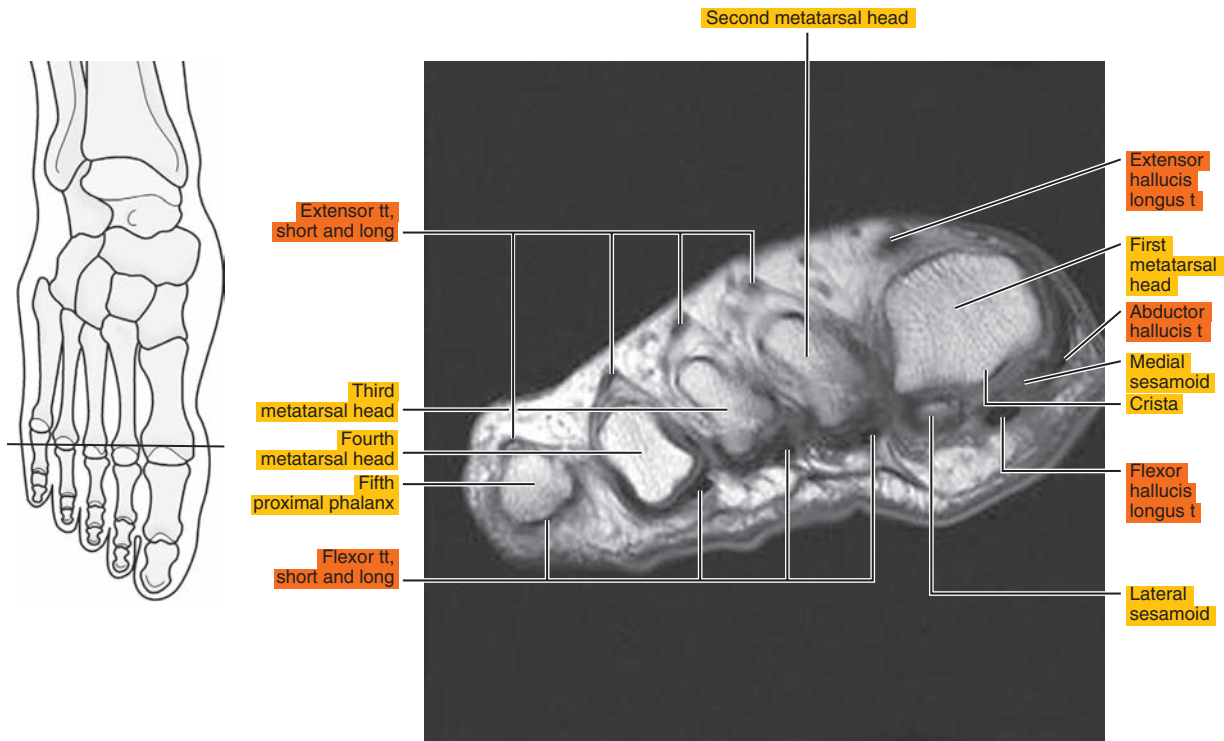


Figure 24.3.5

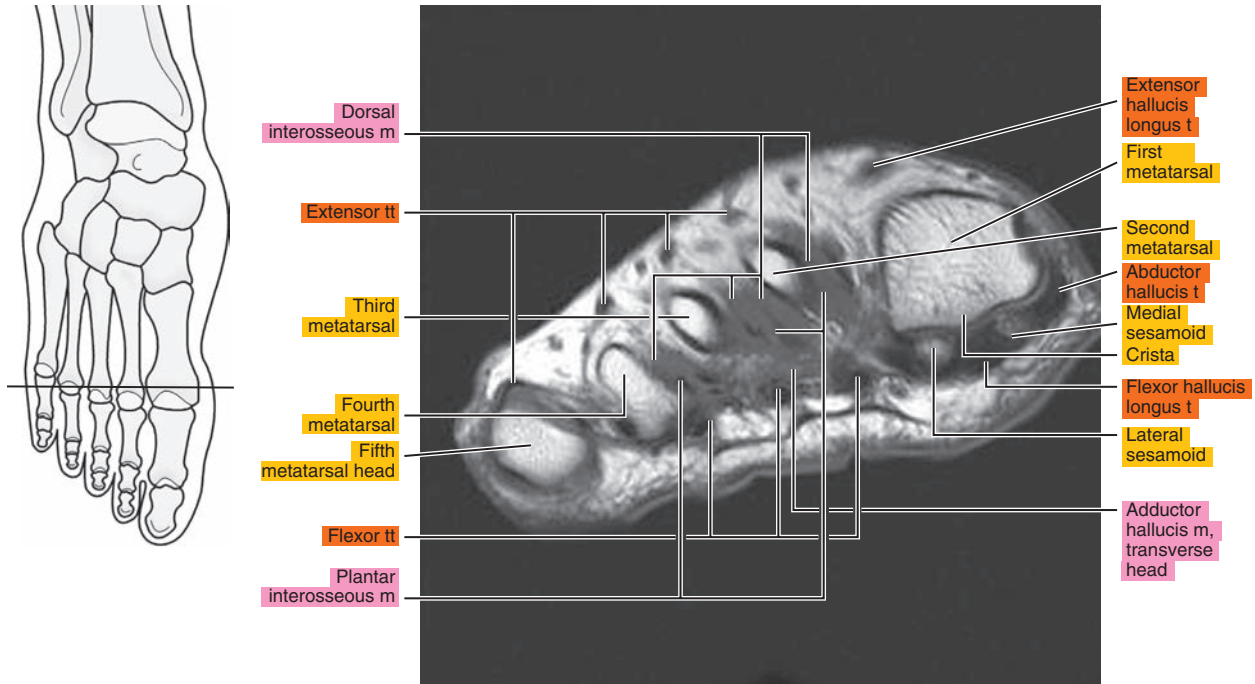


Figure 24.3.6

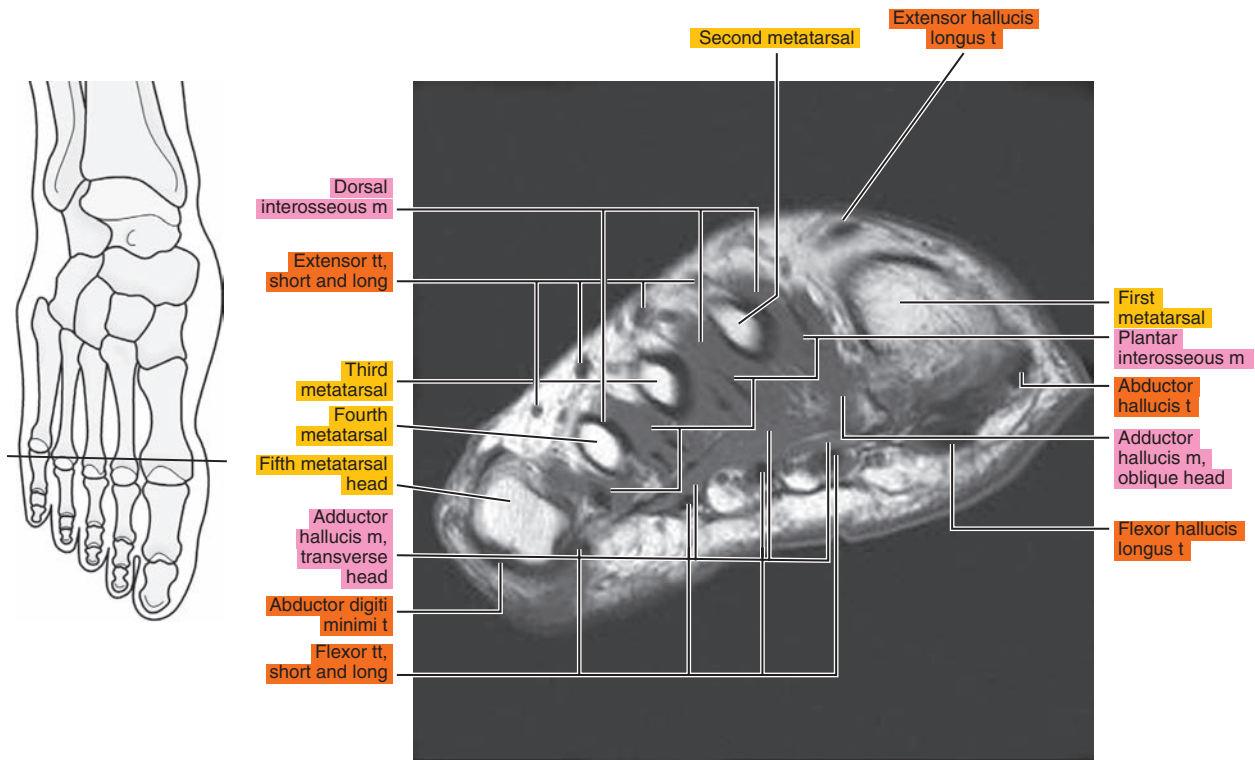


Figure 24.3.7

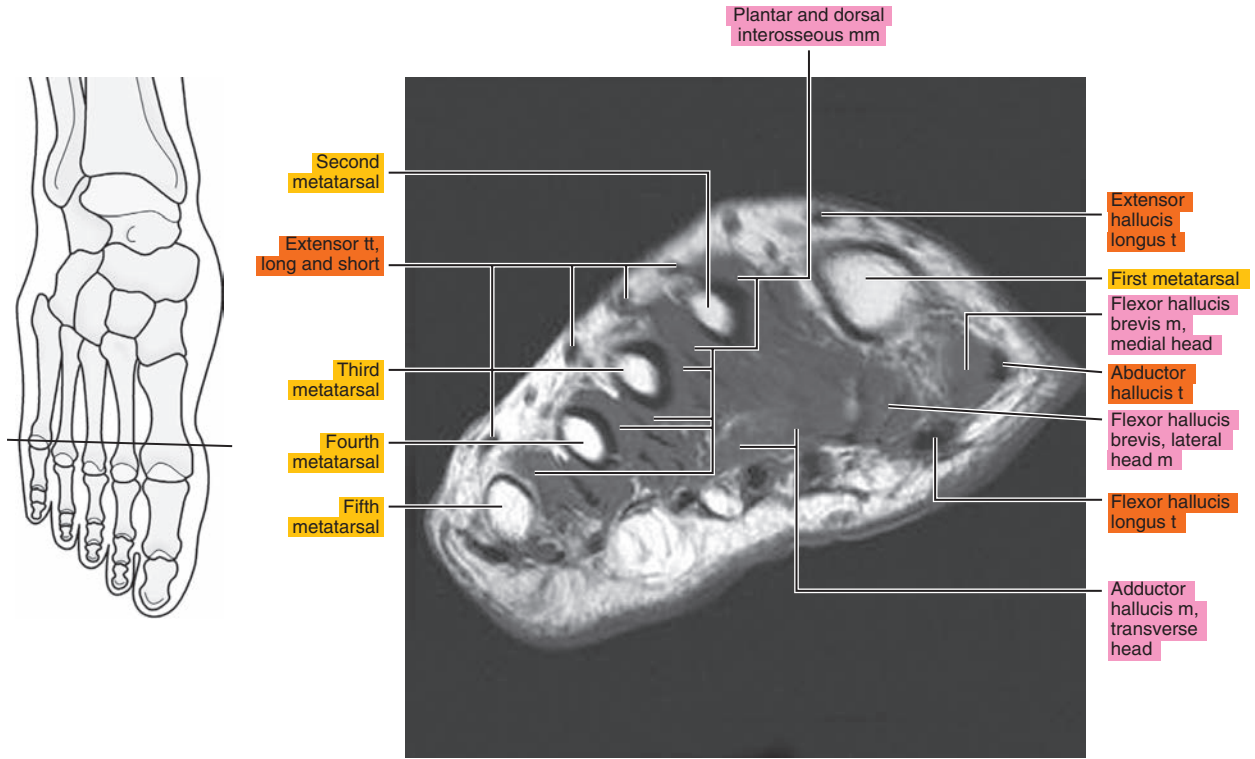


Figure 24.3.8

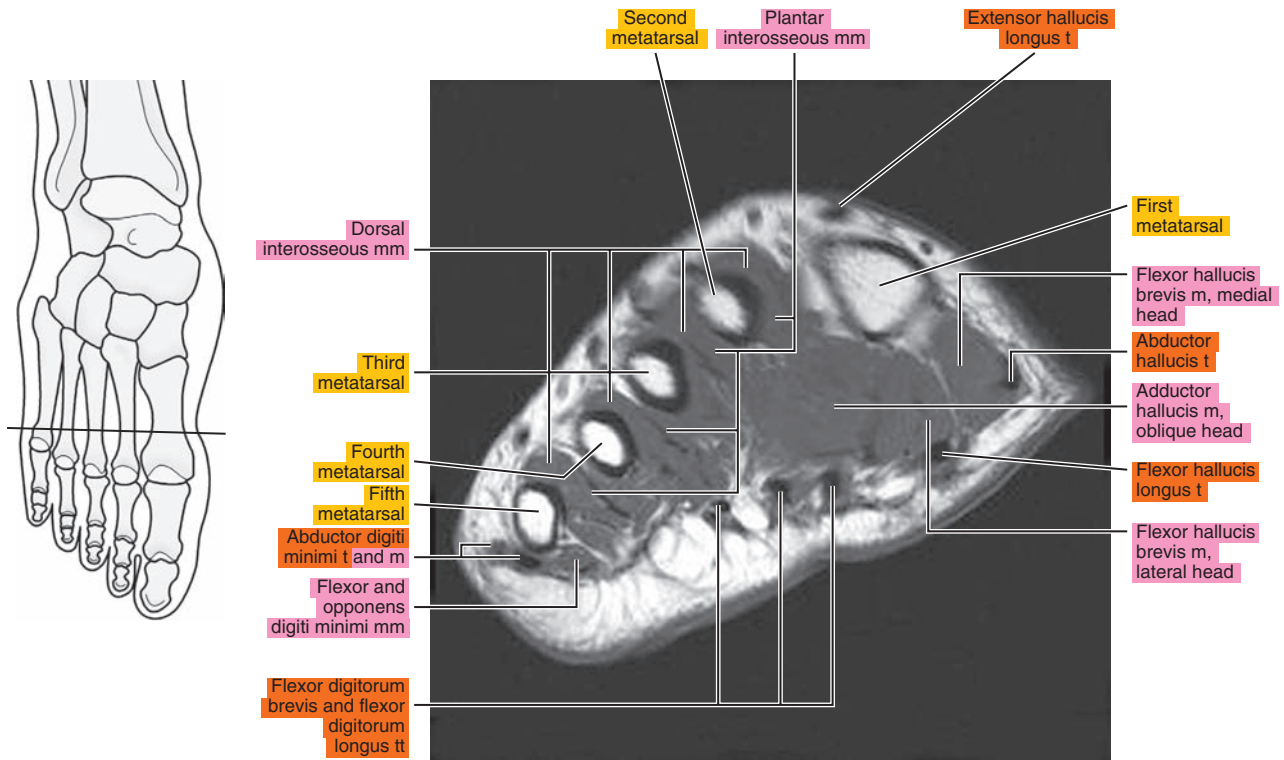


Figure 24.3.9

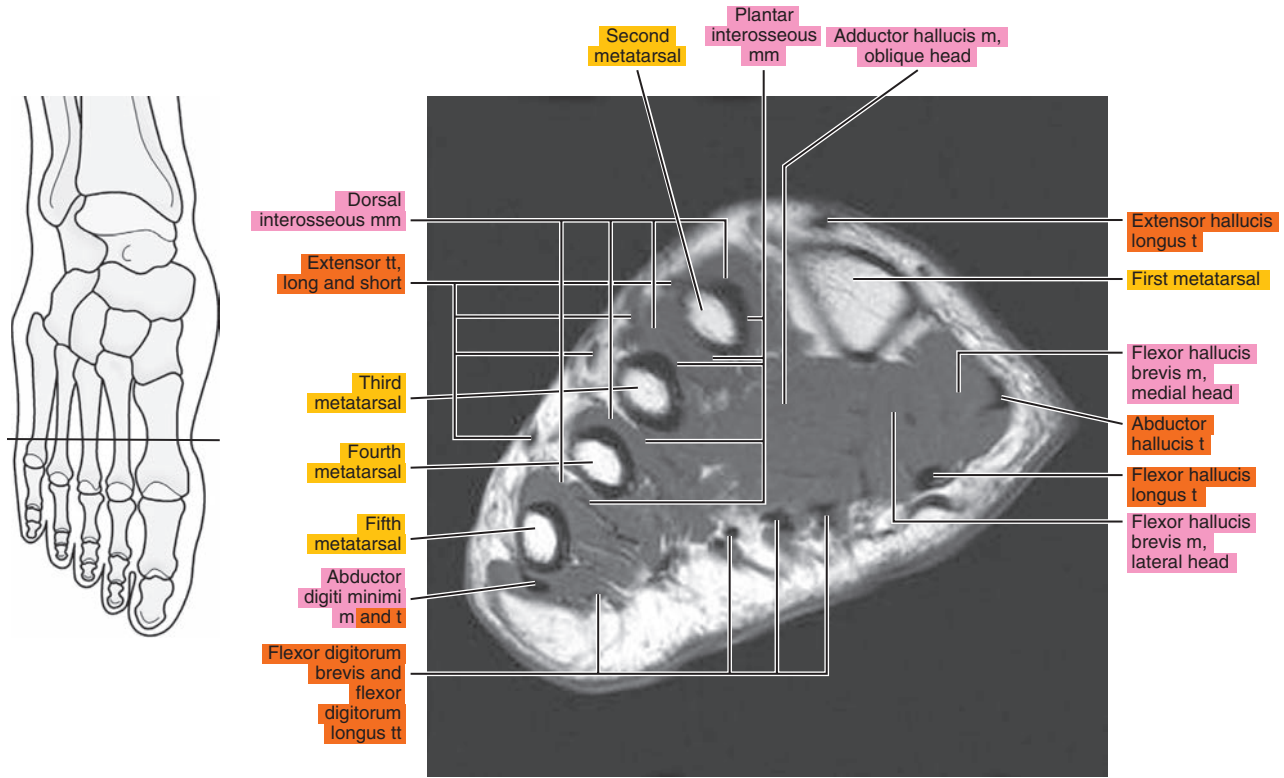


Figure 24.3.10

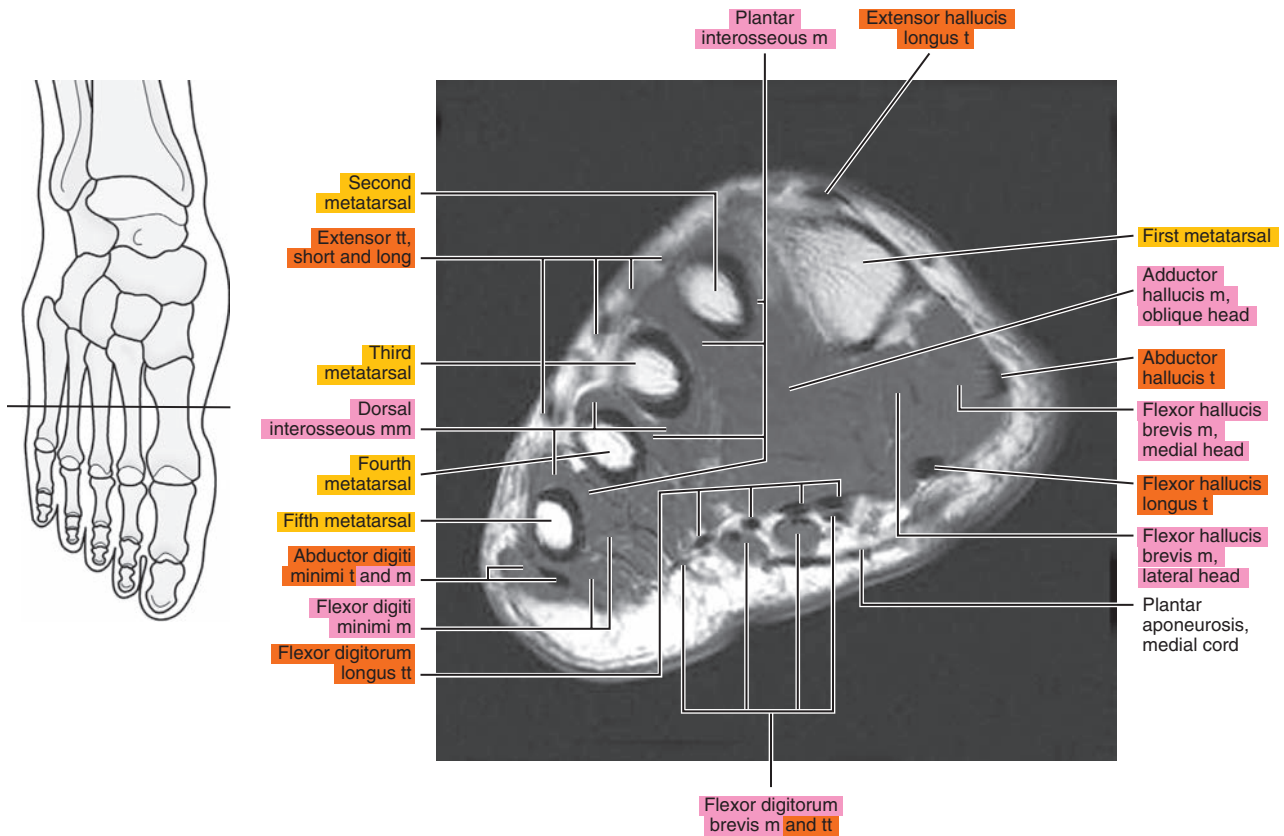




Figure 24.3.11

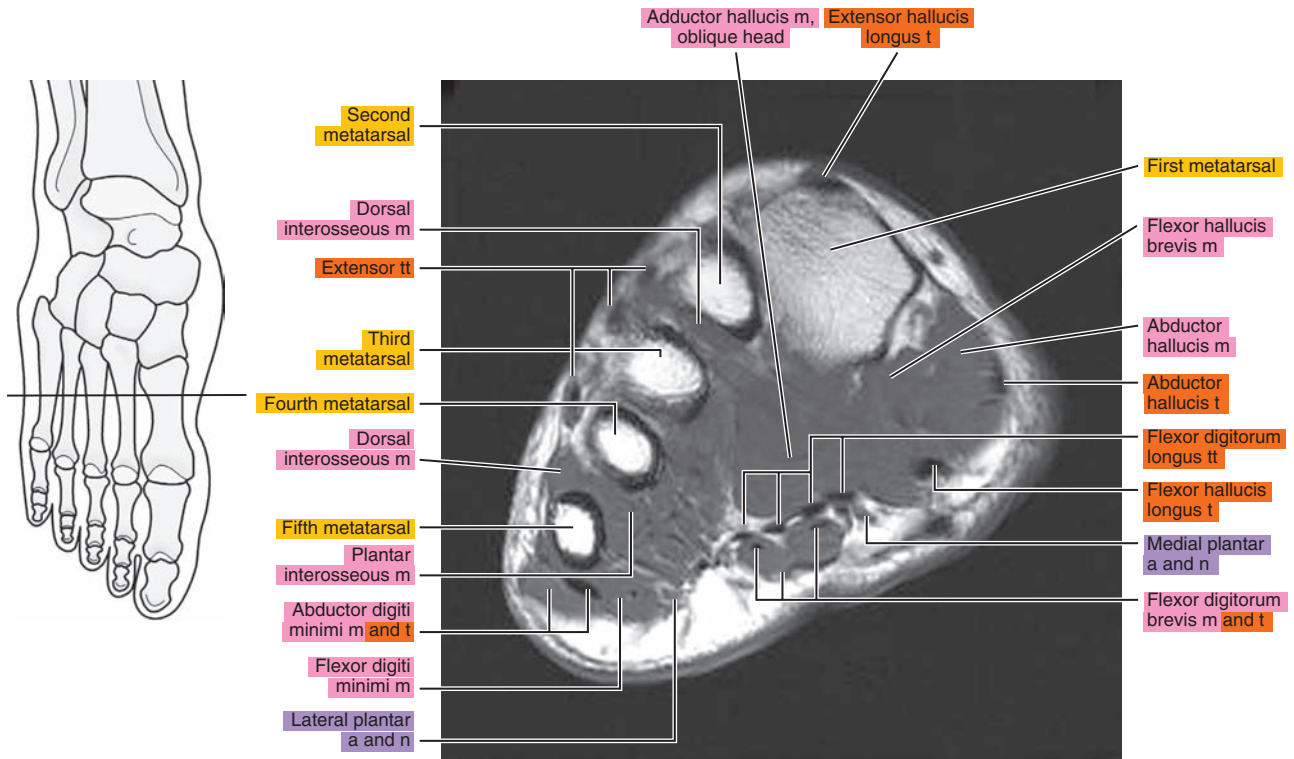


Figure 24.3.12

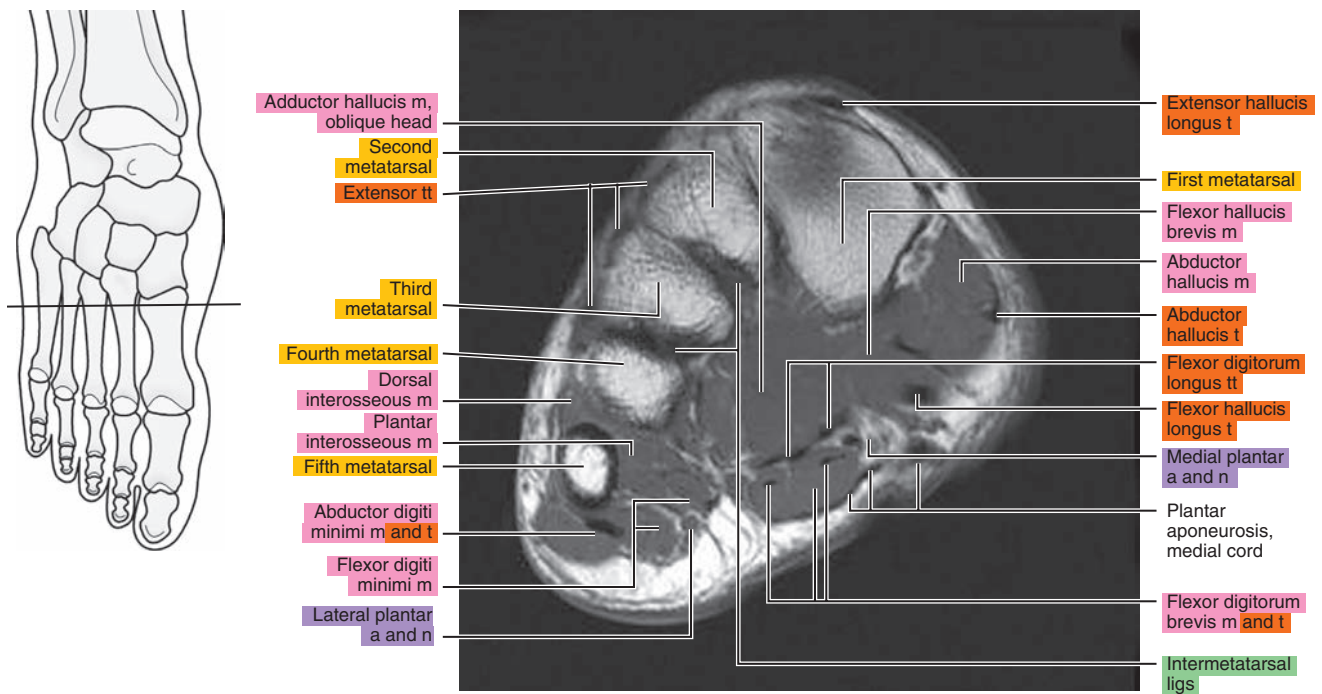


Figure 24.3.13

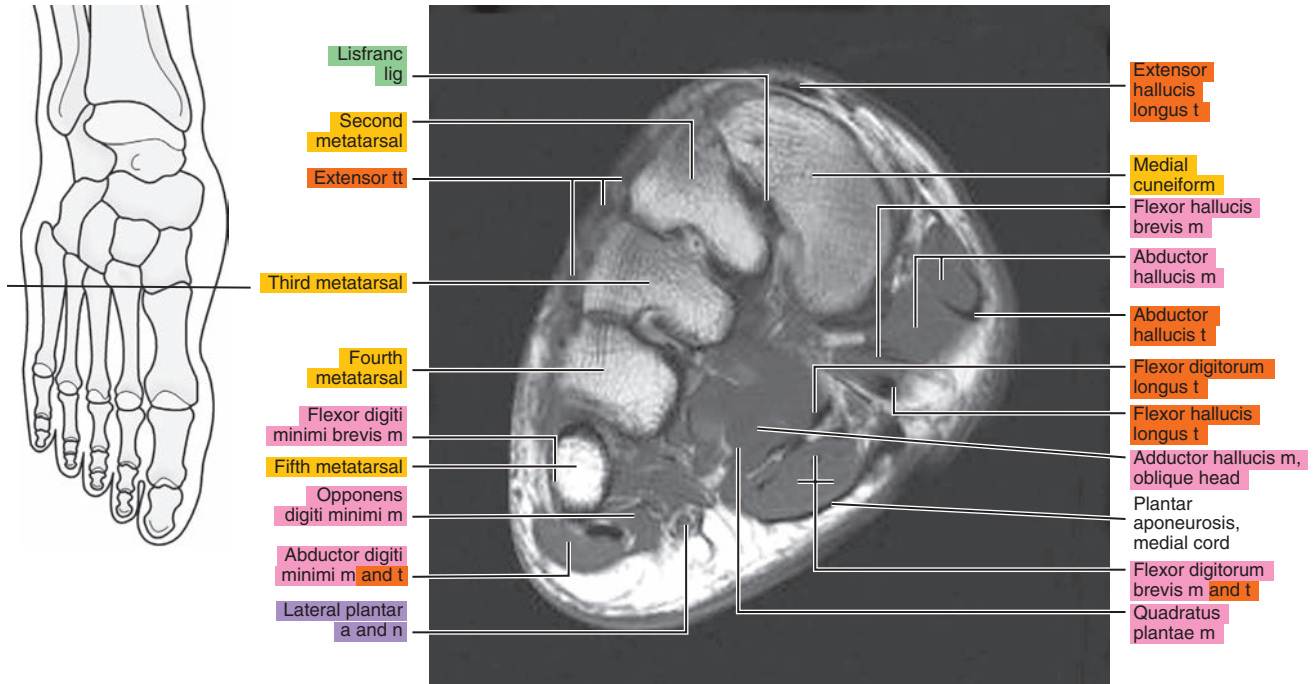


Figure 24.3.14

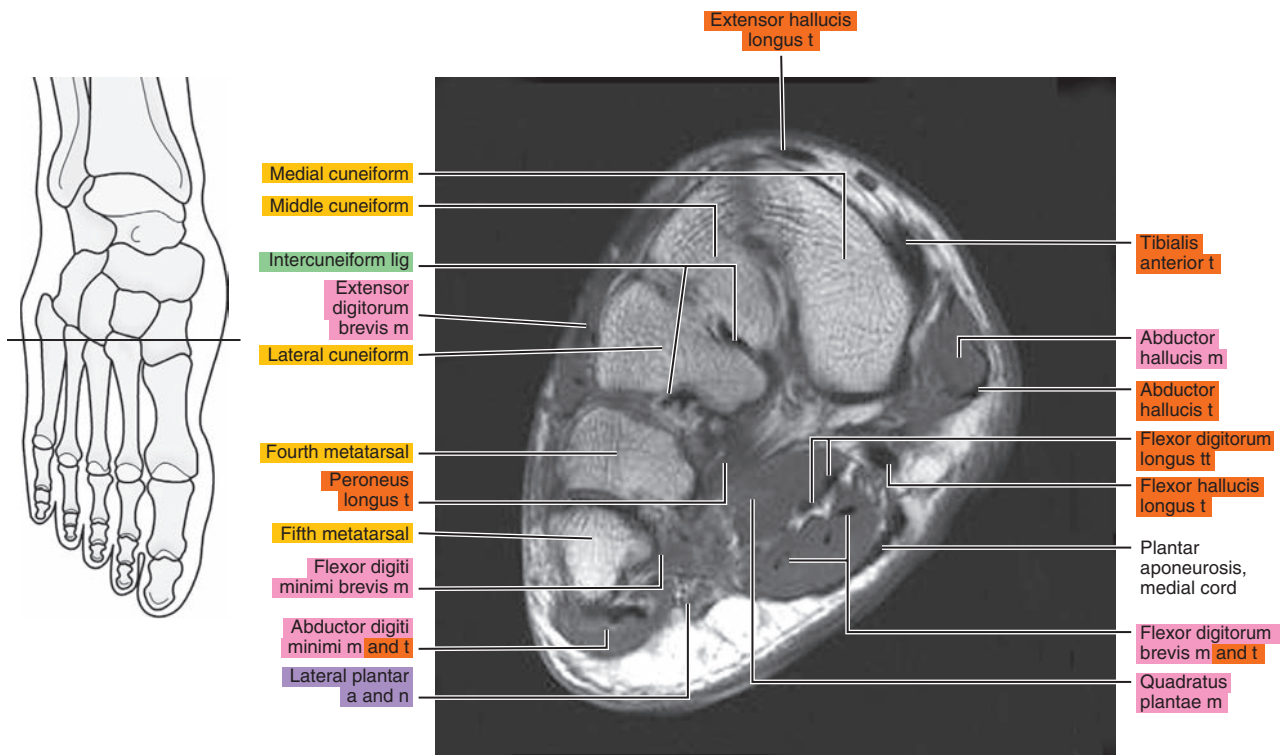


Figure 24.3.15

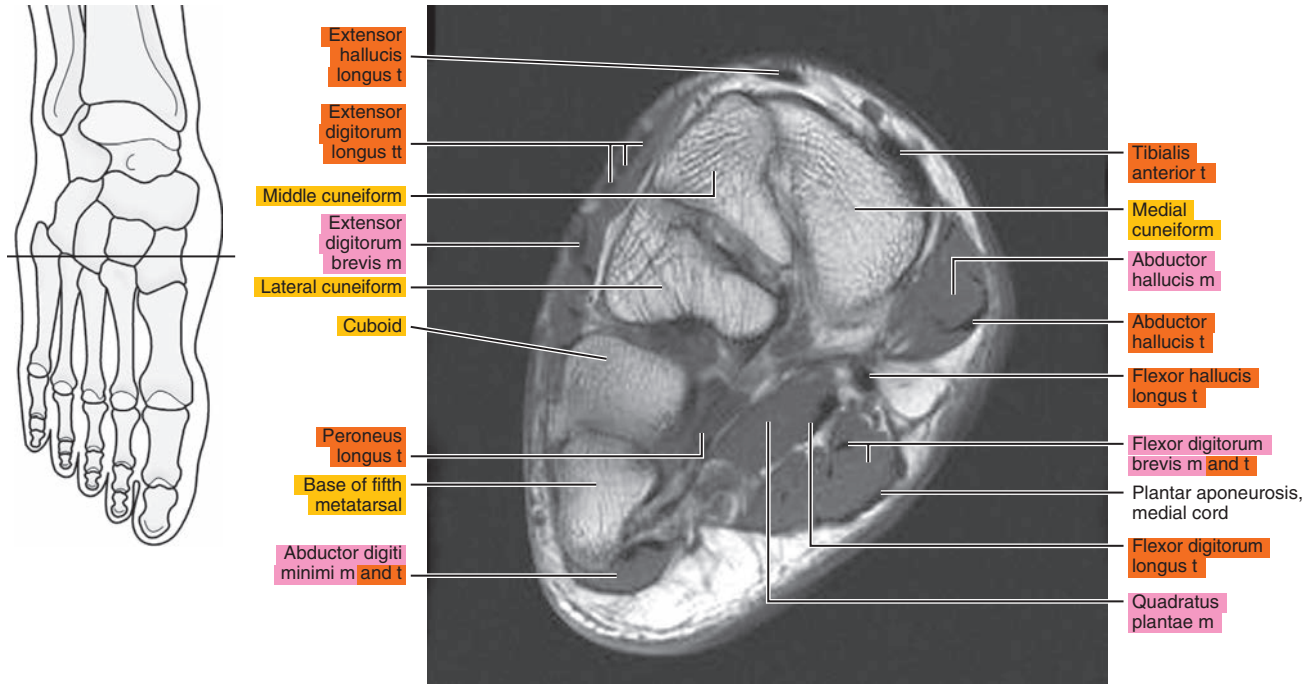


Figure 24.3.16

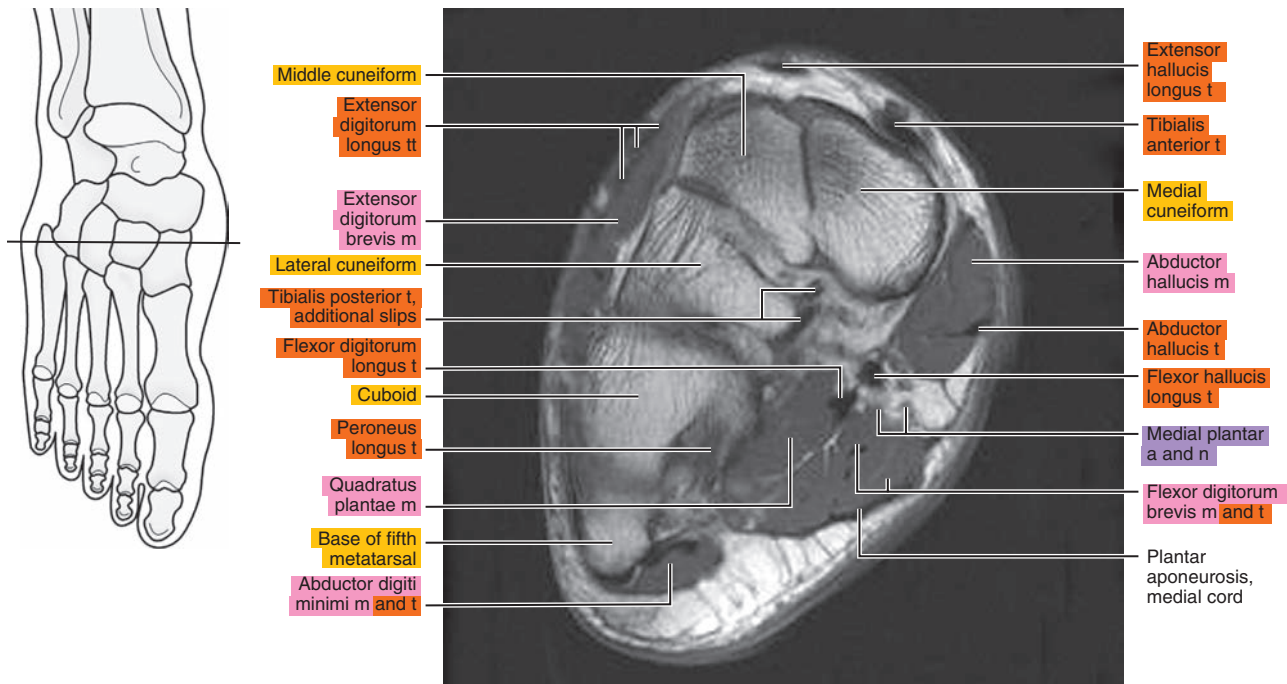




Figure 24.3.17

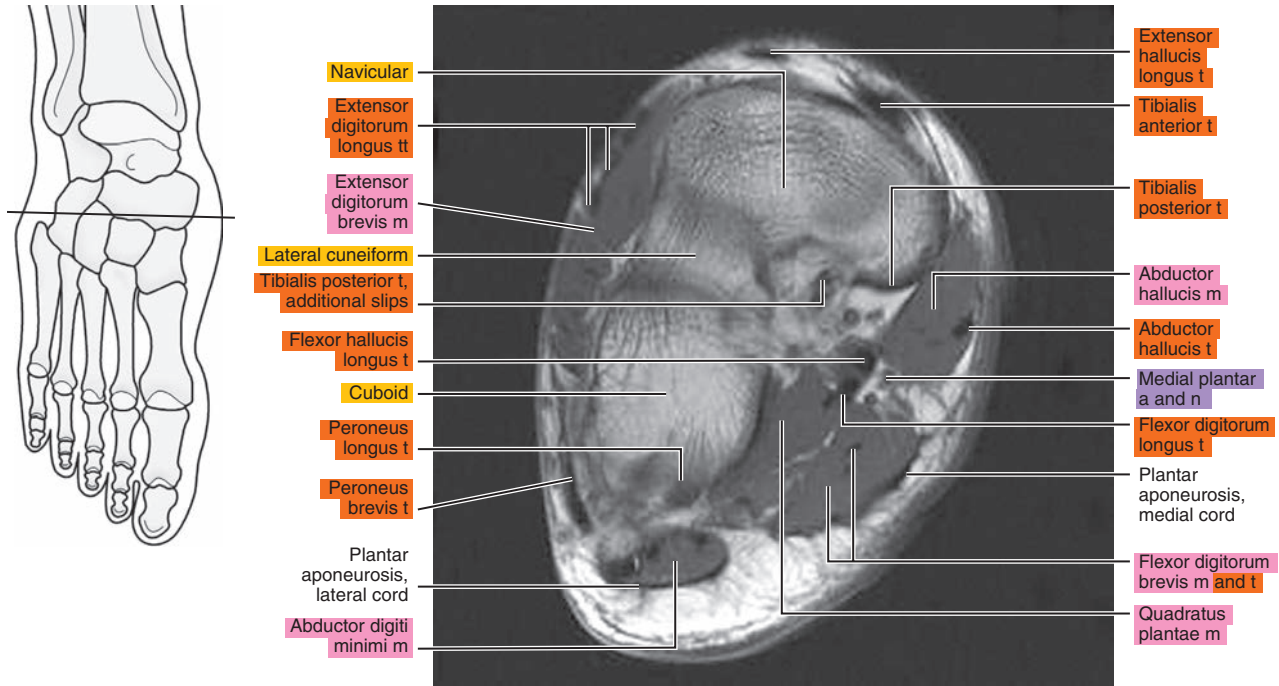
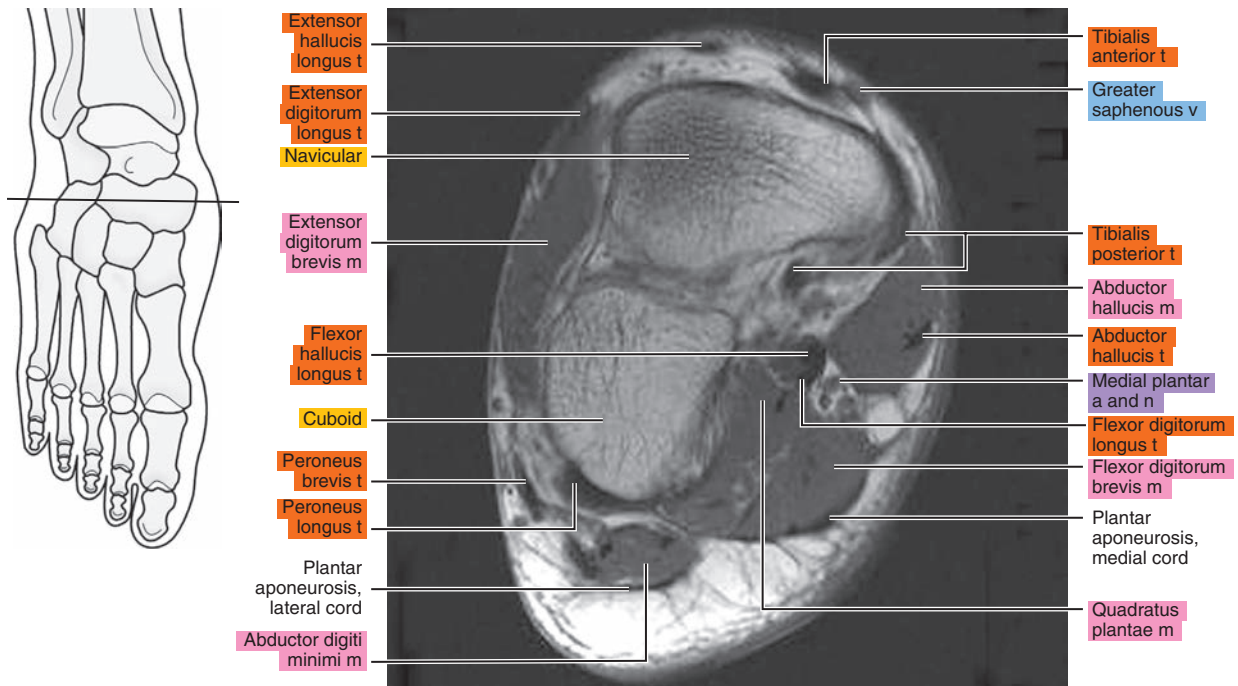


Figure 24.3.18





**Table 24-1. Muscles of the Foot**

MUSCLE	ORIGIN	INSERTION	NERVE SUPPLY
<b>Extensor digitorum brevis</b>	Distal part of the lateral and superior surfaces of the calcaneus and the apex of the inferior extensor retinaculum.	As the fiber bundles extend distally, they become grouped into four bellies. Those fibers of the most medial and largest belly are known as extensor hallucis brevis. The tendon of this muscle inserts onto the base of the first metatarsal. The remaining fiber bundles have more variable insertions. The second toe fibers usually insert onto the middle dorsal aspect of the base of the proximal phalanx and are often united with the long extensor tendon. The three more lateral tendons are usually fused with the lateral margins of the corresponding long extensor tendons near the bases of the respective middle phalanges and usually extend to the bases of the corresponding proximal phalanges.	Deep peroneal.
<b>Flexor digitorum</b>	Medial process of the tuber calcanei, posterior third of the plantar aponeurosis, and medial and lateral intermuscular septa.	Tendons of the short (brevis) flexors pass superficial to those of the long flexor into the osteofibrous canals on the flexor surface of the digits. On the proximal phalanx of each toe, the tendon of the short flexor divides and forms an opening through which the tendon of the long flexor passes. The tendons of the short flexor insert onto the base of the middle phalanx.	Surface near the medial edge of the muscle.
<b>Quadratus plantae (flexor accessorius)</b>	Two heads: a small lateral and a large medial one. (1) Lateral head arises from an elongated tendon from the lateral process of the tuberosity of the calcaneus and from the lateral margin of the long plantar ligament. (2) Medial head originates from the medial surface of the calcaneus in front of the tuberosity and from adjacent ligaments.	The two heads are separated at their origin by a short triangular space. The heads fuse to form a single belly, but the fiber bundles of each head are separately inserted. From the lateral head, the fibers insert into the lateral margin of the flexor tendon. The medial head inserts as an aponeurosis into the deep surface of the flexor tendon.	Lateral plantar nerve branch that passes obliquely across the superficial surface of the muscle, parallel with the tendon of the flexor digitorum longus.
<b>Lumbricals</b>	Three lateral lumbricals arise from the adjacent sides of the digital tendons of the flexor digitorum longus. The first lumbrical arises on the medial margin of the second toe.	Fiber bundles of each muscle converge on both sides of a tendon that becomes free near the metatarsophalangeal joint and is inserted onto the medial side of the proximal phalanx of the appropriate toe. A tendinous expansion is inserted into the aponeurosis of the extensor muscle.	Three lateral lumbricals are usually supplied by branches of the deep ramus of the lateral plantar nerve. Medial lumbrical is supplied by the first common plantar digital branch of the medial plantar nerve. This nerve may supply the two more medial muscles, or the medial muscles may receive a double nerve supply.

**Table 24-1. Muscles of the Foot**

MUSCLE	ORIGIN	INSERTION	NERVE SUPPLY
<b>Abductor hallucis</b>	Medial border of the medial process of the tuber calcanei, flexor retinaculum, and plantar aponeurosis.	Along with the tendon of the medial belly of flexor brevis onto the base of the proximal phalanx of the great toe.	Branch of the medial plantar.
<b>Flexor hallucis brevis</b>	From the plantar surface of the lateral cuneiform and cuboid bones.	The medial and lateral sides of the base of the proximal phalanx of the great toe.	Branch from the medial plantar or first plantar digital. Rarely, the lateral body may receive a branch from the lateral plantar.
<b>Adductor hallucis, oblique head</b>	Tuberosity of the cuboid and sheath of the tendon of the peroneus longus, the plantar calcaneocuboid ligament, the third cuneiform, and bases of the second and third metatarsals.	By a flat tendon that inserts in common with that of the flexor brevis onto the lateral part of the plantar surface of the base of the proximal phalanx and by a slip into the aponeurosis of the long extensor muscle on the back of the great toe.	Branch of the deep ramus of the lateral plantar.
<b>Adductor hallucis, transverse head</b>	Joint capsules of the third, fourth, and fifth metatarsophalangeal joints and the deep transverse metatarsal ligaments.	By a common tendon that splits and passes on each side of the tendon of the oblique head and is inserted into the sheath on the tendon of the long flexor of the great toe.	Branch from the deep ramus of the lateral plantar.
<b>Abductor digiti minimi</b>	Lateral and medial processes of the tuber calcanei and lateral and plantar surfaces of the body of the bone in front of these, lateral intermuscular septum, deep surface of the lateral plantar fascia, and fibrous band extending from the calcaneus to the lateral side of the base of the fifth metatarsal.	Onto the lateral surface of the proximal phalanx of the little toe and the metatarsophalangeal capsule.	Lateral plantar.
<b>Flexor digiti minimi brevis</b>	Sheath of the peroneus longus, tuberosity of the cuboid, and base of the fifth metatarsal.	By short tendinous bands onto the base of the proximal phalanx of the little toe, the capsule of the corresponding joint, and the aponeurosis on the dorsal surface of the toe.	Branch from the superficial ramus of the lateral plantar.
<b>Opponens digiti minimi</b>	An inconstant muscle, it may arise from the sheath of the peroneus longus and the tuberosity of the cuboid by a thin tendon that passes over the tuberosity of the fifth metatarsal.	Onto the lateral surface of the fifth metatarsal.	Branch from the nerve to the flexor brevis and the superficial ramus of the lateral plantar.

*continued*

**Table 24-1. Muscles of the Foot—cont'd**

<b>MUSCLE</b>	<b>ORIGIN</b>	<b>INSERTION</b>	<b>NERVE SUPPLY</b>
<b>Interosseous, dorsal</b>	Each of the three lateral dorsal interosseous muscles arises from the sides of the shaft and the plantar surface of the bases of the metatarsals, bounding the space in which each lies, from the fascia covering it dorsally, and from the fibrous prolongations from the long plantar ligament. The first (medial) has a similar origin, except that its medial origin is by a tendinous slip from the peroneus longus tendon and, occasionally, by fiber bundles from the medial side of the proximal end of the first metatarsal.	The first and second interosseous muscles onto each side of the base of the proximal phalanx of the second toe; the third and fourth onto the lateral side of the bases of the proximal phalanges of the third and fourth toes. Each tendon adheres to the capsule of the adjacent joint.	Deep branch of the lateral plantar. The interosseous muscles of the fourth interspace are usually supplied by a branch from the superficial ramus of the lateral plantar.
<b>Interosseous, plantar</b>	The plantar interosseous muscle arises from the proximal third of the medial plantar surface of the shaft, from the base of the metatarsal on which it lies, and from the fascial expansions of the long plantar ligament.	Onto a tubercle on the medial side of the base of the proximal phalanx of the digit to which it goes.	Lateral plantar.

*Chapter*  
**25**

**CT of the Male Pelvis**



# AXIAL

Figure 25.1.1

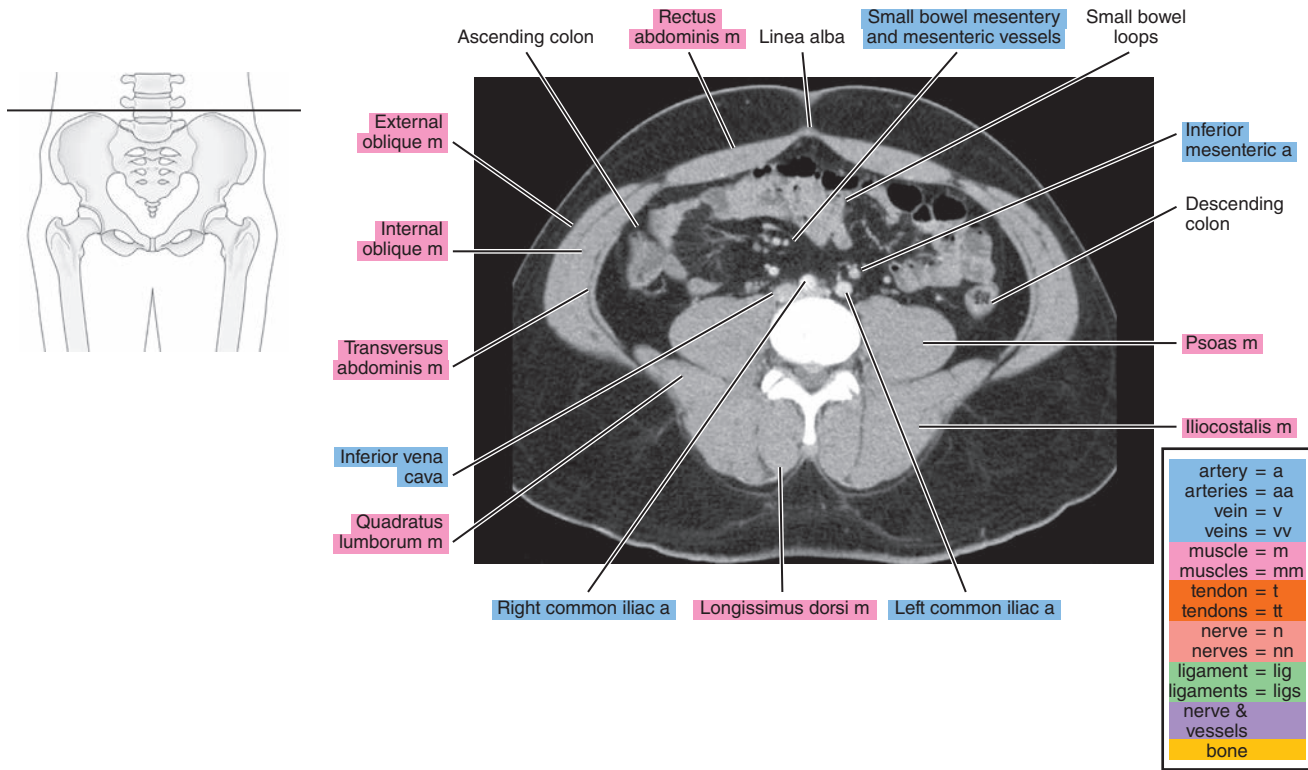


Figure 25.1.2

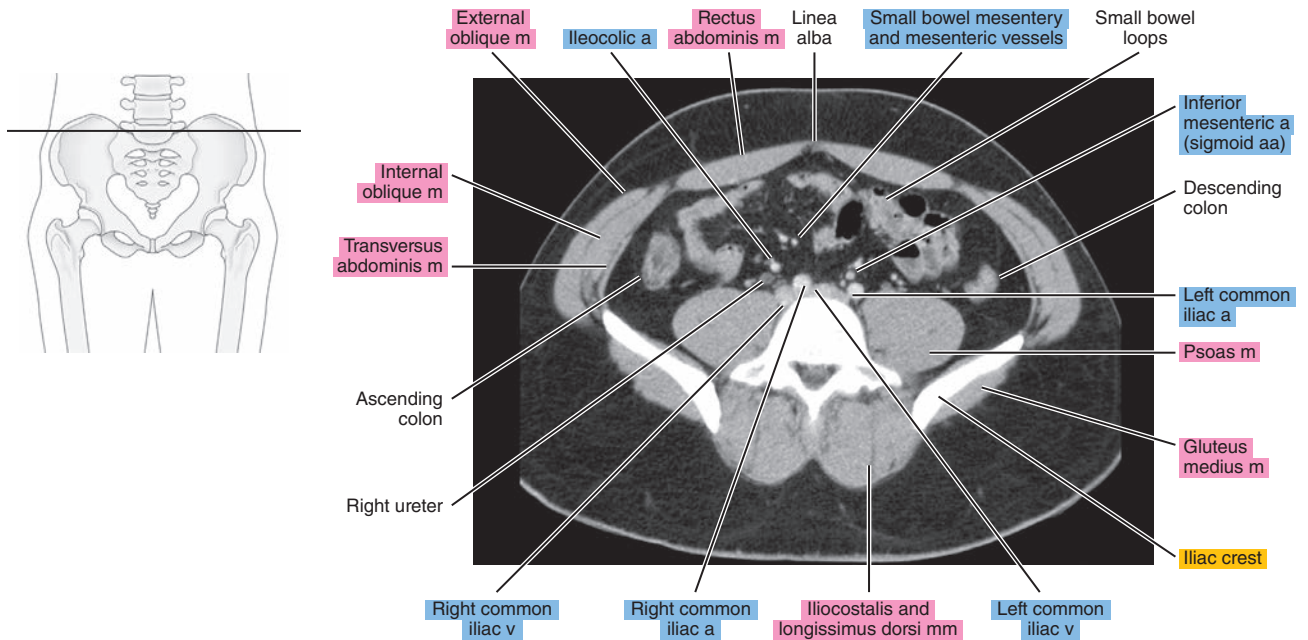


Figure 25.1.3

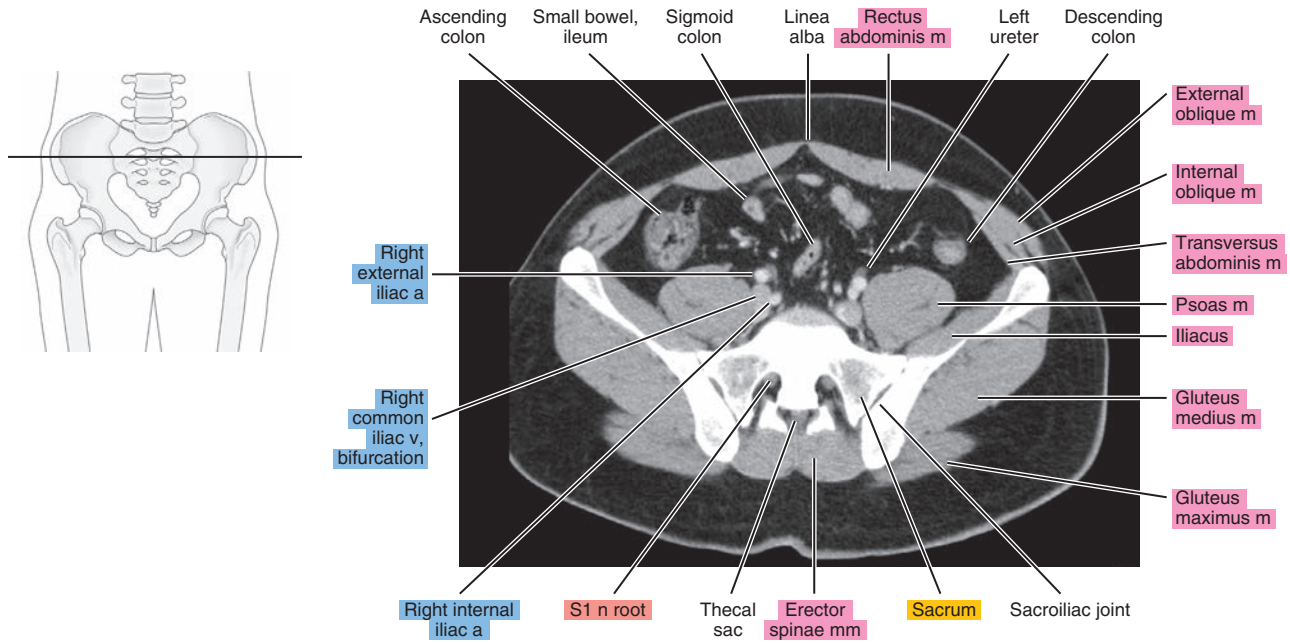


Figure 25.1.4

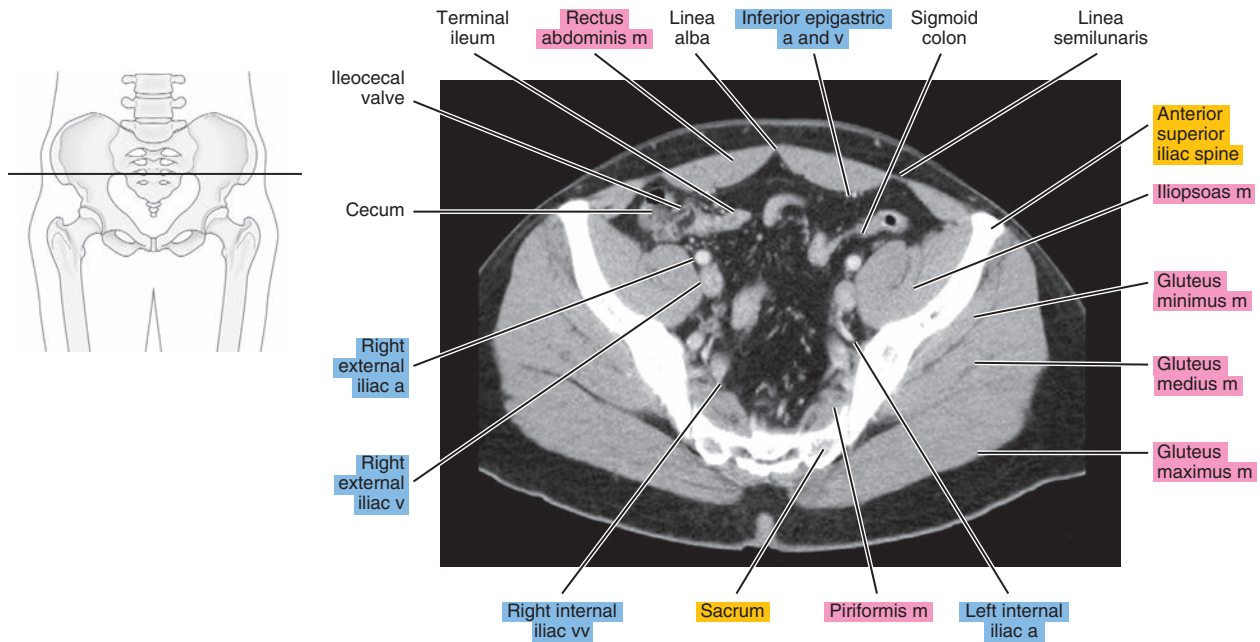


Figure 25.1.5

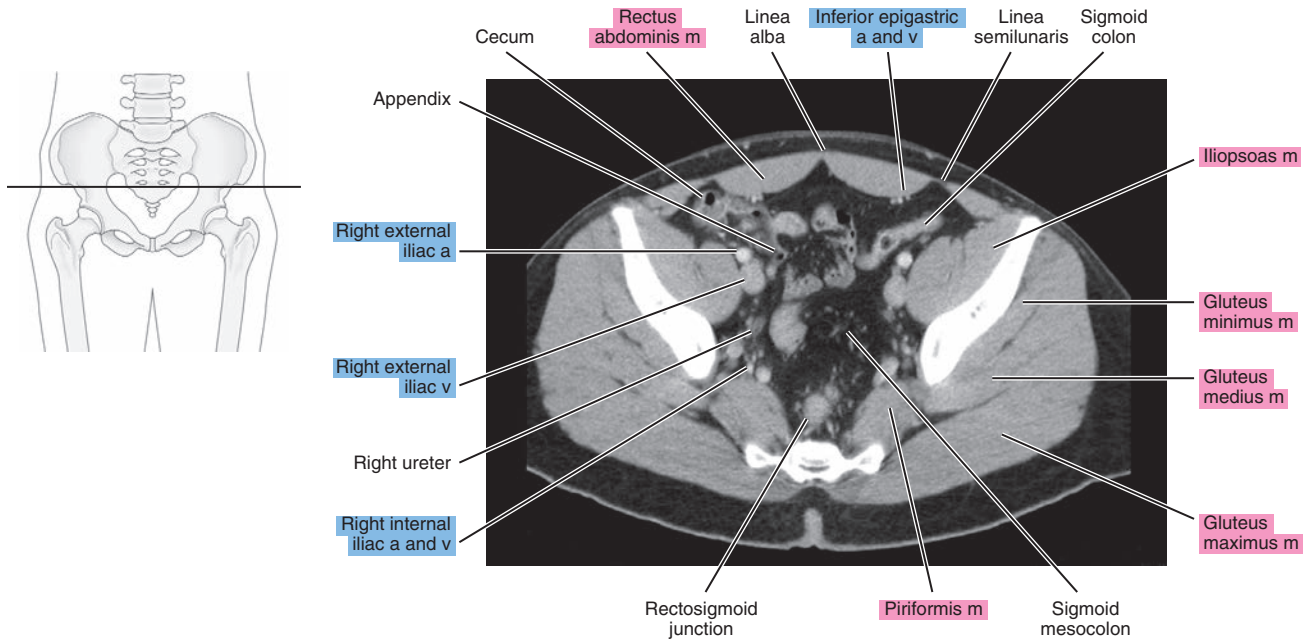


Figure 25.1.6

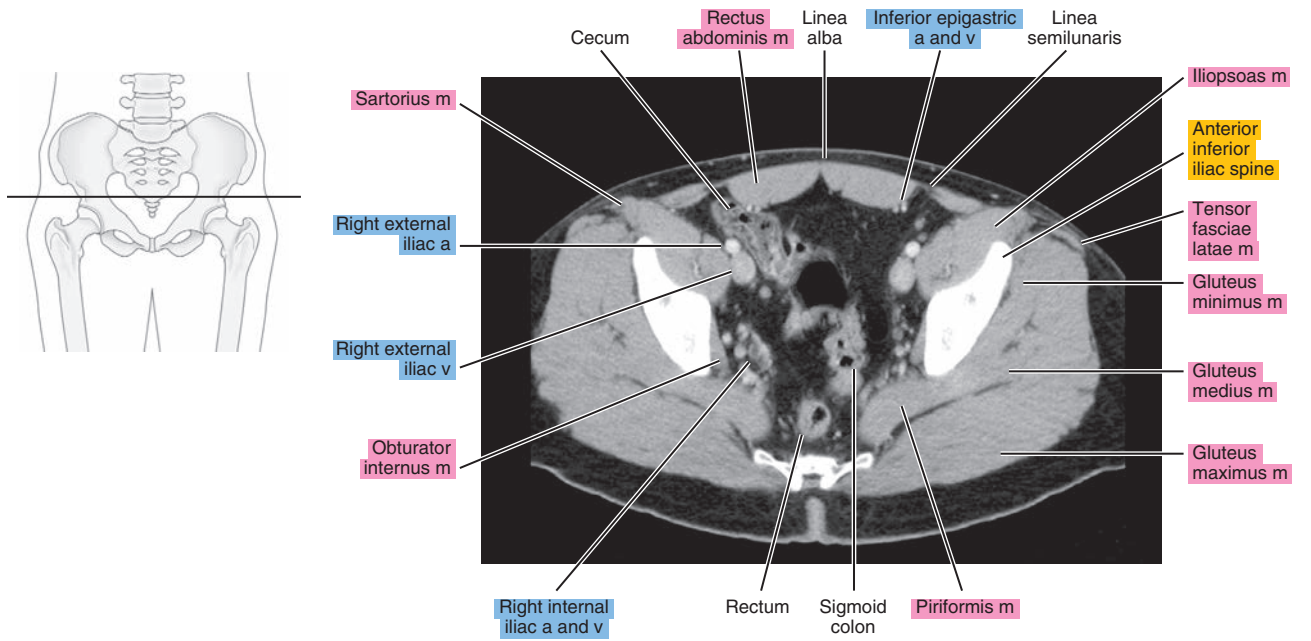


Figure 25.1.7

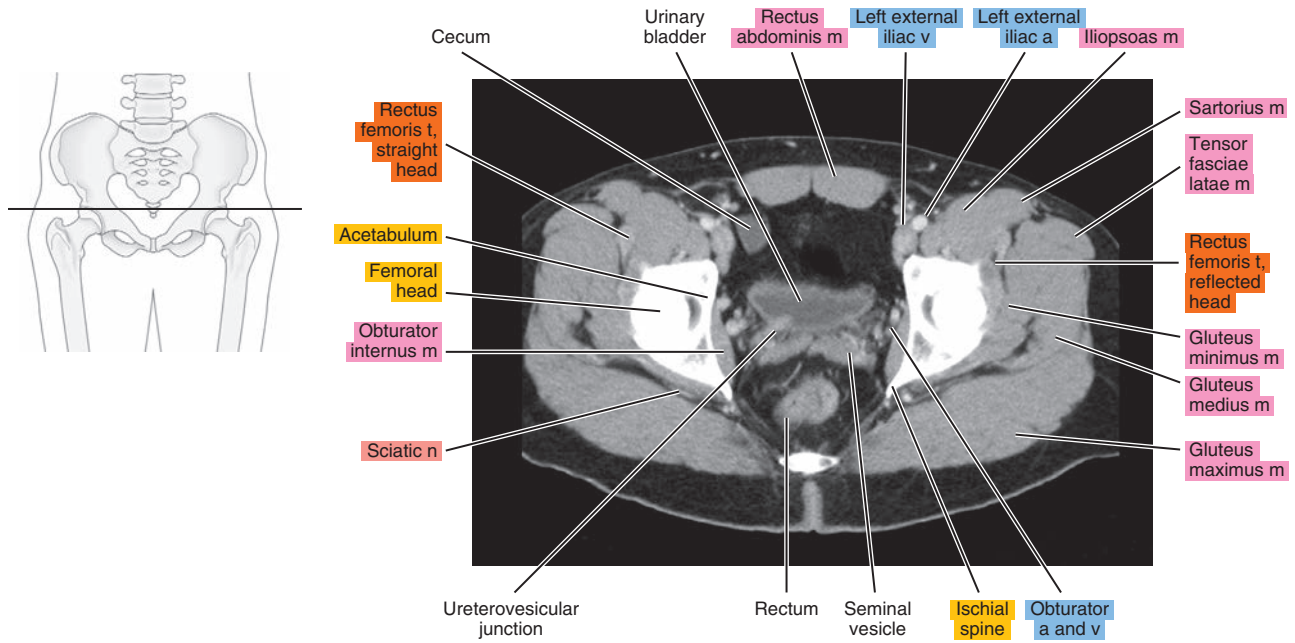


Figure 25.1.8

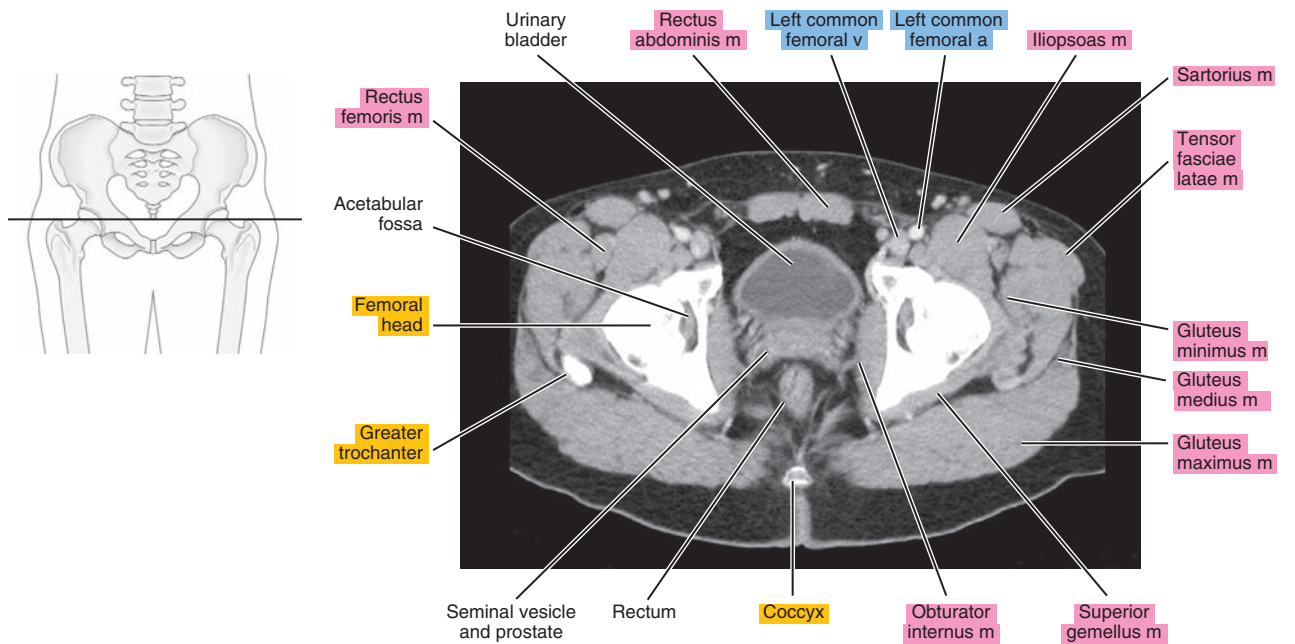




Figure 25.1.9

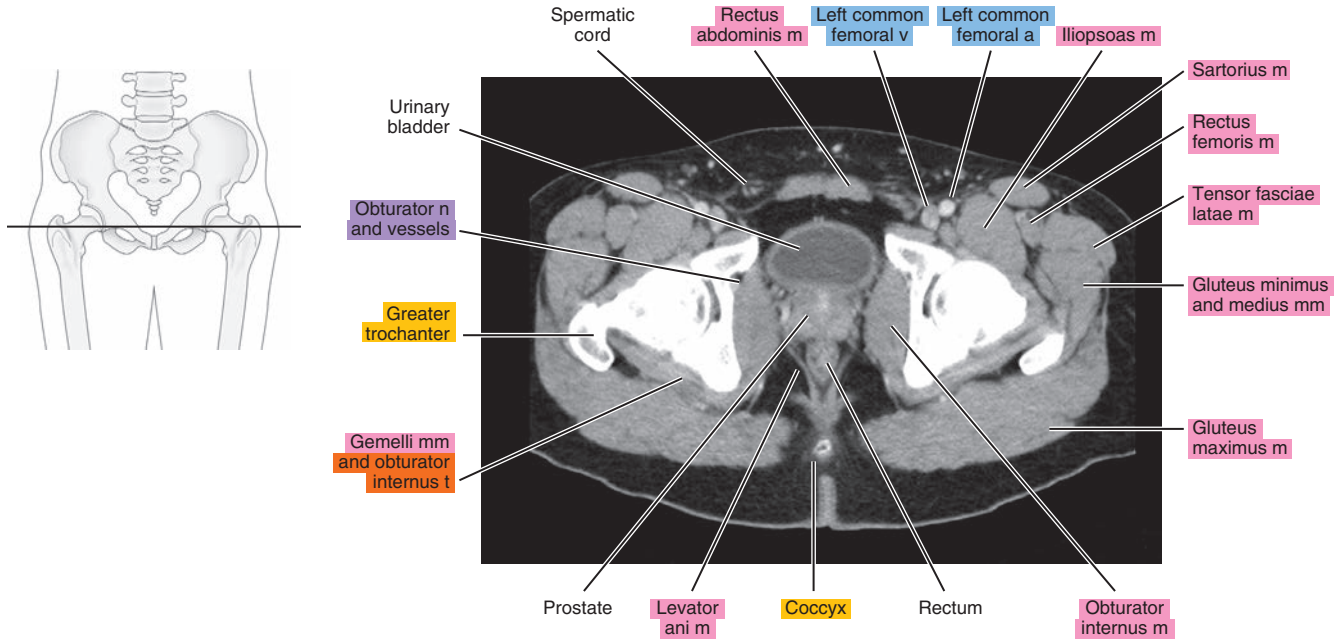


Figure 25.1.10

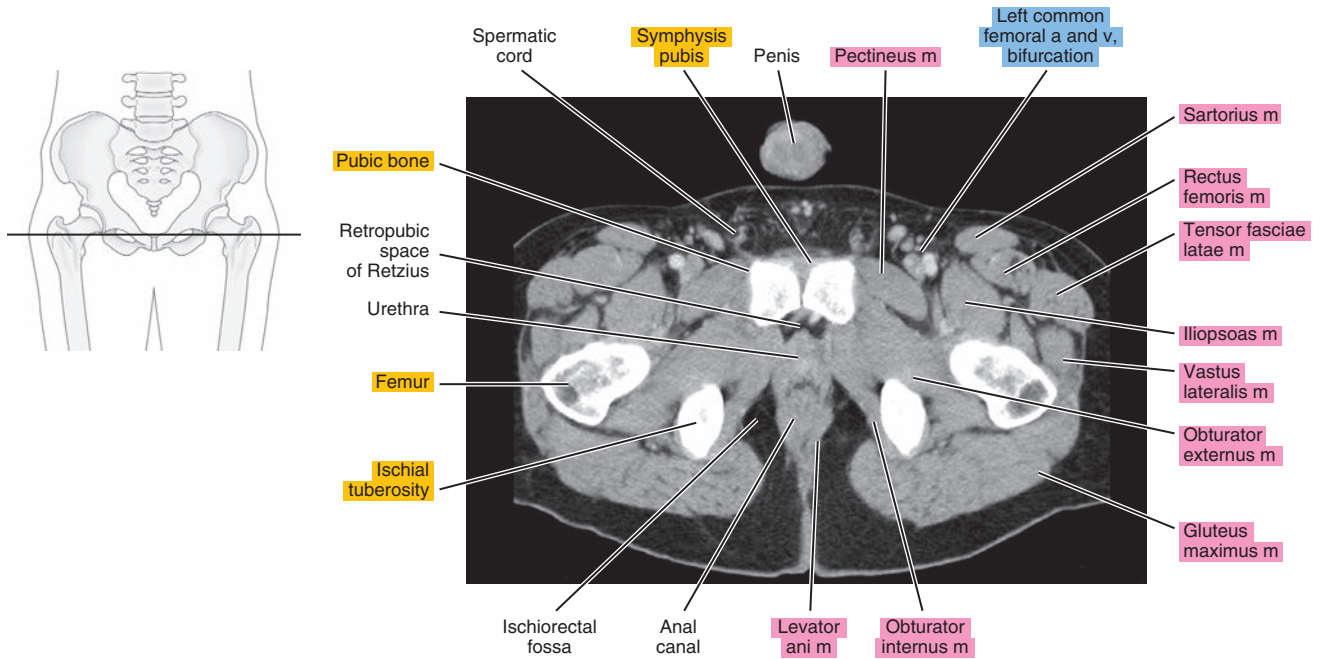


Figure 25.1.11

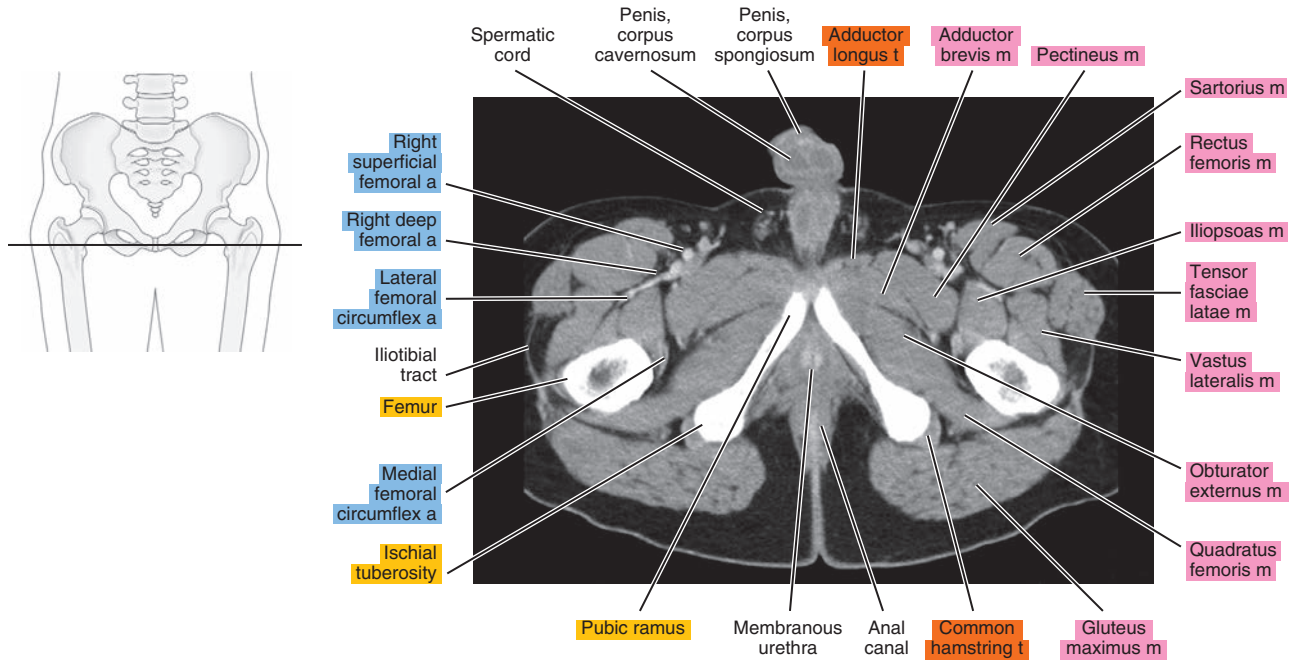
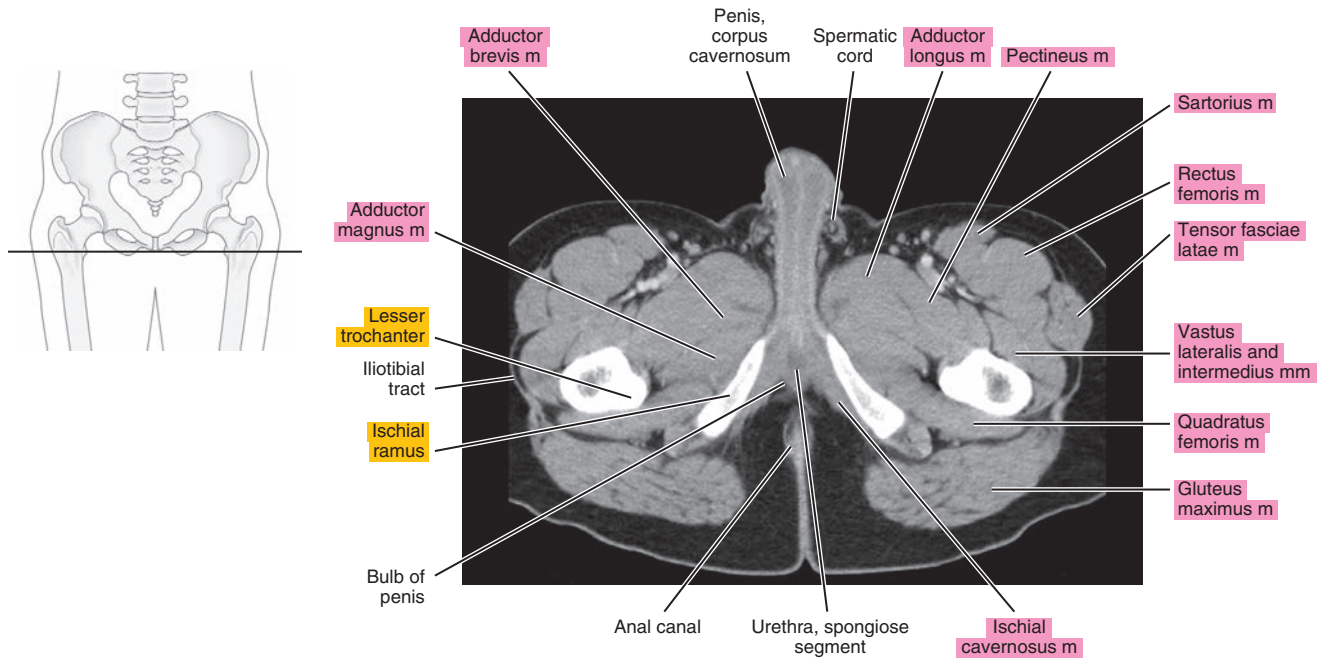


Figure 25.1.12



# SAGITTAL

Figure 25.2.1

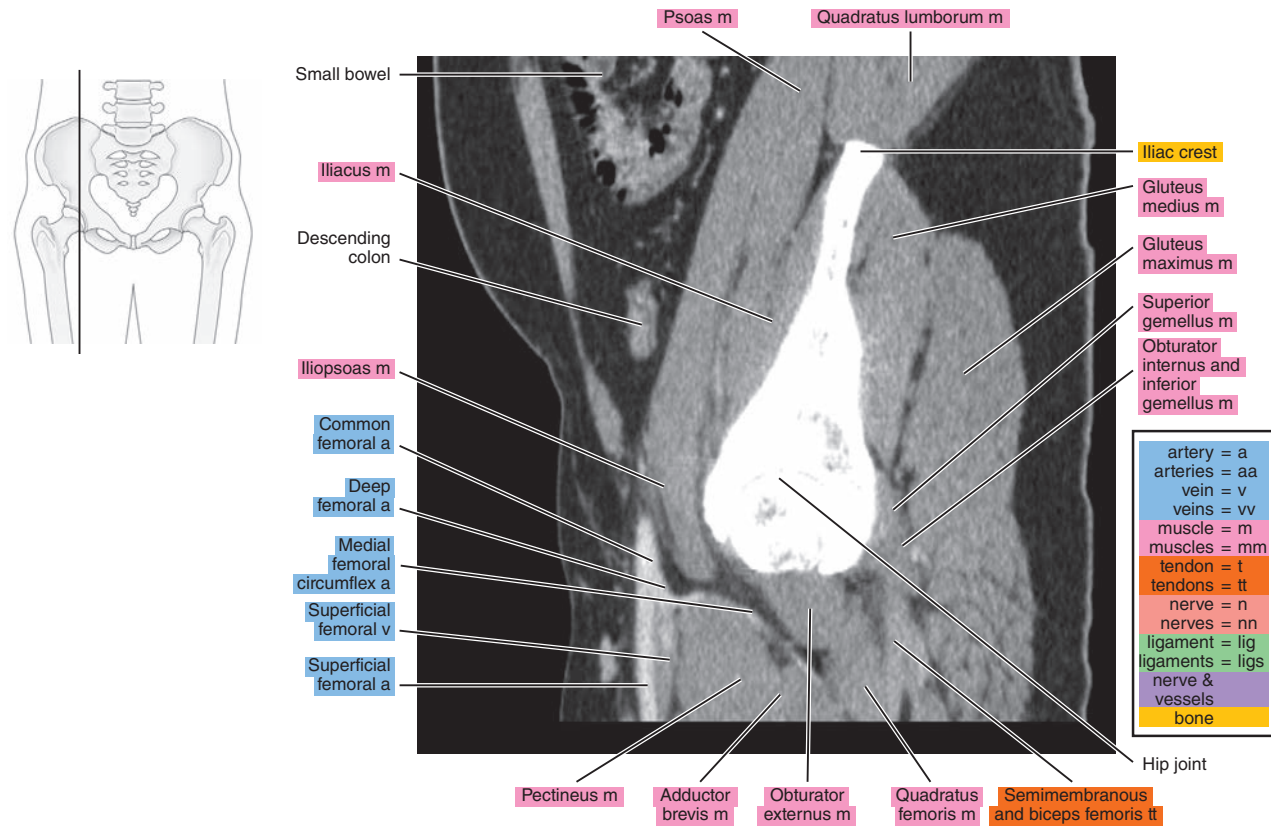


Figure 25.2.2

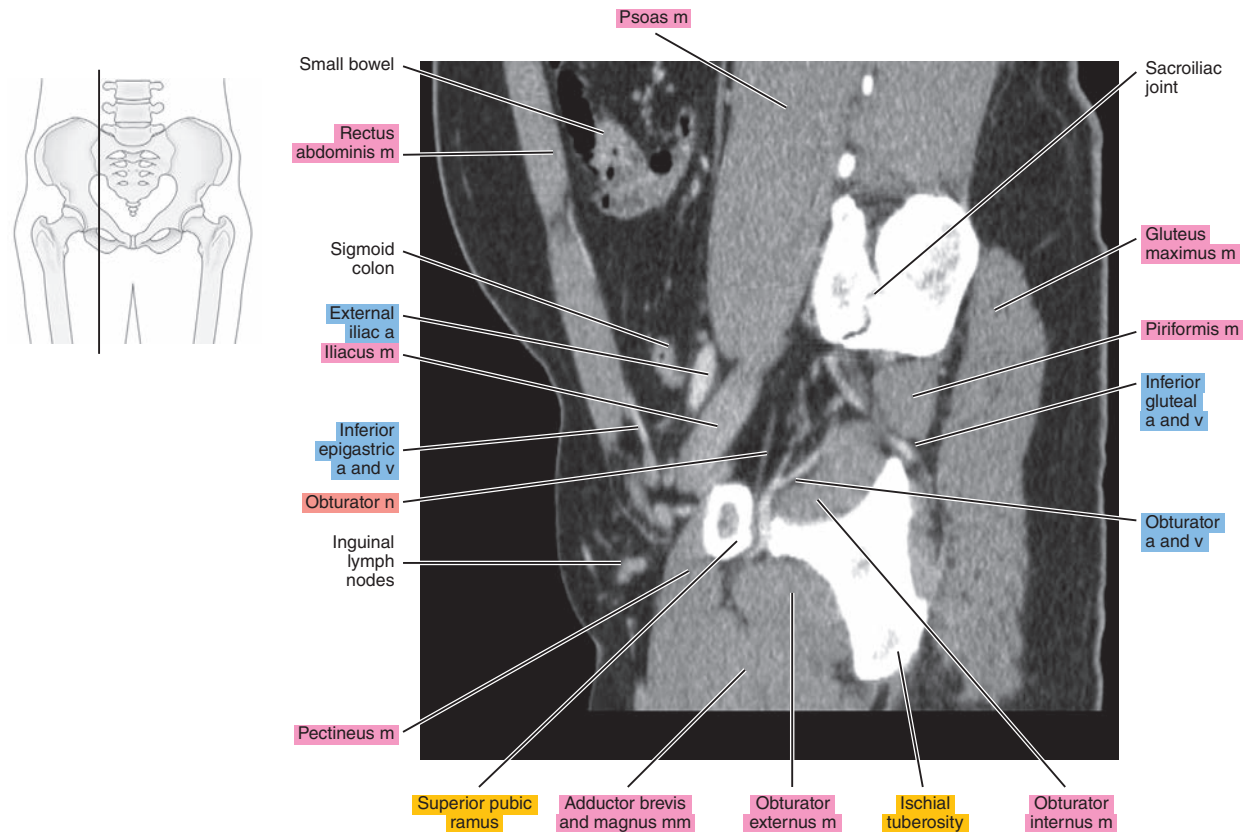




Figure 25.2.3

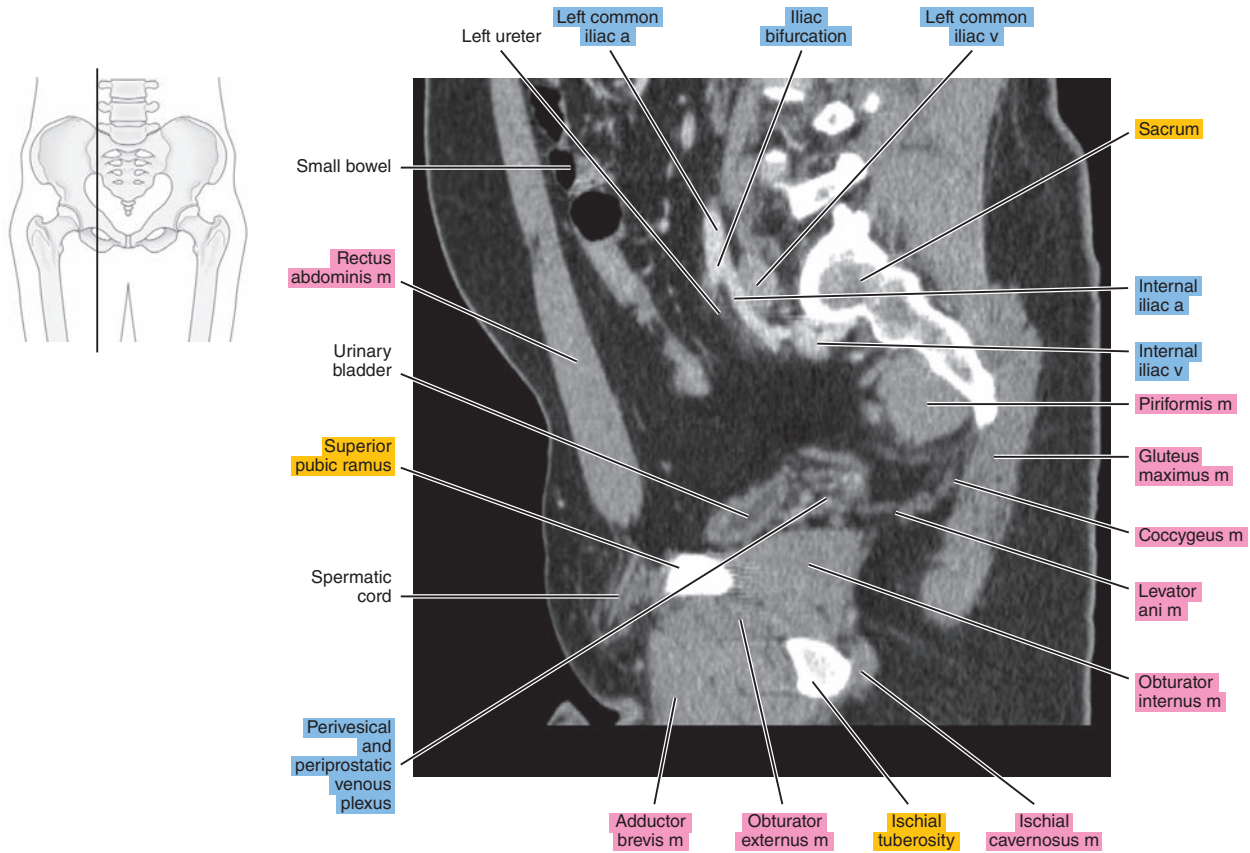


Figure 25.2.4

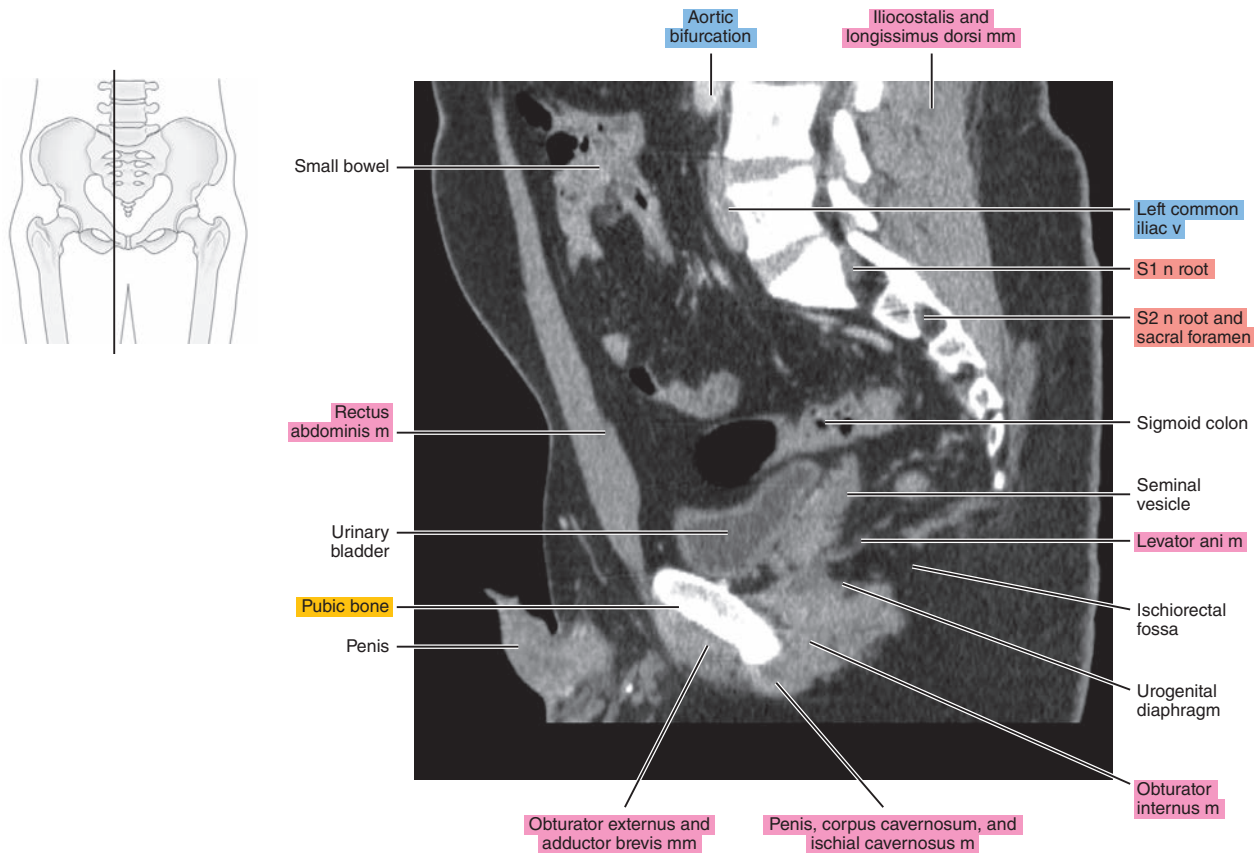
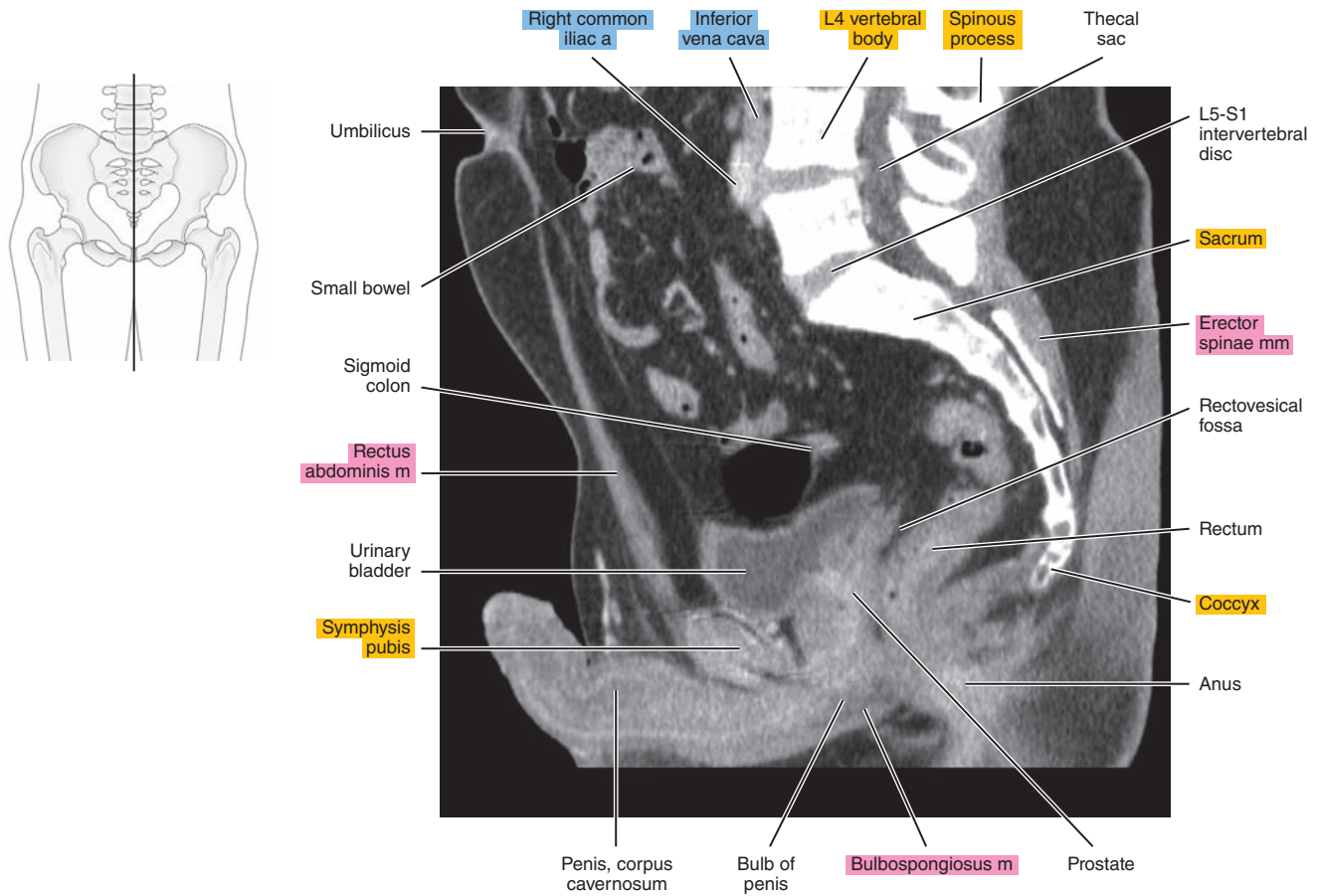




Figure 25.2.5



# CORONAL

Figure 25.3.1

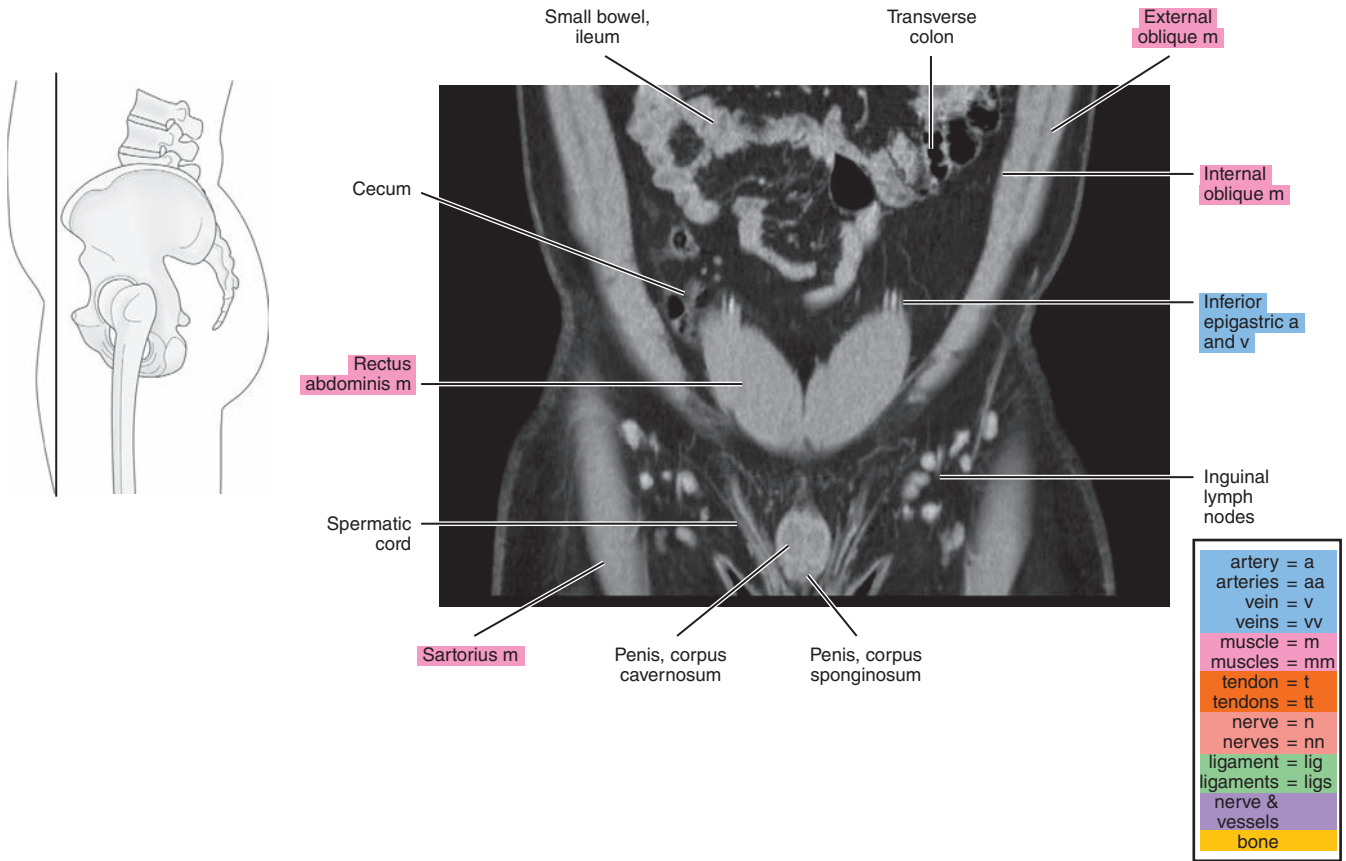


Figure 25.3.2

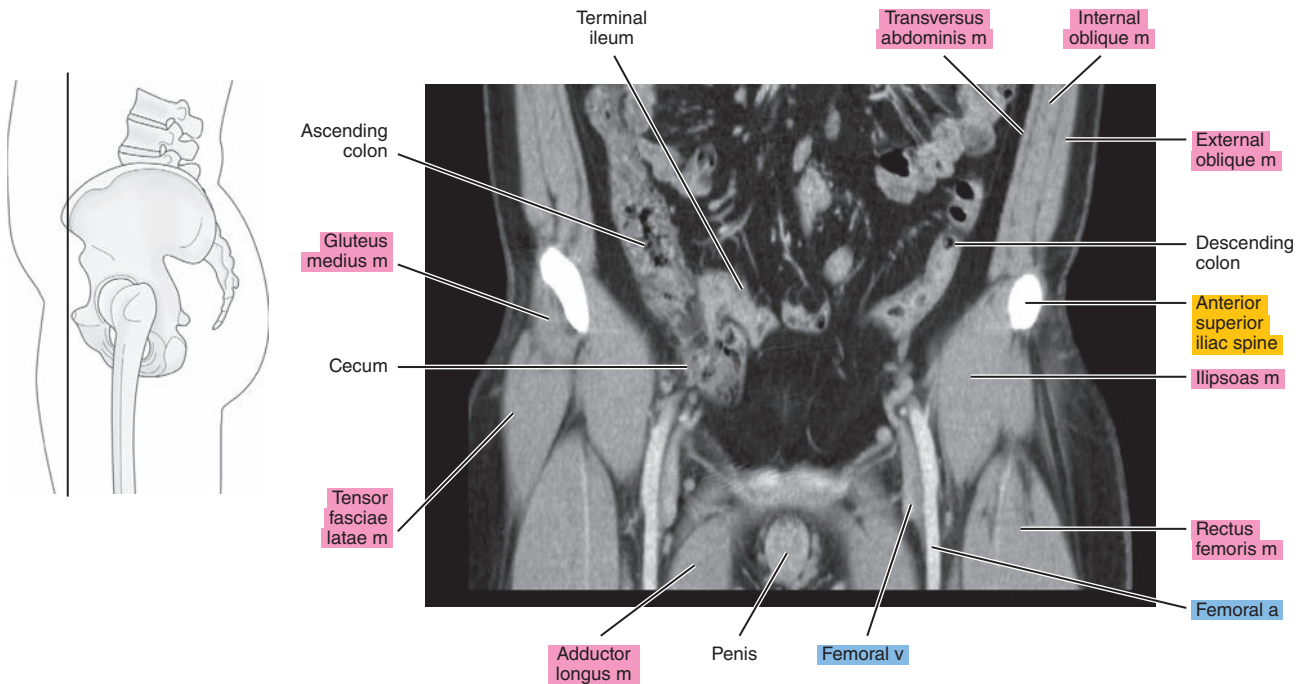


Figure 25.3.3

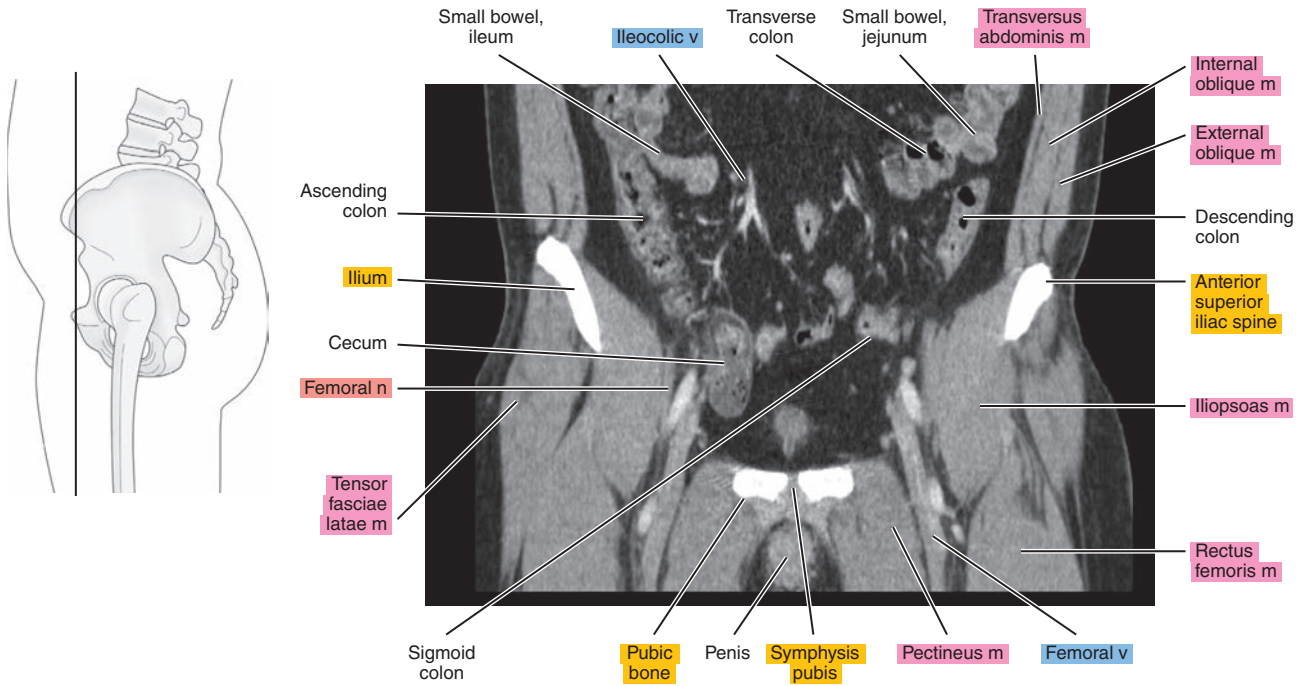


Figure 25.3.4

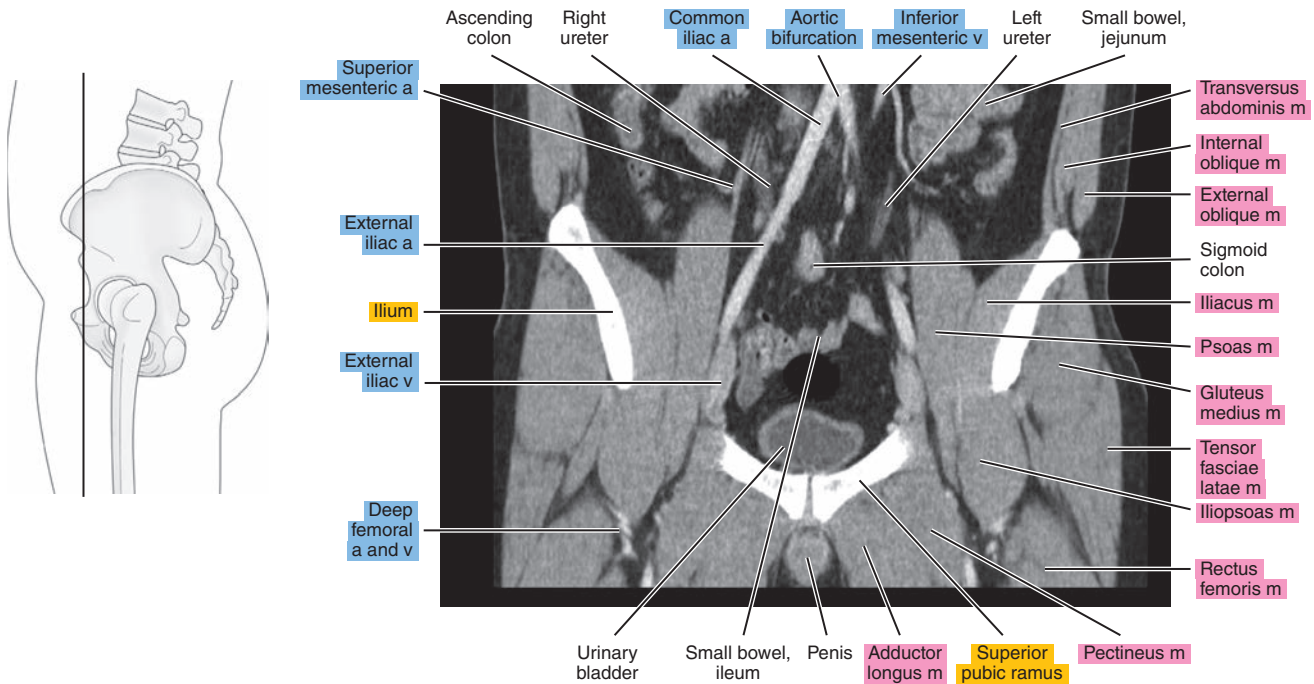


Figure 25.3.5

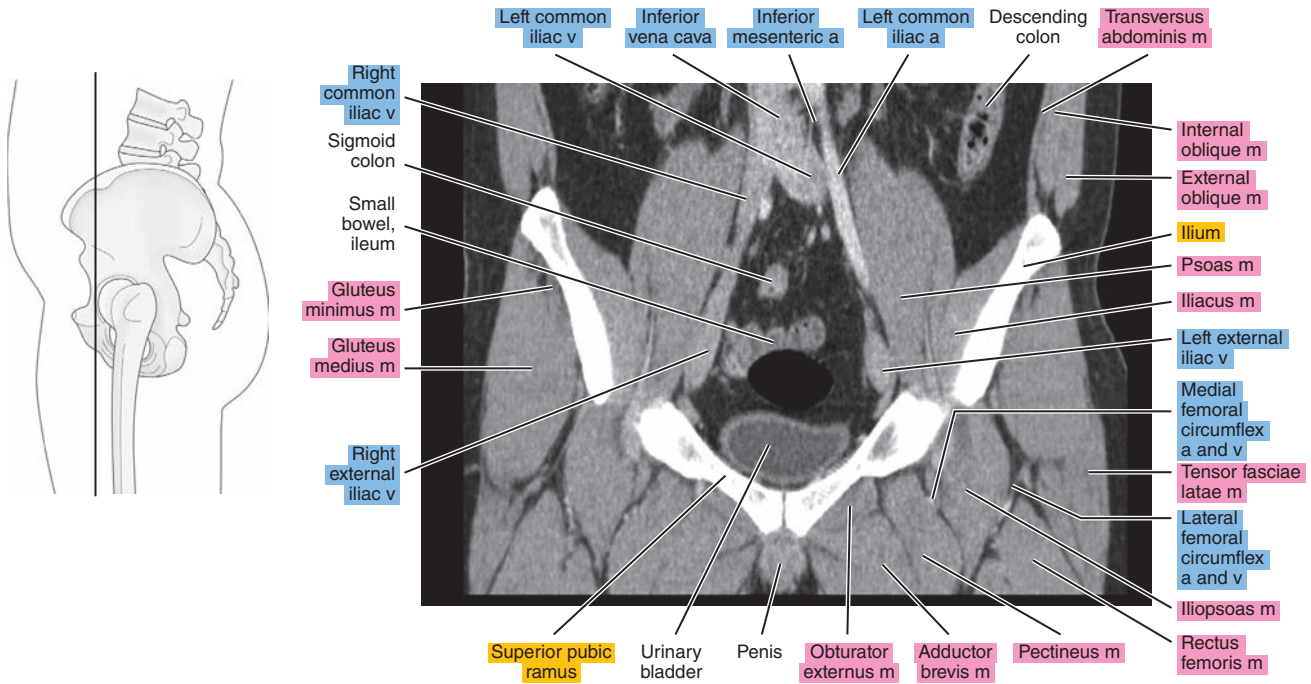


Figure 25.3.6

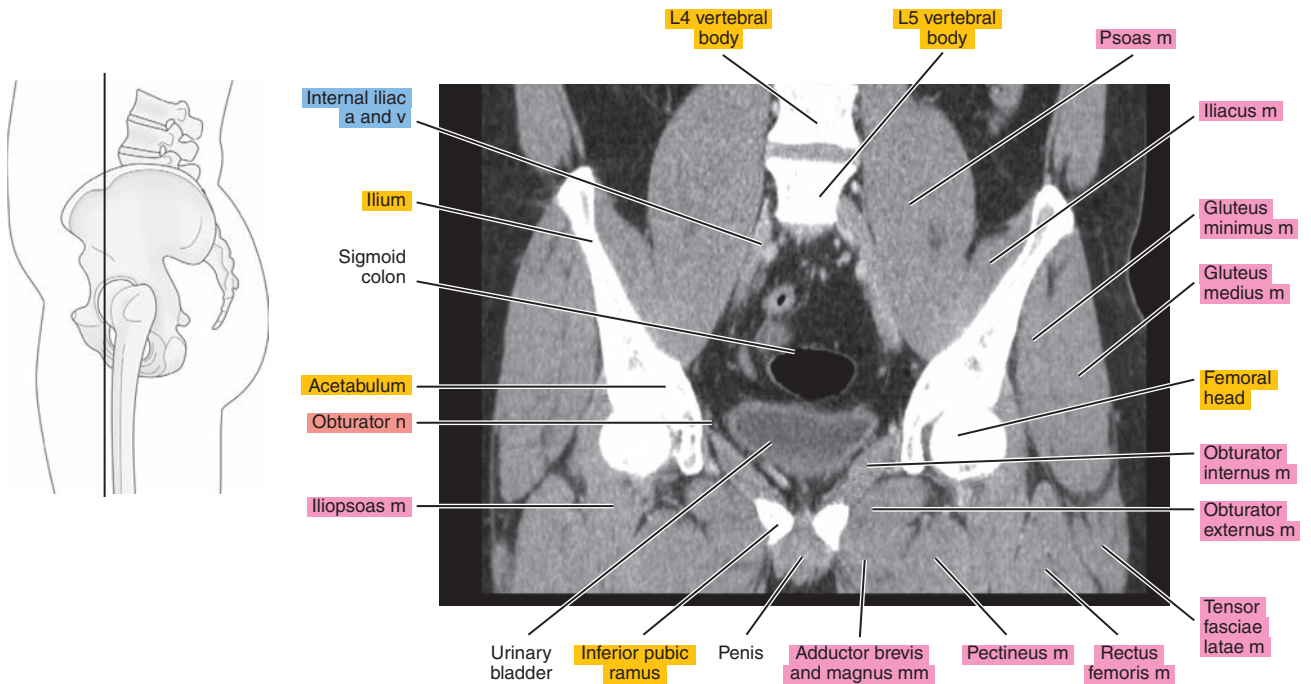




Figure 25.3.7

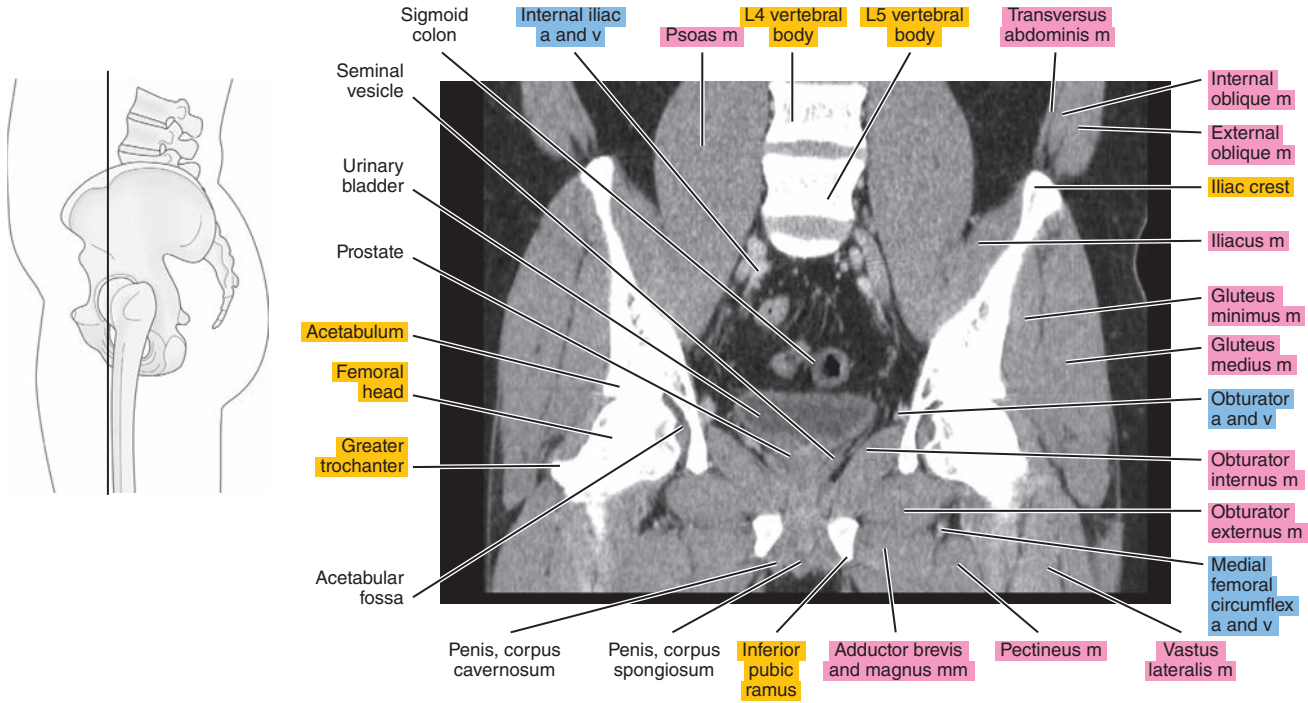


Figure 25.3.8

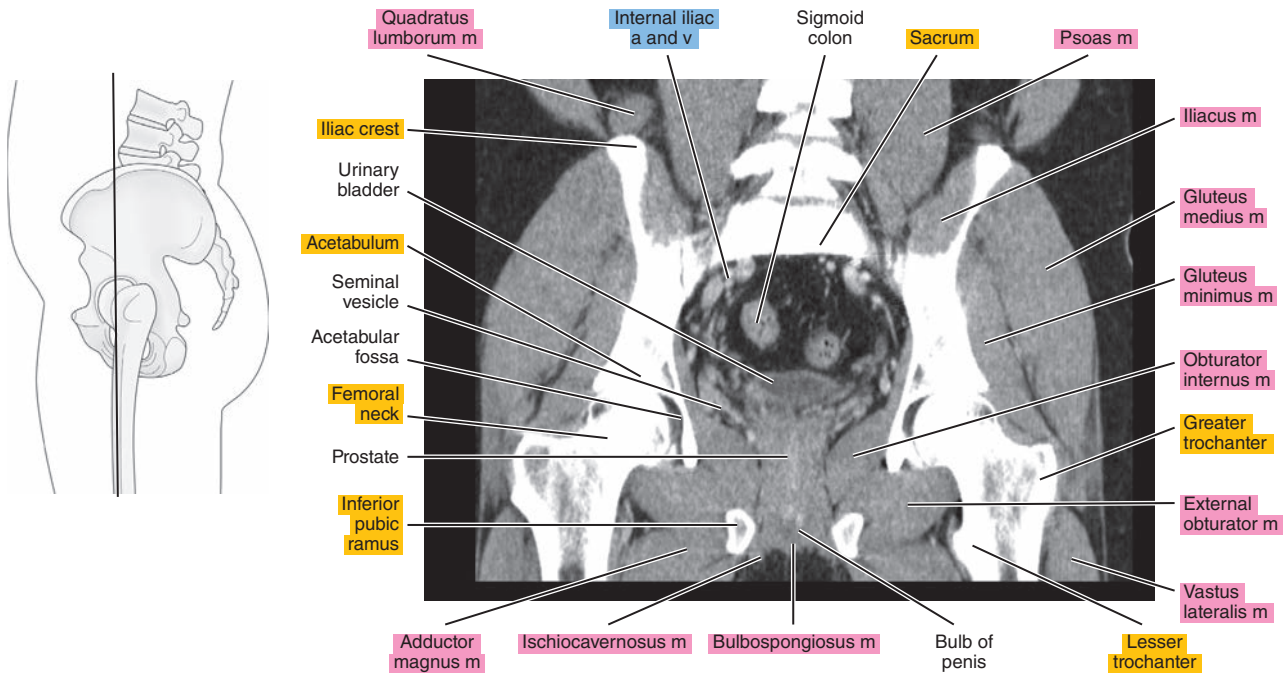


Figure 25.3.9

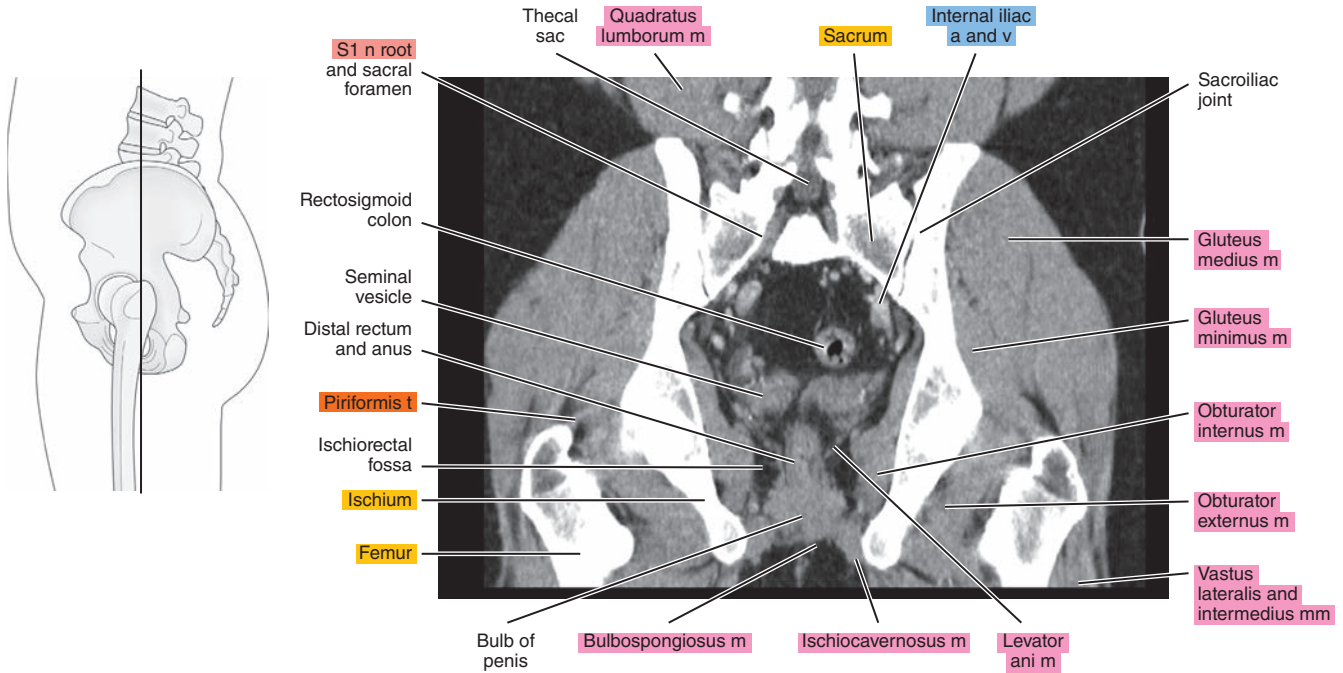


Figure 25.3.10

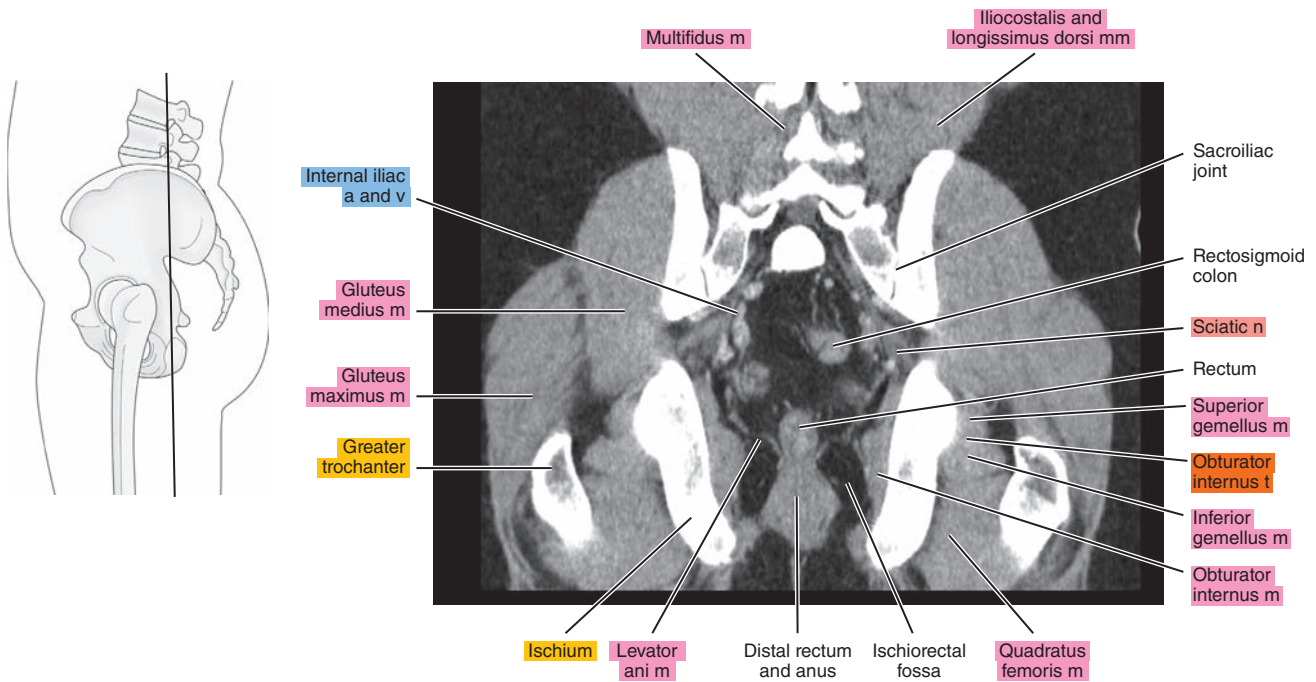
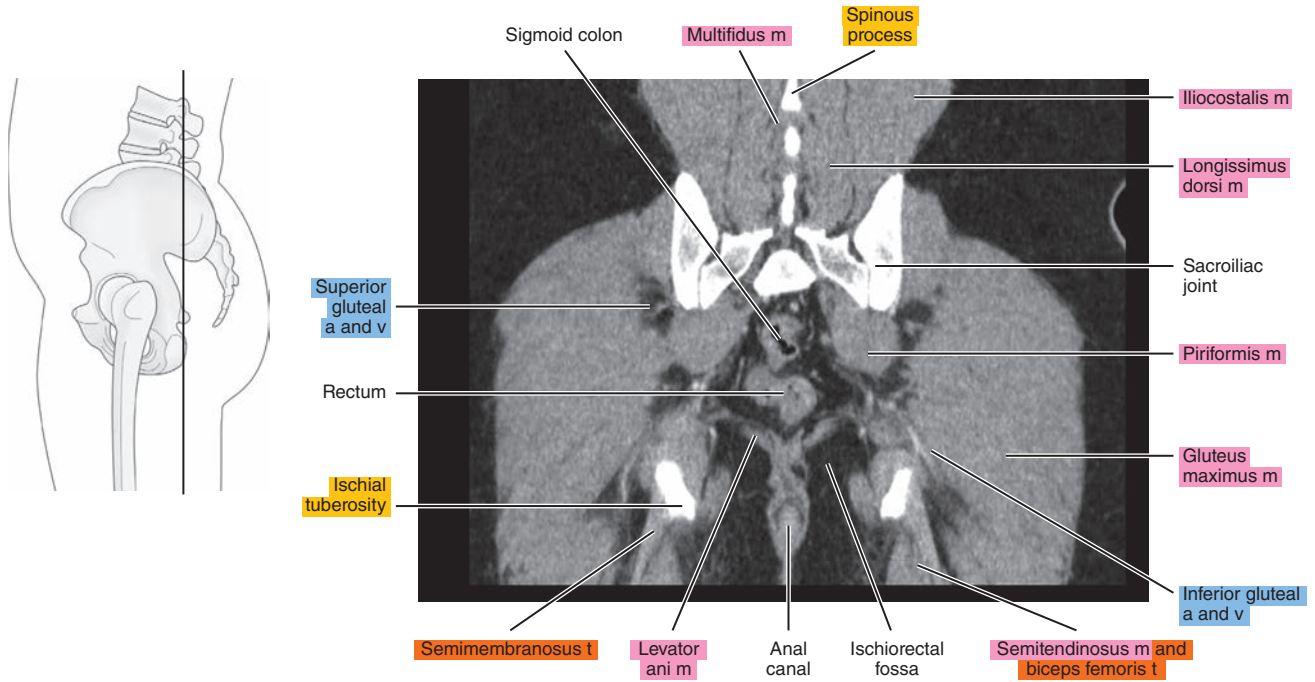


Figure 25.3.11



*Chapter*  
**26**

**CT of the Female Pelvis**



# AXIAL

Figure 26.1.1

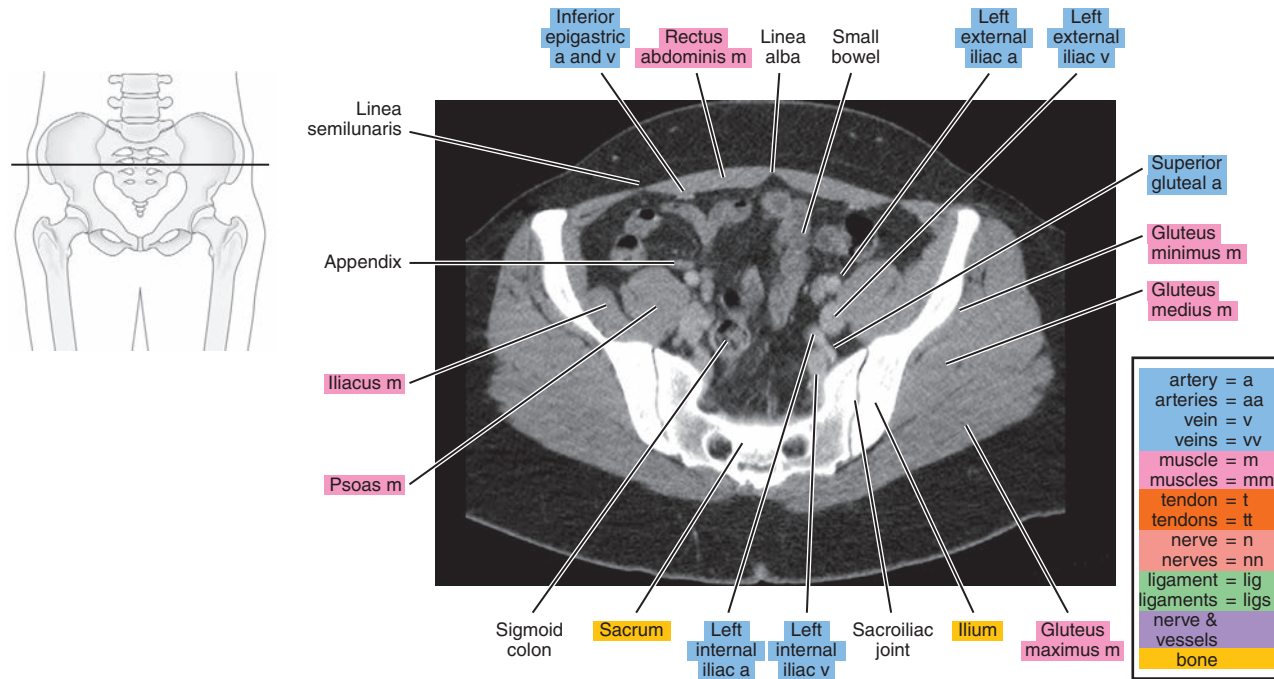


Figure 26.1.2

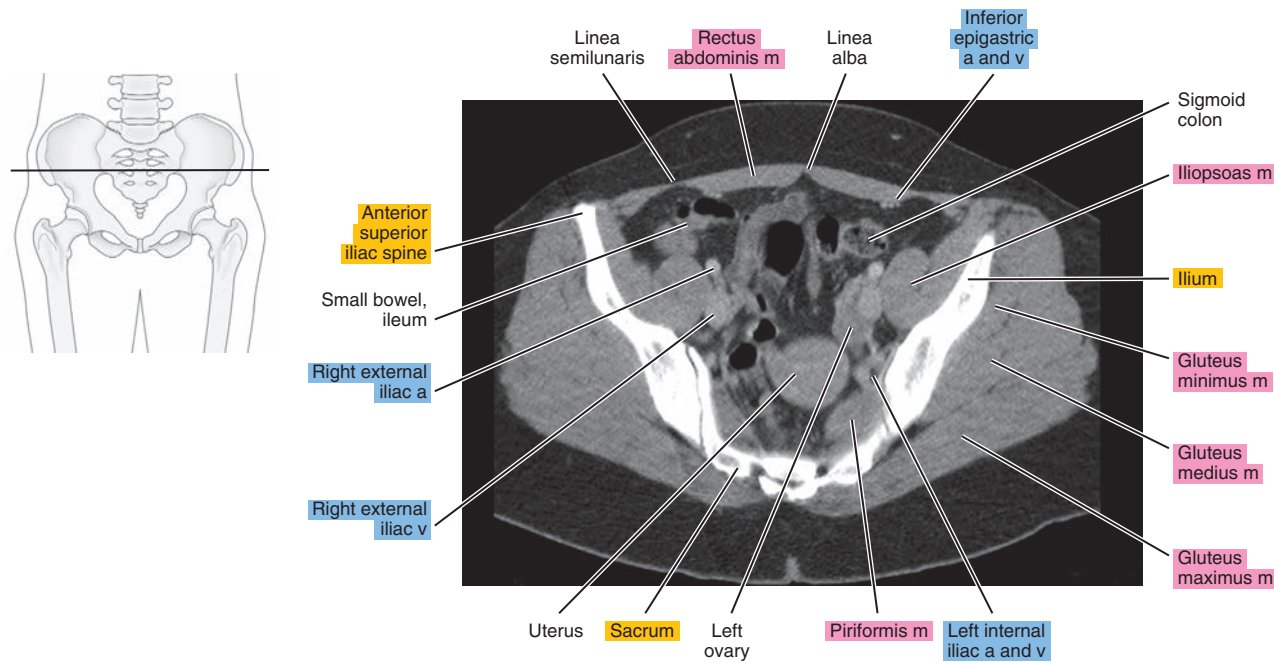


Figure 26.1.3

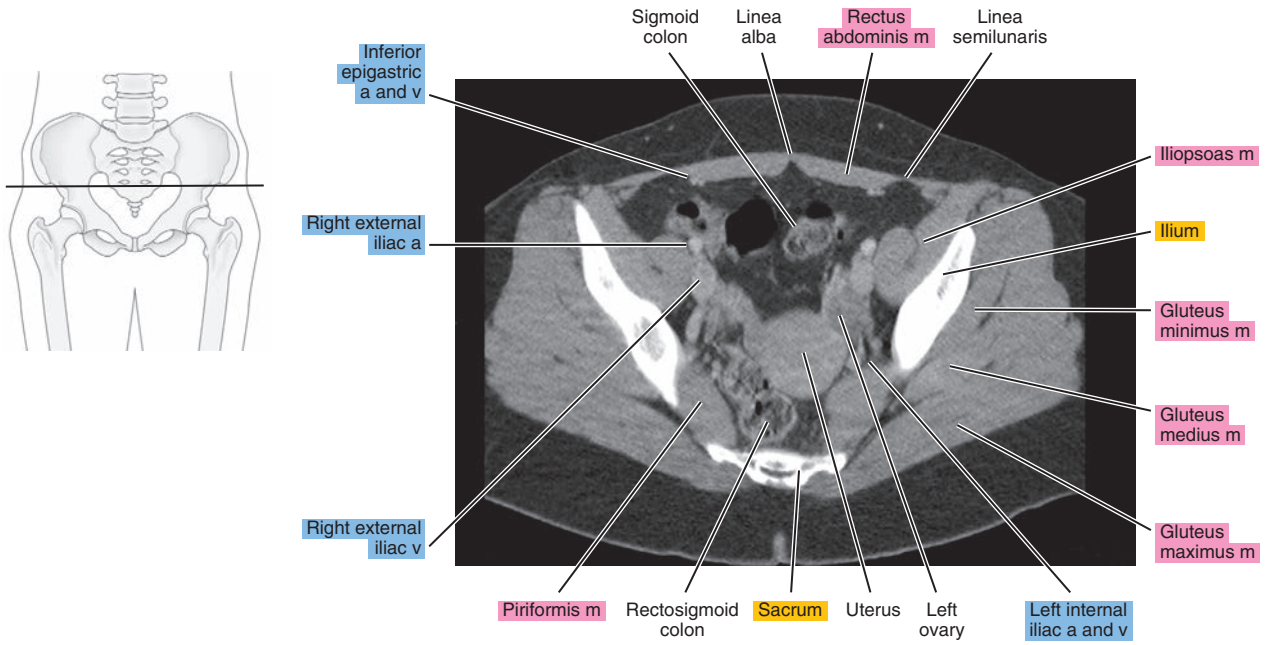


Figure 26.1.4

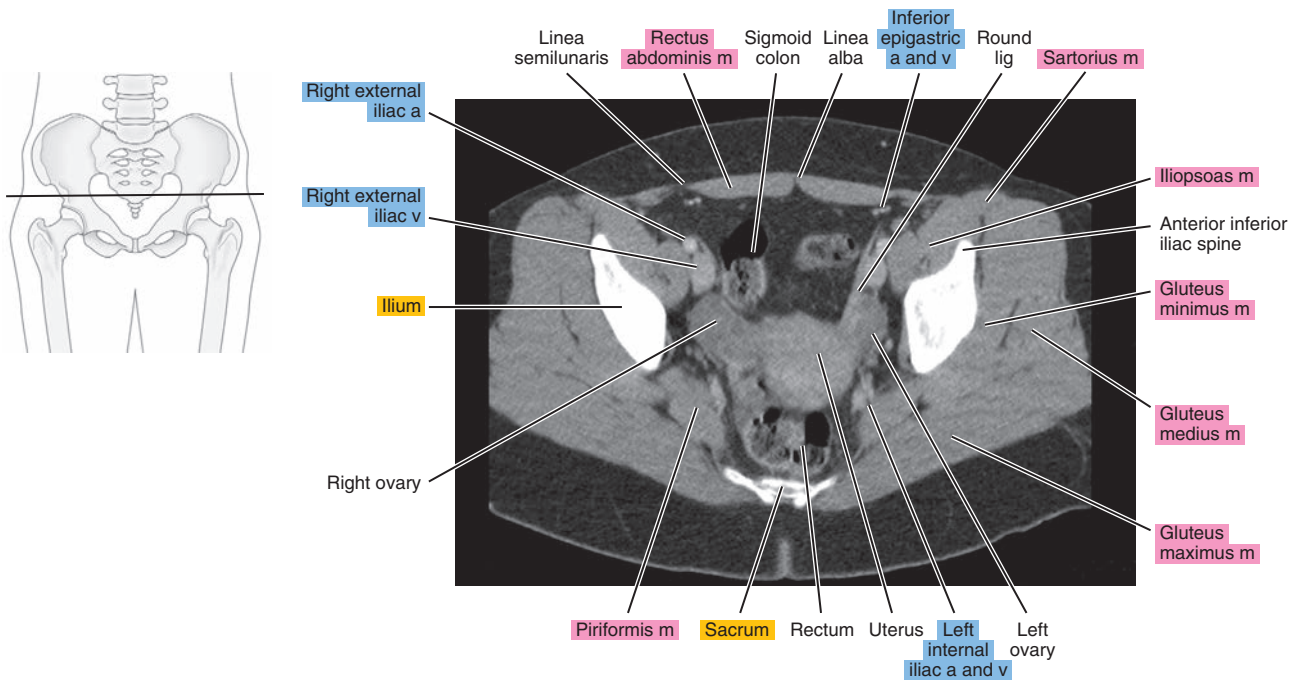


Figure 26.1.5

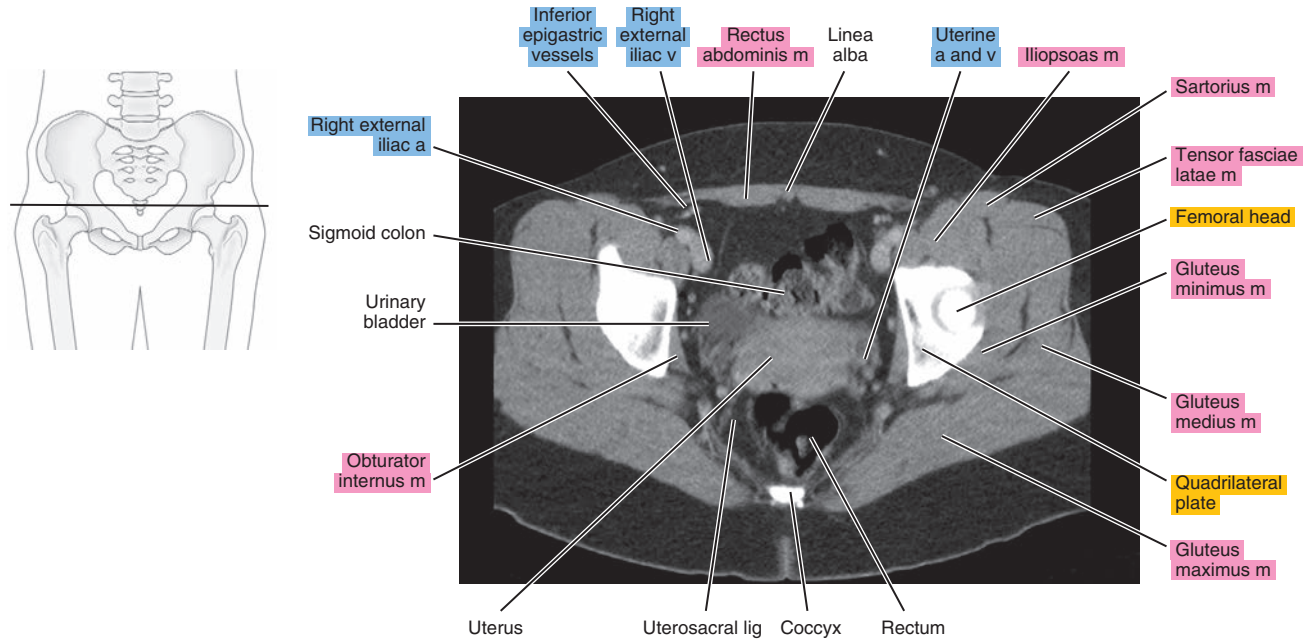


Figure 26.1.6

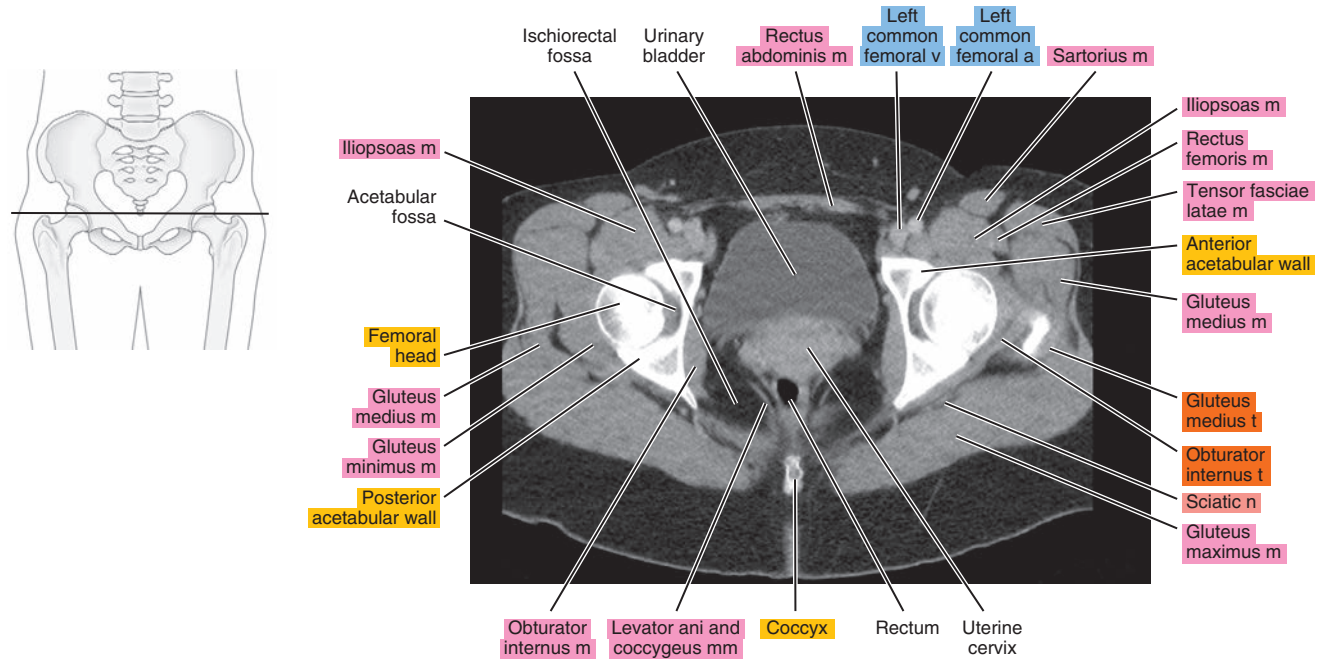




Figure 26.1.7

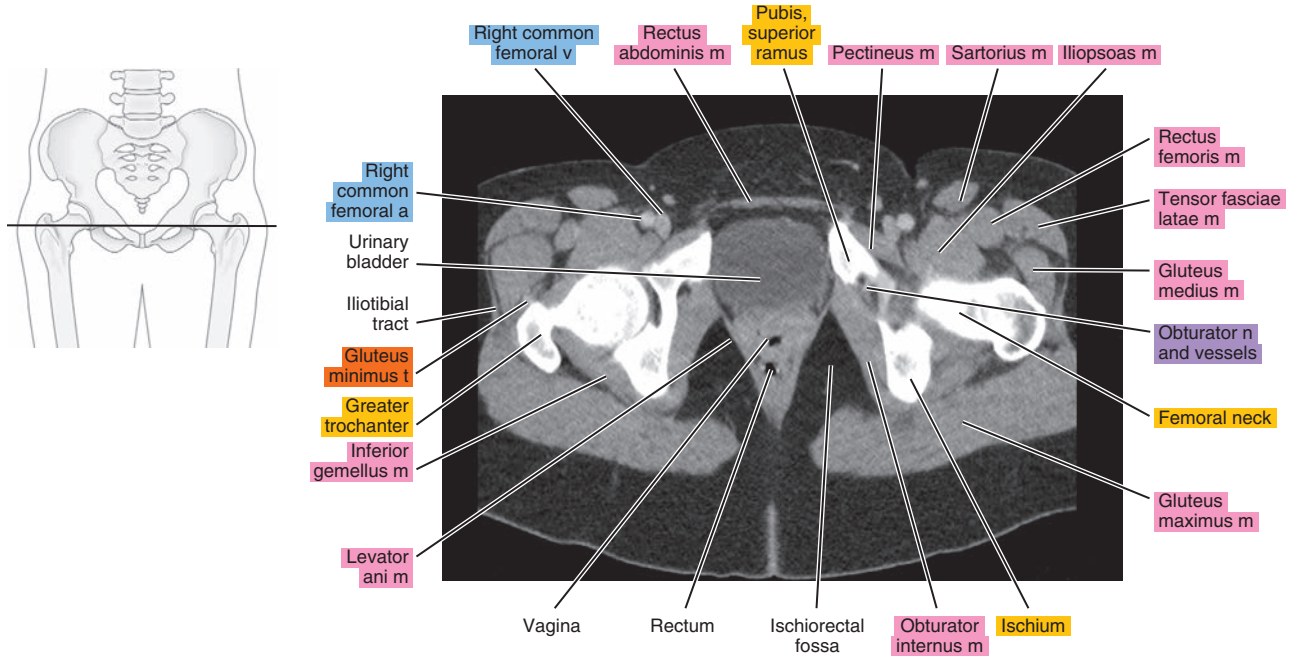


Figure 26.1.8

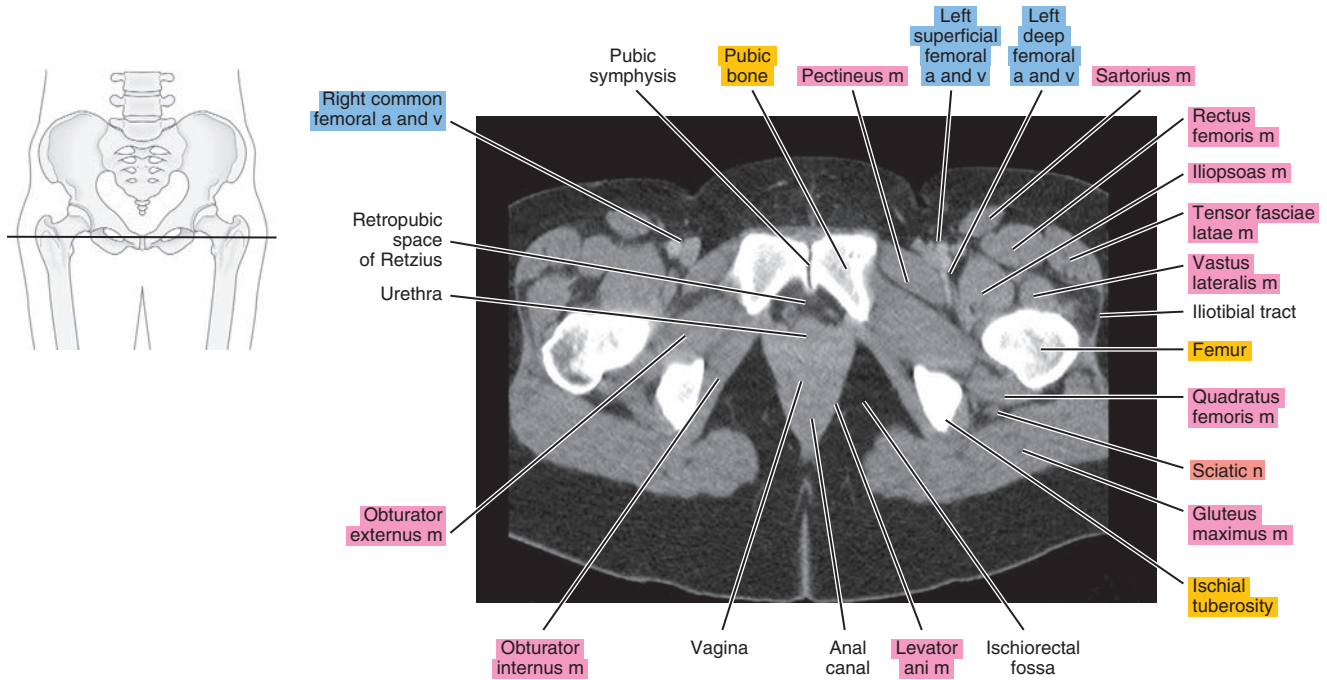
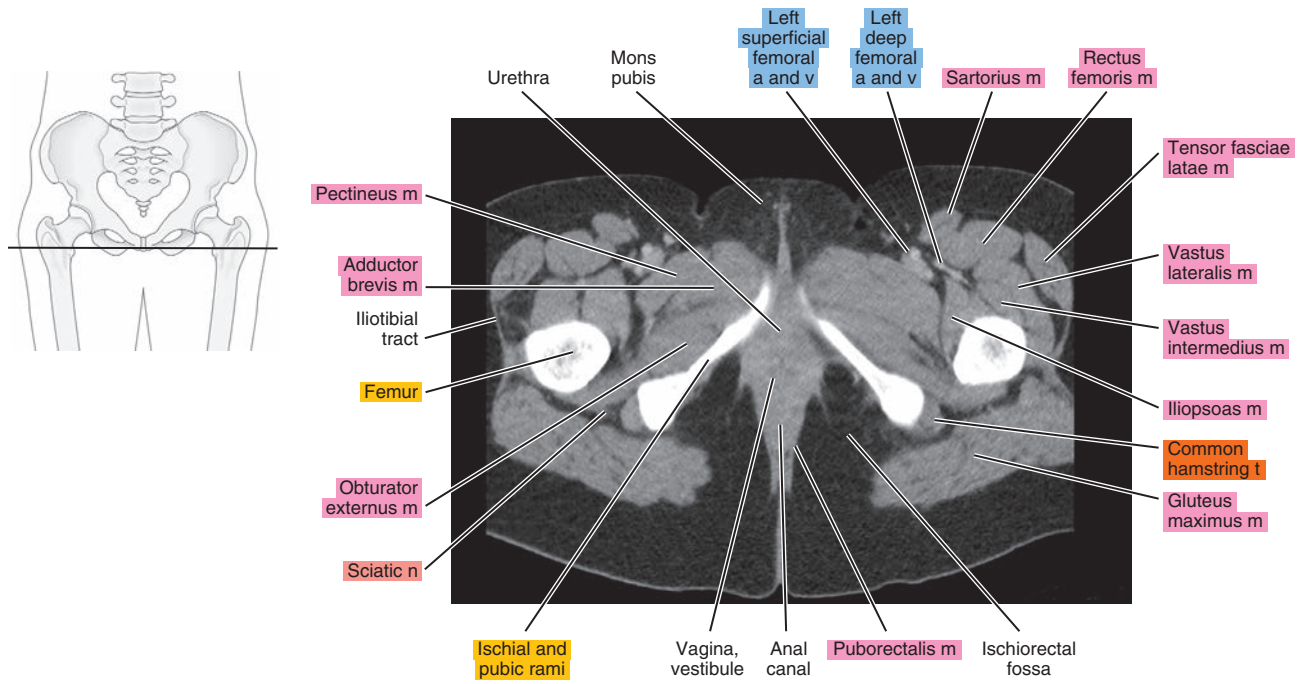




Figure 26.1.9



# SAGITTAL

Figure 26.2.1

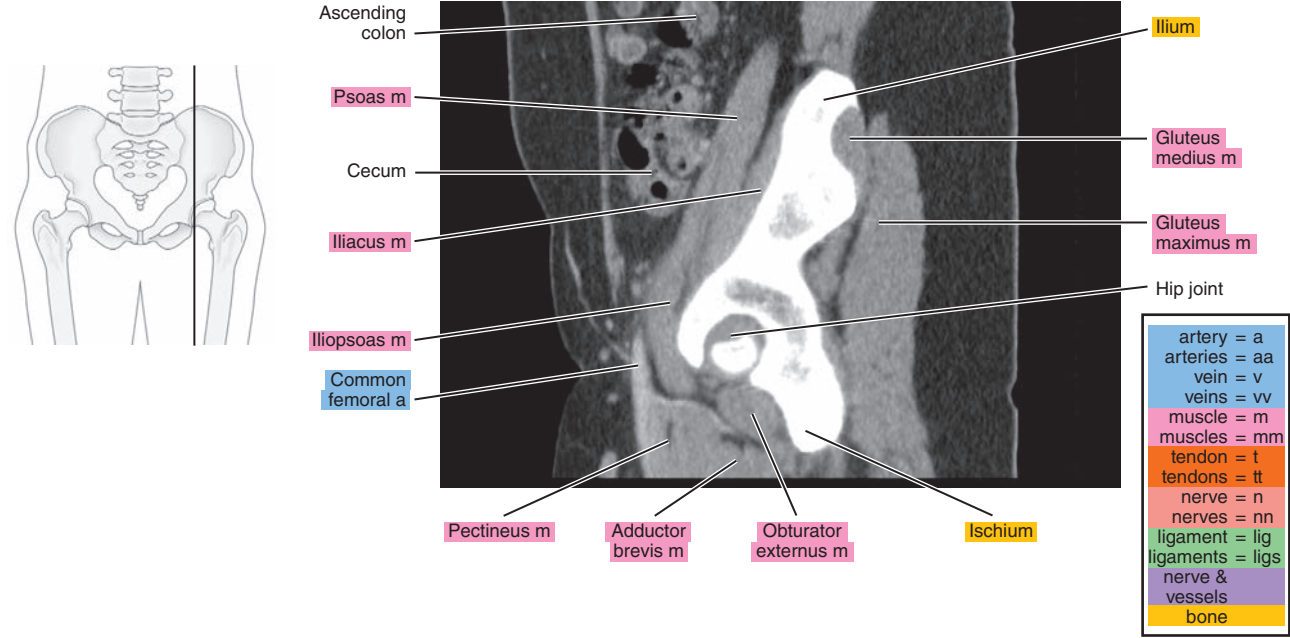


Figure 26.2.2

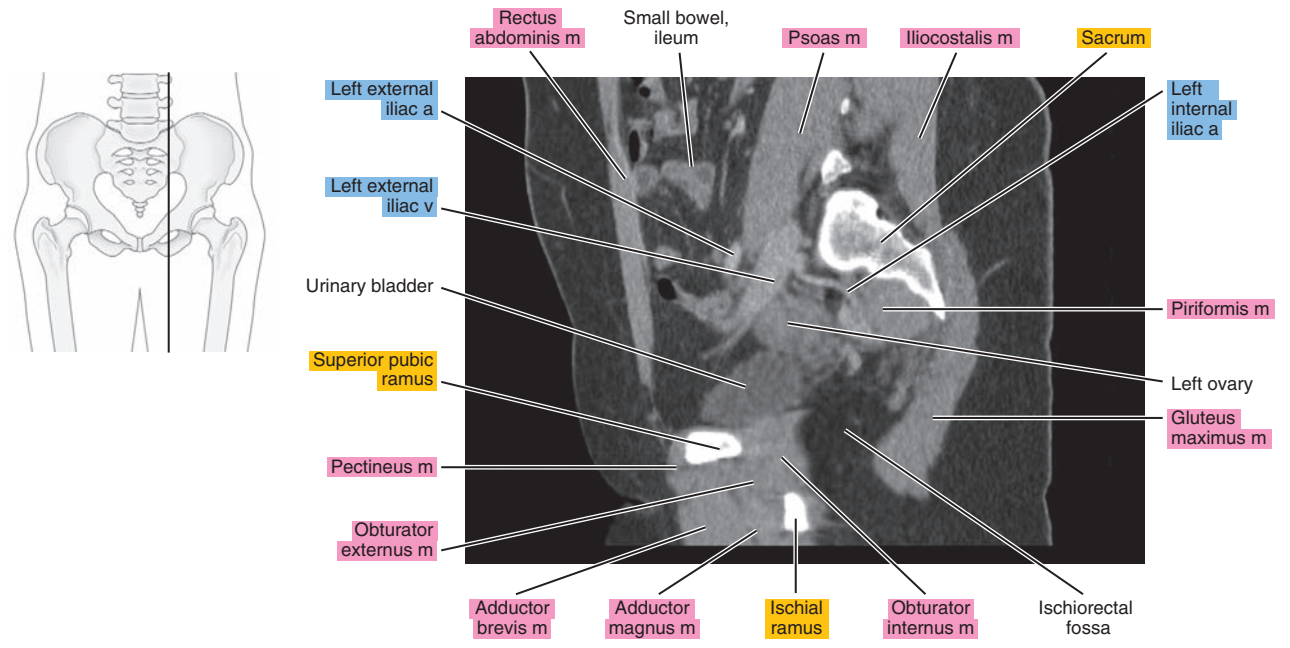


Figure 26.2.3

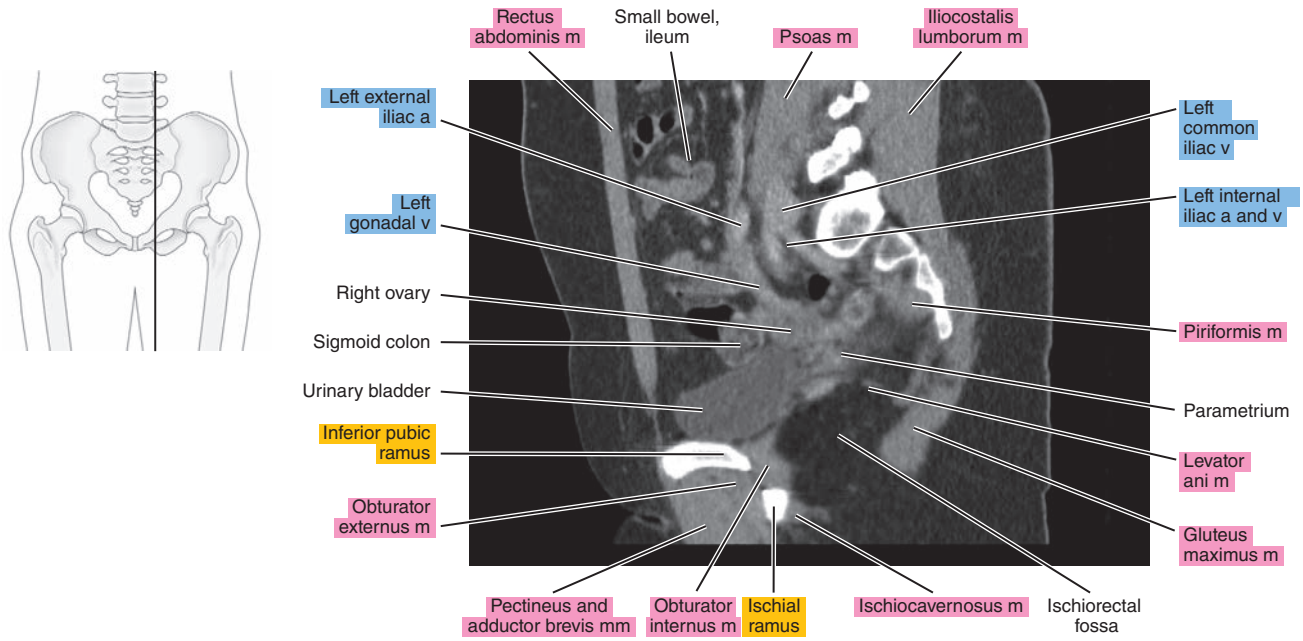


Figure 26.2.4

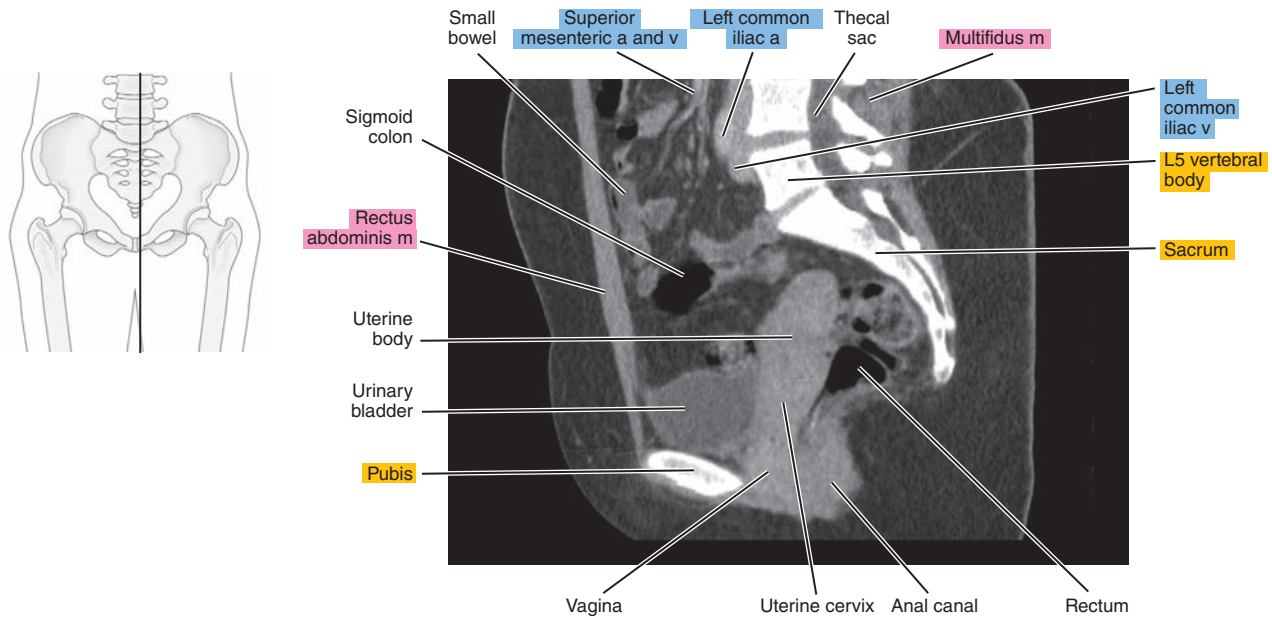
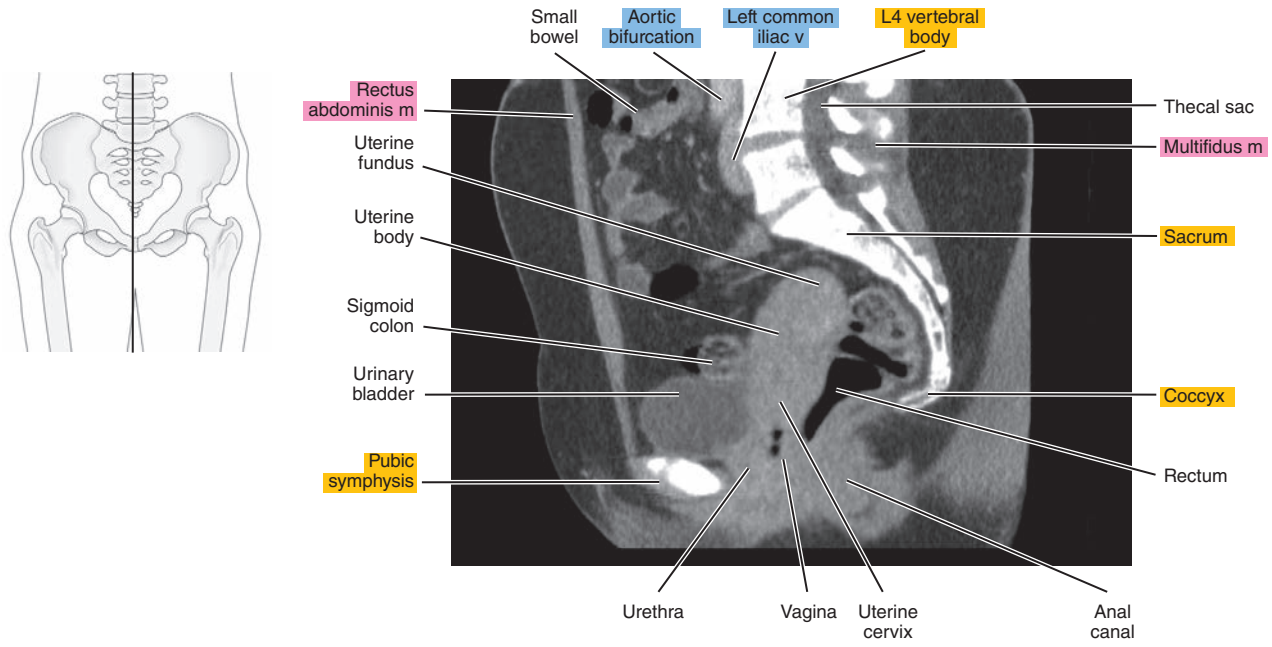


Figure 26.2.5





# CORONAL

Figure 26.3.1

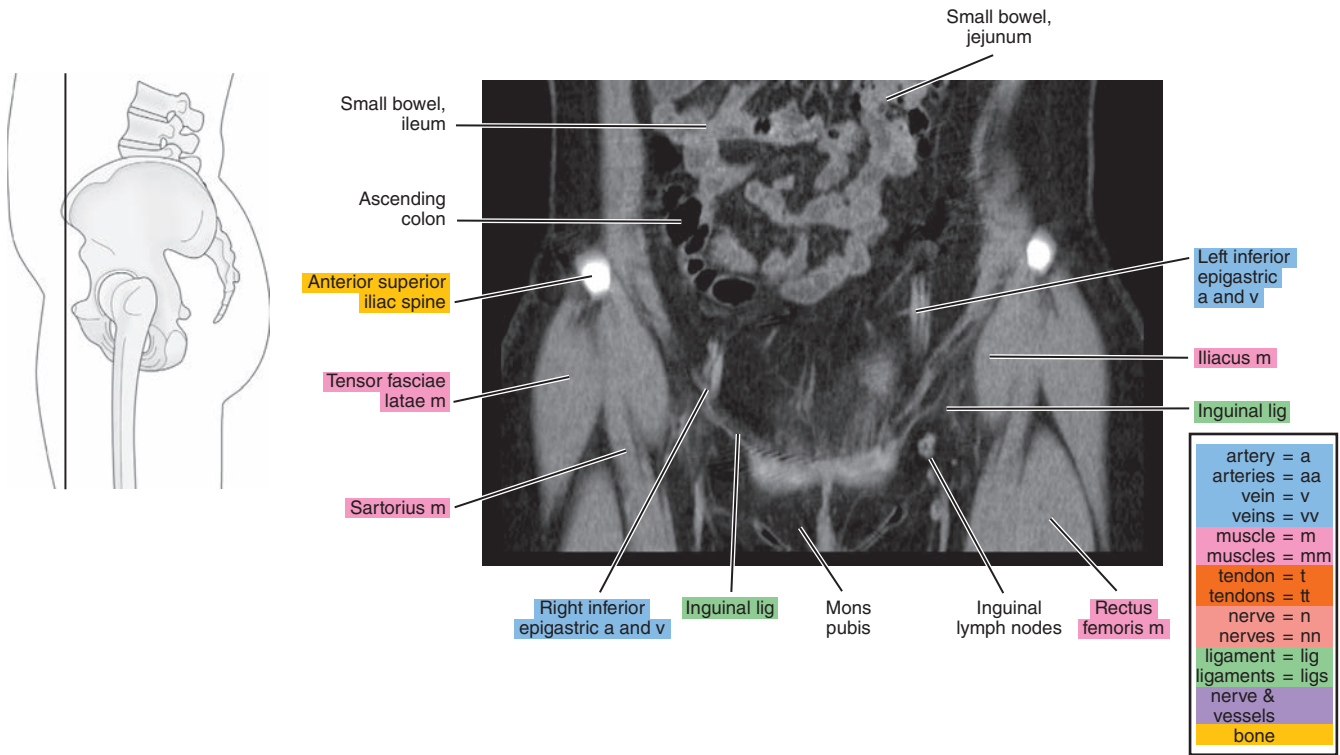


Figure 26.3.2

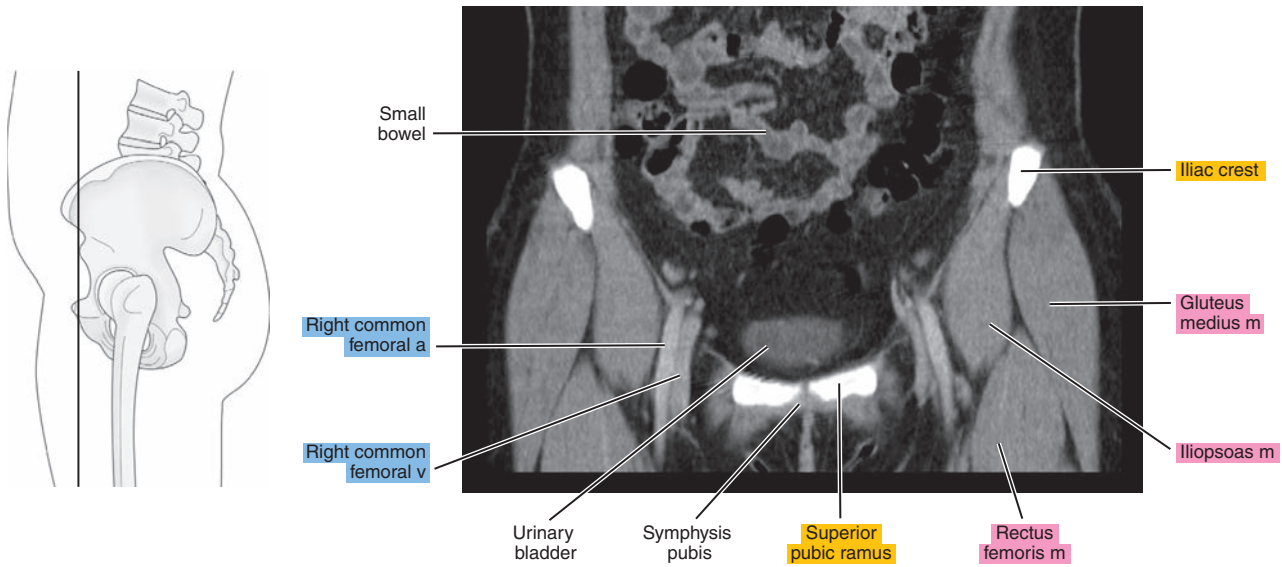


Figure 26.3.3

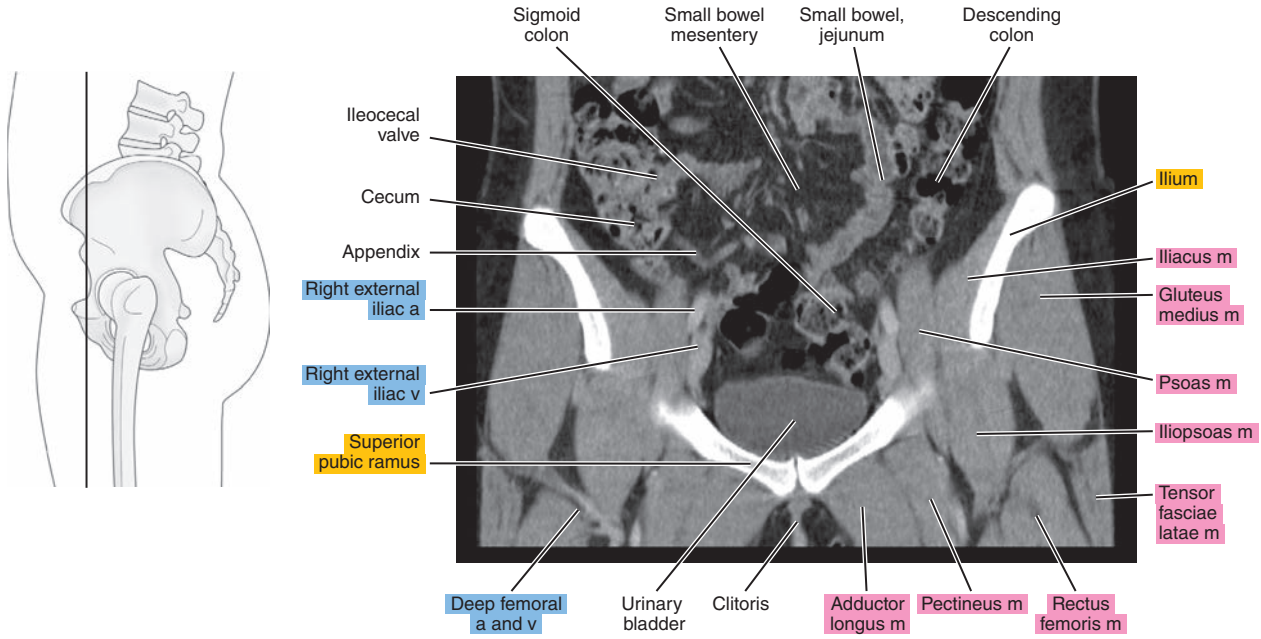


Figure 26.3.4

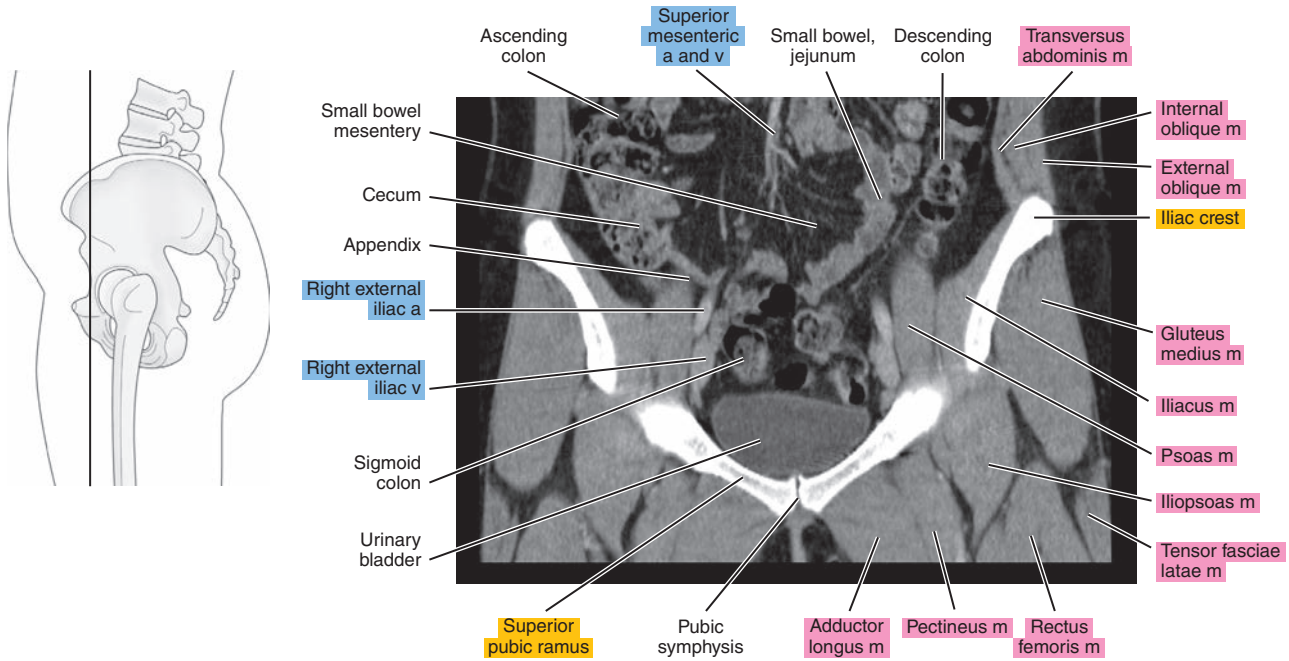


Figure 26.3.5

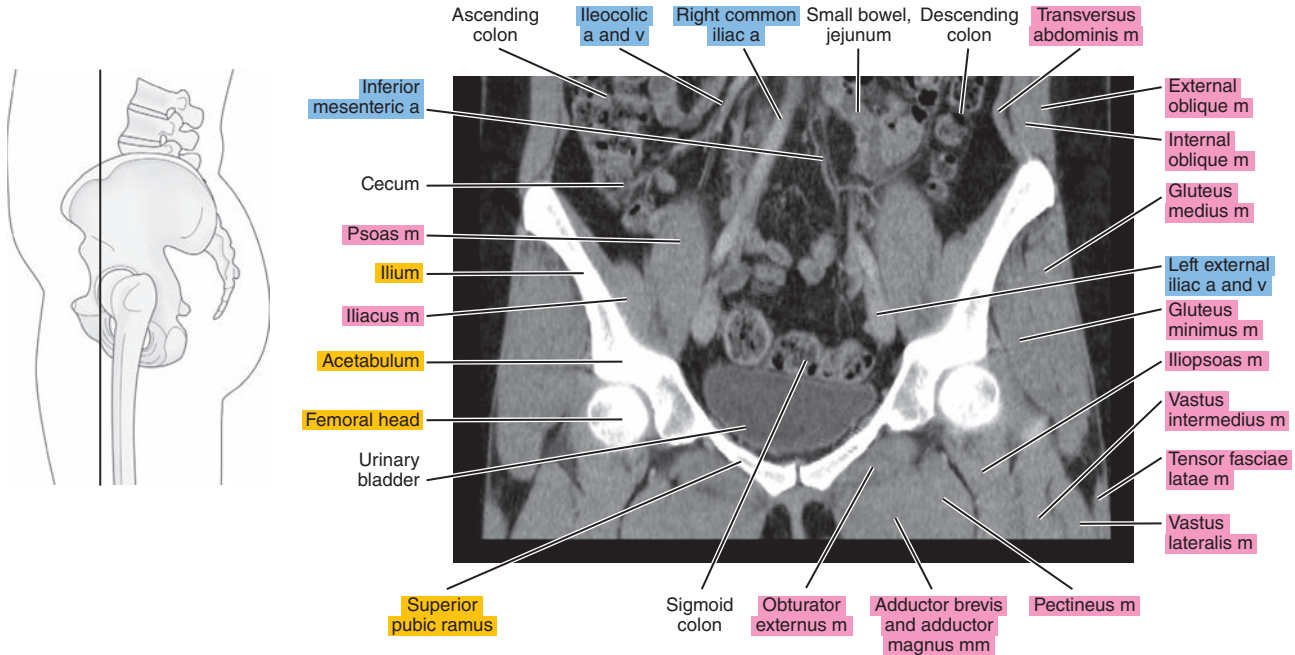


Figure 26.3.6

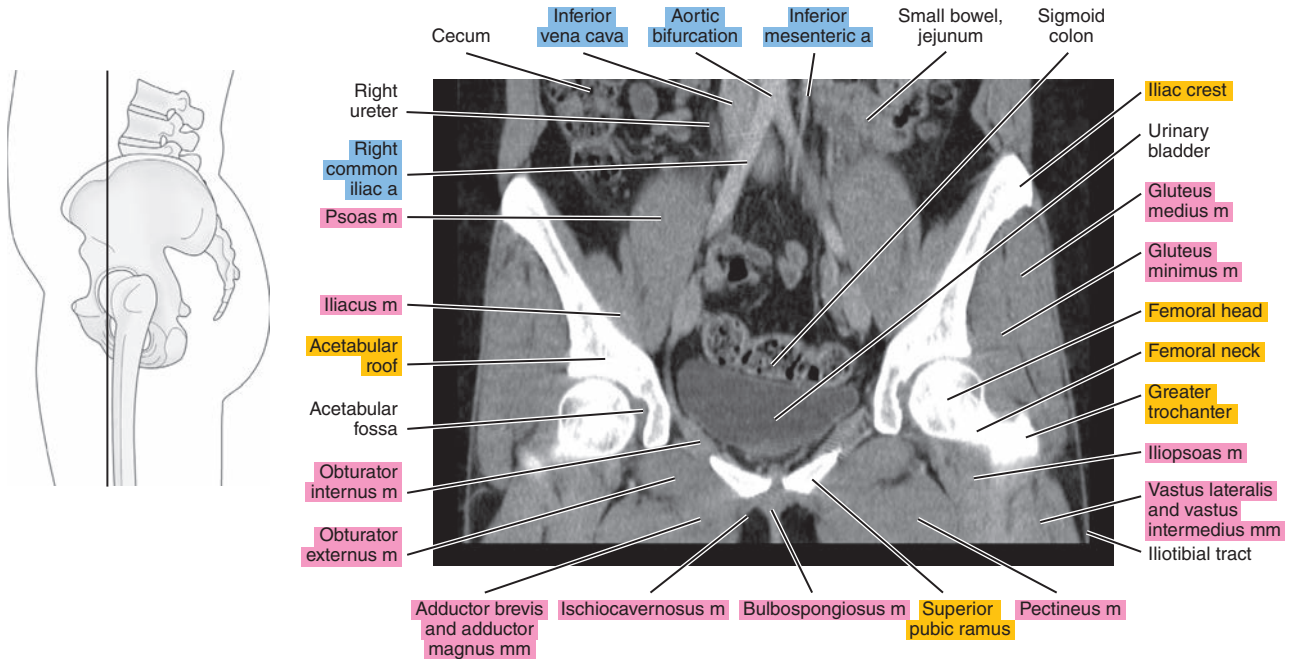




Figure 26.3.7

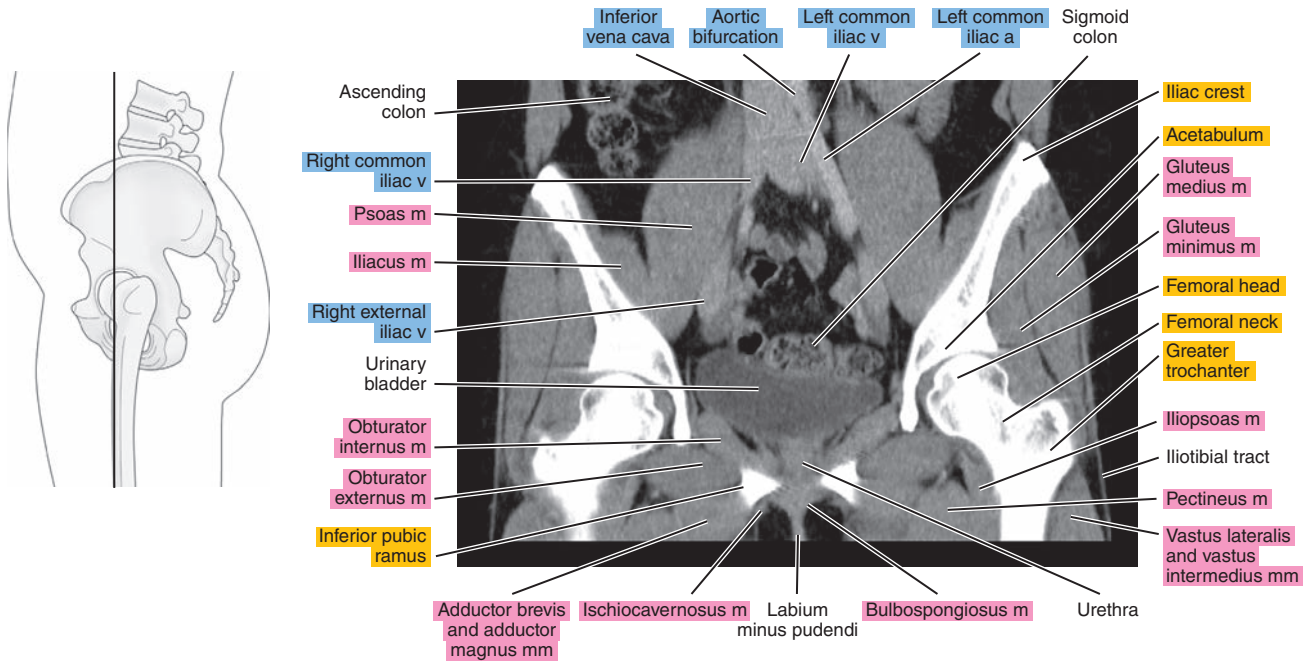


Figure 26.3.8

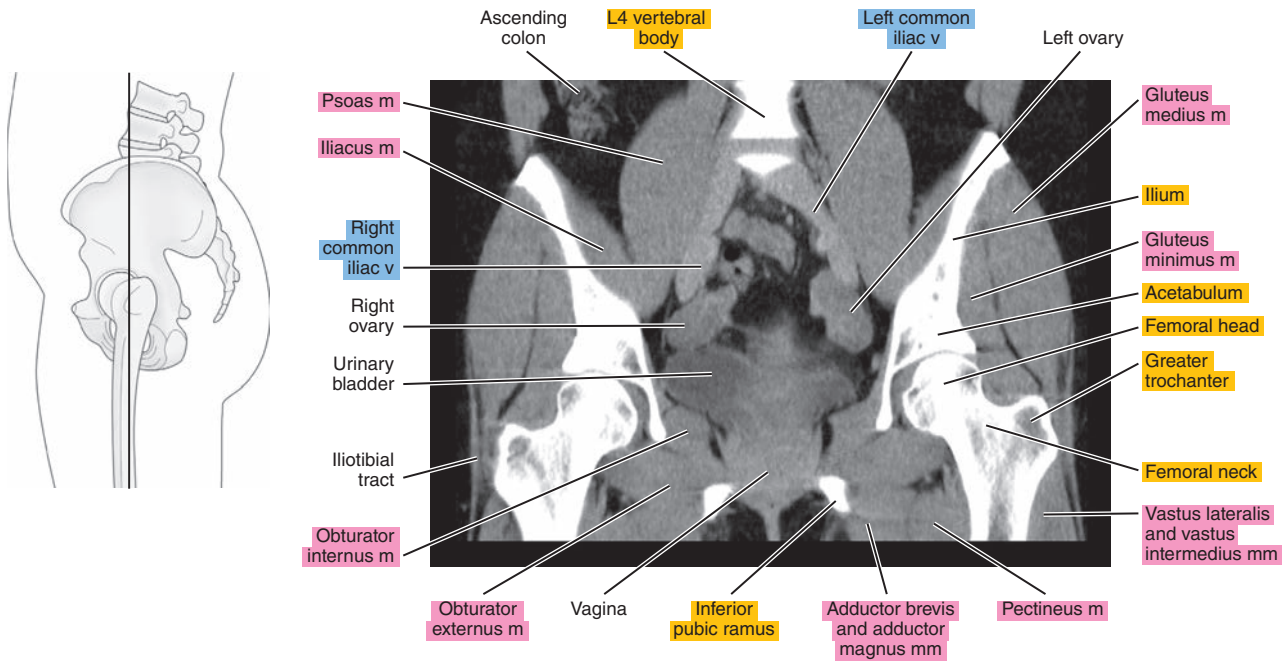




Figure 26.3.9

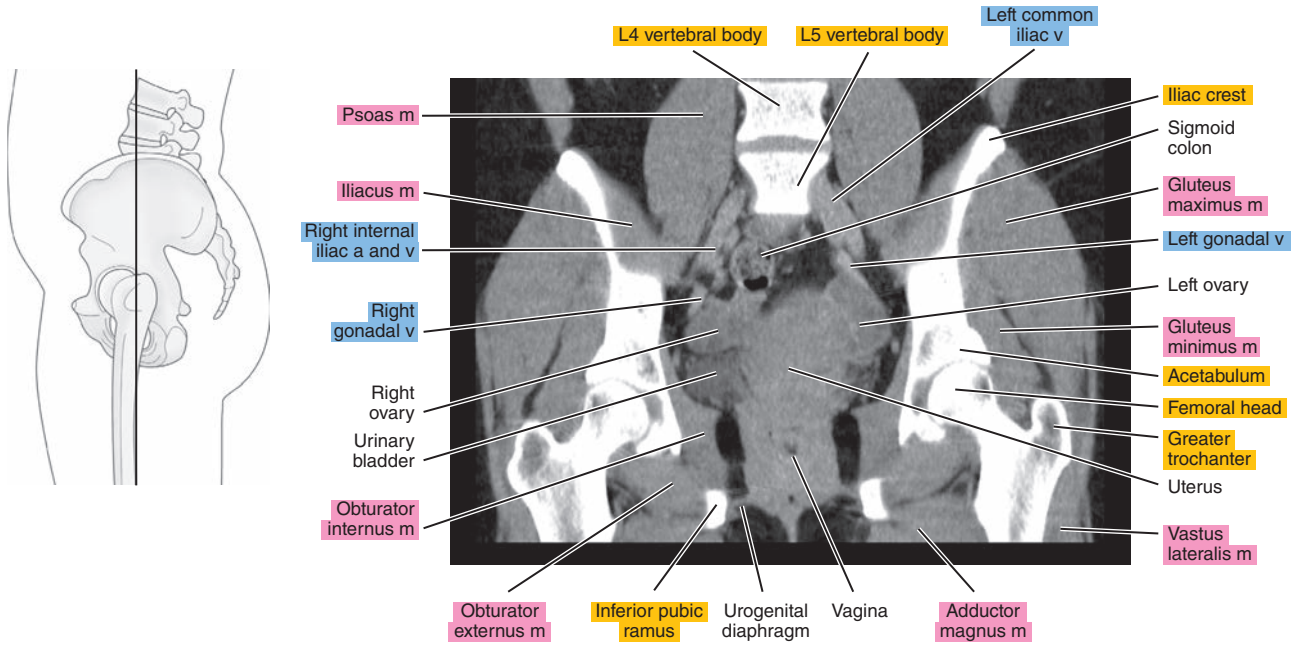


Figure 26.3.10

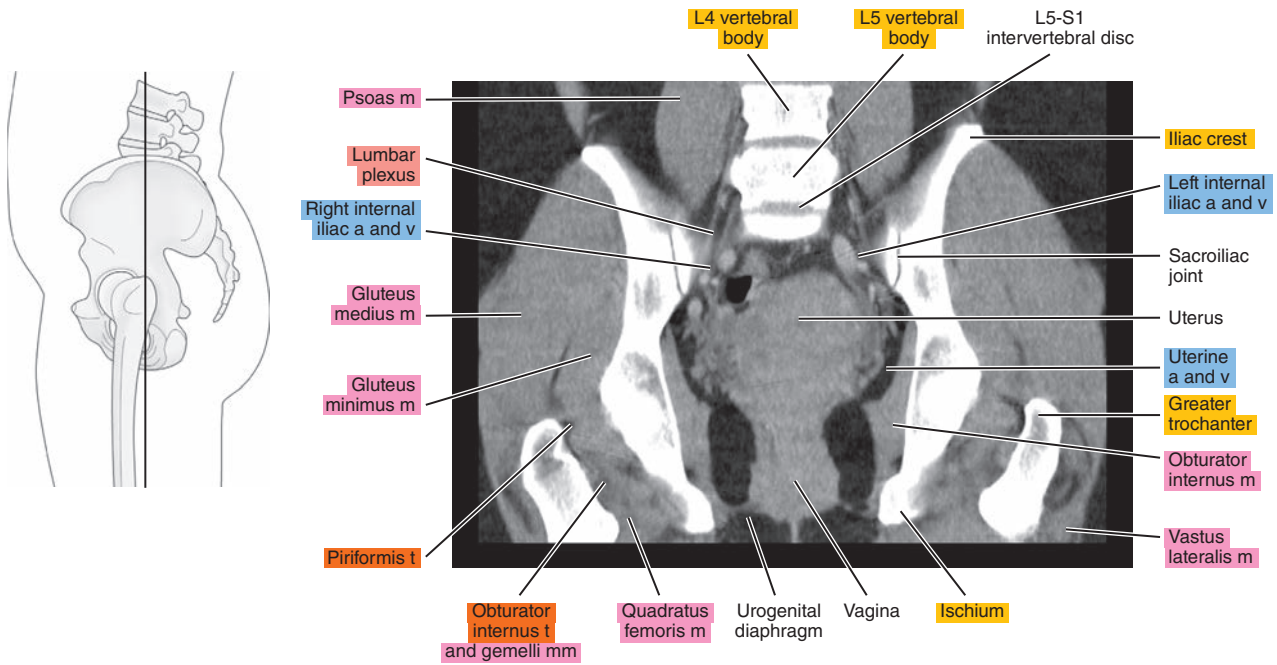


Figure 26.3.11

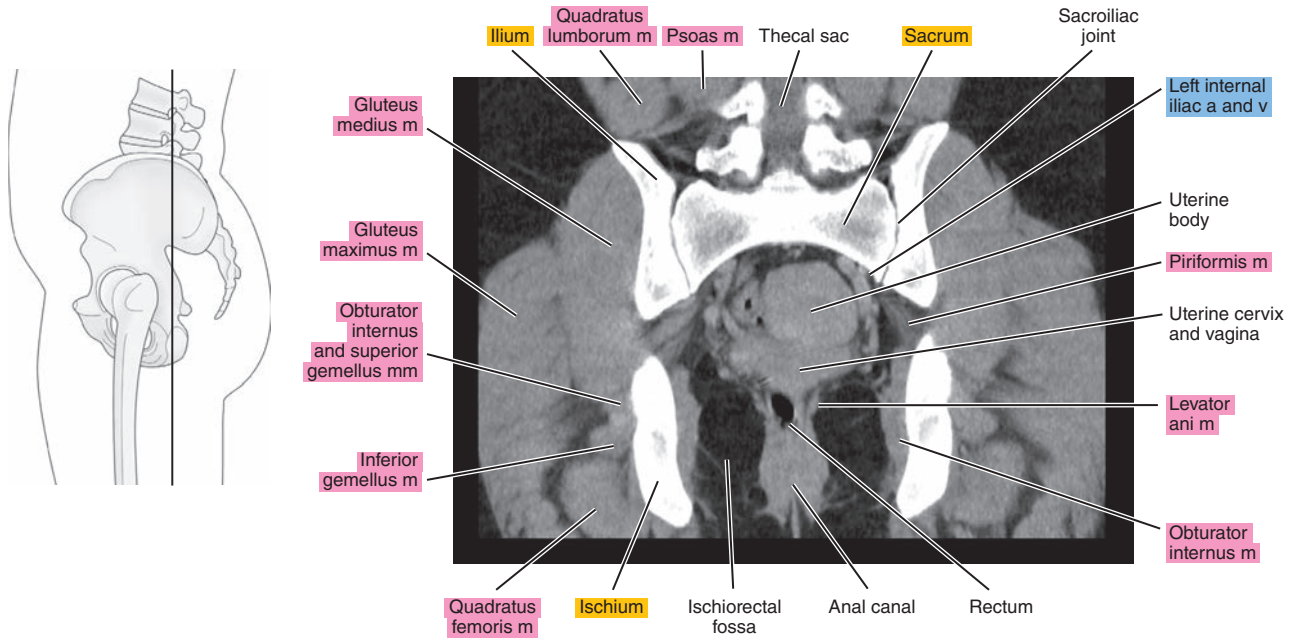
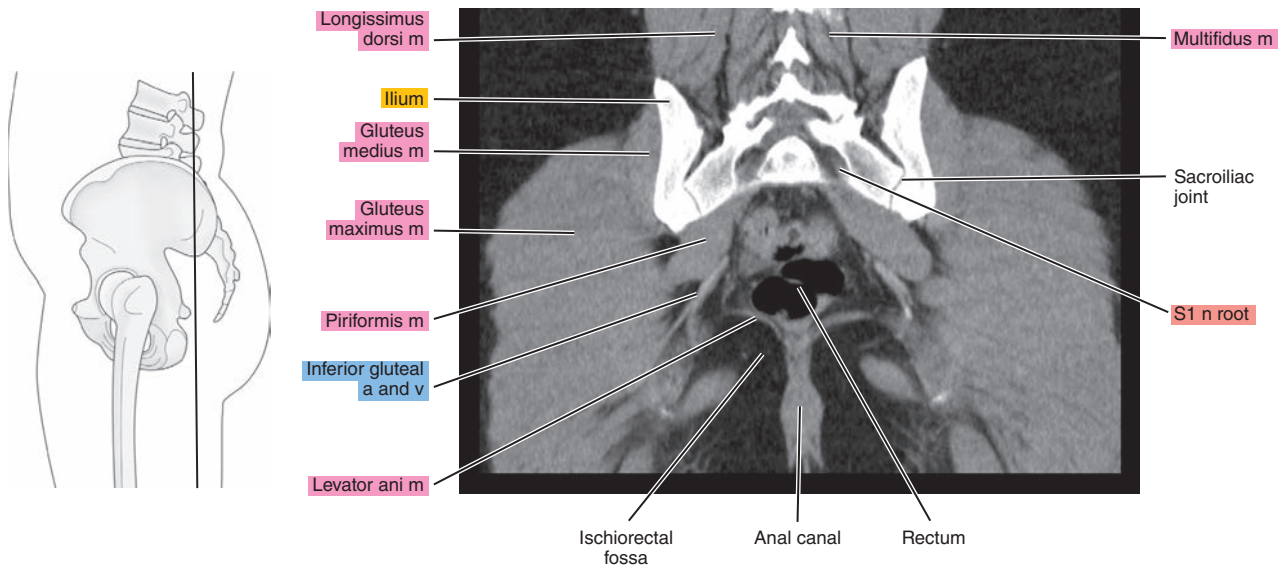


Figure 26.3.12



*Chapter*  
**27**

**MRI of the Male Pelvis**

# AXIAL

Figure 27.1.1

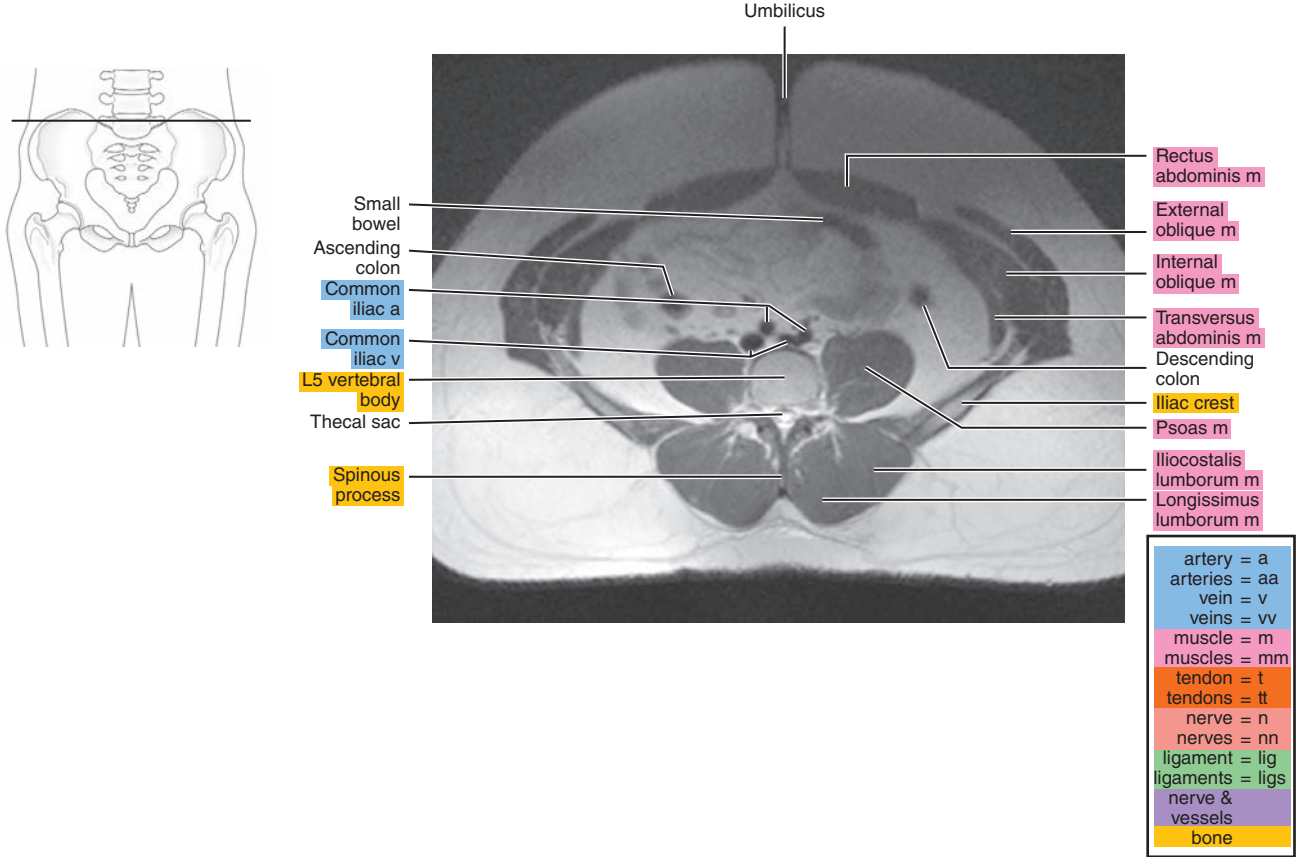


Figure 27.1.2

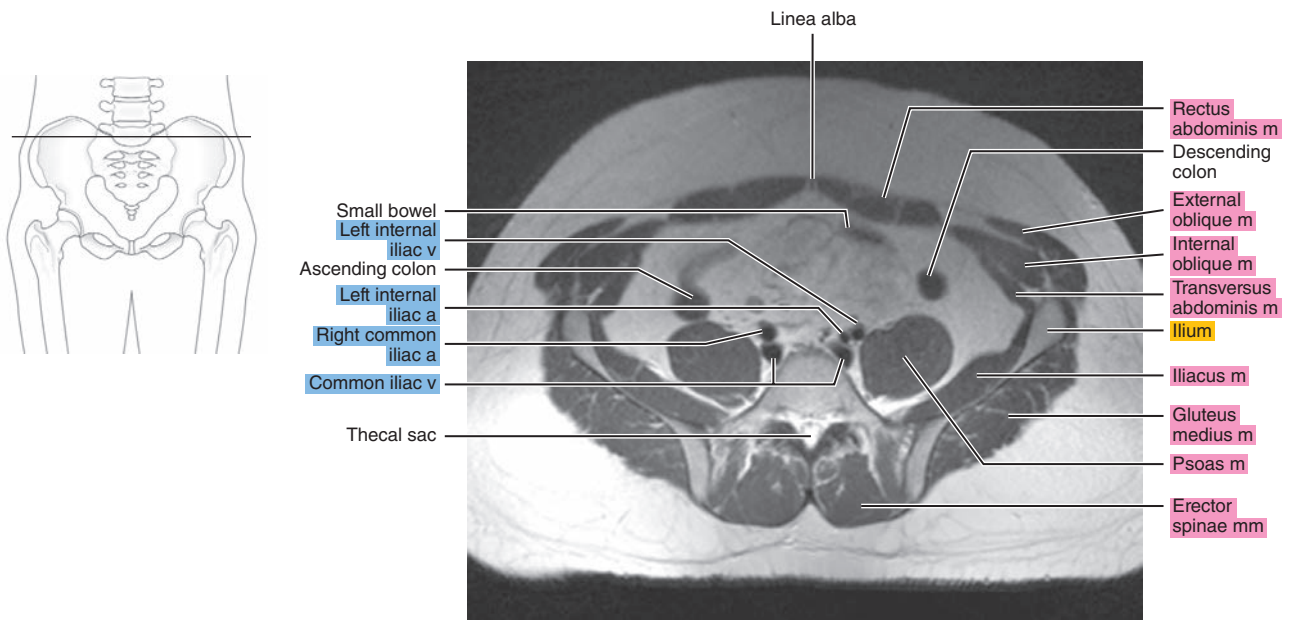




Figure 27.1.3

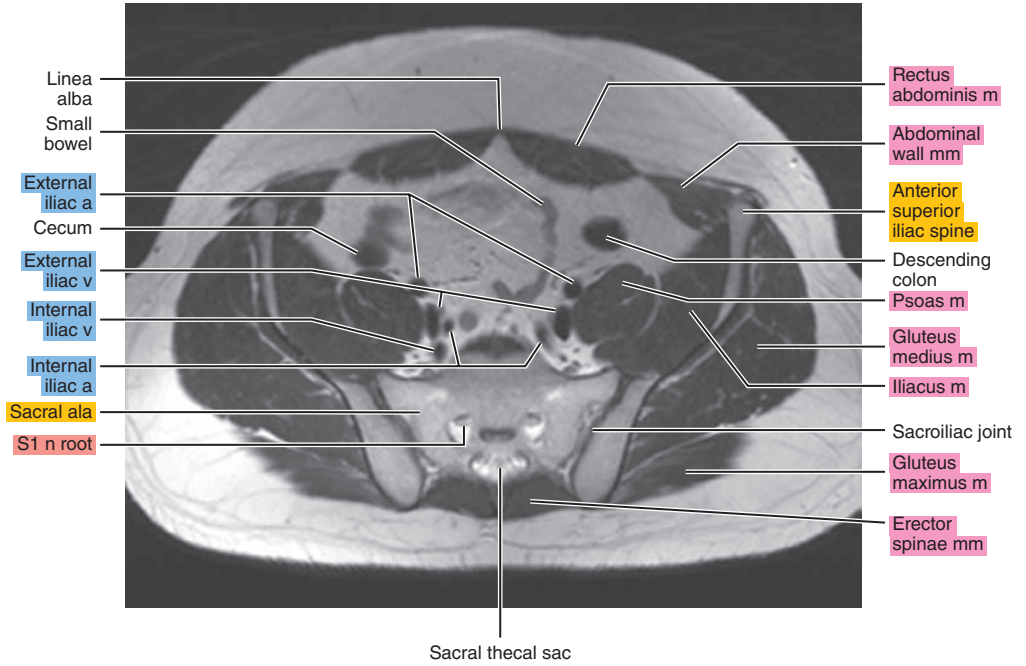
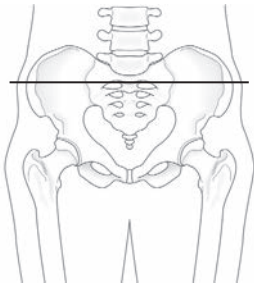


Figure 27.1.4

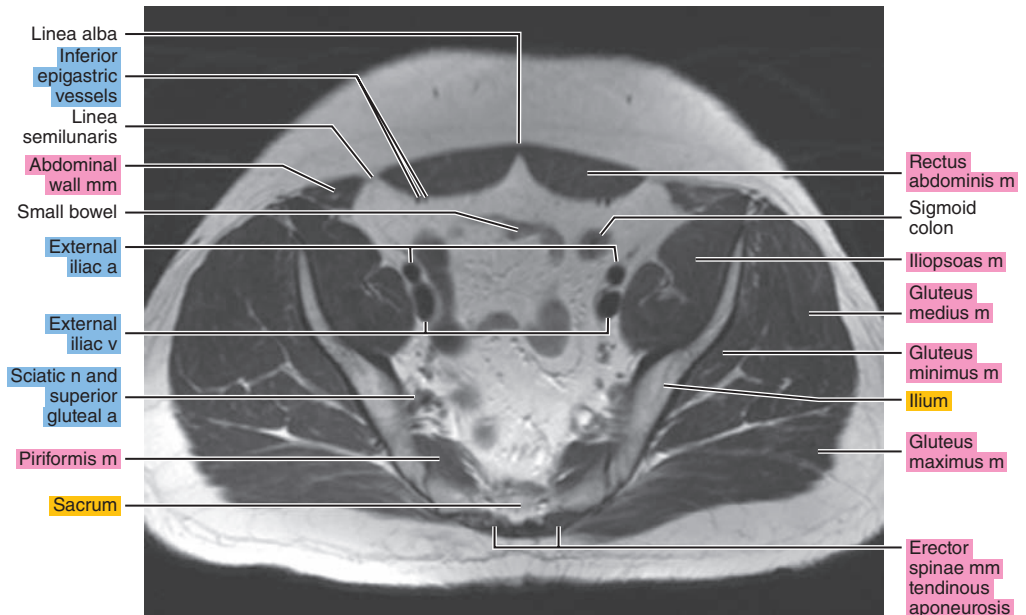
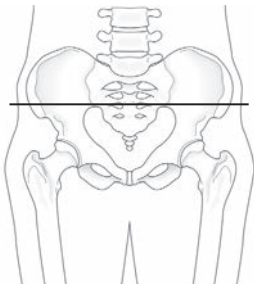


Figure 27.1.5

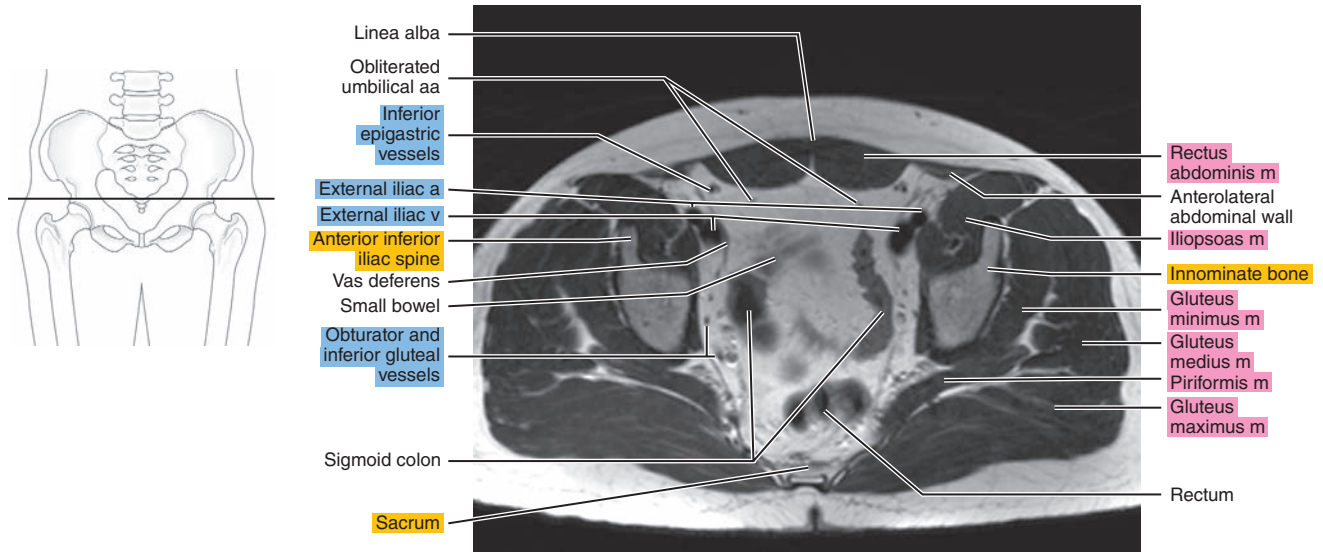


Figure 27.1.6

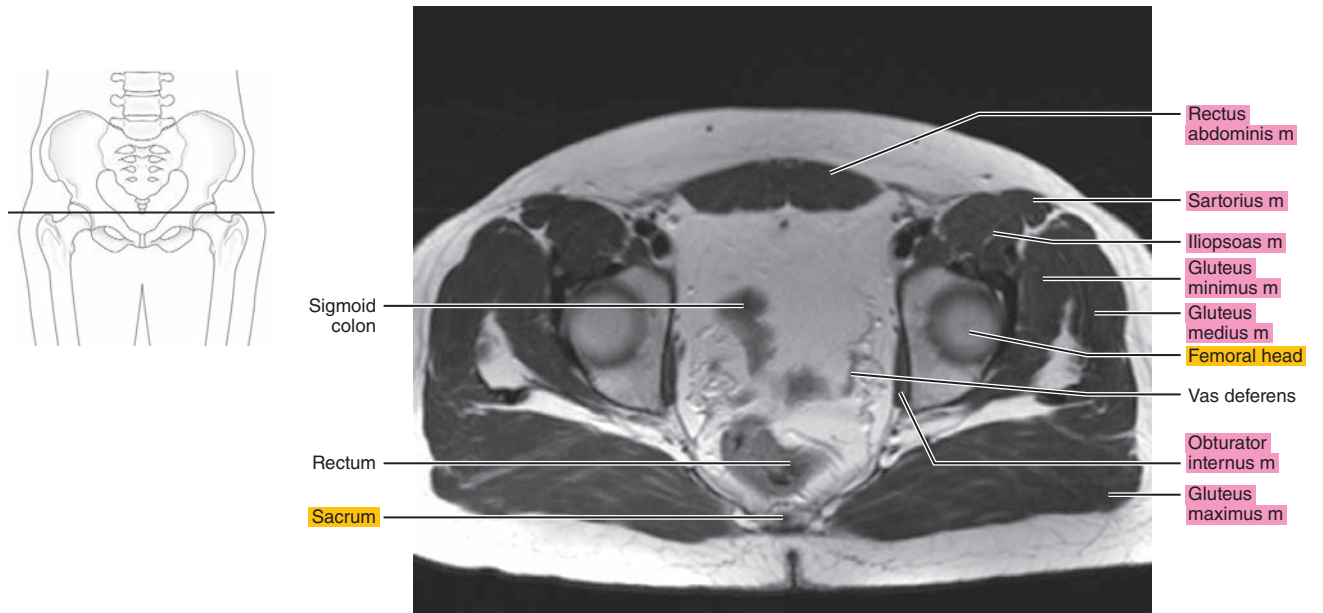


Figure 27.1.7

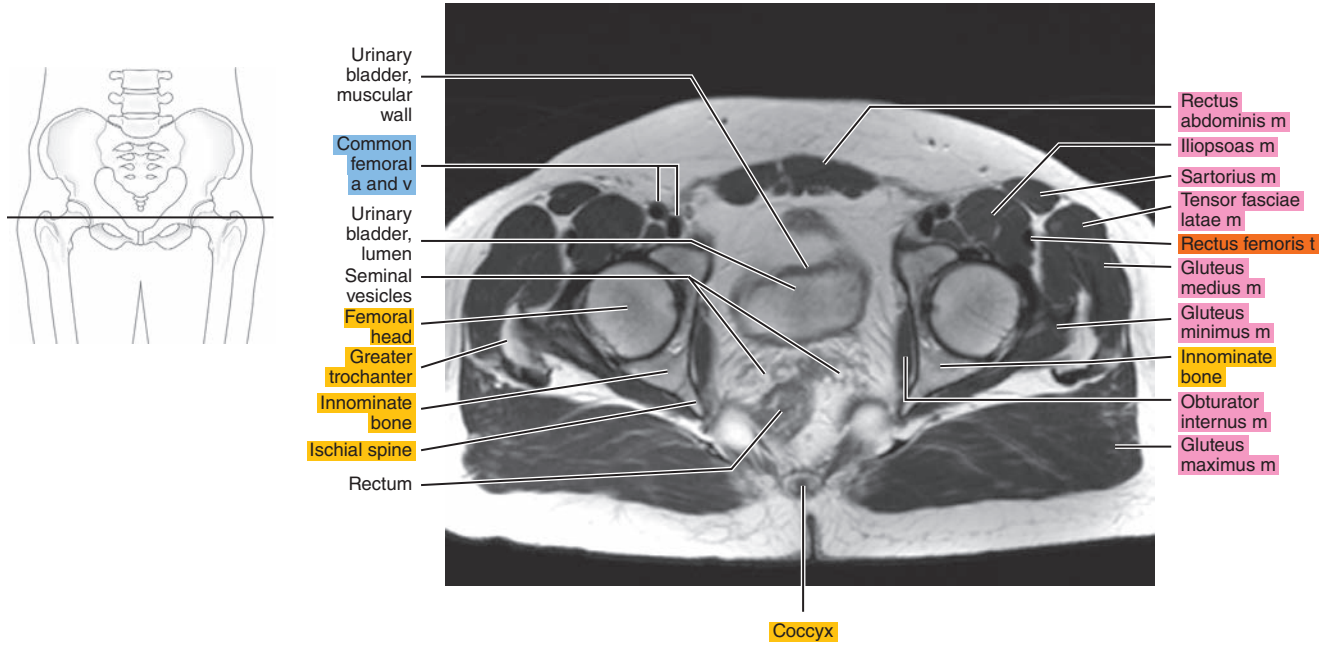


Figure 27.1.8

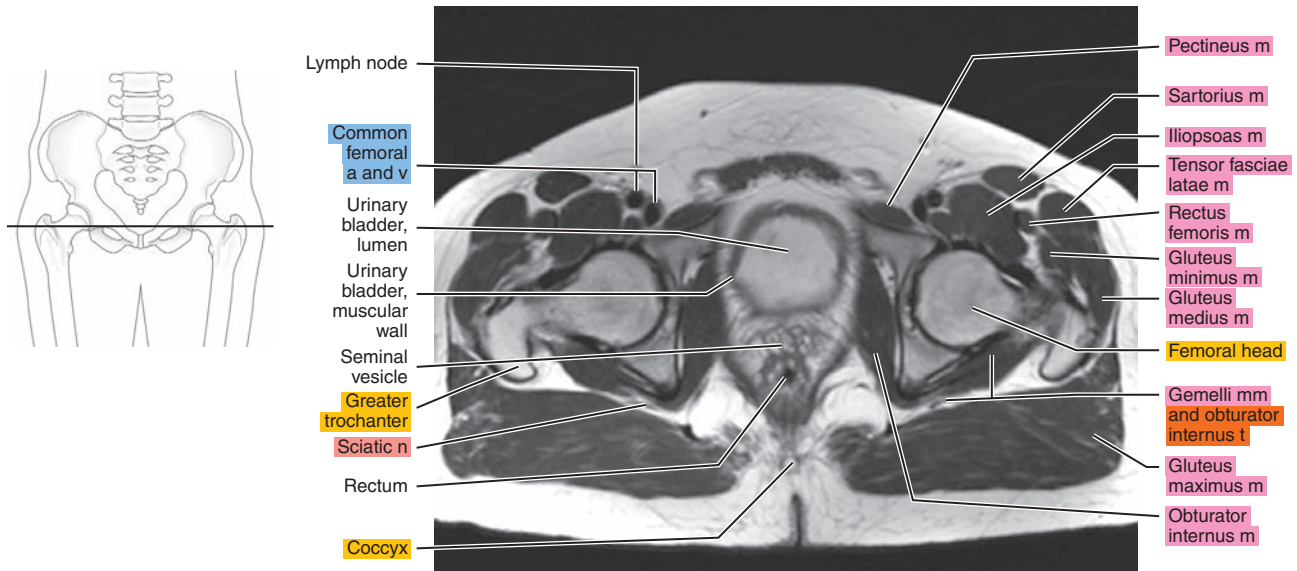


Figure 27.1.9

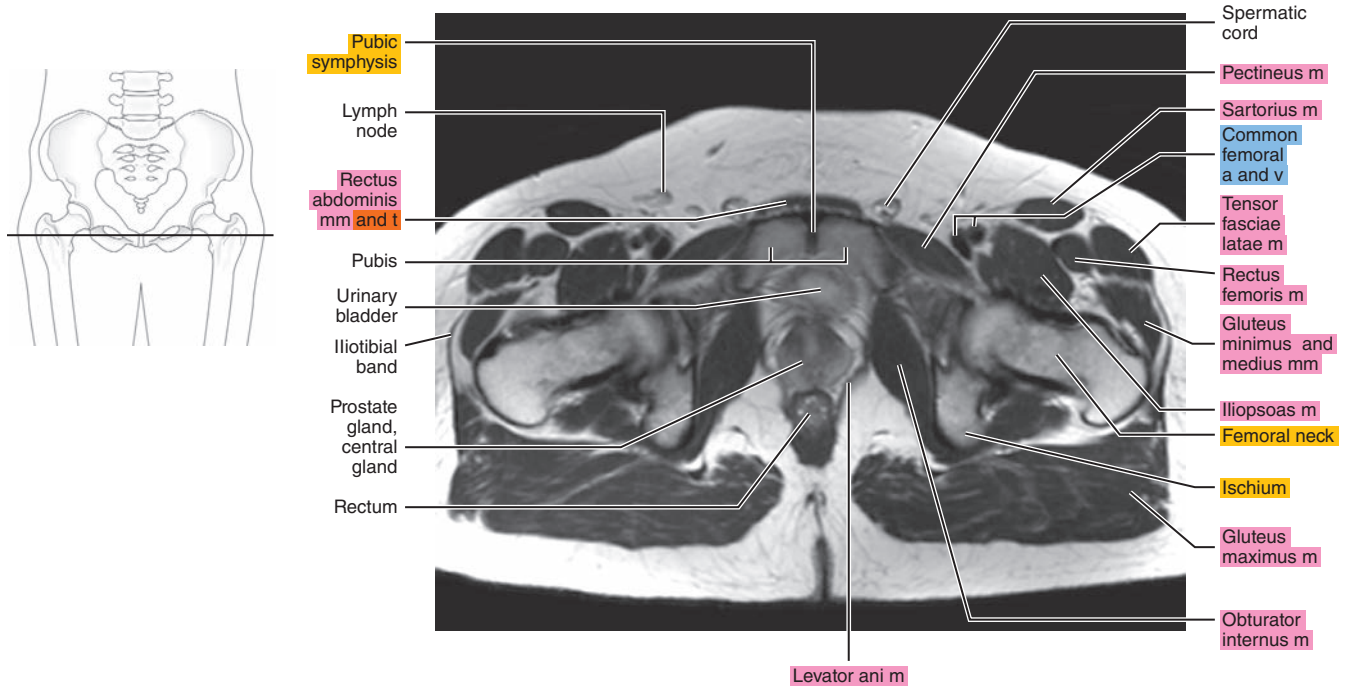


Figure 27.1.10

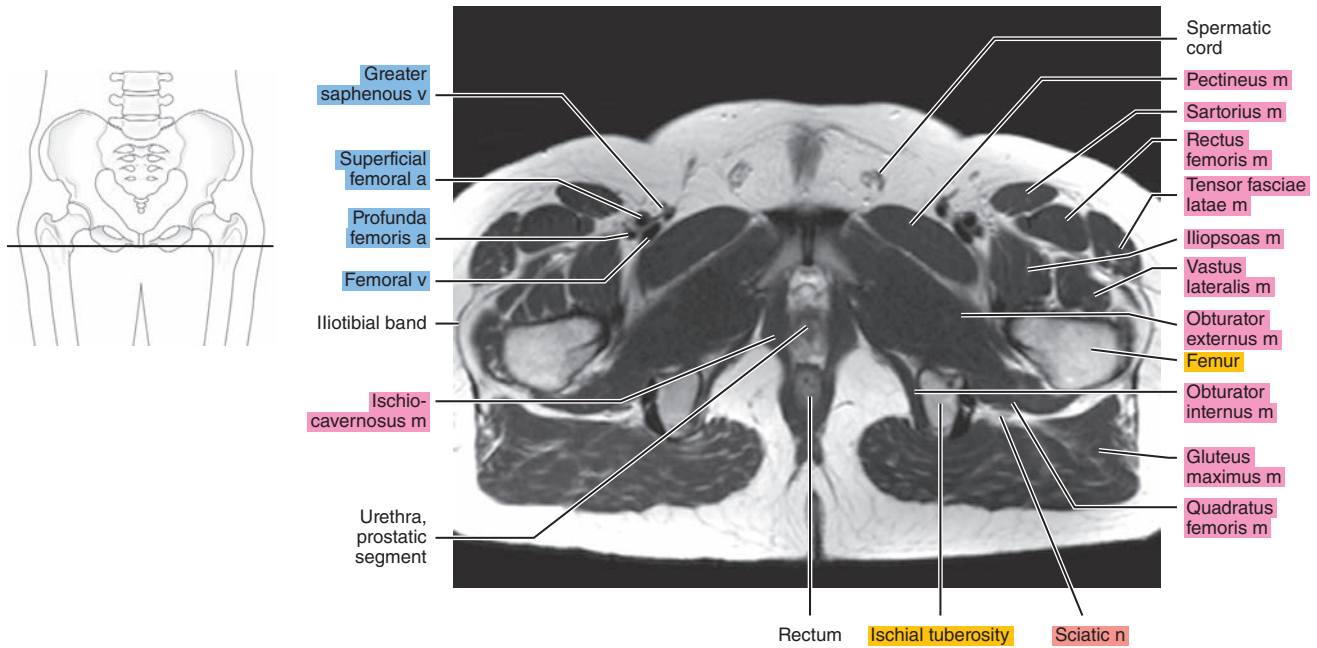




Figure 27.1.11

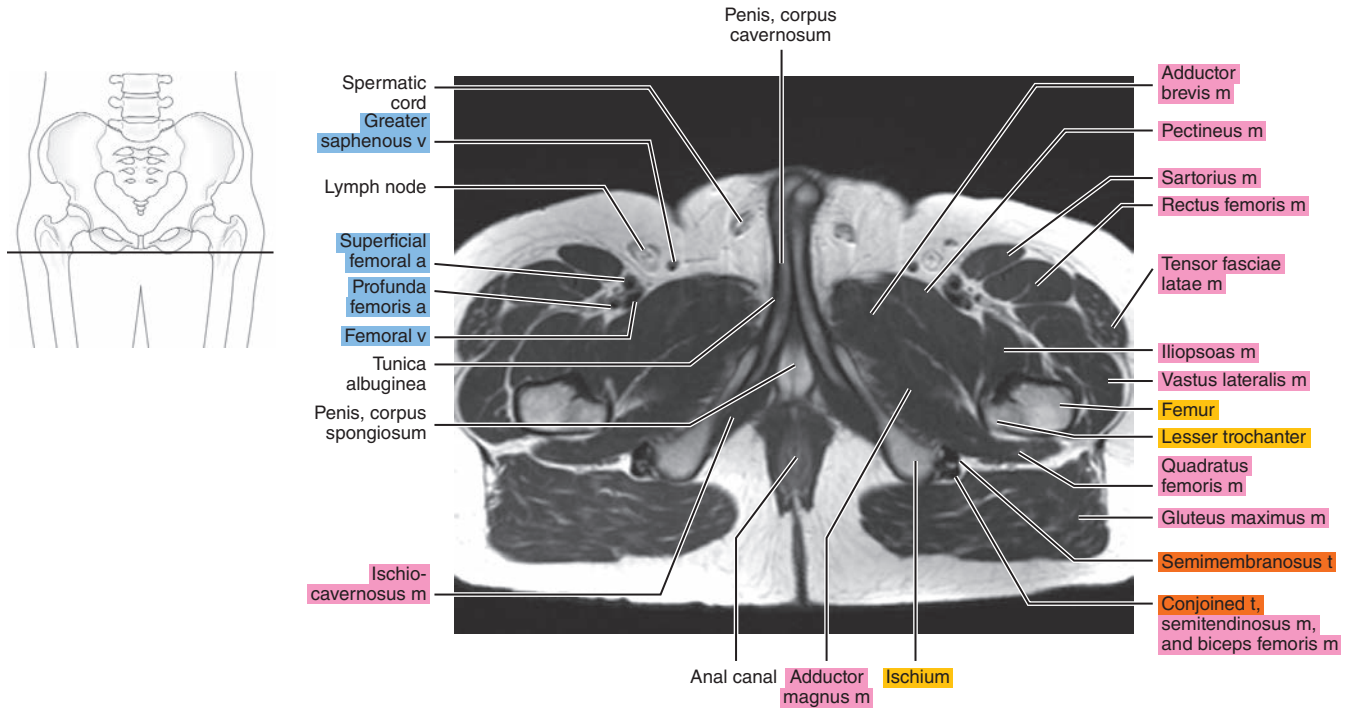
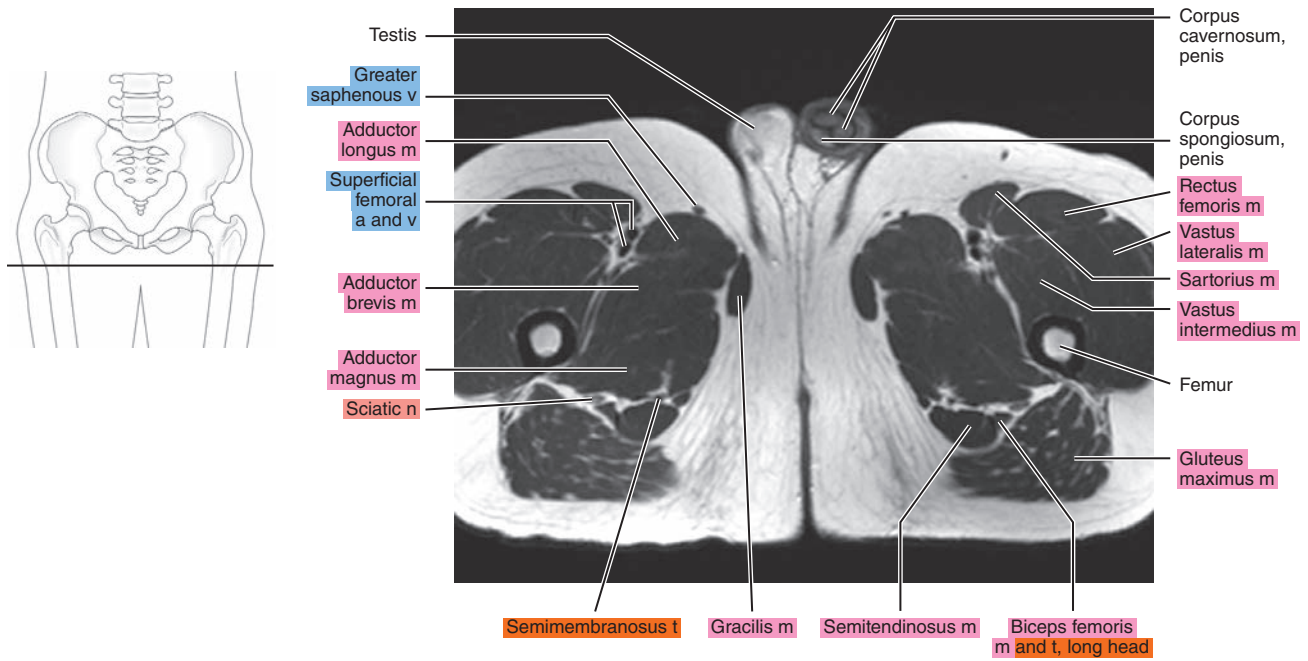


Figure 27.1.12



# SAGITTAL

Figure 27.2.1

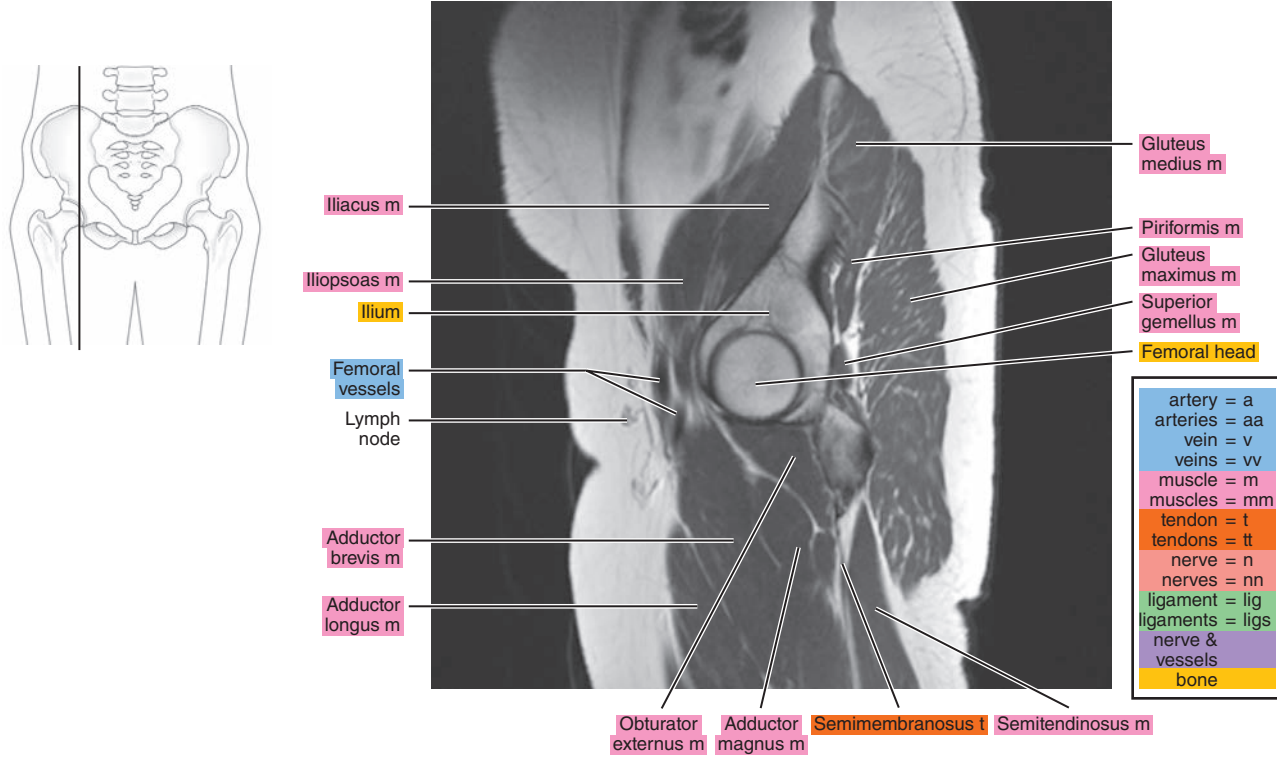


Figure 27.2.2

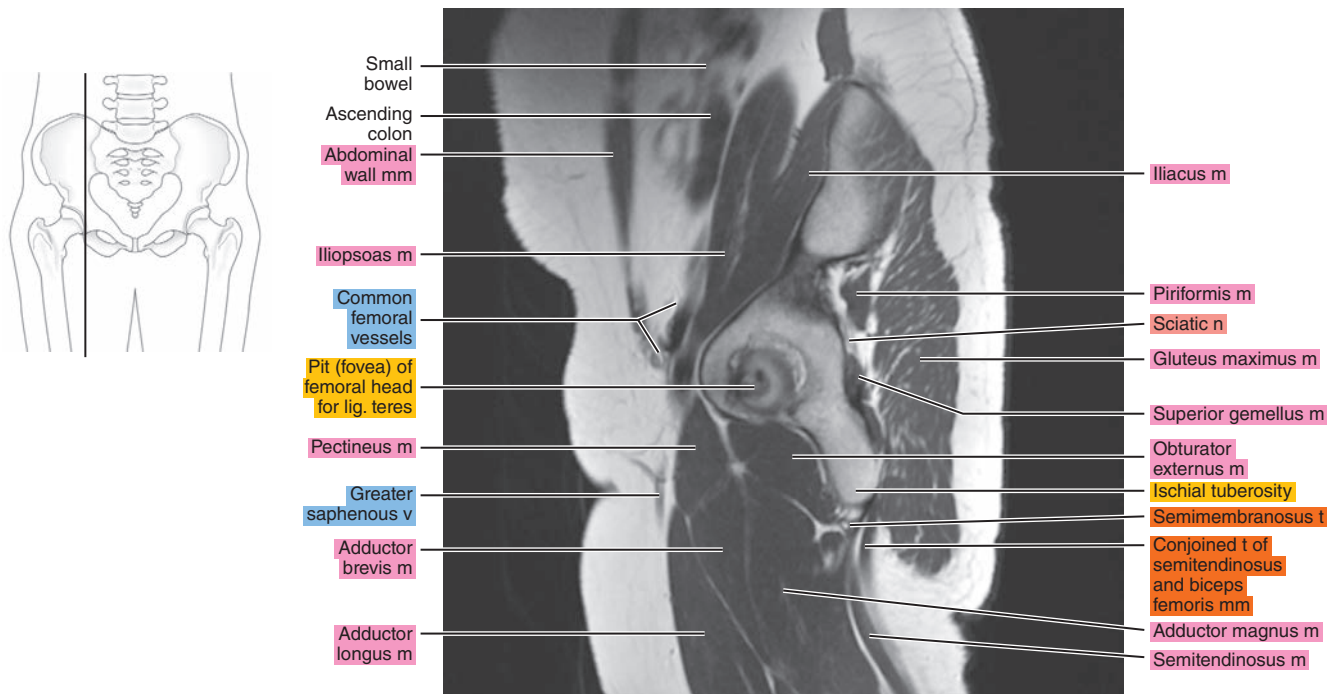


Figure 27.2.3

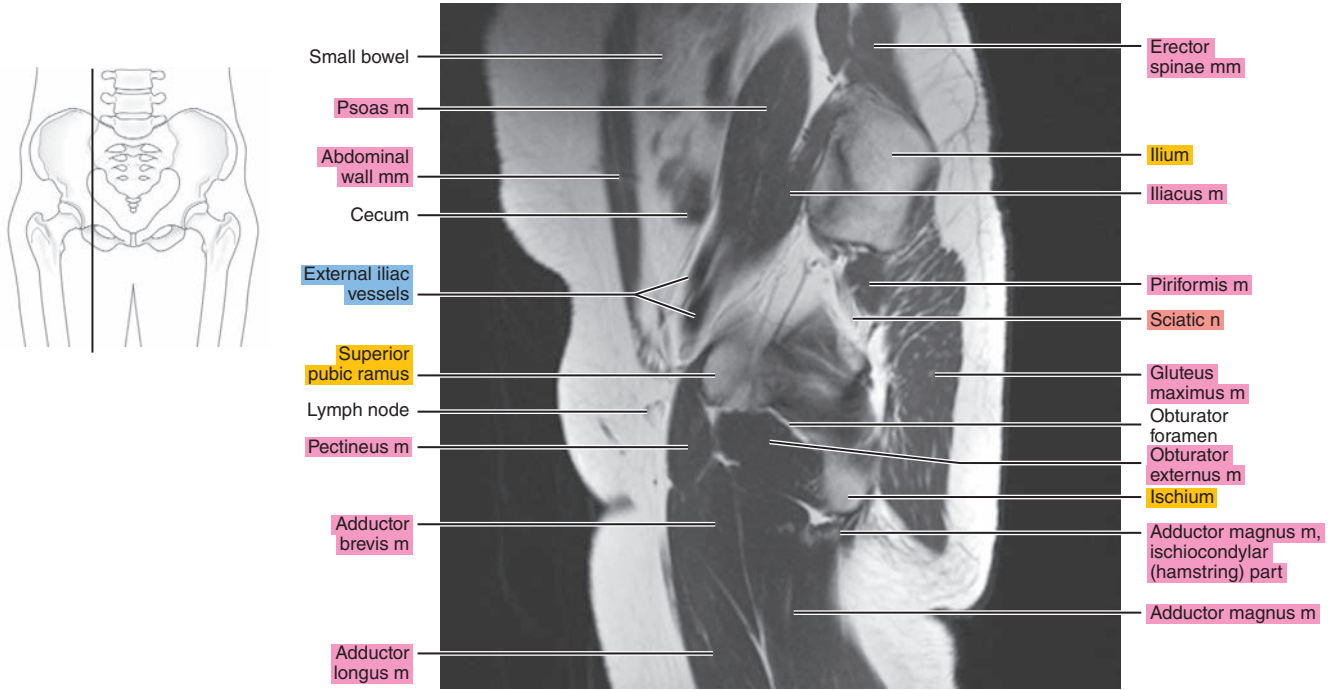


Figure 27.2.4

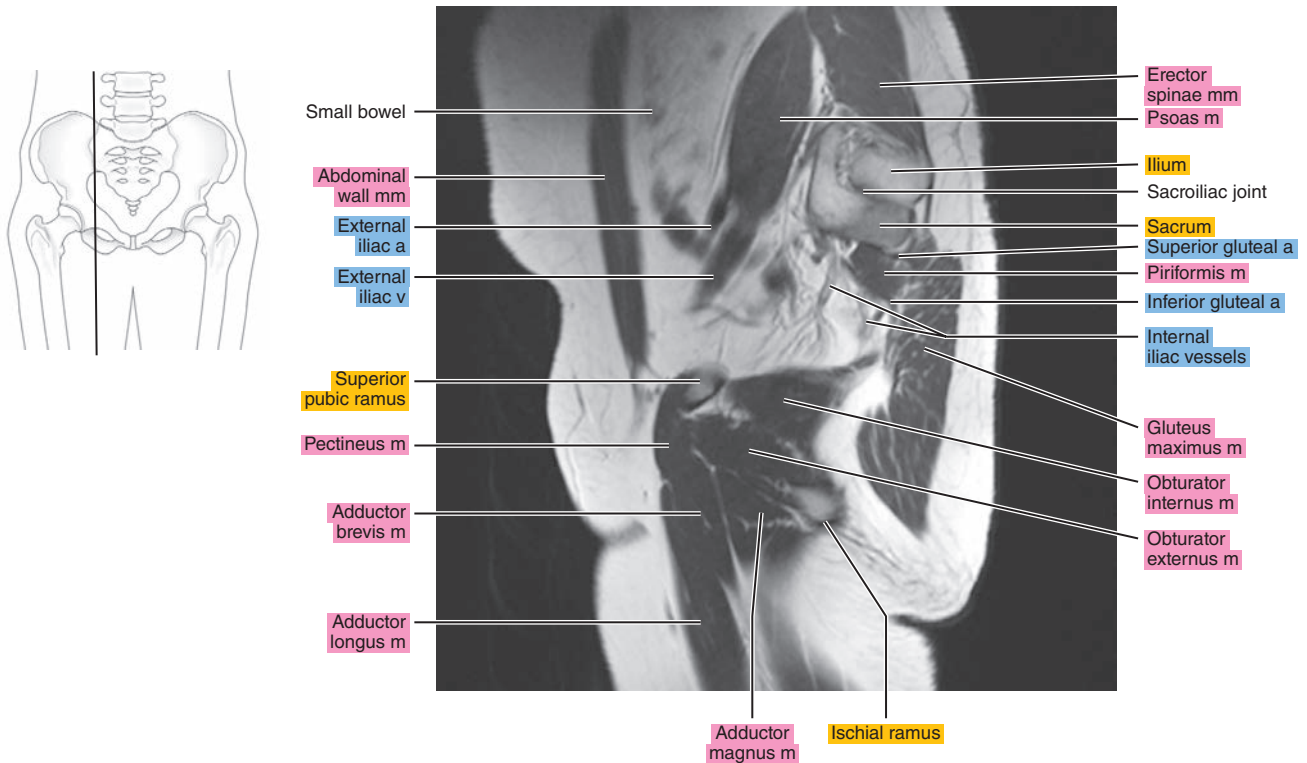


Figure 27.2.5

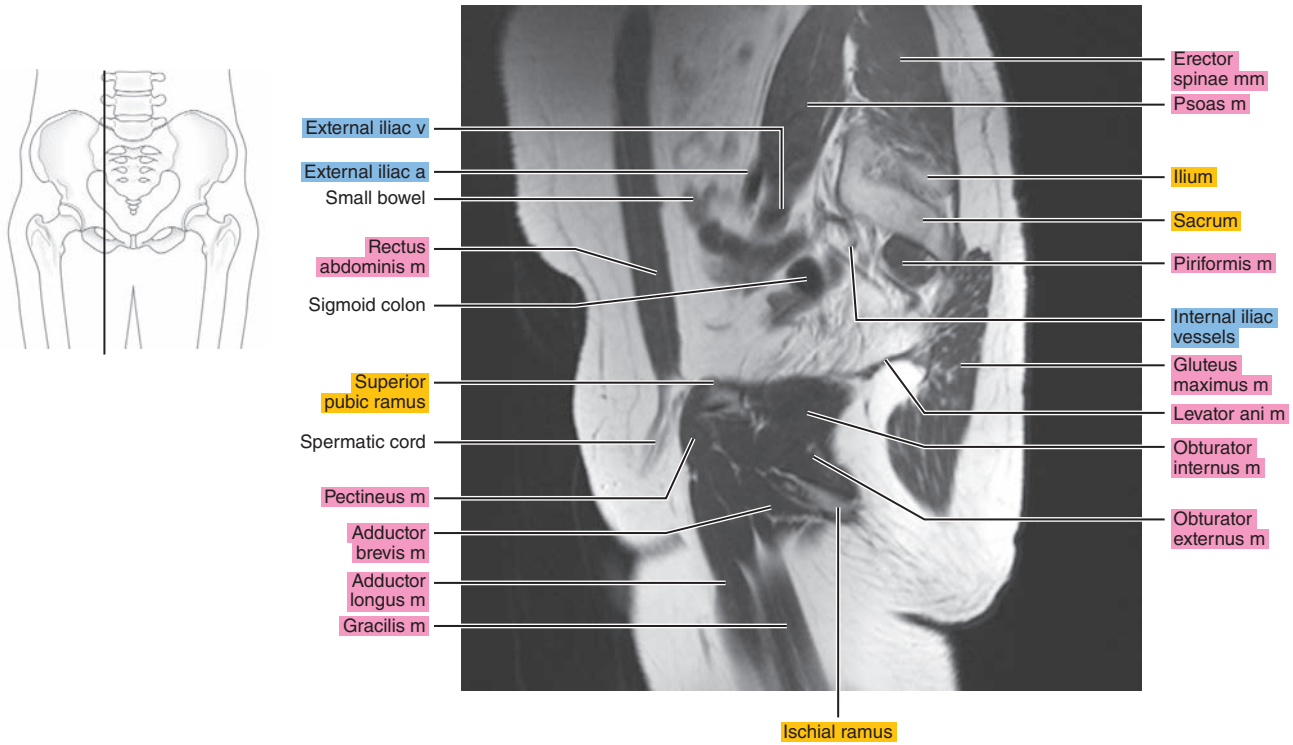


Figure 27.2.6

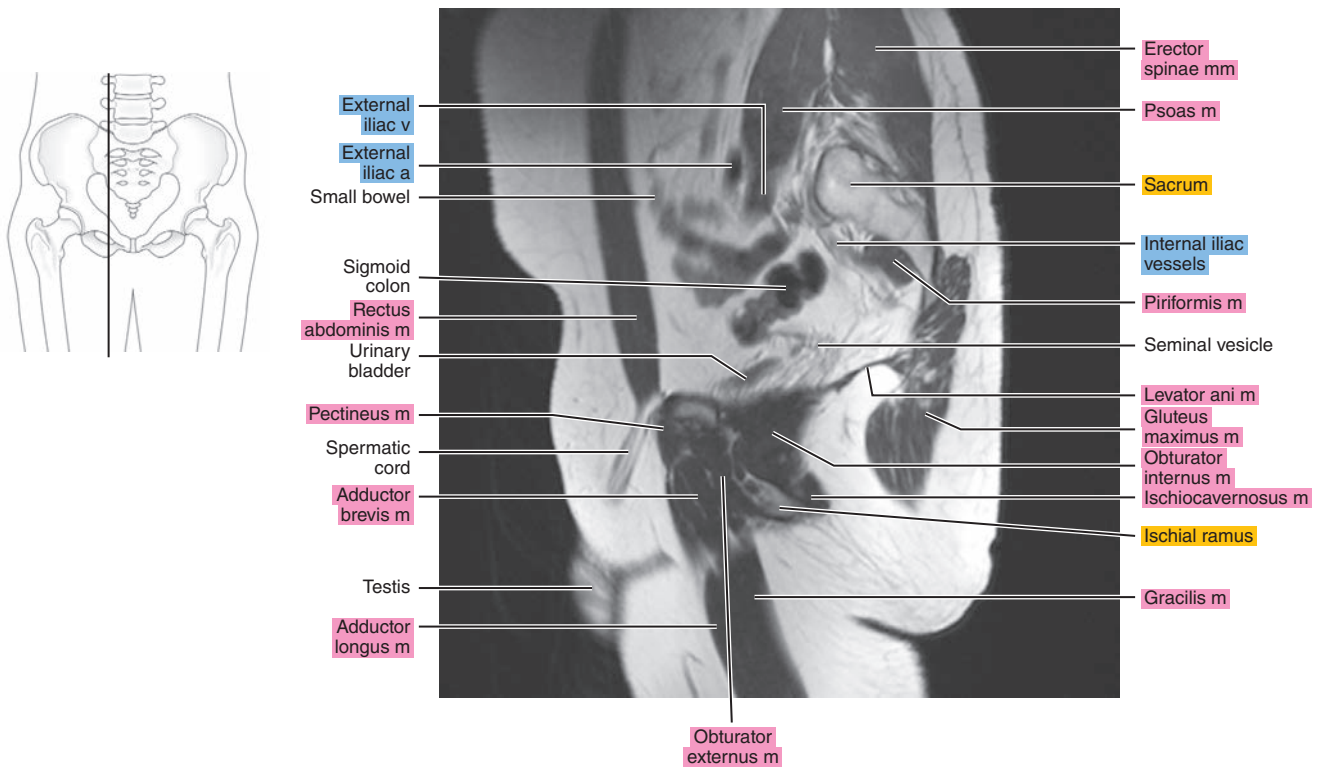




Figure 27.2.7

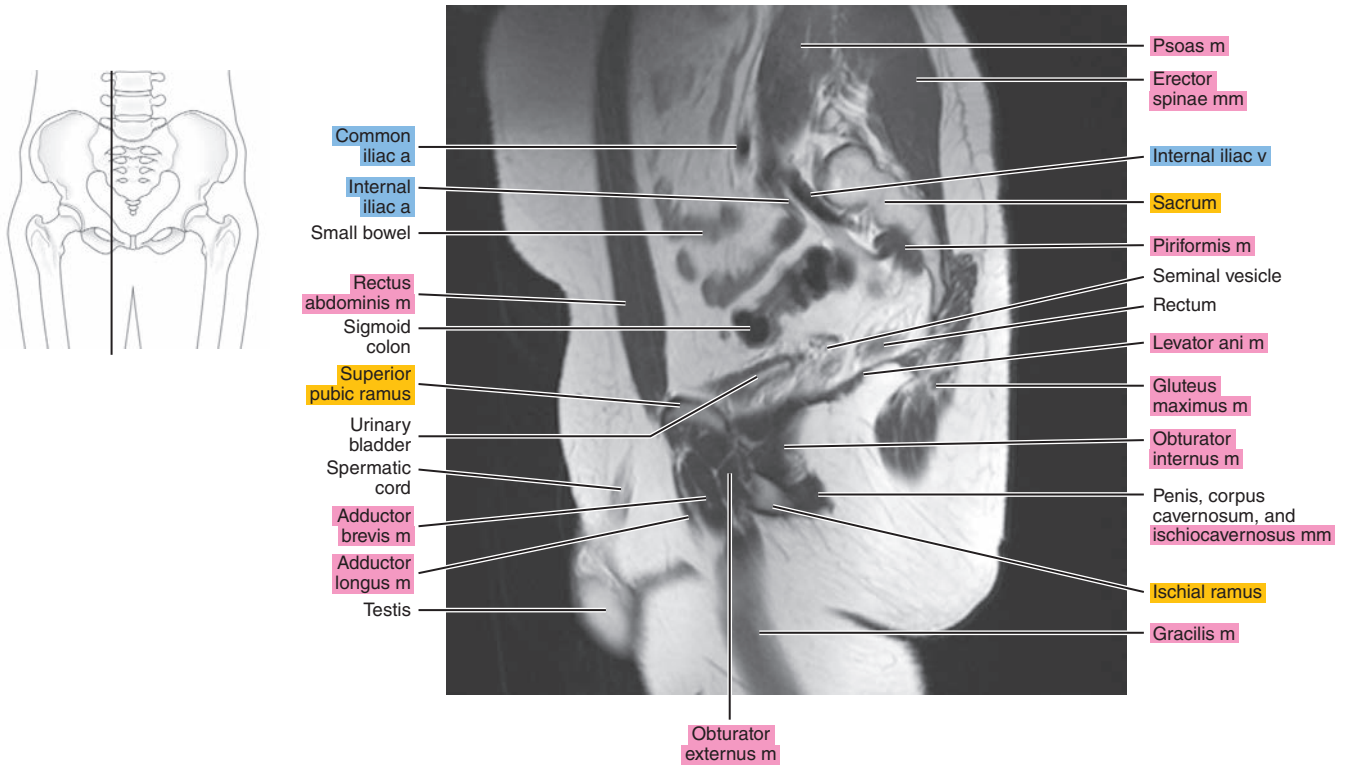


Figure 27.2.8

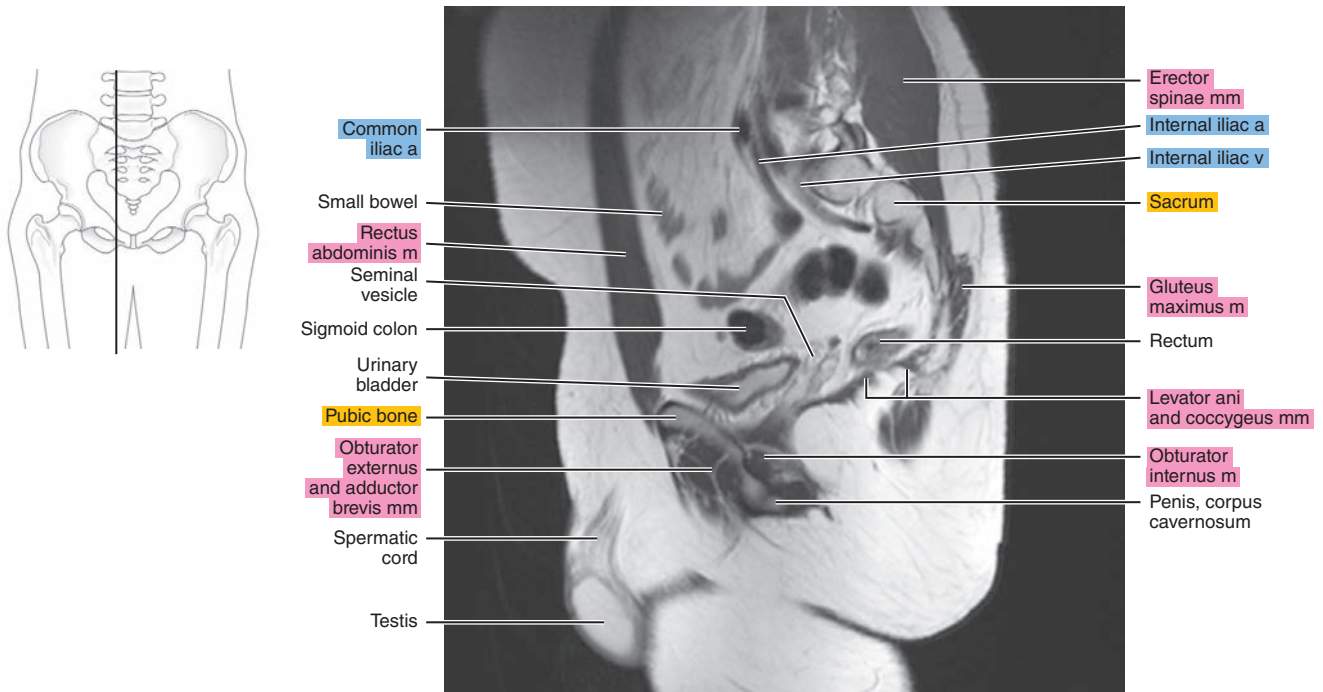


Figure 27.2.9

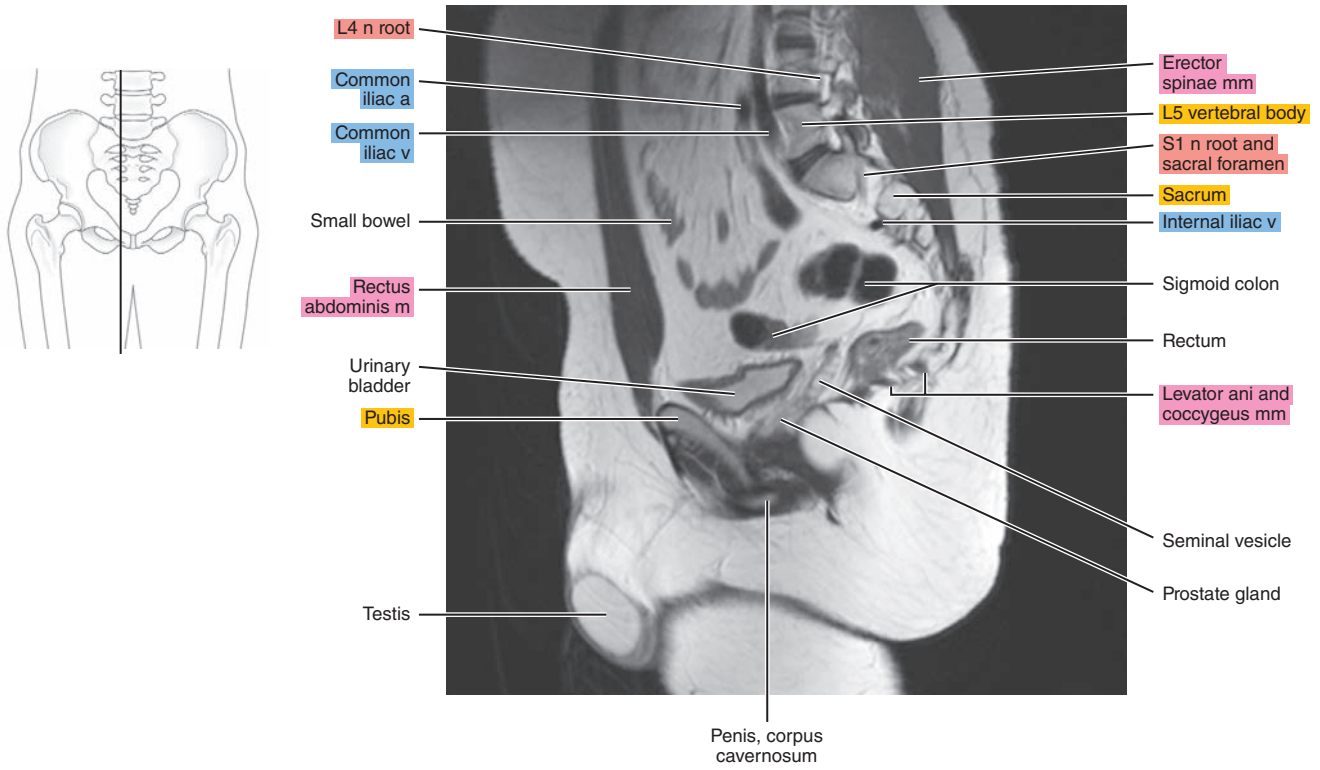


Figure 27.2.10

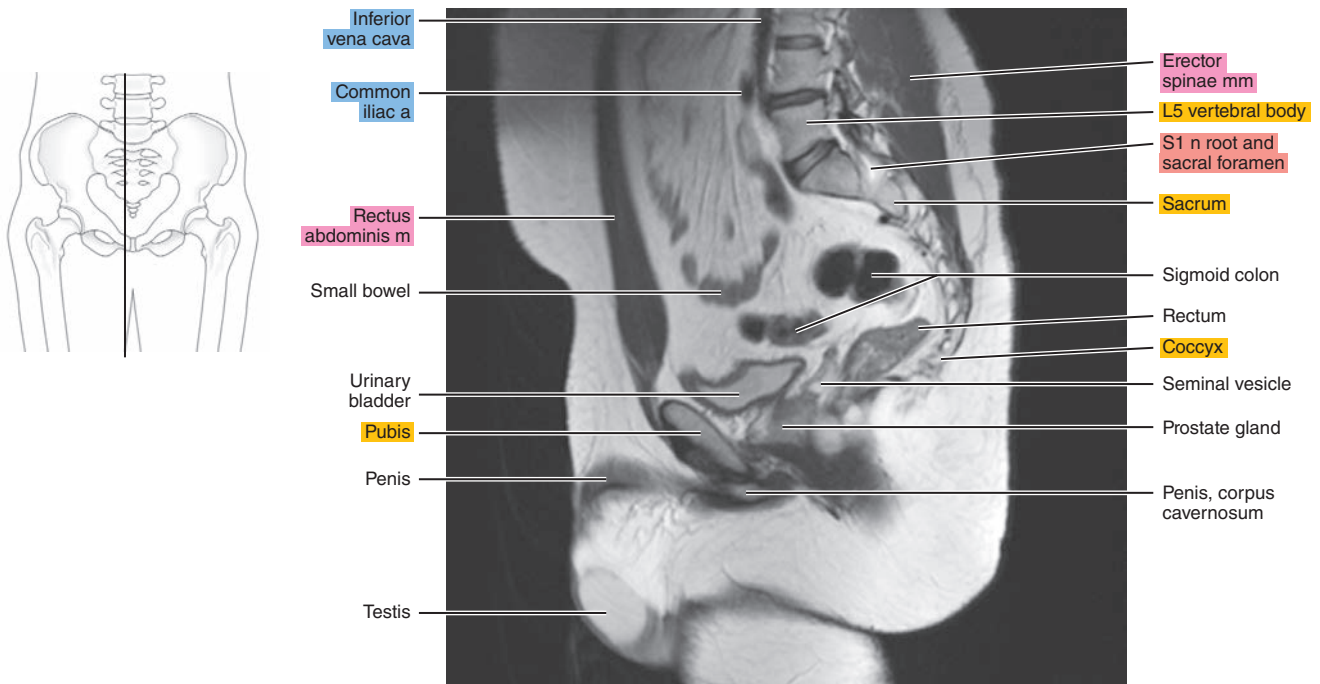


Figure 27.2.11

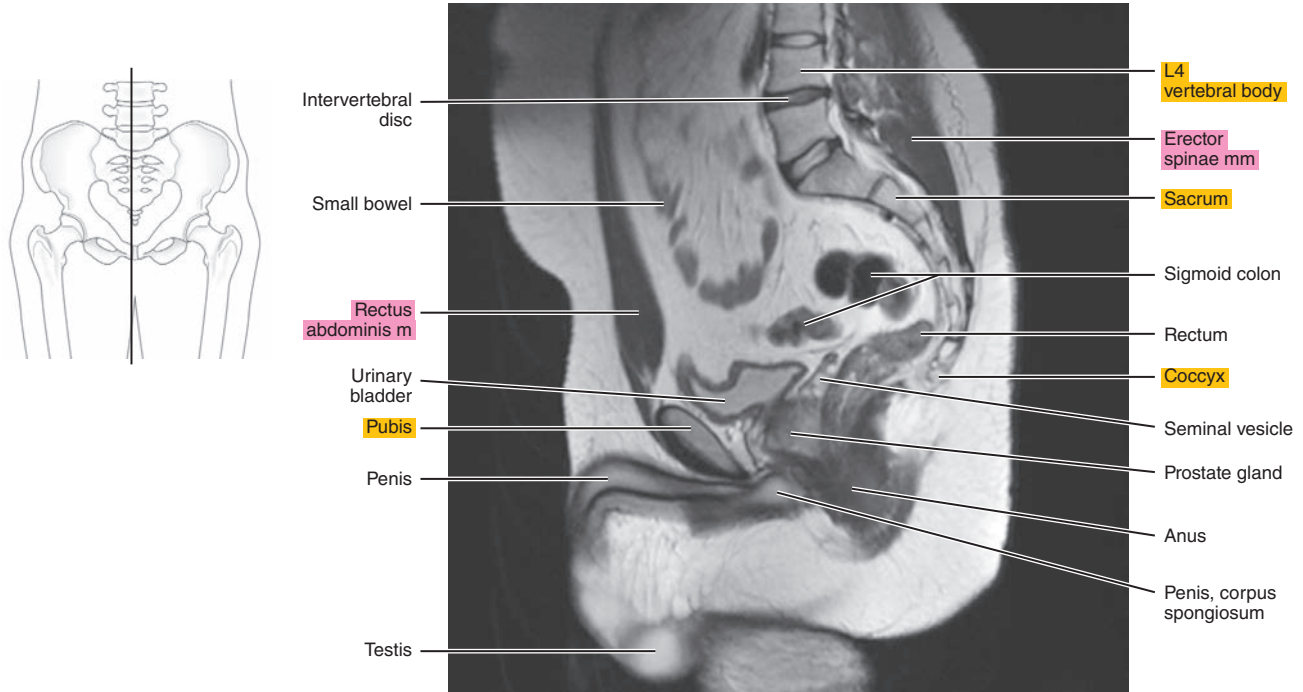
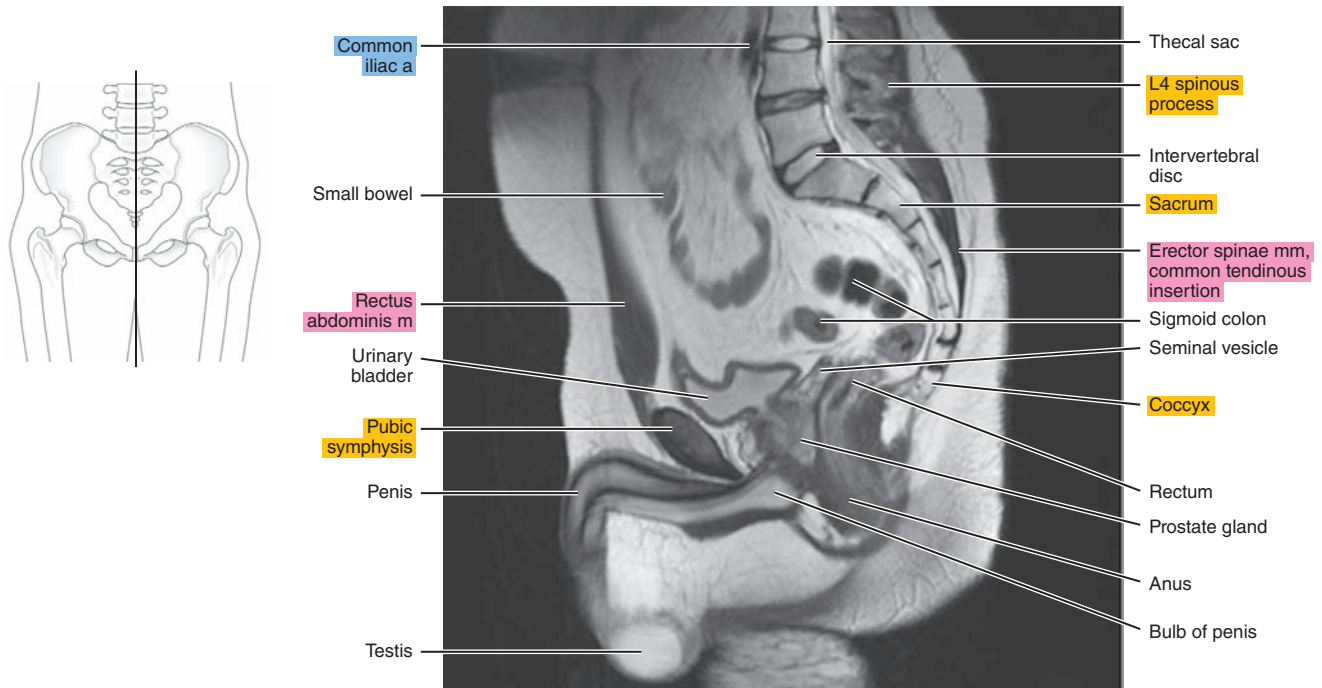


Figure 27.2.12



# CORONAL

Figure 27.3.1

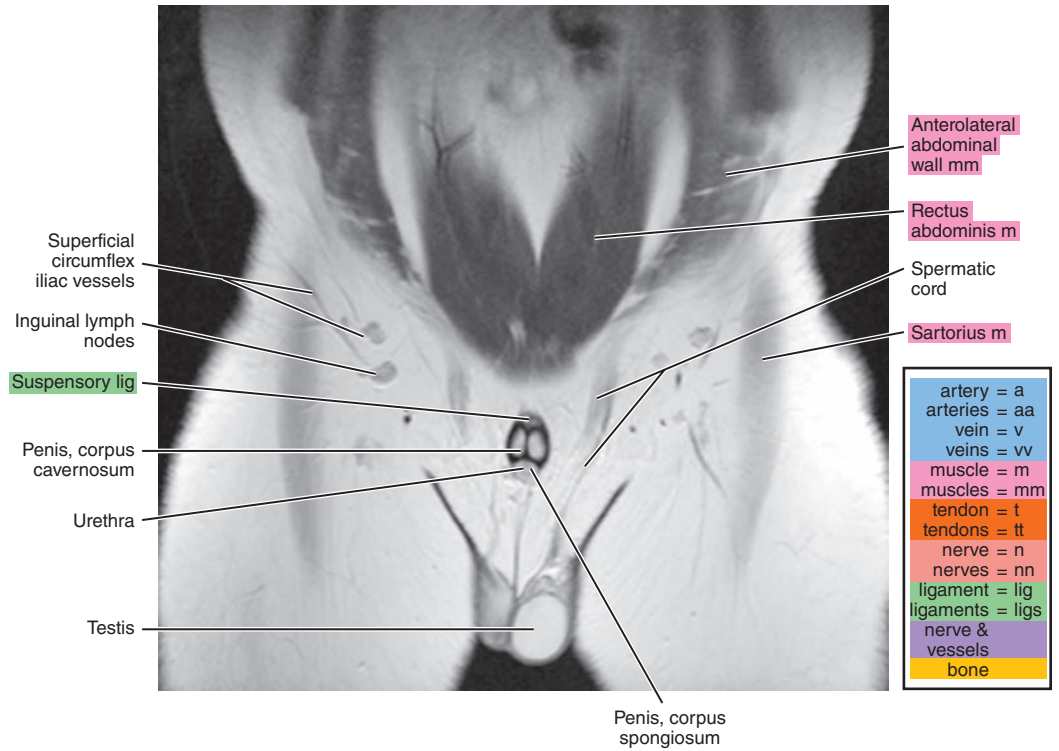
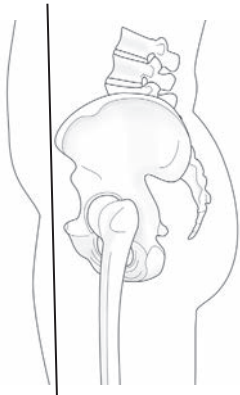

Figure 27.3.2

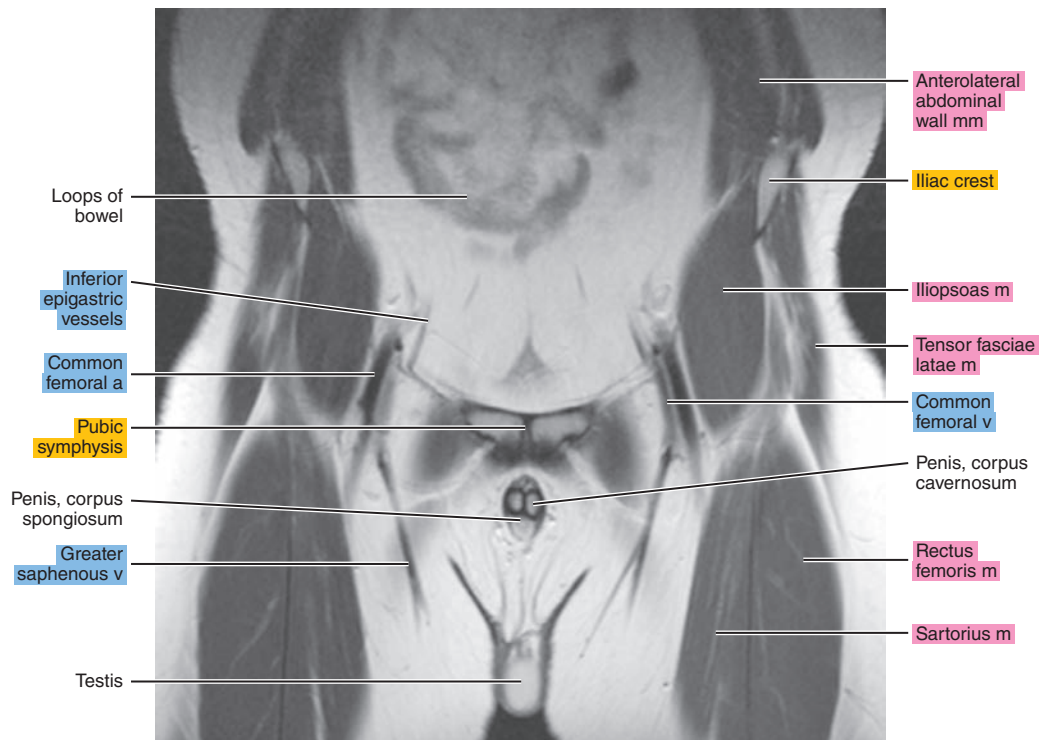
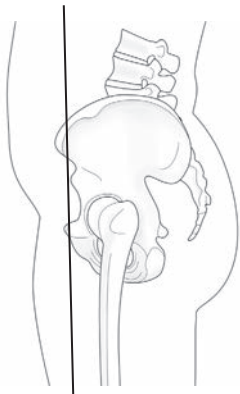



Figure 27.3.3

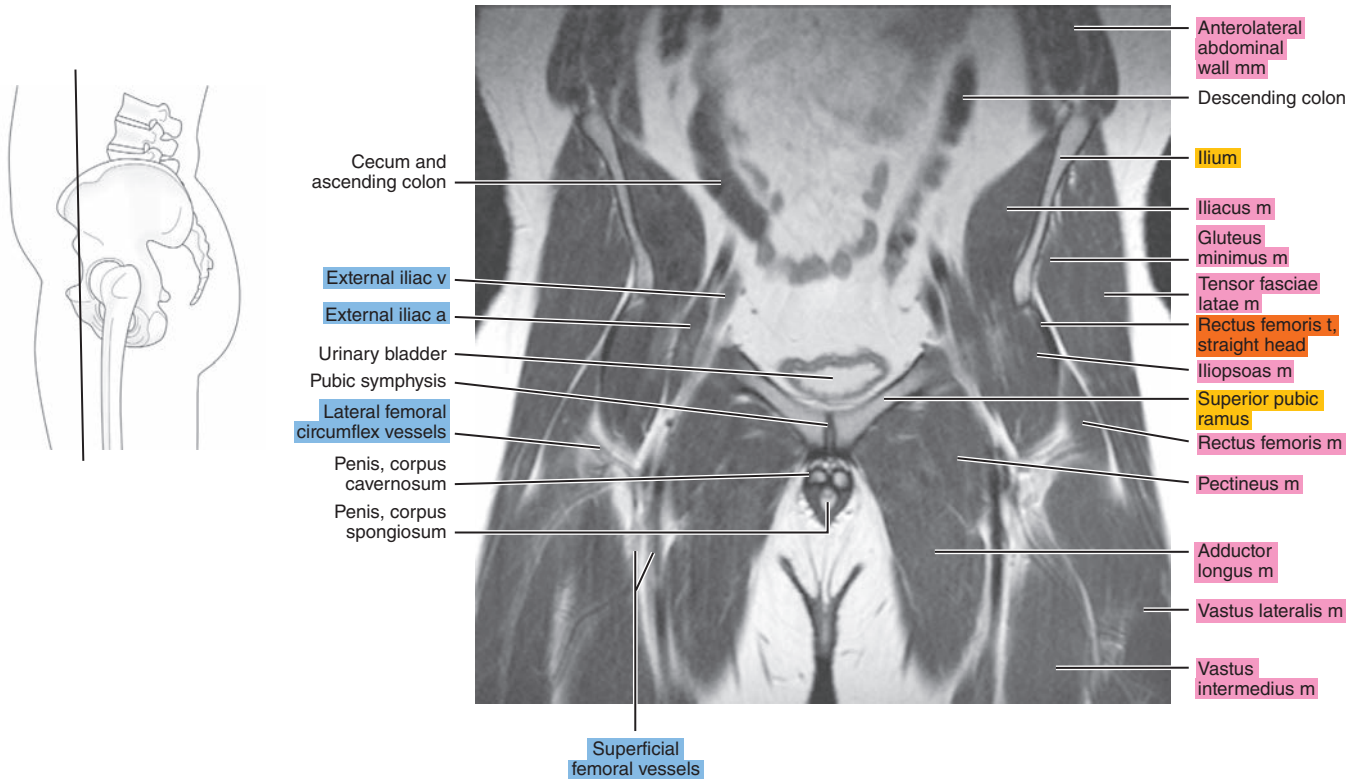


Figure 27.3.4

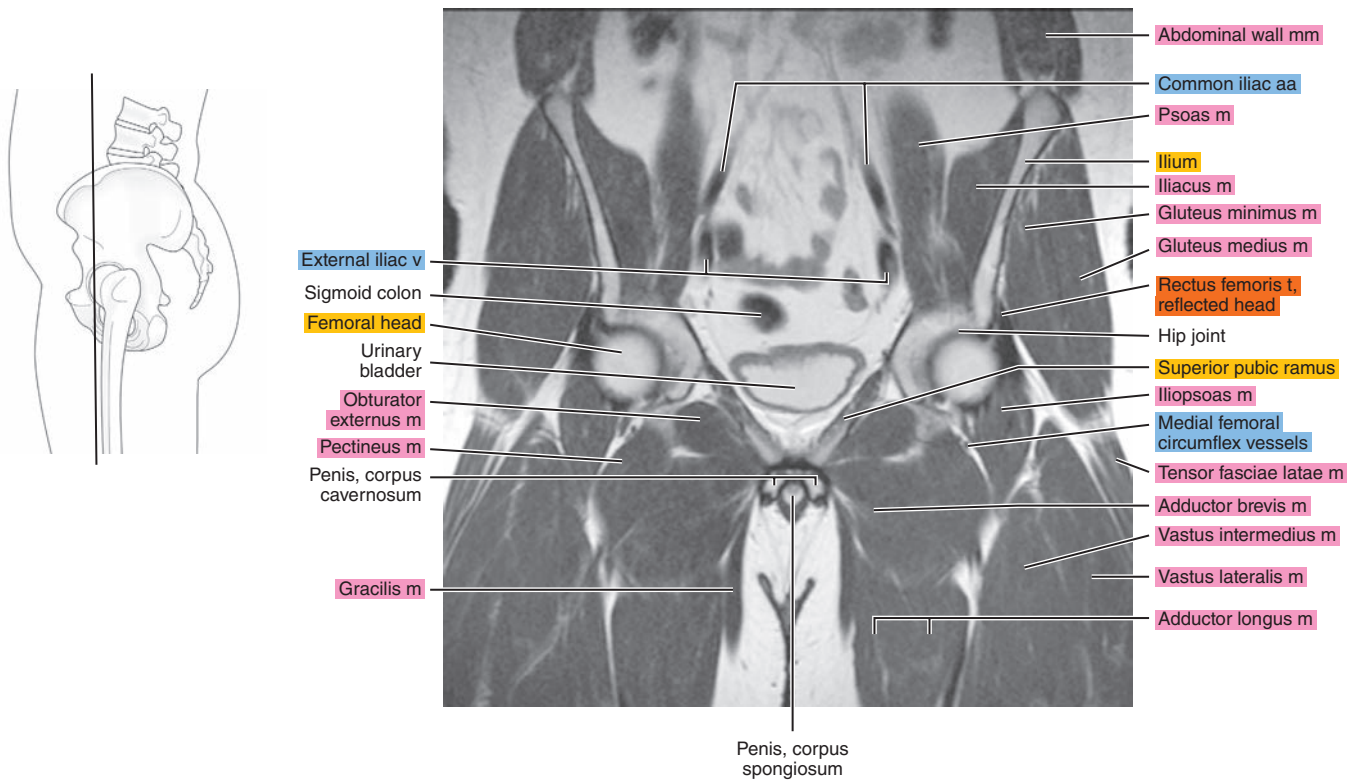


Figure 27.3.5

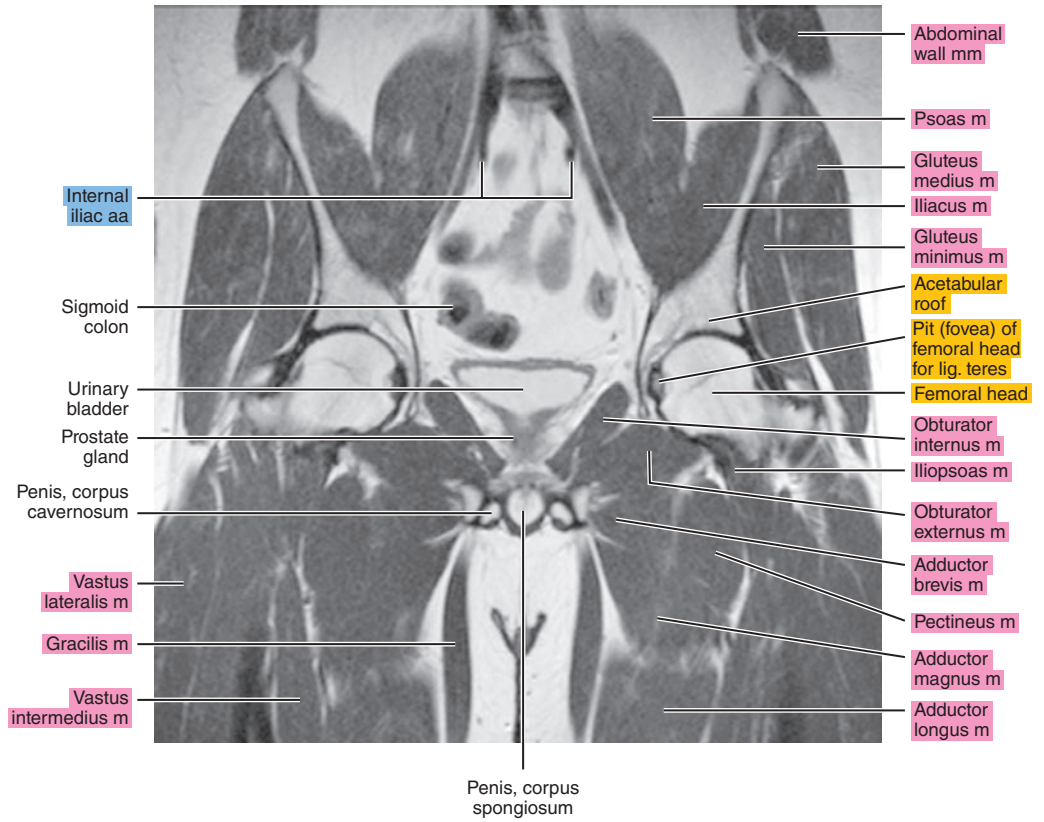
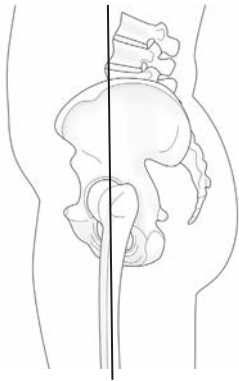


Figure 27.3.6

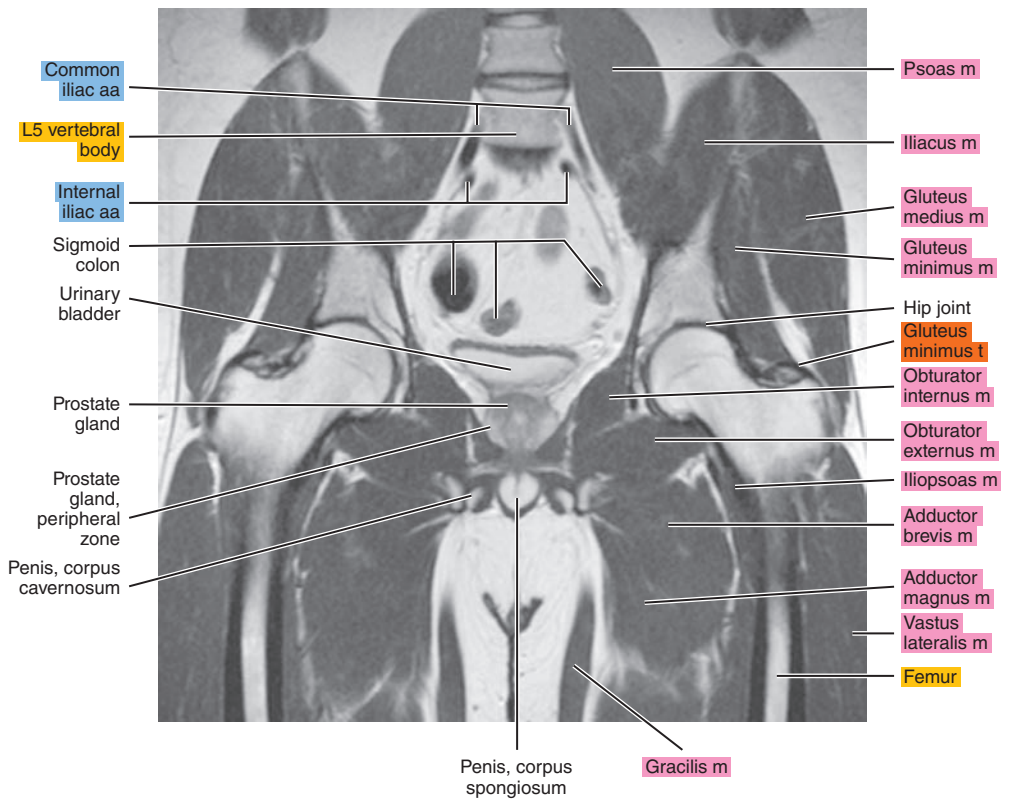
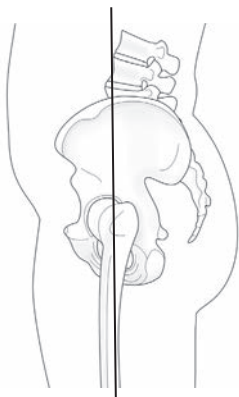


Figure 27.3.7

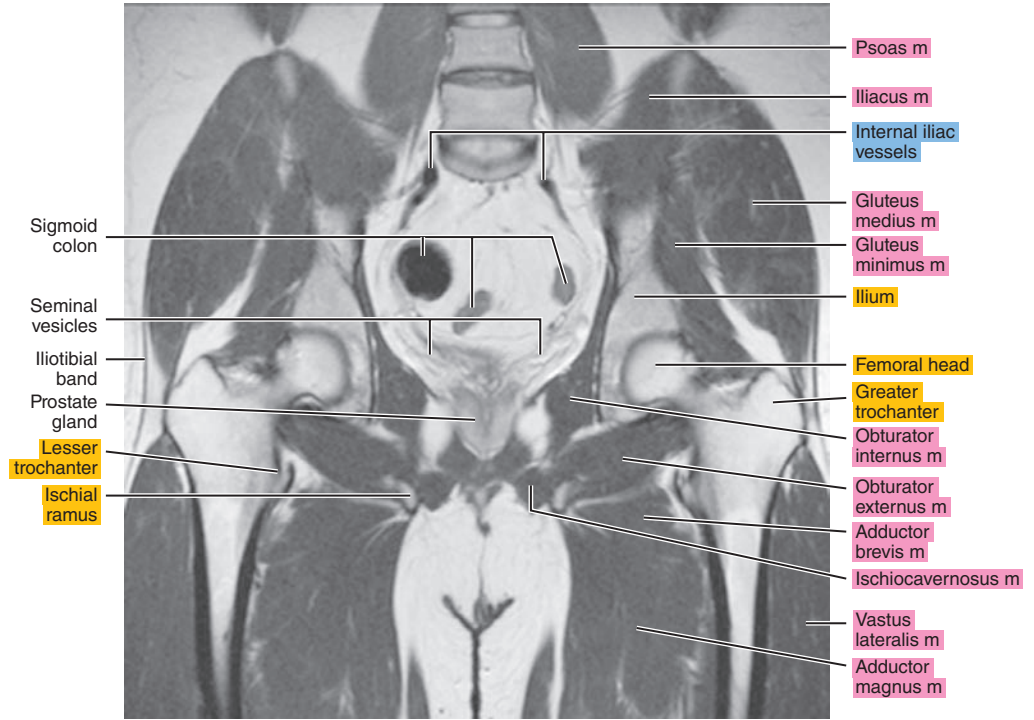
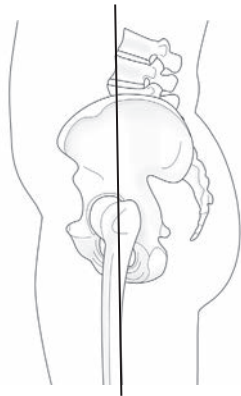


Figure 27.3.8

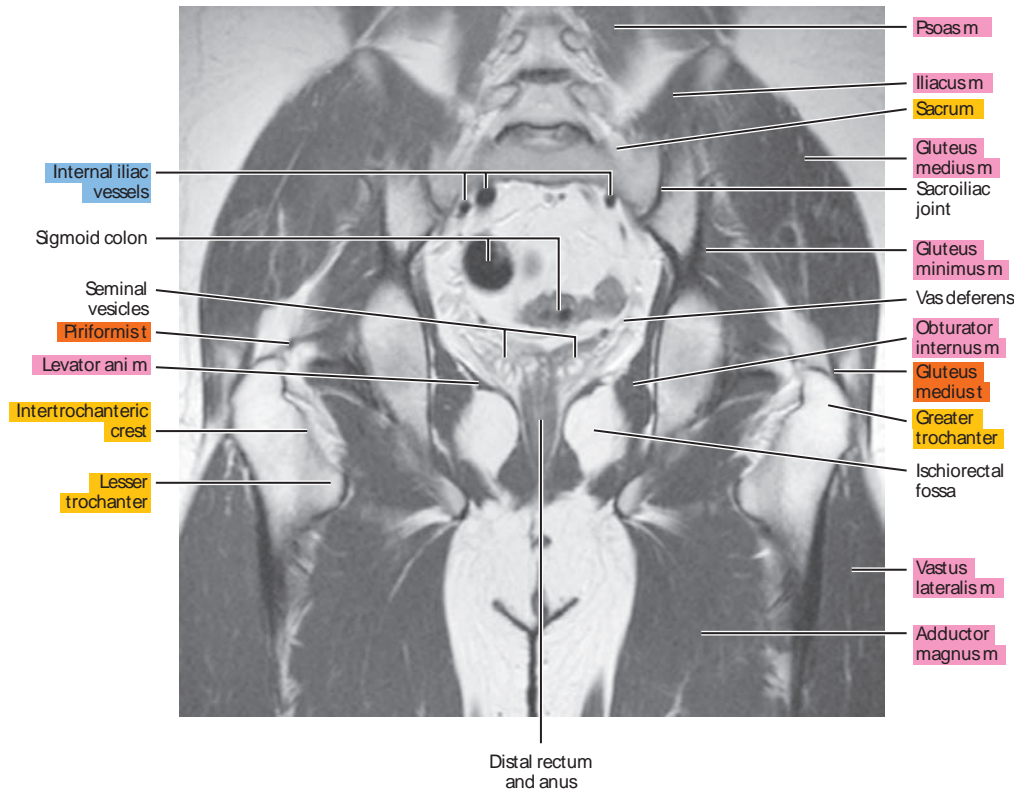
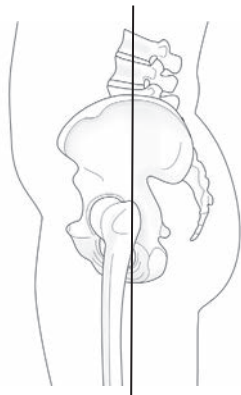




Figure 27.3.9

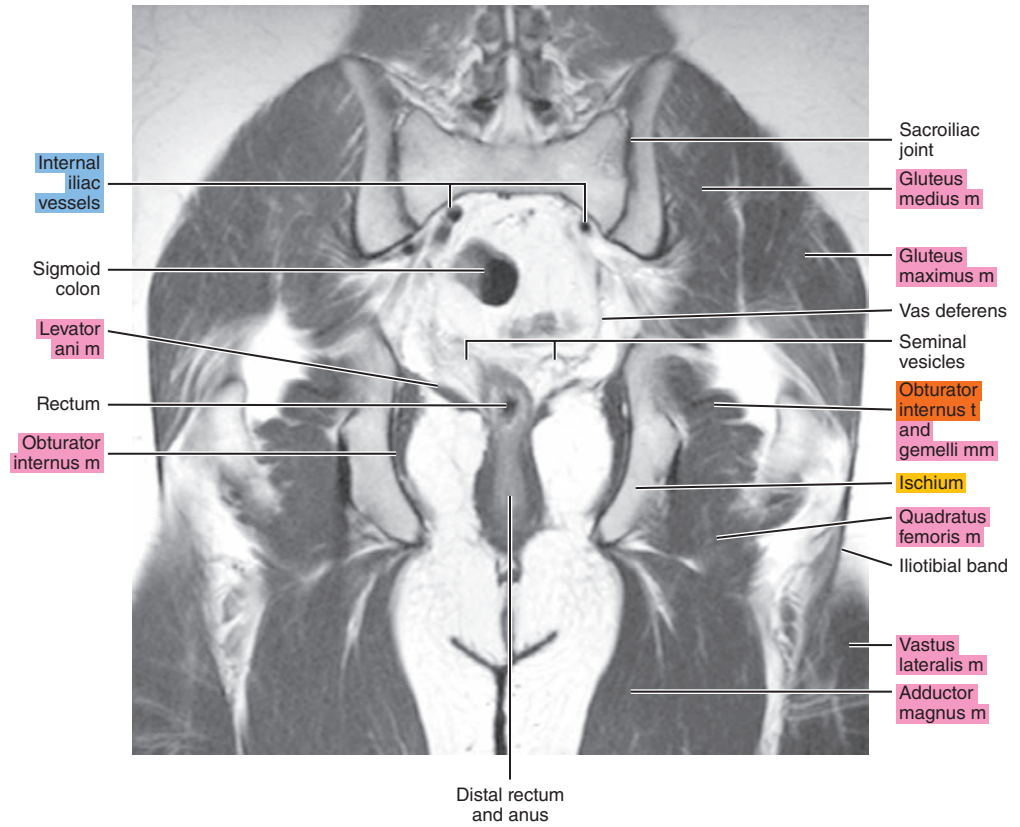
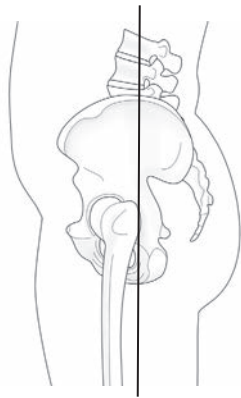


Figure 27.3.10

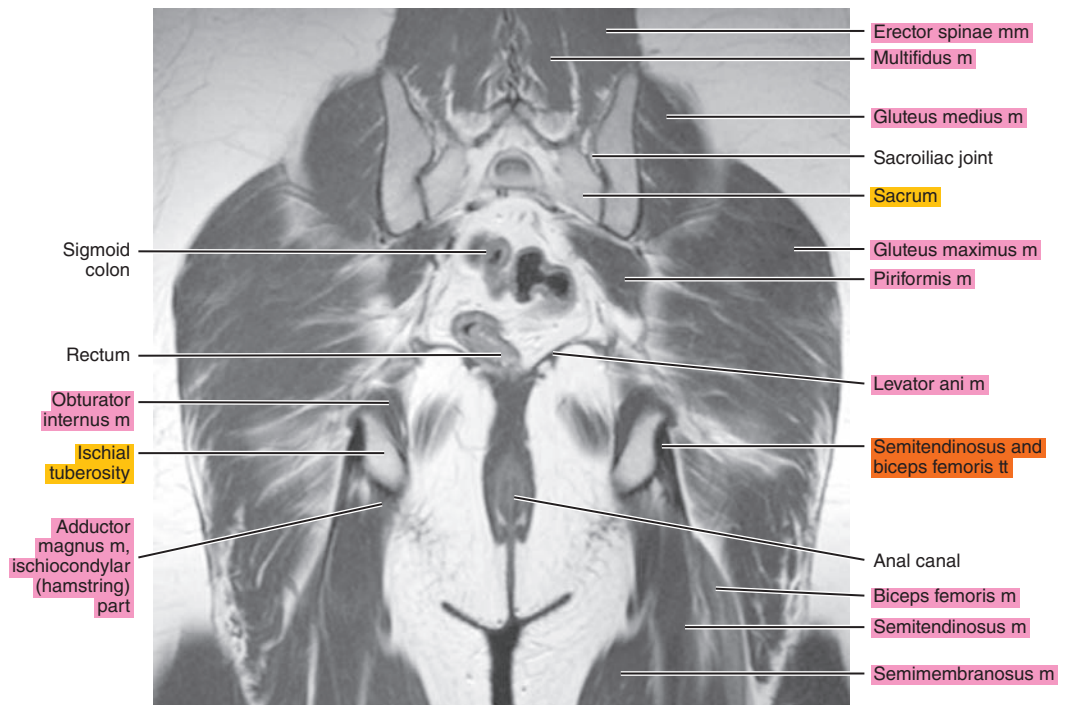
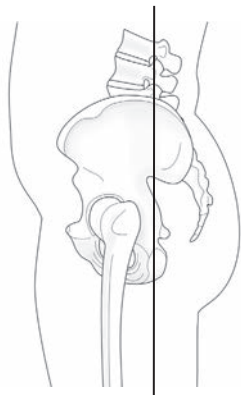




Figure 27.3.11

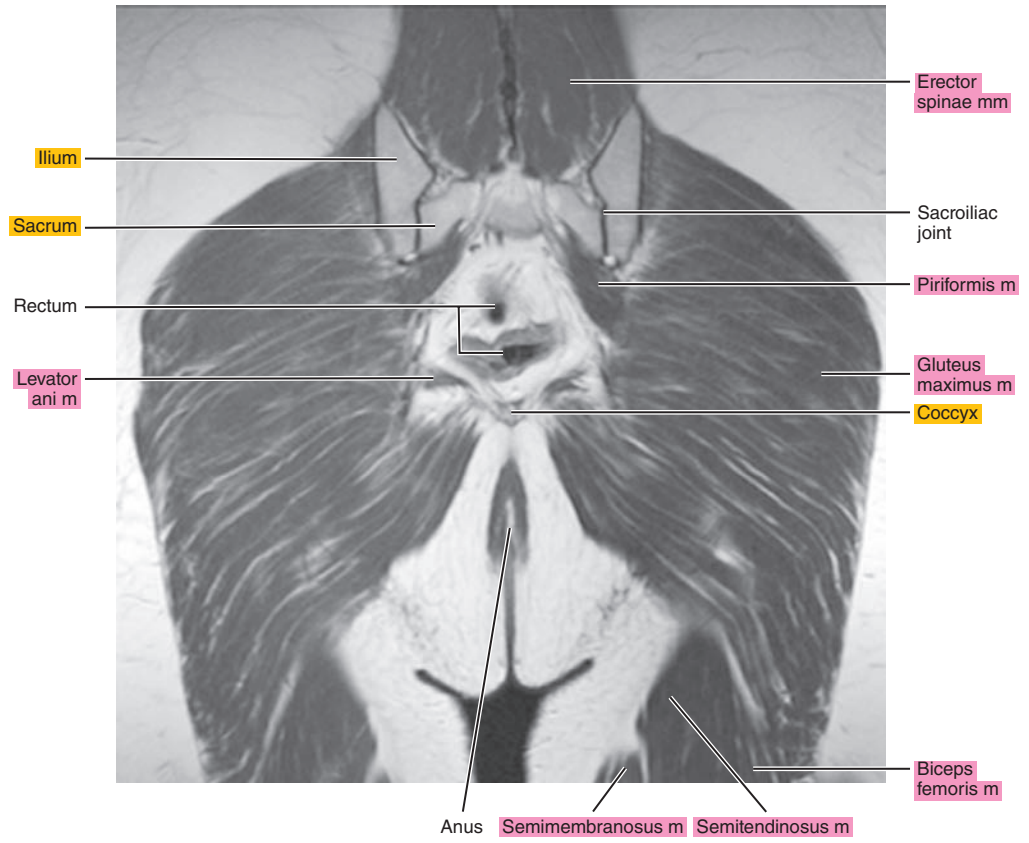
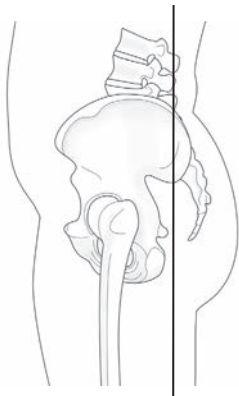
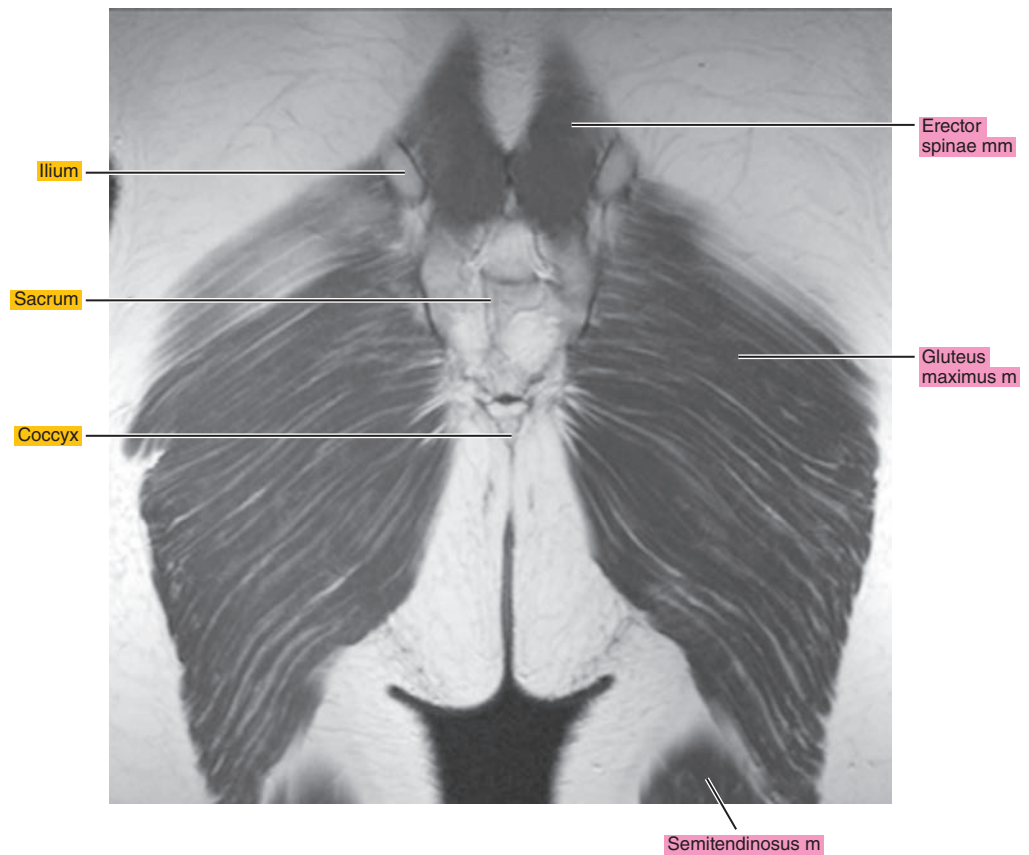
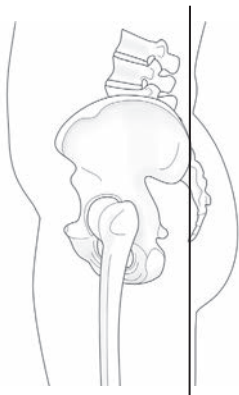


Figure 27.3.12



*Chapter*  
**28**

**MRI of the Female Pelvis**

# AXIAL

Figure 28.1.1

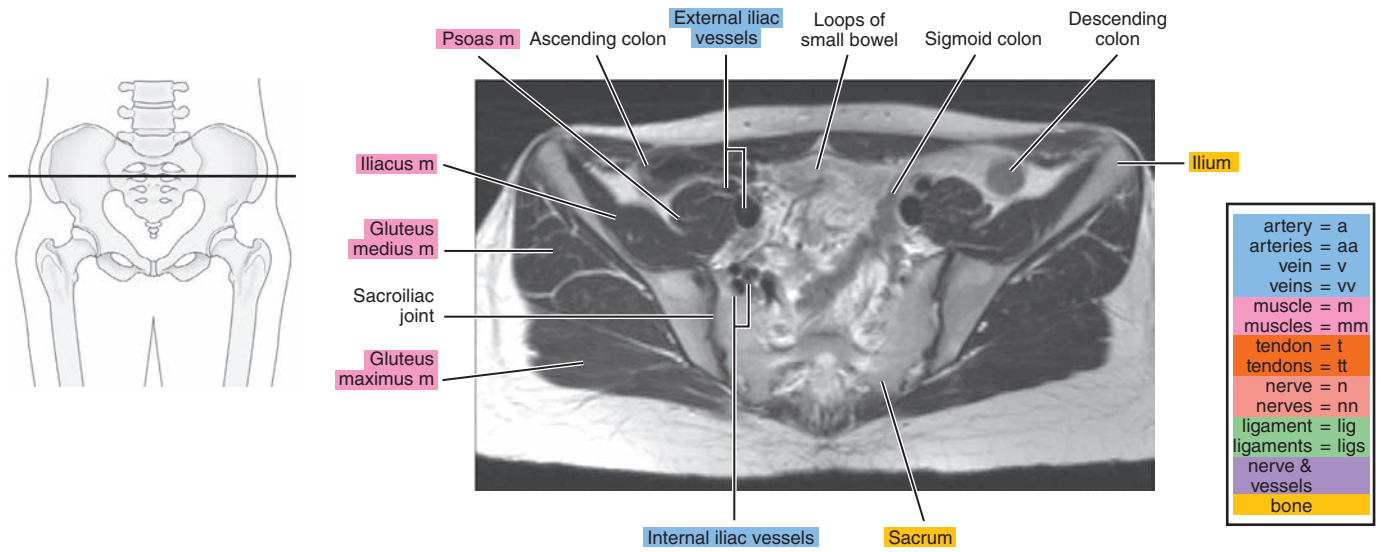


Figure 28.1.2

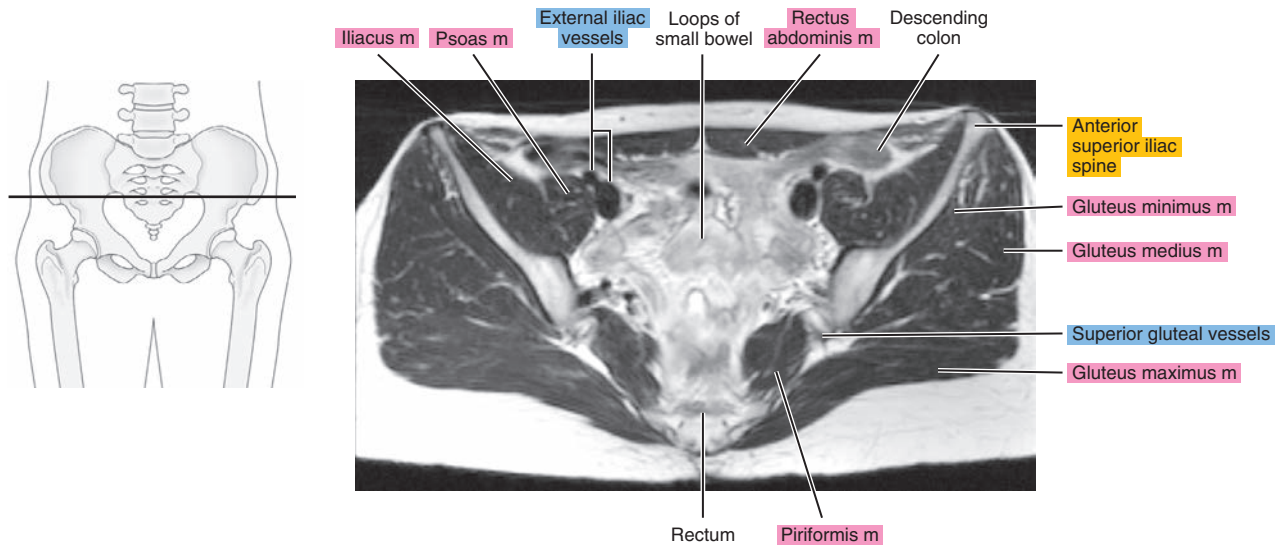


Figure 28.1.3

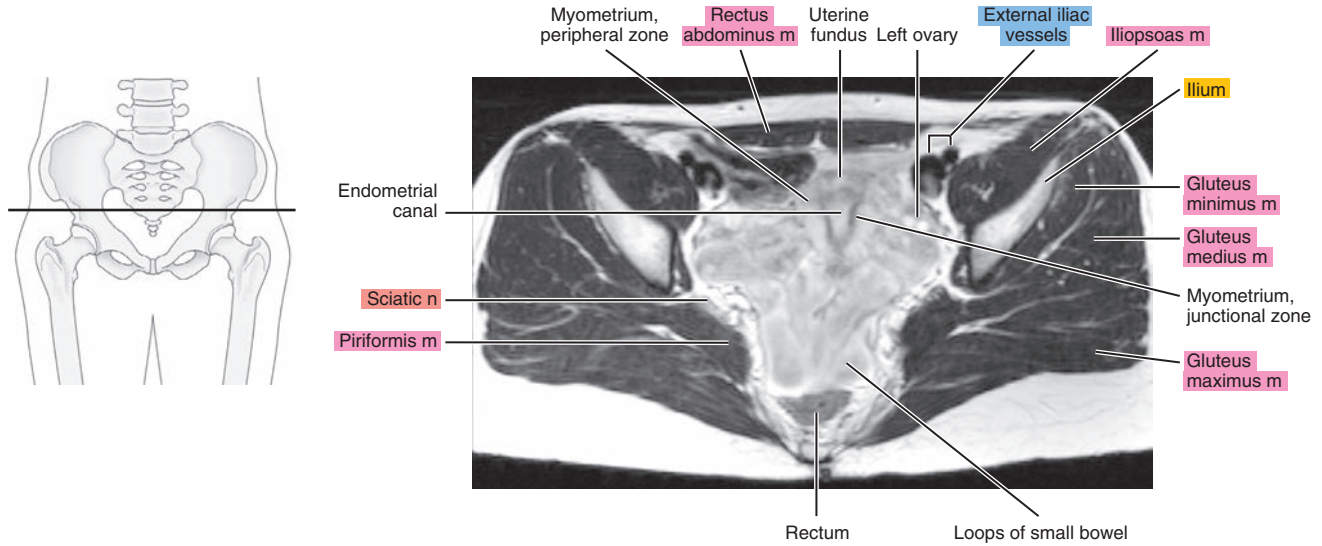


Figure 28.1.4

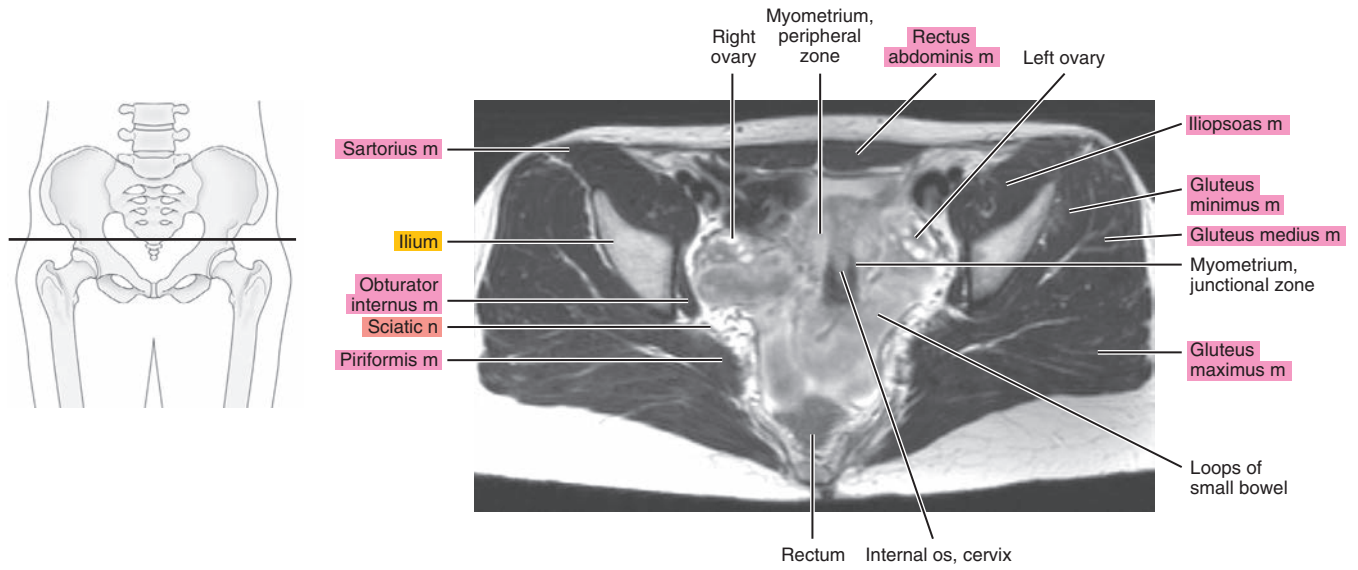




Figure 28.1.5

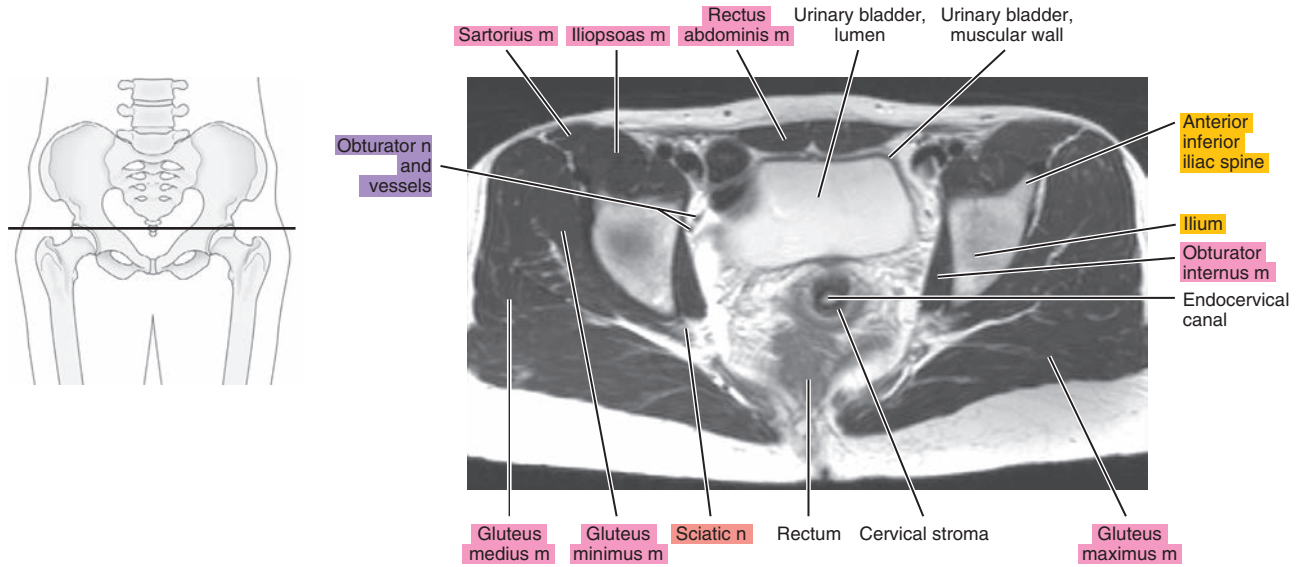


Figure 28.1.6

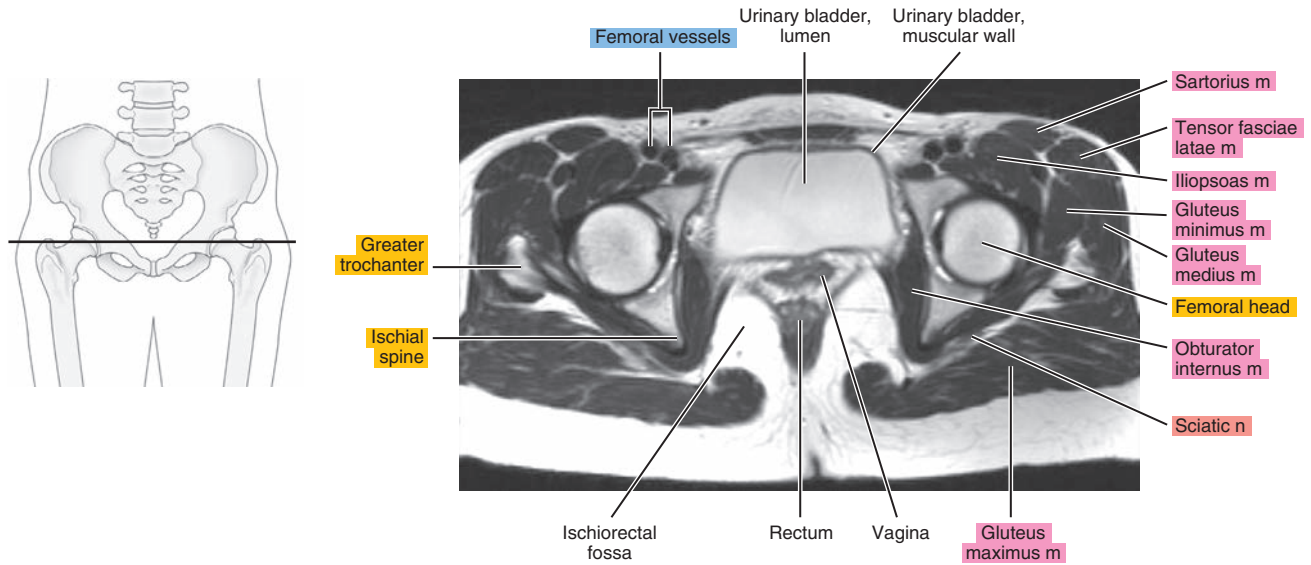


Figure 28.1.7

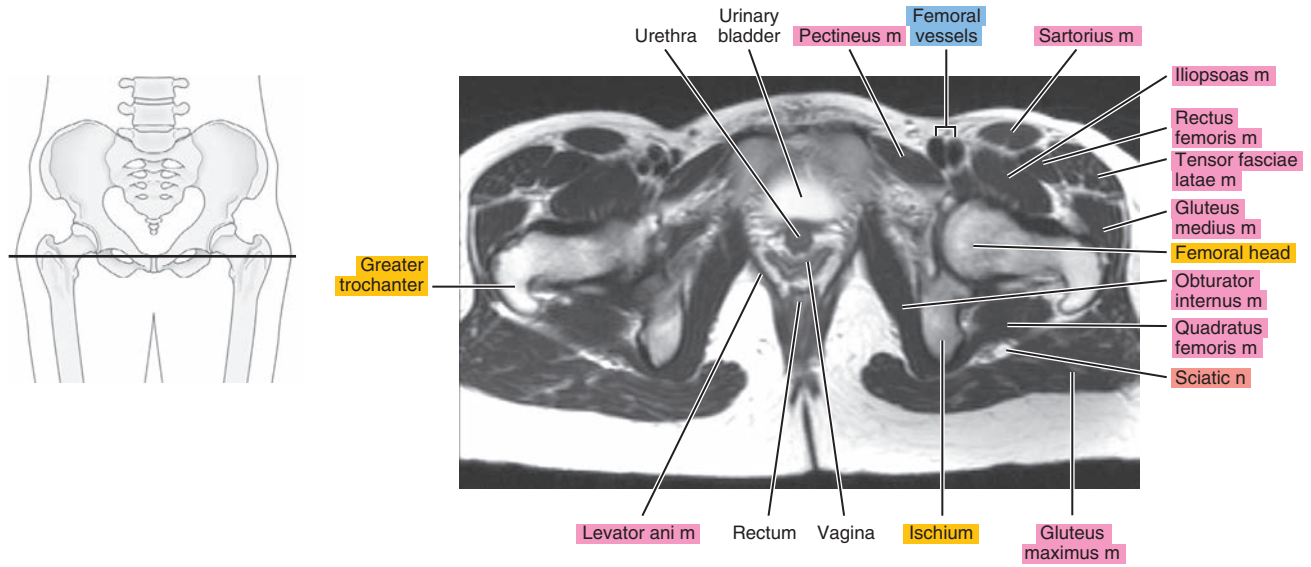
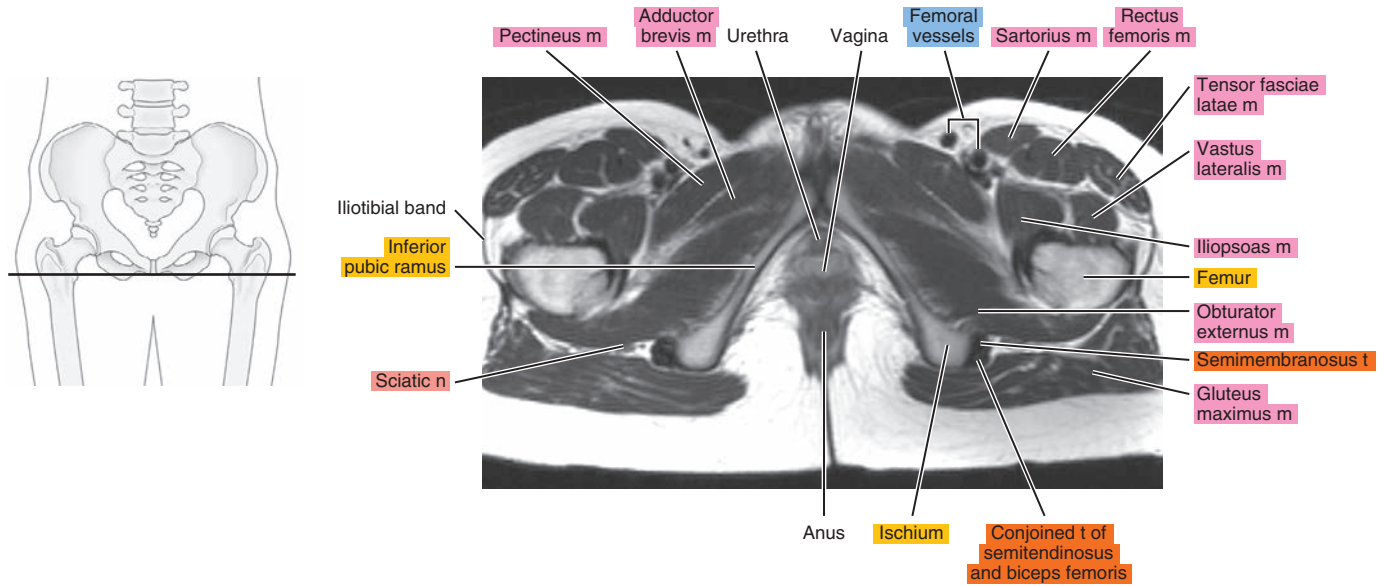


Figure 28.1.8



# SAGITTAL

Figure 28.2.1

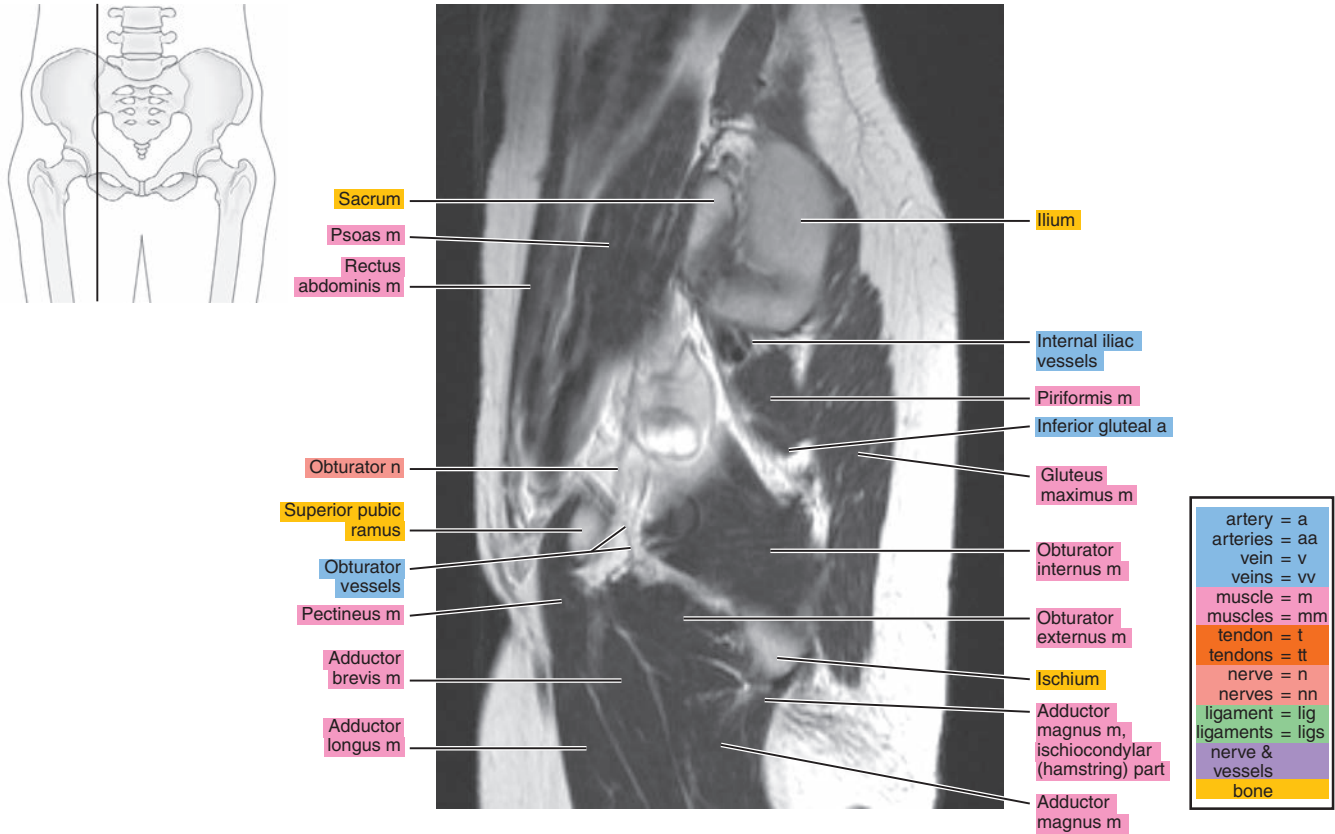


Figure 28.2.2

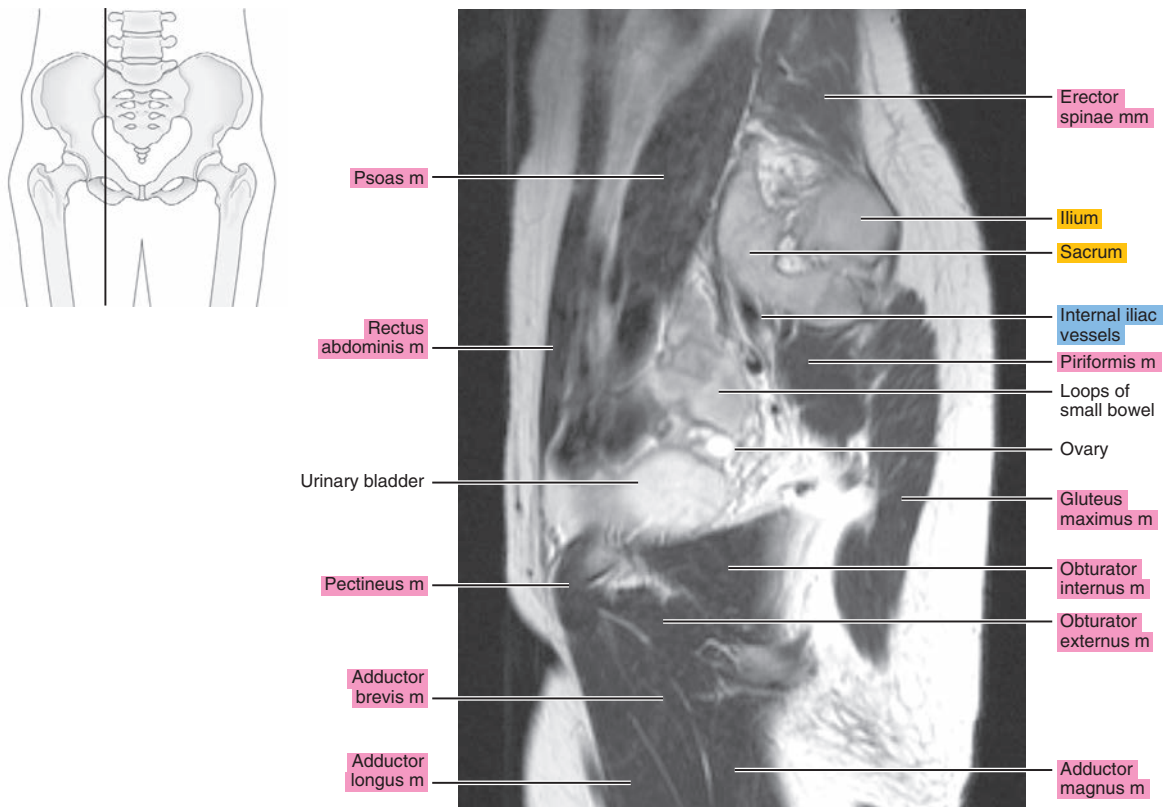


Figure 28.2.3

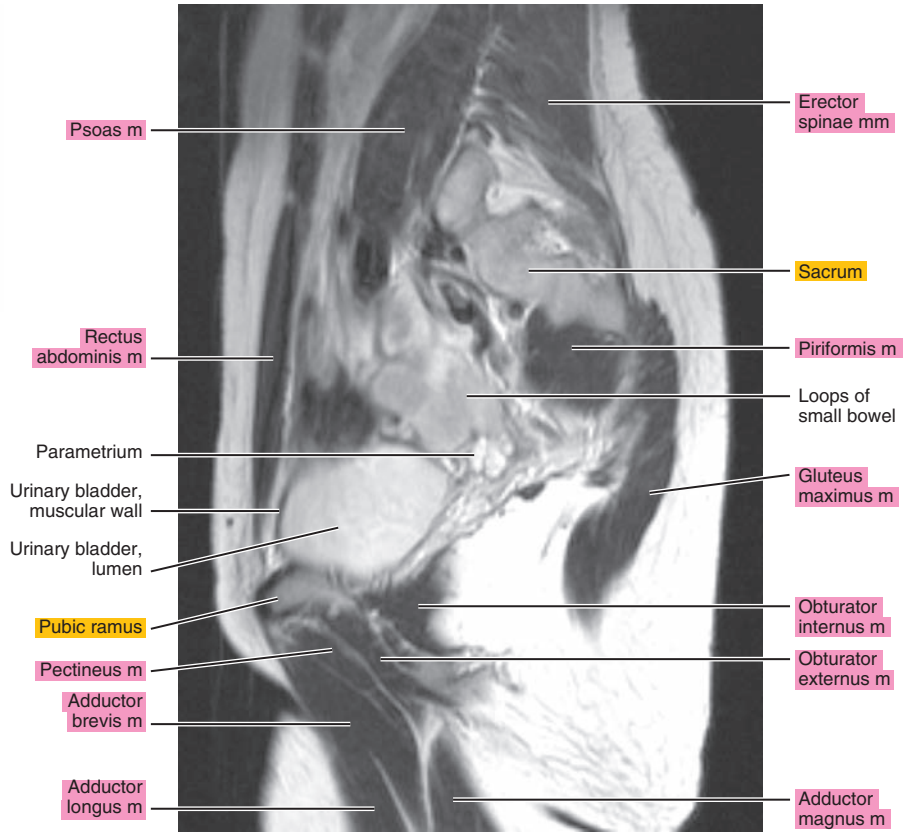
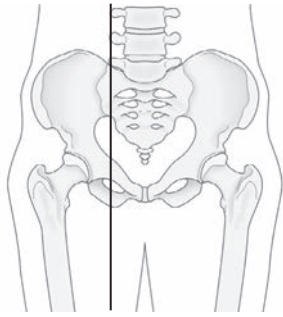


Figure 28.2.4

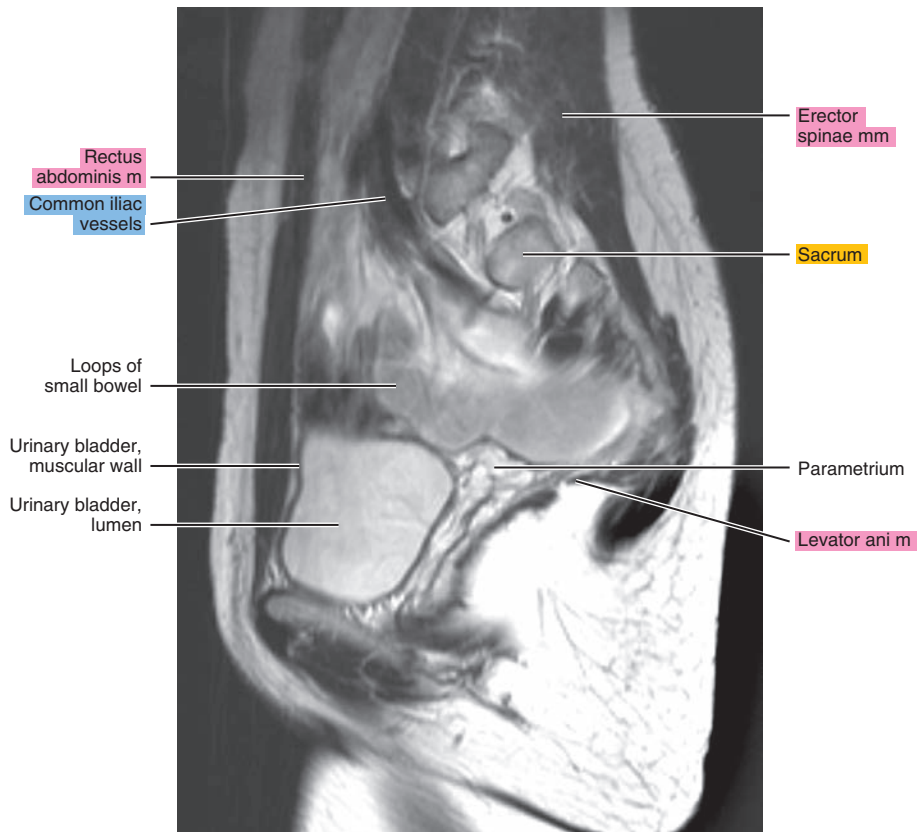
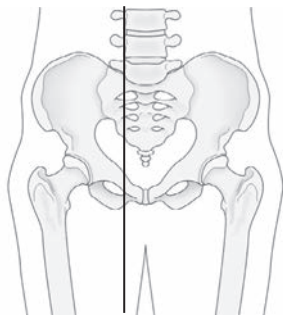




Figure 28.2.5

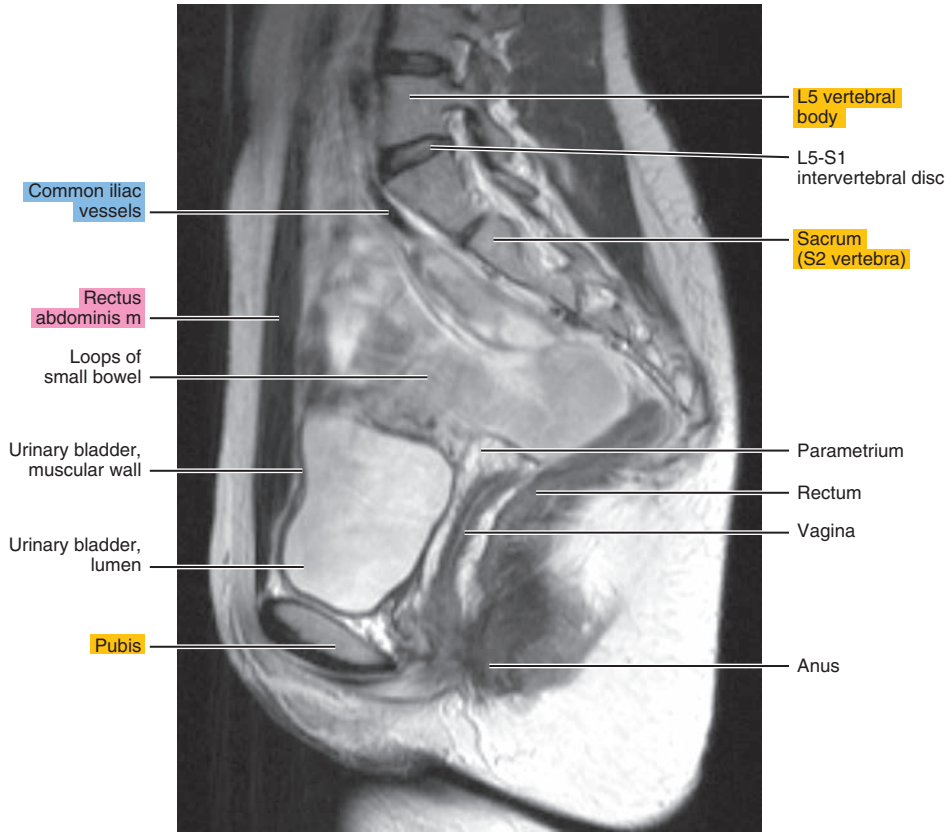
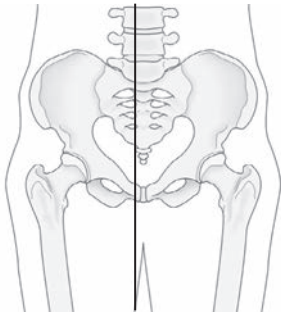


Figure 28.2.6

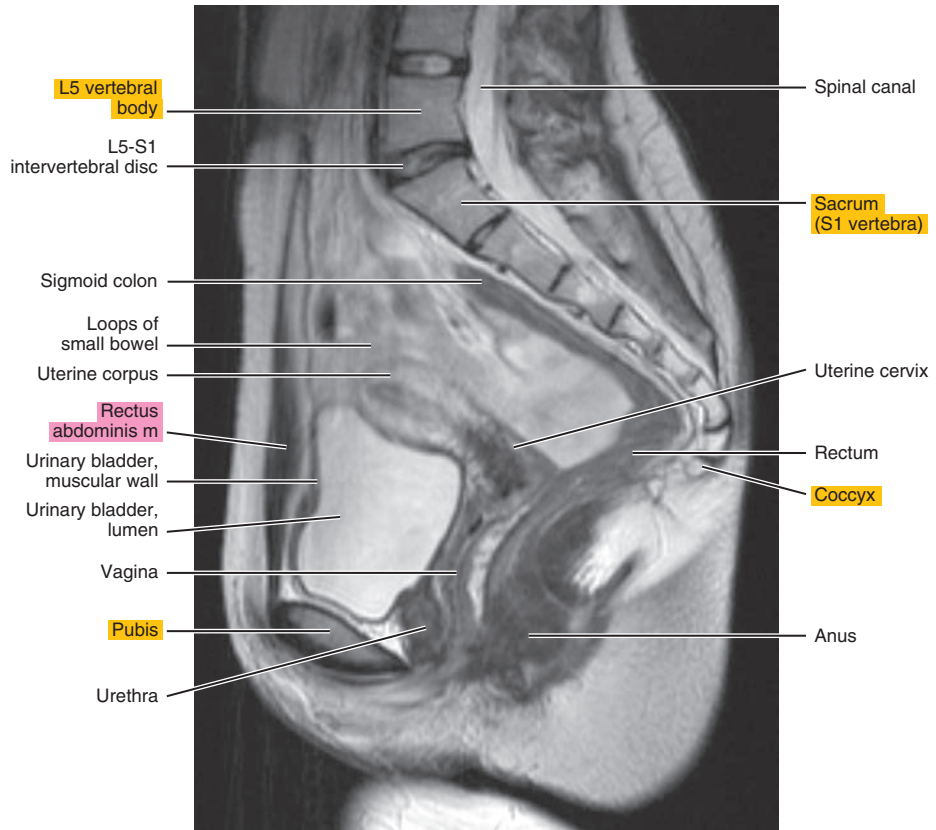
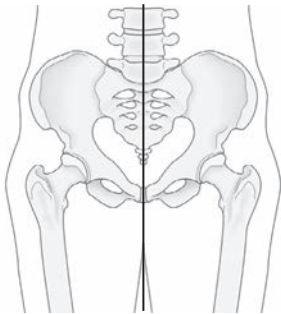
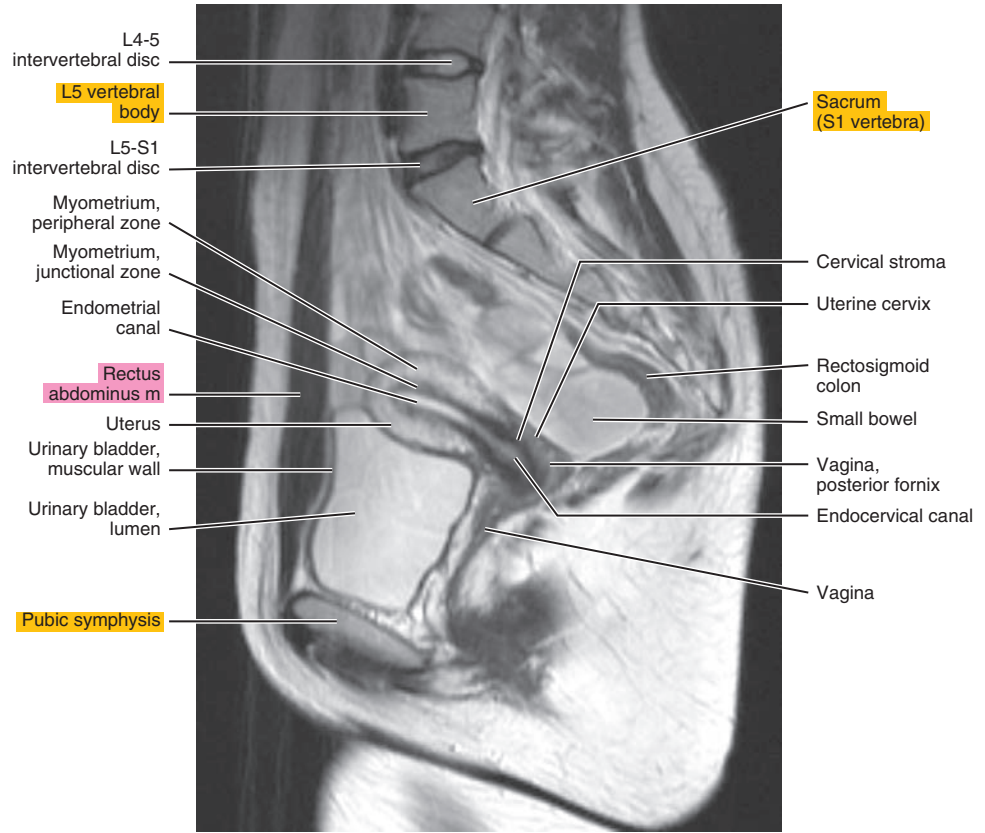
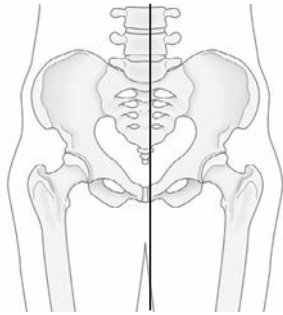


Figure 28.2.7



# CORONAL

Figure 28.3.1

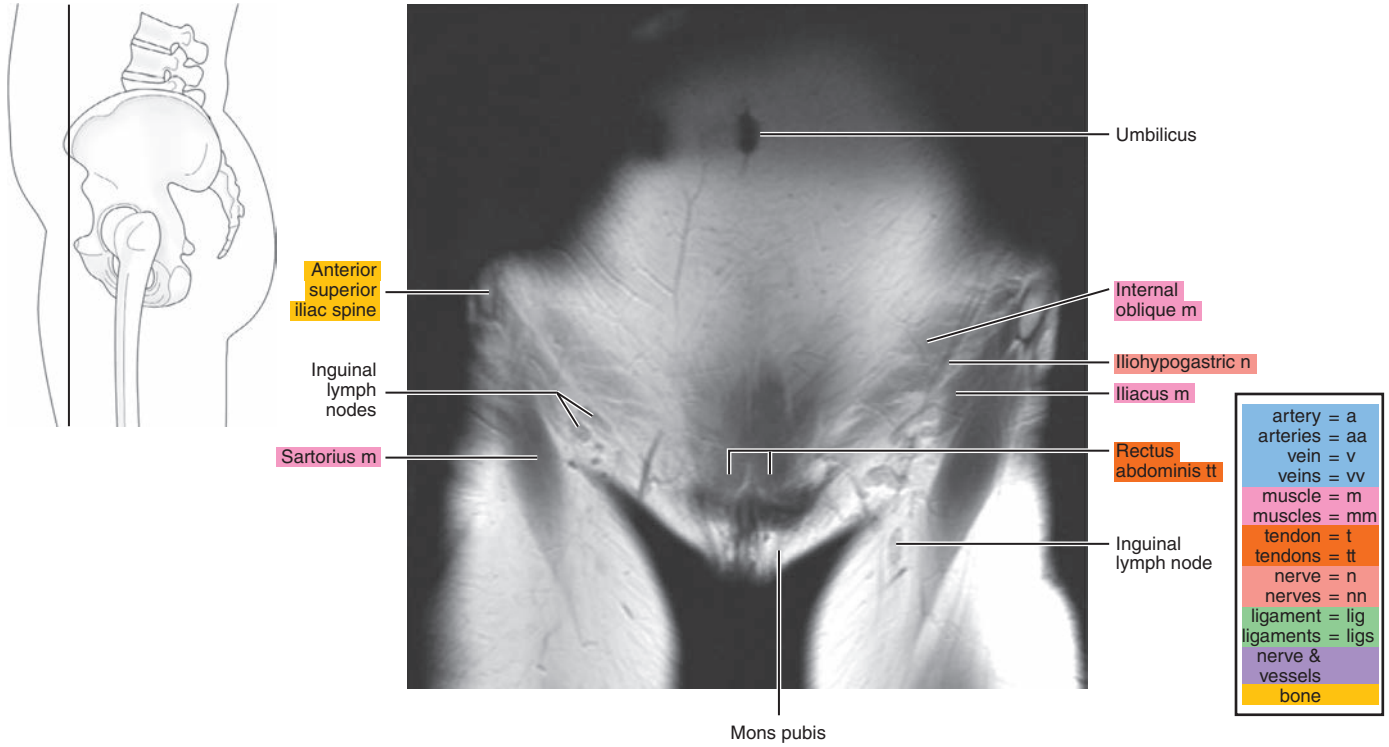


Figure 28.3.2

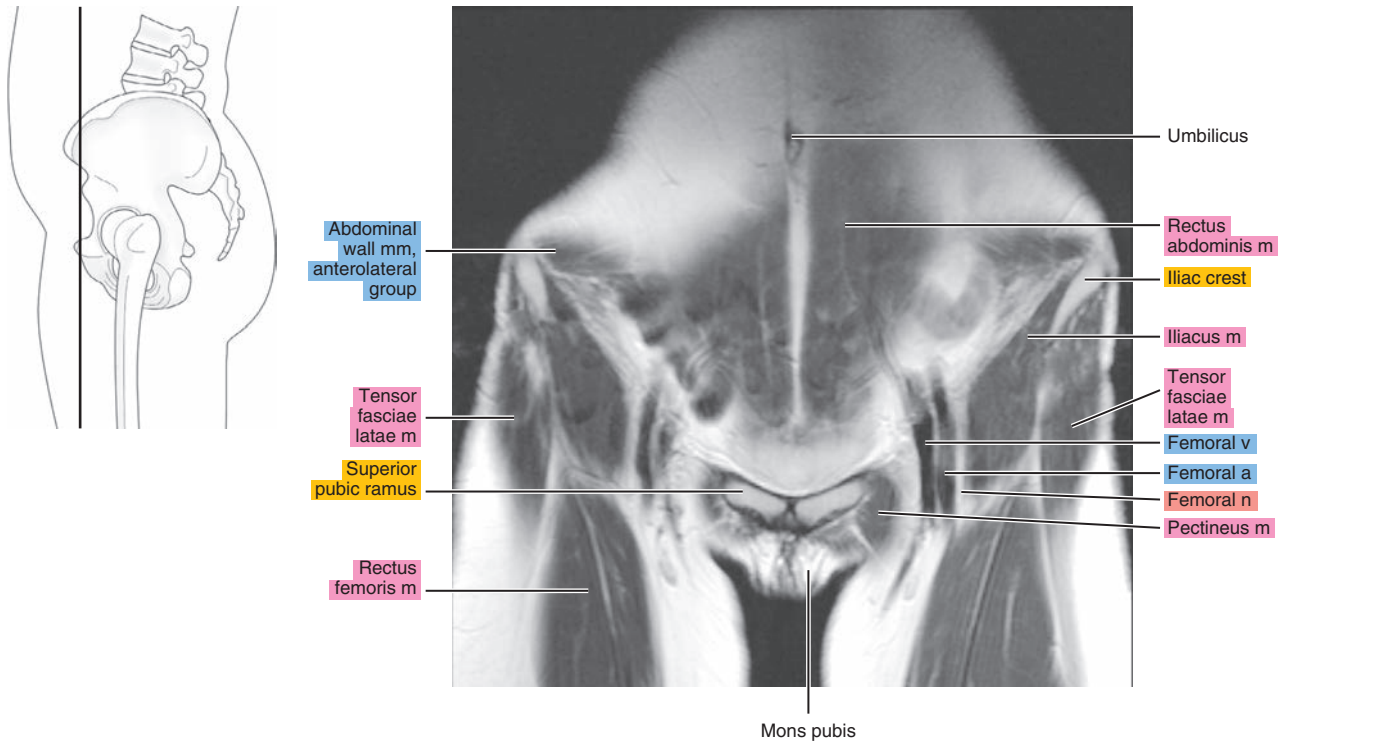


Figure 28.3.3

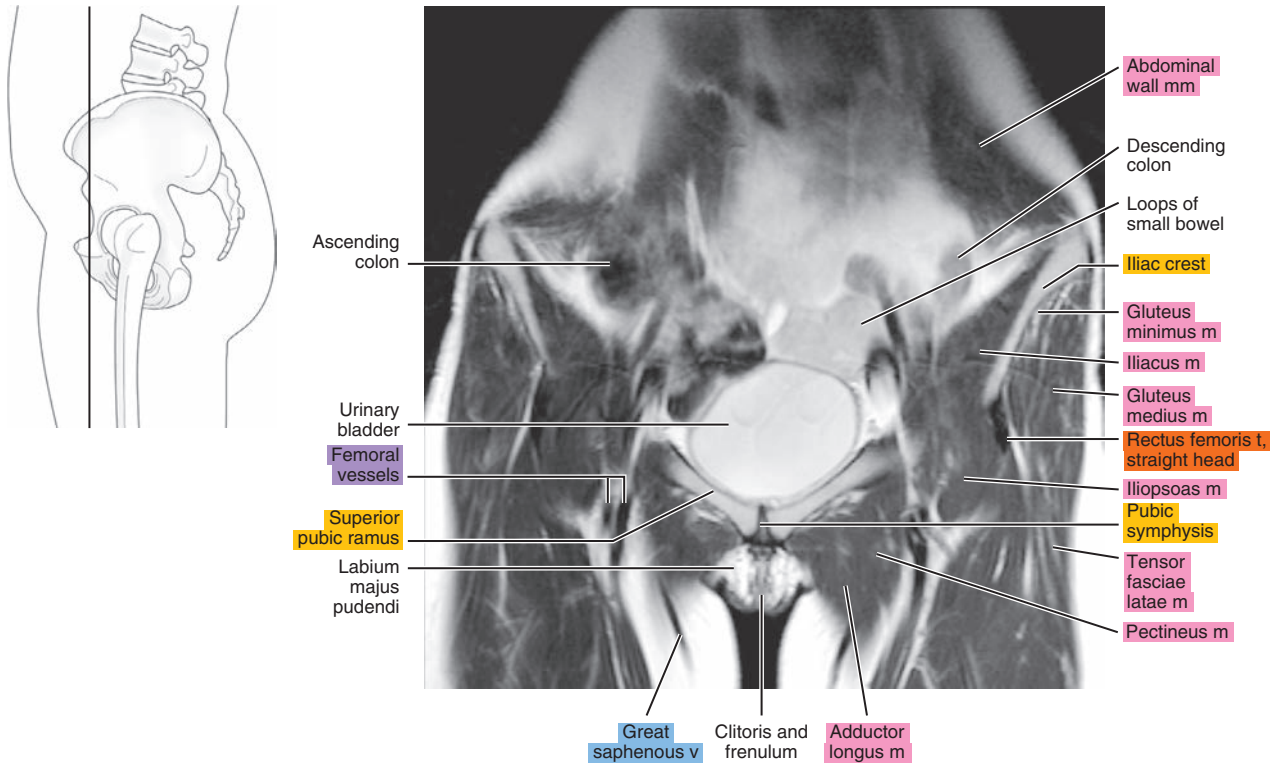


Figure 28.3.4

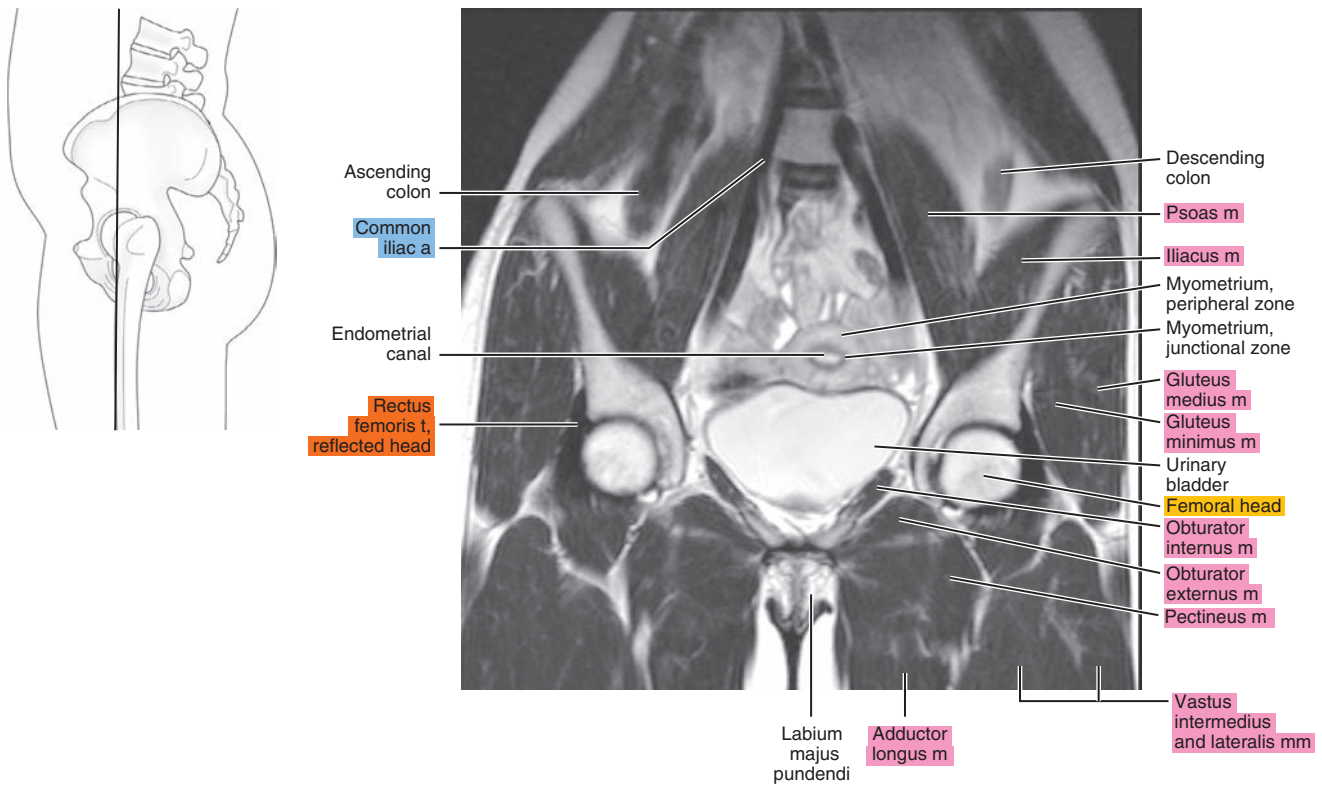




Figure 28.3.5

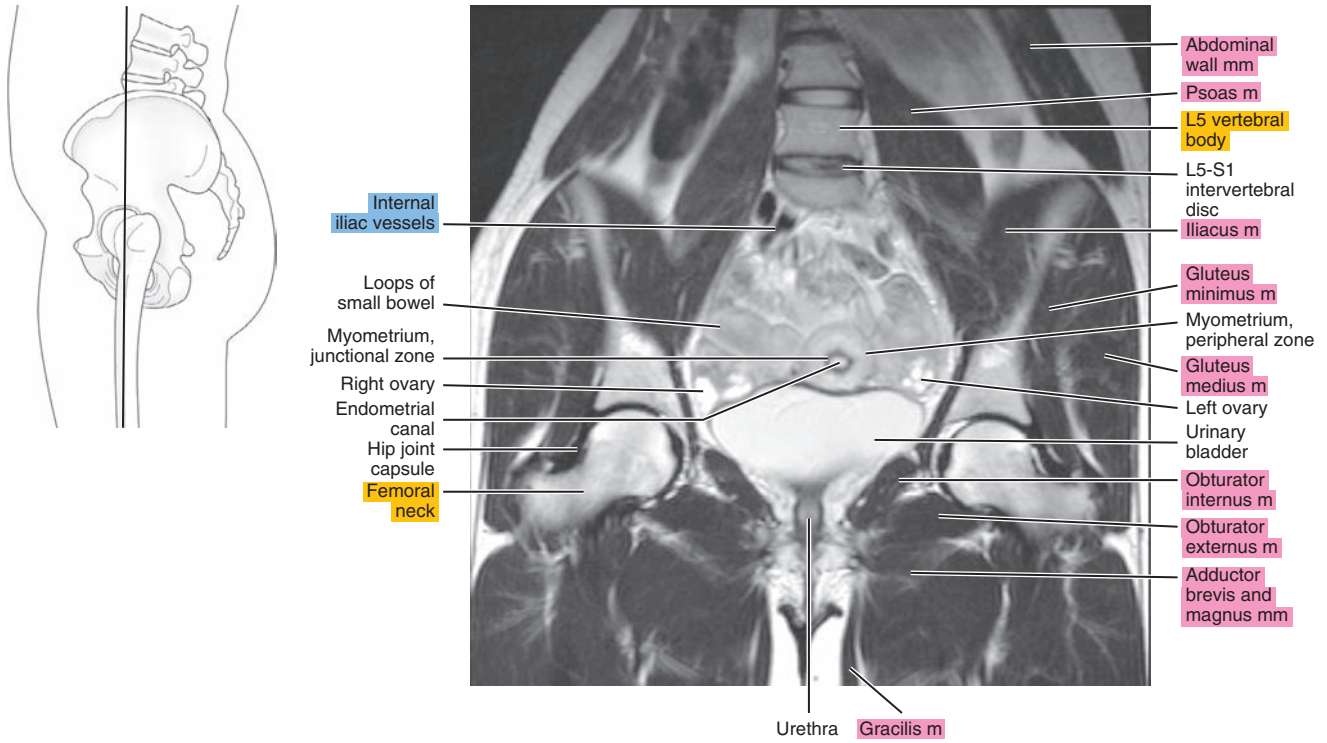


Figure 28.3.6

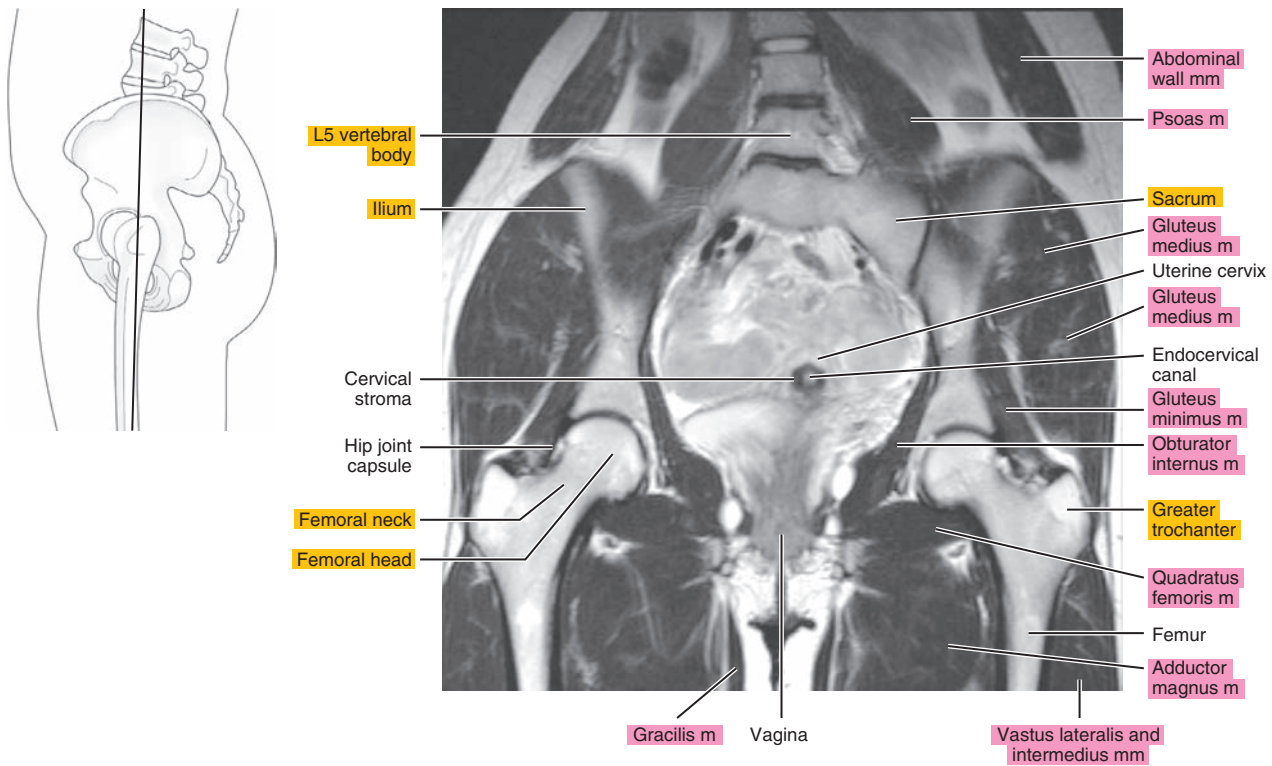


Figure 28.3.7

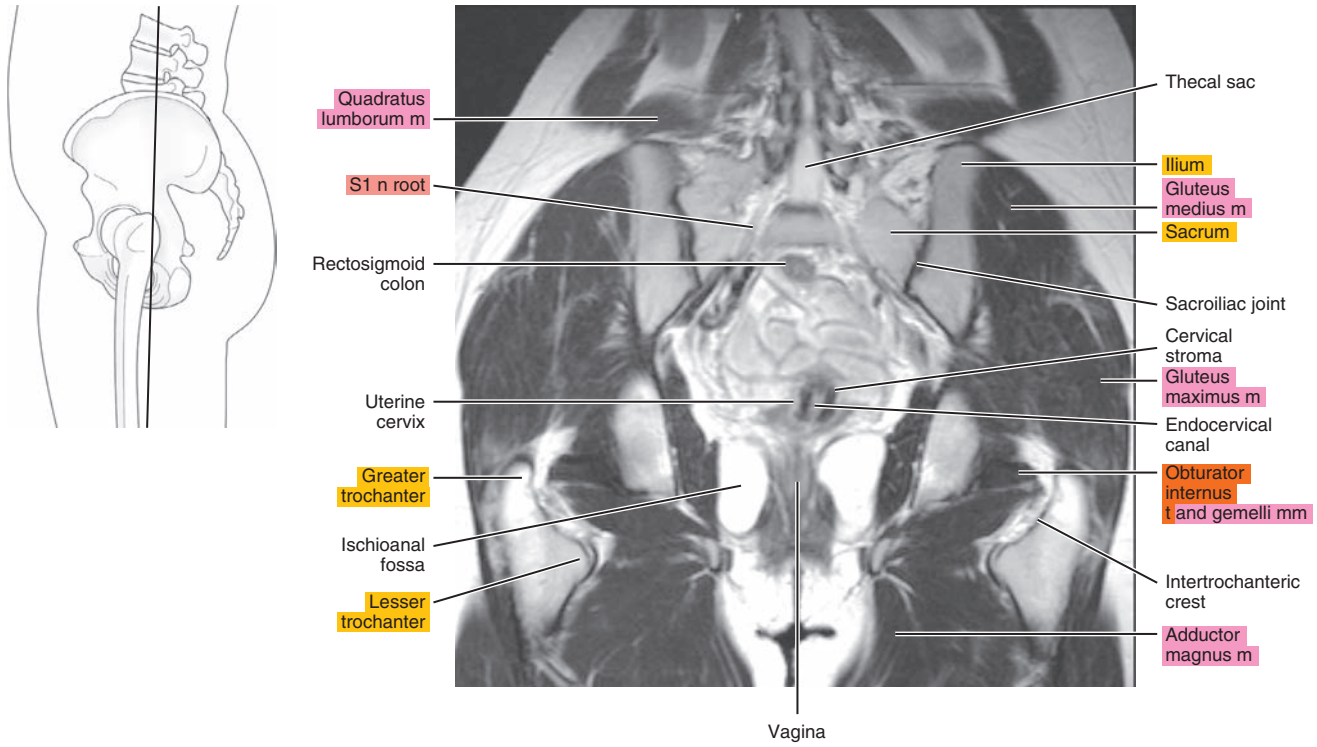


Figure 28.3.8

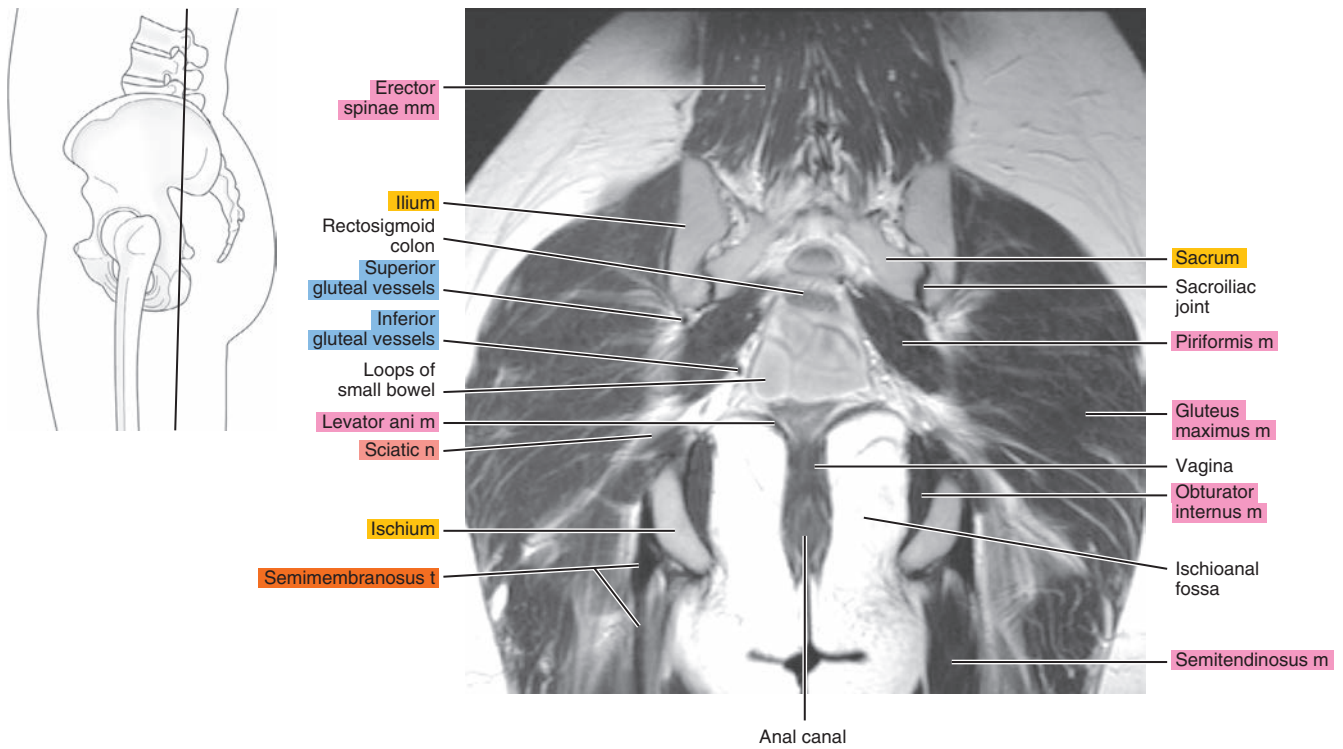
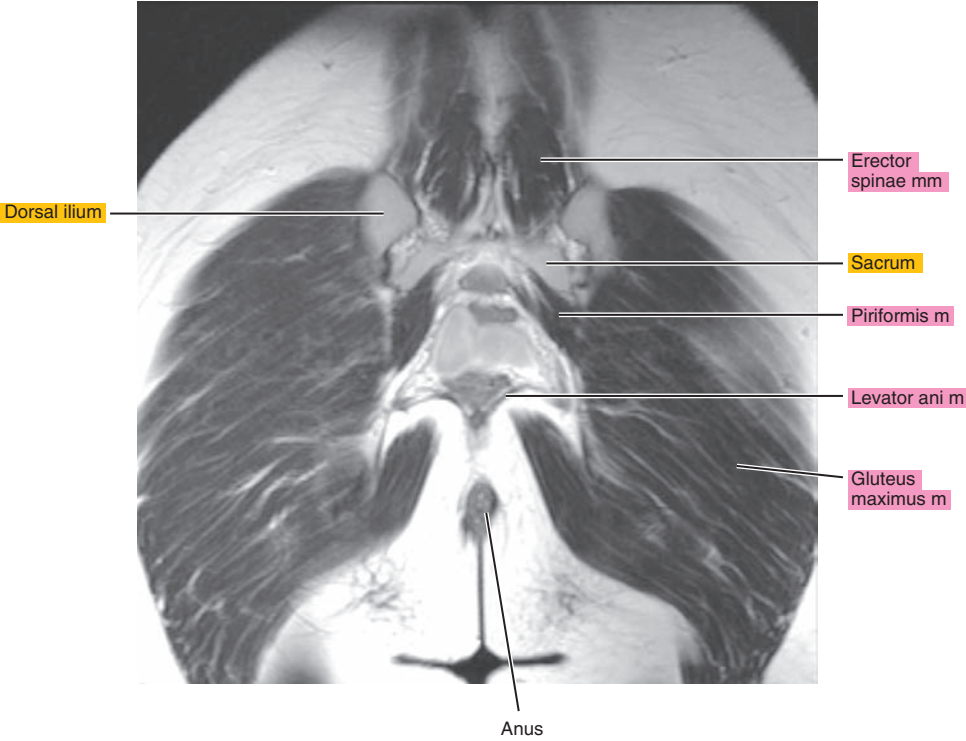
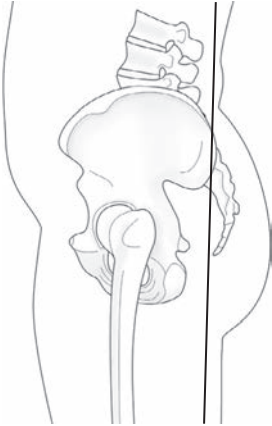


Figure 28.3.9



ClinicalKey®

# Confidence is ClinicalKey

Evidence-based answers, continually updated

The latest answers, always at your fingertips

A subscription to ClinicalKey draws content from countless procedural videos, peer-reviewed journals, patient education materials, and books authored by the most respected names in medicine.

Your patients trust you. You can trust ClinicalKey.

Equip yourself with trusted, current content that provides you with the clinical knowledge to improve patient outcomes.



ELSEVIER

Get to know ClinicalKey at [store.clinicalkey.com](https://store.clinicalkey.com).